

Vertiginous epilepsy: documentation of clinical and electrophysiological findings of nine patients

Reyhan Surmeli¹, Ayse Destina Yalcin¹, Mehmet Surmeli², Gozde Gunay²

¹ University of Health Sciences, Umraniye Training and Research Hospital, Department of Neurology, Istanbul, Turkey

² University of Health Sciences, Umraniye Training and Research Hospital, Department of Otolaryngology, Istanbul, Turkey

Received May 10, 2020; Accepted August 27, 2020

ABSTRACT – *Aims.* Epileptic vertigo is often a diagnostic problem. We aimed to present the clinical and electrophysiological features of patients with epileptic vertigo with a view to addressing the pathophysiology of this rare aura symptom.

Methods. Nine epileptic vertigo patients were included in the study. All patients were subjected to neuro-otologic examination, interictal electroencephalogram (EEG), audiogram, cervical vestibular evoked myogenic potential testing (cVEMP), video head impulse testing (vHIT) and brain magnetic resonance imaging (MRI).

Results. Eight patients described their aura as epileptic vertigo and one as dizziness. In three patients, auditory hallucinations preceded epileptic vertigo. The semiology of epileptic vertigo was true vertigo in five patients, vertigo with nausea in two patients and vertigo with hearing loss in one patient. Two patients suffered from focal seizures, and in seven patients the seizures were evaluated as focal to bilateral tonic-clonic seizures. MRI was normal in all patients. EEG was abnormal in all cases and showed high-voltage spike or spike-slow-wave complexes, or both, located more frequently in the temporal region, more left than right. On vHIT examination, abnormal responses were recorded bilaterally or unilaterally in five patients. Similarly, cVEMP revealed no response bilaterally or unilaterally in five patients. In three patients, the side of no response to cVEMP corresponded to the side of epileptiform pathology based on EEG. Two patients with bilateral abnormalities on EEG showed bilateral abnormalities either on cVEMP or vHIT, or on both. Taken together, these findings support the involvement of the brainstem connections of the peripheral vestibular system in vertiginous epilepsy.

Conclusion. The pathological results of vestibular tests in the majority of our patients, combined with the EEG abnormalities, support the hypothesis of system epilepsies which is based on the dysfunction of specific neural systems.

Key words: epileptic vertigo, EEG, video head impulse test, cervical vestibular evoked myogenic potential

Correspondence:

Reyhan Surmeli
University of Health Sciences,
Umraniye Training and Research Hospital,
Department of Neurology,
Istanbul, Turkey
<reyhansurmeli@gmail.com>

Vertigo is defined as a sense of self-movement when no self-movement occurs, or otherwise a distorted sense of self-movement during a normal head movement. Non-vertiginous dizziness is described as a sensation of disturbed or impaired spatially oriented feeling without a false or distorted sense of motion (Bisdorff *et al.*, 2009).

Epileptic vertigo is a rare form of focal seizures, frequently presenting as an aura symptom. The episodes usually last for a few seconds to minutes; unconsciousness may follow when the seizure spreads (Kluge *et al.*, 2000). Epileptic vertigo is thought to result from abnormal stimulation of central vestibular cortical structures such as the parietal, temporal and frontal cortex. These specific cortical areas include the superior lip of the intraparietal sulcus, the posterior superior temporal lobe, the posterior medial parietal lobe, the temporal parietal border regions, and the frontal cortex - left middle frontal gyrus (Blanke *et al.*, 2000; Kluge *et al.*, 2000; Kahane *et al.*, 2003; Wiest *et al.*, 2004). In addition, vestibular sensations are reported to develop upon stimulation in the occipital, frontal and insular cortex (Kahane *et al.*, 2003).

Epileptic vertigo is often a diagnostic problem when vestibular symptoms are not accompanied by symptoms and signs associated with classic focal or generalized seizures. Epileptic vertigo is easily recognized in the presence of classic seizure-related symptoms and signs such as automatism, twitching or convulsion accompanying vestibular symptoms. Epileptic vertigo with isolated vestibular symptoms has been previously reported (Kluge *et al.*, 2000; Wiest *et al.*, 2004), however, there is limited information on the prevalence and clinical and electrophysiological features of this rare aura symptom. Useful diagnostic tests for epileptic vertigo are electroencephalography (EEG) and brain magnetic resonance imaging (MRI).

In this study, we aimed to present the clinical and electrophysiological findings of nine patients with epileptic vertigo with an attempt to address the pathophysiology of epileptic vertigo based on EEG findings together with the results of vestibular tests.

Materials and methods

Up to January 2012, we diagnosed four patients with vertiginous epilepsy in our epilepsy clinic of a tertiary centre (University of Health Sciences, Umraniye Training and Research Hospital, Department of Neurology, Epilepsy Section Istanbul, Turkey). A prospective study of these patients was then initiated in order to detect their clinical and electrophysiological features. Aura and ictal symptomatology were assessed from the patients' own description and their first-grade relatives who had observed their seizures. In all cases, a

thorough neuro-ophthalmologic and neuro-otologic clinical examination was performed by two of the authors (ADY or RS, and MS), including description of nystagmus, positive or negative video head impulse test (vHIT), and presence of a typically biphasic response for the cervical vestibular evoked myogenic potential test (cVEMP). In addition, all patients underwent neuroimaging and periodically repeated EEG examination.

After the patients gave their informed consent, they underwent video-EEG investigation using a 32-channel device (Micromed, Italy) for routine EEG recording during the interictal period. The electrodes were placed according to the international 10-20 system, and both bipolar and referential montages were used. EEG tests were performed for at least 30 minutes in an environment with favourable conditions. All patients underwent intermittent photic stimulation, hyperventilation for five minutes and examination for eye opening and closing. EEG interpretation was performed based on longitudinal, transverse and other appropriate montages.

Brain imaging of all patients was performed with a 1.5T MRI scanner (Siemens Healthcare, Erlangen, Germany).

v-HIT recordings were performed with the EyeSeeCam system (Interacoustics a/s, Middelfart, Denmark). For the recording, light and tightly fitting glasses were used, on which a small video camera and a half-silver mirror reflecting the eye image (left side) were mounted. Patients were asked to focus on a stationary target, which was placed on the wall at a distance of 1.2 meters. Calibration was performed prior to each recording. For the test, head impulse at a velocity of 1500 - 2000/s was applied at 15-20 degrees to the lateral side of the midline along both lateral semi-circular canal axes in an unpredictable manner. Fifteen recordings were made separately for each side. VOR gains at 40-60 and 80 ms were recorded. Mean VOR gain at 60 ms was taken for evaluation. Normal values for VOR gain were considered 0.8-1.2.

c-VEMP recordings were performed with an evoked potentials machine (Eclipse EP- 25/VEMP; Interacoustics, Denmark). The active electrode was placed in the middle of the same sternocleidomastoid (SCM) muscle, the upper two-thirds of the reference electrode SCM, and the centre electrode in the middle of the forehead. The test was performed once, in silence, in the sitting position and during the awake state. A warning was communicated to the right and left ear, and ipsilateral recordings were obtained. Electrode impedance was <5 k Ω . The acoustic stimulus was 100dB for 0.1 ms and was delivered to each ear separately at 5 Hz. The EMG signal was filtered in the range of 10 to 500 Hz and averaged over a 100 ms interval. Average of a total of 200 results. P13 and N23

positive / negative polarity were measured as peak waves. P13 and N23 peak latencies and P13-N23 inter-peak amplitudes were calculated.

vHIT and cVEMP recordings were evaluated during the interictal period in all patients.

Case 1 (39-year-old, male)

The patient visited our epilepsy outpatient department after his second generalized seizure and had been suffering from focal seizures since he was 15 years old which started with a sensation that the environment was spinning in horizontal plane, lasting approximately for 10-20 seconds, followed by hyper-salivation that caused saliva to drip from the right edge of his mouth, and deviation of his eyes and head to the right side. He had more than 10 seizures in the previous month, of which two were focal to bilateral tonic-clonic seizures. He also described some episodes lasting longer than one hour, characterized by aura symptoms which were interpreted as non-convulsive status epilepticus episodes. His repeated EEGs showed sharp-slow-wave activity located in both posterior temporal regions which were more prominent on the left side. During the follow-up period lasting for 24 years, he was seizure-free first under carbamazepine (CBZ) and later levetiracetam (LEV) monotherapy, but had a relapse as we attempted to reduce his CBZ dosage. vHIT and cVEMP responses were evaluated as bilaterally normal (table 1).

Case 2 (42-year-old, male)

The patient was referred to our epilepsy outpatient department because of his pathological EEG findings. When he was 20 years old, he began to complain about a strange sound in his right ear that sounded like a running machine which increased in intensity; the sound was then heard on the left side, followed by a sensation that the environment was spinning in vertical plane, up and down, and nausea. The whole episode lasted for approximately one minute. Also, he had focal to bilateral tonic-clonic seizures frequently during Ramadan when he was fasting. In the follow-up period, lasting 20 years, he had an episode of convulsive status epilepticus in Ramadan, probably due to a long period of starvation and impaired sleep rhythm. He had spike-wave complexes in the left temporal region, in line with his ictal symptoms in the right ear. Under 800 mg per day CBZ treatment, he was seizure-free. vHIT and cVEMP responses were evaluated as bilaterally normal (table 1).

Case 3 (36-year-old, male)

The patient suffered from a strange sound in his right ear which he described as a sound associated with diving deep under water. The sound became louder, passing over to the left side, accompanied by a sensation that the environment was spinning. The episode lasted a few seconds. These attacks began when he was 24 years old and repeated once or twice weekly. He was examined by many otologists and took different medications, but his complaints continued. After a

Table 1. Relationship between side of EEG anomaly and response to vHIT and cVEMP.

Patient	EEG anomaly	VOR gain		cVEMP	
		Right	Left	Right	Left
1	Bitemporal	0.93	0.88	+	+
2	Left temporal	0.83	0.81	+	+
3	Left temporal	0.88	0.80	+	-
4	Left temporal	0.78	0.61	+	-
5	Bitemporo-parietal	0.65	0.60	-	-
6	Bitemporal	0.67	0.71	+	+
7	Left temporal	0.49	0.98	-	-
8	Right temporal	0.72	0.84	-	+
9	Left temporal	0.84	0.92	+	+
		0.75 ± 0.14	0.79 ± 0.13	55.5% (-)	

VOR: vestibulo-ocular reflex; CVEMP: cervical evoked myogenic potential; + : responded; - : non-responded; M: male; F: female.

head trauma caused by an attack, he was examined by our team in the emergency department and diagnosed with epilepsy. His repeated EEGs revealed spike-wave activity in the left temporal region in accordance with the initial auditory ictal symptoms in the right ear. Under 1,250 mg LEV, he has been seizure-free for nine years. vHIT response was evaluated as bilaterally normal, however, there was no cVEMP response on the left side (*table 1*).

Case 4 (36-year-old, female)

The patient was referred to our epilepsy outpatient department by an otologist for consultation. She described a strange motion sensation inside her head as if she was swinging on a ship in stormy weather, which repeated many times daily for six months, and each episode lasted for 10-20 seconds. Her EEG showed high-voltage sharp-wave activity in the left temporal region which was enhanced during hyperventilation. She did not have any generalized convulsion and has been seizure-free under 1,000 mg LEV treatment for five years. vHIT was evaluated as bilaterally abnormal. Additionally, there was no cVEMP response on the left side (*table 1*).

Case 5 (30-year-old, male)

The patient sought medical advice when he was 17 years old because of repeated focal to bilateral tonic-clonic seizures during the last two years. He described nausea, a sensation that the environment was spinning from right to left, deviation of his eyes and head to the left side, and making a half circle with his trunk to the left side. After these symptoms, he lost consciousness. His repeated EEGs delineated high-voltage sharp-slow wave activity in both temporal regions, extending to the parietal region. Under 1,000 mg LEV treatment, his seizures did not repeat during a follow-up period lasting 15 years. vHIT was evaluated as bilaterally abnormal. Additionally, the cVEMP test demonstrated no response bilaterally (*table 1*).

Case 6 (28-year-old, female)

The patient described three episodes in the last year which started with a sensation of urgency that woke her up in the middle of the night, followed by sliding of objects seen in horizontal plane, from left to right, and loss of consciousness. In the last episode, she fell down and was injured. Her subsequent EEGs during the follow-up period lasting eight years showed sharp-slow-wave complexes in both temporal regions, appearing independently of each other. Under oxcarbazepine treatment (900 mg/day) she has

been seizure-free. vHIT was evaluated as bilaterally abnormal, however, cVEMP response was evaluated as bilaterally normal (*table 1*).

Case 7 (53-year-old, female)

The patient complained of episodes characterized by a spinning sensation inside her head, followed by total loss of hearing. Some of these attacks were associated with loss of consciousness and she injured herself. She was suffering from these attacks since she was 28 years old and was sent to psychiatrists because her episodes were interpreted as psychological. She was referred to our epilepsy outpatient department after she fell down from a ladder and was injured during an attack. Her EEGs showed high-voltage sharp-slow-wave activity in the left temporal region which was increased during hyperventilation. She has been seizure-free under valproate (1000 mg/day) treatment for five years. vHIT was evaluated on the right side as abnormal; the cVEMP test demonstrated no response bilaterally (*table 1*).

Case 8 (45-year-old, female)

The patient was seen in our emergency department after her third focal to bilateral tonic-clonic seizures. Her medical history included nearly identical episodes which started in childhood and were characterized by a dizziness sensation, unsteadiness, nausea, vomiting, and excessive sweating, lasting a few minutes and ending with falling asleep. Her seizure frequency was a few per year and she had three focal to bilateral tonic-clonic seizures, each starting with aura symptoms appearing in her focal seizures. She did not consult a doctor for these attacks. Her EEGs showed sharp-slow-wave complexes in the right temporal region. Under LEV treatment (1,000 mg/day), she has been seizure-free for 15 years. vHIT was evaluated on the right side as abnormal. Additionally, the cVEMP test demonstrated no response on the right side (*table 1*).

Case 9 (25-year-old, female)

The patient suffered from a crackling sound in her right ear, which increased in intensity, accompanied by a spinning sensation inside her head lasting almost one minute, for two years. The frequency of the attacks was two or three times per month. She explained that these complaints were due to tiredness. In the last two attacks, she lost consciousness and was referred to our epilepsy department with a possible diagnosis of epilepsy when she was 20 years old. Her repeated EEGs showed high-voltage sharp waves in the left temporal region and generalized spike-wave discharges during

hyperventilation. She has been seizure-free under LEV treatment for five years. vHIT and cVEMP responses were evaluated as bilaterally normal (*table 1*).

Results

We included four male and five female patients with a diagnosis of epileptic vertigo in the study. The age at onset ranged between 15 and 31 years and the age at the last examination was between 25 and 53 years. None of our patients had febrile seizures, head trauma, or a family history of epilepsy or consanguinity. Eight patients described their aura as epileptic vertigo and one as dizziness. In three patients, auditory hallucinations preceded epileptic vertigo. The semiology of epileptic vertigo was true vertigo in five, vertigo with nausea in two and vertigo with hearing loss in one patient. Two patients suffered from focal seizures and in seven patients the seizures were evaluated as focal bilateral tonic-clonic seizures (*table 2*).

EEG was abnormal in all cases, showing high-voltage spike or spike-slow-wave complexes, or both, located in the left temporal region in four (44%), bitemporal in two (22%), right temporal in one (11%), left temporal

Table 2. Clinical features of patients with epileptic vertigo.

Gender (M/F)	4/5
Mean age (year)	37.11 ± 8.8 (25-53)
Mean age at onset (year)	22.8 ± 5.8 (15-31)
Follow-up duration (year)	14.3 ± 7.8 (5-25)
Family history of epilepsy	None
Past history of febrile convulsion	None
Past history of trauma	None
Aura	
Sound of a running machine	1 (Case 2)
Sound of being deep underwater	1 (Case 3)
Sound of crackling	1 (Case 9)
Semiology	
Dizziness	1 (Case 8)
True vertigo	5 (Case1, 3, 4, 6, 9)
Vertigo with nausea	2 (Case2, 5)
Vertigo with hearing loss	1 (Case 7)
Seizure types	
Focal seizure	2 (Case 3, 4)
Focal to bilateral tonic-clonic seizure	7 (Case 1, 2, 5, 6, 7, 8, 9)

M: male; F: female.

Table 3. EEG abnormalities associated with epileptic vertigo.

EEG findings	
Left temporal epileptic activity	4 (Case 2, 3, 4, 7)
Bitemporal epileptic activity	2 (Case 1, 6)
Left temporal with secondary generalization	1 (Case 9)
Right temporal epileptic activity	1 (Case 8)
Bitemporo-parietal epileptic activity	1 (Case 5)

with secondary generalization in one (11%), and bitemporo-parietal in one (11%) (*table 3, figure 1*).

On vHIT examination, abnormal responses were recorded in five (55.5%), bilateral in three (Case 4, 5 and 6) and unilateral in two (Case 7 and 8). Similarly, cVEMP revealed no response in five (55.5%), bilateral in two (Case 5 and 7) and unilateral in three (Case 3, 4 and 8) (*table 1*). In three patients, the side of no response to cVEMP corresponded to the side of epileptiform pathology on EEG (Cases 3, 4 and 8). Two patients with bilateral abnormalities on EEG, located in temporal and temporoparietal regions (Case 5 and 6), showed bilateral abnormalities either on cVEMP or vHIT, or on both (*table 1*).

Brain MRI was normal in all patients.

Discussion

Vertigo as a manifestation of epilepsy was first described by Hughlings Jackson (Kogeorgos *et al.*, 1981). Today, the brief episodes of vertigo are widely believed to be due to epilepsy, and 19% of temporal lobe epilepsy presents as vertigo only (Pedersen and Epton, 1956; Erbayat Altay *et al.*, 2005).

There is no valid information supporting the genetic transition in epileptic vertigo. In limited patient series and in a small number of cases, the presence of epilepsy in the family has been reported (Saad *et al.*, 2011). None of our cases had a family history of epilepsy.

Vertigo alone may be an aura. Also, epileptic vertigo is sometimes preceded by other aura symptoms, as described by three of our patients (33%) as the sound of a running machine, diving deep under water and crackling. These findings are compatible with previous studies (Hughes and Drachman, 1977; Kluge *et al.*, 2000).

Isolated epileptic vertigo is less common than non-isolated epileptic vertigo. There is no diagnostic parameter specific to epileptic vertigo. Therefore, it takes a long time to establish the correct diagnosis, as in some of our patients. Two of our cases were evaluated as isolated epileptic vertigo, which is also

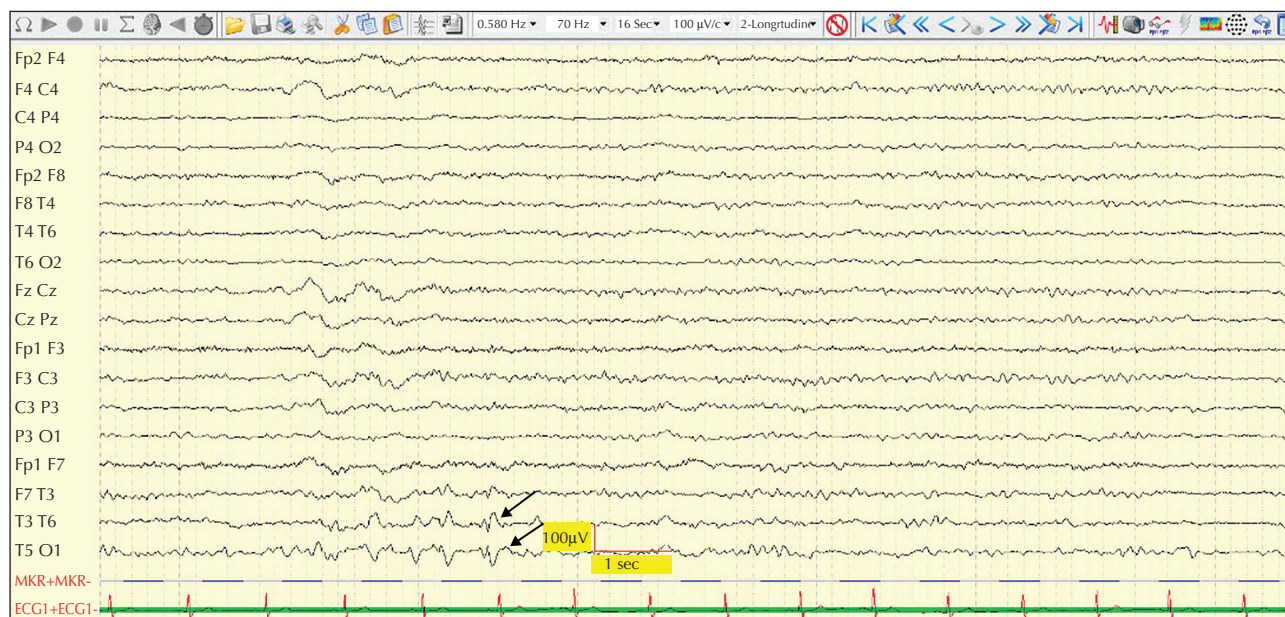


Figure 1. EEG recorded during the interictal period showing spike-slow-wave complexes located in the left posterior temporal region, lasting for 2.5 seconds. Epileptiform activity is indicated by haros.

reported in other studies (Ransohoff and Feinstein, 1978; Tarnutzer *et al.*, 2015).

In all patients, vertigo occurred in brief episodes, each lasting for a few seconds to a few minutes. In two cases with isolated epileptic vertigo, episodes were generally much briefer (lasting seconds) than those of non-isolated epileptic vertigo.

There is no consensus about the exact location of epileptogenic focus causing epileptic vertigo. In most studies, the temporal lobe was found to be affected (Hughes and Drachman, 1977; Ransohoff and Feinstein, 1978; Saad *et al.*, 2011; Tarnutzer *et al.*, 2015). In our study, EEG was abnormal in all cases, in the form of focal high-voltage spike or spike-slow wave activity, reported mainly in the left temporal region (55%). In one study, right hemisphere dominance was suggested for epileptic vertigo (Hewett *et al.*, 2011). In another study, no statistically significant differences were found, however, localisation in the left hemisphere has been reported to be more common (Tarnutzer *et al.*, 2015). In attempting to accurately identify the cortical area responsible for epileptic vertigo, cortical stimulation was used. As known, this may induce dysfunction rather than functional activation of a stimulatory region. For this reason, the area of vertigo defined by cortical stimulation may not correspond to the symptomatogenic area of the epileptic vertigo. Studies of patients with epileptic vertigo and concurrent EEG monitoring are scarce in the literature. One comprehensive study including

40 patients who experienced epileptic vertigo or dizziness as aura revealed five different regions as seizure onset site, including even the mesial temporal lobe. An intracranial EEG with cortical stimulation was performed in seven of these 40 patients, but the area of stimulation that induced vertigo overlapped with the ictal onset area in only one patient (Kim *et al.*, 2016).

We found good response rates to antiepileptic drug treatment in all patients with epileptic vertigo. Antiepileptic drugs included carbamazepine, valproate, levetiracetam and oxcarbazepine. In a previous study, antiepileptic drug response rate in patients with epileptic vertigo was reported to be 90% (Tarnutzer *et al.*, 2015).

Although temporal lobe lesions have been reported as underlying causes of epileptic vertigo (Saad *et al.*, 2011), no demonstrable pathology was detected on brain imaging performed in any of our patients.

Further clinical tests that may help to evaluate the peripheral vestibular system and central connections are the cVEMP and vHIT. These are useful bedside tests in acute vestibular syndrome patients as they are quick and easy to perform. cVEMP is used to evaluate the vestibulo-collic reflex and is mostly used for peripheral diseases such as acoustic neurinoma and Meniere's disease, but also provides information about the brainstem. vHIT is used to evaluate the gain of vestibulo-ocular reflex (VOR), and the abnormal vHIT is suggested to be the most reliable single tool to prospectively differentiate between central

and peripheral causes of acute vestibular syndrome (Newman-Toker *et al.*, 2008). In 55.5% of our cases, unilateral or bilateral abnormalities were observed during vHIT responses. Similarly, cVEMP responses could not be obtained unilaterally or bilaterally in 55.5 % of the cases. These findings may support the involvement of brainstem connections of the peripheral vestibular system in patients with vertiginous epilepsy. Furthermore, in three patients, the side of no response to cVEMP corresponded to the side of epileptiform pathology on EEG, and two patients with bilateral abnormalities on EEG, located in temporal and temporo-parietal regions, showed bilateral abnormalities either on cVEMP or vHIT, or on both. In our opinion, this overlap between EEG abnormalities and pathological cVEMP and vHIT results confirms the dysfunction of the vestibular network in patients with epileptic vertigo.

As a limitation of the study, only nine patients were included and only video scalp EEG recordings were performed for our patients. Invasive intracranial EEG monitoring is necessary to determine the ictal onset area of epileptic vertigo. Although vertigo was first described in 1981 as a manifestation of epilepsy, today there is no consensus regarding the exact location of the epileptogenic focus that causes epileptic vertigo. Another important point is the differentiation between epileptic and non-epileptic vertigo or dizziness; we believe that a crucial step in achieving this is to perform a detailed medical history of the patient, as performed in our cases.

System epilepsies is a new concept related to a novel pathophysiological hypothesis of epilepsy based on an enduring tendency of functionally characterized brain systems to generate seizures. Data supporting this new hypothesis have shown that some types of epilepsy depend on dysfunction of specific neural systems (Avanzini *et al.*, 2012). The pathological results of both vestibular tests in the majority of our patients, combined with EEG abnormalities in all of the patients, suggest that epileptic vertigo is a good example of system epilepsies.

There are a limited number of studies in which the pathogenesis of vertiginous epilepsy has been investigated. Our study is the first to include further vestibular tests for vertiginous epilepsy; we believe this represents a good starting point for further discussions on this topic, which may also shed light on future studies. □

Acknowledgements and disclosures.

The authors would like to thank Mert Yıldız at the University of Health of Sciences, Umraniye Training and Research Hospital, Odiology Department for cVEMP and pure tone audiometry test. None of the authors have any conflict of interest to declare.

References

- Avanzini G, Manganotti P, Meletti S, *et al.* The system epilepsies: a pathophysiological hypothesis. *Epilepsia* 2012; 53(5): 771-8.
- Bisdorff A, Von Brevern M, Lempert T, Newman-Toker DE. Classification of vestibular symptoms: towards an international classification of vestibular disorders. *J Vestib Res* 2009; 19: 1-13.
- Blanke O, Perrig S, Thut G, Landis T, Seeck M. Simple and complex vestibular responses induced by electrical cortical stimulation of the parietal cortex in humans. *J Neurol Neurosurg Psychiatry* 2000; 69(4): 553-6.
- Erbayat Altay E, Serdaroglu A, Gucuyener K, Bilir E, Karabacak NI, Thio LL. Rotational vestibular epilepsy from temporo-parieto-occipital junction. *Neurology* 2005; 65(10): 1675-6.
- Hewett R, Guye M, Gavaret M, Bartolomei F. Benign temporo-parieto-occipital junction epilepsy with vestibular disturbance: an underrecognized form of epilepsy? *Epilepsy Behav* 2011; 21: 412-6.
- Hughes MR, Drachman DA. Dizziness, epilepsy and the EEG. *J Neuro Ment Dis* 1977; 38: 341-5.
- Kahane P, Hoffmann D, Minotti L, Berthoz A. Reappraisal of the human vestibular cortex by cortical electrical stimulation study. *Ann Neurol* 2003; 54(5): 615-24.
- Kim DW, Sunwoo JS, Lee SK. Incidence and localizing value of vertigo and dizziness in patients with epilepsy: video-EEG monitoring study. *Epilepsy Res* 2016; 126: 102-5.
- Kluge M, Beyenburg S, Fernández G, Elger CE. Epileptic vertigo: evidence for vestibular representation in human frontal cortex. *Neurology* 2000; 55(12): 1906-8.
- Kogeorgos J, Scott DF, Swash M. Epileptic dizziness. *Br Med J (Clin Res Ed)* 1981; 282(6265): 687-9.
- Newman-Toker DE, Kattah JC, Alvernia JE, Wang DZ. Normal head impulse test differentiates acute cerebellar strokes from vestibular neuritis. *Neurology* 2008; 70: 2378-85.
- Pedersen E, Epton JO. Epileptic-Vertigo. *Acta Psychiatr Neurol Scand* 1956; 108: 301-10.
- Ransohoff DF, Feinstein AR. Problems of spectrum and bias in evaluating the efficacy of diagnostic tests. *N Engl J Med* 1978; 299: 926-30.
- Saad M, Zakarya S, Abu-Hegazy M. Epileptic vertigo: overview of clinical semiology. *Egypt J Neurol Psychiat Neurosurg* 2011; 48(1): 31-6.
- Tarnutzer AA, Lee SH, Robinson KA, Kaplan PW, Newman-Toker DE. Clinical and electrographic findings in epileptic vertigo and dizziness. *Neurology* 2015; 84(15): 1595-604.
- Wiest G, Zimprich F, Prayer D, Czech T, Serles W, Baumgartner C. Vestibular processing in human paramedian precuneus as shown by electrical cortical stimulation. *Neurology* 2004; 62(3): 473-5.