

# Subdural electrodes in focal cortical dysplasia

Soheyl Noachtar

Department of Neurology, University of Munich, Germany

**ABSTRACT** – Subdural electrodes are useful in selected patients with cortical dysplasia for planning resective epilepsy surgery. Their potential risks have to be balanced against the diagnostic yield and expected benefit of epilepsy surgery for the patient. Recent advances in imaging techniques now allow more accurate placement of the subdural electrodes and also limit the number required.

**KEY WORDS:** cortical dysplasia, invasive recordings, subdural electrodes, electrical stimulation

Presurgical evaluation for epilepsy surgery should: a) select those patients whom surgery could benefit and b) exclude those whom it would not help and might harm. The therapeutic procedure in epilepsy surgery depends on the location and extent of the epileptogenic zone. If the non-invasive results concur on a resectable focus (for instance, the non-dominant temporal lobe), then epilepsy surgery can be recommended on the basis of only non-invasive studies. Otherwise, an invasive evaluation is needed. The convergence of data from structural (MRI) and functional studies (EEG, SPECT, PET, and Wada test/neuropsychology) is crucial for planning epilepsy surgery. Any conflicting results from these tests may be resolved by invasive evaluations or, in some cases, may lead to a decision not to operate, either because the epileptogenic zone cannot be adequately localized or because the risks of removing it are unacceptable.

Electroencephalography is the most specific method for defining epileptogenic cortex. Interictal epileptiform discharges, particularly if consistent over time, can provide useful information. Ictal EEG-video recording is, however, considered by many to be critical for localizing the epileptoge-

nic zone. A careful analysis of the first clinical signs and symptoms of a seizure and of the evolution of the seizure symptomatology can also provide important clues [1]. One must keep in mind, however, that an epileptic seizure often arises from a “silent” region of cortex. It will remain asymptomatic unless it spreads to “eloquent” cortex such as primary motor, primary sensory, or supplementary sensorimotor areas [2].

Structural imaging with high resolution MRI frequently provides essential information, particularly in the case of focal cortical dysplasia. However, postoperative histology can often reveal more widespread dysplasia than originally detected by MRI. In such cases, it may be necessary to remove additional cortex identified with intraoperative or extraoperative invasive recordings. Due to recent advances in imaging techniques (MRI, PET, and SPECT), we now require less invasive evaluations [3].

## Subdural recordings

Invasive recordings are used in patients in whom the epileptogenic zone either cannot be located with non-invasive diagnostic methods or is adjacent to eloquent cortex. Invasive elec-

### Correspondence:

Department of Neurology,  
University of Munich  
Marchioninstr. 15, 81377 Munich, Germany  
Phone: + 49-89-70 95 2685 / 3691  
Fax: + 49-89-70 95 3677  
E-mail: Noa@nro.med.uni-muenchen.de

trodes provide a higher signal-to-noise ratio than surface electrodes and are very sensitive; however, they record only from limited brain areas and may miss epileptic discharges if not appropriately placed. The prerequisite for placement of invasive electrodes is a clear hypothesis about the seizure onset zone, which is derived from the results of non-invasive interictal and ictal EEG recordings, imaging studies, and seizure semiology [4].

Invasive electrodes are subject to sampling errors if misplaced and should be used only after exhaustive non-invasive evaluations have: **a)** failed to localize the epileptogenic zone and **b)** led to a testable hypothesis about its localization. Invasive EEG studies are associated with additional risks [5] that are justifiable only if there is a good chance of obtaining useful and essential localizing information.

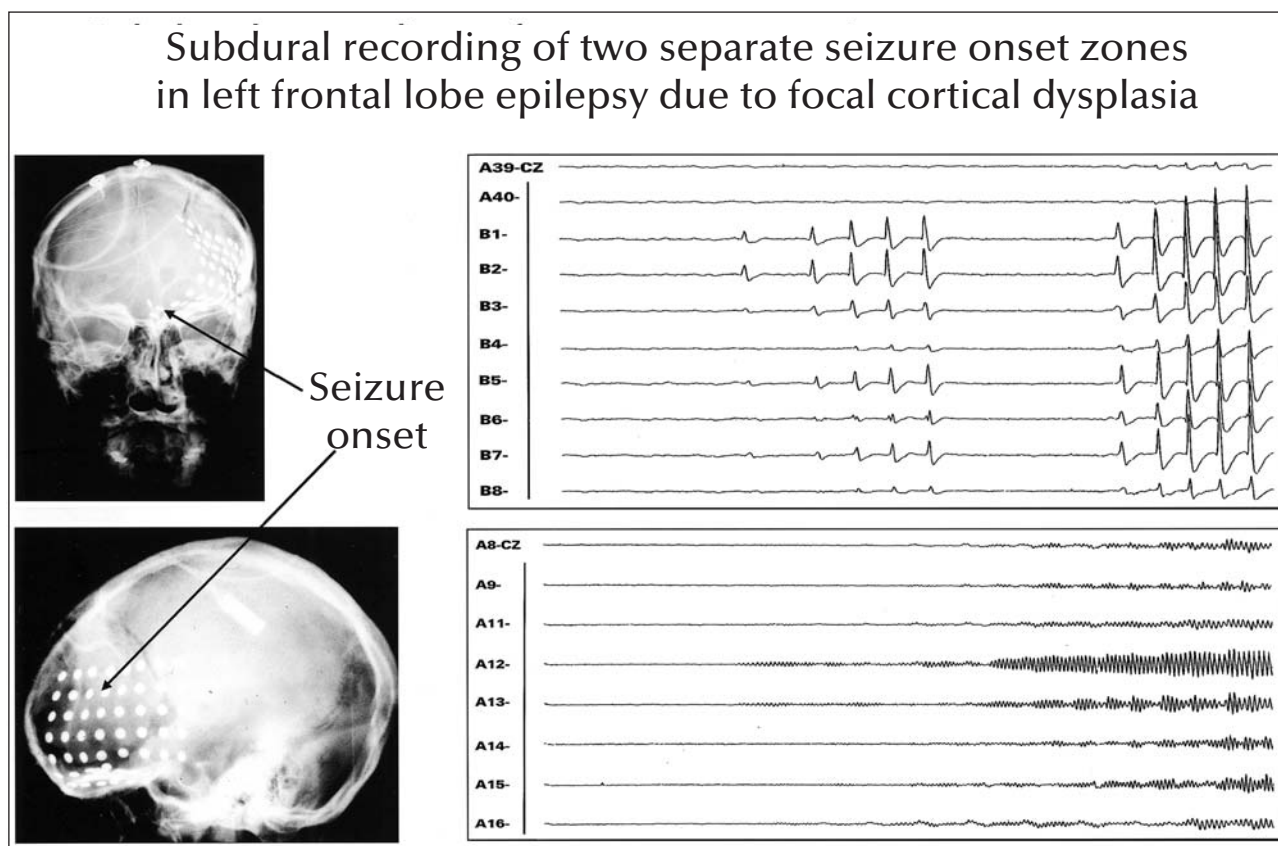
The most commonly used invasive electrodes are stereotactically implanted depth electrodes (see paper by F. Chasseux in this issue) and subdural (strip or grid) electrodes. Subdural strip electrodes can be placed through burr holes. Subdural grid electrodes require a craniotomy. Strip electrodes are typically used if the potentially epileptogenic zone has to be identified in a more widespread

area and involves two or more lobes or subcompartments. Subdural grids covering contiguous areas are very helpful for functional cortical mapping, but their number has to be limited, because the risks of swelling and infection increase with the number of implanted electrodes. Whereas subdural strips can be implanted over both hemispheres, grids are usually implanted only on one side. The choice of electrodes must be based on a hypothesis of the localization of the epileptogenic zone in a given patient, so as to best cover the epileptogenic zone while limiting the electrode number to avoid potential risks. *Figures 1 to 3* show examples of subdural recordings. Preoperative localization of subdural electrodes can be improved by superimposing them on a 3-dimensional MRI cortex relief [6].

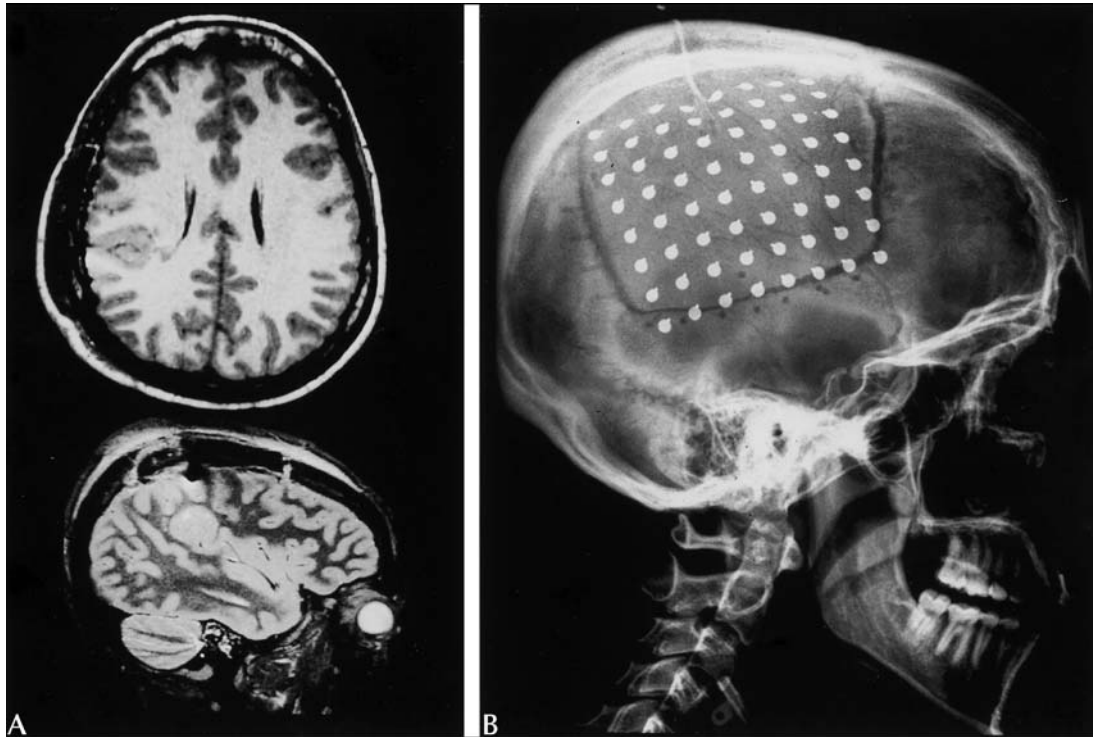
Subdural electrodes have the disadvantage of recording only from the surface of the cortical relief. Epileptic activity in the sulci may be missed unless it spreads to the cortical surface.

### Electrical stimulation

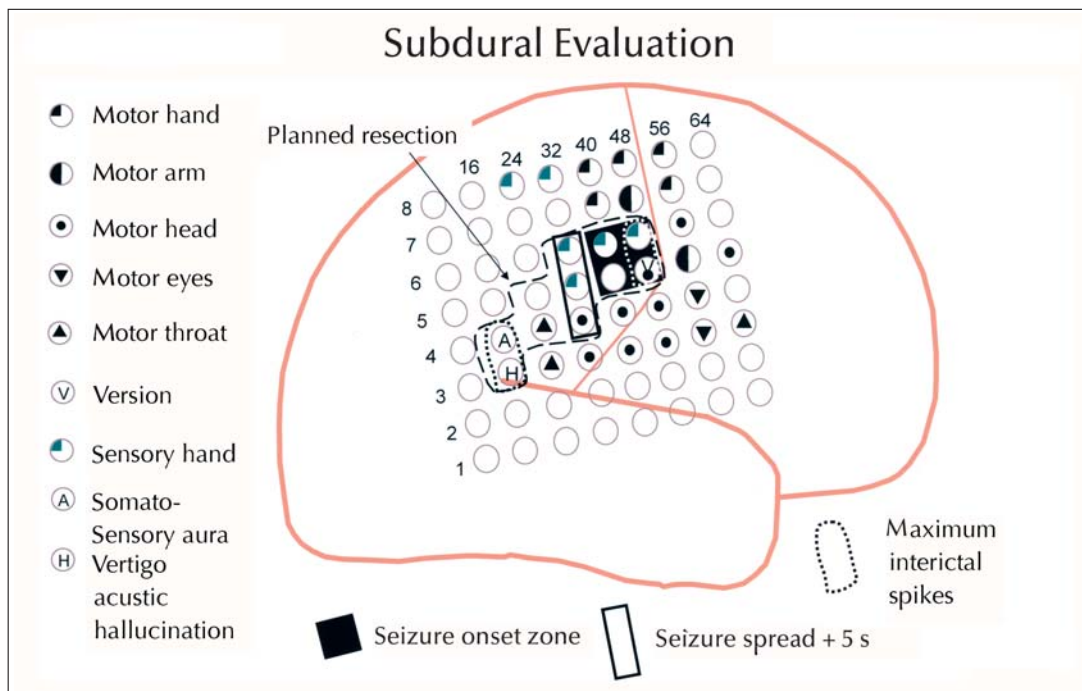
If the presumed epileptogenic zone lies near eloquent cortex such as the speech area or the primary motor



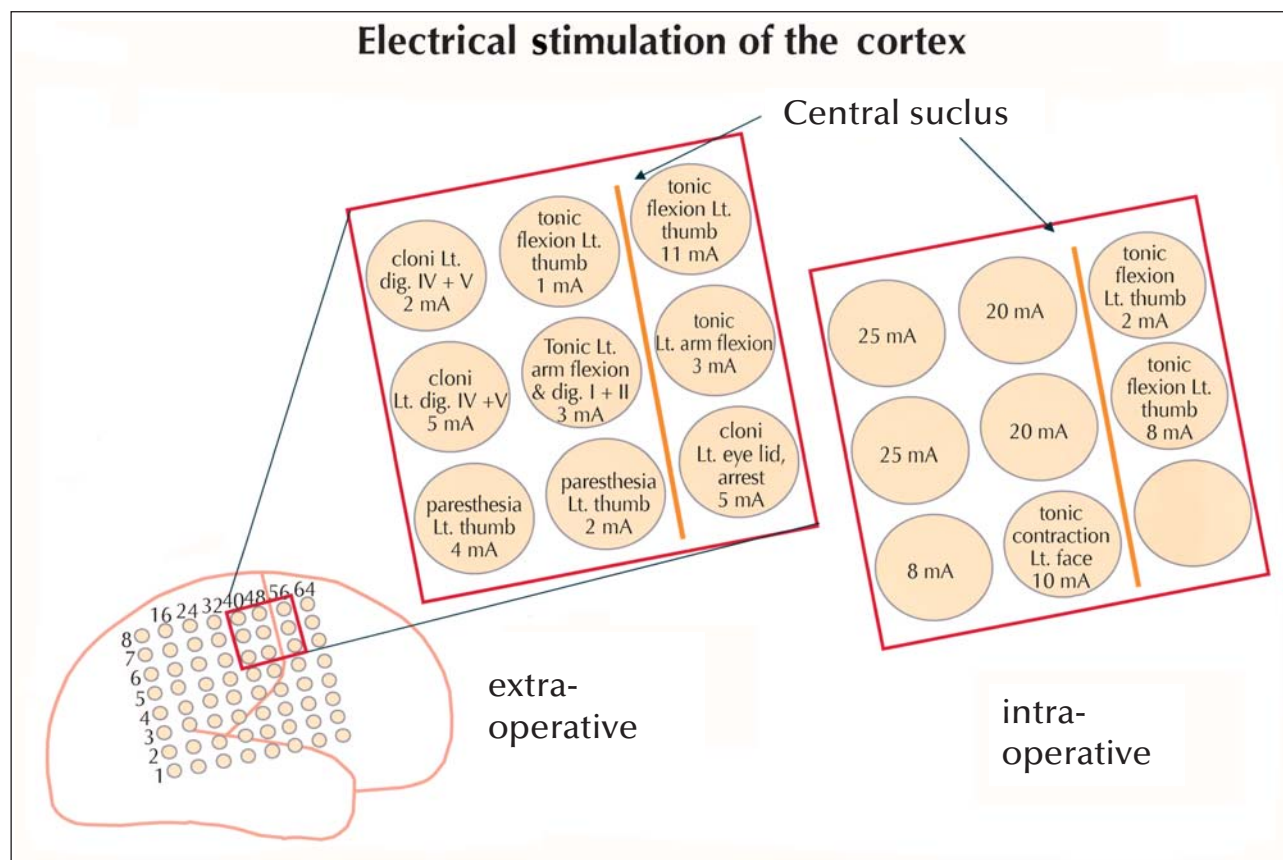
**Figure 1.** The patient had left frontal lobe epilepsy due to cortical dysplasia. Subdural grid electrodes were implanted on the lateral frontal cortex and orbitofrontally. The ictal EEG in this selection of a multichannel recording shows two different seizure patterns in the lateral frontal and orbitofrontal region associated with two different seizure evolutions (from Lüders and Noachtar 2000) [8].



**Figure 2.** A MRI of a patient with focal epilepsy due to bilateral perisylvian dysplasia, which was more pronounced on the left. Non-invasive EEG evaluation showed that the interictal and ictal epileptiform activity occurred exclusively on the left side. B Roentgenogram of the same patient as in Figure 2A showing a subdural grid over the lateral convexity.



**Figure 3.** Results of subdural recordings and electrical stimulation in the same patient as in Figure 2A-B, and Figure 3.



**Figure 4.** Results of extraoperative and intraoperative electrical stimulation of the cortex. Note that the extraoperative stimulation reveals more responses.

cortex, which is frequently the case in cortical dysplasia, its relationship to functional cortex must be defined by intraoperative or extraoperative recording and stimulation techniques [7]. Figure 3 gives a summary of the results of the electrical stimulation of the cortex in a patient with perisylvian dysplasia. On the basis of the results of interictal and ictal EEG recordings as well as the results of electrical stimulation of the cortex, it was possible to individually tailor the resection. The patient remained seizure-free postoperatively for almost one year. She now very rarely has tonic and hypermotor seizures, mainly during sleep.

A comparison of intraoperative and extraoperative electrical stimulation of the cortex in the same patient shows more responses with extraoperative stimulation (figure 4). This discrepancy has to be kept in mind when comparing the results of the two techniques. □

## References

1. Noachtar S. Seizure semiology. In: Lüders HO, ed. *Epilepsy: comprehensive review and case discussions*. London: Martin Dunitz, 2000; 127-40.
2. Rosenow F, Lüders HO. Presurgical evaluation of epilepsy. *Brain* 2001; 124: 1683-700.
3. Noachtar S. Epidural electrodes. In: Lüders HO, Comair Y, eds. *Epilepsy surgery*. 2<sup>nd</sup> ed. Philadelphia: Lippincott Williams & Wilkins, 2001; 585-91.
4. Noachtar S, Lüders HO, Bromfield EB. Surgical therapy of epilepsy. In: Brandt T, Caplan C, Dichgans J, Diener J, Kennard C, eds. *Neurological disorders: course and treatment*. San Diego: Academic Press, 1966; 183-91.
5. Van Buren JM. Complications of surgical procedures in the diagnosis and treatment of epilepsy. In: Engel J Jr, ed. *Surgical Treatment of the Epilepsies*. New York: Raven Press, 1987; 465-75.
6. Winkler PA, Vollmar C, Krishnan KG, Pfluger T, Bruckmann H, Noachtar S. Usefulness of 3-D reconstructed images of the human cerebral cortex for localization of subdural electrodes in epilepsy surgery. *Epilepsy Res* 2000; 41: 169-78.
7. Lüders H, Lesser RP, Dinner DS, et al. Commentary: intracranial electrical stimulation with subdural electrodes. In: Engel J Jr, ed. *The Surgical Treatment of the Epilepsies*. New York: Raven Press, 1987; 297-321.
8. Lüders HO, Noachtar S (eds). *Epileptic seizures: pathophysiology and clinical semiology*. New York: Churchill Livingstone, 2000.