

Paroxysmal autonomic alterations mimicking epilepsy: a case report

Kayihan Uluc, Serap Saygi, Arda Yilmaz, Gulay Nurlu

Hacettepe University Hospitals, Department of Neurology, Ankara, Turkey

Received June 23, 2003; Accepted November 11, 2003

ABSTRACT – A 22-year-old male patient presented with paroxysmal hyperhidrosis, mydriasis, hypertension, and tachycardia. Cranial and cervical MRI revealed focal atrophy in the high order zone of the central autonomic network and syringomyelia. His physical and neurological examinations were unremarkable. Physiological testing included EEG, SPECT, serum/urine tests and autonomic testing. A poor response was achieved with the medical and interventional procedures employed. As the central autonomic network is an integral component of the internal regulation system of the brain, any lesion, no matter where in the network, may lead to paroxysmal autonomic alterations mimicking epilepsy (Published with videosequences).

KEY WORDS: paroxysmal, autonomic, attacks, mechanism, treatment

Introduction

Paroxysmal autonomic disturbances may be seen in central nervous system (CNS) or spinal cord pathologies. Paroxysmal autonomic alterations in the CNS leading to hyperhidrosis, mydriasis, blood pressure and heart rate variability have been described in several disorders such as agenesis or lipoma of the corpus callosum [1], diencephalic and suprasellar tumours, hydrocephalus, and closed head injuries [1-5]. In some published reports, brain stem and diencephalon were thought to be the major regions responsible for these autonomic findings, but any lesion of the central autonomic network (CAN) from insula and medial prefrontal cortices to the medullary intermediate reticular zone can be the cause [6]. The underlying mechanism can be a 'release phenomenon' at the level of the brain stem and diencephalons, secondary to the loss of cortical and subcortical control or the activation/disinhibition of central sympathetic

regions [7]. Clonidine, glycopyrrolate, anticonvulsants, bromocriptine and opioid derivatives may suppress this mechanism [1, 3, 5, 8]. The term 'diencephalic epilepsy' (paroxysmal sympathetic storms) has been used for these attacks because of their paroxysmal nature, but EEGs have not supported this phenomenon during attacks, and anticonvulsant therapies are not successful in many patients [9]. Spinal cord pathologies such as syrinx are other causes of paroxysmal autonomic disturbances. We describe an impressive case of a patient with CNS and spinal cord abnormalities who had paroxysmal sympathetic attacks mimicking epilepsy.

Case study

A 22-year-old male patient presented with episodic attacks up to 40 times a day, which were most prominent when he was awake. These had started at the age of two years. Each



Correspondence:

Kayihan Uluc,
Hacettepe University Hospitals,
Department of Neurology,
06100 Sıhhiye Ankara, Turkey.
Tel.: 00 90 312 3051806
Fax: 00 90 312 3093451
E-mail: kayihanuluc@hotmail.com

attack started with an unpleasant epigastric-raising sensation followed by severe symmetric sweating of the face and neck, without impairment of consciousness. The pupils become mydriatic with no reaction to light. Often he could stop the attack by raising his arms together, and clapping and shaking his hands. At that moment, his head usually turned to the left without forced deviation of the eyes. All attacks lasted longer than 30 seconds, usually up to five minutes.

Tachycardia (120 to 150 beats/min) and increased blood pressure (diastolic, 90 to 110 mmHg; systolic 140 to 160 mmHg) were the other components of the attack. His body temperature did not change during the spells, and his physical and neurological examinations including, pain and temperature sensory testing, were normal.

He had no history of head or cervical trauma, birth asphyxia, congenital infection, or metabolic disease. The only positive finding in his past medical history was a febrile convulsion at the age of six months. He had been evaluated in many medical centers with the diagnosis of simple partial seizures, but mono- or combined antiepileptic drugs such as diphenylhydantoin, carbamazepine, and primidone had been ineffective, except for a partial response to clonazepam. He could describe no attack-free period. Cerebral CT scans and all standard scalp EEGs were normal.

In our center, he was first treated as an outpatient with lamotrigine and then vigabatrin without any improvement. He then underwent scalp video-EEG monitoring for three days. On video-EEG monitoring, 20-30 attacks/day were recorded in three days. Routine laboratory work-up including complete blood count, serum biochemistry, and electrocardiogram revealed no abnormalities. Interictal and ictal serum hormone levels (adrenocorticotrophic hormone, follicle-stimulating hormone, luteinizing hormone, cortisol, prolactin, insulin), serum electrolyte levels, plasma catecholamine and urine metanephrine and epinephrine levels were within normal limits. Interictal and ictal EEGs were also normal. Hypoperfusion was detected in the left frontotemporal region in the ictal SPECT with ^{99m}Tc -HMPO. Cranial MRI examinations were performed on a 3 T system with a standard head coil. Sagittal and transverse T1W, transverse coronal T2W, coronal FLAIR and volumetric coronal T1W sequences were obtained, and they revealed mild, left frontotemporal, opercular focal atrophy (*figure 1*). To evaluate the severity and distribution of autonomic dysfunction; cardiovagal, adrenergic function tests and body temperature monitoring were studied during the spells. The thermoregulatory sweat test showed a band of hyperhidrosis above the upper thoracic level. Sympathetic skin response recording from both palms showed responses to be absent. Heart rate recordings were taken for one hour on different days, while the patient was lying quietly. Subsequent stages of recording, editing, and analysis were done using software developed

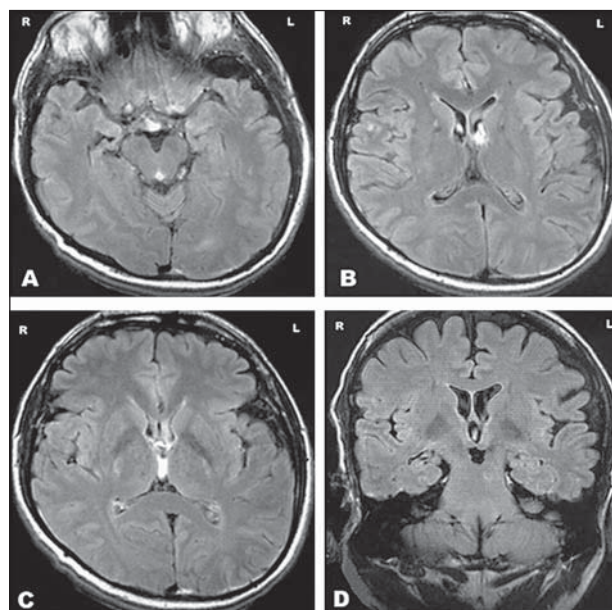


Figure 1. (A, B, C, D). Axial and coronal FLAIR images revealing left frontotemporal opercular atrophy on cranial MRI.

in our institute. The R-R interval series were obtained recorded and stored for off-line processing. The mean R-R interval was calculated for each recording. Analyses of the patient's recordings showed a shift in cardiac autonomic balance towards the sympathetic side.

The episodic, autonomic nature of the attacks suggested a diagnosis of 'paroxysmal sympathetic storms', and further investigations were undertaken. Vertebral fusion from cervical (C) 6 to thoracic (T) 2 level and syringomyelia at the level of C7-T1 were detected in the cervical MRI examination (*figure 2*). Adrenal gland pathology such as pheochromocytoma was excluded with normal abdominal ultrasonography and CT.

As 'paroxysmal sympathetic storm' is thought to be 'a release phenomenon' in the central autonomic network, morphine sulphate, bromocriptine, propranolol, clonidine, clonazepam were tried at effective doses and time intervals. Left satellite ganglion blockade was also performed. Although the severity and frequency of the attacks decreased partially with clonazepam, clonidine and ganglion blockage, they still persist to nearly 20-30 times a day. During follow-up, gabapentin treatment was also tried without any clinically improvement.

Discussion

The central autonomic network areas include the telencephalon, diencephalon, and brain stem control preganglionic sympathetic and parasympathetic visceromotor outputs. The insular and medial prefrontal cortices and the

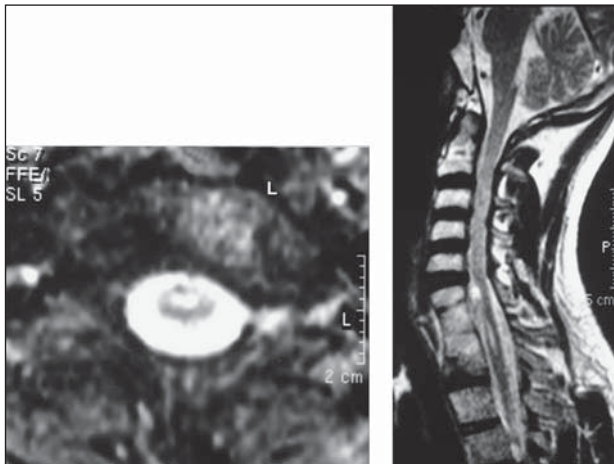


Figure 2. (A, B). T1 and T2-weighted sagittal and transverse images show cervical (C) 6-thoracic (T) 2 vertebral fusion and C7-T1 syringomyelia.

extended amygdala that play a role in the initiation and regulation of autonomic responses carry out high-order autonomic control of the central autonomic network [10]. These areas are interconnected with each other and with the other parts of the central autonomic network so that they produce changes in heart rate, arterial pressure and viscerosensory phenomena. Seizures that arise from amygdalohippocampal, cingulate, opercular, anterior frontopolar, and orbitofrontal regions may produce various autonomic manifestations, including cardiac arrhythmias, viscerosensory phenomena, and vomiting [10]. Sinus tachycardia is one of the most common findings in the pathology of these areas. Hypothalamic and medulla oblongata lesions are the major areas for blood pressure disturbances in the CNS. In particular, nucleus tractus solitarius (NTS) lesions or lesions interrupting the connection of the NTS to high-order zones can lead to hypertension due to disinhibition of sympathetic activity, increase in vasomotor tone and total peripheral resistance. Elevations of plasma vasopressin levels may be another cause of hypertension. Thus, the presence of pheochromocytoma must be excluded. Paroxysmal hyperhidrosis may be seen in hypothalamic pathologies or lesions interrupting the inputs of hypothalamic projections to high-order zones.

Involvement of the autonomic nervous system in patients with syringomyelia is a well-known phenomenon [11]. The clinical picture varies in syringomyelia; it can be found in asymptomatic patients as well as in many others with atypical symptomatology. Spinal cord injuries above midthoracic segments may cause autonomic dysreflexia (AD), in which episodic hypertension and reflex bradycardia occur, and Horner's syndrome [12], severe headache and sweating above the level of lesion. Plasma catecholamine levels are significantly increased in AD.

In our patient, remarkable findings were paroxysmal hyperhidrosis, mydriasis, hypertension and tachycardia. Although, similar autonomic disturbances may be seen in epileptic seizures, especially those involving the diencephalic areas, in this case, interictal and ictal EEGs showed no epileptiform activity, therapeutic levels of anti-convulsant medications were unsuccessful, ictal SPECT showed no hyperperfusion, and the attacks had not changed over time.

Paroxysmal alterations in sympathetic findings might have been caused by hypothalamic, medullary or adrenal gland lesions, but serum hormone and electrolyte levels, plasma-urine catecholamine levels, and radiological findings for these regions were all within normal limits.

As the central autonomic network is an integral component of an internal regulation system of the brain, we suggest that any lesion, no matter where, the network may cause paroxysmal autonomic alterations. Our patient had a focal atrophy in the left frontotemporal opercular area a region that is known as the high-order zone of the central autonomic network, and this lesion might be the cause of the paroxysmal attacks. We do not know the pathology underlying the cerebral focal atrophy. The patient had no specific history of infection, birth asphyxia, metabolic disorder or trauma.

However, the cervical syrinx seen in this patient might have facilitated the paroxysmal attacks by remodelling spinal cord circuits in spinal neurons above the cord injury, but tachycardia, mydriasis without light reaction and normal plasma catecholamine levels during the attacks were inconsistent findings for this possibility. Although in the past reports, several medications have been reported to be effective in ameliorating 'paroxysmal sympathetic storms', this was not the case in our patient.

In conclusion, although the exact aetiology of the paroxysmal attacks is not clear, the dual pathology in the brain and cervical medulla may be responsible for the attacks.

Video sequences

Two consecutive attacks were copied to show the interval and stereotypical features of the attacks.

At 19:09:19: The patient says 'attack is coming' (sweating and an unpleasant epigastric-raising sensation are the initial symptoms) and then he presses the alarm button.

At 19:09:45: Nurse arrives and she tests the patient's consciousness. She gives him a particular phrase to remember and asks questions such as 'where are you', 'in which hospital you are', 'when were you born', 'how old are you' when is your birthday'... The patient is completely awake and consciousness is preserved throughout the attack.

At 19:10:27: Patient is saying 'I have an unpleasant epigastric-raising sensation, and I am sweating'.

At 19:11:21: He remembers the phrase given to him by the nurse, and he is trying to stop the attack by a maneuver created by himself (raising his arms together, and clasping and shaking his hands).

At 19:46:47: The stereotypical attack starts. To stop the attack, the patient does same arm posturing and movements. Consciousness is preserved. □

References

1. Shapiro WR, Williams GH, Plum F. Spontaneous recurrent hypothermia accompanying agenesis of the corpus callosum. *Brain* 1969; 92: 423-36.
2. Talman WT, Florek G, Bullard DE. A hyperthermic syndrome in two subjects with acute hydrocephalus. *Arch Neurol* 1988; 45: 1037-40.
3. Bullard DE. Diencephalic seizures: responsiveness to bromocriptine and morphine. *Ann Neurol* 1987; 21: 609-11.
4. Boeve BF, Wijdicks EFM, Benarroch EE, *et al.* Paroxysmal sympathetic storms ('diencephalic seizures') after severe diffuse axonal head injury. *Mayo Clin Proc* 1998; 73: 148-52.
5. Klein CJ, Silber MH, Halliwill JR, *et al.* Basal forebrain malformation with hyperhidrosis and hypothermia: variant of Shapiro's syndrome. *Neurology* 2001; 56: 254-6.
6. Cechetto DF. Central representation of visceral function. *Fed Proc* 1987; 46: 17-23.
7. Ropper AH. Acute autonomic emergencies and autonomic storm. In: Low PA, ed. *Clinical Autonomic Disorders*. Boston: Little, Brown, 1993: 747-60.
8. Walker BR, Anderson J, Edwards CRW. Clonidine therapy for Shapiro's syndrome. *Q J Med, New Series* 1992; 82: 235-45.
9. Penfield W. Diencephalic autonomic epilepsy. *Arch Neurol Psychiatr* 1929; 22: 358-74.
10. Benarroch EE. The central autonomic network: functional organization, dysfunction, and perspective. *Mayo Clin Proc* 1993; 68: 988-1001.
11. Masur H, Schulte-Oversohl U, Papke K, *et al.* Involvement of the autonomic nervous system in patients with syringomyelia--a study with the sympathetic skin response. *Electromyogr Clin Neurophysiol* 1996; 36: 43-7.
12. Stovner LJ, Kruszewski P, Shen JM. Sinus arrhythmia and pupil size in Chiari I malformation: evidence of autonomic dysfunction. *Funct Neurol* 1993; 8: 251-7.