

Panayiotopoulos syndrome: video-EEG illustration of a typical seizure

Veysi Demirbilek, Aysin Dervent

Istanbul University, Cerrahpasa Medical Faculty, Department of Neurology, Division of Child Neurology, Istanbul, Turkey

Received July 16, 2003; Accepted December 18, 2003

ABSTRACT – Panayiotopoulos syndrome (PS) is a form of idiopathic, partial epilepsy of childhood with a high prevalence rate, but with poor clinical recognition, possibly due to the characteristics of the seizure, which not infrequently lack common epileptic motor and/or sensory phenomena. Instead, autonomic symptoms such as retching and vomiting, predominate. Semiological knowledge of the seizures in PS depends mainly on parental observations, but not enough ictal-EEG data are available, possibly due to the rarity of seizures. In addition to previous knowledge regarding the occipital onset of seizures in PS, it has been recognized that other areas, mainly the frontal regions, may be involved. The present report demonstrates the video-EEG findings of a seizure in a patient with PS. Subclinical ictal EEG discharges with occipital onset precede the clinical autonomic symptoms; eye deviation which is typical of occipital involvement, appears in later sequences. These findings suggest that at least for certain seizures an occipital origin may be considered, even in seizures without the early manifestations typical of this region. (Published with videosequences).

KEY WORDS: Panayiotopoulos syndrome, idiopathic localization-related epilepsy, early onset benign childhood occipital epilepsy, occipital seizure, occipital paroxysms



Correspondence:

Veysi Demirbilek
Tevfikpaşa sok.
21/6 Özgül apt.
34 726 Fenerbahçe- Istanbul
Turkey
Tel.: (+ 90) 216 345 17 75
E-mail: veysi@bistek.net.tr

Although the prevalence of Panayiotopoulos syndrome (PS) is reported as 13% in three-six year-old children with seizures [1], some features of this syndrome, such as the infrequency of seizures, their syncope-like characteristics, predominating autonomic phenomena, lack of major motor manifestations, and others, may well lead to misdiagnosis. Initial seizures with recognizable motor manifestations may suggest acute, symptomatic epileptic conditions such as CNS intoxication or encephalitis when long-lasting autonomic symptoms and confusional episodes complicate the picture; these

patients may only be evaluated and treated for the acute picture. Motion sickness, which is not a very rare condition, has been a misdiagnosis in our experience when seizures have occurred during or soon after travelling.

The infrequent seizures of this benign syndrome include mainly autonomic phenomena with nausea, retching and frequently vomiting, along with unilateral deviation of the eyes. Mild cardio-respiratory, and gastrointestinal, as well as pupillary changes, urination and defecation may occur. Prolonged periods of alterations in consciousness, more con-

ventional seizure manifestations and headache may also occur. The duration is generally long and nearly half of the cases had episodes of 'autonomic status epilepticus' as described by Panayiotopoulos in his comprehensive book on the subject [1]. It has been suggested that PS be classified as a 'benign childhood seizure susceptibility syndrome (BCSSS)' along with 'benign rolandic epilepsy' (BRE) and febrile seizures [1] instead of 'early-onset benign childhood occipital epilepsy' under idiopathic 'childhood occipital epilepsies' as was cited in the new classification scheme proposed by the ILAE Task Force [2]. Panayiotopoulos states that seizures in PS may not be always occipital in origin; the only possible occipital symptom, that is, the eye-deviation, is not usually the first clinical event and the ictal EEG may start from the frontal regions [1]. Accumulation of ictal data may thus contribute not only to theoretical considerations, but may also serve as practical purposes for diagnosis and management.

Here, we present video-EEG documentation of a seizure in an otherwise healthy patient diagnosed as having PS due to his seizure characteristics and inter-ictal EEG features.

Case report

B.U. is a six year-old boy with normal development. His first seizure was at three years of age. It took place half an hour after falling asleep; he opened his eyes, fixed his gaze and was drooling. He seemed attentive but unresponsive, and started retching and vomiting. He was soon taken to a hospital. He became sleepy and hypotonic after IR diazepam, but intermittent staring and episodes of vomiting lasted around 90 minutes, followed by four hours of sleep; he then woke up and neurological examination was normal. He underwent blood and CSF examinations and cranial MRI with normal results. His EEG the next day, revealed single or repetitive spike-and-waves with left occipital localization and a normal background activity. History of a few seizures in four adult members on the paternal side, one with a single febrile seizure during smallpox, was present, and they all had ended by five years of age. No detailed descriptions of these seizures were available.

B.U.'s condition was diagnosed as PS after his first seizure and has been followed up to the present. He has had six more seizures since then. One of the later seizures happened during a long journey by car, after about four hours; another accompanied an upper respiratory tract infection and high fever. Two of the later seizures were similar to the initial one, but they were not as long, about 10-15 minutes; they were all accompanied by vomiting. The other three seizures included awakening, staring, deviation of the eyes to the left, followed by clonic jerking of the left leg. They lasted less than five minutes. All of the seizures happened during sleep, the last one was during a

video-EEG recording in June 2002, at five years of age. He has been seizure-free since then and has been taking carbamazepine 200mg BID, for the last two years. His repeated inter-ictal EEGs revealed frequent right, infrequent left occipital and parieto-occipital spike-and-wave discharges enhanced during sleep. Background activities during waking and NREM were always normal.

The present seizure took place during a routine control video-EEG. He had a shorter-than-usual sleep the night before which might have had a precipitating effect. The seizure took place about 10 minutes after the onset of sleep (pre-ictal NREM see *figure 1a*). It continued for four minutes and ended spontaneously while IR diazepam was just about to be introduced.

As seen in the video, the initial manifestations of the seizure are awakening and staring. A dystonic movement of the right foot is followed by a slow eye-deviation to the left for 30 seconds and was repeated as a down-left deviation (*figure 2b*) after a short period of apparently normal gaze. A dystonic movement of the right hand is evident at that time. Two episodes of vomiting occur approximately two and three minutes after initial awakening. IR diazepam was given by the end of the 4th minute, but the seizure terminated just before the drug was took effect. The child returned to sleep within a few minutes. There was mild hypotonia on the left side of the body during the seizure. The patient was unresponsive during the seizure.

While asleep, ictal spiking on the EEG started in the right occipital (*figure 1b*) region nearly four minutes before the awakening and four and a half minutes before the onset of eye-deviation to the left. The onset of the ictal activity appeared as repetitive spikes and sharp-waves of mixed voltage, later transforming to 2 Hz., multiple spike-and-slow waves. More or less regular alternating sequences take place during the seizure activity. Initial ictal changes limited to the right occipital region showed a subsequent propagation to an adjacent posterior temporal area within a few seconds. Involvement of symmetrical regions of the left hemisphere developed about three minutes later in a similar order, at the same time as the right parietal leads (*figure 1c*).

There was ictal spiking in the right posterior area and slow activity in the same regions of the left hemisphere, at the time when the patient opened his eyes (*figure 2a*). Although bilateral slowing took place in the EEG, focal spiking was predominant in the right occipital region throughout the seizure. Enhancement of spike-waves was seen in the left occipital region post-ictally (*figure 2c*), and the background of NREM activity returned to normal immediately after the patient went back to sleep.

The ECG channel revealed an increase in the pulse rate from a pre-ictal average 94 to ictal 108 during sleep, and to 120 beats per minute after eye opening. No irregularity in the pulse occurred during the seizure.

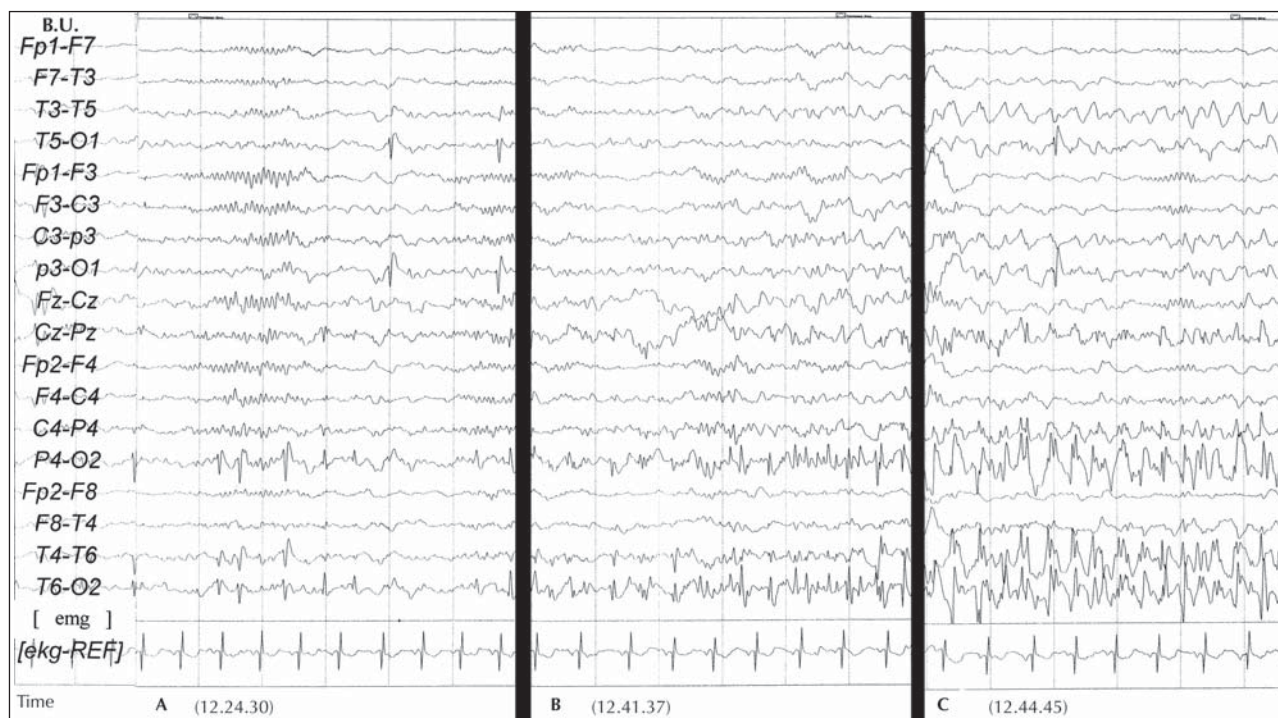


Figure 1 A. Pre-ictal, NREM. B. Onset of ictal discharges. C. Pre-clinical ictal discharges continue.

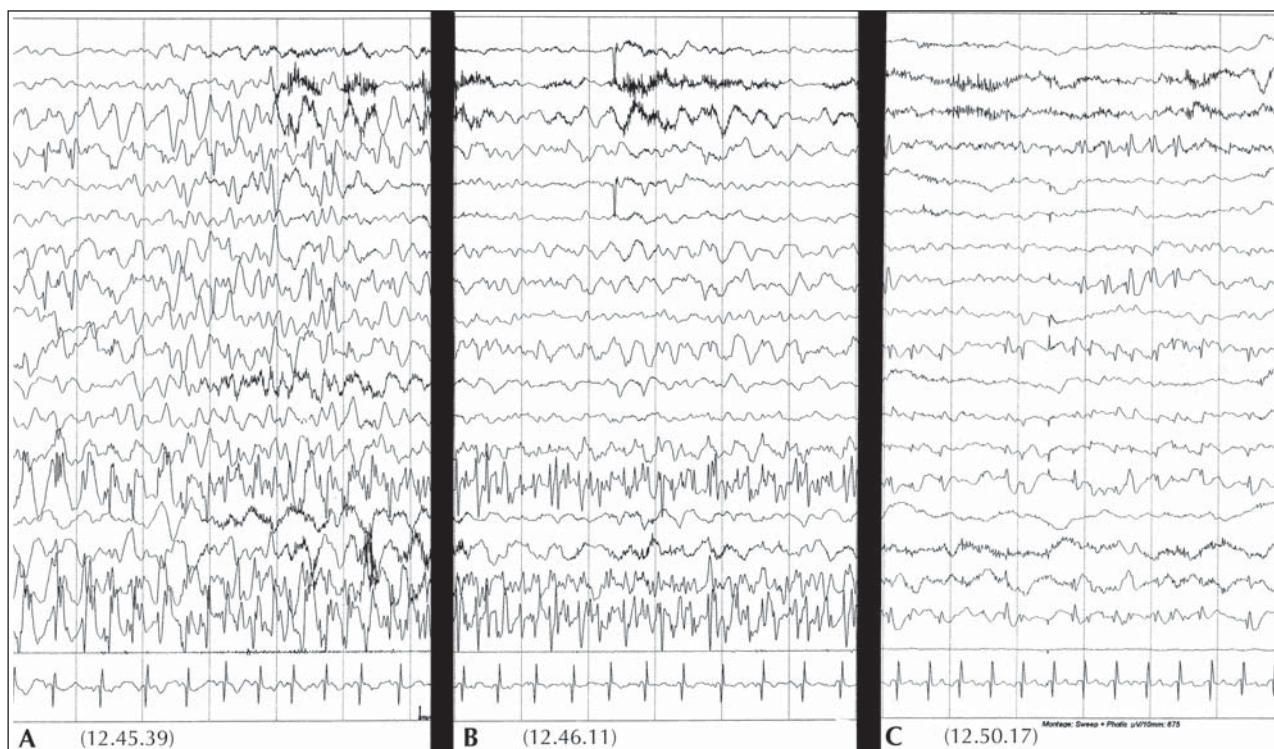


Figure 2 A. Eyes opening. B. Eyes down towards left side. C. Post-ictal awakening.

Discussion

Data on the ictal video-EEG of patients may be of use for a better understanding of the origin and propagation of seizure discharges in PS. In the literature, three ictal recordings from the onset of the seizures are reported one of which was a video EEG. Two of these patients had unilateral occipital seizure onset in their EEG [3, 4], the third one apparently had a frontal origin [5]. Sudden awakening, staring, eye-deviation and retching/vomiting were symptoms common to them and the present case. A unique feature of our case was the long latency between the onset of EEG and clinical seizure activity, which was four minutes. The first symptom of the seizure was apparently related to nausea when the ictal spikes were still unilateral and restricted to the right occipito-temporal leads. Slowing in the same regions of the left hemisphere had already started as the initial clinical symptom, which was, during awakening. However, ictal spiking was consistently localized in the right posterior leads during the whole seizure, including the autonomic manifestations and apparently no diffuse involvement took place in any sequence.

Although a precise localization of the ictogenic neurons can not be determined by scalp EEG only, this case may favor an occipital onset in a seizure with initial clinical symptoms other than eye-deviation. Clinical onset of the present seizure took place after a considerable latency following the EEG onset, and after the abnormal discharges became bilateral. Thus, any subjective sensation leading to awakening (one of which may be nausea in this case, since the patient had a slight retching movement before awakening), might be triggered by the propagation

of ictal discharges to other sites before clinical signs of occipital involvement were visible. Spread of ictal discharges to lateral temporal convexity has previously been shown to coincide with ictal vomiting in a group of patients studied using subdural electrodes [6].

To summarize, it is suggested that documentation of video EEGs of seizures in benign epileptic syndromes may provide a better understanding of the nature of age-related, so-called, seizure-susceptibility, as it may also enable the positioning of possible sub-groups within this context. □

References

1. Panayiotopoulos CP. Panayiotopoulos Syndrome. London: John Libbey, 2002.
2. Engel J. A Proposed Diagnostic Scheme for People with Epilepsy: Report of the ILAE Task Force on Classification and Terminology. *Epilepsia* 2001; 42: 796-803.
3. Beaumanoir A. Semiology of occipital seizures in infants and children. In: Andermann F, Beaumanoir A, Mira L, Roger J, Tassinari CA. *Occipital seizures and epilepsies in children*. London: John Libbey, 1993: 71-86.
4. Vigeveno F, Lispi ML, Ricci S. Early onset benign occipital susceptibility syndrome: video-EEG documentation of an illustrative case. *Clin Neurophysiol* 2000; 111 Suppl. 2: S81-6.
5. Oguni H, Hayashi K, Imai K, Hirano Y, Mutoh A, Osawa M. Study on early-onset variant of benign childhood epilepsy with occipital paroxysms otherwise described as early-onset benign occipital seizure susceptibility syndrome. *Epilepsia* 1999; 40: 1020-30.
6. Kramer RE, Lüders H, Goldstick LP, et al. Ictus emeticus: an electroclinical analysis. *Neurology* 1988; 38: 1048-52.