

# Non-convulsive status epilepticus in the setting of cannabidiol adjunctive therapy

Asra Tanwir<sup>1</sup>, C. Ákos Szabó<sup>1,2</sup>

<sup>1</sup> Department of Neurology,

<sup>2</sup> Department of South Texas  
Comprehensive Epilepsy Center,  
University of Texas Health San  
Antonio, San Antonio, Texas, USA

Received August 17, 2017;

Accepted March 11, 2022

## ABSTRACT

Anti-seizure medications (ASMs) can cause non-convulsive status epilepticus (NCSE), but account for less than 5% of all NCSE cases. We present a 63-year-old, right-handed male with a history of intractable focal epilepsy since age seven years old, whose bouts of NCSE were triggered by cannabidiol (CBD) adjunctive therapy. His most common seizure types included focal myoclonic or tonic seizures with vocalization, usually with awakening, which occurred on a monthly basis despite the combination of tiagabine, perampnamel, levetiracetam, lacosamide and clonazepam. After CBD was initiated, he began to exhibit episodes of prolonged confusion, at times with myoclonic or tonic seizures. Increasing CBD doses led to more frequent and prolonged episodes. The confusional episodes occurred predominantly in the morning, with spontaneous resolution by the afternoon. During one of these episodes, he was hospitalized, and NCSE was confirmed by video-EEG monitoring. CBD was withdrawn and the patient had no further episodes of NCSE. While CBD can cause NCSE, the medication interaction between CBD and tiagabine also needs to be considered.

**Key words:** non-convulsive status epilepticus, anti-seizure medications, cannabidiol, tiagabine, CYP3A4-inhibition



VIDEO ONLINE

## Correspondence:

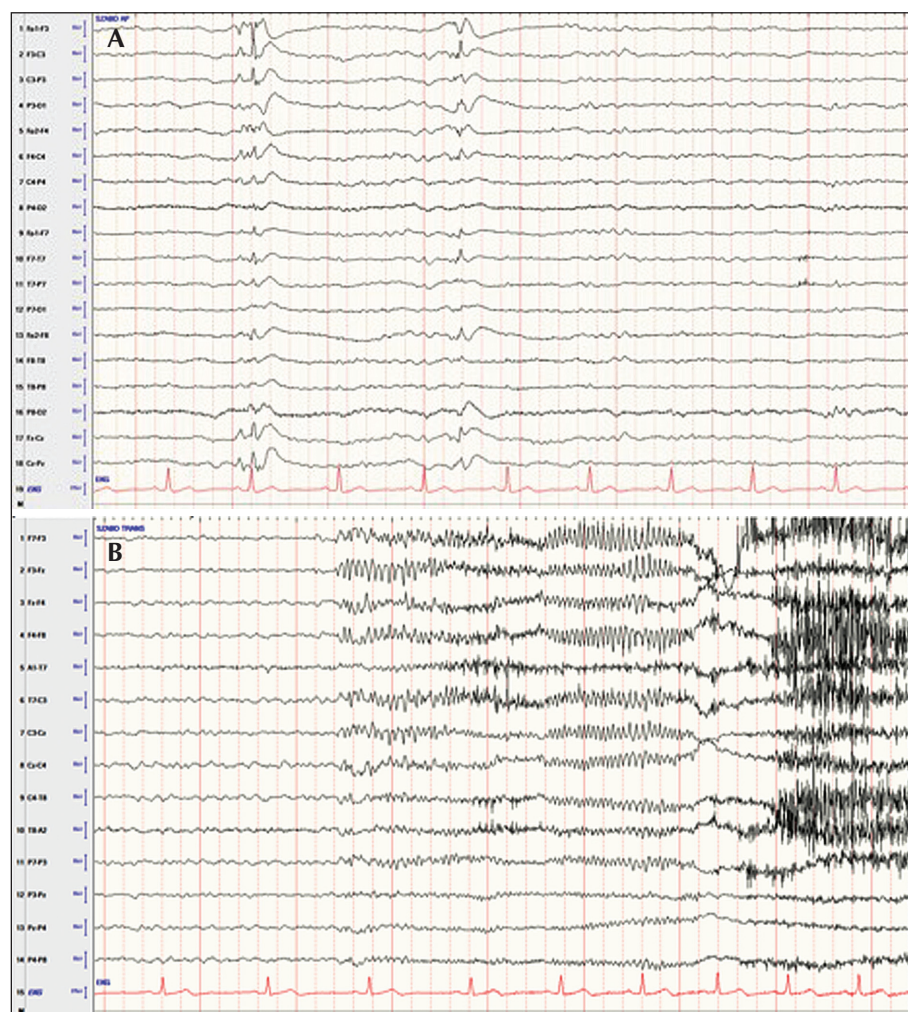
Asra Tanwir  
Department of Neurology,  
University of Texas Health  
Science Center at San Antonio,  
7703 Floyd Curl Drive,  
San Antonio, TX 78229-7883,  
USA  
<tanwira@uthscsa.edu>

Non-convulsive status epilepticus (NCSE) is characterized by an alteration of mental status exceeding 10 minutes [1]. NCSE can result from brain tumors, central nervous system infections, metabolic disorders and drug interactions that effect the brain. Anti-seizure medications (ASMs) rarely result in NCSE [2], but there are several reports of phenytoin (PHT), carbamazepine (CBZ), vigabatrin (VGB), lamotrigine (LTG), gabapentin (GBP), oxcarbazepine (OXC) and tiagabine (TGB) exacerbating absence or myoclonic status epilepticus in people with idiopathic generalized epilepsies, and convulsive or NCSE being triggered in a dose-dependent fashion in people with various types of epilepsy by CBZ, valproic acid (VPA), LTG, levetiracetam

(LVT), pregabalin (PGB) and TGB [3-5]. We report a patient with focal epilepsy who presented with recurrent bouts of NCSE after the introduction of cannabidiol (CBD).

## Case study

A 63-year-old, right-handed male presented with a history of intractable focal epilepsy since age seven years old. There were no known etiological factors or family history for epilepsy. Previous brain MRI scans were normal, and outpatient scalp EEG studies reported generalized or lateralized spikes or spike-and-wave discharges. He had bilateral myoclonic and tonic seizures with or without loss of awareness, at times even associated with falls

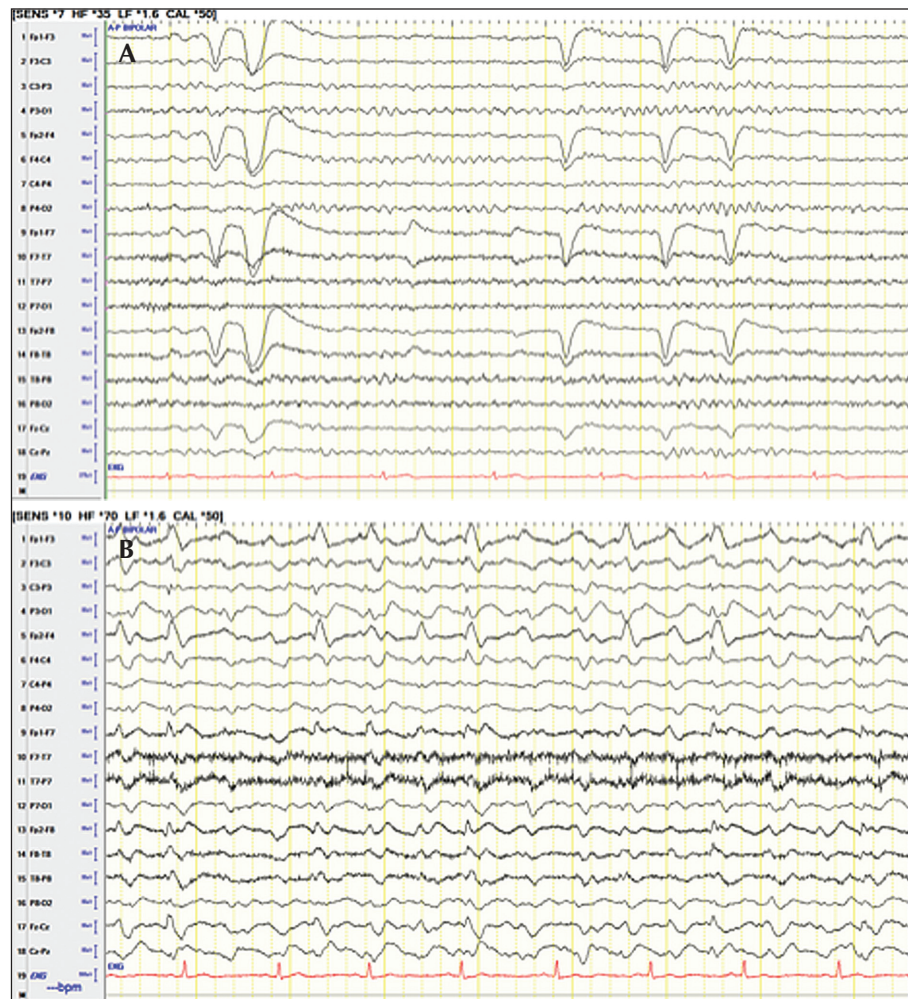


■ **Figure 1.** Interictal epileptic discharges are depicted in (A) (ap-bipolar montage) and ictal EEG correlate during a brief tonic seizure in (B) (transverse-bipolar montage).

and urinary incontinence. At age 60 years old, he was having daily seizures, while on a combination of LVT 3,000 mg/day, VPA 2,000 mg/day, LTG 300 mg/day, clonazepam 1 mg/night and lacosamide (LCM) 600 mg/day. After perampanel (PMP) was added, his seizures were reduced to a weekly occurrence and no longer associated with falls or urinary incontinence. He also, for the first time, described an aura of tingling in his neck prior to his seizures. During this time, he was able to titrate off VPA and LTG, and decrease LCM. However, with PMP at 16 mg per night, he complained of increased daytime somnolence, requiring afternoon naps, mood changes, and had experienced a fall while going to the bathroom in the middle of the night, after which he appeared disoriented. Inpatient video-EEG monitoring confirmed the diagnosis of asymmetric tonic seizures beginning with a vocalization;

while ictal and interictal epileptic discharges appeared generalized, they often demonstrated left hemispheric lateralization (figure 1); his EEG background demonstrated a normal posterior background and sleep activity (figure 2A). The left hemispheric lateralization was also demonstrated by hypermetabolism using scaled averages on PET; review of the concurrent EEG (video was not available) confirmed increased ictal and interictal epileptic discharges during the uptake period. On formal neuropsychological testing, the patient had an average FSIQ, but demonstrated impairments in language and executive functioning. When TGB was initiated, he was on LVT 3,000 mg/day, CLN 1 mg at night, LCM 200 mg twice daily, and PMP 16 mg at night. PMP was lowered gradually to 12 mg per night due to falling one night while in the bathroom and TGB was gradually titrated





■ **Figure 2.** Normal awake background sample in (A), and NCSE sample in (B) (both ap-bipolar montage).

to 48 mg/day (12 mg four times daily). His seizure frequency decreased to twice a month, initially with less somnolence and improved mood. His gait instability at night returned, and, one night when awoke to go to the bathroom at 4 am, he fell twice, appearing confused for several minutes. His wife was concerned as he was more confused than after his habitual seizures. At that time, his TGB was reduced by only half a tablet in the evening without further occurrences for two months. His seizures occurred 2-3 times per month. After a locally produced CBD product was initiated in accordance with the Texas Compassionate-Use Act, he exhibited a similar episode of confusion after a dinner party, this time lasting 30 minutes and associated with repetitive myoclonic jerks. Once he was switched to Epidiolex<sup>®</sup>, his tonic seizures decreased to once a month, occurring only in sleep, but he felt progressively more lethargic in the

daytime. The daytime lethargy improved when PMP was lowered to 8 mg/day. As his CBD was gradually titrated to 20 mg/kg/day, the confusional episodes became more frequent, occurring on a weekly basis, always presenting in the morning and, after hours, resolving by the afternoon. During these episodes, he was intermittently responsive, but appeared somnolent or agitated, unable to comply with the administration of rescue meds, and remained amnesic for their entire duration. On two occasions, two months apart, he was hospitalized, and random anti-seizure medication levels revealed slightly elevated LCM and LVT levels (random, not trough levels), but normal TGB levels on both occasions (220-230 ng/mL). During the second hospitalization, when his confusion extended beyond the morning hours, an inpatient EEG confirmed NCSE (figure 2B). The confusional episodes resolved once CBD was withdrawn. Prior to

▼ **Table 1.** Timetable of medication changes with respect to video-EEG diagnosis of NCSE.

| ASM change   | Other ASMs  | Outcome   |
|--|---|---|
| LCM was increased to 600 mg/day  | LVT 3000 mg/day<br>VPA 2000 mg/day<br>LTG 300 mg/day<br>CLN 1 mg/night                  | Daily seizures, some with falls and urinary incontinence  |
| PMP titration to 12 mg/night   | LVT 3000 mg/day<br>LCM 400 mg/day<br>CLN 1 mg/night                                     | Seizures decrease to weekly, no falls or urinary incontinence; first presentation of an aura  |
| PMP increased to 16 mg/night   | LVT 3000 mg/day<br>LCM 400 mg/day<br>CLN 1 mg/night                                     | Excessive daytime somnolence; falls in bathroom, confused   |
| Video-EEG monitoring as part of a presurgical evaluation                     |   |   |
| TGB titrated to 48 mg/day PMP reduced to 12 mg/night                         | LVT 3000 mg/day<br>LCM 400 mg/day<br>CLN 1 mg/night                                     | Further seizure reduction to 2 per month; he had gait instability in the evening; and fell twice in the bathroom  |
| TGB reduced to 42 mg/day   | LVT 3000 mg/day<br>LCM 400 mg/day<br>PMP 12 mg/night<br>CLN 1 mg/night                  | No further gait instability and falls resolved, but seizures persisted.   |
| CBD adjunctive therapy 150 mg/day  | LVT 3000 mg/day<br>LCM 400 mg/day<br>PMP 12 mg/night<br>TGB 42 mg/day<br>CLN 1 mg/night | While seizures occurred only on a monthly basis, he had one 30-minute episode of confusion with intermittent myoclonic jerks one evening.                     |
| EPD replaced CBD, titrated to 20 mg/kg/day                                   | LVT 3000 mg/day<br>LCM 400 mg/day<br>PMP 8 mg/night<br>TGB 42 mg/day<br>CLN 1 mg/night  | His tonic seizures were reduced, but he developed weekly episodes of confusion in the morning (not at night), often intermixed with tonic/myoclonic activity. |
| Video-EEG monitoring diagnosing NCSE   |   |   |
| EPD stopped<br>BRV 200 mg/day to replace LVT<br>PMP increased to 12 mg/night | LCM 400 mg/day<br>TGB 42 mg/day<br>CLN 1 mg/night                                       | Resolution of confusional episodes, seizures 1-2 times every 2-3 months.  |

ASM: anti-seizure medication; LCM: lacosamide; LVT: levetiracetam; VPA: valproic acid; LTG: lamotrigine; CLN: clonazepam; PMP: perampanel; TGB: tiagabine; CBD: cannabidiol; EPD: Epidiolex; BRV: brivaracetam.

his discharge from the hospital, he was also converted from LVT to brivaracetam (BRV at 200 mg/day). Since then, he has not had any further episodes of NCSE for almost two years. His current TGB level is 45 ng/mL. A timetable summarizing the medication and corresponding outcome is presented in *table 1*.

Discussion

This is a case report documenting new-onset NCSE with CBD adjunctive therapy in a patient with focal epilepsy. Our patient initially tried a locally produced

CBD product approved by the Texas Compassionate-Use Act, subsequently switching to the more concentrated Epidiolex, which had been recently approved by the Food and Drug administration for the treatment of children and adults for seizures associated with Lennox-Gastaut and Dravet syndromes, as well as tuberous sclerosis complex [6, 7]. The mechanisms of action of CBD are still largely unknown, but may be linked to G protein-coupled receptors, transient receptor potential cation channels, and nuclear peroxisome proliferator-activated receptors, and modulation of 5-HT<sub>1A</sub>-receptors [8].

Epidiolex<sup>®</sup> was well-tolerated by children and adults enrolled in Phase 3 clinical trials [9, 10]. However, two studies reported status epilepticus as the most common serious adverse reaction to CBD adjunctive therapy. The type of status epilepticus was not described in detail but was reported to occur in 6% in one study and 7% in another [9, 10]. As people with Lennox-Gastaut and Dravet syndromes often have severe, medically intractable epilepsy with a high risk for convulsive and non-convulsive status epilepticus, it is unclear whether status epilepticus was part of the natural history or due to an adverse effect of the medication. Nonetheless, one of the studies demonstrated a dose-dependent increase in risk for status epilepticus, suggesting a medication effect [10]. In our patient, steady increases of CBD doses resulted in more frequent and severe bouts of NCSE and its withdrawal led to their resolution. Still, the pathomechanisms underlying CBD-induced NCSE are unknown. It is also unclear to what extent the replacement of high-dose LVT with BRV, both SV2A modulators, may have improved his outcome. Alternatively, medication interactions related to the introduction of CBD may have triggered NCSE. CBD is metabolized by several cytochrome P450 enzymes, including CYP2C19, CYP3A5, and 5'-diphosphoglucuronyltransferases [8]. Inhibition of CYP3A4 may lead to increases in perampanel and tiagabine levels. While increases in perampanel could have contributed to his nocturnal confusion and unsteadiness, TGB has been more commonly associated with exacerbation of NCSE in patients with focal and generalized epilepsies [11-13]. Despite an excellent response to TGB, it was unclear whether our patient may have presented with drug toxicity, breakthrough seizures or even a bout of NCSE when his dose was raised to 48 mg/day; these symptoms did not recur after reducing his night-time dose by 6 mg. The definitive episodes of NCSE occurring once CBD was added, occurred mainly in the morning with prolonged confusion lasting up to hours, and were not associated with falls. These episodes became more frequent as Epidiolex was titrated, first occurring on a monthly basis, then increasing to a weekly occurrence on a dose of 20 mg/kg/day. While the TGB levels were not in the toxic range, they decreased from 210 to 45 ng/mL off Epidiolex. The morning predilection of his NCSE symptoms may also have coincided with the diurnal rise of serum concentrations of TGB [14]. These findings support the known risk associated with TGB of causing NCSE in people with focal and generalized epilepsies [3, 11-13], suggesting that pharmacokinetic interactions need to be considered in the setting of polypharmacy. In summary, *de novo*, stereotyped periods of confusion, exceeding 20 minutes, during after starting anti-seizure medication, should raise the suspicion of NCSE. While this case report may suggest that CBD

was the cause, due to the worsening of our patient's symptoms as CBD doses were increased but resolution when CBD was discontinued, pharmacokinetic interactions with concomitant medications were more likely to be implicated. Because CBD is an inhibitor of the CYP3A complex which can raise levels of several ASMs, including eslicarbazepine, zonisamide, rufinamide and topiramate, as well as both TGB and PMP in our patient, the levels of concomitant medications need to be monitored when people with epilepsy treated with polypharmacy present with episodic confusion. Furthermore, ambulatory or inpatient video-EEG monitoring should be considered to ascertain the diagnosis of NCSE [15]. ■

### Key points

- Cannabidiol (CBD) adjunctive therapy led to NCSE in a patient with medically intractable epilepsy.
- NCSE recurrences increased in a dose-dependent manner and resolved with CBD withdrawal.
- Nonetheless, NCSE was probably induced because of pharmacokinetic interactions between CBD and tiagabine.
- Levels of concomitant medications need to be monitored when people with epilepsy present with episodic confusion.

### Disclosures.

There are no conflicts of interest to declare.

### Study ethics and patient consent.

The study, entitled "Non-convulsive Status Epilepticus Induced by a Medication Interaction" was performed in accordance with "The Code of Ethics of the World Medical Association" and the patient provided consent for the publication of this case report.

### References

1. Trinka E, Cock H, Hesdorffer D, Rossetti AO, Scheffer IE, Shinnar S, *et al.* A definition and classification of status epilepticus – Report of the ILAE Task Force on Classification of Status Epilepticus. *Epilepsia* 2015; 56: 1515-23.
2. Cock HR. Drug-induced status epilepticus. *Epilepsy Behav* 2015; 49: 76-82.
3. Ettinger AB, Bernal OG, Andriola MR, Bagchi S, Flores P, Just C, *et al.* Two cases of nonconvulsive status epilepticus in association with tiagabine therapy. *Epilepsia* 1999; 40(8): 1159-62.

4. Osorio I, Reed RC, Peltzer JN. Refractory idiopathic absence status epilepticus: a probable paradoxical effect of phenytoin and carbamazepine. *Epilepsia* 2000; 41: 887-94.
5. Spiller HA, Carlisle RD. Status epilepticus after massive carbamazepine overdose. *J Toxicol Clin Toxicol* 2002; 40: 81-90.
6. Devinsky O, Cilio MR, Cross H, Fernandez-Ruiz J, French J, Hill C, et al. Cannabidiol: pharmacology and potential therapeutic role in epilepsy and other neuropsychiatric disorders. *Epilepsia* 2014; 55: 791-802.
7. Thiele EA, Bebin EM, Bhathal H, Jansen FE, Kotulska K, Lawson JA, et al. Add-on cannabidiol treatment for drug-resistant seizures in Tuberous Sclerosis Complex: a placebo-controlled randomized clinical trial. *JAMA* 2021; 78(3): 285-92.
8. Huestis MA, Solimini R, Pichini S, Pacifici R, Carlier J, Busardo FP. Cannabidiol adverse effects and toxicity. *Current Neuropharm* 2019; 17: 974-89.
9. Devinsky O, Marsh E, Friedman D, Thiele E, Laux L, Sullivan J, et al. Cannabidiol in patients with treatment-resistant epilepsy: an open-label interventional trial. *Lancet Neurol* 2016; 15: 270-8.
10. Szaflarski JP, Bebin EM, Comi AM, Patel AD, Joshi C, Checketts D, et al. Long-term safety and treatment effects of cannabidiol in children and adults with treatment-resistant epilepsies: expended access program results. *Epilepsia* 2018; 59: 15640-21548.
11. Shinnar S, Berg AT, Treiman DM. Status epilepticus and tiagabine therapy: review of safety data and epidemiologic comparisons. *Epilepsia* 2001; 42: 372-9.
12. Kellinghaus C, Dziewas R, Ludemann P. Tiagabine-related non-convulsive status epilepticus in partial epilepsy: three case reports and a review of the literature. *Seizure* 2002; 11(4): 243-9.
13. Vinton A, Kornberg AJ, Cowley M, Matkovic Z, Kilpatrick C, O'Brien TJ. Tiagabine-induced generalised nonconvulsive status epilepticus in patients with lesional focal epilepsy. *J Clin Neurosci* 2005; 12(1): 128-33.
14. Adkins JC, Noble S. Tiagabine: a review of its pharmacodynamic and pharmacokinetic properties and therapeutic potential in the management of epilepsy. *Drugs* 1998; 55(3): 437-60.
15. Brown JD, Winterstein AG. Potential adverse drug events and drug-drug interactions with medical and consumer cannabidiol (CBD) use. *J Clin Med* 2019; 8(7): 989.

## Legend for video sequence

Generalized tonic seizure.

**Key words for video research on [www.epilepticdisorders.com](http://www.epilepticdisorders.com)**

*Phenomenology:* focal-tonic

*Localization:* not lateralized

*Syndrome:* focal epilepsy

*Aetiology:* left hemispheric