

# Neuroimaging in neonatal seizures

Lauren C Weeke, Linda GM Van Rooij, Mona C Toet,  
Floris Groenendaal, Linda S de Vries

Department of Neonatology, Wilhelmina Children's Hospital, UMC Utrecht, Utrecht,  
The Netherlands

Received June 26, 2014; Accepted January 03, 2015

**ABSTRACT** – Seizures are the most common sign of neurological dysfunction in full-term neonates, with an incidence estimated at 0.15-3.5/1,000 live births. Neonatal seizures often reflect severe underlying brain injury and are associated with high rates of mortality and morbidity. Prognosis is primarily determined by the nature, site and extent of the underlying aetiology, making accurate diagnosis and identification of associated brain lesions essential. Data on neuroimaging in newborns presenting with seizures is limited and most studies report on MRI findings in infants with a specific underlying problem, such as hypoxic-ischaemic encephalopathy, stroke or metabolic disorders. The aim of this review is to discuss the spectrum of neuroimaging findings in full-term newborns presenting with seizures, divided into subgroups with different underlying aetiologies. A standard neonatal MRI protocol is presented.

**Key words:** neonatal seizures, neuroimaging, MRI, ultrasound, CT, diffusion weighted imaging

Seizures occur more often during the neonatal period than in any other period of life and have a variety of underlying aetiologies. The incidence varies between 0.15 and 3.5 per 1,000 live births, with higher rates in preterm infants. It also depends on the threshold for using continuous amplitude-integrated or standard electroencephalography (aEEG) monitoring (Ronen *et al.*, 2007). In previous studies, the mortality has been reported to be as high as 40%, but in more recent studies the mortality has come down to 21% (Mastrangelo *et al.*, 2005) and even 7% (Tekgul *et al.*, 2006). However, in contrast to this increase in survival, the prevalence of long-term neurodevelopmental sequelae in survivors has been reported to be

about 30% (Bergman *et al.*, 1983). In a more recent study, 70 (66%) of 106 preterm and full-term infants admitted to a neonatal intensive care unit (NICU) had an adverse neurological outcome. Six variables were identified as the most important independent risk factors. Neuroimaging was one of these six variables, but only cranial ultrasound (cUS) was used (Pisani *et al.*, 2009). Aetiologies associated with a poor outcome include cerebral dysgenesis, severe hypoxic-ischaemic encephalopathy (HIE), metabolic disorders, and infection of the central nervous system (CNS). Conversely, infants with focal infarction, transient metabolic disturbances, or idiopathic seizures have been reported to have a favourable outcome.

## Correspondence:

Linda S de Vries  
Department of Neonatology,  
KE 04.123.1,  
Wilhelmina Children's Hospital,  
UMC Utrecht, PO box 85090,  
3508 AB Utrecht,  
The Netherlands  
<l.s.devries@umcutrecht.nl>

Most NICUs around the world use cUS as the method of first choice. Computed tomography (CT) is now less commonly used and should only be performed in an infant who may acutely need neurosurgical intervention. Magnetic resonance imaging (MRI) is increasingly used and recognised as the best imaging modality. The Vermont Oxford neonatal encephalopathy registry showed that 22.7% of infants admitted with neonatal encephalopathy still had a CT scan and almost two thirds (65%) had an MRI during the neonatal period (Barnette *et al.*, 2014). In this population, admitted between 2006 and 2010, 67% received antiepileptic medication during their stay in the NICU. These imaging data are in agreement with data from Tekgul *et al.* (2006) who studied 89 full-term infants with neonatal seizures. In this study, 82% had at least one MRI scan, whereas 18% only had a CT scan.

Several studies have shown that in the full-term infant, HIE is by far the most common aetiology, followed by intracranial haemorrhage (ICH) and stroke (table 1). These studies were mostly performed before the introduction of therapeutic hypothermia and recent studies have shown that neonatal seizures are less common and better controlled in infants with moderate HIE, treated with hypothermia (Low *et al.*, 2012; Srinivasakumar *et al.*, 2013). Transient metabolic disturbances or inborn errors of metabolism, infection of the CNS, cerebral dysgenesis, and genetic disorders are less common underlying aetiologies for neonatal seizures. Some of these infants may present with encephalopathy and are referred to as “HIE mimics”. Neuroimaging may help to diagnose an underlying problem, for instance polymicrogyria in Zellweger syndrome, which is important for genetic counselling. For those infants who die during the neonatal period and are too unstable to be transported to the MRI unit, a post-mortem MRI should be considered, especially

when there is no permission for autopsy. The value of a post-mortem MRI has been shown by several groups (Griffiths *et al.*, 2005; Nicholl *et al.*, 2007). The number of infants with unknown aetiology is decreasing, as lesions that may not be recognised by cUS or CT are identified by MRI, but also because of advances made in genetics (Weckhuysen *et al.*, 2012; Weckhuysen *et al.*, 2013).

Data on neuroimaging in newborns presenting with neonatal seizures are scarce and most studies report MRI findings in a specific group of infants, with a diagnosis of either HIE, stroke or metabolic disorders (Leth *et al.*, 1997; Tekgul *et al.*, 2006). The aim of this review is to discuss the spectrum of neuroimaging findings in full-term infants with neonatal seizures with different underlying aetiologies. Examples of cUS and MRI performed during the first week after birth in infants presenting with seizures discussed below are presented in figures 1 and 2.

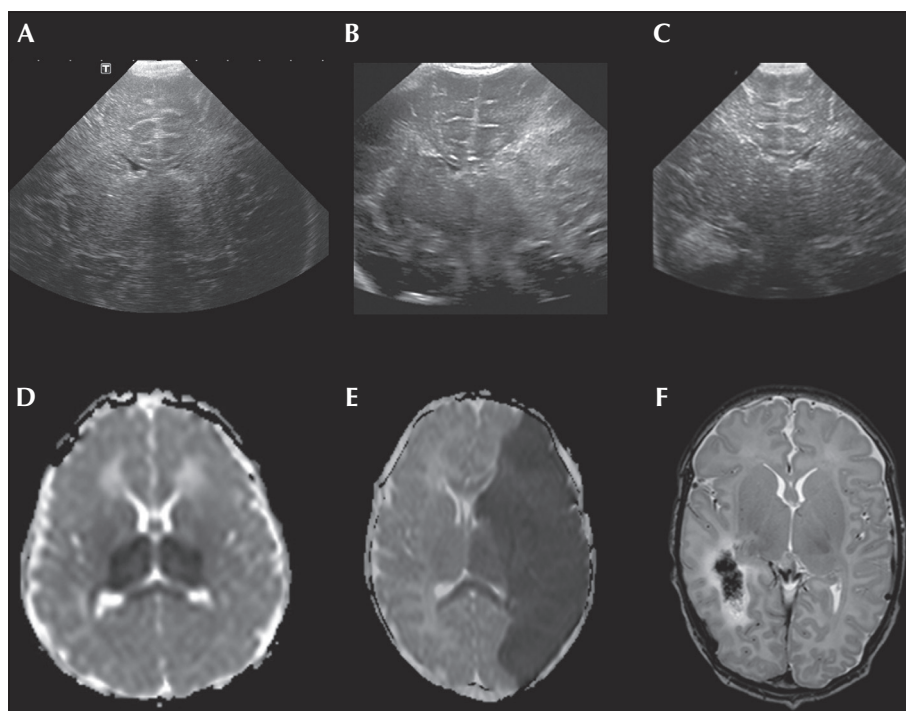
## Hypoxic-ischaemic encephalopathy

Several studies have been reported in the literature concerning different patterns of injury in relation to HIE. Two main patterns of injury can be recognised. The first one predominantly affects the central grey nuclei (ventrolateral thalami and posterior putamina) and perirolandic cortex, bilaterally. Associated involvement of the hippocampus and brain stem is not uncommon. This pattern of injury (basal ganglia-thalamic) is most often seen following an acute sentinel event, for instance, a ruptured uterus, placental abruption or a prolapsed cord (Miller *et al.*, 2005; Okerefor *et al.*, 2008), and is also referred to as a pattern seen after “acute near total asphyxia”. When MRI is performed during the first week, diffusion weighted imaging (DWI) may highlight the abnormalities, which

**Table 1.** Aetiologies and incidence of neonatal seizures in full-term infants.

	<b>Tekgul <i>et al.</i> 2006</b>	<b>Mastrangelo <i>et al.</i> 2005</b>	<b>Yildiz <i>et al.</i> 2012</b>	<b>Ronen <i>et al.</i> 1999</b>	<b>Weeke <i>et al.</i> 2014</b>
HIE	40%	37.1%	28.6%	40%	46%
ICH	17%	4.8%	17%	18%	12.2%
Stroke	18%	11.3%	-	1 case	13.5%
Infection	3% (CNS only)	9.7%	7.2% (+sepsis)	20% (+ sepsis)	7.6% (+sepsis)
Cerebral dysgenesis	5%	11.3%	4.5%	10%	2.9%
Metabolic disorders	1%	11.3%	10.7%	19% (including hypoglycaemia)	9% (including hypoglycaemia)
Unknown/ idiopathic	12%	1.6%	8.9%	14%	6.3%

HIE: hypoxic-ischaemic encephalopathy; ICH: intracranial haemorrhage.

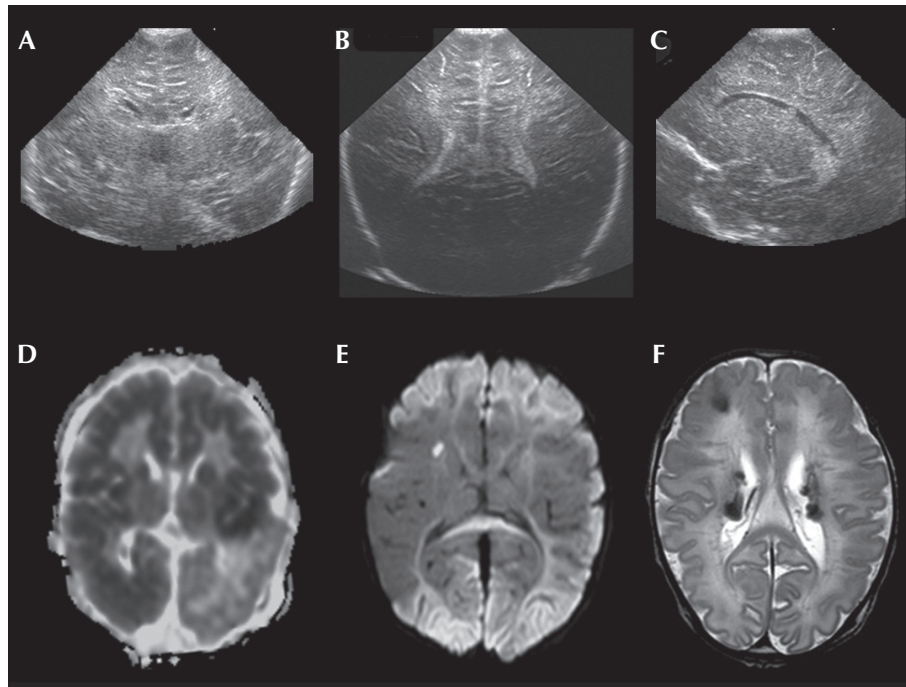


**Figure 1.** Examples of coronal cUS and axial MR images performed during the first week after birth in infants presenting with neonatal seizures. (A) HIE: hyperechogenicity in both thalami on cUS and low signal intensity on the ADC map in thalami, optic radiation and splenium of the corpus callosum (D); (B) PAIS of main branch of the left-middle cerebral artery: wedge-shaped hyperechogenicity with a linear demarcation line in the left hemisphere on cUS and low signal intensity on the ADC map in territory of the left-middle cerebral artery, as well as optic radiation and splenium of the corpus callosum (E); (C) haemorrhage in the right temporal lobe recognised on cUS as a round area of hyperechogenicity and on T2WI as an area of low signal intensity surrounded by high signal intensity due to oedema (F).

first become apparent by the end of the first week on conventional imaging (Bednarek *et al.*, 2012).

The second pattern is referred to as the watershed (WS), a predominant pattern of injury seen following “prolonged partial asphyxia”. The vascular WS zones (anterior-middle cerebral artery and posterior-middle cerebral artery) are involved, affecting the white matter and in more severely affected infants, also the overlying cortex. The lesions can be uni- or bilateral, posterior and/or anterior (Harteman *et al.*, 2013). Although loss of the cortical ribbon and therefore the grey-white matter differentiation can be seen on conventional MRI, DWI highlights the abnormalities and is especially helpful in making an early diagnosis (table 2). More widespread punctate lesions in the white matter (PWML) have also been reported within the HIE population. Li *et al.* (2009) found these PWML in 23% of their infants with neonatal encephalopathy and pointed out that infants with this type of injury had a significantly lower gestational age at birth with a milder degree of encephalopathy and fewer clinical seizures relative to other newborns in their cohort, who were diagnosed to have the two more common patterns of injury. This pattern of brain injury is also seen in newborn infants with congenital heart defects (Galli *et al.*, 2004; Li *et al.*, 2009).

The pattern of brain injury seen on MRI can predict the severity and type of neurodevelopmental dysfunction in later life (Twomey *et al.*, 2010; Martinez-Biarge *et al.*, 2011; Harteman *et al.*, 2013), although the degree of encephalopathy and the extent of EEG abnormalities, including seizures, are also predictive of subsequent neurodevelopmental outcome (Miller *et al.*, 2004; van Rooij *et al.*, 2005). Basal ganglia-thalamic injury is often associated with a worse neurodevelopmental outcome in general and is primarily associated with motor deficits, in particular dyskinetic cerebral palsy, which can already be detected at 12-18 months of age. Involvement of other developmental domains is common as well (cognition, speech and epilepsy) (Miller *et al.*, 2005; Sato *et al.*, 2008; Martinez-Biarge *et al.*, 2010; Twomey *et al.*, 2010). WS injury is most often associated with cognitive impairment (Miller *et al.*, 2005; Steinman *et al.*, 2009; Martinez-Biarge *et al.*, 2012) which can be overlooked at 12-18 months of age and become more apparent after 30 months of age (Marlow *et al.*, 2005; Miller *et al.*, 2005; Steinman *et al.*, 2009; van Kooij *et al.*, 2010). The prevalence of motor impairment after WS injury is low (6-18%) compared to the prevalence after basal ganglia-thalamic injury (50-75%) (Miller *et al.*, 2005; Sato *et al.*, 2008; Martinez-Biarge *et al.*, 2011). An abnormal signal in the posterior



**Figure 2.** Examples of coronal (A, B) and sagittal (C) cUS and axial MRI performed during the first week after birth in infants presenting with seizures. (A) molybdenum cofactor deficiency with diffuse hyperechogenicity in the white matter on cUS shortly after birth; extensive areas of low signal intensity on the ADC map with sparing of the left parieto-occipital lobe (D); (B) group B *Streptococcus* encephalitis with hyperechogenicity in the periventricular and deep white matter; extensive restricted diffusion of the cortex and subcortical white matter on MRI, also note small infarct in right caudate nucleus (E); (C) antenatal diagnosis of tuberous sclerosis (cardiac rhabdomyoma): subependymal nodule seen on cUS; several periventricular subependymal nodules and right-sided subcortical tuber are seen on T2WI (F).

limb of the internal capsule (PLIC) is described as an accurate predictor of neurodevelopmental outcome (Miller *et al.*, 2005). A normal PLIC is usually seen with normal or mild basal ganglia-thalamic lesions and is predictive of a normal motor outcome (Martinez-Biarge *et al.*, 2011). An abnormal PLIC is associated with an unfavourable outcome (Rutherford *et al.*, 1998; Twomey *et al.*, 2010). However, the abnormal signal in the PLIC is usually first seen beyond 72 hours after birth and myelination can only be assessed in infants with a gestational age beyond 38-40 weeks. Apparent diffusion coefficient (ADC) measurements in the basal ganglia and magnetic resonance spectroscopy ( $^1\text{H}$ -MRS) measurements (lactate/N-Acetyl Aspartate [NAA]) can add significantly to the predictive properties of MRI, although it should be noted that ADC shows pseudonormalisation after the first week, but MR spectroscopy measurements remain abnormal for a prolonged period of time (Alderliesten *et al.*, 2011).

## Perinatal stroke

### Perinatal arterial ischaemic stroke

Neonatal seizures and especially hemiconvulsions often suggest the diagnosis of perinatal arterial

ischaemic stroke (PAIS). Compared to those who develop seizures due to HIE, seizures related to PAIS tend to develop significantly later and are more often focal (Rafay *et al.*, 2009). It is important to use at least a two-channel aEEG or standard EEG recording in infants presenting with hemiconvulsions (van Rooij *et al.*, 2010). It is possible to recognize the larger middle cerebral artery infarcts and lenticulostriate infarcts which are well within the field of view using cUS, but in general it will take 24-72 hours before the increase in echogenicity becomes apparent (*table 2*) (Govaert, 2009). It may not be possible to recognise cortical infarcts or infarcts in the territory of the posterior cerebral artery using cUS, unless the posterior fontanel is used as an acoustic window (Cowan *et al.*, 2005; van der Aa *et al.*, 2013). MRI and especially DWI enables detection of PAIS within hours after onset and allows prediction of development of subsequent unilateral spastic cerebral palsy by assessing involvement of the corticospinal tracts (de Vries *et al.*, 2005; Kirton *et al.*, 2007).

### Cerebral sinovenous thrombosis

Cerebral sinovenous thrombosis (CSVT) may also present with neonatal seizures. The presence of an intraventricular haemorrhage associated with a

**Table 2.** Neuroimaging findings over time in HIE and PAIS.

Aetiology	cUS findings	MRI findings			Day 1-7	Day 7-28
		Time after onset of injury	<24h	24-48h	>48-72 h	
<i>HIE</i>						
-BGT pattern	BGT hyperechogenicity, oedema	-	+/-	+	DWI changes; BGT	T1WI/T2WI changes; BGT
-WM/WS pattern	Subcortical/periventricular hyperechogenicity, oedema	-	+/-	+	DWI changes; cortex, white matter	T1WI/T2WI changes; cortex, white matter
<i>PAIS</i>	Focal hyperechogenicity, wedge-shaped, with linear demarcation (MCA infarct)	-	+/-	+	DWI changes; territory of cerebral artery and corticospinal tracts	T1WI/T2WI; loss grey matter-white matter differentiation (MCA infarct)

HIE: hypoxic-ischaemic encephalopathy; BGT: basal ganglia, thalami; DWI: diffusion weighted imaging; T1WI: T1-weighted imaging; T2WI: T2-weighted imaging; WM/WS: white matter/watershed; PAIS: perinatal arterial ischaemic stroke; MCA: middle cerebral artery.

unilateral thalamic haemorrhage in a full-term infant suggests the presence of a CSVT (Wu *et al.*, 2003). Doppler ultrasound may help to diagnose occlusion of the superior sagittal sinus but is less reliable for other sinuses, and an MRI and magnetic resonance venography (MRV) are often required to confirm CSVT. Making the correct diagnosis is important, as anticoagulant therapy is increasingly being used (Moharir *et al.*, 2010). The presence of a neonatal thalamic haemorrhage is strongly associated with later development of electrical status epilepticus in slow wave sleep (Kersbergen *et al.*, 2013).

### Intracranial haemorrhage

An intracranial haemorrhage (ICH) in the full-term infant is not as common as in the preterm infant, but does occur (Bruno *et al.*, 2014). Blood in the *posterior fossa* is common, which can be a chance finding (Whitby *et al.*, 2004) and does not often lead to neonatal seizures. An *intraventricular haemorrhage* can be associated with CSVT, but can also occur without a reasonable explanation. Neonatal seizures in a full-term infant with an intraventricular haemorrhage may be difficult to control (Toet *et al.*, 2005). A parenchymal haemorrhage can also be diagnosed in the absence of a complicated delivery. A frontal lobe haemorrhage is most common and, in the presence of a midline shift, neurosurgical intervention may be considered (Brouwer *et al.*, 2010). An infant with a temporal lobe haemorrhage often presents with apnoeic episodes,

which turn out to be of epileptic origin when continuous aEEG monitoring is used (Hoogstraate *et al.*, 2009). Epileptic apnoeic episodes are thought to originate from the limbic system (Watanabe *et al.*, 1982).

### Central nervous system infection

Any infection of the CNS can present with seizures. Both bacterial and viral CNS infections can occur in the neonatal period, but severe CNS infections are not so common. Early gram negative bacterial infection, as well as late-onset group B *Streptococcus* infection, may be associated with severe brain injury (de Vries *et al.*, 2006). The neuroimaging pattern may be very characteristic (*table 3*), for instance in *Bacillus cereus* septicaemia, where the white matter may show cystic evolution within hours after the onset of the infection (Lequin *et al.*, 2005). In infants with an *Escherichia coli* infection, hydrocephalus may only become apparent weeks after the acute illness, and isolated dilatation of the fourth ventricle is often an associated finding. A wide spectrum of viral infections can present with neonatal seizures. Some infants present with a fever and/or rash, and PCR in the cerebrospinal fluid (CSF) may confirm the diagnosis of an enterovirus or parechovirus encephalitis (Verboon-Macielek *et al.*, 2006; Verboon-Macielek *et al.*, 2008). The DWI changes may be extensive, but the outcome may be better than expected on the basis of the DWI findings in the majority of these infants (van Zwol *et al.*, 2009). A similar

**Table 3.** Neuroimaging findings in CNS infections.

Causative organism	Neuroimaging findings
<b>BACTERIAL</b>	
GBS <sup>1</sup>	Ischaemic infarctions, in particular BGT
<i>Escherichia Coli</i> <sup>1</sup>	Empyema, ventriculitis, hydrocephalus, trapped 4 <sup>th</sup> ventricle
<i>Proteus mirabilis</i> <sup>2,3</sup>	Cerebral abscesses
<i>Streptococcus pneumoniae</i> /haemophilus influenza <sup>4</sup>	Subdural collections/effusions
<i>Klebsiella oxytoca</i> <sup>1</sup>	Frontal lobe infarction
<i>Bacillus cereus</i> <sup>5</sup>	White matter liquefaction
<i>Citrobacter</i> <sup>1</sup>	Ischaemic infarctions, cerebral abscesses
<i>Serratia marcescens</i> <sup>1</sup>	Cerebral abscesses
<b>VIRAL</b>	
HSV <sup>6</sup>	DWI changes in white matter, not restricted to temporal lobes, and brainstem
Parechovirus <sup>7</sup>	DWI changes; white matter, PWML, cystic PVL
Enterovirus <sup>8</sup>	DWI changes; white matter, PWML, cystic PVL
Rotavirus <sup>9</sup>	DWI changes; white matter, PWML, cystic PVL

GBS: group B *Streptococci*; BGT: basal ganglia, thalami; PVL: periventricular leukomalacia; HSV: herpes simplex virus; DWI: diffusion weighted imaging; PWML: punctate white matter lesions.

<sup>1</sup>Jaremkó et al. (2011), <sup>2</sup>Penido et al. (2005), <sup>3</sup>Phan and Lehman (2012), <sup>4</sup>Vinchon et al. (2006), <sup>5</sup>Lequin et al. (2005), <sup>6</sup>Schleede et al. (2013), <sup>7</sup>Verboon-Macielek et al. (2008), <sup>8</sup>Verboon-Macielek et al. (2006), <sup>9</sup>Lee et al. (2014)

pattern of diffusion restriction in the white matter was recently demonstrated in full-term infants presenting with seizures between days 4 and 6 of life with a rotavirus infection (Lee et al., 2014). Herpes simplex virus encephalitis is rare and severe lesions in the temporal lobes, but also elsewhere in the neonatal brain, are best seen with MRI, and once again more clearly and earlier with DWI (Vossough et al., 2008; Bajaj et al., 2014).

Other infections, for instance *Toxoplasmosis gondii*, can also present with neonatal seizures, in the presence of hydrocephalus and extensive white matter injury.

## Inborn errors of metabolism

Inborn errors of metabolism can be difficult to diagnose, and recognition of characteristic neuroimaging features is very helpful in the diagnostic process. It is beyond the scope of this review to describe all potential metabolic disorders which may present with neonatal seizures. A useful review was published by Prasad and Hoffmann (2010). A specific imaging pattern can suggest the diagnosis in some disorders and the additional use of <sup>1</sup>H-MRS may also aid in making the diagnosis (table 4) (Leijser et al., 2007).

Newborn infants with nonketotic *hyperglycinaemia* (NKH) often present with neonatal seizures and/or hiccups which may have been felt by the mother *in utero*. The aEEG typically shows a burst suppression

pattern without a history of HIE. The diagnosis may already be suspected using cUS, as the corpus callosum is often dysplastic, associated with a so-called “bull-horn” shape of the ventricles. It is possible to confirm this by MRI, but DWI may also show restricted diffusion of the PLIC and of the dorsal aspect of the midbrain and pons due to vacuolating myelinopathy (Kanekar and Byler, 2013). Using <sup>1</sup>H-MRS, the high glycine peak also suggests NKH.

Newborn infants with *molybdenum cofactor deficiency* or sulphite oxidase deficiency are often considered to have HIE, but the history is often not typical and these metabolic disorders should be considered as well. Typically, the onset of seizures is rather early to be due to HIE, seizures are very difficult to control and the background activity tends to deteriorate over time (Sie et al., 2010). MRI during the first week may show extensive DWI abnormalities, preceding extensive cystic evolution, which can be seen when the MRI is performed again several weeks later (Stence et al., 2013).

Those with *peroxisomal biogenesis disorders* do not invariably present with neonatal seizures. Ventricular dilatation, germinolytic cysts, and lenticulostriate vasculopathy may be recognised by cUS. As the fontanel is large in newborn infants with Zellweger syndrome, the sylvian fissure can often be clearly visualised and polymicrogyria may be suspected with cUS and confirmed with MRI. In addition, MRI may show signal intensity changes in the white matter and delayed myelination of the PLIC. Using <sup>1</sup>H-MRS with a short

**Table 4.** Neuroimaging findings in metabolic disorders.

Transient metabolic disorders	Neuroimaging findings
Hypoglycaemia	Predominant occipital abnormalities
Hyperbilirubinaemia (kernicterus)	Increased signal intensity in the globus pallidus on T1-weighted sequence
Inborn errors of metabolism	
Pyridoxine deficiency	Abnormalities of white matter and corpus callosum; haemorrhage in white matter.
Biotinidase deficiency	DWI abnormalities of the PLIC, corpus callosum, corona radiata (vacuolating myelinopathy).
Glutaric aciduria type 1	Widened anterior temporal, Sylvian and frontal CSF spaces and T2 hyperintensity of the pallidus.
Nonketotic hyperglycinaemia	Dysplastic corpus callosum, DWI abnormalities and lack of myelination of the PLIC (vacuolating myelinopathy).
Molybdenum cofactor deficiency/ sulphite oxidase deficiency	Extensive DWI changes of white matter with cystic evolution.
Zellweger syndrome	Germinolytic cysts, lenticulostriate vasculopathy, polymicrogyria; <sup>1</sup> H-MRS: abnormal mobile lipid peak at 0.9 ppm

PLIC: posterior limb of the internal capsule; DWI: diffusion weighted imaging; CSF: cerebrospinal fluid; <sup>1</sup>H-MRS: magnetic resonance spectroscopy.

echo time (TE), a reduced NAA peak at 2 parts per million (ppm), a lactate peak at 1.33 ppm, and an abnormal peak at 0.9 ppm can be seen, the latter being due to the resonances of the methyl residues of mobile lipids (Groenendaal *et al.*, 2001).

*Hypoglycaemia* can be considered as a transient metabolic disturbance and newborn infants may present with seizures due to severe hypoglycaemia, usually with a value below 1 mmol/L. The abnormalities tend to be overlooked with cUS, and are typically located in the occipital white matter, unless the posterior fontanel is also examined. MRI is a better technique to identify the lesions, which are often not restricted to the occipital regions (Burns *et al.*, 2008).

## Cerebral dysgenesis/genetic disorders

Infants with migrational disorders can present with neonatal seizures, but this is rather uncommon and most of the infants will develop seizures later during the first year. In most of these infants, there are associated findings leading to a diagnosis, for instance, migrational disorders may be encountered in children with a metabolic disorder (polymicrogyria in Zellweger syndrome) or congenital cytomegalovirus infection. There is considerable overlap with genetic disorders and this overlap is increasing with advances in genetics (Yang *et al.*, 2013). Neurocutaneous syndromes (linear naevus syndrome, incontinentia pigmenti and tuberous sclerosis) may also present with neonatal seizures (Hennel *et al.*, 2003; Merks *et al.*, 2003; Wortmann *et al.*, 2008; Isaacs, 2009).

Refractory neonatal seizures can increasingly be explained by an underlying genetic problem. Weckhuysen *et al.* (2012, 2013) recently showed mutations in *KCNQ2*, which encodes the voltage-gated potassium channel Kv7.2 in children with unexplained neonatal or early-infantile seizures and associated psychomotor retardation. Early MRI showed characteristic hyperintensity in the basal ganglia and thalamus that later resolved in a subgroup of their patients.

*Early infantile epileptic encephalopathy (EIEE or Ohtahara syndrome)* is a diagnosis made when intractable seizures are seen in the neonatal period. Many infants with Ohtahara syndrome have an associated underlying cerebral malformation, for instance, agenesis of the corpus callosum in Aicardi syndrome. EIEE is associated with several gene mutations, including Aristaless-related homeobox (*ARX*), cyclin-dependent kinase-like 5 (*CDKL5*), and syntaxin-binding protein 1 (*STXBP1*). No specific neuroimaging findings have been reported in these children (Pavone *et al.*, 2012).

*Aicardi-Goutières syndrome* is a genetically determined early-onset encephalopathy with a variable phenotype, including neurological manifestations such as dystonia, spasticity, epileptic seizures, progressive microcephaly, and severe developmental delay. Aicardi-Goutières syndrome is a heterogeneous disorder with five disease-associated genes (*AGS1-5*) accounting for 83% of cases that fulfil the clinical diagnostic criteria. In a recent study, 25% of infants were reported to have seizure onset within the first month after birth. Calcification is more easily detected using cUS than with MRI, but MRI shows delayed



myelination, grey and white matter atrophy, ventricular enlargement, and cystic degeneration over time, often quite marked in the temporal lobes and the periventricular white matter (Ramantani et al., 2014).

## Unknown

Although not so common anymore, every now and then neonatal seizures may occur without an explanation based on either neuroimaging or extensive genetic and metabolic investigations. More and more infants, however, can be diagnosed at a later stage. Sometimes, with a second MRI scan, using higher resolution and thinner slices, it may be possible to detect an area of cortical dysplasia (Wang et al., 2013). In others, a new mutation may be identified (Mastrangelo and Leuzzi, 2012).

## Neonatal MRI protocol

A standard neonatal MRI protocol should include sagittal T1-weighted images (T1WI), axial or coronal T2-weighted images (T2WI), and T1WI or inversion recovery-weighted images and DWI, including ADC mapping.

MRV, MR angiography (MRA), <sup>1</sup>H-MRS, and susceptibility-weighted images (SWI) should preferably be available as well. DWI is especially important in HIE and PAIS and is also useful in CNS infections, since pus shows up as a high signal on DWI. MRV should be added when a CSVT is suspected. MRA can be useful in PAIS and in diagnosing arteriovenous malformations. <sup>1</sup>H-MRS can provide additional information in suspected metabolic disorders, and HIE and SWI are useful in diagnosing (small) haemorrhages. Slice thickness should be 2 mm or thinner.

## Conclusion

Neuroimaging is very helpful to identify the underlying aetiology of neonatal seizures in full-term infants. cUS should be used in the acute phase and may show severe and centrally-located lesions, as well as calcification, which will not be recognised by MRI. More detailed information may subsequently be obtained with MRI, provided the use of thin (2 mm) slices and sequences suitable for imaging neonates. This renders MRI superior in diagnosing migrational disorders and lesions in the posterior fossa. When <sup>1</sup>H-MRS is added to the imaging protocol, metabolic disorders may be identified prior to obtaining results from metabolic investigations. Information on the type and severity of brain lesions may help to give a more accurate prognosis, and in some families, will aid with genetic counselling. □

## Acknowledgements and disclosures.

This work was supported by the European Community's 7<sup>th</sup> Framework Programme (HEALTH-F5-2009-4.2-1, grant agreement no. 241479, the NEMO project).

Lauren Weeke was supported by the European Community's Seventh Framework Programme (FP7-HEALTH-2009-4.2-1, grant agreement no. 241479, The NEMO Project). Pr. Linda de Vries presented part of the work at the Progress in Epileptic Disorders Workshop co-organized by the journal *epilepsia* in Rome, Italy.

None of the authors have any financial agreements or conflicts of interest to disclose.

## References

- Alderliesten T, de Vries LS, Benders MJ, Koopman C, Groenendaal F. MR imaging and outcome of term neonates with perinatal asphyxia: Value of diffusion-weighted MR imaging and (1)H MR spectroscopy. *Radiology* 2011; 261(1): 235-42.
- Bajaj M, Mody S, Natarajan G. Clinical and neuroimaging findings in neonatal herpes simplex virus infection. *J Pediatr* 2014; 165(2): 404-7.
- Barnette AR, Horbar JD, Soll RF, et al. Neuroimaging in the evaluation of neonatal encephalopathy. *Pediatrics* 2014; 133(6): e1508-17.
- Bednarek N, Mathur A, Inder T, Wilkinson J, Neil J, Shimony J. Impact of therapeutic hypothermia on MRI diffusion changes in neonatal encephalopathy. *Neurology* 2012; 78(18): 1420-7.
- Bergman I, Painter MJ, Hirsch RP, Crumrine PK, David R. Outcome in neonates with convulsions treated in an intensive care unit. *Ann Neurol* 1983; 14(6): 642-7.
- Brouwer AJ, Groenendaal F, Koopman C, Nievelstein RJ, Han SK, de Vries LS. Intracranial hemorrhage in full-term newborns: A hospital-based cohort study. *Neuroradiology* 2010; 52(6): 567-76.
- Bruno CJ, Beslow LA, Witmer CM, et al. Haemorrhagic stroke in term and late preterm neonates. *Arch Dis Child Fetal Neonatal Ed* 2014; 99(1): F48-53.
- Burns CM, Rutherford MA, Boardman JP, Cowan FM. Patterns of cerebral injury and neurodevelopmental outcomes after symptomatic neonatal hypoglycemia. *Pediatrics* 2008; 122(1): 65-74.
- Cowan F, Mercuri E, Groenendaal F, et al. Does cranial ultrasound imaging identify arterial cerebral infarction in term neonates? *Arch Dis Child Fetal Neonatal Ed* 2005; 90(3): F252-6.
- de Vries LS, Van der Grond J, Van Haastert IC, Groenendaal F. Prediction of outcome in new-born infants with arterial ischaemic stroke using diffusion-weighted magnetic resonance imaging. *Neuropediatrics* 2005; 36(1): 12-20.
- de Vries LS, Verboon-Macielek MA, Cowan FM, Groenendaal F. The role of cranial ultrasound and magnetic resonance imaging in the diagnosis of infections of the central nervous system. *Early Hum Dev* 2006; 82(12): 819-25.
- Galli KK, Zimmerman RA, Jarvik GP, et al. Periventricular leukomalacia is common after neonatal cardiac surgery. *J Thorac Cardiovasc Surg* 2004; 127(3): 692-704.



- Govaert P. Sonographic stroke templates. *Semin Fetal Neonatal Med* 2009; 14(5): 284-98.
- Griffiths PD, Paley MN, Whitby EH. Post-mortem MRI as an adjunct to fetal or neonatal autopsy. *Lancet* 2005; 365(9466): 1271-3.
- Groenendaal F, Bianchi MC, Battini R, et al. Proton magnetic resonance spectroscopy (1H-MRS) of the cerebrum in two young infants with Zellweger syndrome. *Neuropediatrics* 2001; 32(1): 23-7.
- Harteman JC, Groenendaal F, Toet MC, et al. Diffusion-weighted imaging changes in cerebral watershed distribution following neonatal encephalopathy are not invariably associated with an adverse outcome. *Dev Med Child Neurol* 2013; 55(7): 642-53.
- Hennel SJ, Ekert PG, Volpe JJ, Inder TE. Insights into the pathogenesis of cerebral lesions in incontinentia pigmenti. *Pediatr Neurol* 2003; 29(2): 148-50.
- Hoogstraate SR, Lequin MH, Huysman MA, Ahmed S, Govaert PP. Apnoea in relation to neonatal temporal lobe haemorrhage. *Eur J Paediatr Neurol* 2009; 13(4): 356-61.
- Isaacs H. Perinatal (fetal and neonatal) tuberous sclerosis: A review. *Am J Perinatol* 2009; 26(10): 755-60.
- Jaremko JL, Moon AS, Kumbha S. Patterns of complications of neonatal and infant meningitis on MRI by organism: A 10-year review. *Eur J Radiol* 2011; 80(3): 821-7.
- Kanekar S, Byler D. Characteristic MRI findings in neonatal nonketotic hyperglycinemia due to sequence changes in *GLDC* gene encoding the enzyme glycine decarboxylase. *Metab Brain Dis* 2013; 28(4): 717-20.
- Kersbergen KJ, de Vries LS, Leijten FS, et al. Neonatal thalamic hemorrhage is strongly associated with electrical status epilepticus in slow wave sleep. *Epilepsia* 2013; 54(4): 733-40.
- Kirton A, Shroff M, Visvanathan T, deVeber G. Quantified corticospinal tract diffusion restriction predicts neonatal stroke outcome. *Stroke* 2007; 38(3): 974-80.
- Lee KY, Oh KW, Weon YC, Choi SH. Neonatal seizures accompanied by diffuse cerebral white matter lesions on diffusion-weighted imaging are associated with rotavirus infection. *Eur J Paediatr Neurol* 2014; 18(5): 624-31.
- Leijser LM, de Vries LS, Rutherford MA, et al. Cranial ultrasound in metabolic disorders presenting in the neonatal period: Characteristic features and comparison with MR imaging. *AJNR Am J Neuroradiol* 2007; 28(7): 1223-31.
- Lequin MH, Vermeulen JR, van Elburg RM, et al. *Bacillus cereus* meningoencephalitis in preterm infants: Neuroimaging characteristics. *AJNR Am J Neuroradiol* 2005; 26(8): 2137-43.
- Leth H, Toft PB, Herning M, Peitersen B, Lou HC. Neonatal seizures associated with cerebral lesions shown by magnetic resonance imaging. *Arch Dis Child Fetal Neonatal Ed* 1997; 77(2): F105-10.
- Li AM, Chau V, Poskitt KJ, et al. White matter injury in term newborns with neonatal encephalopathy. *Pediatr Res* 2009; 65(1): 85-9.
- Low E, Boylan GB, Mathieson SR, et al. Cooling and seizure burden in term neonates: An observational study. *Arch Dis Child Fetal Neonatal Ed* 2012; 97(4): F267-72.
- Marlow N, Rose AS, Rands CE, Draper ES. Neuropsychological and educational problems at school age associated with neonatal encephalopathy. *Arch Dis Child Fetal Neonatal Ed* 2005; 90(5): F380-7.
- Martinez-Biarge M, ez-Sebastian J, Rutherford MA, Cowan FM. Outcomes after central grey matter injury in term perinatal hypoxic-ischaemic encephalopathy. *Early Hum Dev* 2010; 86(11): 675-82.
- Martinez-Biarge M, ez-Sebastian J, Kapellou O, et al. Predicting motor outcome and death in term hypoxic-ischemic encephalopathy. *Neurology* 2011; 76(24): 2055-61.
- Martinez-Biarge M, Bregant T, Wusthoff C, et al. White matter and cortical injury in hypoxic-ischemic encephalopathy: Antecedent factors and 2-year outcome. *J Pediatr* 2012; 161(5): 799-807.
- Mastrangelo M, Leuzzi V. Genes of early-onset epileptic encephalopathies: From genotype to phenotype. *Pediatr Neurol* 2012; 46(1): 24-31.
- Mastrangelo M, Van LA, Bray M, Pastorino G, Marini A, Mosca F. Epileptic seizures, epilepsy and epileptic syndromes in newborns: A nosological approach to 94 new cases by the 2001 proposed diagnostic scheme for people with epileptic seizures and with epilepsy. *Seizure* 2005; 14(5): 304-11.
- Merks JH, de Vries LS, Zhou XP, et al. PTEN hamartoma tumour syndrome: Variability of an entity. *J Med Genet* 2003; 40(10): e111.
- Miller SP, Latal B, Clark H, et al. Clinical signs predict 30-month neurodevelopmental outcome after neonatal encephalopathy. *Am J Obstet Gynecol* 2004; 190(1): 93-9.
- Miller SP, Ramaswamy V, Michelson D, et al. Patterns of brain injury in term neonatal encephalopathy. *J Pediatr* 2005; 146(4): 453-60.
- Moharir MD, Shroff M, Stephens D, et al. Anticoagulants in pediatric cerebral sinovenous thrombosis: A safety and outcome study. *Ann Neurol* 2010; 67(5): 590-9.
- Nicholl RM, Balasubramaniam VP, Urquhart DS, Sellathurai N, Rutherford MA. Postmortem brain MRI with selective tissue biopsy as an adjunct to autopsy following neonatal encephalopathy. *Eur J Paediatr Neurol* 2007; 11(3): 167-74.
- Okerefor A, Allsop J, Counsell SJ, et al. Patterns of brain injury in neonates exposed to perinatal sentinel events. *Pediatrics* 2008; 121(5): 906-14.
- Pavone P, Spalice A, Polizzi A, Parisi P, Ruggieri M. Ohtahara syndrome with emphasis on recent genetic discovery. *Brain Dev* 2012; 34(6): 459-68.
- Penido NO, Borin A, Iha LC, et al. Intracranial complications of otitis media: 15 years of experience in 33 patients. *Otolaryngol Head Neck Surg* 2005; 132(1): 37-42.
- Phan H, Lehman D. Cerebral abscess complicating *Proteus mirabilis* meningitis in a newborn infant. *J Child Neurol* 2012; 27(3): 405-7.

- Pisani F, Sisti L, Seri S. A scoring system for early prognostic assessment after neonatal seizures. *Pediatrics* 2009;124(4):e580-7.
- Prasad AN, Hoffmann GF. Early onset epilepsy and inherited metabolic disorders: Diagnosis and management. *Can J Neurol Sci* 2010;37(3):350-8.
- Rafay MF, Cortez MA, de Veber GA, et al. Predictive value of clinical and EEG features in the diagnosis of stroke and hypoxic ischemic encephalopathy in neonates with seizures. *Stroke* 2009;40(7):2402-7.
- Ramantani G, Maillard LG, Bast T, et al. Epilepsy in Aicardi-Goutieres syndrome. *Eur J Paediatr Neurol* 2014;18(1):30-7.
- Ronen GM, Penney S, Andrews W. The epidemiology of clinical neonatal seizures in Newfoundland: A population-based study. *J Pediatr* 1999;134(1):71-5.
- Ronen GM, Buckley D, Penney S, Streiner DL. Long-term prognosis in children with neonatal seizures: A population-based study. *Neurology* 2007;69(19):1816-22.
- Rutherford MA, Pennock JM, Counsell SJ, et al. Abnormal magnetic resonance signal in the internal capsule predicts poor neurodevelopmental outcome in infants with hypoxic-ischemic encephalopathy. *Pediatrics* 1998;102(2):323-8.
- Sato Y, Hayakawa M, Iwata O, et al. Delayed neurological signs following isolated parasagittal injury in asphyxia at term. *Eur J Paediatr Neurol* 2008;12(5):359-65.
- Schleede L, Bueter W, Baumgartner-Sigl S, et al. Pediatric herpes simplex virus encephalitis: A retrospective multicenter experience. *J Child Neurol* 2013;28(3):321-31.
- Sie SD, de Jonge RC, Blom HJ, et al. Chronological changes of the amplitude-integrated EEG in a neonate with molybdenum cofactor deficiency. *J Inherit Metab Dis* 2010;33(3):S401-7.
- Srinivasakumar P, Zempel J, Wallendorf M, Lawrence R, Inder T, Mathur A. Therapeutic hypothermia in neonatal hypoxic ischemic encephalopathy: Electrographic seizures and magnetic resonance imaging evidence of injury. *J Pediatr* 2013;163(2):465-70.
- Steinman KJ, Gorno-Tempini ML, Glidden DV, et al. Neonatal watershed brain injury on magnetic resonance imaging correlates with verbal IQ at 4 years. *Pediatrics* 2009;123(3):1025-30.
- Stence NV, Coughlin CR, Fenton LZ, Thomas JA. Distinctive pattern of restricted diffusion in a neonate with molybdenum cofactor deficiency. *Pediatr Radiol* 2013;43(7):882-5.
- Tekgul H, Gauvreau K, Soul J, et al. The current etiologic profile and neurodevelopmental outcome of seizures in term newborn infants. *Pediatrics* 2006;117(4):1270-80.
- Toet MC, Groenendaal F, Osredkar D, van Huffelen AC, de Vries LS. Postneonatal epilepsy following amplitude-integrated EEG-detected neonatal seizures. *Pediatr Neurol* 2005;32(4):241-7.
- Twomey E, Twomey A, Ryan S, Murphy J, Donoghue VB. MR imaging of term infants with hypoxic-ischaemic encephalopathy as a predictor of neurodevelopmental outcome and late MRI appearances. *Pediatr Radiol* 2010;40(9):1526-35.
- van der Aa NE, Dudink J, Benders MJ, et al. Neonatal posterior cerebral artery stroke: Clinical presentation, MRI findings, and outcome. *Dev Med Child Neurol* 2013;55(3):283-90.
- van Kooij BJ, van HM, Nievelstein RA, Groenendaal F, Jongmans MJ, de Vries LS. Serial MRI and neurodevelopmental outcome in 9- to 10-year-old children with neonatal encephalopathy. *J Pediatr* 2010;157(2):221-7.
- van Rooij LG, Toet MC, Osredkar D, van Huffelen AC, Groenendaal F, de Vries LS. Recovery of amplitude integrated electroencephalographic background patterns within 24 hours of perinatal asphyxia. *Arch Dis Child Fetal Neonatal Ed* 2005;90(3):F245-51.
- van Rooij LG, de Vries LS, van Huffelen AC, Toet MC. Additional value of two-channel amplitude integrated EEG recording in full-term infants with unilateral brain injury. *Arch Dis Child Fetal Neonatal Ed* 2010;95(3):F160-8.
- van Zwol AL, Lequin M, Aarts-Tesselaar C, et al. Fatal neonatal parechovirus encephalitis. *BMJ Case Rep* 2009.
- Verboon-Macielek MA, Groenendaal F, Cowan F, Gov-aert P, van Loon AM, de Vries LS. White matter damage in neonatal enterovirus meningoencephalitis. *Neurology* 2006;66(8):1267-9.
- Verboon-Macielek MA, Groenendaal F, Hahn CD, et al. Human parechovirus causes encephalitis with white matter injury in neonates. *Ann Neurol* 2008;64(3):266-73.
- Vinchon M, Joriot S, Jissendi-Tchofo P, Dhellemmes P. Postmeningitis subdural fluid collection in infants: Changing pattern and indications for surgery. *J Neurosurg* 2006;104(6):383-7.
- Vossough A, Zimmerman RA, Bilaniuk LT, Schwartz EM. Imaging findings of neonatal herpes simplex virus type 2 encephalitis. *Neuroradiology* 2008;50(4):355-66.
- Wang DD, Deans AE, Barkovich AJ, et al. Transmantle sign in focal cortical dysplasia: A unique radiological entity with excellent prognosis for seizure control. *J Neurosurg* 2013;118(2):337-44.
- Watanabe K, Hara K, Miyazaki S, Hakamada S, Kuroyanagi M. Apneic seizures in the newborn. *Am J Dis Child* 1982;136(11):980-4.
- Weckhuysen S, Mandelstam S, Suls A, et al. KCNQ2 encephalopathy: Emerging phenotype of a neonatal epileptic encephalopathy. *Ann Neurol* 2012;71(1):15-25.
- Weckhuysen S, Ivanovic V, Hendrickx R, et al. Extending the KCNQ2 encephalopathy spectrum: Clinical and neuroimaging findings in 17 patients. *Neurology* 2013;81(19):1697-703.
- Weeke LC, Groenendaal F, Toet MC, et al. The aetiology of neonatal seizures and the diagnostic contribution of neonatal cerebral magnetic resonance imaging. *Dev Med Child Neurol* 2014.
- Whitby EH, Griffiths PD, Rutter S, et al. Frequency and natural history of subdural haemorrhages in babies and relation to obstetric factors. *Lancet* 2004;363(9412):846-51.

Wortmann SB, Reimer A, Creemers JW, Mullaart RA. Prenatal diagnosis of cerebral lesions in tuberous sclerosis complex (TSC). Case report and review of the literature. *Eur J Paediatr Neurol* 2008; 12(2): 123-6.

Wu YW, Hamrick SE, Miller SP, *et al.* Intraventricular hemorrhage in term neonates caused by sinovenous thrombosis. *Ann Neurol* 2003; 54(1): 123-6.

Yang Y, Muzny DM, Reid JG, *et al.* Clinical whole-exome sequencing for the diagnosis of mendelian disorders. *N Engl J Med* 2013; 369(16): 1502-11.

Yıldız EP, Tatlı B, Ekici B, *et al.* Evaluation of etiologic and prognostic factors in neonatal convulsions. *Pediatr Neurol* 2012; 47(3): 186-92.

### Educational message

Cranial Ultrasound (cUS) should be performed for all newborns presenting with seizures in the acute phase. It may direct the differential diagnosis and is more informative than MRI in identifying intraventricular haemorrhages, germinolytic cysts and lenticulostriate vasculopathy.

It is strongly recommended to subsequently perform an MRI, in cases of hypoxic-ischaemic encephalopathy (HIE) on Day 4-7 after birth, after completion of hypothermia, and in all other cases as soon as possible.

T1- and T2-weighted images and DWI should be included in all MRI protocols. DWI is particularly useful for HIE, perinatal arterial ischaemic stroke (PAIS), CNS infections and inborn errors of metabolism. In cases of suspected cerebral sinovenous thrombosis (CSVT), MRVenography should be added to the protocol.

In cases of suspected inborn errors of metabolism, <sup>1</sup>H-MRS should be added to the MRI protocol.

The use of CT should be restricted to cases of severe intracranial haemorrhage (ICH) when urgent neurosurgical intervention may be required.

### TEST YOURSELF



(1) Which patterns of injury on MRI can be found in a child with hypoxic-ischaemic encephalopathy and how do the patterns relate to neurodevelopmental outcome in later childhood?

(2) For a full-term infant presenting with seizures on day 6 after birth, an intraventricular and thalamic haemorrhage on cranial ultrasound is identified. Which diagnosis should be ruled out and which sequence should be added to the MRI protocol?

(3) Neuroimaging findings in infants with a CNS infection are often dependent on a specific variable, which variable is this?

*Note: Reading the manuscript provides an answer to all questions. Correct answers may be accessed on the website, [www.epilepticdisorders.com](http://www.epilepticdisorders.com), under the section "The EpiCentre".*