

Mirth and laughter elicited during brain stimulation

Guadalupe Fernández-Baca Vaca¹, Hans O Lüders¹,
Maysaa Merhi Basha², Jonathan P Miller³

¹ Department of Neurology University Hospitals Case Medical Center, Case Western Reserve University, Cleveland

² Department of Neurology Harper University Hospital, Wayne State University, Detroit

³ Department of Neurosurgery University Hospitals Case Medical Center, Case Western Reserve University, Cleveland, USA

Received May 30, 2011; Accepted November 30, 2011

ABSTRACT – There are few reports of laughter and/or mirth evoked by electrical stimulation of the brain. In this study, we present a patient with intractable epilepsy in whom mirth and laughter was consistently produced during stimulation of the left inferior frontal gyrus (opercular part) using stereotactically placed depth electrodes. A review of the literature shows that cortical sites that produce mirth when stimulated are located in the dominant hemisphere close to language areas or cortical negative motor areas.

Key words: brain stimulation, cortical mapping, mirth, laughter, language areas, negative motor areas, gelastic seizures

Electrical stimulation in epileptic patients undergoing pre-surgical evaluation with intracranial electrodes is routinely performed to determine the location of eloquent cortical areas. This provides a unique opportunity to study the functional anatomy of the human brain.

Laughter and mirth have been studied by researchers for centuries yet their neuronal correlates still remain poorly defined (Wild *et al.*, 2003). There are few reports of laughter and mirth provoked by electrical stimulation of the brain. Arroyo *et al.* (1993) suggested that the motor program of laughter and the experience of mirth are dissociated. Based on their results, it was concluded that laughter is represented in the anterior cingulate gyrus and that mirth is a func-

tion of the temporal lobe. This was later supported by results published by Satow *et al.* (2003) and Sperli *et al.* (2006). Other reported data (Fried *et al.*, 1998; Krolak-Salmon *et al.*, 2006; Schmitt *et al.*, 2006) showed that laughter with and without mirth can be provoked by stimulation of the frontal cortex; in the pre-supplementary sensorimotor area (pre-SSMA), immediately anterior to face and hand representation in the rostral part of the supplementary sensorimotor area (SSMA), and the superior frontal gyrus.

In this manuscript, we present evidence that electrical stimulation of the left inferior frontal gyrus (opercular part) consistently elicited mirth and laughter in a patient with stereotactically placed depth electrodes for intractable epilepsy.

Correspondence:

Guadalupe Fernandez-Baca Vaca
Epilepsy Center,
Department of Neurology,
University Hospital Case Medical Center,
11100 Euclid Ave,
Lakeside 3200,
Cleveland Ohio 44106, USA
<guadalupe.fernandezbacavaca2
@uhhospitals.org>

Case report

The patient was a 55-year-old right-handed woman with non-lesional focal intractable epilepsy, who started having seizures at the age of 46. Her seizure semiology was characterised by an abdominal aura evolving into a dialeptic seizure. Related medical conditions were anxiety and depression, currently treated with fluoxetine. Her general and neurological examinations were unremarkable. MRI and PET scans showed no abnormalities. Previous noninvasive video-EEG monitoring showed interictal and ictal onset activity maximum at Sp1 (left sphenoidal). The patient had dialeptic seizures during surface monitoring. An intracarotid amobarbital test revealed left hemisphere dominance for language and bilateral dominance for memory (greater on the right than left side). Left mesial temporal lobe epilepsy was suspected and further investigation was performed using ten stereotactically placed depth electrodes covering mesial and lateral aspects of the frontal lobe, temporal lobe and insula, targeting the following structures: lateral and medial frontal lobe, temporal pole, amygdala, anterior and posterior hippocampus, posterior temporal lobe, posterior cingulate, and anterior and posterior insular cortices. The implanted electrodes were made of platinum-iridium and each electrode contact was 2.5mm in length with 5mm centre-to-centre inter-contact distance. The ictal onset zone was localised to the left hippocampus and the patient subsequently underwent multiple hippocampal transections.

Electrical stimulation was performed for functional mapping prior to epilepsy surgery. Electric current was applied with a pulse width of 0.5ms, duration of 3-5 seconds, and stimulation intensity of 1-12mA. Stimulation of the contact, located in the left inferior frontal gyrus (opercular part) in the limit between grey and white matter, consistently elicited laughter and a sensation of mirth. On several occasions, she started laughing during stimulation and stopped at the end of the stimulus. After termination of stimulation, she made comments such as "you guys are making me laugh", "something was making me laugh" or "that was really funny". When asked, she was unable to identify what was funny, but she would describe it "as if somebody was joking with me about something". The laughter appeared to be her typical laugh and was infectious, sometimes leading to a general burst of laughter by the physicians and technicians present in the room. This response was elicited at 6mA, a total of six times during two different stimulation sessions that took place on two different days. The response evoked on both days was almost identical, with the patient unaware that the same electrode was being stimulated. No afterdischarges were recorded. The superimposi-

tion of the presurgical MRI and the post-surgical CT scan using Brainlab® is shown in *figure 2*. The electrode contact where this behaviour was elicited is represented in the centre of the axial, coronal and sagittal planes.

Discussion

There are several reports of laughter evoked by electrical stimulation of the brain. In some of these reports, electrical stimulation was observed to elicit laughter without mirth. Sem-Jacobsen (1968) evoked laughter by electrical stimulation in the anterior cingulate and orbito-frontal cortex. In this study, difficulties were reported in the evaluation of the presence of mirth in these patients as they were diagnosed with psychiatric disorders. A report of a smile as a clinical response to electrical stimulation was described in two patients (Fish *et al.*, 1993) during stimulation of the amygdala and the frontal lobe. Again, it is unclear if these patients felt mirth during the stimulation. Right SSMA stimulation elicited laughter without mirth in one patient (Schmitt *et al.*, 2006). Another group (Sperli *et al.*, 2006) induced a contralateral smile and laughter without mirth by electrical stimulation of the right cingulate cortex. These results suggest the participation of the mesial frontal cortex in the motor aspects of laughter, as previously suggested (Arroyo *et al.*, 1993).

On the other hand, other groups were able to elicit laughter along with mirth sensation (Arroyo *et al.*, 1993; Fried *et al.*, 1998; Krolak-Salmon *et al.*, 2006; Satow *et al.*, 2003). Arroyo *et al.* (1993) reported two patients with mirth and laughter provoked by electrical stimulation in the left basal temporal region (parahippocampal and fusiform gyrus) and one patient with gelastic seizures arising from the left cingulate who was seizure-free after surgery. The authors suggested dissociation between the motor act and processing of emotional content of laughter, with representation in the anterior cingulate and basal temporal areas, respectively. They proposed the basal temporal lobe as the structure involved in the association of visual, auditory and olfactory perception, cognitive processing, and transmission of information to the limbic system. This was supported by Satow *et al.* (2003) who reported a case of mirth provoked during electrical stimulation of the left inferior temporal gyrus. Later on, mirth with laughter was induced by electrical stimulation of the temporal lobe in two patients (Fried *et al.*, 1998; Krolak-Salmon *et al.*, 2006). Mirth with laughter was induced by stimulation of the left frontal cortex, rostral to the anterior part of the SSMA (Fried *et al.*, 1998). The authors proposed a close linkage between the motor, affective and cognitive components of laughter based on the observation that the patient

gave a different explanation each time, attributing the laughter to whatever external stimulus was present at the time. Krolak-Salmon *et al.* (2006) systematically provoked smiling and laughter along with a sensation of merriment in a patient during electrical stimulation in the left pre-SSMA. These results suggest the participation of not only the temporal lobe, but also the frontal lobe in the emotional aspect of laughter. Moreover, laughter was elicited in an 18-month-old patient over the left lateral premotor cortex (Schmitt *et al.*, 2006). However, in this case, due to the patient's age, it was unclear if mirth was present or not. The cortical stimulation sites that elicited mirth in previous reports, including the case reported here, are summarised in *figure 1*.

We consistently induced mirth and laughter at 6mA in the left inferior frontal gyrus (opercular part), very close to the superior border of the anterior insular cortex, in the limit between white and grey matter. This contact resulted from a depth electrode targeting the anterior insular cortex with a medio-ventral to latero-dorsal trajectory. No afterdischarges were seen during stimulation. Stimulation of adjacent contacts did not produce similar symptoms. Position of the depth electrode was verified by superimposition of pre-implantation MRI with a post-implantation high resolution CT scan providing very precise anatomical location, however, the possibility of activation of the insular cortex and/or immediately adjacent white matter tracts cannot be excluded.

It is worthwhile to note that, in most of the cases in which mirth was elicited, the stimulated electrodes were located in the frontal or temporal lobes

of the dominant hemisphere based on Wada results (Arroyo *et al.*, 1993; Satow *et al.*, 2003; Fried *et al.*, 1998; Krolak-Salmon *et al.*, 2006). Handedness or language lateralisation was not specified in one patient (Fried *et al.*, 1998) and in another patient language was lateralised to the right hemisphere with Wada test performed only on the left (Arroyo *et al.*, 1993). In addition, many of the reported stimulation sites were close to a speech area. Mirth and language disturbances were induced in the left basal temporal region in three patients (Arroyo *et al.*, 1993; Satow *et al.*, 2003), two of whom had left language dominance, taking into account that the basal temporal lobe is known to support language functions (Lüders *et al.*, 1991). Our patient is a right-handed woman with left language dominance in whom mirth was elicited in the left hemisphere, in a location next to Broca's area. As discussed in other publications, humour processing in humans is related to language (Arroyo *et al.*, 1993; Spector, 1990) and Broca's area has been associated with the processing of humour in normal patients using fMRI (Ozawa *et al.*, 2000). In another case report (Fried *et al.*, 1998), speech arrest was elicited, in addition to mirth and laughter, in the mesial frontal lobe, rostral to the SSMA region. Fried *et al.* suggested that speech and laughter are closely represented in the area immediately anterior to that involved in manual activity. However, current evidence does not support the assumption that the pre-SSMA area includes a language centre. Many groups have consistently elicited speech arrest and/or speech slowing by electrical stimulation in the region rostral to the SSMA (Penfield and Welch, 1951; Van Buren and Fedio, 1976; Fried *et al.*, 1991; Lim

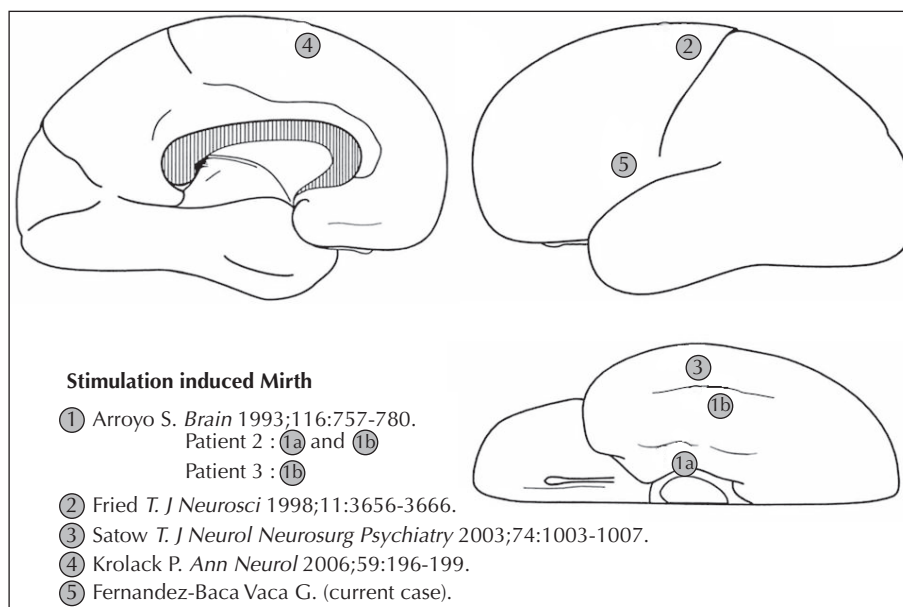


Figure 1. Summary of stimulation sites that elicited mirth alone or with laughter.

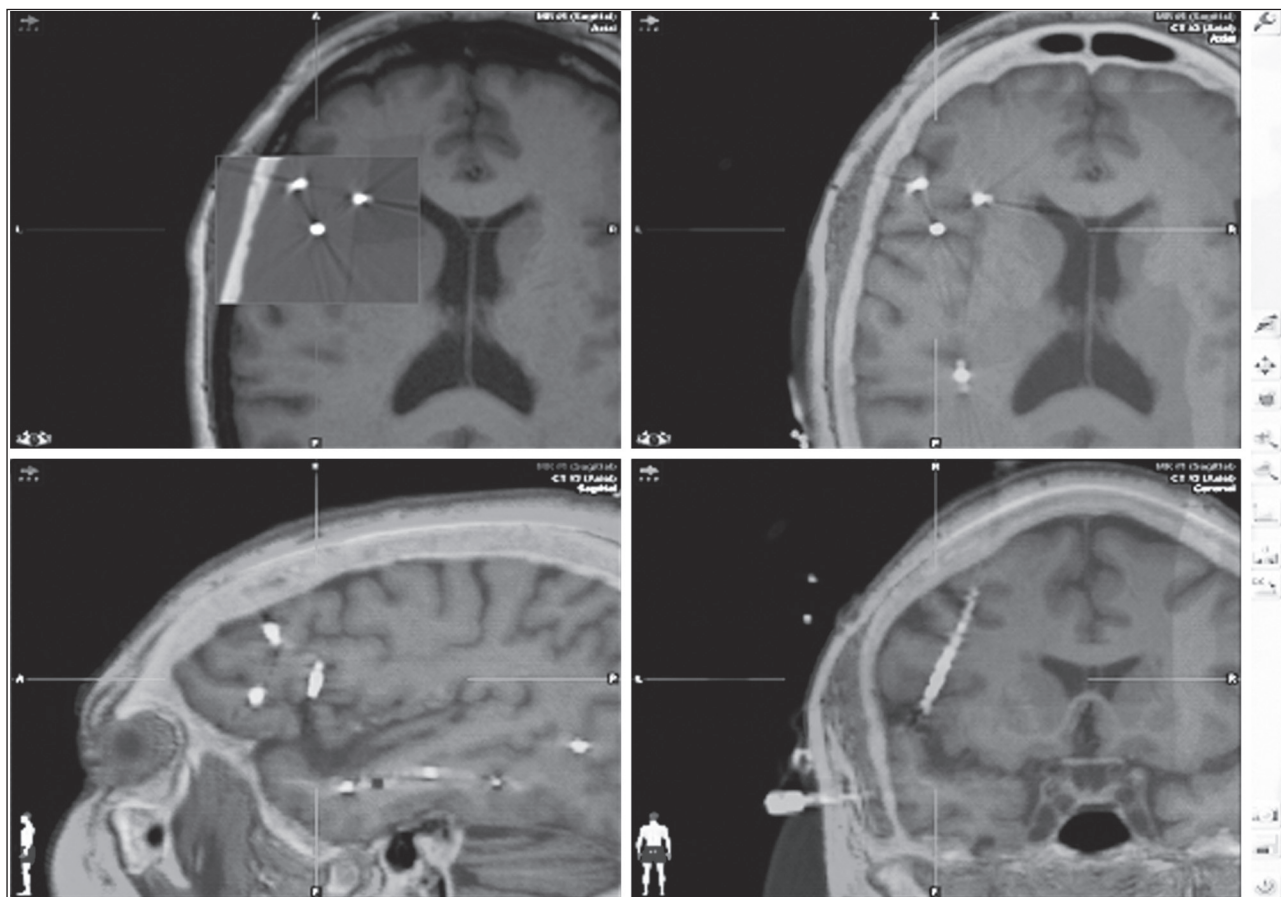


Figure 2. Superimposition of the presurgical MRI and postsurgical cranial CT scan using Brainlab®. The electrode contact where mirth and laughter were elicited is represented in the centre of the axial, coronal and sagittal planes.

et al., 1994). This phenomenon was first interpreted as aphasia but was subsequently demonstrated to be secondary to inhibition of movement of the tongue since the stimulated area is part of the supplementary negative motor area (Lim *et al.*, 1994). Repetitive vocalisations were also elicited by electrical stimulation in the mesial frontal area, either as a continuous prolongation of a vowel sound (Fried *et al.*, 1991) or associated with a rhythmic movement involving the mouth and jaw, bilaterally (Lim *et al.*, 1994). These vocalisation movements differ from the symptoms elicited by stimulation in other language areas (Broca, Wernicke and the basal temporal language areas) (Schäffler *et al.*, 1993).

A negative motor area is defined as a cortical region that, when stimulated at a stimulus intensity that does not otherwise produce symptoms or afterdischarges, produces an inability to perform or sustain voluntary contractions. There is evidence in humans for two negative motor areas which function: (1) bilaterally in the mesial portion of the superior frontal gyrus immediately in front of the face motor area of the SSMA,

and (2) in the inferior frontal gyrus of the dominant hemisphere, in front of the primary motor face area frequently overlapping with Broca's area. It has been speculated that these areas are related to the planning of voluntary movements (Lüders *et al.*, 2000). Matelli *et al.* described two frontal areas in the macaque monkey, F5 and F6, which play a role in the preparation of voluntary movements (Matelli *et al.*, 1991). These areas may correspond to the negative motor areas and Broca's area in humans (Lüders *et al.*, 2000). We believe it is significant that mirth and laughter are elicited in areas that overlap or are in close proximity with these negative areas, as shown in previous publications (Fried *et al.*, 1998; Krolak-Salmon *et al.*, 2006) and our own patient. This suggests that these areas may have evolved from areas F5 and F6 in monkeys and are not only specialised in preparation for voluntary movements and/or language (Broca's area) but also in mirth and humour.

In summary, it appears that mirth with laughter can be induced by stimulation of a variety of frontal or temporal sites, mainly in the dominant hemisphere,

in close spatial proximity to language (basal temporal language area and Broca's area) and negative motor areas, suggesting that these areas may be involved in the motor expression (laughter) of mirth. It is surprising, however, that laughter and mirth are not elicited by electrical stimulation of brain areas in close proximity to Wernicke's area if this assumption is correct.

In addition, electrical stimulation elicits mirth and laughter only very rarely, compared to language and negative motor phenomena. This suggests that the cortical areas involved in mirth and laughter must be relatively small.

The possibility that the mirth and laughter observed in our patient was related to mood alterations or frontal lobe disinhibition (pathological laughter) should also be considered. We believe, however, that this is unlikely in this case. The patient's mood was stable and she denied any symptoms of depression or mania. The patient also did not display any symptoms of disinhibition or pathological laughter. Of course, the possibility that the mirth and laughter was the product of frontal disinhibition elicited by the electrical stimulation cannot be excluded.

Pleasant auras, including sensations of satisfaction, harmony or orgasm-like sensation have been reported (Stefan *et al.*, 2004; Meletti *et al.*, 2006). In some patients, these sensations were associated with other symptoms and signs, such as abdominal auras, *déjà-vu* auras, fear, visual auras and oral automatism. In most of these patients, the epileptogenic zone was localised to the temporal lobe but lateralisation was inconclusive. Our patient had a consistent feeling of mirth along with laughter during electrical stimulation. She described the sensation to be as "if someone was joking with me," "if someone was trying to make me laugh" and her sensation could be interpreted as a humoristic state. We believe this sensation is different from satisfaction, harmony or orgasmic sensation and corresponds to a different symptomatogenic zone. The same applies also to the "humoristic mirth" elicited by cortical stimulation by other authors (Arroyo *et al.*, 1993; Fried *et al.*, 1998; Krolak-Salmon *et al.*, 2006; Satow *et al.*, 2003).

Laughter is the main symptom of gelastic seizures which may or may not be accompanied by subjective feelings of mirth. Spontaneous gelastic seizures have been mainly associated with hypothalamic hamartomas and less frequently with temporal, frontal and anterior cingulate lesions (Bianchin and Sakamoto, 2008; Munnari *et al.*, 2000). Intracranial recordings of patients with gelastic seizures have shown that the ictal onset zone for gelastic seizures without mirth is most often located in the hypothalamic hamartoma (Kahane *et al.*, 2003) but may also be located in the frontal lobe, specifically the anterior cingulate, the superior frontal gyrus and the orbito-frontal cortex (Arroyo

et al., 1993; Chassagnon *et al.*, 2003; Umeoka *et al.*, 2008; Unnwongse *et al.*, 2010). There are studies showing that acute electrical stimulation of hypothalamic hamartoma elicits gelastic seizures (Kahane *et al.*, 2003). It is possible, however, that this may be related to spread of the epileptiform discharge to connected brain areas and that the symptomatogenic zone for mirth and laughter seen during gelastic seizures could be located in a different region. The review of the literature outlined above suggests that the symptomatogenic zone for the motor act of laughing without mirth is most likely represented in the frontal lobe (anterior cingulate and superior frontal gyrus in both hemispheres), and that the symptomatogenic zone for the sensation of mirth may be represented in the temporal and frontal lobes of the dominant hemisphere in close proximity to language (Broca's area or basal temporal areas) and negative motor areas. □

References

- Arroyo S, Lesser RP, Gordon B, *et al.* Mirth, laughter and gelastic seizures. *Brain* 1993; 116: 757-80.
- Bianchin MM, Sakamoto AC. Complex motor seizures: localizing and lateralizing value. In: Lüders HO. *Textbook of Epilepsy Surgery*. London (UK): Informa Healthcare, 2008: 462-78.
- Chassagnon S, Minotti I S, Kremer S, *et al.* Restricted frontomesial epileptogenic focus generating dyskinetic behavior and laughter. *Epilepsia* 2003; 44: 859-63.
- Fish DR, Gloor P, Quesney FL, Olivier A. Clinical responses to electrical brain stimulation of the temporal and frontal lobes in patients with epilepsy. Pathophysiological implications. *Brain* 1993; 116: 397-414.
- Fried I, Katz A, McCarthy G, *et al.* Functional organization of human supplementary motor cortex studied by electrical stimulation. *J Neurosci* 1991; 11: 3656-66.
- Fried I, Wilson CL, MacDonald KA, Behnke EJ. Electric current stimulates laughter. *Nature* 1998; 391: 650.
- Kahane P, Ryvlin P, Hoffmann D, Minotti L, Benabid AL. From hypothalamic hamartoma to cortex: what can we learnt from depth recordings and stimulation? *Epileptic Disord* 2003; 5: 205-17.
- Krolak-Salmon P, Hénaff AM, Vighetto A, *et al.* Experiencing and detecting happiness in humans: the role of the supplementary motor area. *Ann Neurol* 2006; 59: 169-99.
- Lim SH, Dinner DS, Pillay PK, *et al.* Functional anatomy of the human supplementary sensorimotor area. Results of extra-operative electrical stimulation. *Electroencephalogr Clin Neurophysiol* 1994; 91: 179-93.
- Lüders H, Lesser RP, Hahn J, *et al.* Basal temporal language area. *Brain* 1991; 114: 743-54.
- Lüders HO, Dinner DS, Morris HH, Wyllie E, Comair YG. Electrical stimulation of negative motor areas. In: Lüders HO,

- Noachtar S. *Epileptic seizures. Pathophysiology and clinical semiology*. Philadelphia: Churchill Livingstone, 2000: 199-210.
- Matelli M, Luppino G, Rizzolatti G. Architecture of superior and mesial area 6 and the adjacent cingulate cortex in the macaque monkey. *J Comp Neurol* 1991;311: 445-62.
- Meletti S, Tassi L, Mai R, et al. Emotions induced by intracerebral electrical stimulation of the temporal lobe. *Epilepsia* 2006;47: 47-51.
- Munnari C, Quarato P, Kahane P, et al. Gelastic and dacrystic seizures. In: Lüders HO, Noachtar S. *Epileptic seizures. Pathophysiology and clinical semiology*. Philadelphia: Churchill Livingstone, 2000: 458-71.
- Ozawa F, Matsuo K, Kato C, et al. The effects of listening comprehension of various genres of literature on response in the linguistic area: an fMRI study. *Neuroreport* 2000;27: 1141-3.
- Penfield W, Welch K. The supplementary motor area of the cerebral cortex; a clinical and experimental study. *AMA Arch Neurol Psychiatry* 1951;66: 289-317.
- Satow T, Usui K, Matsushashi M, et al. Mirth and laughter arising from the human temporal cortex. *J Neurol Neurosurg Psychiatry* 2003;74: 1003-7.
- Schäffler L, Lüders HO, Dinner DS, Lesser RP, Chelune GJ. Comprehension deficits elicited by electrical stimulation of Broca's area. *Brain* 1993;116: 695-715.
- Schmitt JJ, Janszky J, Woermann F, Tuxhorn I, Ebner A. Laughter and the mesial and lateral premotor cortex. *Epilepsy Behav* 2006;8: 773-5.
- Sem-Jacobsen CW. *Depth-electrographic stimulation of the human brain and behavior: from fourteen years of studies and treatment of Parkinson's disease and mental disorders with implanted electrodes*. Springfield (IL): Charles C. Thomas, 1968.
- Spector CC. Linguistic humor comprehension of normal and language-impaired adolescents. *J Speech Hear Disord* 1990;55: 533-41.
- Sperli B, Spinelli L, Pollo C, Seeck M. Contralateral smile and laughter, but no mirth, induced by electrical stimulation of the cingulate cortex. *Epilepsia* 2006;47: 440-3.
- Stefan H, Schulze-Bonhage A, Pauli E, et al. Ictal pleasant sensations: cerebral localization and lateralization. *Epilepsia* 2004;45: 35-40.
- Umeoka S, Baba K, Mihara T. Symptomatic laughter in a patient with orbitofrontal seizure: A surgical case with intracranial electroencephalographic study: case report. *Neurosurgery* 2008;63: E1205-6.
- Unnwongse K, Wehner T, Bingaman W, Foldvary-Shaefer N. Gelastic seizures and the anteriomesial frontal lobe: A case report and review of intracranial EEG recording and electrocortical stimulation case studies. *Epilepsia* 2010;51: 2195-8.
- Van Buren JM, Fedio P. Functional representation on the medial aspect of the frontal lobes in man. *J Neurosurg* 1976;44: 275-89.
- Wild B, Rodden FA, Grodd W, Ruch W. Neuronal correlates of laughter and humour. *Brain* 2003;126: 2121-38.