

Mind-stretching faints

Roland D. Thijs¹, J. Gert van Dijk¹, John B.P. Stephenson²,
Wouter Wieling³

¹ Department of Neurology and Clinical Neurophysiology, Leiden University Medical Centre, Leiden, The Netherlands

² Fraser of Allander Neurosciences Unit, Royal Hospital for Sick Children, Glasgow, Scotland

³ Department of Internal Medicine, Academic Medical Center, Amsterdam, The Netherlands

Key words: stretch syncope, transient loss of consciousness, Valsalva, seizure

Syncope has been defined as a transient, brief, self-limited loss of consciousness due to global cerebral hypoperfusion (Brignole *et al.* 2004). The specific pathophysiology sets syncope apart from other conditions causing transient loss of consciousness (TLOC), such as epilepsy. The major causes and mimics of TLOC are summarised in *figure 1*. History-taking is the most important tool to distinguish syncope from epilepsy. The paper by Mazzuca and Thomas (2007) on self-induced stretch syncope published in this issue of the journal raises a number of important issues related to the pathophysiology and misdiagnosis of such paroxysmal events. Before discussing the historical features that are useful to discriminate between syncope and epilepsy, we will first briefly review the symptoms and classification of syncope.

Signs and symptoms of syncope

Syncope can be provoked in almost anyone by a procedure that causes an abrupt fall of cerebral perfusion: the "fainting lark". The self-applied manoeuvre consists of squatting in a full knee bend and over-breathing by taking about 20 deep breaths. The subject then stands up suddenly and performs a forced expiration against a closed glottis (Howard *et al.* 1951, Lempert *et al.* 1994, Wieling and van Lieshout 2002). The fainting lark combines the effects of systemic arterial

hypotension induced by acute vasodilatation of the lower limbs (post-ischemic effect of squatting) and decreased cardiac output (effects of standing up and raised intrathoracic pressure) and cerebral vasoconstriction induced by hypocapnia (due to hyperventilation). The high cerebral venous pressure induced by straining can be expected to play an important adjunctive role in the effectiveness of the fainting lark to induce syncope. *Figure 2* documents the precipitous and marked fall in arterial pressure and cerebral blood flow induced by the fainting lark in one of the authors (WW) (Wieling and van Lieshout 2002). It should be noted that hypotension induced by the fainting lark occurs very rapidly and this may also hold for the loss of consciousness. Prodromal symptoms are minimal. In reflex syncope (synonymous with neurally-mediated syncope), the drop in blood pressure usually occurs more gradually; prodromal symptoms due to slight hypoperfusion of the brain and retina may act as warning signs. In acute circulatory arrest, it usually takes 6-8 seconds before the subject loses consciousness (Gastaut and Fischer-Williams 1957, Rossen *et al.* 1943, Weiss and Baker 1933). The threshold to syncope appears to differ between ages, and the lowest threshold is found in early childhood (Stephenson 1990). With asystole beyond 7 seconds, bilateral synchronous slow waves appear in the EEG, which, in turn, fairly abruptly make way for a

Correspondence:

Roland D. Thijs
Department of Neurology and Clinical
Neurophysiology
Leiden University Medical Centre
PO Box 9600
2300 RC Leiden
The Netherlands
Tel.: (+00 31) 71 5266524
Fax: (+00 31) 71 5248253
<r.d.thijs@lumc.nl>

doi: 10.11684/epd.2007.0134

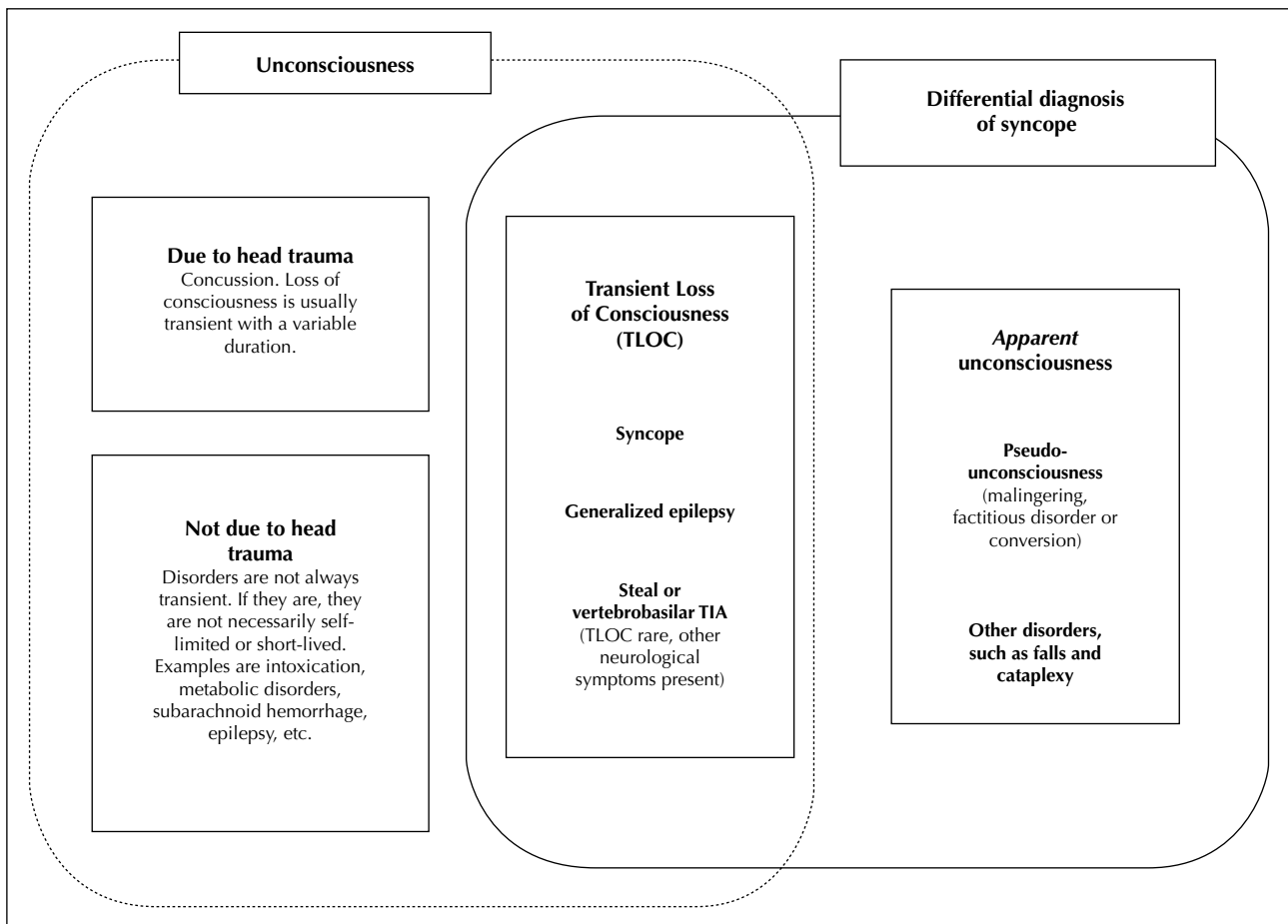


Figure 1. Syncope in relation to real and apparent loss of consciousness. “Transient loss of consciousness” (TLOC) involves a self-limited, transient, short-lived loss of consciousness not due to head trauma. Syncope is a form of TLOC caused by cerebral hypoperfusion. The differential diagnosis of syncope primarily includes other disorders within TLOC. Sometimes it is not clear whether consciousness was truly lost. Disorders that cause “apparent unconsciousness” then also feature in the differential diagnosis of syncope. Causes of unconsciousness that are either due to head trauma, or are not transient, not self-limited or not short-lived, can usually be distinguished from syncope and other forms of TLOC (Thijs *et al.* 2004).

complete flattening of the EEG (Brenner 1997, Gastaut and Fischer-Williams 1957).

Loss of consciousness is usually preceded by prodromal features such as blurred vision (greying or blacking-out due to hypoperfusion of the retina), buzzing in the ears, light-headedness, nausea, sweating and pallor (Gastaut and Fischer-Williams 1957, Hoefnagels *et al.* 1991, Rossen *et al.* 1943, Sheldon *et al.* 2002). These signs may allow the patient to predict an oncoming attack and sometimes even to prevent loss of consciousness by lying down. Other effective manoeuvres to abort an impending faint include total body-tensing squatting, or sitting with the head between the knees (Van Dijk *et al.* 2006, Wieling *et al.* 2004). The duration of the loss of consciousness is usually no longer than 20 seconds, but it may be longer, especially if the subject is kept upright while unconscious. Syncope may cause the subject to fall with either flaccid or stiff limbs (Lempert *et al.* 1994). Myoclonic jerks were

frequently (90%) observed in healthy subjects who intentionally provoked syncope using the “fainting lark” (Lempert *et al.* 1994). In this study, the jerks were almost exclusively arrhythmic and asynchronous, and always occurred after the individual had fallen down. However, jerking movements probably do not occur in 90% of all syncope attacks: in fainting blood donors, such movements were only seen in 46% of patients in a prospective study (Newman and Graves 2001). Prolonged tonic spasms in extension may occur in syncope and should not be misdiagnosed as epilepsy (Gastaut and Fischer-Williams 1957, Rossen *et al.* 1943, Stephenson 1990, Weiss and Baker 1933). Adding to the diagnostic complexity, even definite epileptic seizures may be induced by syncope (Horrocks *et al.* 2005, Stephenson *et al.* 2004). During the loss of consciousness in syncope, the eyes are open and upward eye deviation or downbeat nystagmus may be noted (Gastaut 1974, Lempert and von Brevern

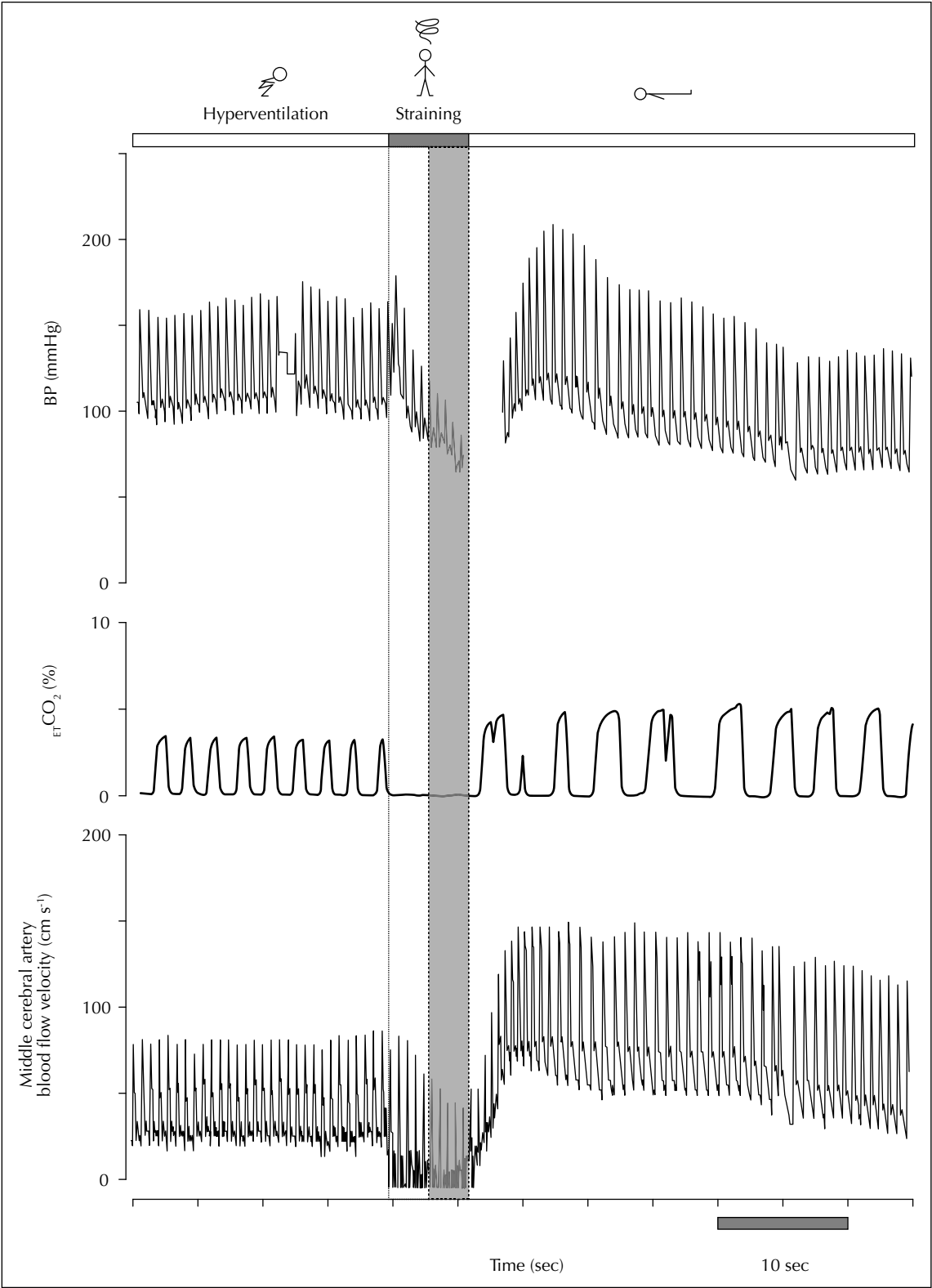


Figure 2. Continuous monitoring of changes in finger blood pressure, end-tidal CO₂ and cerebral blood flow velocity induced by the fainting lark in a 55-year-old male. After a very short period of light-headedness (grey area), the subject blacked out and fainted (Wieling and van Lieshout 2002).

1996, Lin *et al.* 1982, Stephenson 1990). In addition, turning of the head to one side may be observed (Gastaut and Fischer-Williams 1957, Lempert *et al.* 1994, Rossen *et al.* 1943, Stephenson 1990). Subsequent recovery of consciousness is spontaneous and complete. Afterward, the patient may appear pale and complain of headache, a feeling of weakness or fatigue (Gastaut 1974, Lewis 1932, Sharpey-Schafer 1956). Urinary incontinence may occur in syncope, and so does fecal incontinence, although the latter should be considered rare (Hoefnagels *et al.* 1991, Lin *et al.* 1982, Newman and Graves 2001). Occasionally, tongue-biting may be caused by a syncopal event, but if so, it is usually restricted to the tip of the tongue, in contrast to the lateral lacerations caused by epileptic seizures (Benbadis *et al.* 1995).

Classification of syncope

Irrespective of its cause, syncope results from a combination of factors leading to cerebral hypoperfusion. The most important factor is arterial hypotension, but high cerebral vascular resistance, high cerebral (venous) pressure or hypoxia may also contribute to syncope (Sharpey-Schafer 1956).

The causes of syncope can be classified according to pathophysiological mechanisms (*table 1*) (Thijs *et al.* 2004). They fall into two major categories: decreased cardiac output and failure of the systemic circulation to maintain normotension. For each category, two subdivisions can be made. The four mechanisms of failure are: 1) insufficient pumping action of the heart, i.e., reduced cardiac output. Cardiac arrhythmia and structural heart disease fall into this category; 2) insufficient filling of the circulation, i.e. hypovolemia in turn causing a reduced cardiac output; 3) low blood pressure due to loss of

capacity to increase vascular resistance, with failure to prevent blood pooling in the legs and abdomen during standing. Syncope in this group is due to orthostatic hypotension. Primary, secondary and drug-induced autonomic failure also fall into this category; 4) a counterproductive neural influence over the circulation that involves the central nervous system: i.e. reflex syncope or neurally-mediated syncope. The dysfunction consists of vagally-mediated bradycardia, sympathetic withdrawal-mediated vasodilatation or both. The autonomic nervous system abnormality in reflex syncope differs fundamentally from that in autonomic failure: in autonomic failure, the autonomic nervous system initiates a normal action, but fails to deliver a response of sufficient magnitude, while in reflex syncope the action itself is inappropriate.

The classification presented here is a broad overview; it could easily be expanded to include further subtypes of syncope. As examples, a few subtypes of syncope are mentioned in *table 1*. In many cases, syncope involves a complex chain of events, with different interlocking mechanisms contributing to its occurrence. Of all the causes of syncope, reflex syncope is by far the most prevalent form, especially in young subjects, where almost all episodes of syncope are due to reflex syncope (Colman *et al.* 2004, Ganzeboom *et al.* 2003, Ganzeboom *et al.* 2006).

Discriminative factors between syncope and epilepsy

Detailed medical history-taking is of paramount importance to distinguish syncope from epilepsy. Sequential details beginning with the setting, provocation and prodromal phase, through the actual period of unconsciousness (usually necessitating eyewitness descriptions), and

Table 1. Classification of syncope.

<p>A. Decreased cardiac output</p> <p>Cardiac syncope</p> <p><i>Insufficient pumping action of the heart</i></p> <ul style="list-style-type: none"> - Arrhythmia (Examples: paroxysmal ventricular tachycardia, long QT syndrome) - Structural cardiac disease (Examples: valvular disease, obstructive cardiomyopathy) <p>Hypovolemia</p> <p><i>Insufficient circulatory volume</i> (Examples: Addison's disease, diuretics, hemorrhage)</p>
<p>B. Disturbed regulation of resistance and capacitance vessels</p> <p>Reflex syncope (neurally-mediated syncope)</p> <p><i>Inappropriate neural control over the circulation</i></p> <p>Examples: vasovagal syncope, carotid sinus syndrome, micturition syncope, stretch syncope</p> <p>Autonomic failure</p> <p><i>Insufficient vascular tone, leading to orthostatic hypotension</i></p> <ul style="list-style-type: none"> - Primary (Examples: multiple system atrophy, pure autonomic failure) - Secondary (Examples: diabetic and other neuropathies) - Drugs (Examples: antidepressants, alpha-adrenergic blockers)

recovery, are crucial elements of the interview (Gastaut 1974, Sharpey-Schafer 1956, Stephenson 1990). A vital clue favouring reflex syncope are the typical triggers such as pain, fear or prolonged standing (Brignole *et al.* 2004, Ganzeboom *et al.* 2003, Sheldon *et al.* 2002, Sheldon *et al.* 2006). Obvious precipitating events with a consistent history are sufficient to diagnose neurally-mediated or reflex syncope. In addition, the occurrence of pallor, nausea or sweating prior to loss of consciousness or episodes of presyncope without loss of consciousness makes syncope more likely than epilepsy (Hoefnagels *et al.* 1991, Sheldon *et al.* 2002). As mentioned earlier, stiffness, myoclonus and spasms are not restricted to epilepsy. The occurrence of jerks after falling in syncope and the asynchronous movements may be of help to discern between syncope and epilepsy, although this issue has not been evaluated in evidence-based questionnaires. Urinary incontinence cannot be used to discriminate between epilepsy and syncope (Hoefnagels *et al.* 1991, Sheldon *et al.* 2002).

Postictal confusion, prolonged loss of consciousness (if estimated to exceed 5 minutes), head turning, cyanosis, muscle pain and a lateral tongue bite strongly favour a generalized tonic-clonic seizure (Benbadis *et al.* 1995, Hoefnagels *et al.* 1991, Sheldon *et al.* 2002). However, it should be stressed that a single historical feature is not decisive for the diagnosis of syncope. Although head turning may be more prevalent in patients with epilepsy, it may also occur in syncope (Gastaut and Fischer-Williams 1957, Lempert *et al.* 1994, Rossen *et al.* 1943, Stephenson 1990). In addition, cyanosis may also be seen in adults with cardiac syncope and in children with prolonged vasovagal episodes (Sheldon *et al.* 2006, Stephenson 1990). Finally, it should be noted that syncope is an extremely common symptom with a lifetime prevalence of 30-40% in the general population (Ganzeboom *et al.* 2003, Ganzeboom *et al.* 2006, Thijs *et al.* 2006). This contrasts sharply with the lifetime prevalence of epilepsy which has been estimated at 0.5% of the general population (MacDonald *et al.* 2000).

Stretch syncope

For reflex syncope, triggering events may vary from one episode to another within the same patient (Ganzeboom *et al.* 2006). However, in micturition syncope, cough syncope and stretch syncope, syncope is consistently associated with one triggering event and is therefore termed "situational syncope", a subclass of reflex syncope. In this issue, Mazzuca and Thomas (2007) discuss an interesting patient with stretch syncope. The eminent physiologist Sharpey-Schafer was probably the first to describe this condition (and to propose its mechanism in the same sentence): "Young males who leap out of bed, stand on tiptoe in an extreme lordotic posture and "stretch yawn"

are performing a Valsalva manoeuvre and may fall unconsciousness" (Sharpey-Schafer 1965). Stretch syncope has only been rarely reported, but its incidence and prevalence are unknown (Pelekanos *et al.* 1990, Sturzenegger *et al.* 1995). All cases so far reported concerned adolescent boys in whom syncope occurred while they stretched their limbs with the neck hyperextended, in either the standing or sitting position. The precise mechanism of stretch syncope remains obscure. Studies of the cardiovascular responses to stretching and the Valsalva manoeuvre in these patients were the same as controls, indicating that the mechanism is probably not simply related to the Valsalva manoeuvre. However, it should be realised that the yawn-stretch manoeuvre involves a slow, maximal, deep inspiration followed by a slow expiration, which is different from a Valsalva manoeuvre.

An alternative explanation for stretch syncope involves vertebral artery compression (Pelekanos *et al.* 1990, Sturzenegger *et al.* 1995). However, it is difficult to conceive how exactly vertebrobasilar ischemia ensues, as this would probably require a high grade bilateral stenosis of the vertebral arteries and a failure of the collateral circulation to supply blood through the posterior communicating arteries.

Mazzuca and Thomas demonstrated in their patient that neither head rotation nor neck extension alone could provoke syncope. However, forced hyperextension of the neck with stretching while arms were hyper-abducted did induce symptoms together with vertebrobasilar hypoperfusion. Unfortunately, blood pressure recordings during the syncopal spell are lacking. Therefore, it is still unclear whether the drop in cerebral perfusion resulted from mechanical compression of the vertebrobasilar system induced by neck extension, or from systemic arterial hypotension induced by the stretch manoeuvre itself, or both. The time-course of events pleads against the compression theory: the patient did not lose consciousness while stretching, but shortly afterwards. In addition, if the vertebrobasilar compression is sufficient to cause TLOC, one would expect other signs and symptoms of brainstem dysfunction such as diplopia, dysarthria, hemiparesis or ataxia. Therefore, the exact hemodynamic event causing syncope after stretching needs to be elucidated, and ideally, further studies should include continuous recordings of heart rate, blood pressure, intrathoracic pressure and cerebral blood flow velocity of both anterior and posterior circulation. The elusive mechanisms that underlie stretching as a trigger for syncope require us to keep our minds stretched. □

References

- Benbadis SR, Wolgamuth BR, Goren H, *et al.* Value of tongue biting in the diagnosis of seizures. *Arch Intern Med* 1995; 155: 2346-9.

- Brenner RP. Electroencephalography in syncope. *J Clin Neurophysiol* 1997; 14: 197-209.
- Brignole M, Alboni P, Benditt DG, *et al.* Guidelines on management (diagnosis and treatment) of syncope--update 2004. *Europace* 2004; 6: 467-537.
- Colman N, Nahm K, Ganzeboom KS, *et al.* Epidemiology of reflex syncope. *Clin Auton Res* 2004; 14 (Suppl. 1): i9-i17.
- Ganzeboom KS, Colman N, Reitsma JB, *et al.* Prevalence and triggers of syncope in medical students. *Am J Cardiol* 2003; 91: 1006-8; (A8).
- Ganzeboom KS, Mairuhu G, Reitsma JB, *et al.* Lifetime cumulative incidence of syncope in the general population: a study of 549 Dutch subjects aged 35-60 years. *J Cardiovasc Electro-physiol* 2006; 17: 1172-6.
- Gastaut H. Syncope: generalized anoxic cerebral seizures. In : Vinken PJ, Bruyn GW, eds. *Handbook of Clinical Neurology, Volume 15*. Amsterdam : North-Holland Publishing Company, 1974: 815-35.
- Gastaut H, Fischer-Williams M. Electro-encephalographic study of syncope; its differentiation from epilepsy. *Lancet* 1957; 273: 1018-25.
- Hoefnagels WA, Padberg GW, Overweg J, *et al.* Transient loss of consciousness: the value of the history for distinguishing seizure from syncope. *J Neurol* 1991; 238: 39-43.
- Horrocks IA, Nechay A, Stephenson JB, *et al.* Anoxic-epileptic seizures: observational study of epileptic seizures induced by syncope. *Arch Dis Child* 2005; 90: 1283-7.
- Howard P, Leathart GL, Dornhorst AC, *et al.* P. The mess trick and the fainting lark. *Br Med J* 1951; 2: 382-4.
- Lempert T, Bauer M, Schmidt D. Syncope: a videometric analysis of 56 episodes of transient cerebral hypoxia. *Ann Neurol* 1994; 36: 233-7.
- Lempert T, von Brevern M. The eye movements of syncope. *Neurology* 1996; 46: 1086-8.
- Lewis T. A lecture on vasovagal syncope and the carotid sinus mechanism with comments on Gowers's and Nothnagel's syndrome. *BMJ* 1932; 1: 873-6.
- Lin JT, Ziegler DK, Lai CW, *et al.* Convulsive syncope in blood donors. *Ann Neurol* 1982; 11: 525-8.
- MacDonald BK, Cockerell OC, Sander JW, *et al.* The incidence and lifetime prevalence of neurological disorders in a prospective community-based study in the UK. *Brain* 2000; 123: 665-76.
- Mazzuca M, Thomas P. Self-induced stretch syncope of adolescence: a video-EEG documentation. *Epileptic Disord* 2007; 9: 413-7.
- Newman BH, Graves S. A study of 178 consecutive vasovagal syncopal reactions from the perspective of safety. *Transfusion* 2001; 41: 1475-9.
- Pelekanos JT, Dooley JM, Camfield PR, *et al.* Stretch syncope in adolescence. *Neurology* 1990; 40: 705-7.
- Rossen R, Kabat H, Anderson JP. Acute arrest of cerebral circulation in man. *Arch Neurol Psychiatr* 1943; 50: 510-29.
- Sharpey-Schafer EP. Syncope. *Br Med J* 1956; 1: 506-9.
- Sharpey-Schafer EP. Effect of respiratory acts on the circulation. In: Hamilton WFDP, ed. *Handbook of physiology: a critical, comprehensive presentation of physiological knowledge and concepts. Section II: Circulation*. Washington D.C.: American Physiological Society, 1965: 1875-86.
- Sheldon R, Rose S, Connolly S, *et al.* Diagnostic criteria for vasovagal syncope based on a quantitative history. *Eur Heart J* 2006; 27: 344-50.
- Sheldon R, Rose S, Ritchie D, *et al.* Historical criteria that distinguish syncope from seizures. *J Am Coll Cardiol* 2002; 40: 142-8.
- Stephenson J, Breningstall G, Steer C, *et al.* Anoxic-epileptic seizures: home video recordings of epileptic seizures induced by syncope. *Epileptic Disord* 2004; 6: 15-9.
- Stephenson JBP. Anoxic seizures or syncope. In : Stephenson J, ed. *Fits and faints*. Oxford : Mac Keith Press, 1990: 41-58.
- Sturzenegger M, Newell DW, Douville, *et al.* Transcranial Doppler and angiographic findings in adolescent stretch syncope. *J Neurol Neurosurg Psychiatry* 1995; 58: 367-70.
- Thijs RD, Kruit MC, van Buchem MA, *et al.* Syncope in migraine - The population-based CAMERA study. *Neurology* 2006; 66: 1034-7.
- Thijs RD, Wieling W, Kaufmann H, *et al.* Defining and classifying syncope. *Clin Auton Res* 2004; 14 (Suppl. 1): 4-8.
- Van Dijk N, Quartieri F, Blanc JJ, *et al.* Effectiveness of physical counterpressure maneuvers in preventing vasovagal syncope: the Physical Counterpressure Manoeuvres Trial (PC-Trial). *J Am Coll Cardiol* 2006; 48: 1652-7.
- Weiss S, Baker JP. The carotid sinus reflex in health and disease. Its role in the causation of fainting and convulsions. *Medicine* 1933; 12: 297-354.
- Wieling W, Colman N, Krediet CT, *et al.* Nonpharmacological treatment of reflex syncope. *Clin Auton Res* 2004; 14 (Suppl. 1): i62-i70.
- Wieling W, van Lieshout JJ. The fainting lark. *Clin Auton Res* 2002; 12: 207.