

Memory function decline over 18 months after selective amygdalohippocampectomy

Tatsuya Ogino¹, Yoko Ohtsuka¹, Yumiko Ido²,
Yoshiaki Mayanagi³, Eiju Watanabe³, Eiji Oka¹

1. Department of Child Neurology, Graduate School of Medicine and Dentistry,
2. Department of Central Clinical Laboratory, Okayama University Hospital, Okayama,
3. Department of Neurosurgery, Tokyo Metropolitan Police Hospital, Tokyo, Japan.

Received June 16, 2003; Accepted January 20, 2004

ABSTRACT – We report on a 22 year-old woman with left temporal lobe epilepsy who had suffered complex partial seizures since childhood. At 19 years 10 months of age she underwent selective amygdalohippocampectomy, which resulted in a complete cessation of seizures. Preoperatively, the Logical Memory II section of the WMS-R revealed poor logical memory function. Postoperatively, the patient's scores on several neuropsychological tests had deteriorated, namely, the Miyake Paired-Associate Word Learning Test (related and unrelated pairs), several sections of the WMS-R (Figural Memory, Logical memory I, Visual Reproduction II, Visual Paired Associates I, and Verbal Paired Associates I and II), and the BVRT-R. In particular, her scores on the Visual Paired Associates I, Verbal Paired Associates I and II sections of the WMS-R, and the BVRT-R not only declined at one and three months post-surgery, but also showed progressive deterioration at 16 and 18 months post-surgery. It should be kept in mind that selective amygdalohippocampectomy can result in progressive postoperative, deterioration in some aspects of memory function.

KEY WORDS: temporal lobe epilepsy, selective amygdalohippocampectomy, Miyake Paired-Associate Word Learning Test, WMS-R, BVRT-R

This study was performed at the Department of Child Neurology, Graduate School of Medicine and Dentistry, Okayama University Shikata-cho 2-5-1, Okayama 700-8558, Japan

Correspondence:

Tatsuya Ogino
Department of Child Neurology, Graduate School of Medicine and Dentistry, Okayama University, Shikata-cho 2-5-1, Okayama 700-8558, Japan.
Tel.: + 81-86-235-7372
Fax: + 81-86-235-7377
E-mail: (Tatsuya Ogino) tatsu@md.okayama-u.ac.jp

Although unilateral temporal lobectomy rarely causes global amnesia, it is not uncommon for it to cause mild deficits in memory function. The precise nature of the memory disturbances caused by such lobectomies is not fully agreed upon. In general, it is thought that a left temporal lobectomy causes a deterioration in verbal memory [1]. However, visual memory deficits have also been associated with a left temporal lobectomy [2].

Factors influencing memory function after a temporal lobectomy include age-at-seizure-onset and age-at-surgery, preoperative state of memory function, extent of preoperative hippocampal damage, extent of tissue ex-

cision, and postoperative hippocampal shrinkage [3]. Aspects of memory function that are evaluated by neuropsychological tests, as well as the timing of such tests after surgery, can also be important determinants of postoperative testing performance.

We report on a patient who showed deterioration in some aspects of memory function in the 18 months that followed a selective amygdalohippocampectomy.

Case history

The subject of this report is a 22 year-old, right-handed woman. She had a

prolonged febrile generalized convulsion with right-side dominance at the age of two years. She began to have complex partial seizures associated with oral and gestural automatisms at six years of age. These seizures often started with epigastric sensations. Since being referred to the Okayama University Hospital at the age of 14 years, she had been treated with phenytoin, carbamazepine, and zonisamide without seizure cessation. At the age of 18, she began to complain of difficulty in remembering daily events such as schoolwork and the contents of conversations with friends.

Throughout her clinical course, her interictal EEGs showed sporadic spikes independently in the bilateral anterior temporal regions. Her ictal EEGs recorded twice at 14 years six months of age showed 4 to 7 c/s theta rhythms in the left hemisphere. During a presurgical evaluation at 19 years 10 months of age, four complex partial seizures were recorded by long term video/EEG monitoring. In all of these seizures, theta-wave bursts occurred exclusively in the left sphenoidal lead in the initial phase of the seizures, suggesting a left medial temporal epileptogenic focus. A brain MRI revealed atrophy and increased T2 signals in the left hippocampus (*figure 1A*). Interictal TC99m-ECD SPECT showed slight but widespread hypoperfusion in the left basal temporal lobe, the basal frontal lobe, and the occipital lobe. Ictal SPECT revealed a hyperperfusion area in the left temporal lobe. A sodium amyltal test indicated left hemisphere dominance for language.

Since the patient continued to have several seizures a week despite intensive AED therapy, we decided to perform a left selective amygdalohippocampectomy on her at 19 years 10 months of age. A 25 mm cortical incision was made in the left superior temporal gyrus along the direction of the gyrus. The anterior-most point of the cortical incision was made 3cm from the tip of the temporal lobe. Resection was continued through the white matter until the lateral ventricle was opened. After exposing the hippocampal head, the amygdala and a part of the hippocampus were excised along with the parahippocampal gyrus. The hippocampus and parahippocampal gyrus were resected as one block, beginning from the tip of the hippocampal head to a point 3 cm posterior to the tip of the hippocampal head. The MRI, which was taken six months after surgery, is shown in *figure 1B*.

Following surgery, the patient's seizures disappeared but residual, right upper quadrantic hemianopsia was observed. Neuropathological study revealed moderate to severe gliosis throughout the resected hippocampus and more or less nonhomogeneous neuronal cell density in the dentate gyrus. Interictal EEGs showed only sporadic spikes in the right anterior temporal regions. Furthermore, following surgery, the patient began to complain of difficulty in remembering people's names and things she heard, as compared to before surgery. She also found it difficult to

remember the lyrics of songs, although she was able to learn melodies as easily as before surgery. She had started to study the electric organ several years before surgery, and after surgery she had no difficulty in playing the electronic organ or learning new tunes.

No aphasia nor apraxia was noted except for a slight difficulty in finding words. Though the patient's subjective memory disturbances continued until the last follow-up, some gradual improvement was noticed. When the last round of memory tests was performed (16 and 18 months post-surgery), she claimed that she could accomplish the tasks more easily than in the period immediately following the surgery (one and three months post-surgery).

Neuropsychological tests

The following neuropsychological tests were administered one month prior to surgery and/or during the 26-month postoperative period. The results of these tests, with the exception of the SLTA, are shown in *table 1*. All tests were administered as part of routine clinical examinations. When tests were administered more than once, the same version of the test was used, with the exception of the MPLT. Each MPLT trial was administered with different but equivalent stimuli. To maintain the patient's motivation, the tests were performed over the course of a few days whenever possible. The patient took all the tests seriously and earnestly.

Wechsler Adult Intelligence Scale Revised Japanese Edition (WAIS-R)

Administered one month prior to surgery (19y 8 m of age), and 1 month (19y 11 m), 16 months (21y 1 m) and 26 months (22y 0 m) after the surgery.

Results

Prior to surgery, the VIQ score was lower than the PIQ score (VIQ 83, PIQ 105, FIQ 91). Comparing preoperative and postoperative scores, VIQ had marginally deteriorated, while PIQ improved.

Miyake Paired-Associate Word Learning Test (MPLT)

This test involves two word lists, each of which comprises 10 related word pairs or 10 unrelated word pairs. Immediately after the patient hears the list of words, 10 words, one from each pair, are presented and the patient has to recall the corresponding words. The same trial for each list of words is repeated until the patient can recall all 10 corresponding words or until three trials are completed. The MPLT was administered 1 month prior to the surgery (19y 8 m), and 1 month (19y 11 m), 4 months (20y 2 m) and 16 months (21y 1 m) after the surgery.

Results

Prior to surgery, the patient could recall all 10 related word pairs on the first trial and all 10 unrelated word pairs

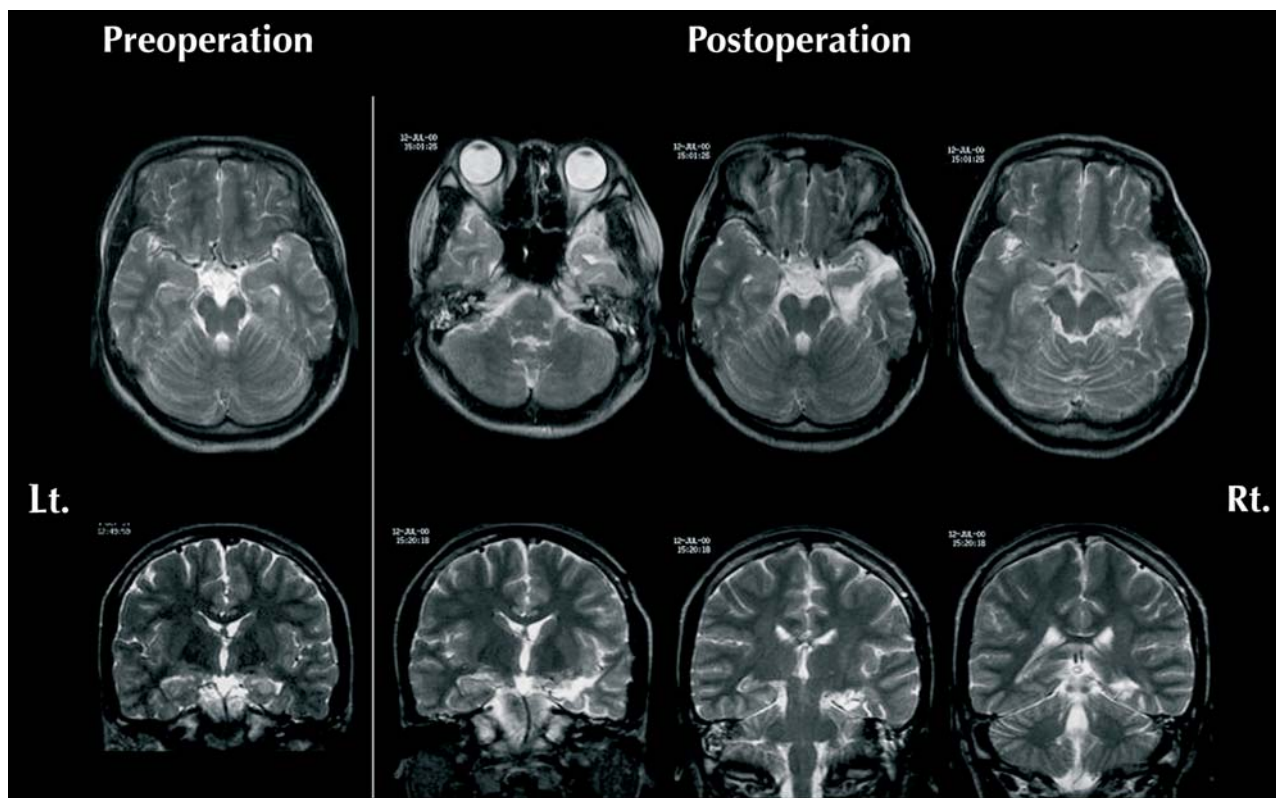


Figure 1. Left: Preoperative MRI, Right: Postoperative MRI which was taken six months after surgery.

on the second trial. Postoperatively, she could not recall all 10 related word pairs on the first trial. In particular, at 16 months post-surgery, she could not recall all 10 related word pairs even on the third trial. Her performance on the unrelated word list section deteriorated so significantly that she could not learn more than half of the words on the list even by the third trial on all three postoperative tests.

Wechsler Memory Scale Revised (WMS-R)

Administered immediately before surgery (19y 9 m), and 3 months (20y 1 m), 15 months (21y 1 m) and 18 months (21y 3 m) after surgery. In order to compare changes in scores across all sections, the scores of the sections were transformed to z-scores, which were computed by reducing the mean of a standardized sample from the raw scores, and dividing by SD.

Results

Prior to surgery, the patient's scores on all the sections were within normal ranges, with the exception of the Logical Memory II section, for which the patient's score was less than -2. Post-surgery, all the verbal memory section scores had deteriorated except for that of Digit Span. In particular, the scores on Verbal Paired Associates I deteriorated by more than two points at three and 15 months post-surgery, and decreased by 6.8 points at

18 months post-surgery. The score on Verbal Paired Associates II also decreased by more than 1 point at three and 15 months post-surgery, and by 3.3 points at 18 months post-surgery. Each score of Logical Memory I in 3 postoperative trials was lower than the preoperative trial by more than 1 point, but this did not deteriorate further as time passed. In contrast to the sections described above, the scores on Digit Span were constantly good. Regarding the visual memory sections, the postoperative decrease of scores was relatively mild. The scores on all three postoperative trials of Figural Memory were lower by about 1.7 points when compared to the preoperative trial. Declines in the scores on Visual Paired Associates I at three and 15 months post-surgery were minimal, but decreased by 1.8 points at 18 months post-surgery when compared with the preoperative trial. On Visual Reproduction II, the scores decreased by more than 1 point at three and 15 months post-surgery, but the score at 18 months post-surgery was equal to the score for the preoperative trial.

Benton Visual Retention Test Revised (BVRT-R)

Administered one month before surgery (19y 8 m), and 1 month (19y 11 m) and 16 months (21y 1 m) after surgery. The numbers of correct answers and errors were evaluated.

Table 1. The results of the neuropsychological tests

Tests		Pre	Post		
WAIS-R			1 month	16 months	26 month
FSIQ		91	95	85	89
VIQ		83	76	68	72
PIQ		104	124	118	118
MPLT			1 month	4 months	16 months
Relevant	1st	10	3	4	1
	2nd	-	7	10	8
	3rd	-	10	-	9
Irrelevant	1st	6	0	0	3
	2nd	10	4	2	4
	3rd	-	4	4	5
WMS-R (z-score)			3 months	15 months	18 months
Mental Control		-0.50	0.75	0.75	0.75
Figural Memory		1.00	-0.67	-0.67	-0.67
Logical Memory I		-1.81	-3.22	-3.22	-3.06
Visual Paired Associates I		0.18	-0.73	-0.73	-1.64
Verbal Paired Associates I		1.05	-1.23	-1.23	-5.77
Visual Reproduction I		-1.56	-0.36	-0.36	-0.76
Digit Span		1.05	0.26	0.26	0.26
Visual Memory Span		0.27	0.27	0.27	-0.33
Logical Memory II		-2.21	-2.96	-2.96	-3.10
Visual Paired Associates II		0.38	0.38	0.38	0.38
Verbal Paired Associates II		0.22	-0.89	-0.89	-3.11
Visual Reproduction II		-0.19	-1.47	-1.47	-0.19
BVRT-R			1 month	16 months	
correct		10	8	6	
error		0	2	5	
KWCST			1 month	18 months	
CA		5	5	6	
PEN		0	0	0	
DMS		0	2	0	

Results

Preoperative performance was excellent: the patient scored 10 correct responses with no errors. After the surgery, the scores on the BVRT-R gradually deteriorated, that is, the number of correct responses decreased from 8 to 6, and the number of errors increased from 2 to 5.

Wisconsin Card Sorting Test Keio Version (KWCST)

Administered one month before surgery (19y 8 m), and 1 month (19y 11 m) and 17 months (21y 3 m) after the surgery. Among several indices, the number of categories achieved (CA), the number of perseverative errors of Nelson (PEN), and the difficulty of maintaining set (DMS) were evaluated.

Results

Throughout the course, the patient's performance on the KWCST was within the average range.

Standard Language Test of Aphasia (SLTA)

Administered 26 months after surgery. This test is comprised of 25 subtests, each of which belongs to one of four domains including hearing, speaking, reading and writing, as well as mathematical tasks.

Results

The score of the section titled "Writing words with KANJI (Japanese ideograms)" was below the standardized mean by one point. All of the other sections were within the normal ranges.

Summary

The patient's performance on the MPLT, and the Figural Memory, Logical Memory I and Visual Reproduction II sections of the WMS-R declined postoperatively (in comparison to preoperative performance). However, these scores did not progressively deteriorate during the postoperative follow-up period. In contrast, the patient's scores

on the Visual Paired Associates I, Verbal Paired Associates I and Verbal Paired Associates II sections of the WMS-R, and her score on the BVRT-R not only declined at one and three months post-surgery, but also showed progressive deterioration at 16 and 18 months post-surgery.

Discussion

Our patient raises several intriguing questions regarding the effect of temporal lobe epilepsy and amygdalohippocampectomy on memory function. It is generally believed that left temporal lobectomies result chiefly in verbal memory dysfunction [1-3]. Selective amygdalohippocampectomy has been reported to be less harmful to verbal memory function than standard temporal resection [4]. However, some studies have failed to support this conclusion [5]. To say the least, even selective amygdalohippocampectomy often causes verbal memory dysfunction after left side resections [1]. Our patient also mostly exhibited a decline in verbal memory performance following surgery. Among the verbal memory functions, only the scores of digit span were fair throughout her clinical course. This finding is consistent with the findings of other authors, who concluded that verbal short-term memory skills assessed by memory span tasks are not affected by temporal lobectomy [6, 7].

Our patient scored poorly on the Logical Memory II section of the WMS-R before surgery, but there were no corresponding deficits on the associative memory and visual memory sections of the test prior to surgery. After the surgery however, her scores on the Paired Associates section, among the verbal memory tasks, declined markedly, which indicates that the nature of her memory disturbance before and after surgery was qualitatively different. Rausch and Babb [8] reported that the degree of hippocampal cell loss was directly related to the scores for learning of unrelated word pairs, but not to the scores for learning of semantically complex logical prose. Therefore, they inferred that the hippocampus proper is involved in simple rote learning. The fact that the most prominent change in our patient after surgery was a disturbance of associative memory supports this conclusion.

Our patient's difficulty with complex semantic memory that was present prior to surgery, maybe have been caused by a dysfunction in a part of the brain other than the hippocampus. The memory disturbances caused by long-term epilepsy may not be restricted to the areas surrounding the epileptic focus. Based on the study of patients with right or left unilateral hippocampal sclerosis, Saling *et al.* [9] concluded that left hippocampal disturbances are related to performance on Paired Associates tests, and that no laterality effect was seen on the recall of passages. They concluded that recall of passages is controlled by widely distributed neural systems, including the bilateral temporal structures.

Postoperative memory disturbance often improves with time [10], but in our patient the scores for several tests deteriorated during the 18-month, postoperative follow-up period. In particular, her performance on the Verbal Paired Associates I and II sections of the WMS-R markedly declined. On the other hand, there was no progressive deterioration in her Logical Memory I and II scores. Since the same tests were administered repeatedly, the test-retest effect should be taken into consideration. However, this effect usually manifests itself as a rise in scores [11]. Accordingly, we believe that the progressive decline of the test scores in our patient is significant. There have been few studies regarding postoperative longitudinal changes in memory test performance. Selwa *et al.* [11] found that there was no significant difference between patients tested at two to five months post-surgery and those tested more than five months post-surgery. Since their conclusion was based on a comparison between the two groups, not on longitudinal changes in the same patients, changes in an individual patient's postoperative performance over time was not considered.

Our patient's memory deterioration cannot be ascribed to residual seizures since her seizures were suppressed following the surgery. It might be possible that postoperative hippocampal remnant shrinkage played a role in the deterioration of her memory function. Baxendale *et al.* [3] reported that patients with more extensive remnant shrinkage showed more severe postoperative memory decline. It is also known that hippocampal remnant shrinkage starts very soon after surgery, and stabilizes three months post-surgery [3]. The decline of memory function in our patient cannot be ascribed to hippocampal remnant shrinkage because progression of her memory deterioration was still observed 18 months post-surgery.

It has been reported that a significant number of patients with temporal lobe epilepsy suffer from depression [12], and that patients with comorbid depression also show disturbances over a wide range of neuropsychological functions including memory [12]. However, this was not the case in our patient because she showed neither obvious depressive symptoms (as assessed by the DSM-IV criteria), nor a deterioration in general intelligence and language functions.

In addition to verbal memory, following surgery our patient showed a gradual decline in the number of correct responses on the BVRT, which measures visual retention. Furthermore, her scores on the Visual Paired Associates I section of the WMS-R were lowest on the trial administered at 18 months post-surgery. Decline of visual memory due to left temporal lesions has often been reported [2, 13, 14]. However, in our patient it is not plausible that the amygdalohippocampectomy directly resulted in the deterioration of her BVRT and Visual Paired Associates I scores because her performance on those tests soon after the surgery were not markedly poor. There is the possibility

that the neuronal systems used for those visual memory tasks are largely the same as those used for verbal tasks, which showed deterioration over the postoperative course. Another possibility is that functions mediated by the right temporal lobe deteriorated because the right temporal lobe is used to compensate for disturbed verbal memory in the left temporal lobe, which is known as the 'crowding effect' [2]. To elucidate whether the operation itself caused the decline of visual memory function, sophisticated procedures such as the anterior selective temporal lobe amobarbital tests [15] may be useful.

Finally, one of the most interesting findings in this study is that our patient reported a subjective improvement in memory performance despite the lack of quantitative improvement on neuropsychological tests. It is well known that the degree of subjective memory disturbance and the performance of objective memory tests are not necessarily comparable in patients with epilepsy [16]. We cannot explain with any certainty our patient's subjective impression of memory improvement. Perhaps some factors related to memory functions which were not measured by our test battery, such as very long-term memory consolidation [16], might have improved in our patient.

Regarding memory dysfunction after temporal lobectomy or amygdalohippocampectomy, the longitudinal changes in individual patients should be investigated from multiple standpoints. These detailed investigations on individual patients will enable future researchers to select the most appropriate items for group-to-group comparisons. Both group studies and longitudinal studies of individual patients are likely to shed light on the complex relationship between memory function and the medial temporal lobe. □

References

1. Gleissner U, Helmstaedter C, Schramm J, *et al.* Memory outcome after selective amygdalohippocampectomy - A study in 140 patients with temporal lobe epilepsy. *Epilepsia* 2002; 43: 87-95.
2. Saykin AJ, Gur RC, Sussman NM, *et al.* Memory deficits before and after temporal lobectomy - Effect of laterality and age of onset. *Brain and Cognition* 1989; 9: 191-200.
3. Baxendale SA, Thompson PJ, Kitchen ND. Postoperative hippocampal remnant shrinkage and memory decline - A dynamic process. *Neurology* 2000; 55: 243-9.
4. Pauli E, Pickel S, Schulemann H, *et al.* Neuropsychologic findings depending on the type of the resection in temporal lobe epilepsy. In: Stefan H, Andermann F, Chauvel P, Shorvon S. *Advances in Neurology*, Vol.81. New York: Raven Press, 1999: 371-7.
5. Jones-Gotman M, Zatorre RJ, Olivier A, *et al.* Learning and retention of words and designs following excision from medial or lateral temporal-lobe structures. *Neuropsychologia* 1997; 35: 963-73.
6. Frisk V, Milner B. The relationship of working memory to the immediate recall of stories following unilateral temporal or frontal lobectomy. *Neuropsychologia* 1990; 28: 121-35.
7. Hermann BP, Wyler AR, Somes G, *et al.* Declarative memory following anterior temporal lobectomy in humans. *Behav Neurosci* 1994; 108: 3-10.
8. Rausch R, and Babb TL. Hippocampal neuron loss and memory scores before and after temporal lobe surgery for epilepsy. *Arch Neurol* 1993; 50: 812-7.
9. Saling MM, Berkovic SF, O'Shea MF, *et al.* Lateralization of verbal memory and unilateral hippocampal sclerosis - Evidence of task-specific effects. *Journal of Clinical and Exp Neuropsychol* 1993; 15: 608-18.
10. Chelune GJ. *Using neuropsychological data to forecast post-surgical cognitive outcome*. In: H. Luders. *Epilepsy Surgery*. New York: Raven Press, 1991: 477-85.
11. Selwa LM, Berent S, Giordani B, *et al.* Serial cognitive testing in temporal lobe epilepsy: Longitudinal changes with medical and surgical therapies. *Epilepsia* 1994; 35: 743-9.
12. Paradiso S, Hermann BP, Blumer D, *et al.* Impact of depressed mood on neuropsychological status in temporal lobe epilepsy. *J Neurol Neurosurg Psyc* 2001; 70: 180-5.
13. Hermann BP, Wyler AR, Somes G, *et al.* Pathological status of the mesial temporal lobe predicts memory outcome from left anterior temporal lobectomy. *Neurosurgery* 1992; 31: 656-7.
14. Morris RG, Abrahamas S, Polkey CE. Recognition memory for words and faces following unilateral temporal lobectomy. *Br J Clin Psych* 1995; 34: 571-6.
15. Wieser HG, Muller S, Schiess R, *et al.* The anterior and posterior selective temporal lobe amobarbital tests: angiographic, clinical, electroencephalographic, PET, SPECT findings, and memory performance. *Brain Cogn* 1997; 33: 71-97.
16. Blake RV, Wroe SJ, Breen EK, *et al.* Accelerated forgetting in patients with epilepsy - Evidence for an impairment in memory consolidation. *Brain* 2000; 123: 472-83.