

# Induction of epileptic negative myoclonus by oxcarbazepine in symptomatic epilepsy

Andreas Hahn<sup>1</sup>, Anke Fischenbeck<sup>2</sup>, Ulrich Stephani<sup>2</sup>

<sup>1</sup> Department of Neuropediatrics, University of Giessen

<sup>2</sup> Department of Neuropediatrics, University of Kiel, Germany

Received June 7, 2004; Accepted for publication August 31, 2004

**ABSTRACT** – Provocation of various seizure types including epileptic negative myoclonus and generalised atonic seizures is rarely observed in children treated with carbamazepine (CBZ). Provocation of the latter seizure types by oxcarbazepine (OXC) is not described in the literature. We report a four year-old boy with symptomatic epilepsy caused by left-sided cerebral atrophy of unknown origin who developed numerous daily drop attacks when exposed to OXC. Polygraphic analysis revealed secondary generalised precentral sharp-slow waves frequently associated with a silent period lasting for 100-150 ms in the electromyogram recorded from the deltoid and neck muscles. These seizures stopped promptly within 36 hours after discontinuation of OXC. This case demonstrates that OXC, similar to CBZ, can provoke epileptic negative myoclonus in some children with focal epilepsies. [Published with videosequences]

**KEYWORDS:** oxcarbazepine, carbamazepine, seizure provocation, atonic-astatic seizures, epileptic negative myoclonus

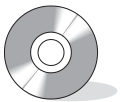
Oxcarbazepine (OXC) is a highly efficacious drug for the treatment of partial seizures and is structurally closely related to carbamazepine (CBZ). Activation of epileptic discharges, aggravation of seizures, and induction of new seizure types caused by CBZ-medication have been observed at therapeutic drug levels in children with partial epilepsies [1-3].

Epileptic negative myoclonus (ENM) is a recently recognised seizure type that can be interpreted as a focal variant of generalised atonic-astatic seizures [4, 5]. Video-polygraphic studies revealed brief pauses in the electromyogram (EMG) corresponding to focal or generalised spike-/sharp slow wave discharges in the EEG in both seizure types [4, 5]. Provocation in children treated with CBZ has been observed [1, 2].

Provocation of ENM or generalised atonic-astatic seizures by OXC has not yet been described. We report a four-year-old boy with secondary generalised tonic-clonic seizures (GTCS) due to symptomatic left-hemispheric epilepsy, who developed reversible ENM during OXC therapy.

## Case report

The boy was born spontaneously after an uneventful pregnancy at term. Family history for epilepsy was negative. Delivery was complicated by shoulder dystokia. At age 12 months, he was referred to our department because of developmental delay. Neurological examination revealed a right-sided hemiparesis and MRI demonstrated atrophy of the left hemisphere with preponderance of the



## Correspondence:

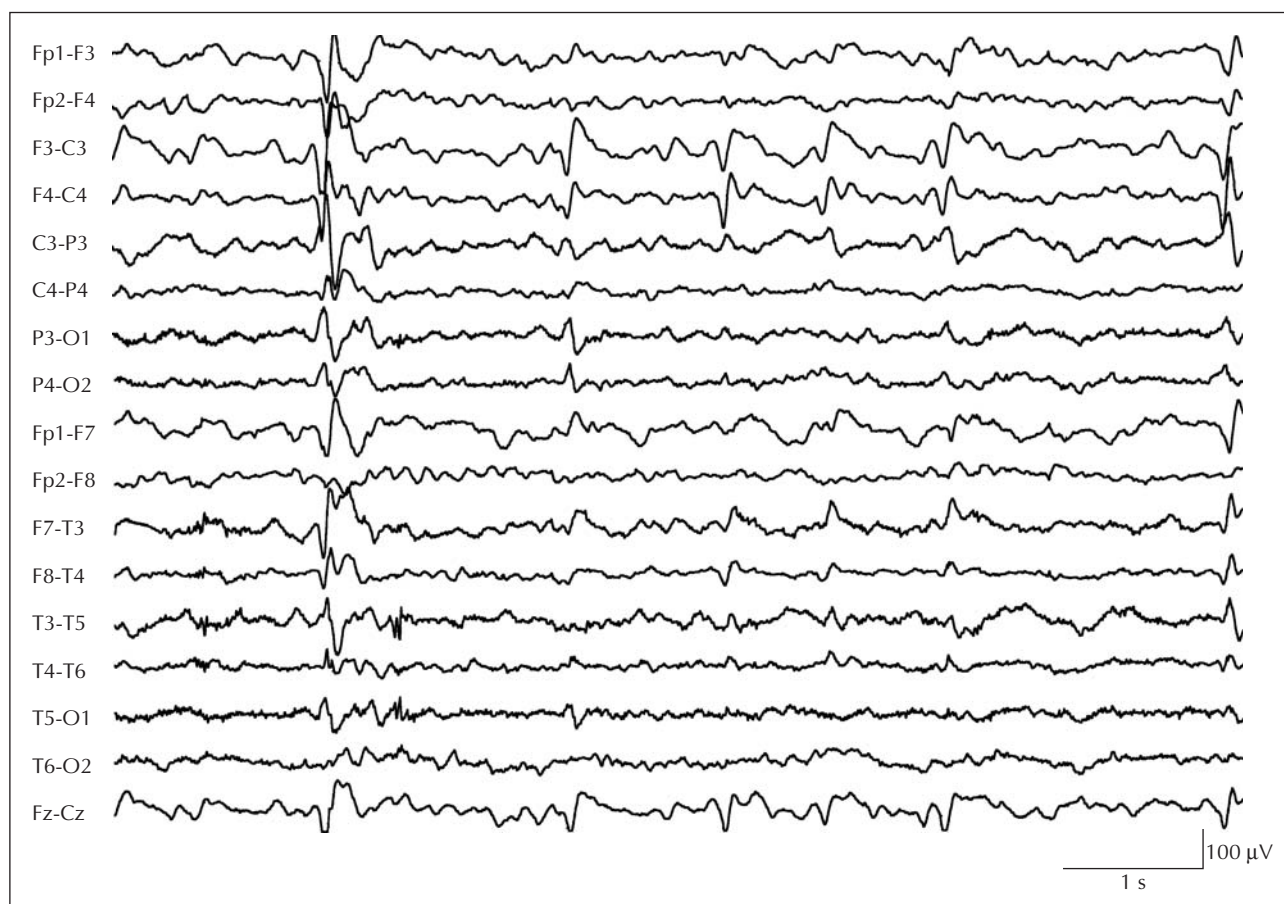A. Hahn, MD,  
Department of Neuropediatrics,  
University of Giessen,  
Feulgenstr, 12, 35385 Giessen, Germany  
Telephone: + 49-641-9943497  
Fax: +49-641-9943489.  
<andreas.hahn@paediat.med.uni-giessen.de>

fronto-temporal region. At this time, the EEG was normal. At age 3 1/2 years, he suffered two nocturnal GTCS. The EEG displayed left-sided slowing and bilateral precentral sharp slow waves. Antiepileptic treatment with sulthiame (STM) was initiated and led to a distinct reduction of the epileptic discharges.

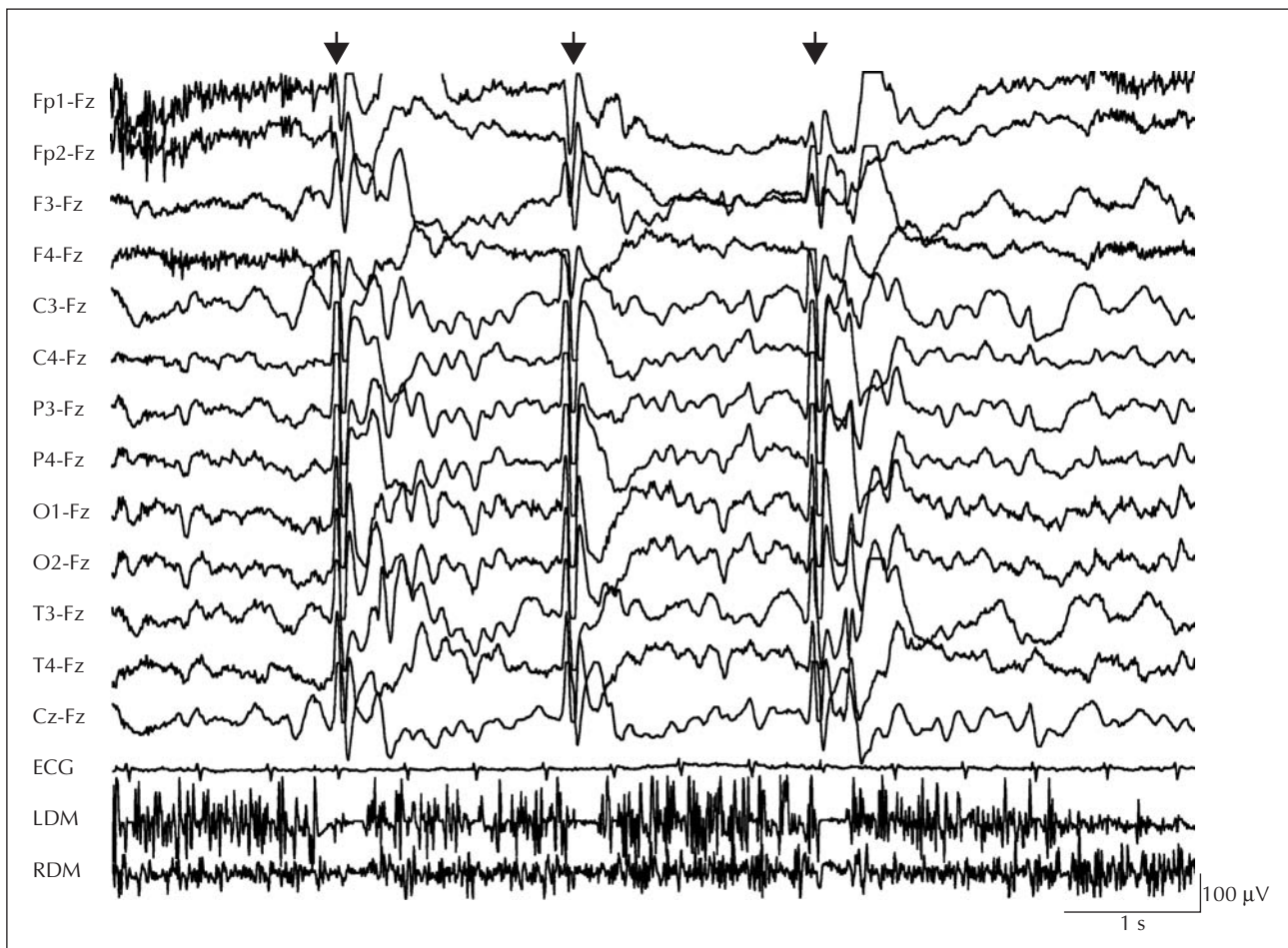
At age 4 1/2 years, he experienced several further nocturnal generalised seizures, sometimes starting with myoclonia of the right hand and face. Again, the EEG demonstrated left-sided slowing and bilateral precentral sharp-slow-waves with rare secondary generalisation. At sleep, distinct activation, but no electrical status epilepticus during slow sleep (ESES) was found. Valproic acid (VPA) (25 mg/kg body weight) was added to STM. Two weeks later, the patient was re-admitted for video telemetric analysis to assess the effect of VPA co-medication. The EEG showed no clear improvement (*figure 1*) and two nocturnal GTCS were registered. Therefore, STM was discontinued and OXC was added to VPA. OXC was tapered in over 2 1/2 weeks starting at 5 mg/kg body weight and increased every four days by 5 mg/kg body weight. At a dosage of 25 mg/kg body weight, numerous daily drop attacks occurred (10-

OH-carbazepine serum level 15.4 mg/l). Video telemetric analysis was repeated, now demonstrating a marked increase of generalised sharp slow-waves, often accompanied by nodding of the head and dropping of both arms, without clear impairment of consciousness. Frequently, generalised sharp slow waves were associated with silent periods in the EMG from the deltoid and neck muscles lasting for 100-150 ms (*figure 2* and *video sequence*). These attacks were classified as ENM. During sleep, a marked activation of epileptic discharges up to a discontinuous generalized sharp-slow-wave activity was recorded. OXC was discontinued and ENM disappeared within 36 hours after withdrawal of OXC. A few days after cessation of ENM, clobazam was added and resulted in a marked reduction of the epileptic discharges. The boy remained seizure-free on VPA and clobazam for five months. Then, partial oromotor seizures were noticed. Clobazam was replaced by ethosuximide, and lamotrigine was also added leading to remission of seizures for more than one year.

At age 6 1/2 years, VPA was tapered off. Four months later, partial motor seizures of the right hand and nocturnal



**Figure 1.** EEG while awake during therapy with sulthiame and valproate showing left-sided slowing and bilateral precentral sharp slow waves with generalisation.



**Figure 2.** EEG while awake after institution of oxcarbazepine and replacement of sulthiame showing frequent generalisation of epileptic discharges. Arrows mark epileptic negative myoclonus (ENM). The sharp wave component is accompanied by a silent period in the EMG of the right (RDM) and left deltoid muscle (LDM) lasting for approximately 100-150 ms. ECG = electrocardiogram.

GTCS returned accompanied by a marked deterioration of the EEG with a discontinuous generalized sharp-slow-wave activity during sleep. This situation is presently unchanged.

## Discussion

Paradoxical worsening of epilepsy caused by treatment with an antiepileptic drug is not infrequent [3]. Aggravation of seizures, induction of new seizure types and activation of epileptic discharges due to CBZ in patients with partial epilepsies was first described by Shields and Saslow in 1983 [1]. The main seizure types provoked are myoclonic seizures, atonic seizures and atypical absences [1-3]. Induction of tonic seizures has never been observed. Recently, provocation of ENM by CBZ has also been described [2]. Only rarely, has the exact seizure type provoked by CBZ been confirmed by video-polygraphic studies [2].

OXC (10,11-dihydro-10-oxo-carbamazepine) is structurally closely related to CBZ. It is metabolised rapidly and completely to an active 10-monohydroxy compound without an epoxide intermediate. Pharmacological studies comparing OXC and CBZ have shown a similar efficacy for treatment of partial epilepsies, but with a lower rate of allergic side effects for OXC. Therefore, some authors recommend OXC as first line drug in children with focal epilepsies [6].

Our patient suffered from nocturnal GTCS due to symptomatic focal epilepsy. ENM occurred when OXC therapy was initialised and disappeared when OXC was discontinued. In addition, secondary generalised sharp slow waves were markedly activated up to a discontinuous bioelectrical status during sleep that was not present before treatment with OXC. Escalation and dosage of OXC were correctly chosen and overdosage could be excluded in view of the appropriate 10-OH-carbamazepine serum levels. Although STM was withdrawn at the beginning of OXC

therapy and the boy was not re-exposed to OXC, we believe that these observations clearly demonstrate that ENM was provoked by an inverse pharmacodynamic effect of OXC [3].

To our knowledge, this is the first report describing induction of ENM in a patient treated with OXC. Because of their structural similarity and their similar pharmacodynamic mechanisms, it may be assumed that both, OXC and CBZ can provoke seizures in some subjects with focal epilepsies. Deterioration of epilepsy with CBZ has been reported in patients with lesion-related epilepsy, benign childhood epilepsy with centrotemporal spikes (BECTS), atypical benign partial epilepsy, Landau-Kleffner syndrome and ESES, demonstrating that this incident is not confined to a single type of epilepsy [1-3].

As in our patient, secondary generalised sharp slow waves and activation of epileptic discharges by sleep before treatment with CBZ have been identified as major risk factors for aggravation of epilepsy by CBZ [3]. In addition to worsening of a pre-existing epilepsy, an atypical evolution of epilepsy into an ESES with associated severe neuropsychological deficit has been reported in five patients with classical BECTS when treated with CBZ [7]. In our patient, activation and generalisation of epileptic discharges during sleep was a prominent finding before and after OXC therapy. Therefore, this case resembles a group of patients with multilobar polymicrogyria, drop attacks and sleep-related electrical status epilepticus described by Guerrini *et al.* [8]. Similar to subjects with idiopathic ESES, these children had a good seizure outcome after cessation of ESES despite cortical malformation [8].

ENM is characterised by a short lapse of postural tone or an involuntary interruption of tonic muscle contraction time-locked to a spike-/sharp slow wave complex in the contralateral sensorimotor cortex [4]. Simultaneous registration of the EMG reveals a brief pause of electric activity lasting for 100-400 ms in corresponding muscles [4, 5]. Typically, dropping of one arm is observed when the patient is asked to hold the arms outstretched. Usually, consciousness is not impaired [4, 5]. Precentral (supplementary motor, premotor and primary motor areas) as well as postcentral cortical structures are suspected of being involved in the generation of ENM [5, 9]. As observed in our patient, spreading of epileptic discharges over both central regions has been shown to result in the dropping of both arms and the head [4]. Generalisation of spike-/sharp slow waves accompanied by a prolonged silent period in the EMG up to 400 ms was found to be associated with a generalised atonic-astatic seizure [5]. Simultaneous occurrence of ENM and generalised atonic-astatic seizures in the same patient depending on the extent of the epileptic activity has been observed [5]. As in our patient, a clear-cut differentiation between these two seizure types may be difficult.

The mechanisms causing provocation of ENM by CBZ and OXC are equivocal. However, it has been suggested that

the mechanisms provoking ENM are parallel to those underlying absence seizures [5]. In absence seizures, it is assumed that rhythmic alteration of excitation and inhibition in cortical neurons transiently interferes with cortical function. Such transient arrests in cortical function are mainly caused by inhibitory postsynaptic potentials [10]. Therefore, treatment with CBZ or OXC in some patients with focal epilepsy could activate localised or provoke generalised epileptic activity that transiently interferes with cortical motor outflow and results in interruption of sustained muscle contraction. □

**Acknowledgements.** We thank Heike Wagner and Ralf Berger for their careful help in preparation of the video sequence.

### Legend for video sequences

EEG of the patient while painting, during therapy with VPA and OXC. Frequent generalisation of sharp slow waves occurs. Numerous ENM seizures are registered. Notice silent electrical periods of approximately 100-150 ms, best seen in the EMG of the left deltoid muscle time-locked to the sharp slow waves. The term "Nacken" corresponds to neck muscles

### References

1. Shields WD, Saslow E. Myoclonic, atonic and absences seizures following institution of carbamazepine therapy in children. *Neurology* 1983; 33: 1487-922.
2. Nanba Y, Maegaki Y. Epileptic negative myoclonus induced by carbamazepine in a child with BECTS. *Pediatr Neurol* 1999; 21: 664-73.
3. Genton P. When antiepileptic drugs aggravate epilepsy. *Brain Dev* 2000; 22: 75-8044.
4. Guerrini R, Dravet C, Genton P, *et al.* Epileptic negative myoclonus. *Neurology* 1993; 43: 1076-8355.
5. Oguni H, Uehara T, Tanaka T, Sunahar M, Hara M, Osawa M. Dramatic effect of ethosuximide on epileptic negative myoclonus: implications for the neurophysiological mechanisms. *Neuropediatrics* 1998; 29: 29-346.
6. Glauser TA. Expanding first-line therapy options for children with partial seizures. *Neurology* 2000; 55(Suppl 3): S30-S377.
7. Prats JM, Garaizar C, García-Nieto ML, Madoz P. Antiepileptic drugs and atypical evolution of idiopathic partial epilepsy. *Pediatr Neurol* 1998; 18: 402-68.
8. Guerrini R, Genton P, Bureau M, *et al.* Multilobar polymicrogyria, intractable drop attack seizures, and sleep-related electrical status epilepticus. *Neurology* 1998; 51: 129-504.
9. Noachtar S, Holthausen H, Lüders HO. Epileptic negative myoclonus. Subdural EEG recordings indicate a postcentral generator. *Neurology* 1997; 49: 1534-710.
10. Gloor P. Generalised epilepsy with spike-and-wave discharge: a reinterpretation of its electrographic and clinical manifestations. *Epilepsia* 1979; 20: 571-88.