

Ictal video-polysomnography and EEG spectral analysis in a child with severe Panayiotopoulos syndrome

Pasquale Parisi^{1,2}, Raffaele Ferri³, Jacopo Pagani²,
Manuela Cecili², Enza Montemitro², Maria Pia Villa²

¹ Child Neurology Unit,

² Pediatric Sleep Centre, University of Rome "La Sapienza", II faculty of Medicine, "Sant'Andrea" Hospital, Rome

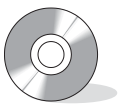³ Sleep Research Centre, Department of Neurology I.C., Oasi Institute for Research on Mental Retardation and Brain Aging (IRCCS), Troina, Italy

Received April 19, 2005; Accepted September 9, 2005

ABSTRACT – Objective. To describe the ictal polysomnographic features of a patient with Panayiotopoulos syndrome, a peculiar epileptic syndrome characterized by infrequent, often single, prolonged, nocturnal, focal seizures comprising an unusual constellation of autonomic symptoms (malaise, nausea, pallor, tachycardia, vomiting) and unilateral deviation of the eyes at the onset of seizures. These clinical, ictal manifestations are rarely followed by post-ictal headache. In the literature, there is little information on the ictal EEG characteristics of Panayiotopoulos syndrome and, in particular, on certain autonomic manifestations, such as tachycardia, as the sole ictal phenomena at the onset of seizures. **Methods and results.** One, all-night videopolysomnography, during which one seizure was recorded. Video-EEG data were evaluated visually and by means of quantitative spectral analysis. The spectral analysis of the recorded seizure showed a complex ictal pattern of cortical involvement with focal onset in the right occipital area followed by the recruitment of widespread extra-occipital cortical regions. **Conclusions.** This is the first such analysis of this peculiar epileptic condition. Most of the symptoms were consistent with a diagnosis of severe Panayiotopoulos syndrome, although the patient also presented "atypical findings": a relatively high frequency of seizures, post-ictal headache, no spontaneous remission of seizures with age, and late onset of visual hallucinations; this last finding is more frequent in "Gastaut-type childhood occipital epilepsy", in which onset typically occurs later than in Panayiotopoulos syndrome.

[Published with video sequences]

Key words: Panayiotopoulos syndrome, sleep videopolysomnography, ictal EEG, EEG spectral analysis, compressed spectral array, idiopathic occipital epilepsy



Correspondence:

P. Parisi
Child Neurology Unit and Pediatric Sleep
Centre, Pediatric Department, "Sant'
Andrea" Hospital, Via di Grottarossa, 1035-
1039 00189, Rome,
Italy
Tel.: (+ 00 39) 06 80 345 277;
fax: (+ 00 39) 06 80 345 941.
<parpas@iol.it>

Panayiotopoulos syndrome (PS) is a recently recognised, common childhood idiopathic susceptibility to focal, mainly autonomic, seizures and auto-

nomic status epilepticus (Panayiotopoulos 1988, Caraballo *et al.* 2000, Ferrie and Grunewald 2001, Koutroumanidis 2002, Panayiotopoulos 2002,

Lada *et al.* 2003, Ohtsu *et al.* 2003, Covanis *et al.* 2003, Demirbilek and Dervent 2004, Sanders *et al.* 2004, Panayiotopoulos 2005). Seizures comprise an unusual constellation of autonomic, particularly emetic, symptoms, behavioural changes, unilateral deviation of the eyes, and other more conventional ictal manifestations such as convulsions. Consciousness and speech, as a rule, are preserved at seizure onset but often become impaired as the attacks progress. Seizures commonly start with autonomic manifestations (81%), which are mainly emetic (72%). All functions of the autonomic system may be affected during the seizure, though emesis is the most prominent. Two thirds of seizures occur during sleep, with nearly half lasting between 30 minutes and several hours, thus constituting autonomic status epilepticus.

Age at onset is 1-14 years, with a peak at 4-5 years; in 76% of cases, onset occurs at 3-6 years of age. Boys and girls are equally affected (Panayiotopoulos 2002). Prevalence is around 13% in 3- to 6-years-old children who have had one or more non-febrile seizures, and 6% in the 1 to 15-years age group. In the general population, 2-3/1000 children are affected. These figures may be higher if cases currently considered to have atypical features are included (Panayiotopoulos 2002, Panayiotopoulos 2005).

Affected children have a normal physical and neuropsychological development. Prognosis is usually excellent, with one third having a single seizure.

A major problem with PS is that misdiagnosis is common because seizures often imitate non-epileptic conditions such as migraine, cardiogenic syncope, encephalitis, gastroenteritis, cyclic vomiting syndrome and sleep-related paroxysmal disorder, which explains why PS initially escaped recognition.

In the last decade, numerous studies have clarified the differences between PS and Gastaut-type childhood occipital epilepsy (GTCOE) (Gastaut 1982). The ictal visual symptoms (multicoloured or spherical pattern as opposed to the predominantly black and white linear patterns of migraine) typical of GTCOE are rarely present (< 5%) in PS-affected patients (Lada *et al.* 2003). As prognosis is always benign in PS although not in GTCOE, differential diagnosis is important.

EEG is the most important procedure in the diagnosis of PS. In about 90% of cases, the EEG reveals functional, mainly multi-focal, high amplitude sharp-slow wave complexes which, in order of prevalence, most commonly occur in the occipital, frontal and centroparietal regions; the right and left hemispheres are equally involved. Ictal EEG is rare: only 4 cases exist of "typical" PS video-EEGs of seizures with frontal or posterior onset (Oguni *et al.* 1999, Vigeveno *et al.* 2000, Panayiotopoulos 2004, Demirbilek and Dervent 2004). No video-polysomnography (VPSG) of a PS seizure has previously been documented.

We describe a child with severe PS who had a seizure during an all-night VPSG.

Case report

Clinical assessment

An 8-years-old, Italian boy was referred to us because of "headache and paroxysmal sleep disorder". There was no family history of epilepsy or migraine. His two brothers and one sister are all normal. Birth, and neurological and psychomotor development were normal. Weight at birth was 3.48 kg, head circumference 35 cm, and length 52 cm.

At the age of three years, he started suffering from nocturnal attacks consisting of pallor, vomiting and a mild impairment of consciousness followed by severe headache. There were no visual symptoms or convulsions. The attacks occurred exclusively during sleep, at roughly the same time in the early morning (between 5 and 6.30 a.m.), lasted for 5-20 minutes and had a frequency of one or two per month.

The child also had monthly episodes of severe headache with clinical characteristics of migraine without aura, which occurred in the morning or early afternoon, independently of his habitual nocturnal attacks.

Furthermore, from the age of seven years the boy experienced three diurnal visual seizures of multicoloured, spherical hallucinations, each lasting 10-30 seconds. Several EEGs performed between three and eight years of age had been reported to be normal and his condition was diagnosed as migraine and paroxysmal sleep disorder. He is currently attending a mainstream school with satisfactory scholastic results.

Upon referral to us, the awake-EEG interictal features included right occipital spikes as fixation-off sensitivity phenomena, whereas photosensitivity was not observed. Right occipital spikes appeared during sleep, particularly in sleep stages 1 and 2 (see all night video-polysomnography and ictal video-polysomnography below) and even more so in the pre-ictal period (see video sequence).

Both the neurological and mental state (IQ = 106, at full scale of the WISC-R) were normal. Brain CT scan and MRI were also normal. Haematological, biochemical and metabolic investigations were negative.

All night video-polysomnography

Method

All night, standard video-polysomnography was performed using a Grass multi-channel recording system (Grass Instruments, Quincy, Mass, USA) with video (Panasonic Camera WV-BP334, Secaucus, NJ, USA). Polygraphic recording included scalp EEG, (8 channels), ECG, electro-oculogram, chin electromyogram, nasal and oral airflow, respiratory effort, abdominal movement and arterial oxygen saturation. Sleep was scored visually, according to international criteria (Rechtschaffen and Kales 1968).

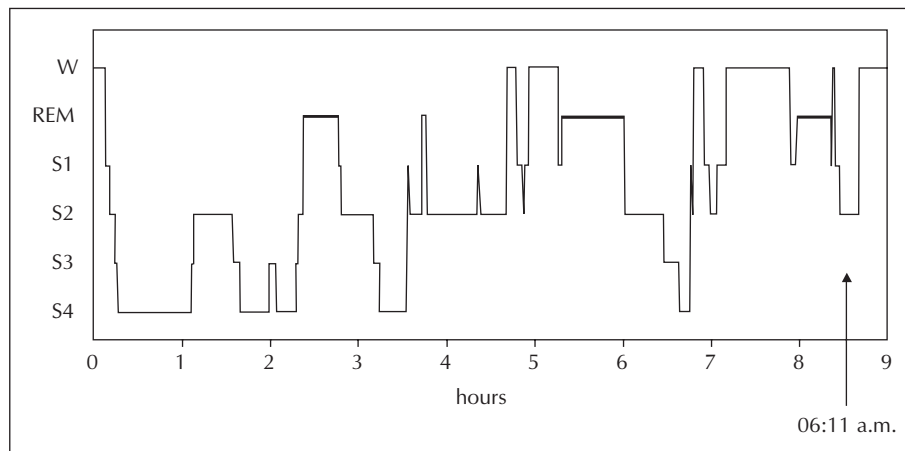


Figure 1. Hypnogram of the polysomnography; time when seizure occurred is also indicated (arrow).

Spectral EEG analysis

The signals were acquired digitally and stored in European Data Format (Kemp *et al.* 1992) for the subsequent spectral EEG analysis. Power spectra were calculated for each channel using the sleep analysis software Hypnolab 1.2 (SWS Soft, Italy), after Welch windowing, by means of the Fast Fourier Transform (Cooley and Tukey 1965), on 30-second epochs immediately before and during the ictal episode. Individual spectra were obtained in the 0-15 Hz frequency range and plotted sequentially, for each channel, in order to detect any changes during the period under study; this procedure is known as *Compressed Spectral Array* (Bickford *et al.* 1972).

Results

Figure 1 and table 1 show the results of the sleep structure analysis in the patient. Figure 1 also indicates (arrow) when the seizure occurred.

There were 2.4 movement arousal events per hour, no respiratory obstructive events, 0.6 central apnea events per hour and a mean SaO₂ of 98.5%.

Ictal videopolysomnographic findings

The videopolysomnography showed interictal spikes, sharp-waves and spike-and-wave complexes, involving above all the right occipital region that increased markedly in number during sleep stages 1 and 2 in the pre-ictal period.

The ictal episode started at 6:11:16 a.m., during sleep stage 2 (figure 2A), and lasted approximately 14 minutes. The seizure started as an electrical partial seizure, with minimal clinical manifestations (a movement in the left arm at onset), tachycardia as the sole autonomic manifestation (HR = 120 b.p.m. at onset of seizure versus 80 b.p.m. before onset) and a run of fast spikes (at approximately 7 Hz) mainly involving the right occipital region. figure 2A shows the video-EEG of the onset of the seizure with the associated transient tachycardia, while figure 3

clearly shows the peak at around 7 Hz in the power spectrum of O2 only at the onset of the seizure.

After the start of the seizure, for approximately 10 minutes the patient did not display any clinical manifestations other than the tachycardia described above (figure 2A); during this period, the EEG showed the persisting spike-and-wave activity at 3 Hz, initially located almost exclusively in the right occipital region (figure 2B) before progressively involving all the other EEG derivations after a few minutes (figure 3).

Ten minutes after the onset of the seizure, a tonic conjugate deviation of the eyes to the left (time 6:21:16; see video sequence) started and lasted approximately 2 min; this motor phenomenon was accompanied on the EEG by numerous high-amplitude slow waves in the theta and

Table 1. Results of all-night, polygraphic sleep recording.

Time in bed (min)	540
Time spent asleep (min)	503
Total time asleep (min)	433
Sleep efficiency (%)	80.2
Sleep onset (min)	8
REM latency (min)	135
Wakefulness after sleep onset (min)	80
Sleep stage 1 (min)	34.5
Sleep stage 2 (min)	165.5
Sleep stage 3 (min)	28
Sleep stage 4 (min)	110
REM sleep (min)	85
Wakefulness after sleep onset (%)	15.9
Sleep stage 1 (%)	6.8
Sleep stage 2 (%)	32.9
Sleep stage 3 (%)	5.6
Sleep stage 4 (%)	21.9
REM sleep (%)	16.9

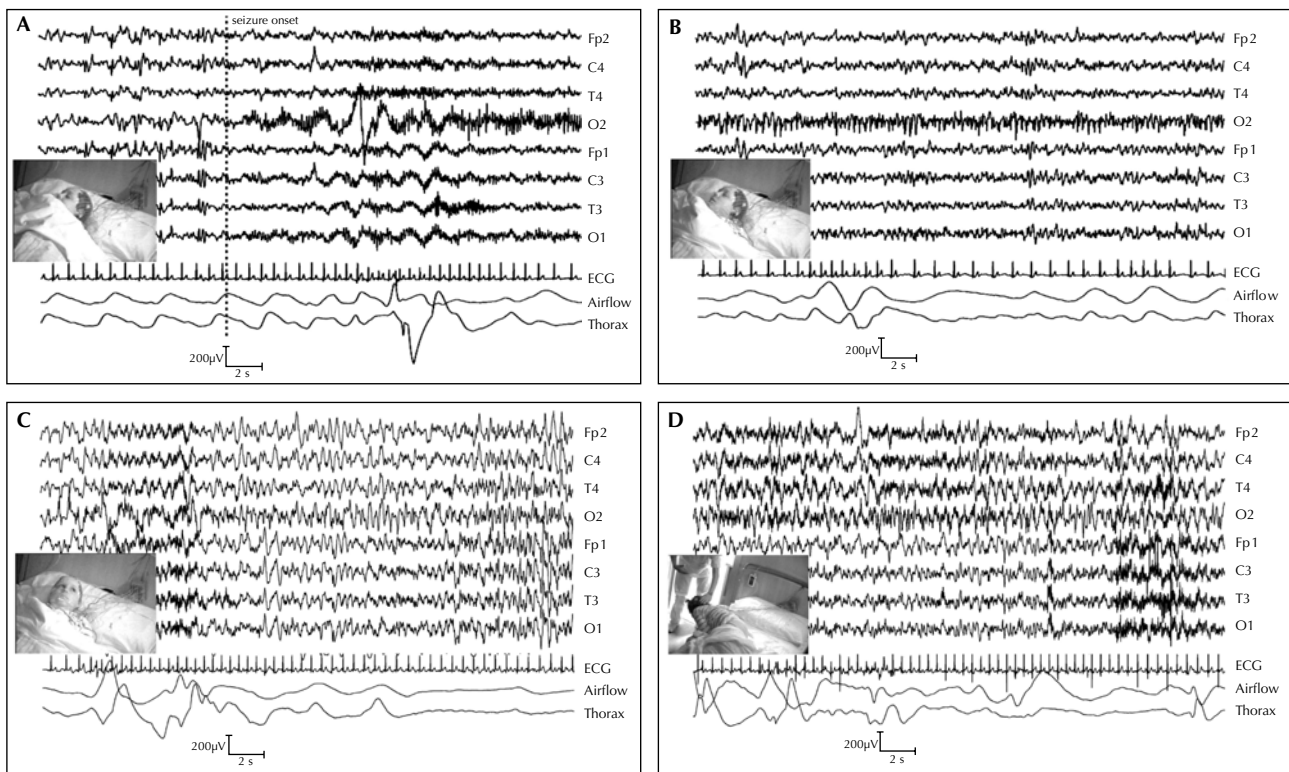


Figure 2. Video-EEG study of the seizure. **A)** Seizure onset with a run of fast spikes (at approx. 7 Hz), mainly involving the right occipital region; a clear increase in heart rate is evident together with irregular breathing. **B)** Spike-and-wave activity at 3 Hz, initially located almost exclusively in the right occipital region; heart rate irregularities correlate with irregular breathing. **C)** Tonic conjugate deviation of the eyes to the left, accompanied by high-amplitude slow waves in the theta and delta range intermixed with more rapid activity and increased heart rate. **D)** Same type of EEG activity and heart rate during vomiting.

delta range, intermixed with more rapid activity (figure 2C). This was also evident at the spectral EEG analysis with the onset of large peaks in the 0–6 Hz range, evident in all the channels though slightly predominant in the frontal regions (figure 3).

The same EEG activity was evident during the last two minutes of the seizure, when vomiting occurred (time 6:22:16 to 6:24:46) (figure 2D, figure 3 and video sequence). Repetitive vomiting occurred 11 minutes after the onset of the electrical discharge (see video sequence: time 6:22:16 to 6:24:46). After vomiting, the low-amplitude high-frequency components evident in O2 throughout the ictal episode suddenly disappeared and the spectra were characterized exclusively by the presence of post-ictal, low-frequency components, prevalently in the frontal regions (figure 3).

Consciousness was only partially impaired during the seizure (after the eye deviation): when interviewed, the patient was in contact but was unable to answer questions adequately. After the onset of the tonic deviation of the eyes, the boy was able to voluntarily direct his eyes in all

directions, although visual gaze intermittently deviated to the left when not fixed on a target.

The seizure ended abruptly at 6:25 a.m.; there were no neurological deficits, although the child complained of a severe headache.

The entire seizure is shown in the video PSG clip (see video sequence).

To sum up, the ictal episode started at 6:11:16 a.m. as an autonomic (tachycardia) partial seizure (time 6:11:16 to 6:21:16); left tonic eye deviation was observed at 6:21:16 and lasted about 1 minute; repetitive ictal vomiting occurred from 6:22:16 to 6:24:46; the seizure ended abruptly at 6:25 (see figure 2A,B,C,D, figure 3, and video sequence).

Follow-up

Treatment with valproic acid (20 mg/Kg/die) was initiated after the diagnosis of PS was made at the age of 8. This has, to date, resulted in the complete disappearance of any paroxysmal clinical events, including headache (follow-up: 12 months).

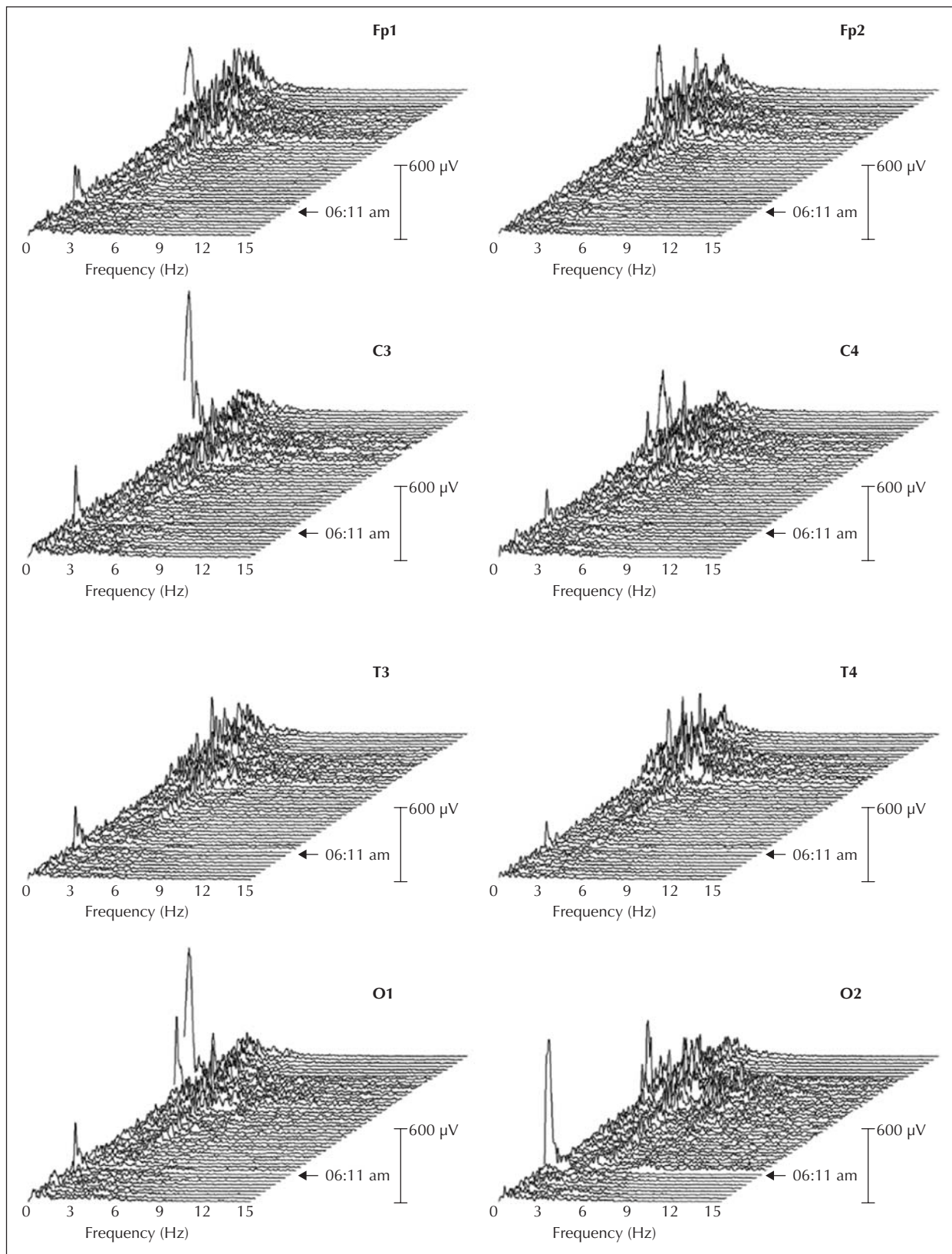


Figure 3. Compressed spectral array obtained for each EEG electrode during the seizure; each spectrum corresponds to an epoch of 30 seconds.

Discussion

Despite its high prevalence and striking clinical manifestations, PS remains practically unknown among general pediatricians; this lack of awareness leads to a high number of misdiagnoses which, in turn, lead to avoidable morbidity and costly hospital admissions.

The clinical pattern of PS is characterized by a number of findings (Panayiotopoulos 1988, Caraballo *et al.* 2000, Ferrie and Grunewald 2001, Koutroumanidis 2002, Panayiotopoulos 2002, Lada *et al.* 2003, Ohtsu *et al.* 2003, Covanis *et al.* 2003, Demirbilek and Dervent 2004, Sanders *et al.* 2004, Panayiotopoulos 2005): age at onset from two to five years; a family history of epilepsy (30%) or migraine (10%) is rare; nocturnal seizures, tonic deviation of the eyes and vomiting are the distinctive ictal clinical triad of the syndrome; consciousness is usually disturbed, but may be preserved throughout the episode; the seizure manifestations may progress to hemiconvulsion or generalized tonic-clonic convulsion, duration of which ranges from seven minutes to three hours, although usually averages 10 to 15 minutes; the recurrence of seizures is remarkably low (1 to 6 seizures), though only one seizure is usually observed; prognosis appears to be excellent, with a complete recovery being made one or two years after onset; neuroradiological and laboratory investigations are usually normal; EEG findings frequently display occipital spikes (67% of cases), often associated with fixation-off sensitivity phenomena (35% of cases) (Lada *et al.* 2003, Panayiotopoulos 2005).

For the purposes of the differential diagnosis between PS and GTCOE, the latter is, as described in 1982, characterized by partial seizures with elementary ictal visual symptoms (often spherical, multicoloured hallucinations) frequently associated with other ictal phenomena (loss of vision, nausea, vomiting), followed by post-ictal headache (33% of cases), often associated with interictal occipital rhythmic paroxysmal EEG activity that only appears after eye closure (Andermann and Zifkin 1998, Panayiotopoulos 2005); the frequency of the seizures (which usually occur during the day) is high, secondary generalization or hemiconvulsion also being frequent; prognosis is sometimes unfavourable.

At onset (at the age of three), most of the symptoms in our patient were consistent with a diagnosis of severe PS, although he also presented a relatively high frequency of seizures (1-2/month) and post-ictal headache. The late onset of visual hallucinations (spherical, multicoloured pattern lasting 20-30 sec.), which was referred sporadically (three episodes from the age of seven years), constitutes the third atypical finding in our case; an additional atypical finding was the lack of spontaneous recovery (complete remission is usually achieved within two years of onset in PS); lastly, secondary generalization never

occurred in our patient (it typically occurs in 51% of PS). By contrast, in the series of 43 patients recently reported by Lada *et al.* (2003), three cases displayed "atypical" features, which led to the authors of that study acknowledging the need for further studies to assess atypical cases. Other authors (Ferrie *et al.* 1997, Ferrie and Grunewald 2001, Lada *et al.* 2003, Andermann and Zifkin 1998) have previously suggested that the lack of visual symptoms in PS might be due to the young age of the patients who, as is the case for the visual manifestations, are unable to describe such symptoms. This is, however, unlikely in our case because consciousness alone was mildly impaired during the nocturnal seizures, with the visual symptoms, which only occurred three times and always during the day, being referred to only from the age of seven years, never before this age.

The spectral analysis of the ictal episode performed in our patient clearly shows that his seizure was characterized by a complex pattern of cortical involvement, with an initial focal involvement of the right occipital areas followed by the recruitment of widespread extra-occipital cortical regions. This progressive involvement of wider cortical areas might explain the complex symptomatology of the seizure. Our study is the first to perform such an analysis in this peculiar epileptic syndrome.

Despite the occurrence of relatively frequent and prolonged seizures (≥ 10 -15 min) or several possible episodes of "partial electrical status epilepticus", the sleep structure in our case seems to be fairly well preserved (*figure 1* and *table 1*); this might, however, be due to the time at which the seizures occurred (usually at the end of the nocturnal sleep). The apparent lack of consequences on the cognitive functions is also worthy of note (Full scale of WISC-R: IQ = 106).

The ictal symptoms in our case, *i.e.* autonomic signs (tachycardia and vomiting) and eye deviation (Panayiotopoulos 2004, Panayiotopoulos 2005), do not seem differ from those of "typical" PS patients (Oguni *et al.* 1999, Vigeveno *et al.* 2000, Panayiotopoulos 2004, Demirbilek and Dervent 2004); by contrast, the other peri- or post-ictal clinical findings, particularly the clinical outcome, are clearly different.

As severe cases with frequent seizures have previously been reported (approximately 10% of cases with PS), and children with PS may develop other types of benign childhood focal seizures (mainly rolandic seizures and, more rarely, pure visual seizures of GTCOE) (Panayiotopoulos 2004, Panayiotopoulos 2005), patients such as the one in this paper should be considered and discussed from a "benign childhood seizure susceptibility syndrome" point of view. Benign childhood focal seizures and related epileptic syndromes are the commonest and probably the most fascinating and rewarding topic in pediatric epileptology (Panayiotopoulos 2004, Panayiotopoulos 2005).

Legend for video sequence

The entire seizure event is shown in the video-PSG-sequence. The ictal episode lasted nearly 14 minutes: it started at 6:11:16 a.m. as an autonomic (tachycardia) partial seizure (time 6:11:16 to 6:21:16); left tonic eye deviation was observed at 6:21:16 and lasted about 1 minute; repetitive ictal vomiting occurred from 6:22:16 to 6:24:46; the seizure ended abruptly at approximately 6.25 a.m.

Our patient yields enough evidence to classify him as a case of PS. Advances in molecular genetics might help clarify whether PS, GTCOE and other idiopathic childhood epilepsies are separate entities or represent a "syndromic continuum". □

References

- Andermann F, Zifkin B. The benign occipital epilepsies of childhood: an overview of the idiopathic syndromes and of the relationship to migraine. *Epilepsia* 1998; 39(Suppl 4): S9-S23.
- Bickford RG, Billinger TW, Fleming NI, *et al.* The compressed spectral array (CSA): A pictorial EEG. *Proc San Diego Biomed Symp* 1972; 11: 365-70.
- Caraballo R, Cersosimo R, Medina C, *et al.* Panayiotopoulos-type benign childhood occipital epilepsy: a prospective study. *Neurology* 2000; 55: 1096-100.
- Cooley JW, Tukey OW. An algorithm for the machine calculation of complex Fourier series. *Math Comput* 1965; 19: 297-301.
- Covanis A, Lada C, Skiadas K. Children with rolandic spikes and ictus emeticus: rolandic epilepsy or Panayiotopoulos syndrome? *Epileptic Disord* 2003; 5: 139-43.
- Demirbilek V, Dervent A. Panayiotopoulos syndrome: video-EEG illustration of a typical seizure. *Epileptic Disord* 2004; 6: 121-4.
- Ferrie CD, Beaumanoir A, Guerrini R, *et al.* Early-onset benign occipital seizure susceptibility syndrome. *Epilepsia* 1997; 38: 285-93.
- Ferrie CD, Grunewald RA. Panayiotopoulos syndrome: a common and benign childhood epilepsy. *Lancet* 2001; 357: 821-3; [Commentary].
- Gastaut H. A new type of epilepsy: benign partial epilepsy of childhood with occipital spike-waves. *Clin Electroencephalogr* 1982; 13: 13-22.
- Kemp B, Värri A, Rosa AC, *et al.* A simple format for exchange of digitized polygraphic recordings. *Electroencephalogr Clin Neurophysiol* 1992; 82: 391-3.
- Koutroumanidis M. Panayiotopoulos syndrome: a common benign but underdiagnosed and unexplored early childhood seizure syndrome. *BMJ* 2002; 324: 1228-9; [Editorial].
- Lada C, Skiadas K, Theodorou V, Covanis A. A study of 43 patients with Panayiotopoulos syndrome: A common and benign childhood seizure susceptibility. *Epilepsia* 2003; 44: 81-8.
- Oguni H, Hayashi K, Imai K, *et al.* Study on the early-onset variant of benign childhood epilepsy with occipital paroxysms otherwise described as early-onset benign occipital seizure susceptibility syndrome. *Epilepsia* 1999; 40: 1020-30.
- Ohtsu M, Oguni H, Hayashi K, *et al.* EEG in children with early-onset benign occipital seizure susceptibility syndrome: Panayiotopoulos syndrome. *Epilepsia* 2003; 44: 435-42.
- Panayiotopoulos CP. Vomiting as an ictal manifestation of epileptic seizures and syndromes. *J Neurol Neurosurg Psychiatr* 1988; 51: 1448-51.
- Panayiotopoulos CP. *Panayiotopoulos syndrome: A common and benign childhood epileptic syndrome*. London: John Libbey and Company, 2002.
- Panayiotopoulos CP. Autonomic seizures and autonomic status epilepticus peculiar to childhood: diagnosis and management. *Epilepsy Behav* 2004; 5: 286-95.
- Panayiotopoulos CP. Benign childhood focal seizures and related epileptic syndromes. In: Panayiotopoulos CP, ed. *The Epilepsies: Seizures, Syndromes and Management*. Oxford: Bladon Medical Publishing, 2005: 223-69.
- Rechtschaffen A, Kales A. *A manual of standardized terminology, techniques and scoring system of sleep stages of human subjects*. Washington Public Health Service. US Government Printing Office, 1968.
- Sanders S, Rowlinson S, Manidakis I, Ferrie CD, Koutroumanidis M. The contribution of the EEG technologists in the diagnosis of Panayiotopoulos syndrome (Susceptibility to early onset benign childhood autonomic seizures). *Seizure* 2004; 13: 565-73.
- Vigevano F, Lispi ML, Ricci S. Early onset benign occipital susceptibility syndrome: video-EEG documentation of an illustrative case. *Clin Neurophysiol* 2000; 111(Suppl 2): S81-S86.