

Ictal SPECT in a case of pure musicogenic epilepsy

Philippe Gelisse^{1, 2}, Pierre Thomas³, Raymond Padovani⁴,
Nathalie Hassan-Sebbag⁵, Jacques Pasquier⁵, Pierre Genton¹

¹ Centre Saint-Paul, Marseille, France

² Epilepsy Unit, Gui-de-Chauliac, CHU Montpellier, France

³ UF EEG/Epileptologie, Hôpital Pasteur, CHU Nice

⁴ Hôpital Saint-Joseph, Marseille

⁵ Department of Nuclear Medicine, Institut Paoli-Calmettes, Marseille

Received February 14, 2003; Accepted May 12, 2003

ABSTRACT – A 39-year-old, right-handed woman had seizures for two years which were always triggered by exposure to various types of music: the first occurred while she listened to a tune she particularly liked, *Con Te Partiro*, by Andrea Bocelli. Other triggering factors were various types of music such as supermarket background music and polyphonic singing or instrumental music played by family members. The seizures had a stereotyped course: she felt anxious, tearful, then occurred slight obtundation, during which she smacked her lips and moved restlessly. There was no complete loss of consciousness, but some degree of amnesia. She never experienced a generalized tonic-clonic seizure, but reported rare spontaneous feelings of *déjà-vu* that had begun at the same time as the induced seizures. There were no other spontaneous attacks; only one seizure was apparently provoked, not by music but by a loud background noise in her office. She was a music lover and a singer. Interictal EEG showed independent slow waves over the temporal regions. Several seizures with EEG localisation over the right temporal region were elicited after several minutes of exposure to music. Monoauricular stimulation with the same music produced a seizure when applied to the left ear but was ineffective when applied to the right ear. Ictal SPECT demonstrated right temporal hyperperfusion. MRI was normal. On high dose of carbamazepine, seizure frequency decreased. The addition of topiramate resulted in full seizure control. Musicogenic epilepsy is a rare form of reflex epilepsy. Pure cases, when patients do not experience unprovoked seizures, are exceptional. Our report confirms the implication of the right temporal lobe in this epilepsy. [Published with video sequence].

KEY WORDS: musicogenic epilepsy, temporal lobe epilepsy, reflex seizures, SPECT



Correspondence:

P. Genton, Centre Saint-Paul, 300 boulevard de Sainte-Marguerite, 13009 Marseille
E-mail: piergen@aol.com

Musicogenic epilepsy is a very rare form of complex reflex epilepsy [1]. It is characterized by seizures induced by music. We report on a woman with cryptogenic temporal lobe epilepsy in whom all the seizures were precipitated by music. Video-EEG and ictal SPECT were consistent with temporal lobe involvement.

Observation

A 39 year-old, right-handed woman was referred for the assessment of drug-resistant epilepsy. She complained of seizures which had begun two years earlier, persisted under treatment and had a very stereotyped and reproducible course. The first at-

tack occurred while she listened repeatedly to a tune she particularly liked, *Con Te Partiro*, by the Italian singer Andrea Bocelli. She had listened to that song many times before without problems. She then experienced scores of seizures, always as the result of at least several minutes of exposure to musical stimuli, but this delay had a tendency to become shorter. She also reported frequent feelings of *déjà vu*, that were associated with high anxiety that began at the same time as the seizures. Any type of singing, instrumental music, and even background music in the supermarket triggered seizures. Her family was musically active. She liked singing herself but did not play any instrument. Seizures could be triggered by her children playing their instruments, or by the polyphonic singing practiced by other family members, and it was painful for her to ask everybody to stop these activities in the home. At her office, she could no longer tolerate the slightest background music, and only once experienced a slight attack at work without music, which she ascribed to a loud background noise. If the stimulus stopped, the seizure ceased immediately. When in the supermarket, she was able to get out and the seizure stopped. She was highly distressed because of possible unexpected exposure to music outside her home, and because of the burden of deprivation of music in her home. Two typical seizures are presented on the video.

She was born at term to healthy, non-consanguineous parents with no family history of epilepsy or other neurological disorder. Her medical history revealed that she had been treated for an auto-immune thyroiditis with low-dose thyroxin for the past 5 years. At the age of 37, several months before seizure onset, she had a sudden, bilateral hypoacusia predominating in the right ear, for which she consulted a doctor, but for which she was given no precise diagnosis and no specific treatment: and the hypoacusia spontaneously disappeared within a few days. At admission, her general and neurological examination were normal without any abnormal psychological traits. Routine biological procedures were normal. Brain magnetic resonance imaging (sagittal T1-weighted imaging sequence, coronal T1, T2-weighted image and FLAIR through the hippocampus and the temporal lobe, axial T1 and T2-weighted imaging sequence), performed twice, showed no abnormality. She had received valproate (VPA) without effect, and had then been given carbamazepine (CBZ) 400 mg/d for 18 months, with slight improvement, then at 600 mg/d, with further abatement of seizures (fasting blood levels were then at 8 mg/l). However, she was still unable to listen to music for more than a short time without having a seizure.

Interictal EEG demonstrated the presence of independent theta slow waves or slow spikes over the temporal regions. A first seizure was elicited by a few minutes exposure to Verdi's *Nabucco* (video 1). The seizure started over the right anterior temporal leads and lasted about one minute (figure 1). The clinical attack consisted of anxiety, with

secondary clouding of consciousness and oro-alimentary automatisms. Another seizure was elicited when the music was applied to one ear only. The monoauricular application of music to the left ear produced a simple partial seizure, with a feeling of anxiety, and without any loss of contact, which ceased as soon as the music stopped. The application to the right ear was ineffective. An HMPAO-SPECT scan was performed during a complex partial seizure triggered by *Con Te Partiro* (video 2), and showed a right lateral hyperperfusion that corresponded to a propagation of the seizure (figure 2). Indeed, HMPAO was injected 41 seconds after seizure onset signalled by the patient (see legend of video 2), and 25 seconds after the onset of right temporal EEG changes.

On CBZ (1200 mg/day), seizure frequency decreased and she was able to slowly and cautiously reintroduce music into her life. Topiramate (150 mg/day) was then added. Five years after the onset of epilepsy, she has been seizure-free for more than two years, but still avoids exposure to music, which is a burden for her musically active family.

Discussion

Reflex epileptic seizures can be induced by auditory stimulation. There are several animal models with seizures induced specifically by very loud noise, but in these the stimulus is represented by the excessive loudness and the resulting seizures are wild running followed by convulsions [2]: these models do not have much in common with musicogenic epilepsy. In humans, the most common example of sound-induced seizures is found in startle epilepsy, a condition characterized by seizures induced by sudden and unexpected stimuli, such as contact or noise, usually in patients with extensive brain damage and hemiplegia [3]; the auditory stimulus is non-specific, surprise or suddenness being the critical element. Other effective auditory stimuli include voice, tone, frequency or sound-induced seizures such as a whirring or ringing machine. Musicogenic epilepsy is a particularly rare form of complex reflex epilepsy identified in 1937 by Critchley [1]. Wieser et al. (1997) reported, from the literature and their personal experience, 83 patients with musicogenic or tone/sound-induced seizure [4]. Of the 83 patients, 78% reported music was the only seizure-provoking stimulus, but most of these patients also had spontaneously occurring seizures. Four percent reported tone as the provoking stimulus. In 4%, it was sound and in 14% "all kinds of music and sounds". Excluding 33 cases for whom precise data with regard to the onset of musically-triggered seizures were missing, 36 subjects had both musicogenic and unprovoked seizures, while only 14 of the 83 patients (17%) had seizures exclusively triggered by music.

Musical triggers are often variable but may be very specific for a patient: a discrete frequency band of church bells [5], brass wind instrument playing low notes [6], hillbilly

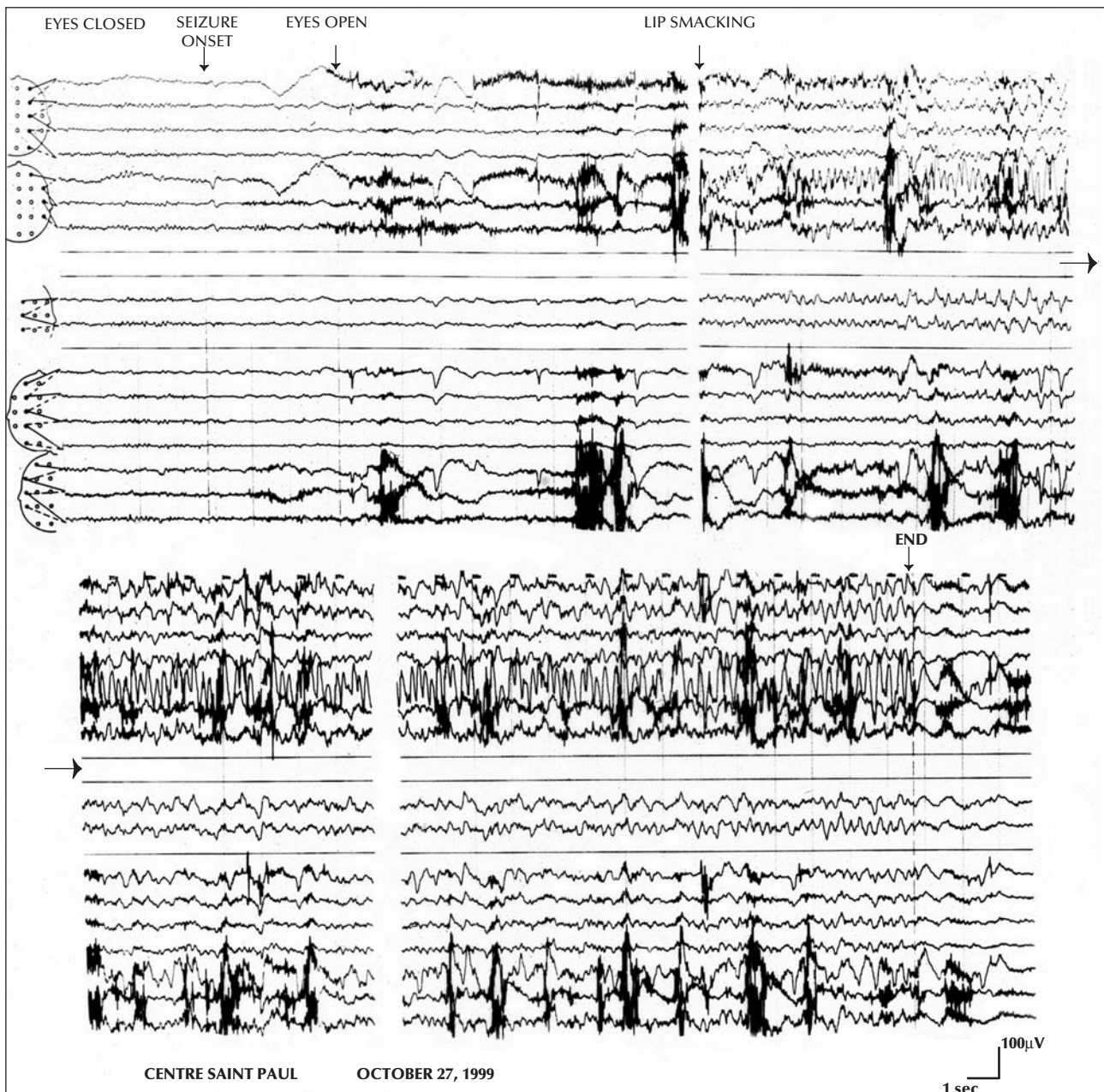


Figure 1. Focal seizure triggered by listening to the Nabucco of Verdi. The seizure start by a slow spike over F8, then 10 seconds after rhythmic slow spikes well localized over the anterior right temporal lobe.

organ [7], the *Marseillaise* [8], *String of Pearls* by Benny Goodman [9], voice of a TV personality [10]. According to Jallon *et al.* (1989), seizures can be precipitated by the type of music (classical, lyric, religious, military, jazz, musical comedy), the type of instrument (piano, violin), the kind of music (Cheerful, sad, sentimental) or by a specific composer (Wagner, Beethoven) [8]. Sometimes, but very rarely, thinking about a type of music is enough to precipitate a seizure [8]. Affective components seem to be very significant in some cases. Wieser *et al.* (1997) re-

ported a high prevalence of musicogenic epilepsy in music lovers. Among their 83 patients, the musical standard was relevant described in 35: four (11%) were professional musicians, 11 (31%) were amateur musicians, five (14%) were "music fans" and seven (20%) had an above average interest in music. Only eight patients declared that they were not especially interested in music.

From the study of Wieser *et al.* (1997), this epilepsy appears to be more frequent in women (females/

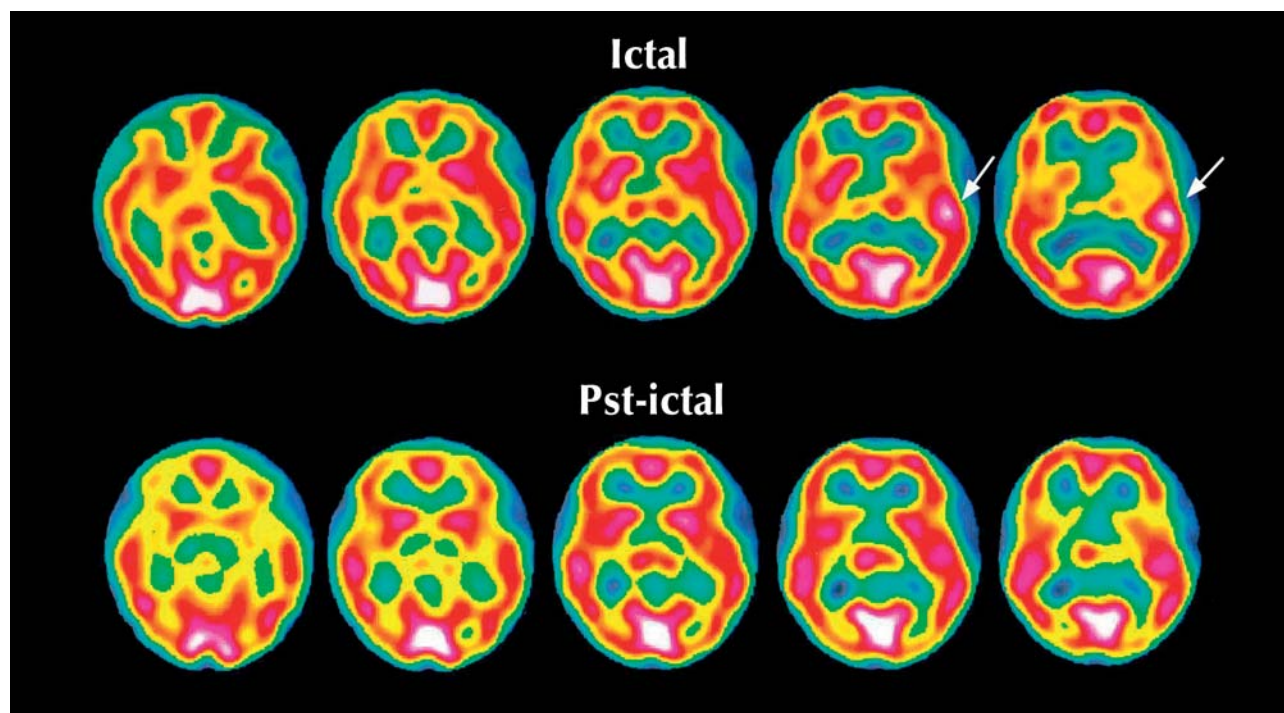


Figure 2. Ictal versus interictal SPECT: ictal hyperperfusion involving the right temporal lobe, no specific findings on the interictal SPECT.

males = 54/46%). Seizure onset is in adulthood at a mean age of 27.7 years (12.5 years). Forty-four patients had a clear description of the localisation. Onset was found in the temporal lobe in 75% of cases, and seizure focus was more often right (61%) than left [4].

Ictal SPECT was performed in a patient by Wieser *et al.* (1997) and showed a right anteropolar temporal hyperperfusion [4]. Another ictal SPECT was reported by Genc *et al.* (2001) and demonstrated a right anterior and mesial temporal hyperperfusion [11]. Both author groups proposed the participation of the mesial temporal structures in the production of musicogenic epilepsy: this hypothesis is sustained by our observation, since our patient reported some spontaneous episodes of *déjà-vu* and had lip smacking and swallowing.

The physiopathology of seizures induced by music is unclear. The latency observed between the stimulus and the seizure is variable, from a few seconds to several minutes, longer than for simple reflex seizure. Musicogenic epilepsy appears to represent a peculiar form of complex reflex epilepsy [12]. Dichotic listening allows us to distinguish a main, crossed auditory pathway and a less important, ipsilateral auditory pathway. In our case, the monoaural stimulation, contralateral to the epileptic focus, produced a simple partial seizure, whereas the ipsilateral stimulation was ineffective. This allows us to conclude that binaural stimulation is not necessary to

produce a seizure. To further validate the strongly lateralized sensitivity in this patient, a dichotic test should be performed. Our patient had right temporal lobe epilepsy. It is in accord with the preponderance of right-sided seizure origin, as reported in the literature [4] and that the right hemisphere is proved regularly superior to the left hemisphere in the identification of non verbal sounds in dichotic listening [13]. The only interesting history as regards our patient consisted of in an unclear history of brief, spontaneously regressive right-sided hearing loss: this may point to the existence of inflammatory factors. The lack of clear EEG changes over 10-15 seconds at clinical seizure onset followed by high-voltage sharp 5-7 Hz theta rhythm over the anterior temporal region, is the most common pattern seen in medial temporal lobe seizures [14]. The high prevalence of significant emotional factors among patients with ME is also in favour of the implication the limbic system.

Conclusion

Musicogenic epilepsy is a rare entity among the large category of reflex epilepsies. Pure cases with no associated spontaneous seizures are exceptional. Our observation confirmed the implication of the right temporal lobe in this epilepsy. □



Video sequence Caption

Sequence 1: Seizure triggered by listening to Verdi's Nabucco. The clinical attack consisted of a conscious manifestation of anxiety and discomfort, followed quickly by lip smacking and swallowing. The EEG (see *figure 1*) was normal at clinical onset, with appearance, 20 seconds after the first symptoms, of a rhythmic theta discharge over the anterior right temporal leads. The patient did not remember the full duration of the seizure, and regained contact immediately after the cessation of the musical stimulation.

Sequence 2: Seizure triggered by listening to *Conte Te Partiro* with ictal HMPAO SPECT (see *figure 2*). The seizure occurred approximately 1.5 minutes after the beginning of the song. The first symptom is a change in mimic with a slight body movement, the patient signals seizure onset. There is no change on the EEG at this moment. Consciousness and contact appear normal. Early occurrence of lip smacking and oral automatism. About 20 seconds later, appearance of rhythmic slow wave activity over the right anterior temporal region. Oral automatisms persist, and there is a slight obtundation, later confirmed by the patient. The injection is performed 25 seconds after the onset of the EEG changes. At the end of the seizure, the patient is immediately responsive.

References

- Critchley M. Musicogenic epilepsy. *Brain* 1937; 60: 13-27.
- Naritoku DK, Mecozzi LB, Aiello MT, Faingold CL. Repetition of audiogenic seizures in genetically epilepsy-prone rats induces cortical epileptiform activity and additional seizure behaviors. *Exp Neurol* 1992; 115: 317-24.
- Cokar Ö, Gelisse Ph, Livet MO, Bureau M, Genton P. Startle Response: epileptic or non-epileptic? The case for "flash" SMA reflex seizures. *Epilep Disord* 2001; 3: 7-11.
- Wieser HG, Hungerbuhler H, Siegel AM, Buck A. Musicogenic epilepsy: review of the literature and case report with ictal single photon emission computed tomography. *Epilepsia* 1997; 38: 200-7.
- Poskanzer DC, Brown AE, Miller H. Musicogenic epilepsy caused only by a discrete frequency band of church bells. *Brain* 1962; 85: 77-92.
- Critchley M. Musicogenic epilepsy. In Critchley M, Hensen RA, eds. *Music and the brain*. London: Heinemann, 1977: 344-53.
- Joynt RJ, Green D, Green R. Musicogenic epilepsy. *JAMA* 1962; 179: 501-4.
- Jallon P, Heraut LA, Vanelle JM. Musicogenic epilepsy. In: Beaumanoir A, Gastaut H, Naquets R, eds. *Reflex seizures and reflex epilepsies*. Geneva: Editions Médecine et Hygiène, 1989: 269-74.
- Daly DD, Barry MJ Jr. Musicogenic epilepsy. Report of three cases. *Psychosom Med* 1957; 19: 399-8.
- Ramani V. Audiogenic epilepsy induced by a specific television performer. *N Engl J Med* 1991; 325: 134-5.
- Genc BO, Genc E, Tastekin G, Iihan N. Musicogenic epilepsy with ictal single photon computed tomography (SPECT): could these cases contribute to our knowledge of music processing? *Eur J Neurol* 2001; 8: 191-4.
- Zifkin BG, Zatorre RJ. Musicogenic epilepsy. *Adv Neurol* 1998; 75: 273-81.
- Habib M. Bases neurobiologiques des comportements. 3rd édition. Paris: Masson, 1998.
- van Emde Boas W, Parra J. Long-term noninvasive video-electroencephalographic monitoring in temporal lobe epilepsy. In: Lüders HO, Comair YG. *Epilepsy surgery*, 2nd edition. Philadelphia: Lippincott Williams, Wilkins, 2001: 413-29.