

# Hypothalamic hamartoma causing gelastic seizures treated with stereotactic radiofrequency thermocoagulation

Wei Wang<sup>1,2,3,4</sup>, Weimin Wang<sup>4</sup>, Xiaofei Guo<sup>4</sup>,  
Yan Jun Zeng<sup>5</sup>, Xiaodan Jiang<sup>1,2,3</sup>

<sup>1</sup> Neurosurgery Institute of Guangdong, Southern Medical University

<sup>2</sup> Key Laboratory on Brain Function Repair and Regeneration of Guangdong

<sup>3</sup> Department of Neurosurgery, Zhujiang Hospital, Southern Medical University, Guangzhou

<sup>4</sup> Department of Neurosurgery, The Military General Hospital of Guangzhou PLA, Guangzhou

<sup>5</sup> Biomechanics & Medical Information Institute, Beijing University of Technology, Beijing, China

Received May 14, 2009; Accepted September 24, 2009

**ABSTRACT – Purpose.** To present a case of small hypothalamic hamartoma (HH) causing gelastic seizures and treated with stereotactic radiofrequency thermocoagulation. **Case report.** A 22-year-old man presented with intractable gelastic seizures and focal seizures refractory to medical treatment. Magnetic resonance imaging showed a 6 mm × 6 mm × 7 mm sessile intraventricular HH. Under local anesthesia, four intra-hamartoma lesions were made via stereotactic radiofrequency thermocoagulation using a depth electrode for recording and stimulation. **Results.** Transient central hyperthermia, hypertension, and tachycardia were observed during the coagulation procedure. Intra-hamartoma spikes and slow waves were identified on depth electrode recordings. No gelastic seizure was induced by deep stimulation. The patient was seizure-free during the 12-month follow up and no permanent surgical complications occurred. **Conclusion.** Stereotactic radiofrequency thermocoagulation may be an effective and safe treatment option in selected cases of hypothalamic hamartoma with gelastic seizures.

**Key words:** gelastic seizure, hypothalamic hamartoma, stereotactic radiofrequency thermocoagulation

Hypothalamic hamartoma (HH) with gelastic seizures (GSs) is a rare epilepsy syndrome, affecting approximately 0.5 in 100,000 children (Brandberg *et al.*, 2004). Seizures caused by hypothalamic hamartoma are always refractory to antiepileptic

drugs (AEDs). The intrinsic epileptogenicity of hypothalamic hamartoma has been confirmed in the last decade (Kuzniecky *et al.*, 1997; Munari *et al.*, 1995), and surgical intervention is required for such lesions. Although various treatment options for

**Correspondence:**

Prof. W. Wang  
<gzwangwm@163.com>  
Prof. X. Jiang  
<jiangxiao\_dan@163.com>

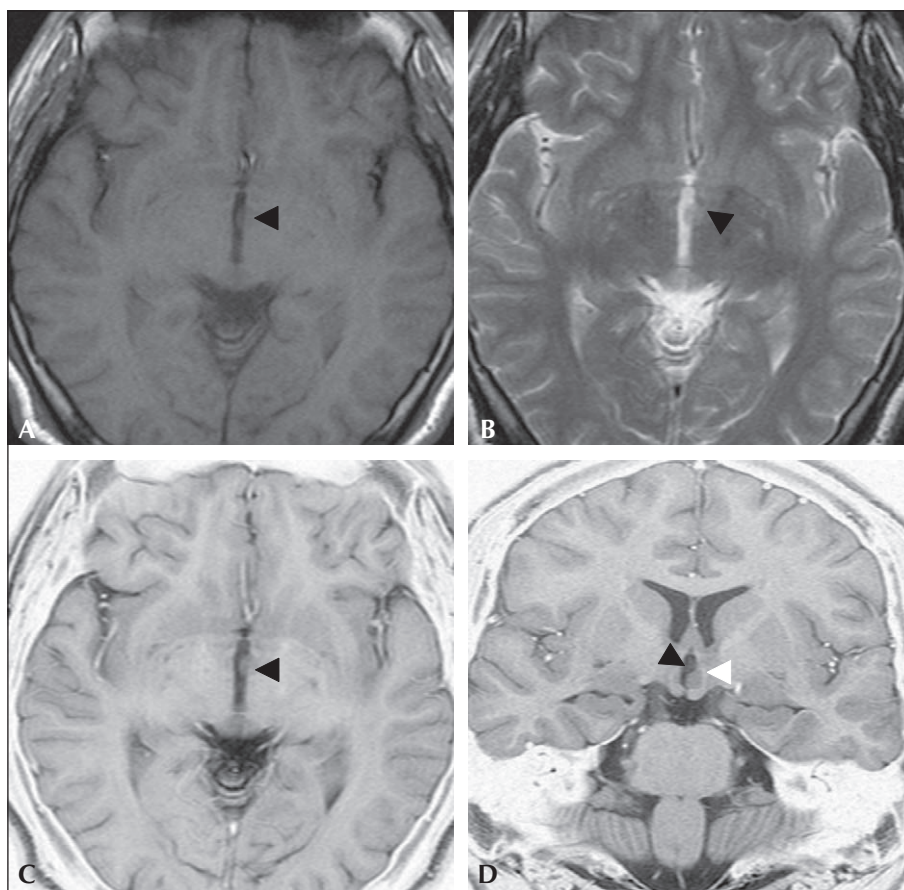
hypothalamic hamartoma with intractable gelastic seizures have been reported, the optimal strategies remain controversial. Only a few cases of stereotactic radiofrequency thermocoagulation have been published, and the reported seizure-free rates are not consistent (Kuzniecky *et al.*, 1997; Fukuda *et al.*, 1999; Parrent, 1999; Homma *et al.*, 2007; Kuzniecky and Guthrie, 2003). Herein, we report a case of gelastic seizures caused by a small hypothalamic hamartoma treated with stereotactic radiofrequency thermocoagulation.

## Case report

### Clinical presentation

The 22-year-old right-handed man presented with intractable gelastic seizures and focal seizures refractory to AEDs. He was the product of a normal pregnancy, and was delivered at term without complication. At the age of 6 months, he began to experience seizures characterized by episodes

of spontaneous unexplained laughter without impairment of consciousness and lasting less than a minute. Despite daily seizures, the patient exhibited no developmental delay, and treatment was not sought. At the age of 15 years he also experienced focal seizures with a giggling sensation at onset. Initial magnetic resonance imaging (MRI) studies failed to reveal any abnormalities. The patient received a diagnosis of “temporal lobe epilepsy” and was treated with carbamazepine, valproate, and topiramate. The drugs failed to control the seizures and he continued to experience one to two daily seizures. Cognitive and memory functions remained intact but he frequently exhibited episodes of rage behavior. Repeated MRI scans (Sonata, 1.5 Tesla, Siemens, Erlangen, Germany) revealed a 6 mm × 6 mm × 7 mm homogeneously non-enhancing, soft-tissue intra-third ventricular mass. The mass was attached to the left mammillary body and mammillothalamic fasciculus, and was consistent with a hypothalamic hamartoma (*figure 1*). Continuous electroencephalography (EEG) monitoring revealed interictal bursts of 2 to 2.5 Hz spike/polyspike-and-slow wave activity over the left hemisphere.

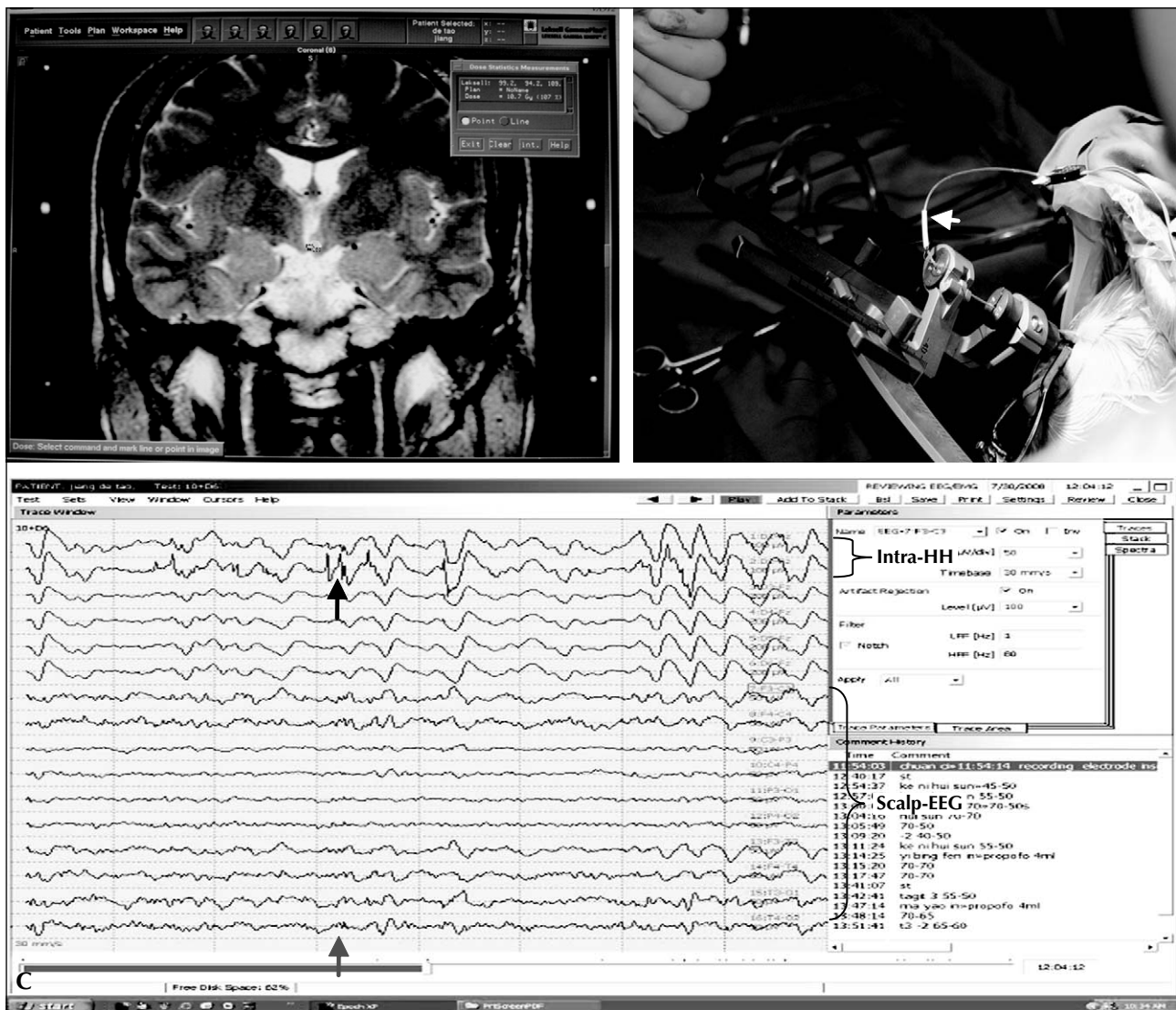


**Figure 1.** A small hypothalamic hamartoma (6 mm × 6 mm × 7 mm) is wholly intraventricular and attached to the left mammillary body and mammillothalamic fasciculus (white arrow head). The hamartoma (black arrow head) is more easily visualized on reversed T2-weighted images (C, D) than T1-weighted images (A) or T2-weighted images (B).

## Surgical procedure

A stereotactic frame (Leksell G, Elekta, Stockholm, Sweden) was mounted on the patient's skull and an MRI scan was performed under local anesthesia. The MRI protocol included axial T1-weighted and axial and coronal T2-weighted imaging (3 mm-thickness; no interslice gap). The target coordinates were determined by MRI-based software (Leksell SurgiPlan, Elekta, Sweden). A semi-open cannula (Insertion Cannula kit, Elekta, Stockholm, Sweden) was introduced to the anterior portion of the hypothalamic hamartoma with the Leksell Stereotactic System, and a deep recording electrode (1.3 mm in diameter, 1.5 mm in length, and 2 mm apart/

HKHS, Beijing, China) was implanted in the same target through the cannula (*figure 2*). The depth electrode consisted of six contacts, with contact 1 as the most ventral contact and contact 3 as the most dorsal. The depth recording showed spike-slow waves which synchronized with the scalp EEG. After removing the depth electrode, a radiofrequency electrode with 1.9 mm diameter and a 2 mm exposed tip (Radionics Medical Products, Inc., MA, USA) was implanted into the hypothalamic hamartoma. Lesions were produced using a radiofrequency (RF) lesion-generator system (model RFG-5; Radionics Medical Products, Inc., MA, USA). Although various stimulation indices had been attempted, neither gelastic nor complex partial seizures could be induced. A test lesion



**Figure 2.** The target coordinates were determined using gamma knife SurgiPlan software (A). The depth electrode (white arrow) was introduced into the anterior portion of the hamartoma (B). Intra-hamartoma recording shows spikes (black arrow) which synchronized with the bilateral temporal discharge on the scalp recording (grey arrow) (C).



was made (45°C, 40 s) before the final lesions were created (70°C, 70s). After the first lesion was made, the radio-frequency electrode was withdrawn 2 mm and the second lesion was created. The third and the fourth lesions were 2 mm posterior to the first and the second ones. The patient complained of “palpitations,” and feeling “hot” and “uncomfortable” during the test and final lesions; hypertension (up to 160/90 mmHg), tachycardia (up to 110/min), perspiration, and cold limbs were observed during the procedure.

## Results

The post-operative MRI scan, performed just before hospital discharge, showed that most of the HH was coagulated (*figure 3*). The patient experienced mild to moderate fever (37.5–38.4°C) for the first 3 days postsurgery and discharged on the fifth day. Gelastic and focal seizures ceased instantly and the patient remained seizure-free during the 12-month follow-up. We do not dispose of a MRI control at 12 months from the operation as the patient could not afford the cost. No hyperphagia, oculomotor palsy, memory loss, or other permanent surgical complication occurred.

## Discussion

The incidence of hypothalamic hamartoma associated with gelastic seizures is currently estimated about 0.5 in 100,000 in children (Brandberg *et al.*, 2004). Although many case reports have linked gelastic seizures to lesions of the temporal lobe, frontal lobe, pituitary tumors, and head trauma (Arroyo *et al.*, 1993; Sartori *et al.*, 1999; McConachie and King, 1997; Cheung *et al.*, 2007), most cases of gelastic seizures involve the presence of a hypothalamic hamartoma. The diagnosis of hypothalamic hamartoma can be established in the presence of gelastic or other types of seizures associated with precocious

puberty and MRI results of a homogeneously non-enhancing soft-tissue mass located in the hypothalamic region that is isointense to gray matter on T1-weighted imaging and hyperintense or isointense on T2-weighted imaging (Freeman *et al.*, 2004)

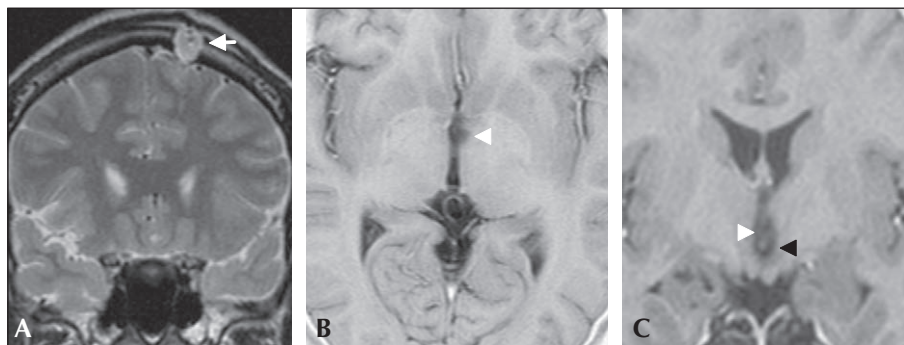
On the basis of the size of the hamartoma and the patterns of attachment to the hypothalamus, several classification systems have been proposed. Delalande’s classification includes four types:

- type I: the hamartoma is below the third ventricle, has a horizontal implantation plane, and may be lateralized on one side;
- type II: the hamartoma has an intraventricular location and vertical insertion plane;
- type III is the combination of type I and type II;
- type IV includes all giant hamartomas (Fohlen *et al.*, 2003).

Although the intrinsic epileptogenicity of hypothalamic hamartoma had been confirmed by numerous investigators, the mechanism of seizures associated with HHs is still not completely understood. Data from intracranial recordings have demonstrated that the other associated seizure types (*i.e.*, without the laughing or crying component) do not arise from HHs, but originate in various cortical areas. These findings suggest that these seizures may result from secondary epileptogenesis and may explain the variable scalp EEG results associated with HHs (Kahane *et al.*, 2003)

Surgical intervention is an effective strategy for hypothalamic hamartoma with gelastic seizures; surgery may be classified as lesion resection, disconnection, radiosurgery, or stereotactic radiofrequency thermocoagulation.

Lesion resection can be achieved through the pterional approach, lamina terminalis approach, or the transcallosal interforniceal approach. According to a review by Harvey *et al.* (2008), the highest seizure control rate in patients with HH associated with seizures could be achieved through the transcallosal interforniceal approach (66% with Engel



**Figure 3.** The MRI was obtained 20 hours after radiofrequency thermocoagulation. The burr hole on skull is shown on **A** (white arrow). Most HHs had been coagulated (**B**, **C**, white arrow head), and the left mammillary body and mammillothalamic fasciculus were intact (**C**, black arrow head).

class I or II outcome). Although most surgeons believe that the classification system is useful in selecting the surgical approach, total resection appears to be dependent on the size and location of HHs. Pedunculated HHs are generally asymptomatic or associated only with precocious puberty, and total resection could be achieved easily. Unfortunately, HHs with gelastic seizures are almost always intraventricular, at least partially, with significant mammillary body attachment; therefore, total resection without surgical complication is rarely achieved (Ng *et al.*, 2006; Shim *et al.*, 2008; Polkey, 2003).

Because the hamartoma is a stable lesion and complete removal may not be necessary to treat the epilepsy or difficult to achieve, the disconnection approach using open surgery or endoscopy has been proposed in the last decade as an alternative. This approach is primarily used for large pedunculated HHs, and the seizure control rates have been reported as comparable to the lesion resection group (Choi *et al.*, 2004).

Radiosurgery (gamma knife) also appears to be an alternative treatment for HH with epilepsy; its major advantage is its safety. However, the lesions are benign and not sensitive to radiation, thus the mechanism of radiosurgery for HH-related seizure control is not clear. Radiosurgery is typically used for postoperative residuals and small HHs (*i.e.*, small intraventricular HHs of Delalande classification type II). A report by Régis *et al.* (2006) of the largest series of radiosurgery cases (27 patients) revealed that complete seizure control or significant improvement were achieved in 10 (37%) and 6 (22%) patients respectively. These results are less favorable than the report of largest series of cases of HHs removed with the transcallosal interforniceal approach, (54% of 26 patients achieved seizure control) (Ng *et al.*, 2006). Interstitial radiosurgery is another treatment option for HHs causing gelastic seizures, according to the experience from Freiburg (Schulze-Bonhage *et al.*, 2008). After a mean 24-month follow up, 11 of 24 patients were seizure-free or had seizure reduction of at least 90% (Engel class I and II), although some patients required repeated treatment.

In 1997, Kuzniecky *et al.* confirmed the intrinsic epileptogenicity of hypothalamic hamartoma with a stereotactic deep recording technique already reported by Munari *et al.* (1995). If there is no apparent mass effect from the benign lesion, HHs associated with seizures may be controlled with stereotactic radiofrequency thermocoagulation. A literature review suggests that only a few cases undergoing this treatment have been reported (Fukuda *et al.*, 1999; Parrent, 1999; Homma *et al.*, 2007; Kuzniecki and Guthrie, 2003). Fukuda *et al.* (1999) and Homma *et al.* (2007) reported five patients with HH who underwent stereotactic radiofrequency thermocoagulation for the treatment of intractable epilepsy; in all cases the hamartoma was intraventricular and less than 15 mm in diameter. The outcomes were excellent; three patients became seizure free and the remaining two patients

experienced 90% improvement in seizure frequency (mean follow-up, 50.6 months) and no permanent surgical complication occurred (Fukuda *et al.*, 1999). In the largest series of cases undergoing stereotactic radiofrequency thermocoagulation (8 patients) reported by Kuzniecky and Guthrie (2003) seizure control was less favorable (Engel I,  $n = 3$ , Engel II,  $n = 2$ , Engel III,  $n = 2$ , Engel IV,  $n = 1$  patient); however, the only complication that occurred was transient third-nerve palsy ( $n = 1$ ). In a review of the literature, Harvey and Freeman (2005) suggested that only 27% of patients with HHs associated with seizure who undergo stereotactic radiofrequency ablation could expect to achieve Engel I or II outcomes.

Because a small radiofrequency electrode is unlikely to destroy a large HH, repeated procedures were needed in some patients after the first failure. Thus, stereotactic radiofrequency thermocoagulation may only be suitable for small HHs. As mentioned above, HHs causing gelastic seizures are always intraventricular, isointense to the gray matter, and without enhancement on MRI imaging. For this reason some small HHs, like the present case, may be difficult to detect unless the hypothalamic region is examined specifically; a T2 reversed image may improve interpretation. Although central hyperthermia and postoperative fever occurred more frequently compared to using the open approach (Homma *et al.*, 2007), the disadvantages of stereotactic radiofrequency thermocoagulation are acceptable. Due to the solid mass of HHs, there is a small possibility of missing the target by a few millimeters, even with computer-assisted stereotactic planning. Some surgeons combine this approach with the endoscopic technique to improve the accuracy, but the application of endoscopy is restricted by the width of the third ventricle. For that reason, we did not use endoscopy to identify the coagulation. The main limitation of the stereotactic approach is that the seizure-free rate in patients with large HHs is lower than treatment with open approaches. However, for small hamartomas, the stereotactic approach may be appropriate because destruction of the lesion and seizure control can be achieved with operative risks and postoperative complication rates that are much lower than any of the open cranial procedures.

Our patient has been seizure-free for 12 months but the results need to be evaluated with long-term follow-up. Compared to radiosurgery, seizure control may be achieved shortly after stereotactic coagulation. Thus, stereotactic radiofrequency thermocoagulation appears to be a safe and efficacious treatment option for select patients with HHs. □

#### Disclosure.

This work was supported by the Funds for Medical Research Projects of Guangdong Province[A2008501] and Key Sci-tech Research Projects of Guangdong Province [YUE KEJIBAN (2007) 05/06-7005206], YUECAIJIAO(2008)258-(2008)A030201019], Research Funds of Guangzhou [SUIKETIAOZI (2008) 3-2008A1-E4011-6, 9B52120112], China.

## References

- Arroyo S, Lesser RP, Gordon B, et al. Mirth, laughter and gelastic seizures. *Brain* 1993; 116: 757-80.
- Brandberg G, Raininko R, Eeg-Olofsson O. Hypothalamic hamartoma with gelastic seizures in Swedish children and adolescents. *Eur J Paediatr Neurol* 2004; 8: 35-44.
- Cheung CS, Parrent AG, Burneo JG. Gelastic seizures: not always hypothalamic hamartoma. *Epileptic Disord* 2007; 9: 453-8.
- Choi JU, Yang KH, Kim TG, et al. Endoscopic disconnection for hypothalamic hamartoma with intractable seizure. Report of four cases. *J Neurosurg* 2004; 100: 506-11.
- Fohlen M, Lellouch A, Delalande O. Hypothalamic hamartoma with refractory epilepsy:surgical procedures and results in 18 patients. *Epileptic Disord* 2003; 5: 267-73.
- Freeman JL, Coleman LT, Wellard RM, et al. MR imaging and spectroscopic study of epileptogenic hypothalamic hamartomas: analysis of 72 cases. *Am J Neuroradiol* 2004; 25: 450-62.
- Fukuda M, Kameyama S, Wachi M, et al. Stereotaxy for hypothalamic hamartoma with intractable gelastic seizures: technical case report. *Neurosurgery* 1999; 44: 1347-50.
- Harvey AS, Freeman JL. Newer operative and stereotactic techniques and their application to hypothalamic hamartoma. In: Wyllie E, ed. *The treatment of epilepsy: principles and practice*. Philadelphia: Lippincott Williams & Wilkins, 2005.
- Homma J, Kameyama S, Masuda H, et al. Stereotactic radiofrequency thermocoagulation for hypothalamic hamartoma with intractable gelastic seizures. *Epilepsy Res* 2007; 76: 15-21.
- Kahane P, Ryvlin P, Hoffmann D, et al. From hypothalamic hamartoma to cortex: what can be learnt from depth recordings and stimulation? *Epileptic Disord* 2003; 5: 205-17.
- Kuzniecky R, Guthrie B, Mountz J, et al. Intrinsic epileptogenesis of hypothalamic hamartomas in gelastic epilepsy. *Ann Neurol* 1997; 42: 60-7.
- Kuzniecky R, Guthrie B. Stereotactic surgical approach to hypothalamic hamartomas. *Epileptic Disord* 2003; 5: 275-80.
- McConachie NS, King MD. Gelastic seizures in a child with focal cortical dysplasia of the cingulate gyrus. *Neuroradiology* 1997; 39: 44-5.
- Munari C, Kahane P, Francione S, et al. Role of the hypothalamic hamartoma in the genesis of gelastic fits (a video-stereo-EEG study). *Electroencephalogr Clin Neurophysiol* 1995; 95: 154-60.
- Ng YT, Rekate HL, Prenger EC, et al. Transcallosal resection of hypothalamic hamartoma for intractable epilepsy. *Epilepsia* 2006; 47: 1192-202.
- Parrent AG. Stereotactic radiofrequency ablation for the treatment of gelastic seizures associated with hypothalamic hamartoma. Case report. *J Neurosurg* 1999; 91: 881-4.
- Polkey CE. Resective surgery for hypothalamic hamartoma. *Epileptic Disord* 2003; 5: 281-6.
- Régis J, Scavarda D, Tamura M, et al. Epilepsy related to hypothalamic hamartomas: surgical management with special reference to gamma knife surgery. *Childs Nerv Syst* 2006; 22: 881-95.
- Sartori E, Biraben A, Taussig D, et al. Gelastic seizures: video-EEG and scintigraphic analysis of a case with a frontal focus; review of the literature and pathophysiological hypotheses. *Epileptic Disord* 1999; 1: 221-8.
- Schulze-Bonhage A, Trippel M, Wagner K, et al. Outcome and predictors of interstitial radiosurgery in the treatment of gelastic epilepsy. *Neurology* 2008; 71: 277-82.
- Shim KW, Chang JH, Park YG, et al. Treatment modality for intractable epilepsy in hypothalamic hamartomatous lesions. *Neurosurgery* 2008; 62: 847-56.