

GEFS⁺ where focal seizures evolve from generalized spike wave: video-EEG study of two children

Yu Hong Deng^{1,2}, Samuel F. Berkovic², Ingrid E. Scheffer^{2,3,4}

¹ Department of Neurology, Institute of Neurosciences and the 2nd Affiliated Hospital, Guangzhou Medical College, Guangzhou, China

² Department of Medicine, Austin Health, University of Melbourne

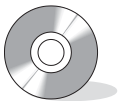³ Department of Neurology, Royal Children's Hospital, University of Melbourne

⁴ Department of Paediatrics, Royal Children's Hospital, University of Melbourne, Australia

ABSTRACT – Focal seizures often secondarily generalize but the reverse is much less frequently documented. The idiopathic generalized epilepsies have the EEG signature of generalized, or bilaterally synchronous spike wave activity and although focal features can be seen, seizures are usually generalized once they commence. Although focal seizures can be seen in some syndromes, it is not well recognized that generalized seizures can become focal *during* the attack. Here we describe two cases of idiopathic epilepsy with a genetic basis; both cases falling within the spectrum of generalized epilepsy with febrile seizures plus (GEFS⁺). One patient has a family history consistent with the family epilepsy syndrome diagnosis of GEFS⁺, whilst the second has a *de novo* SCN1A mutation in the setting of “severe” Febrile Seizures. In both patients, seizures began with generalized spike wave activity and then a focal ictal rhythm emerged. This is a further example of the increasingly blurred distinction between generalized and focal categories of specific genetically determined epilepsies.

[Published with video sequences]

Key words: GEFS⁺, video-EEG, partial seizure, generalized seizure, SCN1A mutation



Correspondence:

Department of Neurology,
Austin Health, Heidelberg,
Victoria 3081
Australia
Tel.: 613 9496 2737
Fax: 613 9496 2291
<scheffer@unimelb.edu.au>

GEFS⁺ (generalized epilepsy with febrile seizures plus) is a familial epilepsy syndrome comprising a broad spectrum of clinical phenotypes or subsyndromes ranging from benign to severe epilepsies. GEFS⁺ includes febrile seizure (FS), febrile seizures plus (FS+) and generalized seizure types, and the more severe syndromes of myoclonic-astatic epilepsy (MAE) and Dravet syndrome (Scheffer et Berkovic, 1997; Singh et al. 2001). Although GEFS⁺ was originally concep-

tualized as a generalized epilepsy as generalized seizures predominated, GEFS⁺ families with partial seizures and sodium channel mutations have subsequently been reported. These families have members with temporal lobe epilepsy (TLE) and frontal lobe epilepsy (Baulac et al. 2001; Aboukhalil et al. 2001; Ito et al. 2002; Scheffer et al. 2007).

In the families with GEFS⁺ and TLE, temporal lobe seizures have been well documented and are distinct from the

individual's generalized seizures. In Dravet syndrome, which may occur infrequently or in GEFS⁺ families, partial seizures are usual and include hemiclonic and complex partial seizures. In contrast, partial seizures are not considered part of the semiology of MAE or typical FS or FS+. Furthermore, some patients in the GEFS⁺ spectrum have more difficult attacks to describe where onset is generalized and the seizure evolves to a focal attack and may then become "tertiarily" generalized again. This type of seizure is not well described and may complicate syndrome diagnosis. Here, we report two unusual patients who fall within the GEFS⁺ syndrome and have generalized seizures leading into partial seizures, as distinct from separate generalized and partial attacks.

Case studies

Case 1

A 13-years-old boy presented with febrile seizures at 2 years 5 months with 2 convulsions lasting 2 minutes on one day, associated with fever and *otitis media*. Seizures occurred every three months, gradually increasing to 1-5 per month. He had two types of seizures: rare brief GTCS (generalized tonic-clonic seizures) and frequent complex partial seizures (CPS). CPS began with an aura of nausea and vomiting and then he became limp with altered awareness. Prior to 5 years, seizures usually occurred when he was unwell with a temperature of 37.5° C (per axilla). Later, seizures were unlikely to be accompanied by fever. Carbamazepine, lamotrigine, topiramate, and valproate were not effective; high doses of clobazam lessened seizure frequency.

He had a bilineal family history of seizure disorders (*figure 1*). He was the product of a normal pregnancy and forceps delivery at 42 weeks gestation. Early developmental milestones were normal; at 2.5 years, unclear speech was noted. Neuropsychological assessment at 5.5 years showed full scale IQ 70 with performance IQ (PIQ) 67 and verbal IQ (VIQ) 80. Cognitive decline was evident at 8 years 8 months with PIQ 55 and VIQ 64, and he required a modified program in mainstream school with extra assistance. His difficulties were most prominent in executive function, language and visuospatial reasoning. General and neurological examinations were normal. MRI brain scan was normal at six years. The following genes were negative when screened for mutations: *SCN1A*, *SCN1B*, *SCN2A*, *GABRG2*, *GABRA1*, *GABRDA(A)*, *GABRA6*, *GABRB1*, *GABRP*, *CHRNA4*, *CHRNA2*.

Interictal EEG at 9 years showed background slowing with frequent bursts of fast 4-5 Hz irregular generalized spike wave activity (GSW) and polyspike wave activity (GPSW) (*figure 2*).

Video-EEG monitoring at 9 years captured three different types of seizures: seizures characterized by head deviation to either side or with no definite clinical features. Seizures

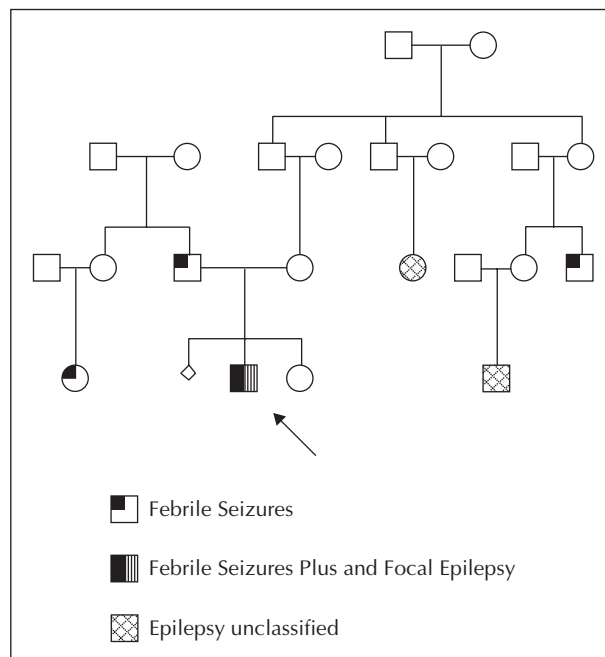


Figure 1. Pedigree of case 1.

with right head version had no aura but, on one occasion (see *video sequence 1A*), the seizure was preceded by a prodrome of nausea for 24 minutes prior to electrical onset. Vomiting or dry retching occurred followed by head deviation to the right accompanied by left leg extension, then secondary generalization. The ictal EEG (*figure 3A and B*) began with irregular GPSW activity lasting two seconds that, on one occasion, was preceded by one second of left temporal rhythmic theta (T5). Diffuse attenuation followed, then a focal fast rhythm emerged. The localization of the fast rhythm varied from the left posterior quadrant to the left frontotemporal region in different seizures. The rhythmic activity spread to involve the left hemisphere more diffusely evolving to generalized 2 Hz sharp and slow activity. Postictal diffuse slowing was noted, more prominent over the left hemisphere.

The seizure with head version to the left (see *video sequence 1B*) was clinically silent until 42 seconds after electrical onset when the patient complained of nausea and vomited. His head turned to the left with left hemiclonic activity 56 seconds later, then secondarily generalized. He had a further electrical seizure, without definite clinical manifestations that followed a 52 minute prodrome of nausea. Both of these seizures (*figure 4A and B*) began with a burst of GSW evolving to fast activity localized to the right posterior quadrant; the fast activity remained localized in the seizure without clinical features. In the seizure with secondary generalization, the ictal rhythm gradually evolved to generalized 2.5 Hz sharp-slow activity. Postictally, there was initial flattening fol-

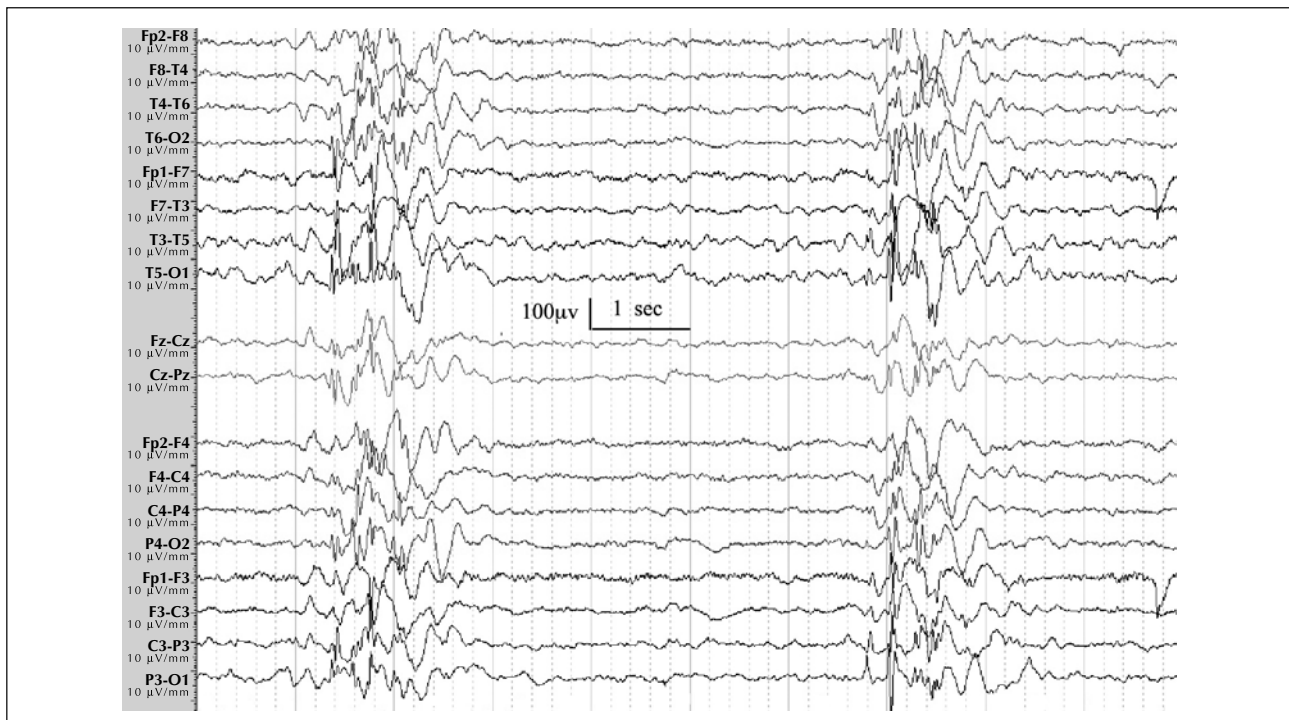


Figure 2. Case 1. Interictal EEG showing diffuse slowing with almost continual rhythmic 2-4 Hz delta over the left hemisphere maximal in the temporal region. Bursts of irregular posteriorly predominant fast 4-5 Hz GSW and GPSW are shown.

lowed by high amplitude slowing over the right hemisphere and left hemispheric slowing.

Thus, this 13-years-old boy has a history of febrile and afebrile GTCS and CPS consistent with FS+ and CPS. VEM showed GSW, GPSW and different seizure types with “mirror image” head version to either side. Focal ictal rhythms from each hemisphere independently evolved directly from paroxysms of GSW activity.

Case 2

This 5-years-old boy had recurrent febrile status epilepticus and died of focal febrile status epilepticus. His seizures began at 18 months with a 10-15 minute febrile seizure. His next febrile seizure occurred at 22 months; he had 24 febrile seizures by the time that he died at five years. Seizures were generalized on history although he had a left Todd's paresis after one seizure. All seizures were associated with a fever over 38 °C and were usually prolonged requiring medical intervention. He commenced on valproate at two years, and was seizure free from 2 years 5 months until 4 years 4 months whilst his exposure to other children was minimized. At 4 years 11 months, lamotrigine was added. At 5 years 2 months, he was found convulsing at 2 am. He was in febrile status epilepticus and overnight had multiple febrile seizures. In hospital he had focal clonic activity migrating from the right finger to the thumb, the head and the left hand, and this cycle of

activity recurred every two minutes. He died of multiple system organ failure.

There was no family history of epilepsy or febrile seizures. He was born in good condition after a pregnancy complicated by bleeding at 12 weeks gestation. He was otherwise well and development was normal although concerns about his memory had just been raised when he started school at five years.

His brain MRI and CT scans were normal at 3 years. Immediately prior to death, his MRI brain demonstrated widespread oedema and infarction with uncal herniation. Morphological evidence of a lesion causing epilepsy was not seen at autopsy. Postmortem testing revealed a *de novo* *SCN1A* missense mutation, 4970G>A: R1657H (Harkin *et al.* 2007).

Routine EEG at 3 years, during a febrile illness, showed stage III/IV sleep with diffuse high amplitude 2-4 Hz delta superimposed on low voltage theta. A fortuitously recorded 2.5 minute seizure (see video sequence 2) started with a generalized jerk, followed by head extension and deviation to the left with clonic activity. He attempted to crawl up the bed with generalized clonic activity followed by right leg extension, bilateral upper limb clonic activity and cyanosis. Ictal EEG (figure 5) began with a sharp slow complex in the right posterior quadrant (T6, O2), immediately followed by GSW with right hemispheric predominance. A focal rhythm emerged with high amplitude sharply contoured 6Hz theta at O2, reflected over the left

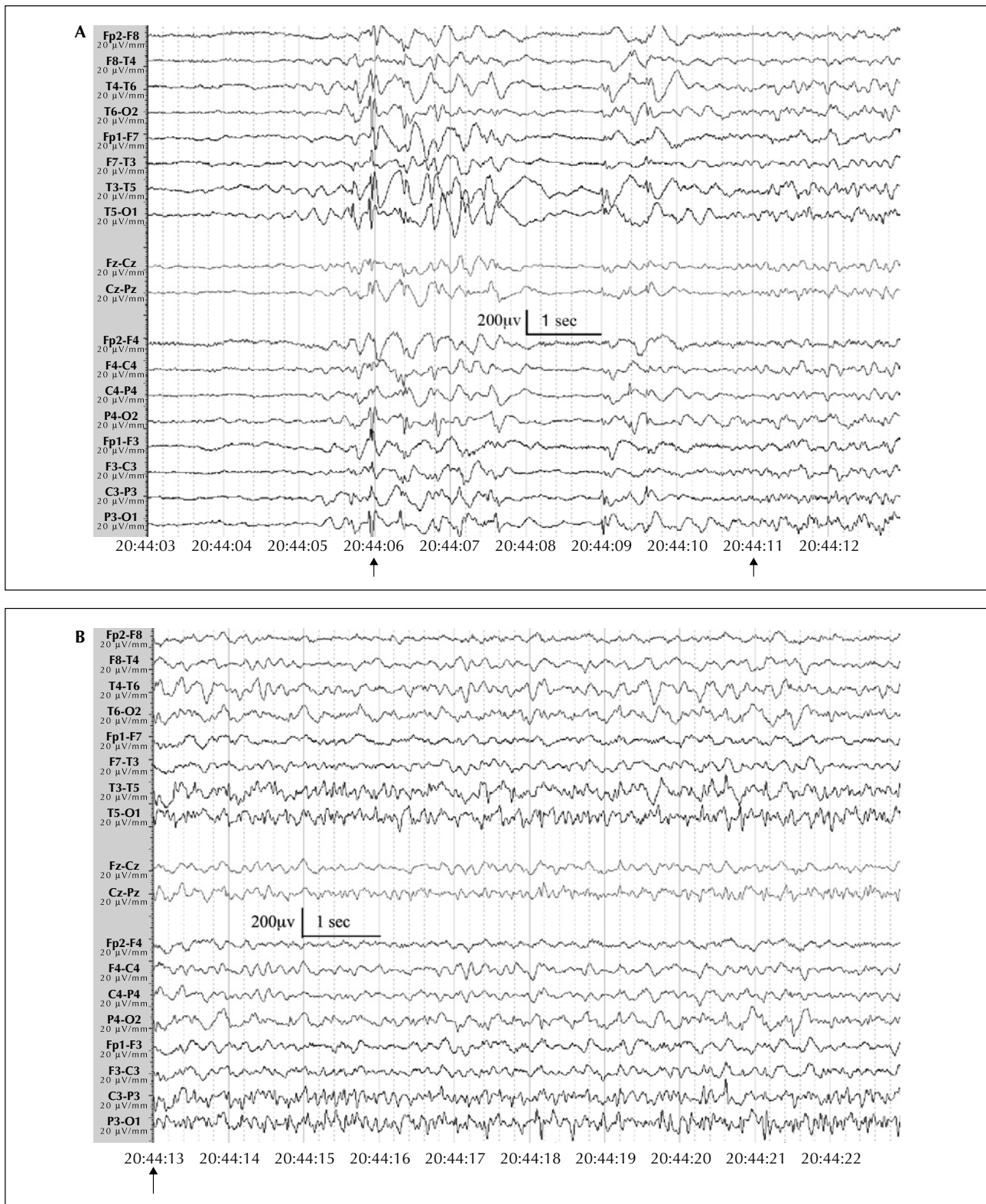


Figure 3. A. Case 1. Ictal EEG for seizure with head deviation to the right. The seizure began with 2 seconds of irregular GPSW activity (20:44:06), preceded by one second of left posterior temporal rhythmic theta. GPSW was followed by 1.5 second generalized attenuation, then a burst of irregular GSW evolving to a focal fast rhythm in the left posterior quadrant (20:44:11, maximal O1, P3, T5); **B.** Case 1. Ictal EEG for seizure with head deviation to the right. Ongoing focal fast rhythm in left posterior quadrant seen at 20:44:13 continues until 20:47:09.

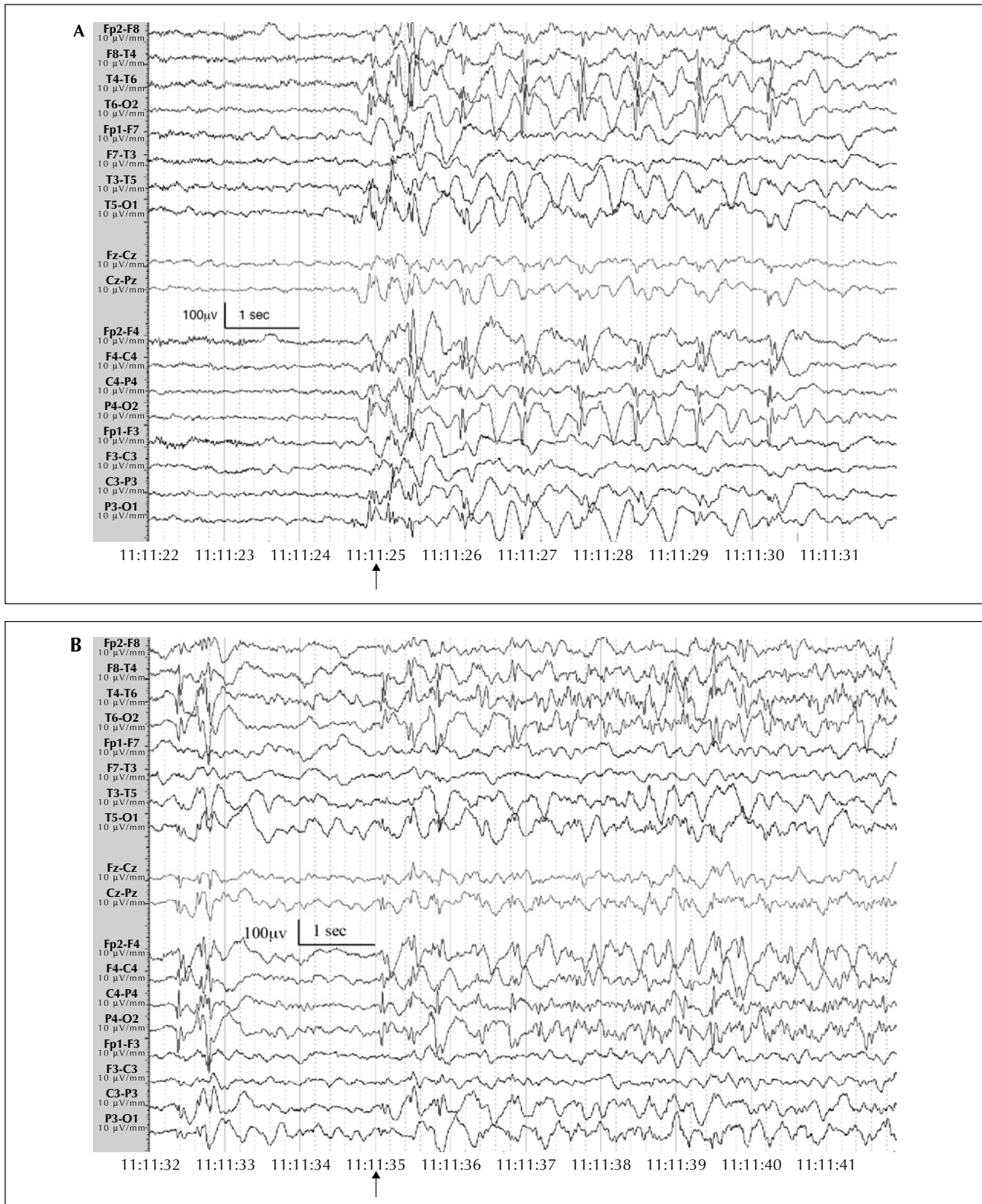


Figure 4. A. Case 1. Ictal EEG for seizure with head deviation to the left. The seizure began with GSW (11:11:25) predominating over the right hemisphere; **B.** Case 1. Ictal EEG for seizure with head deviation to the left. At 11:11:35, a fast ictal rhythm emerged over the right posterior quadrant (T6, O2, P4) superimposed on diffuse rhythmic 3-4Hz slowing.

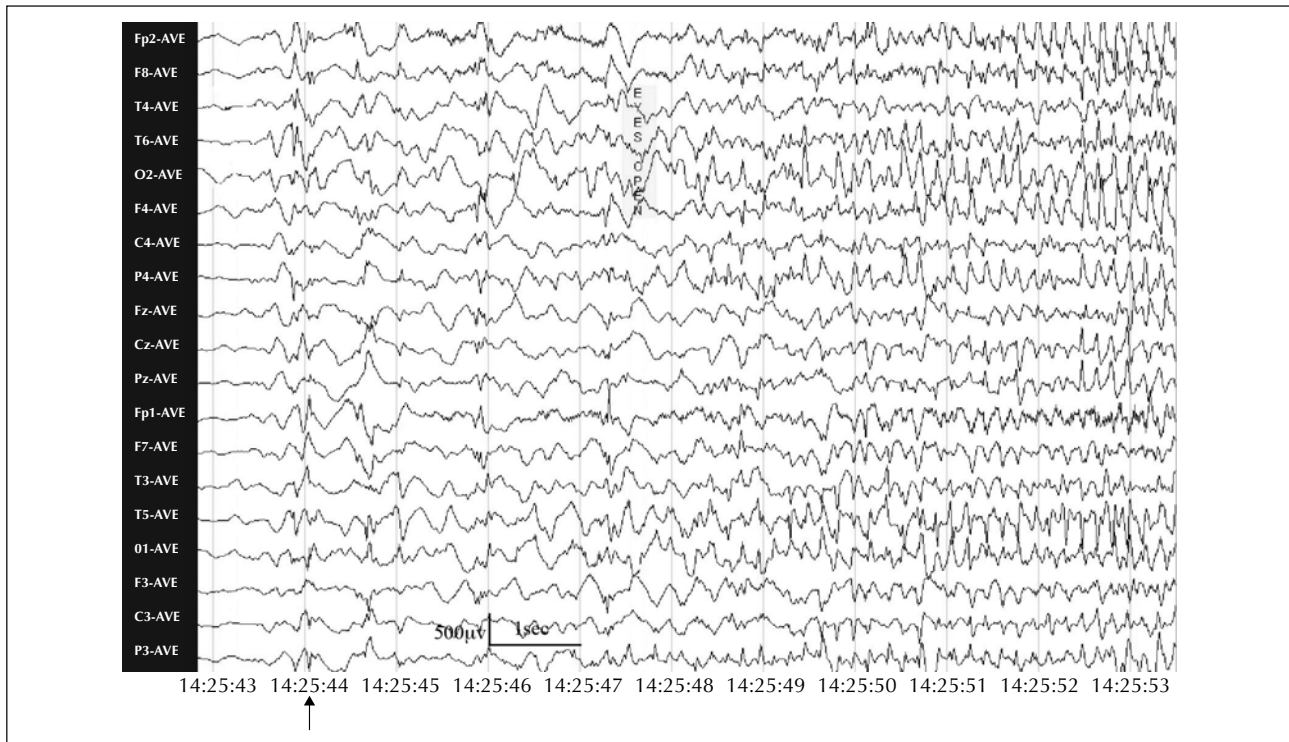


Figure 5. Case 2. Ictal EEG. The ictal recording began with a sharp slow complex (14:25:44) in the right posterior quadrant (T6, O2), immediately followed by GSW with a right hemisphere predominance. At 14:25:48, sharply contoured 6Hz theta rhythm emerged at O2 and was reflected over the left posterior quadrant.

posterior quadrant that rapidly propagated to the right frontal region. The discharge became generalized and gradually evolved to 1 Hz sharp-slow activity with diffuse postictal slowing.

Discussion

GEFS⁺ was initially conceptualized as a familial epilepsy syndrome where most individuals have febrile seizures (FS) and forms of generalized epilepsy (Scheffer *et al.* 1997 ; Singh *et al.* 1999). With time, it has become clear that focal epilepsy both with and without preceding FS is not uncommon in GEFS⁺ families. Focal seizures emanating from the temporal and frontal lobes have been reported in association with mutations of sodium channel alpha 1 and beta 1 subunit genes, *SCN1A* and *SCN1B* (Abou-khalil *et al.* 2001 ; Ito *et al.* 2002 ; Scheffer *et al.* 2007 ; Baulac *et al.* 2001). Individuals with mutations may have focal seizures that secondarily generalize. In contrast, here we describe patients with GEFS⁺ phenotypes who show unusual electroclinical semiology where generalized onset evolves to a focal ictal rhythm with focal clinical features, and then may generalize again. The definition of a generalized seizure is “a seizure whose initial semiology indicates, or is consistent with, more than minimal involvement of both cerebral hemispheres”

whereas a focal seizure is defined as “a seizure whose initial semiology indicates, or is consistent with, initial activation of only part of one cerebral hemisphere” (Blume *et al.* 2001). Further, it is well recognized that frontal neocortical lesions may present with GSW. Here we show a different scenario when GSW evolves to focal ictal abnormality with normal structural imaging. In the patients reported here a typical generalized pattern was seen at onset evolving to a clearcut focal pattern. This pattern of evolution is not well recognized, particularly in generalized epilepsies with GSW.

This finding is different to patients who manifest separate focal and generalized seizures; such a history is well recognized in syndromes such as Dravet and Lennox-Gastaut syndrome (Engel, 2001). Whilst focal seizures commonly secondarily generalize, seizures evolving from a generalized onset to a focal seizure are less well appreciated.

This observation highlights the sometimes blurred distinction between generalized and focal epilepsies. Classical idiopathic generalized epilepsies such as Juvenile Myoclonic Epilepsy may have focal clinical features and focal discharges (Taylor *et al.* 2004); however, they are not known to progress from generalized to focal ictal rhythms within a seizure. Here we show that in GEFS⁺, with the EEG hallmark of generalized epilepsy, generalized spike wave activity can progress to a focal seizure.

GEFS⁺ remains a clinical family syndrome diagnosis (Scheffer *et al.* 2005). At least two individuals with a GEFS⁺ phenotype in a family are required to be able to diagnose GEFS⁺. In the first case the family tree is consistent with GEFS⁺. This boy has a bilineal family history of seizure disorders including FS on both sides; two maternal relatives have unclassified epilepsy. His more complex phenotype may well have a polygenic basis likely due to inheriting epilepsy genes from both sides of the family. He is negative for mutational screening in known GEFS⁺ and other epilepsy genes. This is not surprising given that the known genes account for only a minority of GEFS⁺ families (Wallace *et al.* 2001), and that most cases of GEFS⁺ have complex inheritance with a polygenic basis.

The second patient had febrile seizures alone, but of unusual severity. His *SCN1A* mutation is likely to be the basis of his seizures. Even though he did not have a family history of FS or epilepsy, his phenotype is compatible with a GEFS⁺ phenotype. The finding of *SCN1A* missense mutation confirms this concept as *SCN1A* missense mutations have been identified in many GEFS⁺ families in individuals with typical FS and more severe phenotypes such as FS+, Doose and Dravet syndrome (Abou-Khalil *et al.* 2001 ; Escayg *et al.* 2000, Harkin *et al.* 2007 ; Mulley *et al.* 2005 ; Wallace *et al.* 2001). It is likely that the more severe cases in these families have complex inheritance where the *SCN1A* mutation is one of several genes contributing to the phenotype.

It is known that a single patient can have both focal and generalized seizures but here we illustrate that a genetic epilepsy can manifest as a generalized seizure that becomes focal. This observation adds to the complexity of our understanding of the interplay between generalized and focal seizure disorders. □

Acknowledgements. The authors thank the families of the patients. We are grateful to Dr Simon Harvey and Associate Professor John Mulley for their assistance. Funding was provided by the National Health and Medical Research Council of Australia.

References

- Abou-Khalil B, Ge Q, Desai R, *et al.* Partial and generalized epilepsy with febrile seizures plus and a novel *SCN1A* mutation. *Neurology* 2001; 57: 2265-72.
- Baulac S, Huberfeld G, Gourfinkel-An I, *et al.* First genetic evidence of GABA (A) receptor dysfunction in epilepsy: a mutation in the gamma2-subunit gene. *Nat Genet* 2001; 28: 46-8.
- Blume WT, Lüders HO, Mizrahi E, Tassinari C, van Emde Boas W, Engel J. Glossary of descriptive terminology for ictal semiology: Report of the ILAE Task Force on Classification and Terminology. *Epilepsia* 2001; 42: 1212-8.
- Engel J. A proposed diagnostic scheme for people with epileptic seizures and with epilepsy: Report of the ILAE Task Force on Classification and Terminology. *Epilepsia* 2001; 42: 796-803.

Legends for video sequences

Video sequence 1A and 1B contains two seizures of case 1 with head version to either side. Focal ictal rhythms evolved from a paroxysm of GSW activity in both seizures.

Video sequence 1A. The seizure began with nausea for 24 minutes prior to electrical onset. Twenty-four seconds after electrographic onset (20:44:30), the patient vomited and at 20:47:00, his head deviated to the right and his left lower limb extended. At 20:47:13, secondary generalization occurred with persistent head deviation to the right for 51 seconds. The initial ictal EEG is described in *figure 3A and 3B*. The focal rhythm in the posterior quadrant evolves to sharp and slow activity associated with diffuse 2.5 Hz delta. The fast activity spread to the left frontotemporal region (F7, T1, T3), and then became diffuse (20:47:15), evolving to 2 Hz sharp and slow activity (20:48:05). Postictal slowing was seen diffusely with a left hemisphere predominance (20:49:10).

Video sequence 1B. The seizure was clinically silent at electrical onset. After 42 seconds of an ictal rhythm (11:12:17), the patient complained of nausea and vomited. Fifty-six seconds later (11:13:03), his head turned to the left with left hemiclonic activity lasting 10 seconds (11:13:13) then secondary generalization occurred. The initial ictal EEG is described in *figure 4A and 4B*. The right posterior quadrant fast activity gradually evolved to frank 2.5 Hz sharp-slow activity localized to the right posterior quadrant then becoming generalized until abruptly terminating (11:13:47) with clinical seizure offset. Postictally, there was flattening over the right hemisphere with left hemispheric slowing, followed by higher amplitude slowing over the right hemisphere (11:14:12).

Video sequence 2. This 2.5 minute seizure started with a generalized jerk (14:25:44), immediately followed by head extension and deviation to the left with clonic activity. At 14:25:55, the patient tried to crawl up the bed, accompanied by generalized clonic activity for 5 seconds. He was turned onto his left side (14:26:08), and had right leg extension and right upper limb clonic activity. He became cyanosed and left upper limb clonic activity was also apparent. The initial ictal EEG is described in *figure 5*, then the right posterior quadrant fast activity rapidly propagated to the right frontal region and at 14:25:54, the discharge became generalized and gradually evolved to 1 Hz sharp-slow activity until abruptly ceasing at 14:28:29. There was diffuse slowing postictally.

- Escayg A, MacDonald BT, Meisler MH, *et al.* SCN1A, encoding a neuronal sodium channel, in two families with GEFS⁺2. *Nat Genet* 2000; 24: 343-5.
- Harkin LA, McMahon JM, Iona X, *et al.* The spectrum of SCN1A-related infantile epileptic encephalopathies. *Brain* 2007; 130: 843-52.
- Ito M, Nagafuji H, Okazawa H, *et al.* Autosomal dominant epilepsy with febrile seizures plus with missense mutations of the (Na⁺)-channel alpha 1 subunit gene, SCN1A. *Epilepsy Res* 2002; 48: 15-23.
- Mulley JC, Scheffer IE, Petrou S, *et al.* SCN1A mutations and epilepsy. *Hum Mutat* 2005; 25: 535-42.
- Scheffer IE, Berkovic SF. Generalized epilepsy with febrile seizures plus. A genetic disorder with heterogeneous clinical phenotypes. *Brain* 1997; 120: 479-90.
- Scheffer IE, Harkin LA, Dibbens LM, Mulley JC, Berkovic SF. Neonatal epilepsy syndromes and generalized epilepsy with febrile seizures plus (GEFS⁺). *Epilepsia* 2005; 46: 41-7.
- Scheffer IE, Harkin LA, Grinton BE, *et al.* Temporal lobe epilepsy and GEFS⁺ phenotypes associated with SCN1B mutations. *Brain* 2007; 130: 100-9.
- Singh R, Andermann E, Whitehouse WP, *et al.* Severe myoclonic epilepsy of infancy: extended spectrum of GEFS⁺? *Epilepsia* 2001; 42: 837-44.
- Singh R, Scheffer IE, Crossland K, Berkovic SF. Generalized epilepsy with febrile seizures plus: a common childhood-onset genetic epilepsy syndrome. *Ann Neurol* 1999; 45: 75-81.
- Taylor I, Marini C, Turner S, Berkovic SF, Scheffer IE. Juvenile myoclonic epilepsy and idiopathic photosensitive occipital lobe epilepsy: is there overlap? *Brain* 2004; 127: 1878-86.
- Wallace RH, Scheffer IE, Barnett S, *et al.* Neuronal sodium-channel (alpha 1-subunit mutation in generalized epilepsy with febrile seizure plus. *Am J Hum Genet* 2001; 68: 859-65.