

Anatomo-electro-clinical correlations: the Freiburg, Germany Case Report Case 02-2009

Functional hemispherectomy in adults with intractable epilepsy syndromes: a report of 4 cases

Bernhard J. Steinhoff¹, Anke Maren Staack¹, Sofia Bilic¹, Uwe Kraus¹, Andreas Schulze-Bonhage², Josef Zentner³

¹ Kork Epilepsy Center, Kehl-Kork

² Epilepsy Centre, University Hospital Freiburg

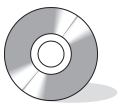³ University Department of Neurosurgery, Freiburg, Germany

Received July 27, 2008; Accepted June 23, 2009

ABSTRACT – [Case records of *Epileptic Disorders*. Anatomo-electro-clinical correlations. Case 02-2009]

Background. Functional hemispherectomy (FH) is mainly performed in children with catastrophic epilepsies and pre-existing severe hemiparesis. It is accepted that mainly patients at young ages with more or less complete loss of their hand function are suitable candidates for FH. However, we feel that FH should be considered also in some adults with devastating unilateral epilepsy syndromes. **Patients and methods.** We report four cases of adults who underwent FH because of their intractable epilepsy syndromes. Three of the four patients had reduced but not complete loss of hand function. Careful weighing-up of the risk-benefit ratio still led to the decision to perform FH in order to achieve complete seizure relief. **Results.** All patients had a surgical outcome of Engel class I; one of them suffered from post-operative psychogenic non-epileptic seizures which were treated successfully by psychotherapy. No clinically relevant complications occurred. **Conclusion.** We wish to point out that FH is a possible surgical option in cases with catastrophic epilepsies in adulthood. Patients and relatives should strongly consider that the likelihood of at least partially, impaired hand function or other surgery-related additional handicaps may be outweighed by the chance of freedom of seizures in a limited number of patients. In all of our cases, patients and relatives agreed that the surgical outcome led to a marked improvement of quality of life and that it had been the right decision to proceed with FH in spite of the expected negative impacts of the operation. Video examples of the pre- and post-surgical hand function of one sample patient are enclosed. [Published with video sequences]

Key words: epilepsy surgery, functional hemispherectomy, adults, risk-benefit ratio



Correspondence:

Prof. B.J. Steinhoff
Medical Director,
Epilepsiezentrum Kork,
Landstrasse 1,
77694 Kehl-Kork, Germany
<bsteinhoff@epilepsiezentrum.de>

Functional hemispherectomy (FH) was introduced as a surgical procedure performed in patients primarily with brain tumours and later performed in cases with drug-resistant, highly active epilepsy syndromes in childhood (de Almeida and Marino, 2005). However, the mortality rate was relatively high mainly due to post-operative

intracranial bleeding complications (de Almeida and Marino, 2005). Mortality rates could be markedly reduced by modifications of the procedure, namely by the contributions of Rasmussen (1983) and later by the introduction of hemispherical deafferentation. The latter consists of a hippocampectomy or a resection of the anterior temporal lobe combined with differentiation of the temporal, occipital, parietal and frontal lobes as well as a transventricular callosotomy leaving the insular cortex in place which may be also resected in selected cases (Schramm *et al.*, 1995). This approach requires a transcortical transventricular or a transsylvian key hole approach and allows a smaller trepanation, less operation time and less blood loss (Binder and Schramm, 2006; Schramm *et al.*, 1995, 2001). Since the concept of FH requires the complete separation of the frontal and occipital lobes, a removal of the temporal lobe and a discontinuation of the motor tract, further deterioration of muscle strength and tone, especially of the hand, is a natural consequence which may however partially recover over time in children (Van Empelen *et al.*, 2004; Schropp *et al.*, 2006). In general, children suffering from severe and often progressive central nervous disorders that affect mainly one hemisphere with additional impairments beyond the epilepsy, (*i.e.* hemiparesis including the hand function) are considered as candidates for FH. Typical underlying aetiologies comprise Sturge Weber syndrome, Rasmussen's encephalitis, hemimegalencephaly or post-ischemic lesions (González-Martínez *et al.*, 2005). Therefore, only patients with a more or less complete loss of their hand function are usually considered as suitable FH candidates, although recovery of an initial motor impairment over time has been described (Van Empelen *et al.*, 2004) and may depend on the underlying aetiology (de Bode *et al.*, 2005).

Since the introduction of FH, the success rates in appropriate patients were among the highest in epilepsy surgery (Engel *et al.*, 1993). Therefore FH is one of the most common resective epilepsy surgery techniques in childhood (Cross, 2002). In adults, this type of surgery is rare. Data on a first retrospective series of nine adult patients, collected over decades, reported similarly excellent outcome data as were seen for children (McClelland and Maxwell, 2007). In adults, the sequelae of FH and the general surgical risk should be weighed up even more critically against the epileptological benefit since, due to reduced compensatory potential, the neurological, psychological and social consequences may be more radical than in young children.

In 2006 and 2007, we had four cases of adult patients where the discussion arose as to whether or not FH could be an appropriate method of treatment, despite the elevated risk in adulthood and especially the fact that three out of the four were still able to use their paretic hand for movements in daily life, even though they were suffering from severely drug-resistant epilepsy with fre-

quent and violent seizures, as well as from severe hemiparesis. Finally, extensive discussions of the risk-benefit ratio made the patients and relatives decide to proceed with FH. Clinical data and the post-operative outcome of these patients, including video documentations of the pre-and post-operative hand function for one patient, are reported.

Patients and methods

All four patients reported were subjected to extensive pre-surgical evaluation. Each of them had highly active and difficult-to-treat epilepsy. Pre-surgical diagnostics at our centre regularly comprise the careful collecting of all relevant clinical data, long-term video-EEG with recording of several typical seizures, imaging including 1.5 or 3 Tesla magnetic resonance imaging (MRI) and additional functional MRI if necessary. Additional information was obtained by PET or SPECT studies. In addition, every patient underwent extensive neuropsychological investigations. *Table 1* displays the relevant clinical and diagnostic pre-surgical data.

All patients were extensively discussed in our regular epilepsy management conference and it was ultimately decided to propose FH for all of the cases presented. FH was also proposed for another case of severely intractable epilepsy resulting from hemimegalencephaly. In this case the patient's family decided not to proceed with FH and seizure frequency has since remained unchanged with optimized AED treatment. For patient 3, the first surgical procedure failed to render seizure freedom, since it was intended to spare any potential loss of hand functions by addressing the removal of postcentral tissue exclusively. Since this patient did not achieve seizure freedom, we proposed FH with all potential consequences thereafter.

For all other cases, the option of less radical operations was extensively discussed, but finally not suggested since the massive extent of the pre-surgical lesions (*table 1, figure 1*) and the pre-surgical monitoring data did not convincingly suggest an epileptogenic lesion distinct enough to be removed in order to achieve seizure freedom.

Parents acted as legal representatives for only two of four cases, as the two remaining patients suffered from moderate (case 1) to marked cognitive impairment (see pre-surgical neuropsychological data in *table 1*). A rule, we would only proceed with a radical epilepsy surgical technique, such is FH, if the patients themselves and close family would both accept this strategy after extensive and repeated information on the risk-benefit ratio. For the cases with legal representatives, both patients agreed to have the operation, although in both cases a sufficient understanding of the potential success and safety hazards was certainly not the case. In these cases the legal representatives had to take over almost the full responsibility

Table 1. Clinical, neurophysiological and neuroimaging pre-surgical data.

	Patient 1, male, 27 years	Patient 2, female, 26 years	Patient 3, female, 26 years	Patient 4, male, 24 years
Age at seizure onset (years)	3	10	14	8
Etiology	Pre- or perinatal infarction after occlusion of left carotid artery	Rasmussens's encephalitis, right hemisphere	Encephalitis age 10 months, not unequivocally proven	Perinatal infarction due to occlusion of the left medial cerebral artery
Seizure types	SPS, CPS, GTCS	SPS left (clonic, myoclonic face and arm, sensorimotor, CPS, GTCS	SPS (tingling feeling in the throat, no lateralized symptoms), CPS, GTCS	SPS (sensori-motor), GTCS
Neurological findings	Left-handed, spastic hemiparesis right side, no fine motor abilities right hand, impaired sensibility right side, incomplete homonymous hemianopia to the right	Nystagmus to the left, incomplete hemianopia, spastic hemiparesis left side with leg preponderance, partially preserved hand function with impaired fine motor skills	Spastic hemiparesis of the left side with leg preponderance, slight strength deficit left hand, complete hemianopia, discrete impairment of coordination, left side	Left-handed, spastic hemiparesis right side, no fine motor abilities right hand, impaired sensibility right side, unreliable perimetric assessment of visual field
Mental status	IQ 89, verbal and figural mnestic deficits, deficits in executive and spatial tasks	IQ 83, attentional and mental speed deficits, deficits of spatial memory and planning	Moderate mental retardation, Impaired attention with markedly prolonged reaction and test time, verbal thinking at level 7 – 7.8 years, writes her name without mistakes, immediate recall for figures at level 4.11 years, better performance in figural recall and memory, figural thinking at level 6.3 – 7.2 years	Severe mental retardation, almost no active speech, autism-like behaviour
EEG monitoring	Interictal EEG: continuous slow, left hemisphere, temporal maximum, IED, intermittent, left hemisphere, maximum T3, rare IED right anterior temporal (< 5%) Ictal EEG: increase of left IEDs, flattening, ictal pattern right with rapid evolution to bilateral pattern, in 2 of 8 seizures ictal pattern left side	Interictal EEG: continuous slow and attenuation right hemisphere, IED with maximum at F8, T4, T6. Ictal EEG: diffuse attenuation, obscured by artifacts, no unequivocal rhythmic pattern	Interictal EEG: continuous slow, right hemisphere, intermittent rhythmic slow, right hemisphere, IEDs intermittent, frontotemporal, bilateral synchronous and independent, IEDs intermittent, regional, maximum electrodes T4, T6, TP8, TP 10, P4 Ictal EEG: diffuse attenuation, obscured by artefacts, no unequivocal rhythmic pattern	Interictal EEG: continuous slow, generalized and bilateral independent, maximum frontal, IEDs and PLEDs, intermittent, lateralized left hemisphere, maximum frontal, rare contralateral IEDS Ictal EEG: ictal EEG pattern almost resembling the interictal data: repetitive epileptiform discharges lateralized left, maximum frontal or frontocentral
Ictal semiology	Arrest, slight head and eye version right, salivation, one seizure with deviation of head and eyes to the left side, secondary generalization without lateralizing clinical signs	Clonic movements of the face and the arm, left side, no CPS or GTCS recorded.	SPS as previously described, CPS with slight movements upper body, followed by arrest, optional oroalimentary automatisms, tonic and dystonic elevation, both arms or left arm, ictal speech, no postictal aphasia	Tonic movements maximum upper body, maximum right arm or tonic movement right arm, optional secondary generalization preponderance
MRI	Massive atrophy of left hemisphere, partial preservation of basal mesial temporal and occipital structures, mesial temporal atrophy without signs hyperintensity on T2 or FLAIR, hyperintense basal ganglia, atrophy of left brain stem and right cerebellum	Massive atrophy of the right hemisphere. Parietal region and the central sulcus are preserved. Hand area shows signal hyperintensity.	Atrophy right hemisphere, mesial temporal sclerosis and atrophy	Lesion of the frontal to the parietal operculum including insula, superior temporal gyrus, inferior frontal gyrus and adjacent parietal cortex, left thalamus atrophic with hyperintense signal

MRI: magnetic resonance imaging; SPS: simple partial seizures; CPS: complex partial seizures; GTCS: generalized tonic-clonic seizures; IEDs: interictal epileptiform discharges; IQ: intelligence quotient.

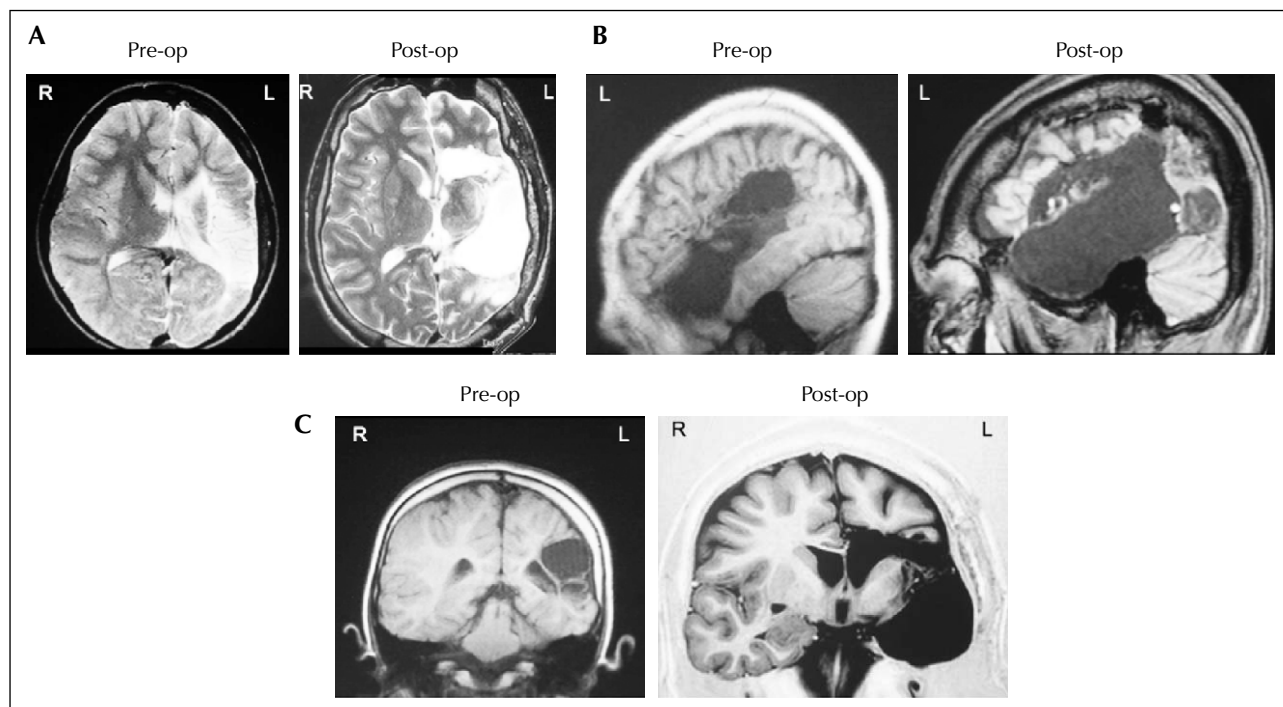


Figure 1. Pre- and post-operative magnetic resonance imaging (MRI) findings in patient 4. Comparable slices are displayed in parallel resembling the pre-operative (pre-op, left side) and post-operative (post-op, right side) status according to axial T2-weighted, thickness 2.0 mm (A) and sagittal T1 weighted, thickness 3.5 mm (B) and coronal T1 weighted inversion recovery (C) images. Scans were performed on a 1.5 Tesla Siemens Magnetom MRI Scanner.

R: right hemisphere; L: left hemisphere.

for the decision. In every case, extensive discussions of the pros and cons of FH were repeatedly undertaken by the epileptologists at the Epilepsy Centre Kork and independently by the neurosurgeons of the University of Freiburg, with both the patients and their relatives.

FH was performed as a modification of the technique described by Rasmussen (1983) and others (Schramm *et al.*, 1995, 2001; Binder and Schramm, 2006). For every case, the temporal lobe including amygdalar and hippocampal formation was removed, while the frontal, parietal and occipital lobes were anatomically presented, but completely disconnected. The frontal and temporal opercula were removed or disconnected while the insula was usually preserved to a large extent.

The surgical results based on interviews, clinical findings, neuropsychological investigations, routine-EEG, MRI and video documentation of the motor skills were documented at three months and at 12 months from surgery. For patient 4, the video documentation was also performed prior to surgery. The assessment of their quality of life was performed by extensive video-taped interviews. Three of the four patients were able to respond to questions addressing their individual quality of life. For all cases, both the patients and their relatives were inter-

viewed. With regard to quality of life, no standardized questionnaires were used prior to and after surgery.

Results

All patients achieved Engel class I (Engel, 1993) and Wieser class 1 (Wieser *et al.*, 2001) outcome. The post-operative course for each patient was as follows.

Patient 1

During the first weeks after surgery patient 1 suffered from headaches, intermittent nausea and vomiting, intermittent myoclonic jerks of the right side and ataxia. An MRI revealed a small hygroma which did not change over time. At subsequent visits these difficulties had disappeared completely. Neurological findings showed a slight deterioration of leg function which almost completely resolved under extensive physiotherapy. Neuropsychological investigations revealed a further decline of executive functions and verbal memory. Figural memory performance had been normal pre-operatively and worsened after surgery. However, this was not felt to deteriorate the patient's performance of daily life. The previously incomplete hemianopia was

complete after surgery. No language impairment was encountered.

Patient 2

A large subdural cyst was seen on the MRI without any neurological sequelae. Several controls including a complete post-operative neurosurgical work-up revealed no therapeutic consequences. The hemiparesis was markedly deteriorated with a complete paresis of the hand and an accentuated paresis of the upper extremity including shoulder, according to levels 2-3. The findings concerning the leg were unchanged. She had an almost complete hemianopia. Neuropsychologically, verbal memory had improved. All other functions were unchanged.

She developed seizures again after an initial seizure-free period of three months. Interestingly, careful evaluation including video-EEG monitoring revealed that she now suffered solely from psychogenic non-epileptic seizures (PNES). We initiated extensive psychotherapeutic treatment at our centre which helped to achieve complete seizure freedom including freedom from PNES.

Patient 3

This patient had undergone previous epilepsy surgery one year before. At that time the motor cortex had been preserved in order to maintain functional integrity of motor pathways. However, after a short period of seizure freedom, seizures relapsed with identical semiology and pre-operative frequency. Extensive discussions with the patient and her mother, as the legal representative, led to the decision to proceed with FH and to consciously accept the consequence of a considerable deterioration of her hand function. After FH she remained seizure-free.

Prior to surgery the patient presented with left spastic hemiparesis, predominating over the lower limb and complete hemianopia. Neuropsychological evaluation revealed moderate cognitive impairment. Verbal recall and memory functions were more impaired than figural abilities. Following surgery she presented a transitory facial hemiparesis. Spastic left hemiparesis persisted with loss of the holding function hand.

Neuropsychological evaluation showed a slight improvement of attention and figural immediate recall. None of the neuropsychological parameters assessed deteriorated. Both the patient and her mother agreed that the individual improvement of the quality of life was dramatic, in spite of the almost complete paresis of the hand.

Patient 4

This severely mentally retarded patient suffered from a medically intractable non-convulsive status epilepticus and several motor seizures per day. Pre-operatively he showed a marked spastic hemiparesis of the right side

without fine motor abilities of the hand. Clinical findings suggested hemianopia although perimetric measurement was not reliably possible.

FH led to complete post-operative abolishment of seizures.

The post-operative EEG showed a reduction of interictal epileptiform discharges. Follow-up investigations after three months and one year suggested down-regulation of still recordable epileptiform activity. Prior to surgery, the patient had a relatively well preserved verbal perception but almost no spontaneous speech. He exhibited autism-like behaviour. Post-operatively, his attention ability and his verbal and non-verbal communication behaviour improved.

In spite of a further loss of hand function, the post-operative situation was judged by the relatives to be an extraordinary success. Pre- and post-operative MRI scans are shown in *figure 1*, video clips show the hand function prior to and after surgery with identical tasks during working therapy (*see video sequence*).

In summary, in all patients the motor and especially the hand function deteriorated post-operatively, and two patients who did not have a visual deficit pre-operatively developed complete homonymous hemianopia. In spite of these consequences, interviews with the relatives and three of the four patients clearly revealed that the quality of life of the patients and their families had improved dramatically. All four patients and their relatives emphasized that they were certainly in favour of FH.

Table 2 summarizes the post-operative outcome of the four patients.

Discussion

The main purpose of epilepsy surgery is to achieve seizure control without additional handicaps. The decision as to whether epilepsy surgery should be proposed has to be guided mainly by the careful weighing up of the individual risk-benefit ratio including the epilepsy-related impairment of the quality of life. Finally, one should keep in mind that epilepsy surgery aims to improve the quality of life and usually is not performed for vital indications.

Nevertheless, there may be situations where continuation of conservative antiepileptic drug treatment or additional therapeutic approaches such as vagal nerve stimulation are not able to change the situation of so-called catastrophic epilepsy at all, even in adulthood. Whereas for children with catastrophic epilepsies based on a well-defined aetiology harbouring severe hemiparesis, functional hemispherectomy is considered to be the therapeutic approach of choice, similar data and guidelines in adults are still lacking.

Table 2. Clinical, neurophysiological and neuroimaging post-surgical data and outcome.

	Patient 1	Patient 2	Patient 3	Patient 4
Complications of FH	Postoperative temporary headache, nausea and vomiting, myoclonic jerks right side, ataxia, complete recovery within weeks	Postoperative headache and fatigue, onset of somatoform psychogenic symptoms and PNES (see text)	No complications	Temporary headache and increased CSF pressure
Changes of neurological findings	Moderate deterioration of right leg muscle strength	No active extension of the fingers, flexibility of the shoulder reduced, almost complete hemianopia	Temporary facial hemiparesis, aggravated paresis of upper and lower extremities, loss of holding functions left hand	Marked deterioration of hand function, no fine motor skills preserved (see Video), slight improvement during the postoperative one-year follow-up
Changes of mental status	Deterioration of figural memory, not relevant for daily-life activities	Improvement of verbal memory, no further changes	Moderate attentional improvement, improvement of figural immediate recall, no deterioration	Attentional improvement, no deteriorations, markedly improved abilities of verbal and non-verbal communication
EEG	Continuous slow and flattening left hemisphere, infrequent slowing right hemisphere, no IEDs	Continuous slow and attenuation right hemisphere, Intermittent slow and single sharp waves, regional, left frontal, intermittent IEDs, regional, right temporal posterior, Last EEG recording: Continuous slow and attenuation right hemisphere, Intermittent slow, regional, left frontal	Continuous slow and attenuation, lateralized, right hemisphere, rare IEDs, regional, right frontal or parietal	Continuous attenuation and intermittent slow, lateralized, left hemisphere, IEDs, intermittent, regional left frontal and temporal, rare IEDs regional, right frontal, after 3 months and 1 year cessation of IEDs, only single left frontal spikes
MRI	Complete removal of temporal lobe, diffuse lesional defects occipital lobe, temporary small hygroma	Subdural hygroma with space occupying effect, stable over 2 years with several MRI controls	Removal of temporal lobe, disconnection of adjacent frontal and posterior cortex	Complete removal of temporal lobe, complete disconnection of adjacent frontal and posterior cortex
Seizure outcome	Engel Ia, Wieser 1	Postoperative PNES, meanwhile complete seizure freedom Engel Ia, Wieser 1	Engel Ia, Wieser 1	Engel Ia, Wieser 1
Follow-up and comments	35 months, Considerable improvement of quality of life witnessed by the patient and his relatives	29 months, Reintegration in working life, clear improvement of personal quality of life under the conditions of permanent psychotherapy	16 months Considerable improvement of quality of life witnessed by the patient and her mother	13 months, Considerable improvement of quality of life witnessed by the patient and his relatives

MRI: magnetic resonance imaging; IEDs: interictal epileptiform discharges; PNES: psychogenic non-epileptic seizures; CSF: cerebrospinal fluid.

For all four cases, reluctance to perform FH would have resulted in definite continuation of drug-resistant epilepsy syndromes with increased morbidity and mortality. In one patient (patient 3) the first surgical approach was aimed to preserve motor functions but failed to obtain noticeably epileptological improvement. Seizure relief was only achieved with FH, and both the patient and her mother post-operatively confirmed that they definitely agreed that FH was the right choice, even with the experience of the additional post-operative motor deficit. For the three other cases, the pre-surgical clinical, EEG and imag-

ing data, in line with the underlying aetiologies (two cases of large perinatal infarctions and one case of Rasmussen's encephalitis), indicated a more aggressive or less selective surgical procedure, in order to obtain potential seizure relief. Therefore, the conclusion of our case conference was either to proceed with FH or not to offer epilepsy surgery. Moreover, the large lesions in two of the three remaining patients would have prevented us placing invasive EEG electrodes, in order to obtain more information of potentially more distinctive and removable epileptogenic lesions.

From our experience, it is absolutely essential to inform patients and relatives extensively about the probable sequelae of FH. It is certainly not useful to speculate about the possibility of the less aggressive alternative of multilobar resections, which in our third patient, did not lead to any worthwhile improvement and ultimately resulted in FH that was successful. From our experience, we clearly advocate the surgical procedure with the best possible seizure outcome in such catastrophic cases, as are reported here. The fact that there were no major complications in our series supports this opinion. We therefore conclude, in line with a larger retrospective series of adults who even partially underwent traditional FH (McClelland and Maxwell, 2007), that the risk-benefit ratio appears to be similar to that of children.

An interesting additional finding in this case series is that one patient developed psychogenic non-epileptic seizures after a seizure-free post-operative period. In order to identify the nature of these post-operative events it was essential to perform another long-term video-EEG to discuss this diagnosis clearly both with the patient and the relatives and to initiate regular psychotherapeutic care. This case also underscores the considerable interference of severe and active epilepsy with the sociobiographic interactions and daily life activities in these patients.

The video sequence clearly demonstrates the deterioration of the hand motor function in patient 4. However, one has to point out that surgery did not result in complete hemiplegia. The post-operative follow-up revealed that our patients became more and more accustomed to the additional deficit. This process was supported by regular physiotherapy. Whether or not additional partial recovery will occur in time due to brain plasticity mechanisms in adults, as previously described in children (Van Empelen *et al.*, 2004; Schropp *et al.*, 2006), cannot be definitively determined at this moment.

We conclude that as a result of a multidisciplinary group analysis functional hemispherectomy is a possible surgical option in cases with catastrophic epilepsies in adulthood. Patients and relatives should consider that the probable loss of an already pre-operatively impaired hand function may be outweighed by the chance of seizure relief after FH. □

Acknowledgments.

MRI scans were performed by Matthias Bacher, M.D., and Peter Martin, M. D. Werner Butzkies recorded the video clips during work therapy. These contributions are gratefully acknowledged.

Disclosures.

None.

Legend for video sequence

Patient No. 4 prior to and after functional hemispherectomy of the left hemisphere. The video clips show him during working therapy performing identical tasks.

References

- Binder DK, Schramm J. Transsylvian functional hemispherectomy. *Child Nerv Syst* 2006; 22: 960-6.
- Cross JH. Epilepsy surgery in childhood. *Epilepsia* 2002; 43 (Suppl. 3): 65-70.
- de Almeida AN, Marino Jr R. The early years of hemispherectomy. *Pediatr Neurosurg* 2005; 41: 137-40.
- de Bode S, Firestone A, Mathern GW, Dobkin B. Residual motor control and cortical representations of function following hemispherectomy: effects of etiology. *J Child Neurol* 2005; 20: 64-75.
- Engel Jr J. Update on surgical treatment of the epilepsies. Summary of the Second International Palm Desert Conference on the Surgical Treatment of the Epilepsies (1992). *Neurology* 1993; 43: 1612-7.
- Engel Jr J, Van Ness PC, Rasmussen TB, Ojemann LM. Outcome with respect to epileptic seizures. In: Engel J, ed. *Jr. Surgical Treatment of the Epilepsies*. New York: Raven Press, 1993: 609-21.
- González-Martínez JA, Gupta A, Kotagal P, *et al.* Hemispherectomy for catastrophic epilepsy in infants. *Epilepsia* 2005; 46: 1518-25.
- McClelland 3rd S, Maxwell RE. Hemispherectomy for intractable epilepsy in adults: the first reported series. *Ann Neurol* 2007; 61: 372-6.
- Rasmussen T. Hemispherectomy for seizures revisited. *Can J Neurol Sci* 1983; 10: 1-8.
- Schramm J, Behrens E, Entzian W. Hemispherical deafferentation: an alternative to functional hemispherectomy. *Neurosurgery* 1995; 36: 509-15.
- Schramm J, Kral T, Clusmann H. Transsylvian keyhole functional hemispherectomy. *Neurosurgery* 2001; 49: 891-900.
- Schropp C, Sörensen N, Krauss J. Early periinsular hemispherotomy in children with Sturge-Weber syndrome and intractable epilepsy – outcome in eight patients. *Neuropediatrics* 2006; 37: 26-31.
- Van Empelen R, Jennekens-Schinkel A, Buskens E, Helders PJ, van Nieuwenhuizen O. Dutch Collaborative Epilepsy Surgery Programme. Functional consequences of hemispherectomy. *Brain* 2004; 127: 2071-9.
- Wieser HG, Blume WT, Fish D, *et al.* Commission on Neurosurgery of the International League Against Epilepsy (ILAE). ILAE Commission Report: Proposal for a new classification of outcome with respect to epileptic seizures following epilepsy surgery. *Epilepsia* 2001; 4: 282-6.