

Frontal lobe epilepsy manifesting with seizures consisting of isolated vocalization

Ricardo Rego¹, Stephan Arnold², Soheyl Noachtar²

¹ Neurology Service, Hospital Pedro Hispano, Matosinhos, Portugal

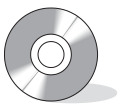² Dept. of Neurology, University of Munich, München, Germany

Received February 22, 2006; Accepted September 2, 2006

ABSTRACT – Vocalizations may occur in focal epileptic seizures, which typically arise from frontal and temporal regions. They are commonly associated with other motor phenomena such as automatisms, tonic posturing, or head version. We report on a patient whose seizures were documented by video-EEG monitoring, but in whom the observable ictal semiology consisted solely of a brief, monotonous vocalization. Ictal EEGs showed left frontal seizure patterns. Isolated vocalizations can constitute an ictal epileptic event and may be the only observable clinical manifestation of a left frontal lobe epilepsy.

[Published with video sequences]

Key words: seizure semiology, frontal lobe epilepsy, vocalization, frontal seizures



Correspondence:

S. Noachtar
Neurologische Klinik
Universität München
Marchioninistrasse 15
81377 München
Deutschland
Tel.: (+00 49) 089 7095 2685
Fax: (+00 49) 089 7095 5686
<Soheyl.Noachtar@med.uni-muenchen.de>

The 52-year-old, right-handed male underwent video-EEG evaluation of paroxysmal episodes that had occurred several times a day since he was 14 years old. These episodes were characterized as an involuntary production of a “groaning” sound, which at times was preceded by a feeling of unspecific “inner tension” and “tingling” throughout his whole body. They had previously been attributed to “nervousness”, but after a diagnosis of epilepsy was suggested in recent years, the patient received anti-epileptic treatment. The patient’s prior medical history included a possibly relevant, perinatal hypoxia. Neurological examination disclosed no abnormalities. The patient had previously undergone a high-resolution brain MRI (1.5 Tesla, 2 mm slices) including

T1-3D, T2 and FLAIR sequences, with normal results.

Video-EEG monitoring was performed after the withdrawal of anti-epileptic drugs (carbamazepine, sodium valproate, gabapentin, and levetiracetam). Interictal recordings showed a normal background rhythm with intermittent generalized slow activity; no interictal epileptiform discharges were recorded. Four identical seizures, recorded during one night, occurred during stage I sleep. They consisted of an arousal, followed by a monotonous vocalization lasting four to seven seconds (see video sequence). Upon testing, the patient was fully responsive. He reported having had his usual aura (diffuse “inner tingling”) immediately before the vocalization. A seizure pattern (fast rhythmical activity) was

consistently recorded over the left frontal region, starting two to four seconds before the vocalization and lasting three to five seconds (*figure 1*).

Further investigations, such as invasive EEG or functional imaging, were not performed since epilepsy surgery was not contemplated (seizure control was satisfactory under medical treatment).

Discussion

Pure ictal vocalizations have been recently defined as audible sounds that lack speech quality and do not accompany apnea or clonic or generalized tonic-clonic seizures (Janszky *et al.* 2000). In a review of 27 patients with frontal lobe epilepsy, confirmed by pre-surgical evaluation and seizure-freedom after frontal lobe resections, ictal vocalizations occurred during different seizure types (more frequently tonic) in 11 patients. Those patients with left-sided frontal foci, as the ictal EEG suggests in our case, had ictal vocalizations significantly more often than patients with right-sided foci (75% *versus* 13%). Another report on a series of frontal lobe epilepsy patients, who

underwent resective epilepsy surgery (Laskowitz *et al.* 1995), noted ictal vocalizations (less stringently defined as a "phonation of any kind") during the seizures of approximately two-thirds of the patients; however, an association between vocalization and lateralization was not found.

In a study of the different speech manifestations during seizures that arise from temporal regions, Gabr *et al.* (1989) observed ictal vocalizations, defined as sustained or interrupted sounds with no speech quality, during the seizures of almost half of the patients. There was a non-statistically significant trend toward seizures originating in the dominant temporal lobe. Ictal speech however, and positictal aphasia showed a significant association with seizure-onset in the non-dominant and dominant hemisphere, respectively (Gabr *et al.* 1989).

Although the gold standard for focal epilepsy classification is post-surgical seizure-freedom after a focal resection, we feel that a diagnosis of frontal lobe epilepsy in our patient is supported by the clear left frontal ictal EEG and by the clinical features. He had clusters of brief seizures arising from sleep, with preserved responsiveness, as is frequently seen in frontal lobe epilepsies; furthermore, auras with a

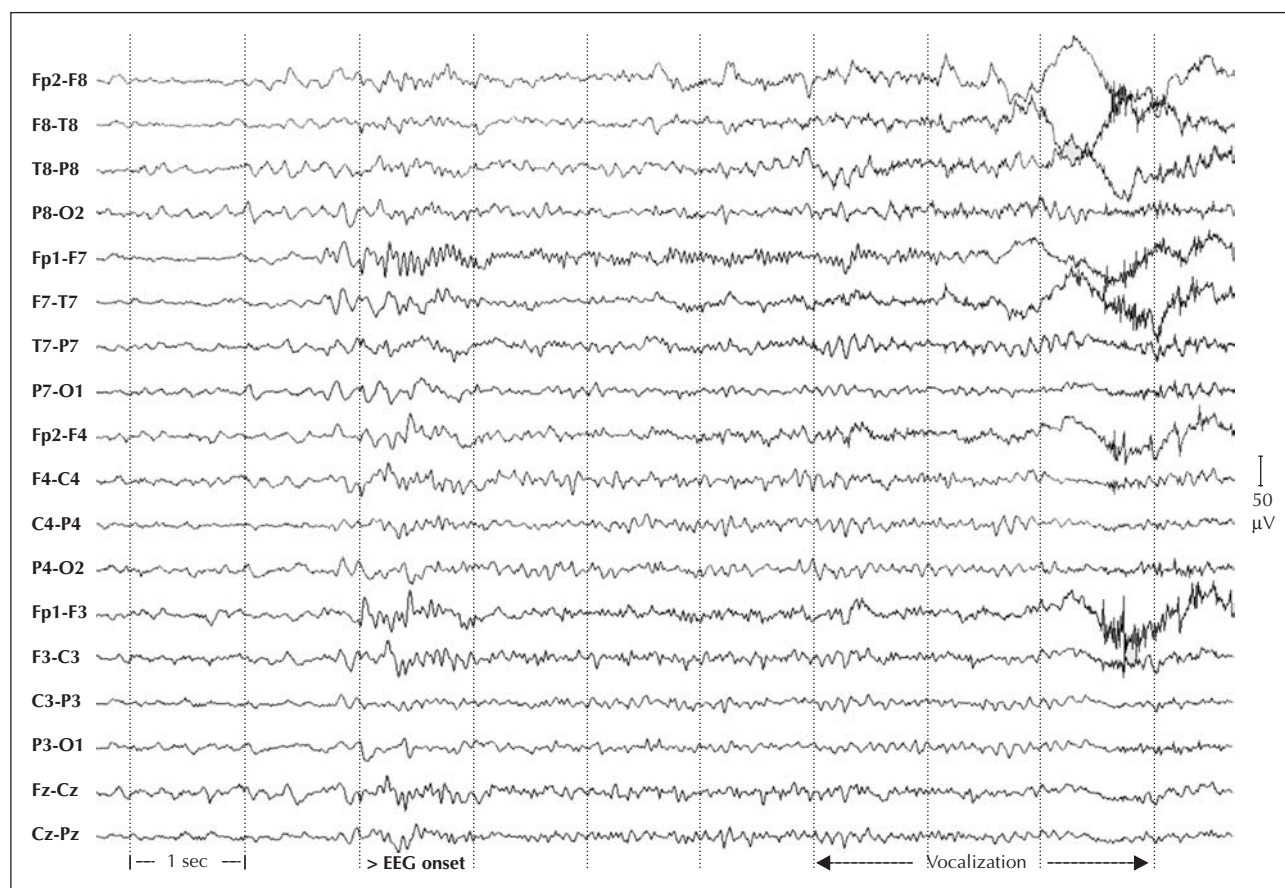


Figure 1. Seizure pattern consisting of fast rhythmical activity over the left fronto-polar area (channels Fp1-Fp7 and Fp1-F3), starting 3.5 seconds before the vocalization.

diffuse “tingling” or “tension” sensation and tonic vocalizations are common during the early phase of seizures originating or spreading to the supplementary sensorimotor area, which may then evolve rapidly into a bilateral asymmetric tonic seizure (Kellinghaus and Lüders, 2004).

In our patient, ictal vocalizations repeatedly occurred as the single objective manifestation of epileptic seizures arising from the left frontal lobe. To the best of our knowledge a similar finding has not yet been reported. □

Legend for video sequences

Two of four similar recorded seizures, each of them showing in sequence: arousal, monotonous vocalization, full responsiveness upon testing, and description of a preceding unspecific aura (“tingling” of the whole body).

Acknowledgements. The authors wish to thank the EEG-technicians of the Epilepsy Monitoring Unit of the University of Munich hospital for their skill and support as well as Mrs. Judy Benson for copy editing the manuscript.

References

- Gabr M, Lüders H, Dinner D, Morris H, Wyllie E. Speech manifestations in lateralization of temporal lobe seizures. *Ann Neurol* 1989; 25: 82-7.
- Janszky J, Fogarasi A, Jokeit H, Ebner A. Are ictal vocalisations related to the lateralisation of frontal lobe epilepsy? *J Neurol Neurosurg Psychiatry* 2000; 69: 244-7.
- Kellinghaus C, Lüders HO. Frontal lobe epilepsy. *Epileptic Disord* 2004; 6: 223-39.
- Laskowitz DT, Sperling MR, French JA, O'Connor MJ. The syndrome of frontal lobe epilepsy: characteristics and surgical management. *Neurology* 1995; 45: 780-7.