

# Fixation-off sensitivity in epilepsies other than the idiopathic epilepsies of childhood with occipital paroxysms: a 12-year clinical-video EEG study

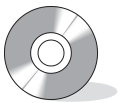Michail Koutroumanidis, Katerina Tsatsou, Sue Sanders, Michael Michael, Stella V. Tan, Alexandros Agathonikou, Chrysostomos P. Panayiotopoulos

Department of Clinical Neurophysiology and Epilepsies, Guy's & St. Thomas' NHS Foundation Trust, London, UK

Received August 4, 2008; Accepted November 30, 2008

**ABSTRACT – Purpose.** To define the spectrum of the epileptic syndromes and epilepsies (other than the idiopathic epilepsies of childhood with occipital paroxysms) that can be associated with fixation-off sensitivity (FOS), delineate the electrographic types of FOS abnormalities and identify the patterns that can be associated with clinical seizures, and examine whether there may be a pure form of fixation-off sensitive epilepsy. **Methods.** We reviewed the clinical and video EEG data of all our patients with FOS over the last 12 years. Children with idiopathic focal epilepsies and occipital EEG paroxysms were excluded. **Results.** From January 1995 to December 2006, 19 of about 8,500 patients had had one or more video-EEGs with FOS, yielding an approximate incidence of 0.2%. From the 14 patients with full clinical and EEG data available, 12 had various epilepsies that included IGE phenotypes (7), symptomatic or probably symptomatic focal (3), cryptogenic generalised (1), and adult onset idiopathic photosensitive occipital (1), and two had no seizures. Seven patients (50%) were photosensitive. FOS EEG abnormalities were occipital in six patients, generalised in eight, and generalised with posterior emphasis in two patients. Seven of these patterns were associated with habitual seizures in seven patients, but actual FOS-induced seizures (absences) were documented with video EEG in only one patient; three others had some historical evidence suggesting that, under some circumstances, their FOS EEG abnormalities might generate clinical seizures. **Conclusions.** Despite the association of FOS with generalised and focal, symptomatic and cryptogenic and mild or pharmaco-resistant epilepsies, closer analysis of our data, and supportive evidence from functional imaging and physiological observations on alpha rhythm generation, disclose a prominent role of the occipital areas, even when FOS EEG abnormalities and seizures are ostensibly generalised. Although FOS appears to be of relatively low epileptogenicity, an electroclinical profile of pure FOS epilepsy may exist [*Published with video sequences*].

**Key words:** fixation-off sensitivity, photosensitivity, eye closure paroxysms, eyes closed paroxysms, epilepsy, video EEG



**Correspondence:**

M. Koutroumanidis, MD  
Department of Clinical Neurophysiology  
and Epilepsies,  
Lambeth Wing, 3rd floor,  
St Thomas' Hospital,  
London SE1 7EH, UK  
<michael.koutroumanidis@gstt.nhs.uk>

Visual fixation brings the images of a *bright* object of interest on to the area of the retina where the resolution of the visual field is highest (the foveae of the two eyes), and maintains them there. Both aspects, the response to the peripheral stimulus and the maintenance of fixation, are mediated by the same basic mechanism (Kristjánsson 2007): the eyes move with small ballistic movements (saccades), so that the images approach the foveae, and the required nervous response becomes maximal when fixation is achieved or needs to be maintained. Fixation may be voluntary (when we plan to direct our gaze to an object of interest) or involuntary in response to something that catches our attention (visual motor grasp reflex) (Munoz and Everling 2004), but even so, fixation involves awareness, and therefore is classed as a psycho-optical reflex.

Most people with visually-provoked seizures and visually-sensitive epilepsies are photosensitive, pattern-sensitive or both, but there are few reported patients with seizures that occur when their eyes are closed or when their central vision becomes compromised, for example when they enter a dark room. There may be several mechanisms involved, either independently, such as sensitivity to darkness (Pazzaglia *et al.* 1970; Beaumanoir *et al.* 1989) or possibly to proprioceptive triggers (Rafal *et al.* 1986), or perhaps in combination, but amongst them, loss of fixation is a principal, well defined and autonomous trigger (Panayiotopoulos 1998).

The term fixation-off sensitivity (FOS) was coined by Panayiotopoulos to denote the forms of epilepsy or EEG abnormalities or both, which are elicited by elimination of central vision and fixation (Panayiotopoulos 1987b). FOS was first documented in four children with occipital paroxysms (two had what is now known as Panayiotopoulos syndrome (PS), one had idiopathic childhood occipital epilepsy of Gastaut and one symptomatic occipital epilepsy) (Panayiotopoulos 1981).

If, during a routine EEG, abnormalities are observed that consistently occur for as long as the eyes are closed and disappear when the eyes open then FOS might be suspected. Diagnosis may be confirmed by demonstrating that the same abnormalities also occur (or are activated) by impeding central vision and fixation using translucent, spherical lenses, underwater goggles covered with semitransparent tape, Frenzel lenses or Ganzfeld stimulation. FOS occurs mainly in children with idiopathic epilepsies with occipital paroxysms (Gastaut type), and PS when occipital paroxysms occur (Camfield *et al.* 1978, Panayiotopoulos 1980, Panayiotopoulos 1981, Gastaut 1982, Beaumanoir 1983, Newton and Aicardi 1983, Cirignotta *et al.* 1987, Panayiotopoulos 1987a, Ferrie *et al.* 1997, Panayiotopoulos 1998, Martinovic 2001, Panayiotopoulos, 2007a). There are only rare case reports of patients with FOS and other epilepsies that appear to include symptomatic or cryptogenic focal

(Panayiotopoulos 1981, Martinovic 2001, Kurth *et al.* 2001, Iannetti *et al.* 2002) and generalised epilepsies (Gumnit *et al.* 1965, Panayiotopoulos 1979, Lugaresi *et al.* 1984, Panayiotopoulos 1987b, Barclay *et al.* 1993, Agathonikou *et al.* 1997, Agathonikou *et al.* 1998). There are even reports of non-epileptic children (Herranz Tanarro *et al.* 1984, Beaumanoir and Grandjean 1987) and adults (Krakow *et al.* 2000) with FOS.

We reviewed our EEG database to find all patients with video-EEG-documented FOS and epilepsies other than the benign idiopathic focal epilepsies of childhood with occipital paroxysms, who had been seen and followed up in our department between January 1995 and December 2006, aiming to: a) define the spectrum of the epileptic syndromes and epilepsies that can be associated with FOS; b) explore the electrographic types of FOS abnormalities and identify any particular patterns that could generate clinical seizures; c) examine whether there may be a pure form of fixation-off sensitive epilepsy.

## Patients and methods

Our methodologies for studying patients with epilepsies, and the setup of our epilepsy clinic and EEG department at St Thomas' Hospital, have been described elsewhere (Koutroumanidis *et al.* 2008). Briefly, a detailed history including different types of seizure, their clinical manifestations and age-at-onset, frequency and circadian distribution, precipitants and possible reflex phenomena, as well as causative factors and family history, is routinely obtained in the initial assessment, and all patients undergo a routine or sleep video-EEG after partial sleep deprivation, tailored to the clinical information. To increase their diagnostic yield, video-EEGs are appropriately activated in patients with evidence of seizure precipitants, such as photosensitivity, pattern-sensitivity, video game, or fixation-off sensitivity, or sensitivity to reading or other linguistic activities, calculations and other triggers. When IGE is suspected, sleep EEGs are extended by prolonged recording on awakening, activated by one or multiple sessions of hyperventilation and specific triggers as indicated by history. Repeat video EEG recordings supplement the clinical follow-up according to the individual clinical needs.

When "eye-closure" or "eyes closed" EEG epileptiform abnormalities are suspected from the early stages of an EEG recording, a specific protocol is applied that includes several "eye closures" in the normally lit environment and in complete darkness, and multiple and sometimes long trials of recording with the eyes open and closed, using translucent spherical lenses (that distort light refraction and therefore fixation), underwater goggles fitted with semitransparent tape (that also impede fixation without significantly reducing the incoming light) or Ganzfeld stimulation (that has long been shown to activate alpha rhythm,

**Table 1.** Patients with FOS: clinical characteristics and MRI findings.

| Pts/<br>Gender | Age<br>(yrs) | Onset<br>(yrs) | Diagnosis/aetiology  | Seizure types (history)  | Seizures (video-EEG)               | Brain MRI                          | AED   | Follow-up | Outcome   |
|----------------|--------------|----------------|--|--|------------------------------------|------------------------------------|---|-----------|---|
| 1 / F          | 24           | 14             | Symptomatic right OLE/cortical dysplasia                           | Focal ("vagueness", hazy vision → unresponsive)<br>Focal → sec GTCS  | Both types; also brief oculoclonic | Right occipital cortical dysplasia | All available AED; currently on CBZ, CLB, TPM                           | 5         | Intractable   |
| 2 / M          | 9            | 4              | Multifocal cryptogenic epilepsy (occipital and temporal)/uncertain | Focal 1: brief; blinks, no obvious loC<br>Focal 2: longer; stares, unresponsive, head drooping                           | Both types                         | Normal                             | All available AED including steroids; currently on multiple AED and VNS | 5         | Intractable   |
| 3 / F          | 29           | 6              | Symptomatic TLE (left?)/viral meningitis, age 1                    | Focal (cephalic sensation → vacant)<br>Focal → sec GTCS  | Not recorded                       | Normal                             | CBZ   | 4         | Infrequent focal seizures and sec GTCS                            |
| 4 / F          | 18           | 8              | Lennox-Gastaut syndrome/uncertain                                  | Focal (right motor), ATA, tonic, atonic, atypical ASE  | ATA, tonic, atonic, atypical ASE   | Normal                             | All available AED, including steroids                                   | 10        | Intractable   |
| 5 / F          | 20           | 18             | Photosensitive OLE / idiopathic                                    | Focal (visual) → sec GTCS (two in total)   | Not recorded                       | Normal                             | None  | 2         | Seizure-free  |
| 6 / F          | 43           | 10             | IGE (ELMA)   | TA<br>GTCS   | TA                                 | Normal                             | VPA, LTG  | 10        | Infrequent TA   |
| 7 / M          | 48           | 40             | IGE  | 3 photoically induced GTCS at 40, 41 and 43 years. Also, infrequent photoically induced focal seizures NCSE?             | Not recorded                       | Normal                             | VPA   | 6         | Occasional photoically-induced focal seizures                     |
| 8 / F          | 18           | 8              | IGE  | TA (2 distinct types): long spontaneous and brief on eye closure   | Both types of TA                   | Normal                             | VPA, LTG  | 10        | Infrequent TA   |
| 9 / M          | 16           | 7              | IGE  | Pyknoelectric brief TA<br>Myoclonic jerks<br>Single GTCS   | TA<br>MJ                           | Normal                             | VPA   | 3         | Monthly MJ and brief TA   |
| 10 / F         | 44           | 13             | IGE  | TA<br>Catamenial ASE<br>GTCS   | TA<br>ASE                          | Normal                             | VPA, LTG  | 12        | Seizure-free for the last seven years                             |
| 11 / F         | 45           | 5              | IGE  | TA associated with 3Hz SW but also with fast rhythms<br>Catamenial ASE<br>Nocturnal GTCS                                 | Both types of TA<br>ASE            | Normal                             | VPA, CLZ, LTG   | 12        | Infrequent TA, rare ASE   |
| 12 / F         | 21           | 14             | IGE  | Eyelid flicker on eye closure without loC<br>Monthly vacant attacks from sleep, with throat "clicking"<br>Nocturnal GTCS | Eye flickers                       | Normal                             | VPA, LTG, LEV, CLB, TPM   | 7         | Monthly vacant episodes from sleep<br>3-4 nocturnal GTCS per year |
| 13 / F         | 20           | 9*             | No seizures (asymptomatic occipital photosensitivity)              | N/A  | N/A                                | Normal                             | none  | 11        | N/A   |
| 14 / M         | 27           | N/A            | No seizures  | N/A  | N/A                                | Normal                             | none  | 3         | N/A   |

OLE: occipital lobe epilepsy; loC: impairment of consciousness; GTCS: generalised tonic clonic seizure; AED: antiepileptic drugs; VPA: sodium valproate; LTG: lamotrigine; CBZ: carbamazepine; CLB: clobazam; CLZ: clonazepam; TPM: topiramate; VNS: vagus nerve stimulation; TLE: temporal lobe epilepsy; ATA: atypical absences; NCSE: non-convulsive status epilepticus; IGE: idiopathic generalised epilepsy; ELMA: eyelid myoclonia with absences; TA: typical absences; ASE: absence status epilepticus; \* refers to symptoms that were never proved to be epilepsy-related (see text).

**Table 2.** EEG features of the 14 patients with FOS.

| Pts | Interictal EEG   | Ictal EEG   | FOS inter-ictal abnormalities  |                                    | Effect of drowsiness/<br>sleep on FOS | Photosensitivity  |
|-----|--|---|--|------------------------------------|---------------------------------------|---|
|     |  |   | Pattern  | Relevance to seizures <sup>†</sup> |                                       |   |
| 1   | Continuous R occipital spiking   | Disappearance of spikes for one second, then rhythmic fast over T6 and O2. Eye blinks with rhythmic R occipital spikes  | Occipital (unilateral)   | Yes <sup>#</sup>                   | No change                             | No  |
| 2   | R occipital paroxysms with variable diffusion to the mid-temporal and contralateral areas<br>Polymorphic R temporal slowing              | Type 1: Momentary disappearance of occipital spikes, then brief bilateral bursts of occipital spikes (R > L) concurrent with ocular phenomena<br>Type 2: build up of beta / sharp theta and delta over right anterior to mid-temporal | Occipital (unilateral)   | Yes                                | No clear change                       | No  |
| 3   | Diffuse bilateral bursts of high voltage sharp waves<br>Polymorphic L temporal slowing   | Not recorded  | Generalised  | No <sup>*</sup>                    | Not possible to test                  | No  |
| 4   | Slow background with multifocal spikes<br>Slow GSW   | Slow GSW during ATA<br>Fast rhythms during tonic seizures<br>Continuous slow GSW pattern during NCSE  | Generalised  | Yes                                | Not possible to test                  | No  |
| 5   | Diffuse bilateral bursts of irregular SW with posterior max  | Not recorded  | Generalised with posterior emphasis  | No <sup>**</sup>                   | Not possible to test                  | Generalised PPR with posterior emphasis                                   |
| 6   | Generalised bursts of fast activity mixed with GSW.<br>Posterior fast rhythms on eye closure   | 4-3Hz generalised spike/polyspike wave  | Generalised  | Yes                                | "Drop out"                            | Generalised PPR   |
| 7   | Generalised bursts of fast activity mixed with GSW.  | Not recorded  | Generalised  | No <sup>**</sup>                   | "Drop out"                            | Generalised PPR   |
| 8   | Regular 3 Hz GSW<br>Bilateral bursts of polyspikes on eye closure<br>Bilateral posterior delta with spikes, sometimes spreading forwards | TA with 3 Hz GSW<br>TA with bilateral bursts of fast rhythms/polyspikes on eye closure, associated with eyelid myoclonia  | Occipital (bilateral)  | No <sup>***</sup>                  | "Drop out"                            | Generalised PPR   |
| 9   | Repetitive brief GSW   | 3 Hz GSW  | Generalised  | Yes <sup>#</sup>                   | "Drop out"                            | Generalised PPR   |
| 10  | 2.5-3 Hz GSW   | 2.5-3 Hz GSW  | Generalised  | Yes                                | "Drop out"                            | No  |
| 11  | Repetitive generalised bursts of fast rhythms intermixed with spikes<br>3 Hz GSW   | TA mainly associated with generalised fast (tonic) movements of eyelids<br>TA associated with 3 Hz GSW without prominent eyelid manifestations  | Generalised (both types of discharge)  | Yes                                | "Drop out"                            | No  |
| 12  | Eye closure GSW<br>GSW ± occipital predominance<br>Bilateral occipital spikes/polyspikes   | Eye closure GSW with eyelid flicker. Also Generalised PPR associated with body jerks  | Occipital (bilateral)  | No <sup>#</sup>                    | Not possible to test                  | Generalised PPR between 12 and 30 Hz.<br>Inhibition of FOS by IPS < 12 Hz |
| 13  | Bilateral synchronous occipital spikes<br>GSW with posterior emphasis  | N/A   | Occipital (bilateral)<br>Generalised with posterior emphasis (both types of discharge) | No                                 | Not possible to test                  | Occipital photosensitivity and generalised PPR with posterior emphasis    |
| 14  | Bilateral occipital spikes<br>Brief GSW  | N/A   | Occipital (bilateral)<br>Generalised (both types of discharge)                         | No                                 | "Drop out"                            | No  |

GSW: generalised spike-wave; ATA: atypical absences; TA: typical absences; PPR: photoparoxysmal response; NCSE: non convulsive status epilepticus.

<sup>†</sup> On video-EEG evidence.

<sup>#</sup> Additional suggestive evidence from history.

<sup>\*</sup> Focal seizures relate to coexistent probably symptomatic left temporal focus.

<sup>\*\*</sup> Focal seizures relate to coexistent occipital photosensitivity.

<sup>\*\*\*</sup> Typical absences relate to coexistent photosensitivity and also occurred spontaneously.

diffuse slow rhythms and spike-wave activity (Takahashi 1976) to assess for possible FOS, and opaque underwater goggles to assess sensitivity to complete darkness. Monocular blocking of visual fixation is performed by using a frame with only one translucent spherical lens. We diagnose FOS on the basis of the video EEG only when we can convincingly demonstrate that epileptiform abnormalities (spikes, spike wave or sharp wave focal, regional or generalized discharges) consistently occur when (and persist for as long as) central vision and fixation are blocked or compromised (*i.e.* when the eyes are closed, and open in complete darkness and in an adequately lit environment using goggles that produce refractive errors), and which disappear immediately upon visual fixation. In patients with significant learning or behavioural difficulties, who may not cooperate with long trials using different goggles, we employ a modified Ganzfeld stimulation (using a large, white surface without visual cues). Eye closed abnormalities that persist when the eyes are open in full darkness, but without testing for actual fixation-off may not be FOS, as pure forms of scotosensitivity may exist (Pazzaglia *et al.* 1970; Beaumanoir *et al.* 1989). Purely scotosensitive patients however, should not show EEG abnormalities when fixation is hampered by translucent spherical lenses, semitransparent goggles or Ganzfeld stimulation in adequate ambient light.

We studied the clinical and EEG features of all patients with FOS, obtained from comprehensive video EEG studies in our department according to the above principles and methodology, over a 12-year period. Only patients whose video EEG recordings had been stored and were available for review, and whose clinical notes were accessible, were included in the analysis.

## Results

From January 1995 to December 2006, 19 patients had one or more video-EEGs that were reported as showing FOS, but full clinical information and video EEG recordings were available for only 14 (*tables 1 and 2*). The five remaining patients were excluded from further analysis because either the pertinent EEG recordings that had documented FOS were not available for review, or important clinical information was missing. During the study period, 8 500 patients had had 10 100 EEG recordings in our department yielding for FOS an approximate incidence of 0.20% (considering epilepsies and seizures other than the idiopathic epilepsies of childhood with occipital paroxysms).

Ten women and four men, aged 9 to 48 years (mean 27.3, median 22.5) had 54 video EEG recordings (median 4, range 2 to 7), and were followed up from 2 to 12 years (mean 7.1, median 6). Twelve had epilepsy with seizure-onset from 4 to 40 years of age (average 12.25; median 8), and two had no seizures (patients 13 and 14, *tables 1 and 2*).

FOS was associated with the following epilepsies (*table 1*):

1. symptomatic or probably symptomatic focal (occipital and temporal) epilepsies (patients 1-3);
2. cryptogenic generalised epilepsy (patient 4);
3. idiopathic photosensitive occipital epilepsy of adult onset (patient 5);
4. various IGE phenotypes (patients 6-12);
5. non-epileptic conditions (patients 13 and 14).

The observed patterns of FOS EEG abnormalities in terms of cerebral topography were (*table 2*):

1. occipital in six patients (1, 2, 8, 12, 13 and 14);
2. generalised in eight (3, 4, 6, 7, 9-11 and 14);
3. generalised with posterior emphasis in two (5 and 13).

Of these, seven patterns of FOS-EEG abnormalities were similar to those associated with the habitual clinical seizures of seven patients, as these were shown on ictal video-EEG (*table 2*): these FOS patterns were occipital in patients 1 and 2, and generalised in patients 4, 6 and 9-11. Actual FOS-induced seizures (absences associated with fast rhythms and tonic eyelid movements) were documented with video EEG in only one patient (patient 11, *table 2*). In three more patients, some evidence from their history suggested that, under some circumstances, their FOS EEG abnormalities might also become clinically significant: patient 1 had more seizures during holidays than during college terms, patient 9 reported "fear" of small dark places, and patient 12 had seizures occurring only during sleep.

The clinical features of the 14 patients are summarized below and pertinent EEG findings are presented in *figures 1-8*.

## Patients

### Patient 1

This 24-year-old, right-handed student was born at 32 weeks with forceps, and spent two weeks on a special care baby unit. There are no other predisposing factors for epilepsy and there is no relevant family history. She started having seizures at the age of 14 years. Typically, she has a warning of "dizziness" or "vagueness" that may occur in isolation, is associated with blurred vision and may last up to 20 seconds. She then tries to "concentrate" to abort the seizure. She becomes vacant for a few minutes, and may suffer a secondary generalised convulsion. Her seizures are medically intractable and tend to occur three to four times per month on average. However, she reports generally fewer seizures during the college term, particularly around her exams, and more frequent seizures when living with her family during the school holidays. She was referred at age 19 years, and her first video EEG after partial sleep deprivation showed continuous



runs of right occipital spikes when her eyes were closed, attenuating or disappearing on eye opening. The blocking effect was rather incomplete before sleep, but complete after awakening. Further testing with translucent spherical lenses and completely dark goggles covered with opaque tape, demonstrated perseverance of the right occipital spikes when the eyes were open, whereas visual fixation abolished them completely (*figure 1*). The partial and fluctuating block of right occipital spikes before sleep was attributed to her inability to fixate because of tiredness and sleep deprivation (quite obvious on the video). Drowsiness and light slow sleep did not affect the occipital paroxysms (*figure 2, left*). These EEG findings were reproducible in her follow-up recordings. Brain MRI showed right occipital cortical dysplasia (*figure 2, right*). She currently averages two to four focal seizures per month (half are secondary generalised); attempts to fixate when she feels the warning (suggested to her after her EEG showed FOS), abort seizure evolution only occasionally.

#### Patient 2

This nine-year-old boy with congenital hypotonia, mild global developmental delay and medically intractable focal epilepsy, began having multiple, brief blinking/eye rolling episodes daily at age four years; more prolonged seizures consisting of staring, dribbling and head dropping appeared a year later. Prolonged multiple video EEG and scalp telemetry studies showed that his habitual, complex partial seizures arose from the right anterior to mid-temporal areas, whereas the blinking episodes were associated with bursts of more posterior spikes on the right side (*table 2*). Interictally, there was an ongoing, regional polymorphic slowing over the right mid-temporal area and bilateral posterior spike wave activity, more on the right; during drowsiness and light sleep, the occipital spikes did not change, and even increased over the right posterior quadrant in one of his EEGs. Co-operation was problematic, but several video EEG recordings consistently showed that interictal occipital paroxysms vanished whenever he was lured to fixate, but persisted for as long as his eyes were closed and also when his eyes were open, but he was either staring vacantly or his visual fixation was impeded by modified Ganzfeld stimulation; notably, the right, mid-temporal, slow activity did not respond to eye opening. The child was assessed for epilepsy surgery, but both MRI and FDG PET were non-contributory, and he is now receiving combined treatment with anti-epileptic drugs and vagus nerve stimulation.

#### Patient 3

This 29-year-old, right-handed woman with a history of viral meningitis in the first year of life had had generally well-controlled complex partial seizures with occasional secondary generalisation since the age of six years (*table 1*). EEGs at eight, 10, 12, 14 and 15 years of age

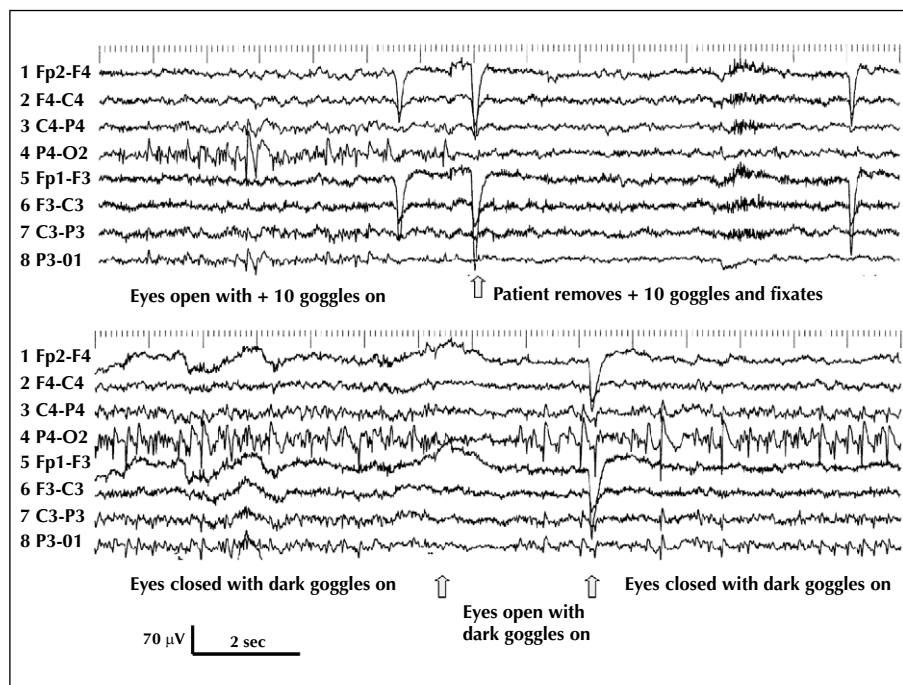
were reported as showing independent bilateral temporal abnormalities and generalised bursts of irregular sharp activity with variable side emphasis. Her brain MRI at age 28 years was unremarkable, and her video EEG showed left temporal runs of irregular slow activity and diffuse discharges of high voltage, sharp theta activity only when her eyes were closed, or open with elimination of visual fixation and in complete darkness (*table 2, figure 3*).

#### Patient 4

This 18-year-old, right-handed girl with Lennox-Gastaut syndrome and severe developmental delay had her first overt seizure - right focal motor with head deviation to the right - at age eight years. The first EEG in our department was performed at age nine years, while she was on lamotrigine (LTG) and carbamazepine (CBZ) and recorded atypical absence status associated with continuous diffuse spike-wave activity at around 1.5 Hz. A repeat EEG after discontinuation of CBZ showed that the bursts of slow spike-waves occurred when her eyes were closed, and in addition, with the eyes open only when staring at a featureless wall and white paper; she resisted testing with goggles, but the modified Ganzfeld effect was thought to be highly indicative of FOS. For the same reason, visual fixation was hard to sustain, but it seemed to eliminate the slow spike-wave discharges, at least temporarily. Follow-up video EEGs recorded tonic seizures, mainly during sleep, and atypical absences with progressive loss of muscle tone. She also had multiple episodes of non-convulsive status. Brain MRI scans at eight and 13 years were normal. She continues to have seizures, although less frequently than during the first years of her epilepsy.

#### Patient 5

This 20-year-old, right-handed woman with severe, chronic obsessive compulsive disorder, had two visually-induced seizures at age 18 years, one while watching TV at a close distance and another while reviewing a programme at a short distance from the screen in a production studio. On both occasions she experienced brief, visual hallucinations (yellow and blue circles and flickering fireworks in the centre of her visual field, coming towards her), and head deviation to the right, followed by fast secondary generalisation. Two video EEGs showed brief and asymptomatic bilateral bursts of slow waves intermixed with sharp waves and spikes with posterior emphasis only when the eyes were closed or open, but with the patient wearing translucent spherical goggles; these paroxysms disappeared on visual fixation. She also had generalised photoparoxysmal responses (PPR) between 16 and 30 Hz that showed posterior predominance. Neurological examination and intellect, and brain MRI were normal. She declined treatment and, following appropriate advice on how to prevent



**Figure 1.** (Patient 1) Continuous right occipital spiking when eyes are open and fixation is impeded by + 10 translucent goggles (left half of upper trace); spiking immediately disappears upon visual fixation (right half of upper trace). Ongoing right occipital spiking when the patient wears dark goggles (lower trace): eye opening temporarily blocks spiking, but spikes resume after one second despite the fact that eyes remain open (middle part of lower trace, in-between the two arrows). Note the diffusion of the spikes to the left occipital areas (HFF 70 Hz, TC 0.3 s).

visually-induced seizures, she remained seizure-free for two years after her second seizure, but thereafter she was lost to follow-up.

### Patient 6

This 43-year-old woman developed eyelid myoclonia with absences (ELMA) at age 10 and had experienced three GTCS evoked by flickering lights or TV (two at age 11 years and one at age 20 years). Her sister also has ELMA and her brother juvenile absence epilepsy. Sequential video-EEGs showed photoparoxysmal responses to intermittent photic stimulation, bilateral posterior fast rhythms at around 14 Hz (not harmonic with her alpha rhythm of 8.5-9 Hz) on eye closure that disappeared in complete darkness using opaque goggles, and diffuse sharp and spike wave discharges only when her eyes were closed, or open with impeded fixation. The FOS-related diffuse epileptiform discharges were better demonstrated after hyperventilation, and were reduced during light drowsiness along with the alpha rhythm “drop out”.

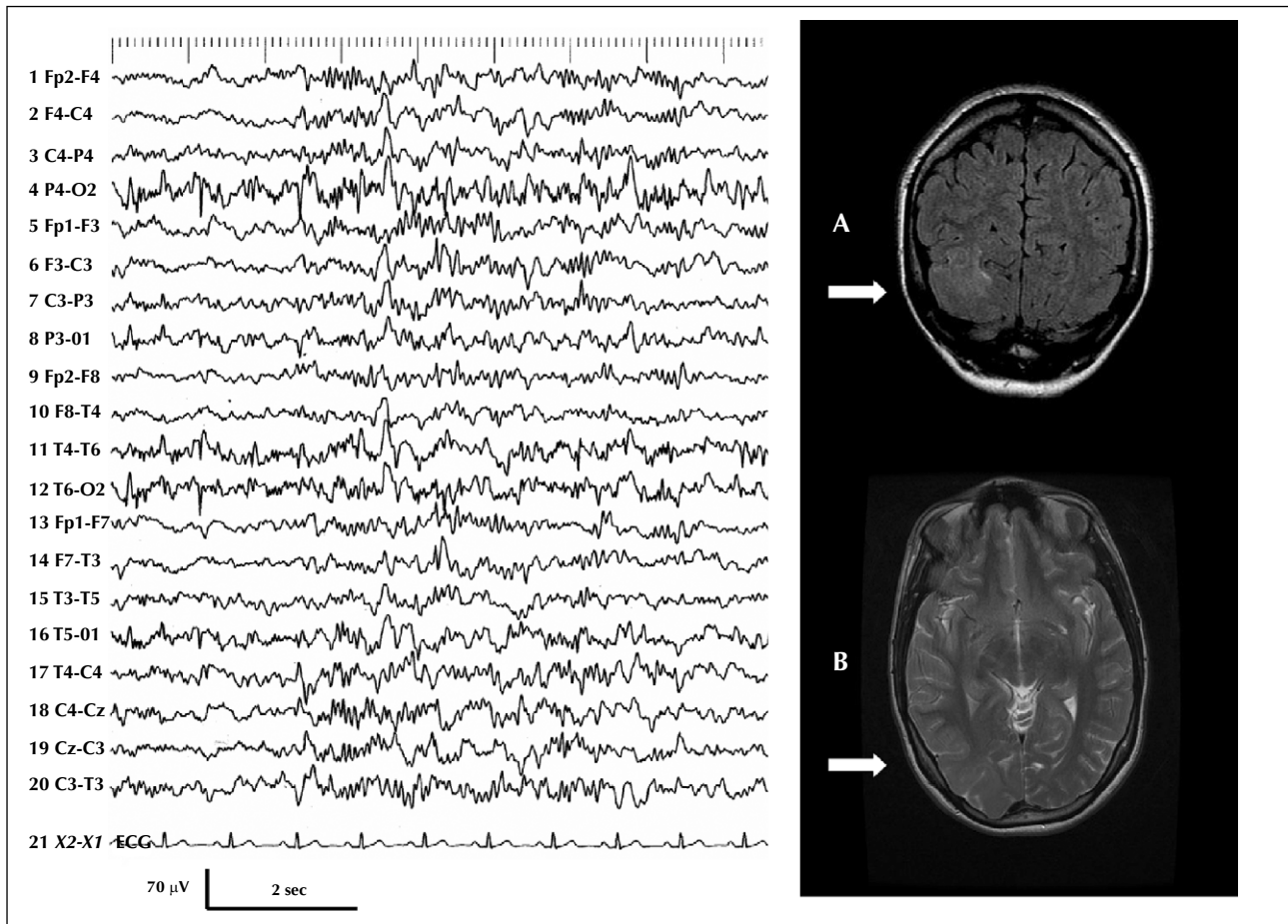
### Patient 7

This 48-year-old, right-handed man had experienced three photically-induced GTCS, at the ages of 40, 41 and 43 years. All occurred in the morning upon sudden

exposure to bright daylight, were preceded by a cephalic sensation, a feeling of dizziness, “wobbly legs” and a cluster of bilateral twitches, and had followed heavy alcohol consumption and poor sleep during the preceding nights. He also described brief episodes of dizziness as though he was going to faint when exposed to possible environmental light sources (crossing Waterloo bridge and watching the river on sunny days), that had started around that age. The last episode occurred at age 47, again on a sunny day, and lasted for 30 minutes, raising the possibility of non-convulsive status epilepticus. In addition, he described brief, myoclonic jerks mainly of the lower limbs, which also started after the age of 40 years and related to flickering lights. His video EEGs showed both photosensitivity and FOS. Fixation-off abnormalities were more obvious after hyperventilation and perhaps better formed in complete darkness than with semi-transparent goggles, and “dropped out” during light drowsiness.

### Patient 8

This is an 18-year-old, left-handed, student who, at age eight years, started having prolonged (10-20 sec) absences and brief episodes of eyelid myoclonus on eye closure that were sometimes associated with a brief impairment of awareness. Video-EEGs from that age showed generalised discharges of polyspike-wave complexes and runs of pos-



**Figure 2.** (Patient 1) Left: occipital spiking during stage II of sleep. Note that in contrast to the FOS related abnormalities in patients with idiopathic epilepsies that tend to attenuate during drowsiness along with the alpha rhythm dropout, occipital paroxysms here do not seem to have lost their vigour compared to wakefulness and they were also abundant during light drowsiness (HFF 70 Hz, TC 0.3 s). Right: brain MRI of patient 1. Coronal FLAIR (A) and axial T2 sequences (B) show a sizable dysplastic area with cortical thickening, blurred grey-white matter junction and faint cortical and subcortical T2 high signal in the right lateral occipital gyri (arrows).

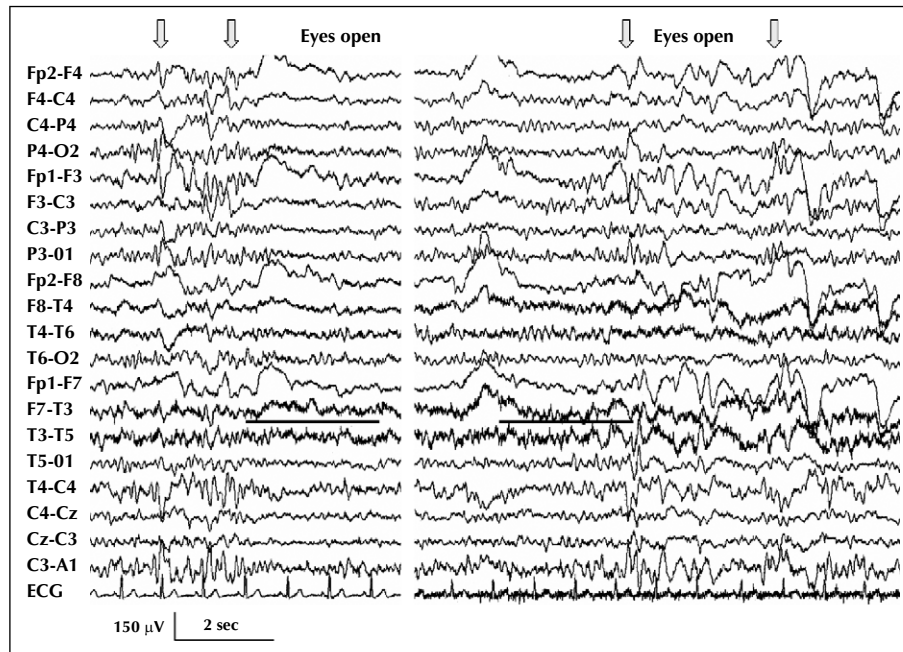
terior high voltage delta activity intermixed with spikes when her eyes were closed, disappearing on eye opening (figure 4, upper trace). There were also brief eye-closure paroxysms of polyspikes/polyspike-wave associated with eyelid myoclonus with or without impairment of awareness (figure 4, upper trace and figure 5, left upper trace) that were totally inhibited in complete darkness (figure 4, lower trace). She was highly photosensitive (figure 5, right upper trace). Long typical absences with profound impairment of awareness occurred either spontaneously when the eyes were open (figure 5, lower trace), or with eyes closed at rest or during hyperventilation, in which cases they were consistently preceded by rhythmic 3Hz posterior delta activity (OIRDA). Fixation-off-induced abnormalities became more obvious after hyperventilation that augmented generalised and posterior abnormalities, and were less evident during light drowsiness. She received treatment with valproate (VPA) and LTG, but

nine years after onset she continues to experience absences, albeit infrequently. She has never had a generalised convulsion or any other seizure apart from typical absences.

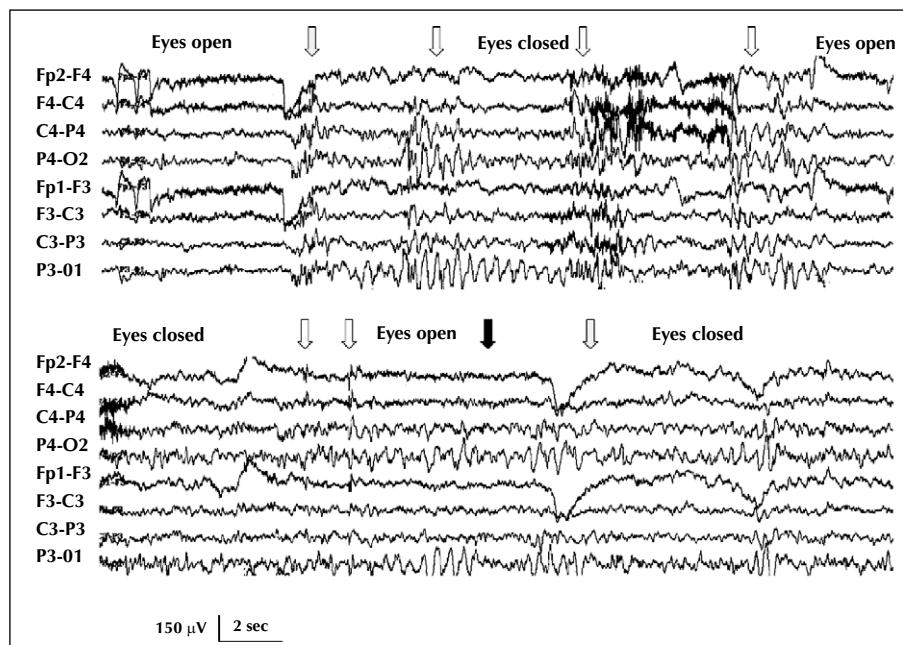
#### Patient 9

This 16-year-old boy has been described in detail elsewhere (Agathonikou *et al.* 1998). He presented at the age of seven years with brief, pyknoleptic absences and myoclonic jerks of the head and mainly the upper limbs that could occur during the absences or independently. His absences and jerks responded significantly to a combination of VPA and LTG, and he had only one GTCS after sleep deprivation having missed his medication. Sequential video EEGs showed photoparoxysmal responses and FOS. Fixation-off/on effects occurred immediately, or with a less than three second delay, and

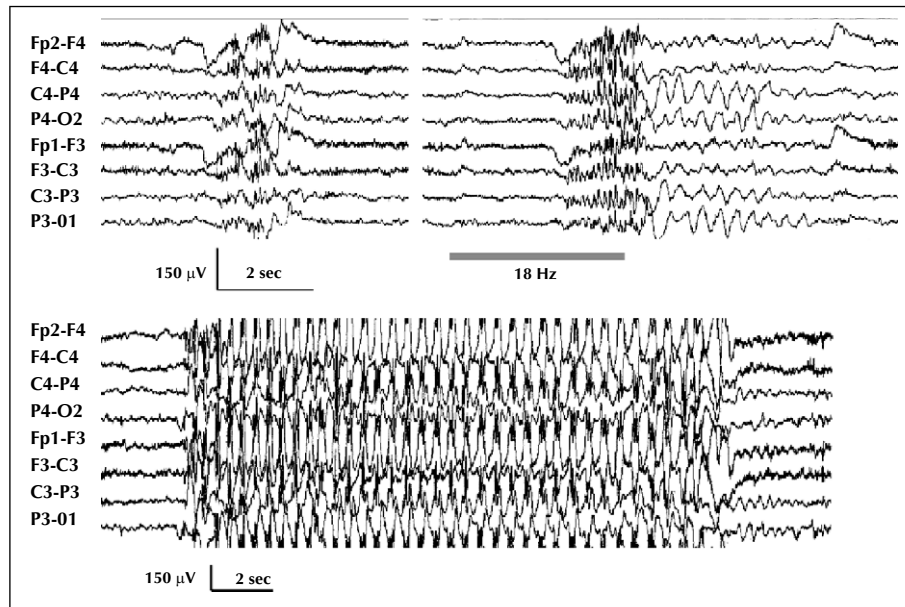




**Figure 3.** (Patient 3) Left trace: diffuse, bilateral bursts of high voltage sharp activity when eyes are closed (arrows), and polymorphic slow activity over the left temporal area that persists on eye opening (underlined). Bilateral sharp activity occurred only when eyes were shut, and was consistently inhibited by eye opening. Note also that eye opening completely blocks the alpha rhythm. Right trace: eye opening does not inhibit the bilateral bursts of sharp activity or the alpha rhythm when the patient wears semi-transparent goggles. Complete darkness (using opaque underwater goggles) also showed perseverance of the alpha rhythm on eye opening and diffuse bursts of sharp activity (HFF 70 Hz, TC 0.3 s).



**Figure 4.** (Patient 8) Top: “eyes closed”-related posterior high voltage 3-4 Hz delta rhythm with intermixed spikes and more generalised bursts of spike-wave activity (white arrows). Both block on eye opening. Note also the brief discharge of polyspike-waves that occur on eye closure (grey arrow). Bottom: the patient wears completely opaque goggles (absolute darkness). Both posterior high voltage delta rhythm (black arrow) and the generalised bursts of sharp activity (white arrows) now occur when eyes are open. Note that in complete darkness, the eye closure paroxysms disappear (grey arrow) (compare with top trace and also with figure 5; semi-transparent goggles had similar effects confirming FOS (HFF 70 Hz, TC 0.3 s).



**Figure 5.** (Patient 8) Top left: typical eye-closure paroxysms (ECP) of diffuse polyspike and wave that were consistently associated with eyelid myoclonia and variably with brief impairment of cognition. Top right: generalised photoparoxysmal response at 18 Hz associated with eyelid myoclonus. Bottom: Spontaneous typical absence when eyes were open. The regular 3 Hz spike-wave discharge starts with a bilateral burst of polyspike-wave and is associated with profound impairment of cognition, eyelid fluttering and minor automatisms. Similar long absences occurred with eyes closed, spontaneously or during hyperventilation, in which case they were preceded by a run of high voltage occipital rhythmic delta (OIRDA) (HFF 70 Hz, TC 0.3 s).

monocular elimination of visual fixation did not activate discharges. Fixation-off abnormalities were reduced concurrently with the alpha rhythm dropout during drowsiness, and enhanced after awakening and hyperventilation.

#### Patient 10

This 45-year-old woman has been presented elsewhere (Agathonikou *et al.* 1997). She started having absences at the age of 13 years that occurred in clusters every two to three weeks and were associated with eyelid flickering. She also suffered from prolonged (one to three days), catamenial episodes of absence status epilepticus (ASE), and had six generalised convulsions that either followed episodes of ASE or were associated with alcohol consumption; the first occurred at the age of 15 and the most recent at the age of 34 when she gave birth to twins. Video-EEGs have shown FOS generalised spike wave discharges that dropped out concurrently with alpha rhythm during drowsiness and increased on awakening and after hyperventilation. She has never been photosensitive. She has been seizure-free for the last eight years on VPA and LTG.

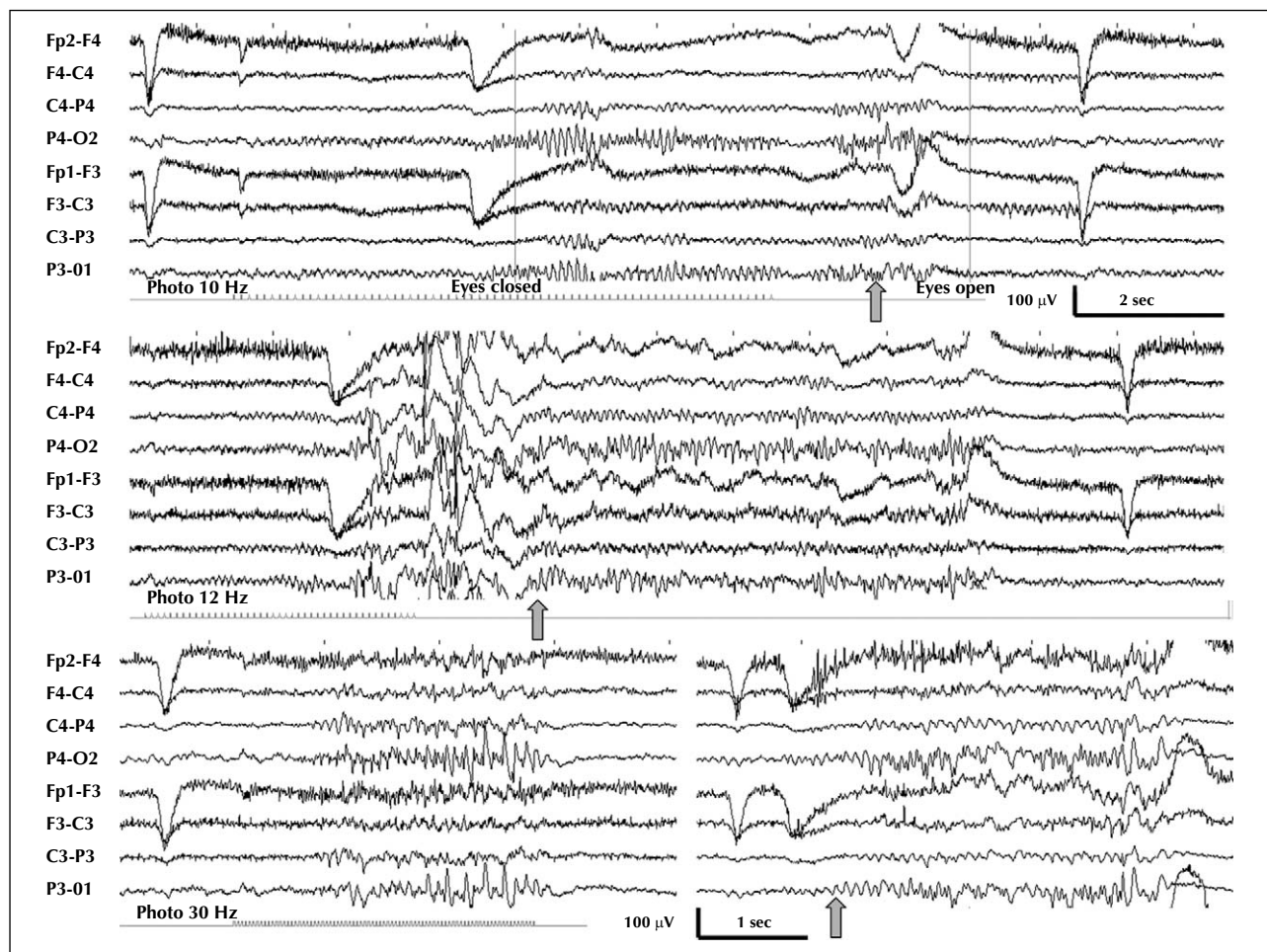
#### Patient 11

A 45-year-old woman of borderline intelligence was first seen in 1987 (Panayiotopoulos 1987b), and was followed up until 2000. She started having absences with abnormal

eyelid movements at the age of five years. She also had prolonged (two to seven days) episodes of absence status that occurred mainly pre-menstrually, and infrequent nocturnal generalised convulsions. Video EEGs have shown brief, generalised discharges of fast rhythms intermixed with spike-wave activity, and brief, generalised 3 Hz regular spike-wave discharges; both types showed FOS. The fast discharges were accompanied by clonic movements and tonic spasm of the eyelids and deviation of the eyes upwards and laterally. Neurological examination and brain MRI were normal. The patient was not photosensitive. FOS generalised spike wave discharges dropped out with alpha rhythm during drowsiness, and increased on awakening and after hyperventilation.

#### Patient 12

A 21-year-old woman started having brief episodes of eyelid flickering at the age of 14 years, usually on eye closure or when exposed to environmental lights including TV. From that age, and only when she is about to take an afternoon nap, she presents episodes in which she becomes unresponsive and emits characteristic clicking noises from her throat. These occur every one to three months and last for one to three minutes each time. Finally, she has had about 15 GTCS, all occurring during overnight sleep. Video EEGs at the ages of 14, 15 and 17 years showed bilateral occipital spikes, brief GSW discharges with



**Figure 6.** (Patient 12) Complex relationship between photosensitivity and FOS; the patient has been photosensitive since her first video EEG at the age of 14 years, and this video EEG at the age of 20 shows for the first time FOS that concerns her bilateral occipital needle-like spikes/polyspikes (right bottom trace, in which occipital spikes are associated with eye watering). The range of photosensitivity is from 30Hz (bottom left trace) to 12 Hz (generalized PPR of posterior onset in middle trace). Note that the latter is followed by FOS bilateral posterior spikes (their onset is marked by the grey arrow) that persist throughout the eyes-closed period. The possibility that the bilateral posterior spikes relate to eye closure and not to FOS is negated by the right bottom trace, in which there are no eye closure abnormalities and the posterior spiking starts one second after eye closure, also marked by a grey arrow. IPS at 10Hz (upper trace) or less appears to “suppress” the FOS posterior spiking, as this appears when IPS ceases and after a brief (0.5 sec) of electrical suppression (grey arrow) (HFF 70 Hz, TC 0.3 s).

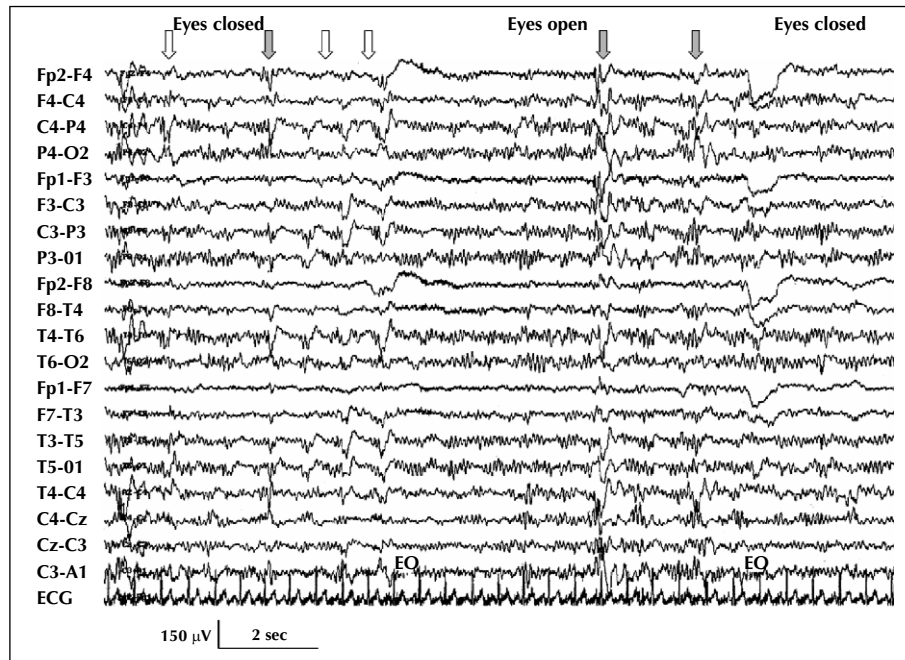
variable side emphasis, but usually of posterior predominance, eye closure abnormalities associated with eyelid flickering, and generalised photoparoxysmal responses associated with a single body jerk, or a sensation of a jerk. Her last EEGs at the age of 21 showed coexistence of FOS and photosensitivity (figure 6). Her seizures during sleep have been resistant to VPA, LTG, levetiracetam, topiramate and clobazam.

### Patient 13

This 20-year-old, right-handed girl was referred for EEG because of suspected complex partial seizures. She presented with uncontrollable, violent outbursts at the age of eight years, lasting from minutes to several hours, which

occurred only at home and never at school, and consisted of her being verbally abusive and physically violent to herself and others. These episodes gradually remitted and disappeared a few years later. There were no predisposing factors for epilepsy and she had no early convulsions or other seizures. Her first routine video EEG at the age of nine showed only occipital spikes on photic stimulation, and a follow-up video recording after partial sleep deprivation a month later showed brief subclinical, posteriorly predominant diffuse spike-wave discharges that occurred only during sleep, and eye closure abnormalities on awakening; she had a generalised photoparoxysmal response (PPR) at 18 Hz and photically provoked occipital spikes with other stimulus frequencies, but there was





**Figure 7.** (Patient 13) Bilateral posterior spike-wave bursts (white arrows) diffusing forwards (grey arrows) occur during eye-closed state (left and right parts of trace), and persist when eyes open but fixation is impeded using semi-transparent goggles (middle part of trace). Note also the persistence of the alpha rhythm throughout the “eyes open” period. The EEG normalised every time she opened her eyes and fixated (HFF 70 Hz, TC 0.3 s).

no evidence of FOS. A repeat EEG at the age of 13 showed predominantly posterior PPR between 20-30Hz and FOS (*figure 7*), and the final video EEG at the age of 17 showed only occipital photosensitivity. The patient never had symptoms when exposed to environmental sources of light or any other clinical evidence of epilepsy until her last clinical follow up at age 20 years, and has never received anti-epileptic treatment.

#### Patient 14

This 27-year-old man has been presented in detail elsewhere (Krakow *et al.* 2000). He has a family history of generalised epilepsy and suffered from panic attacks and obsessive-compulsive neurosis, but he has never had an overt epileptic seizure. His video-EEG showed continuous, bilaterally synchronous high amplitude occipital paroxysms that showed FOS. There were also brief and subclinical generalised spike/polyspike and wave discharges that occurred when his eyes were closed or open (even when fixating), and background activity was normal on fixation. During a two-hour video EEG recording, the patient reported no symptoms during occipital paroxysms, and he was able to talk and recall normally, and perform mathematical calculations successfully; the latter did not inhibit the posterior paroxysms. However, formal neuropsychological assessment under video EEG monitoring elsewhere revealed significantly lower scores in the story recall and the list learning tasks when his eyes were closed, but not in

the digit span task (Krakow *et al.* 2000). Functional MRI showed activation of parieto-occipital and frontal areas during the paroxysms.

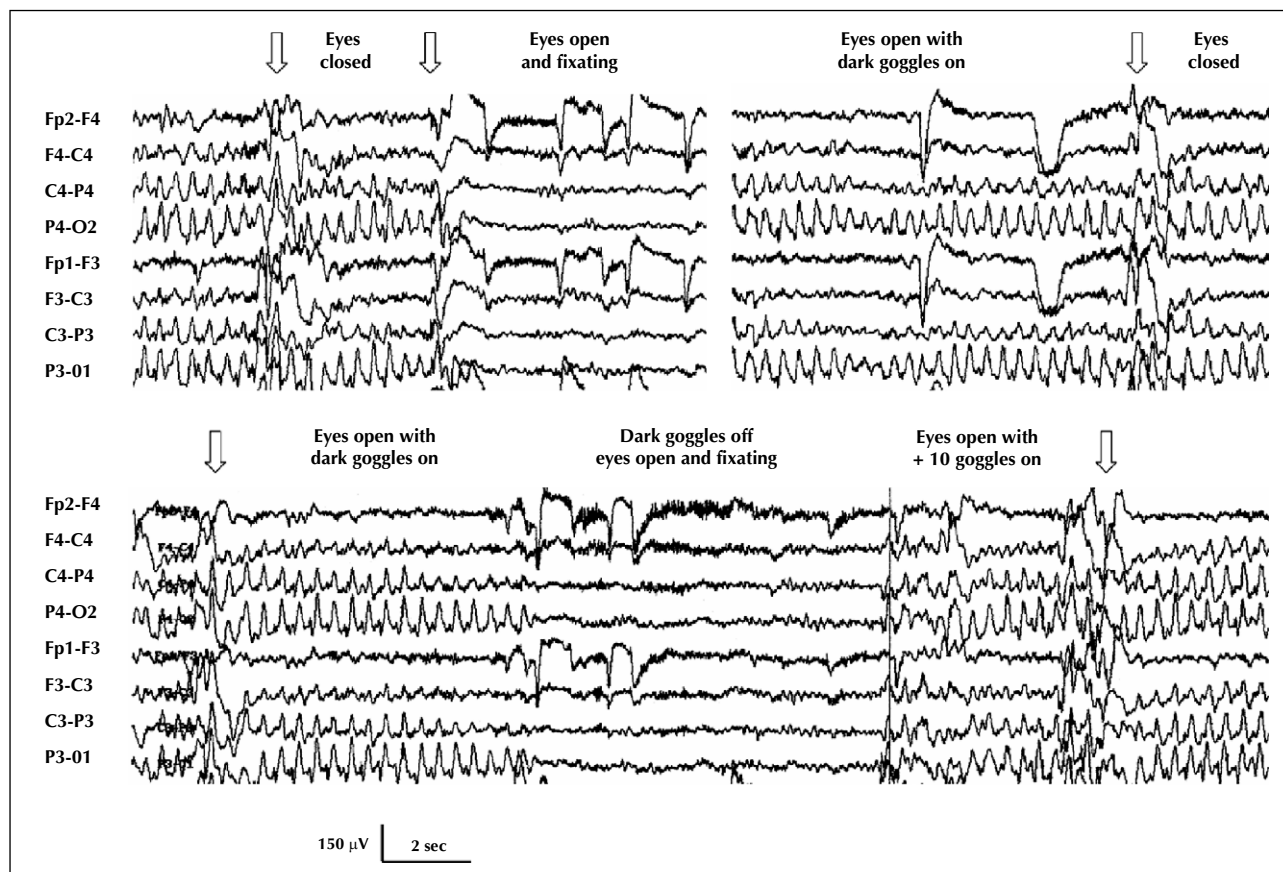
## Discussion

We present the pertinent clinical and EEG features of 14 patients with FOS abnormalities on their video EEG and epilepsies other than idiopathic epilepsy of childhood with occipital paroxysms; all had frank epileptiform activity (focal, generalised or both), and all but two had various epilepsies. Our findings indicate that FOS is rare (with an approximate incidence of 0.2%) amongst patients with seizures; there are only a few other case reports, some of which do not appear to have been subjected to a comprehensive FOS-specific protocol. We were able to make the following electroclinical observations, but we are conscious of the tentative nature of any conclusions drawn from such limited material.

### The clinical spectrum of epilepsies and epileptic syndromes that may be associated with FOS

Our findings indicate that FOS can occur in all types of epilepsy when one uses the double dichotomy of the current ILAE classification scheme (Commission on Classification and Terminology of the International League Against Epilepsy, 1989), namely focal versus





**Figure 8.** (Patient 14) Top left trace: bilateral synchronous occipital paroxysms (OP) with eyes closed are promptly inhibited by eye opening and visual fixation. Top right trace: ongoing OP irrespective of the state of the eyes as long as dark goggles are on. Lower trace: eyes are open with dark goggles on (left third), dark goggles off and visual fixation (middle third), and + 10 translucent goggles on (right third). Sub-clinical generalised polyspike – wave discharges are marked with arrows (HFF 70 Hz, TC 0.3 s).

generalised, and idiopathic versus symptomatic or probably symptomatic. FOS can occur in both non-photosensitive and, despite the conflicting corresponding mechanisms (Panayiotopoulos 1998), in photosensitive patients; finally, FOS can be encountered in mild and medically intractable epilepsies alike, and even in patients without obvious epileptic seizures (table 1).

#### Factors that may interfere with FOS expression, and diagnostic principles and techniques to elicit FOS during EEG recording

The intensity and consistency of fixation-off-related EEG phenomena appear to depend on variables that determine and modulate the alpha rhythm, but possibly also the overall level of cortical hyperexcitability: for example, a clear attenuation of the FOS-related EEG abnormalities, be these occipital or generalised, was observed in patients 6-11 (with IGE), and patient 13 (without overt seizures) in parallel with the “drop out” of the alpha rhythm (table 2 and relevant short case reports). Similar behaviour was

not shown by the occipital paroxysms of patients 1 and 2 with symptomatic and cryptogenic focal seizures; in both patients occipital spikes remained unchanged during drowsiness and up to stage 2 of slow sleep (figure 2). The specificity of this distinction for differentiating between idiopathic and symptomatic/probably symptomatic causes (if confirmed in other patients with symptomatic epilepsies) pertains only to the “alpha dropout” period of the early drowsiness and not to deeper sleep stages, during which the occipital paroxysms in idiopathic occipital epilepsy for example, may also increase and occasionally evolve into electrical status epilepticus.

We also observed that in our patients with IGE, FOS abnormalities increased during and mainly after hyperventilation, particularly when the exercise was performed soon after awakening. In contrast, the right occipital spiking of patient 1 with symptomatic occipital epilepsy did not appear to change. This effect probably relates to the general activation of the epileptiform discharges and of the overall liability to absences, myoclonic seizures or GTCS on awakening and during and after hyperventila-

tion in IGE. Similar activation is observed in other IGE-related paroxysmal phenomena, such as the eye-closure paroxysms that may enhance from posterior to generalised with or without clinical accompaniments, and photosensitivity that, from sub-clinical posterior responses, may become generalised with or without clinical manifestations. A contribution to FOS enhancement by the concurrently activated alpha rhythm cannot be excluded.

FOS abnormalities typically appear within two to three seconds after eye closure (or elimination of central vision and fixation by any of the means described above), apparently depending on the general threshold, but they may sometimes be delayed for few more seconds (Cirignotta *et al.* 1987); they may also habituate after a few repetitions (as photoparoxysmal responses may do), and testing may appear less reliable. Because of the facilitating effect of hyperventilation, particularly after awakening, it is more rewarding to test for FOS in this part of the recording.

#### *On “eye-closure” and “eyes closed” abnormalities*

The distinction between “eye-closure” and “eyes closed” abnormalities is illustrated in patients 8 (*figures 4,5*) and 12 (*figure 6*), who combined both phenomena. Eye closure paroxysms (ECP) that occur within one to three seconds after the positive deflection of the eye closure artefact, are self-limited, typically relate to photosensitivity and are suppressed by complete darkness. In contrast, fixation-off paroxysms may start either immediately or with a few seconds delay after eye closure, typically persist for as long as eyes remain closed, and are activated by complete darkness because fixation is impeded (Duncan and Panayiotopoulos 1996, Panayiotopoulos 1998, Panayiotopoulos 2007b). Occasionally, eye closure paroxysms may last for longer, especially after awakening or hyperventilation, and may be misinterpreted as eyes-closed abnormalities; similarly, in such periods of increased excitability FOS-related abnormalities may start immediately on eye closure, mimicking ECP. It is therefore important to maintain the eyes-closed intervals for several seconds and record under complete darkness and also while fixation is prevented.

#### *FOS and photosensitivity*

Despite the distinctly opposite conditions that are required for the manifestation of photosensitivity and FOS (eye-closure EEG abnormalities inhibited by total darkness and dependence on central vision and fixation [Jeavons and Harding 1975 ; Wilkins, 1995] *versus* eyes closed EEG abnormalities enhanced by total darkness and dependence on abolition of central vision and fixation respectively), half of our patients had both phenomena: patients 6-9 and 12 with IGE had generalised photoparoxysmal responses, and patient 5 with photosensitive occipital epilepsy and patient 13 without seizures had occipital photosensitivity, the second with variable forward diffusion (*table 2*). It is likely that these patients have more

“complete” occipital hyperexcitability that concerns both systems of magnocellular (mainly for photosensitivity) and parvocellular (more widespread and mainly for FOS) pathways (Wilkins 1995). It appears that such dual system hyperexcitability may coexist independently, as exemplified by our patient 13 with asymptomatic occipital photosensitivity in all her EEGs at the ages of 9, 13 and 17 years, and coexistent FOS discovered only when she was 13 years old, probably in patient 1 of Green (1968), and in the patient of Garcia Silva *et al.* (1987) with myoclonic epilepsy with ragged-red fibres (MERRF), photosensitivity since age nine and probably FOS since age 13 years. One form may also transform into the other, as in a 13-year-old girl with a conversion of photosensitivity to FOS within a fourteen-month period (Panayiotopoulos 1979), or there may be an even more complicated relationship, as in patient 12 of our series (*figure 6*).

#### **Possible clinical epileptogenic potential of FOS**

FOS is identified as a reflex EEG phenomenon triggered by elimination of visual fixation, mediated by central vision. Fixation is, on the whole, an automatic reflexive process that despite involving awareness, and sometimes even volition, does not usually depend on conscious (and therefore memorable) effort to maintain it; hence it is very difficult to establish on history a clear temporal sequence, and therefore a reliable cause-effect relationship between its loss or compromise and seizure occurrence. Consequently, the possible role of FOS as a seizure trigger can be only indirectly suggested (after demonstration of the phenomenon on video EEG), the relevant clinical evidence from the existing literature being weak and scanty. We were able to extract only seven suggestive references or individual examples: seizures upon entering dark rooms, particularly on bright days (Panayiotopoulos 1979); feeling of “strangeness” each time the patient entered dark rooms (patient 1 of Lugaresi *et al.* 1984 with idiopathic occipital epilepsy of Gastaut) (Lugaresi *et al.* 1984), multiple, disseminated, erratic and arrhythmic twitching in the face, head and limbs a few seconds after eye closure in the patient of Garcia Silva *et al.* (1987) with MERRF, “dazzle”, wandering and lack of balance, or amyotonic falls (nine patients with idiopathic occipital epilepsies of Beaumanoir *et al.* 1989), descriptions of “fear” for small dark places (our patient 9) (Agathonikou *et al.* 1998), seizures occurring only during sleep (our patient 12), and seizures occurring over the weekends and holidays (Ming and Kaplan 1998) or during school holidays as opposed to college terms (our patient 1). In this study, ictal video EEG showed that from the 16 distinct interictal EEG patterns of FOS epileptiform activity in our 14 patients of *table 2*, only seven corresponded to habitual clinical seizures of seven patients (occipital in patients one and two, and generalised in patients four, six, and nine-11, *table 2*). This would suggest that about half of the patients with demonstrable FOS on their EEG

may have seizures provoked or facilitated by loss of visual fixation. We found that the actual extent of the FOS contribution to these seizures is very difficult to gauge, not only because of the inherent difficulty of establishing a clear cause-effect relationship on the clinical history, but also because of the significant day-to-day variability of the epileptogenic threshold that, particularly for the idiopathic cases of FOS, may be influenced by the complex interactions of several parameters that include sleep deprivation, alcohol consumption, awakening, stress, menstruation and possibly coexisting triggers such as photosensitivity. Although FOS-related seizures have been recorded (myoclonic in the patient of Garcia Silva *et al.* [1987], absences in our patient 11 and absence status in the patient of Ming and Kaplan [1998]), the intrinsic epileptogenic potential of FOS is presumed low, as the occipital FOS paroxysms in idiopathic occipital lobe epilepsy and most of the generalised FOS discharges in IGE phenotypes here do not appear to be associated with overt, ictal clinical manifestations.

#### **Evidence that links FOS EEG abnormalities and related seizures to occipital hyperexcitability**

Despite the apparently wide association of FOS with generalised and localisation-related epilepsies of idiopathic or symptomatic aetiology, the following evidence suggests a prime role of the occipital areas.

##### *Physiological*

A. Dependence on central (macular) vision that projects to a disproportionately larger area of the primary visual cortex compared with peripheral vision.

B. Induction of alpha rhythm (including slow alpha variant) by the same means that induce FOS, namely blocking fixation without changing the lighting conditions (Takahashi 1976).

##### *Pathological*

A. Clinical. FOS is associated with occipital epileptogenesis in:

– idiopathic childhood epilepsy with occipital paroxysms (where FOS is most frequent) (Camfield *et al.* 1978, Panayiotopoulos 1980, 1981, 1987a, 1998, 2007a, Gastaut 1982, Beaumanoir 1983, Newton and Aicardi 1983, Cirignotta *et al.* 1987, Ferrie *et al.* 1997);

– symptomatic occipital lobe epilepsy: this may not be as rare as suggested by the published case reports. Apart from two previously reported patients (Panayiotopoulos 1981, Kurth *et al.* 2001) and patient 1 of our series, there is a child with Sturge-Weber syndrome and left posterior calcification (Maher *et al.* 1995) (their patient 31), and presumably some patients with coeliac disease, seizures and posterior cerebral calcifications. Of the 127 such patients in the review by Gobbi (2005), 109 had focal seizures, and of these 78 (72%) had occipital epilepsy. Interictal EEG occipital spikes typically occurred when the eyes were

closed and were activated during sleep, mimicking idiopathic occipital epilepsy. It is very likely that some of these children may have (symptomatic) FOS. It also seems possible that a few of the children diagnosed with idiopathic, childhood occipital epilepsy of Gastaut (some possibly with FOS) may have coeliac disease; Labate *et al.* (2001) showed that two of 25 children previously diagnosed with idiopathic childhood epilepsy with occipital paroxysms had coeliac disease (based on positive anti-endomysium immunoglobulin A antibodies and characteristic jejunal biopsy), one without occipital classifications. FOS in symptomatic occipital epilepsies seems to relate to local hyperexcitability, either due to characteristic anatomic/physiologic substrates (cortical dysplasia, calcifications of coeliac disease) or to cortical de-afferentiation as suggested by Kurth *et al.* (2001) in their patient with perinatal bilateral occipital haemorrhages; the latter may account for FOS in some children with amblyopia without seizures (such as case two of Beaumanoir and Grandjean 1987);

– probably symptomatic (cryptogenic) occipital lobe epilepsy in adults (Iannetti *et al.* 2002) and children (patient two here);

– photosensitive epilepsies: posterior FOS coexisted with occipital photosensitivity either clinical (idiopathic photosensitive occipital lobe epilepsy, patient five here) or subclinical (patient 13 here), whereas generalised FOS was associated with generalised photosensitive epilepsy (patient six with EMA); IGE phenotypes with generalised photosensitivity (patients seven - nine and 12 here) may also associate with FOS that may involve either occipital (patient eight) or generalised discharges (patients seven, nine and 12);

– asymptomatic (non-epileptic) adults with occipital paroxysms (Krakow *et al.* 2000) (patient 13).

B. Functional imaging. fMRI studies in patient 14 showed activation of the parieto-occipital and frontal areas (Krakow *et al.* 2000), and implicated areas 19 and 37 of the extrastriate cortex in three adults with medically intractable (probably symptomatic) occipital lobe epilepsy and FOS (Iannetti *et al.* 2002).

#### **Is there a pure form of FOS epilepsy?**

Any “pure” form of reflex epilepsy would require that: a) all (or almost all) EEG discharges and all (or almost all) seizures are triggered by the specific stimulus, b) the patterns of the clinical seizures (generalised, focal or both) are indicative of the involvement of a particular functional system), and c) other potent triggers are excluded. Notwithstanding the inherent difficulty in identifying FOS as the trigger and the rarity of the phenomenon, it may be possible to identify four patients with a similar electroclinical phenotype that may satisfy some or most of the above requirements: our two patients nine and 10, and the patients of Gummit *et al.* (1965) and Ming and Kaplan (1998) are adult women of normal or nearly nor-



mal intelligence with seizure onset between five and 13 years, and have typical absences that are associated with eyelid myoclonic phenomena, tend to evolve into catamenial episodes of absence status and are subject to FOS, and GTCS. There is no photosensitivity and (generalised) FOS EEG discharges occur against a normal background. This is only a preliminary observation, and more studies are needed before making a more solid hypothesis on possible pure FOS epilepsy. □

**Acknowledgments.** We would like to express our gratitude for the generous moral support and the charitable donation kindly bestowed by Mrs Ellis Stewart to honor the memory of her son Gordon Stewart; her support encourages us to continue our research into epilepsy.

All EEG tracings of the present article are available for PowerPoint presentation on the DVD.

## References

- Agathonikou A, Koutroumanidis M, Panayiotopoulos CP. Fixation-off-sensitive epilepsy with absences and absence status: video-EEG documentation. *Neurology* 1997; 48: 231-4.
- Agathonikou A, Koutroumanidis M, Panayiotopoulos CP. Fixation-off (Scoto) sensitivity combined with photosensitivity. *Epilepsia* 1998; 39: 552-5.
- Barclay CL, Murphy WF, Lee MA, et al. Unusual form of seizures induced by eye closure. *Epilepsia* 1993; 34: 289-93.
- Beaumanoir A. Infantile epilepsy with occipital focus and good prognosis. *Eur Neurol* 1983; 22: 43-52.
- Beaumanoir A, Capizzi G, Nahory A, et al. Scotogenic seizures. In: Beaumanoir A, Gastaut H, Roger J, Geneve, eds. *Reflex seizures and reflex epilepsies*. Medicine and Hygiene, 1989: 219-23.
- Beaumanoir A, Grandjean E. Occipital spikes, migraine and epilepsy. In: Andermann F, Lugaresi E, eds. *Migraine and epilepsy*. Boston: Butterworths, 1987: 97-110.
- Camfield PR, Metrakos K, Andermann F. Basilar migraine, seizures, and severe epileptiform EEG abnormalities. *Neurology* 1978; 28: 584-8.
- Cirignotta F, Lugaresi E, Montagna P. Occipital EEG activity induced by darkness: the critical role of central vision. In: Andermann F, Lugaresi E, eds. *Migraine and epilepsy*. Boston: Butterworths, 1987: 139-45.
- Commission on Classification and Terminology of the International League Against Epilepsy. Proposal for revised classification of epilepsies and epileptic syndromes. *Epilepsia* 1989; 30: 389-99.
- Duncan JS, Panayiotopoulos CP. The differentiation of 'eye-closure' from 'eye-closed' EEG abnormalities and their relation to photo- and fixation-off sensitivity. In: Duncan JS, Panayiotopoulos CP, eds. *Eyelid myoclonia with absences*. London: John Libbey & Company Ltd, 1996: 77-87.
- Ferrie CD, Beaumanoir A, Guerrini R, et al. Early-onset benign occipital seizure susceptibility syndrome. *Epilepsia* 1997; 38: 285-93.
- Garcia Silva MT, Aicardi J, Goutières F, et al. The syndrome of myoclonic epilepsy with ragged-red fibers. Report of a case and review of the literature. *Neuropediatrics* 1987; 18: 200-4.
- Gastaut H. A new type of epilepsy: benign partial epilepsy of childhood with occipital spike-waves. *Clin Electroencephalogr* 1982; 13: 13-22.
- Gobbi G. Coeliac disease, epilepsy and cerebral calcifications. *Brain Dev* 2005; 27: 189-200.
- Green JB. Seizures on closing the eyes. Electroencephalographic studies. *Neurology* 1968; 18: 391-6.
- Gummit RJ, Niedermeyer E, Spreen O. Seizure activity uniquely inhibited by patterned vision. *Arch Neurol* 1965; 13: 363-8.
- Herranz Tanarro FJ, Saenz Lope E, Cristobal Sassot S. La pointe-ocde occipitale avec et sans epilepsie benigne chez l'enfant. *Rev Electroencephalogr Neurophysiol Clin* 1984; 14: 1-7.
- Iannetti GD, Di Bonaventura C, Pantano P, et al. fMRI/EEG in paroxysmal activity elicited by elimination of central vision and fixation. *Neurology* 2002; 58: 976-9.
- Jeavons PM, Harding GFA. *Photosensitive epilepsy*. W. London: Heinemann Medical Books, 1975.
- Koutroumanidis M, Aggelakis K, Panayiotopoulos CP. Idiopathic Epilepsy with Generalized Tonic Clonic Seizures only vs. Idiopathic Epilepsy with Phantom Absences and Generalized Tonic Clonic Seizures: one or two syndromes? *Epilepsia* 2008; 49: 2050-62.
- Krakov K, Baxendale SA, Maguire EA, et al. Fixation-off sensitivity as a model of continuous epileptiform discharges: electroencephalographic, neuropsychological and functional MRI findings. *Epilepsy Res* 2000; 42: 1-6.
- Kristjánsson Á. Saccade landing point selection and the competition account of pro- and antisaccade generation: the involvement of visual attention-a review. *Scand J Psychol* 2007; 48: 97-113.
- Kurth C, Bittermann HJ, Wegerer V, Bleich S, Steinhoff BJ. Fixation-off sensitivity in an adult with symptomatic occipital epilepsy. *Epilepsia* 2001; 42: 947-9.
- Labate A, Gambardella A, Messina D, et al. Silent celiac disease in patients with childhood localization-related epilepsies. *Epilepsia* 2001; 42: 1153-5.
- Lugaresi E, Cirignotta F, Montagna P. Occipital lobe epilepsy with scotosensitive seizures: the role of central vision. *Epilepsia* 1984; 25: 115-20.
- Maher J, Ronen GM, Ogunyemi AO, Goulden KJ. Occipital paroxysmal discharges suppressed by eye opening: variability in clinical and seizure manifestations in childhood. *Epilepsia* 1995; 36: 52-7.
- Martinovic Z. Clinical correlations of electroencephalographic occipital epileptiform paroxysms in children. *Seizure* 2001; 10: 379-81.
- Ming X, Kaplan PW. Fixation-off and eyes closed catamenial generalized nonconvulsive status epilepticus with eyelid myoclonic jerks. *Epilepsia* 1998; 39: 664-8.
- Munoz DP, Everling S. Look away: the anti-saccade task and the voluntary control of eye movement. *Nat Rev Neurosci* 2004; 5: 218-28.
- Newton R, Aicardi J. Clinical findings in children with occipital spike-wave complexes suppressed by eye-opening. *Neurology* 1983; 33: 1526-9.



- Panayiotopoulos CP. Conversion of photosensitive to scotosensitive epilepsy: report of a case. *Neurology* 1979; 29: 1550-4.
- Panayiotopoulos CP. Basilar migraine? Seizures, and severe epileptic EEG abnormalities. *Neurology* 1980; 30: 1122-5.
- Panayiotopoulos CP. Inhibitory effect of central vision on occipital lobe seizures. *Neurology* 1981; 31: 1330-3.
- Panayiotopoulos CP. Difficulties in differentiating migraine and epilepsy based on clinical and EEG findings. In: Andermann F, Lugaresi E, eds. *Migraine and epilepsy*. Boston: Butterworths, 1987: 31-46.
- Panayiotopoulos CP. Fixation-off-sensitive epilepsy in eyelid myoclonia with absence seizures. *Ann Neurol* 1987; 22: 87-9.
- Panayiotopoulos CP. Fixation-off, scotosensitive, and other visual-related epilepsies. *Adv Neurol* 1998; 75: 139-57.
- Panayiotopoulos CP. *A clinical guide to epileptic syndromes and their treatment*. London: Springer, 2007.
- Panayiotopoulos CP. Reflex seizures and reflex epilepsies. In: Panayiotopoulos CP, ed. *A Clinical Guide to Epileptic Syndromes and their Treatment*. London: Springer, 2007: 435-69.
- Pazzaglia P, Sabattini L, Lugaresi E. Occipital seizures precipitated by darkness. *Riv Neurol* 1970; 40: 184-92.
- Rafal RD, Laxer KD, Janowsky JS. Seizures triggered by blinking in a non-photosensitive epileptic. *J Neurol Neurosurg Psych* 1986; 49: 445-7.
- Takahashi T. Influence of gazing at a fixation point and total visual field on electroencephalograms. *No To Shinkei* 1976; 28: 95-103.
- Wilkins A. Towards an understanding of reflex epilepsy and absence. In: Duncan JS, Panayiotopoulos CP, eds. *Typical absences and related epileptic syndromes*. London: Churchill Communications Europe, 1995: 196-205.