

First reported case of an inherited *PACS2* pathogenic variant with variable expression

Elisabetta Cesaroni, Sara Matricardi, Silvia Cappanera, Carla Marini

Child Neurology and Psychiatric Unit, Pediatric Hospital G. Salesi, United Hospitals of Ancona, Ancona, Italy

Received October 13, 2021;
Accepted January 27, 2022

ABSTRACT

Neonatal epilepsy, cerebellar dysgenesis and facial dysmorphisms may be associated with *de novo* *PACS2* missense pathogenic variants (EIEE 66) (OMIM #618067). Here, we report a toddler boy with neonatal-onset seizures, developmental delay with hypotonia, facial dysmorphisms and prominence of the cisterna magna, mild inferior vermian and cerebellar hypoplasia. A next-generation epilepsy gene panel revealed a known pathogenic *PACS2* missense variant, p.Glu209Lys, that was inherited from his mildly affected mother. We describe the first *PACS2* pathogenic variant to be inherited, expanding the clinical spectrum, associated with a mild phenotype in the mother and a more severe phenotype in her son, in keeping with previously reported descriptions.

Key words: epilepsy, neonatal seizure, genetics, *PACS2* gene, cerebellar dysgenesis

In 2018, Olson *et al.* reported 14 individuals with the same *de novo* *PACS2* gene missense pathogenic variant, c.625G>A (p.Glu209Lys), associated with developmental and epileptic encephalopathy-66 (EIEE 66) (OMIM #618067) [1]. The phenotype consisted of neonatal intractable focal to bilateral seizures, global developmental delay with hypotonia, behavioural abnormalities with autistic symptoms, dysmorphic features and ophthalmologic defects. Brain MRI showed cerebellar dysgenesis in most patients. A subset of patients also had extra-neurological manifestations, including haematological and distal limb abnormalities [1]. Since then, three independent patients have been reported, two carrying the same recurrent p.Glu209Lys missense pathogenic variant [2, 3] and the third a novel *de novo* c.631G>A (p.Glu211Lys) variant [4].

PACS2 (phosphofurin acid cluster sorting protein 2 gene) encodes a multifunctional protein expressed in the brain including the cerebellum, involved in nuclear gene expression and pathway traffic regulation controlling endoplasmic reticulum mitochondrial communication [5]. *PACS2* is also involved in ion channel trafficking, directing acid cluster-containing ion channels to distinct subcellular compartments [6].

Here, we report on the same recurrent missense p.Glu209Lys variant identified by next-generation sequencing (NGS) using an epilepsy gene panel in a mother and child. We performed the genetic study “expecting” a *KCNQ2* gene pathogenic variant, known to cause neonatal autosomal dominant epilepsy, yet results revealed a maternally inherited *PACS2* pathogenic variant. The affected

• **Correspondence:**
Carla Marini
Child Neurology and Psychiatric Unit,
Pediatric Hospital G. Salesi,
via Filippo Corridoni 11,
0123 Ancona, Italy
<carla.marini@ospedaliriuniti.marche.it>

mother with a mild phenotype had a son who, at seven days after birth, manifested with repetitive focal to bilateral seizures.

Recurrent missense pathogenic *PACS2* variants might thus also be associated with a mild phenotype without a reproductive disadvantage, allowing transmission. Our findings expand the phenotypic spectrum of this disease to include a mild and transmittable form of the disorder and confirm the occurrence of a *PACS2* mutational hot spot in patients with *PACS2*-associated phenotypes.

Clinical study

An 11-month-old male was the only child of non-consanguineous parents, born at term and following an uncomplicated pregnancy. At age seven days, he presented with several focal seizures characterized by staring, loss of contact, crying and apnoea with severe cyanosis followed by a tonic and vibratory prolonged phase. Phenobarbital (PB) treatment led to immediate seizure remission. At age three months, seizures recurred at home and in hospital where a polygraphic video-EEG was performed and seizures were recorded. The adjustment of the PB dose was sufficient to obtain seizure control. Clusters of focal tonic to bilateral seizures relapsed at four and at nine months with similar features. Phenobarbital was substituted by valproic acid (VPA) and nitrazepam with good control of the seizures and global motor skills were delayed.

At three months of age, we examined the baby for the first time, and noted diffuse severe hypotonia, poor global general movements with occasional eye contact and smiling. At nine months, he presented with significant global psychomotor delay with persistent hypotonia and he was unable to sit and pick up objects. Recognition of familiar voices and acquisition of non-verbal and verbal communication skills were also severely delayed. At 12 months, seizures relapsed again with VPA blood levels within normal range, thus VPA and nitrazepam were withdrawn and substituted with carbamazepine (CBZ). At age 17 months, a formal neuropsychological assessment using the Griffiths Mental and Developmental scale showed a GQ (global developmental quotient) of 94 consistent with moderate to severe delay (motor scale score equivalent to eight months of age; oculo-manual coordination score equivalent to five months of age, performance score equivalent to nearly six months of age; motor skills score equivalent to eight months of age; personal/social skills score equivalent to five months of age). At the last follow-up visit at age 19 months, the patient was still seizure-free. Dysmorphisms included highly arched and sparse broad eyebrows, long eyelashes, broad nasal tip,

smooth philtrum, thin and everted upper lip vermilion, and down-turned corners of the mouth (*figure 1A*).

At one month of age, brain magnetic resonance imaging (MRI) demonstrated prominence of the cisterna magna, mild inferior vermian and cerebellar hypoplasia (*figure 1B*).

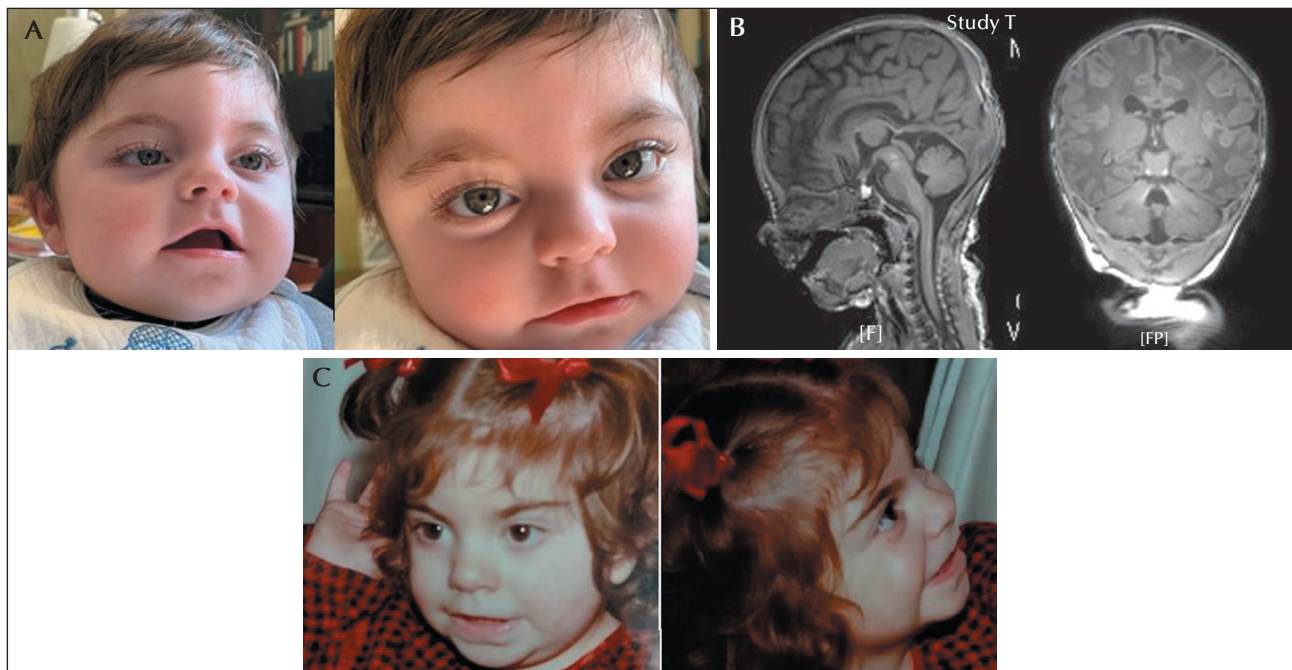
Interictal EEG showed generalized slowing with sporadic multifocal sharp waves. Several seizures were recorded during long-term EEG monitoring showing brief tonic stiffening and symmetric tonic posturing accompanied by apnoea and cyanosis. Ictal EEG showed focal rhythmic sharp waves and poly-spike activity, predominant in the frontal regions and alternating between sides from one seizure to the next, rapidly spreading to become bilateral and then generalized (*figure 2*).

The 37-year-old mother had three brief febrile tonic seizures from a few weeks after birth up to age three months. She was treated with PB for few years, and medication was then withdrawn and since then she has never had seizures. At age three months, she had a CT scan, and several EEG recordings were reported to be normal. During childhood, some learning disabilities emerged; she did not pass secondary school examinations, thus in late adolescence, she left school to work in a factory. At present, she leads an autonomous, satisfactory and independent life. Upon careful evaluation, mild dysmorphic signs, including synophrys, highly arched and sparse broad eyebrows, long eyelashes, a broad nasal tip and a thin everted upper lip with down-turned corners of the mouth, were evident (*figure 1C*).

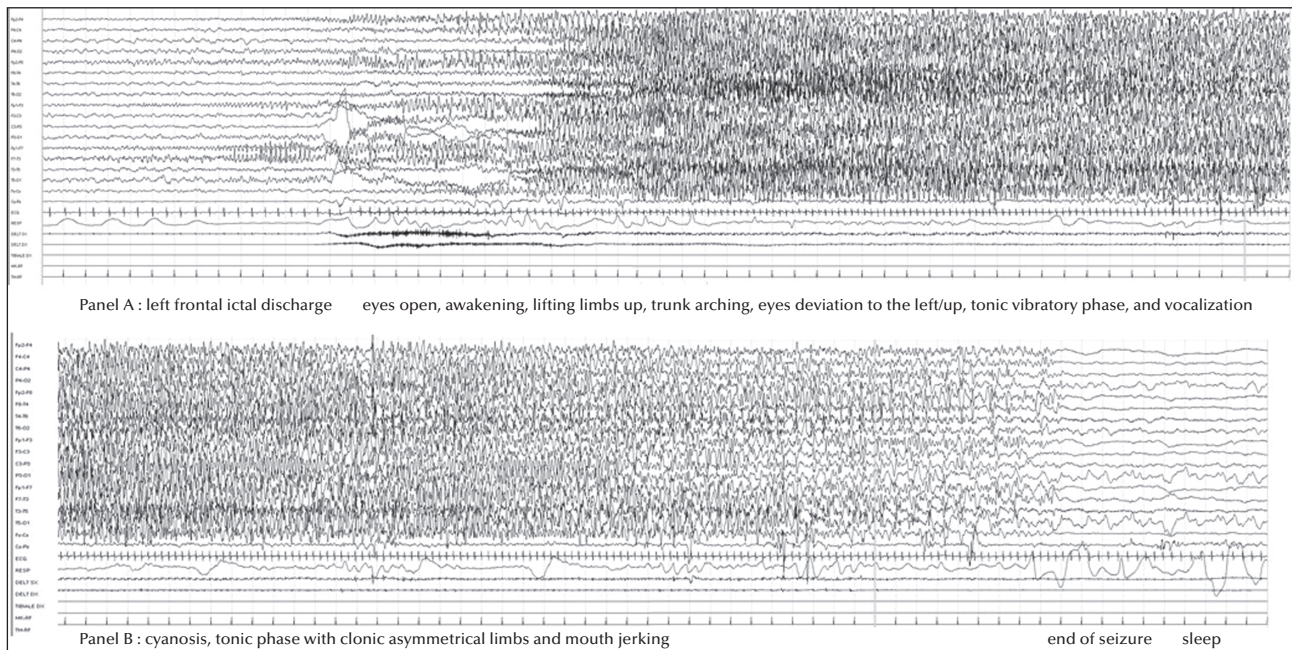
An NGS panel of 220 genes associated with epilepsy led to the identification of a *PACS2* missense variant, c.625 G>A, causing the amino acid change from glutamic acid to lysine (p.Glu209Lys) in exon 6 (NM_001100913.2), also present in the mother. Sanger sequencing (via polymerase chain reaction PCR) in both individuals confirmed the presence of the variant. This variant was previously reported in patients with similar phenotypes [1], and was thus considered pathogenic. Additional familial segregation of the variant showed that it was absent in the proband's maternal grandparents. NGS and Sanger sequencing (child= 431 reads [229 ref / 202 alt]; mother= 410 reads [212 ref / 197 alt]) excluded the hypothesis of somatic mosaicism in the mother. Written informed consent for the use of photographs and research findings were obtained from the family

Literature review

To date, only 16 patients carrying the *de novo* *PACS2* recurrent missense variant, c.625G>A (p.Glu209Lys), are on record [1-3], and one patient is reported



■ **Figure 1.** (A) Facial dysmorphisms of the proband showing highly arched and sparse broad eyebrows, elongated eyelashes, a broad nasal tip, a smooth philtrum, thin and everted upper lip vermilion and downturned corners of the mouth. (B) T1-weighted brain MRI showing vermian and cerebellar hypoplasia on longitudinal sequence and large cisterna magna on coronal sequence. (C) The mother's facial dysmorphisms included a broad nasal tip, smooth philtrum and thin and everted upper lip vermilion.



■ **Figure 2.** (A, B) EEG recording during one of the child's typical seizures, lasting about two minutes, showing the correlation between seizure semiology and epileptiform activity.

harbouring a *de novo* pathogenic variant, c.631G>A p.Glu211Lys [4]. Almost all patients (13/17) had neonatal-onset seizures, global developmental delay, facial dysmorphisms and cerebellar dysgenesis. Epilepsy was reported to be refractory in infancy yet information on long-term evolution were lacking except in two patients who, at the age seven and 23 years, were reported to be seizure-free without antiseizure medications [3, 4]. Furthermore, a 26-month-old girl carrying the c.631G>A variant, following neonatal-onset refractory epilepsy, became seizure-free while treated with carbamazepine [2].

Other signs were less frequently described, including congenital heart disease (3/15 patients), ocular abnormalities with myopia and strabismus, and mild distal limb anomalies, including fifth finger brachyclinodactyly. Recently, a male adult with early infantile-onset epilepsy and facial dysmorphisms, carrying the Glu209Lys variant, was also reported to feature iridal and choroidal coloboma, suggesting that *PACS2* and related genes may be involved in ocular development [3].

Discussion

Epilepsies beginning in neonates or infants encompass a large group of disorders from self-limiting epilepsies with good outcome to devastating disorders known as epileptic encephalopathies, in which the infant or child typically has several types of seizures and abundant epileptiform activity on EEG, associated with developmental slowing or regression that might follow seizure onset. The spectrum of epilepsies, syndromes and comorbid neurodevelopmental disorders has expanded greatly in the latest decade and specific, aetiology-based diagnoses can be very challenging [7-9]. Seizure types, semiology and age at onset comprise important clinical information, yet often insufficient to frame a specific diagnosis and predict evolution and long-term outcome. When confronting a neonate with seizures, often with a tonic asymmetrical posture, and at times clonic jerking, cyanosis and apnoea, several diagnostic possibilities immediately spring to mind, from neuro-metabolic disorders to other developmental encephalopathies [10]. The evidence of a family history of seizures might be significant information for the diagnostic process and perhaps be informative of a more benign disorder. The most frequent form of familial neonatal epilepsy with or without developmental delay is associated with a defect in the *KCNQ2* gene [11-12]. Likewise, *SCN2A* pathogenic variants might also be taken into account in the differential diagnoses [12-13], whereas other gene variants, of e.g. *SCN8A* and *PRRT2*, are usually associated with a later age at onset [9, 14, 15]. Thus, we predicted that our

mother and child could carry a pathogenic variant in one of these genes. The NGS epilepsy gene panel instead revealed the missense recurrent pathogenic *PACS2* variant, p.Glu209Lys, in both the mother and her child. We carefully reviewed clinical signs and noted their peculiar facial dysmorphisms, in addition to cerebellar hypoplasia that is also a common feature across patients reported in the literature. Our data and the literature reports [1-4] show that dysmorphic features, especially when associated with cerebellar hypoplasia, play a key role in the recognition of *PACS2*-related disorders.

Considering a total of 19 patients (17 from the literature and the two cases presented here), 17 of them (89.4%) had neonatal seizures occurring at a mean age of nine days (range: 1 to 14 days). Only two patients had later onset at around two months of age. Seizures captured on EEG, from our proband and from previously reported patients [1], show a focal onset with bilateral spread of discharge and alternating side of seizure onset. Ictal semiology at onset is predominantly focal motor with some autonomic signs including cyanosis, tonic posturing at times, followed by a tonic-clonic phase. Status epilepticus has also been reported in some patients [1]. Data on treatment were available for only seven patients (five patients from the literature [1-4] plus our two cases); PB was used in five and all were seizure-free for a short period after which epilepsy relapsed. At the time of seizure recurrence, during the first year of life, different medications were used including VPA, vigabatrin, levetiracetam and CBZ [1-4]. Phenobarbital, VPA and CBZ were reported as effective medications leading to seizure control both in the literature [1-4] and in our proband and his mother. The epilepsy appears to be more active and difficult to treat in infancy with improvement after the first year of life. Data from older patients suggest that epilepsy might resolve in late infancy or early childhood. Indeed, there were at least four patients in whom antiseizure medications were withdrawn without seizure recurrence including the mother of our proband.

Taken together, these data also suggest that when considering specific medication efficacy, the age at which seizure control was obtained is important since it could be related to the evolution of the disorder rather than the type of medication last introduced. These observations need to be further evaluated in a larger cohort.

Thus, we report the first case of an inherited pathogenic *PACS2* gene variant with the novel finding of a very mild phenotype in the mother, with only three seizures in infancy, borderline-to-mild intellectual disability, not adversely affecting her social life, a degree of independency and able to have children. She transmitted the pathogenic variant to her child who, at age 19 months, presented with a more severe

phenotype with further seizures and moderate developmental delay, leading to deficits in both motor function and cognition.

In conclusion neonatal epilepsy, facial dysmorphisms and cerebellar dysgenesis represent the hallmarks of PACS2-related disorder. Pathogenic variants may be associated with mild phenotypes and inherited, with relevant implications for appropriate genetic counselling. ■

Supplementary material.

Summary slides accompanying the manuscript are available at www.epilepticdisorders.com.

Disclosures.

Neither of the authors has any conflict of interest to disclose.

References

1. Olson HE, Jean-Marçais N, Yang E, Heron D, Tatton-Brown K, van der Zwaag PA, et al. A recurrent *de novo* PACS2 heterozygous missense variant causes neonatal-onset developmental epileptic encephalopathy, facial dysmorphism, and cerebellar dysgenesis. *Am J Hum Genet* 2018; 102: 995-1007.
2. Terrone G, Marchese F, Vari MS, Severino M, Madia F, Amadori E, et al. A further contribution to the delineation of epileptic phenotype in PACS2 related syndrome. *Eur J Epil* 2020; 79: 53-5.
3. Sakaguchi Y, Yoshihashi H, Uehara T, Miyama S, Kosaki K, Takenouchi T. Coloboma may be a shared feature in a spectrum of disorders caused by mutations in the WDR37-PACS1-PACS2 axis. *Am J Med Genet A* 2021; 185(3): 884-8.
4. Dentici ML, Barresi S, Niceta M, Ciolfi A, Trivisano M, Bartuli A, et al. Expanding the clinical spectrum associated with PACS2 mutations. *Clin Genet* 2019; 95: 525-31.
5. Thomas G, Aslan JE, Thomas L, Shinde P, Shinde U, Simmen T. Caught in the act—protein adaptation and the expanding roles of the PACS proteins in tissue homeostasis and disease. *J Cell Sci* 2017; 130: 1865-1876.
6. Köttgen M, Benzing T, Simmen T, Tauber R, Buchholz B, Feliciangeli S, et al. Trafficking of TRPP2 by PACS proteins represents a novel mechanism of ion channel regulation. *EMBO J* 2005; 24: 705-16.
7. Peter C, Camfield C. Modes of onset of epilepsy and differential diagnosis. *Handb Clin Neurol* 2013; 111: 447-53.
8. Weber YG, Biskup S, Helbig KL, Von Spiczak S, Lerche H. The role of genetic testing in epilepsy diagnosis and management. *Expert Rev Mol Diagn* 2017; 17(8): 739-50.
9. Symonds JD, McTague A. Epilepsy and developmental disorders: next generation sequencing in the clinic. *Eur J Paediatr Neurol* 2020; 24: 15-23.
10. Samanta D. Recent advances in the diagnosis and treatment of neonatal seizures. *Neuropediatrics* 2021; 52(2): 73-83.
11. Zara F, Specchio N, Striano P, Robbiano A, Gennaro E, Paravidino R, et al. Genetic testing in benign familial epilepsies of the first year of life: clinical and diagnostic significance. *Epilepsia* 2013; 54(3): 425-36.
12. Grinton BE, Heron SE, Pelekanos JT, Zuberi SM, Kivity S, Afawi Z, et al. Familial neonatal seizures in 36 families: clinical and genetic features correlate with outcome. *Epilepsia* 2015; 56: 1071-80.
13. Wolff M, Johannesen KM, Hedrich UBS, Masnada S, Rubboli G, Gardella E, et al. Genetic and phenotypic heterogeneity suggest therapeutic implications in SCN2A-related disorders. *Brain* 2017; 140(5): 1316-36.
14. Gardella E, Møller RS. Phenotypic and genetic spectrum of SCN8A-related disorders, treatment options, and outcomes. *Epilepsia* 2019; 60(3): S77-85.
15. Marini C, Conti V, Mei D, Battaglia D, Lettori D, Losito E, et al. PRRT2 mutations in familial infantile seizures, paroxysmal dyskinesia, and hemiplegic migraine. *Neurology* 2012; 79(21): 2109-14.

TEST YOURSELF

(1) What is the aetiology of neonatal epilepsies?

(2) What features are associated with PACS2 gene mutations?

(3) Are pathogenic variants of genes causing early-onset developmental epileptic encephalopathies always associated with a severe phenotype?

Note: Reading the manuscript provides an answer to all questions. Correct answers may be accessed on the website, www.epilepticdisorders.com.