

Epileptic spasms in epilepsy with myoclonic-atonic seizures (Doose syndrome)

Francesca Pittau^{1,a}, Christian M. Korff^{2,a}, Douglas R. Nordli Jr.³

¹ Neurology Department

² Pediatric Neurology Department, University Hospitals, Geneva, Switzerland

³ Epilepsy Center, Ann and Robert H. Lurie Children's Hospital of Chicago, Chicago, Illinois, USA

Received October 23, 2015; Accepted June 22, 2016

ABSTRACT – *Aim.* To describe the occurrence of epileptic spasms in epilepsy with myoclonic-atonic seizures (EMAS) or Doose syndrome.

Methods. Case descriptions of patients with EMAS and epileptic spasms. Diagnosis of EMAS was performed according to the following criteria: (1) onset of myoclonic, myoclonic-atonic, or atonic seizures at between 7 months and 6 years of age; (2) normal development before onset of epilepsy; (3) absence of structural cerebral abnormalities on MRI; (4) presence of generalized spike-waves or polyspike-waves on EEG; and (5) exclusion of other myoclonic epilepsies.

Results. Four patients with EMAS were included. For each of them, epileptic spasms were documented by video interpretation, or video-EEG when available.

Conclusions. Our description of epileptic spasms in four patients with EMAS enlarges the spectrum of seizures that may be observed in this syndrome, as well as the number of epilepsy syndromes which may involve epileptic spasms. This evidence suggests that the presence of epileptic spasms is consistent with a diagnosis of EMAS; epileptic spasms should therefore not be considered a seizure type that excludes diagnosis of this epilepsy syndrome. The prognostic significance of epileptic spasms associated with EMAS remains unknown.

Key words: epileptic spasms, myoclonic-atonic seizures, drop-attacks, Doose syndrome

Epilepsy with myoclonic-atonic seizures (EMAS) (Berg *et al.*, 2010), or Doose syndrome was identified by Dr. Hermann Doose in 1970 (Doose *et al.*, 1970) as a large group of early cases of epilepsies “with myoclonic and atonic manifestations of idiopathic origin”, with emphasis on “the wide variability of the IGEs of early childhood as a result of a multifactorial

background responsible for electro-clinical differences in presentation.” The estimated incidence of EMAS during childhood is 1/10,000, *i.e.* 1-2% of all cases of childhood-onset epilepsy (Kelley and Kossoff, 2010). EMAS typically starts in otherwise healthy children aged 2-4 years. Various seizure types are observed, including the prototypic myoclonic-atonic attacks, but also

Correspondence:

Francesca Pittau
Neurology Department,
Geneva University Hospitals,
4 Rue Gabrielle-Perret-Gentil,
Geneva 14, Switzerland
<francesca.pittau@gmail.com>
<christian.korff@hcuge.ch>

^a Authors contributed equally.

atypical absences, subtle status epilepticus, and nocturnal tonic seizures. To our knowledge, the co-existence of EMAS with epileptic spasms (ES) has not been described to date, in spite of a description by Dooze himself of a chaotic high-voltage interictal EEG pattern seen in some patients, and identified as hypsarrhythmia-like. In this article, we present a series of four patients with EMAS, who presented with ES during the course of their disease.

Material and methods

The following criteria were chosen to diagnose EMAS in our four patients:

- normal development before onset of epilepsy;
- absence of structural cerebral abnormalities on MRI;
- onset of myoclonic, myoclonic-aticonic, or atonic seizures between 7 months and 6 years of age;
- presence of generalized spike-waves or polyspike-waves at 2-3 Hz, and absence of constant focal discharges on EEG;
- exclusion of other myoclonic epilepsies, such as myoclonic epilepsy of infancy, Lennox-Gastaut syndrome, and Dravet syndrome. (Nabbout and Dulac, 2008; Bourgeois et al., 2014).

Results

Patient 1

The first patient was a right-handed, 10-year-old boy, with unremarkable neurological and psychiatric

family history and normal birth. He presented, at the age of 2 years, an episode of simple febrile seizures and, in the same year, four episodes of afebrile generalized seizures. He started therapy with valproate after the third episode. Standard and sleep EEG at that time were normal. At the age of 3 years, episodes, lasting 2-3 seconds and characterized by sudden involuntary “jerks” with retropulsion of the head and upward eye deviation, were observed. These episodes presented in clusters, lasting 6-8 minutes, several times per week, mostly during sleep-wake transition, and were followed by crying. At 3 years of age, treatment with levetiracetam was started, and the patient underwent structural MRI that was normal. Several treatments were tried in various combinations, including levetiracetam, valproate, ethosuximide, topiramate, and clobazam, without lasting effect. A ketogenic diet had a partial effect but only for a short time. On evolution, myoclonic-aticonic seizures were also observed. At the age of 9 years, the frequency of seizures increased. A long-term video-EEG showed a background activity of 5-6 Hz with intermittent theta rhythms in the frontal regions (*figure 1*). During sleep, several bursts of diffuse high-amplitude spike- or polyspike-and-slow-wave complexes were recorded (*figure 2*), lasting from 2 to 20 seconds, without any clinically visible sign. Two episodes of electro-clinical spasms were also recorded (*figure 3*). In another epoch, a generalized tonic-clonic seizure immediately followed a cluster of three spasms. The phase of spasms lasted for four seconds and was characterized clinically by three sudden and brief (lasting around one second) flexion contractions (around 1/sec) of

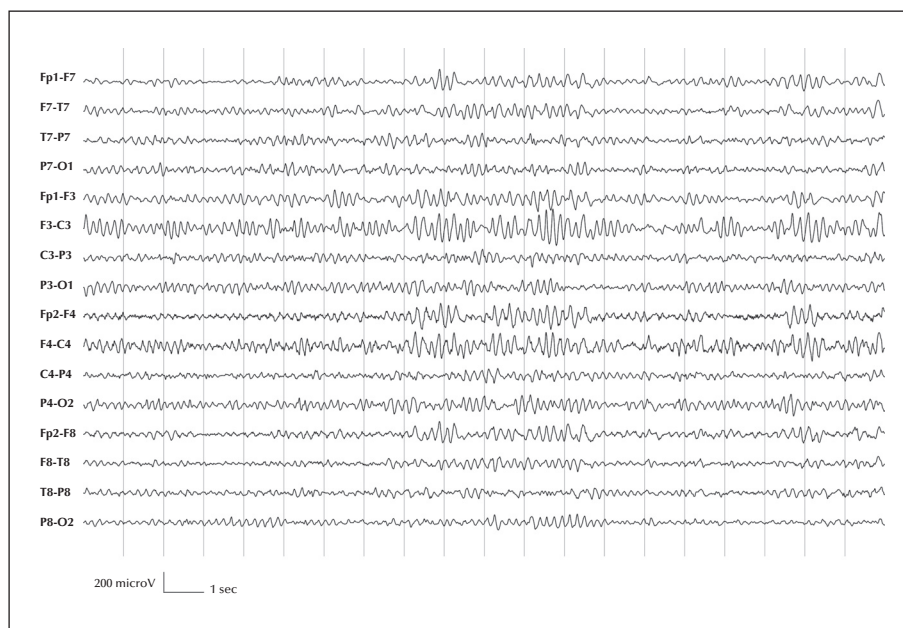


Figure 1. Patient 1. Background activity of 5 Hz. Intermittent theta high-amplitude activity in frontal regions.

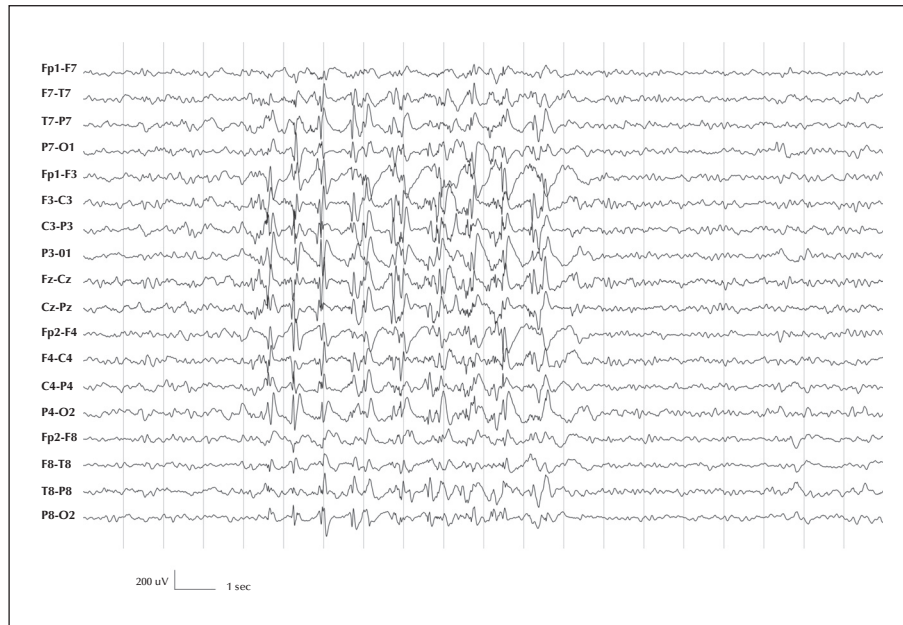

Figure 2. Patient 1. A burst, lasting approximately eight seconds, of repetitive diffuse high-amplitude spike/polyspikes-and-slow-wave complexes with a frequency of approximately 1 Hz.

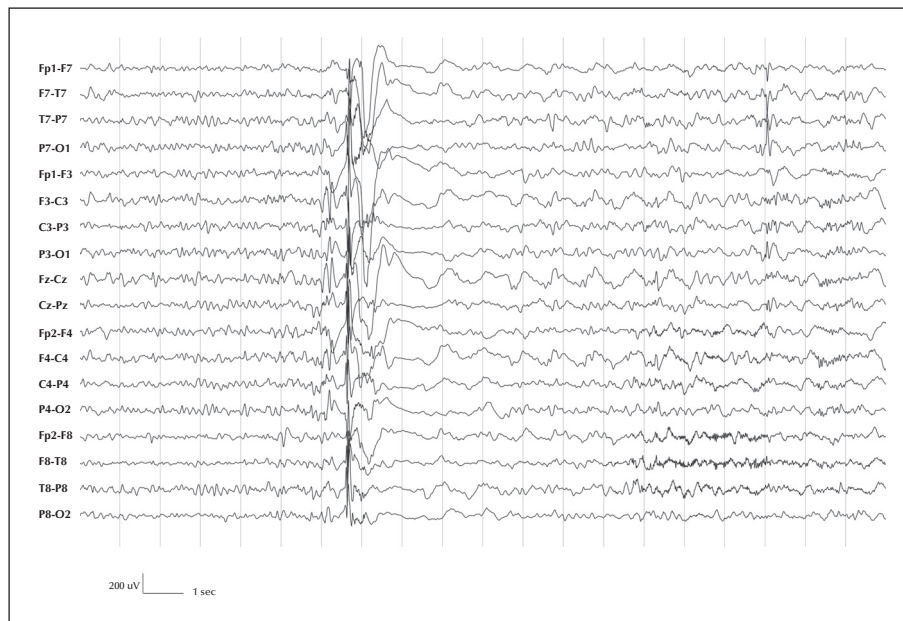


Figure 3. Patient 1. From drowsiness, electroclinical ES characterized by sudden flexion and contraction of proximal limb muscles and head, lasting around one second. Clinical symptoms were preceded by a burst of diffuse polyspikes, followed by a high-voltage slow wave lasting 700 ms, and by a diffuse flattening lasting 2 seconds.

the head and proximal inferior limbs, and extension of the proximal superior limb. From the EEG point of view, 500 ms before each spasm, there was a burst of diffuse polyspikes, prominent in the fronto-central regions, followed by a high-voltage slow wave.

The starting point of the tonic-clonic phase was characterized on the EEG, by a sequence of diffuse rhythmic spike-wave complexes at around 2.5 Hz. Then, the EEG recording was masked by muscular artefacts.

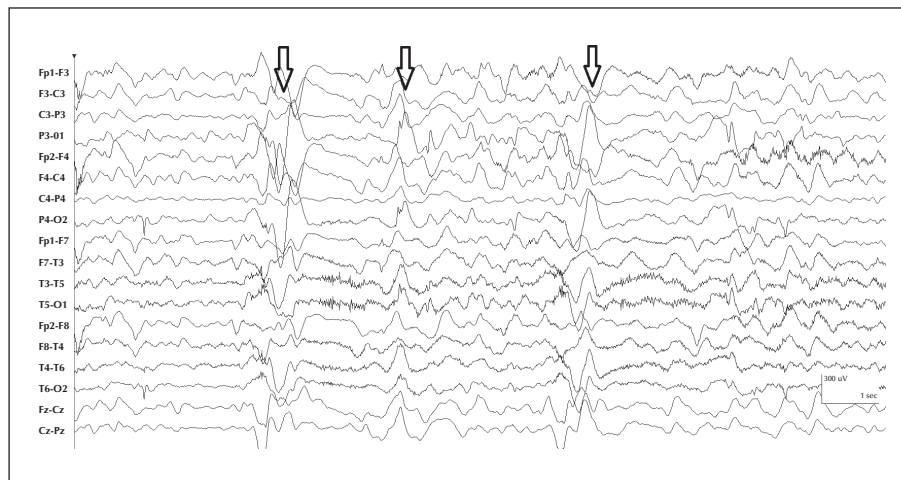


Figure 4. Patient 2. Cluster of spasms.

Patient 2

The second patient was a right-handed, 6-year-old boy, with normal birth and family history negative for epilepsy. Baseline neurological examination and development prior to seizure onset were described to be within normal limits. At 18 months, stereotyped episodes, characterized by “full-body drop, as if he had lost his muscles”, lasting a few seconds, were observed once or twice every day. At two years, episodes described as “body stiffening with both hands moved upward and eyes wide open” were noted. A standard EEG was reportedly abnormal, but the formal report was not available. Genetic tests to investigate *SCN1A* and *SLC2A1* mutations were negative.

During an overnight video-EEG, three types of seizures were recorded:

- atonic seizures (head nods with loss of muscular tone, lasting 1-2 seconds, not triggered by any precipitating factors), occurring multiple times per day;
- myoclonic jerks (quick jerks of bilateral arms, jerking outwards forcefully, lasting seconds, without identified precipitating factors), occurring multiple times per day;
- clusters of periodic spasms (with overall duration of more than five minutes), occurring daily, on awakening (*figure 4*). There were no identified precipitating factors. Spasms occurred in regular or periodic fashion with the cluster. The spasms themselves were symmetric, with slight elevation of the proximal portions of the arms and concurrent flexion of the neck. In terms of the entire cluster, there was not an appreciable crescendo-decrescendo characteristic. Crying was not observed during the cluster.

EEG background activity was slow with abundant diffuse spike-wave discharges, with amplitude

predominance in the posterior regions. Structural MRI was normal.

From the age of 2 years, several medical treatments were tried, including carbamazepine, ethosuximide, levetiracetam, primidone, clonazepam, and topiramate, alone or in several combinations; it was not possible to decrease the frequency of the seizures using standard dosages. A ketogenic diet improved the frequency of seizures for a short time. Given the severity of the clinical situation, a treatment with intravenous methylprednisolone (at 30 mg/kg/dose, once per day for three consecutive days) was tried and resulted in complete cessation of seizures for several months. Thereafter, his ketogenic diet was adjusted. At long-term follow-up at the age of 6 years, he had been seizure-free for more than two years, and he was still on the diet.

Patient 3

The third patient was a right-handed, 15-year-old boy, with normal birth and family history. Baseline neurological examination and development prior to seizure onset were within normal limits. From the age of 2 years, he presented three types of seizures, as follows. Type 1: described as “sudden freezing, arm stiffening, staring, subtle head version to either side, followed by a period of speech disturbance, without response to verbal command”. Each of these episodes were described by the parents as lasting 10-15 minutes, but this estimate likely included some period of decreased responsiveness as a postictal phenomenon. Type 2: generalized tonic-clonic seizures, sometimes followed by restlessness and hyperactive behaviour (at times, the patient would get up and run down the hallway),

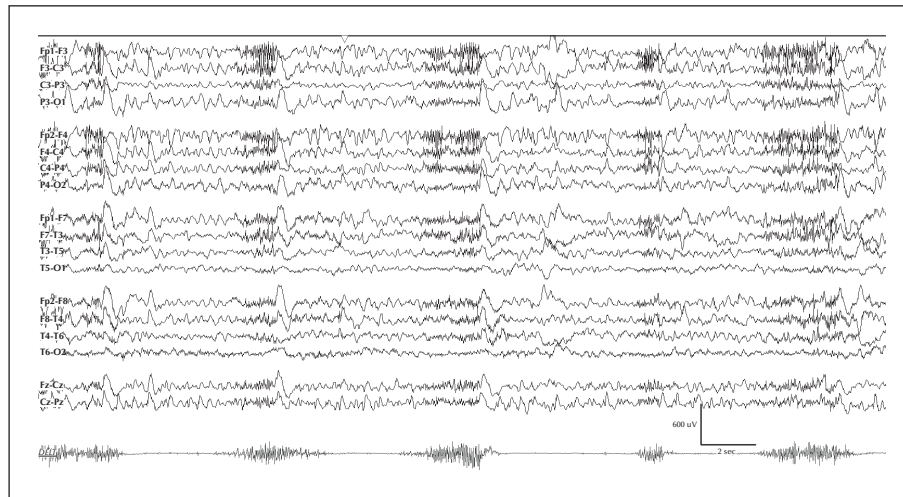


Figure 5. Patient 3. EEG recording with EMG (electrodes on the right deltoid). The EEG correlate to each of these events was a short phase of low-voltage fast activity preceding a higher-voltage bilateral slow wave, without clear attenuation between episodes. On EMG, the seizures were correlated with a diamond-shaped pattern, consistent with spasms.

lasting up to one minute at a frequency of 1-3 seizures every night. Type 3: reported as short tonic contraction of proximal muscles, with inability to speak, and transient rightward eye deviation. These appeared in clusters of multiple episodes, and review of the home video was consistent with epileptic spasms. Routine EEG performed at the age of 6 years led to the recording of a cluster of episodes (*figure 5*), clinically characterized by a sudden flexion and contraction of proximal limb muscles and head, lasting around two seconds. The EEG correlate to each of these events was a short phase of low-voltage fast activity, preceding a higher-voltage bilateral slow wave, without clear attenuation between episodes. On EMG, the seizures were correlated with a diamond-shaped pattern, consistent with spasms. The patient stopped having this type of seizure at 13 years.

Long-term video-EEG monitoring showed a slow background with intermittent irregular delta activity in anterior regions, with shifting laterality. Intercially, there were frequent brief (one-second) bursts of diffuse polyspike/spike-and-slow-wave discharges during the awake state, which were more frequent during sleep. Furthermore, multifocal independent spike-and-wave discharges were noted, more frequently on the left than on the right side. In addition, several electroclinical tonic vibratory seizures were recorded from sleep, preceded by diffuse rhythmic low-voltage fast activity.

Several drugs were tried, all of which were ineffective. These included carbamazepine, valproate, topiramate, levetiracetam, clonazepam, felbamate, clobazam, primidone, acetazolamide, and zonisamide. A ketogenic diet and oral steroids over three months led to a

short transient improvement in seizure frequency. A longer improvement was obtained with lamotrigine at 250 mg/day.

Patient 4

The last patient was a right-handed, 9-year-old boy, with normal birth and family history, who began having events at 5.5 years. Initial events were described as myoclonic jerks, predominantly in the right arm, lasting a second. One year later, onset of two other types of seizures occurred. The first type comprised “bilateral stiffening of the arms and jerking”. The second type was described as shrugging of the shoulders with slight head nod that would occur in clusters, primarily in the morning (classified as spasms on the basis of ictal semiology by the author who observed the episodes). These presented in clusters of 4-5 events over a period of 20-30 minutes. During this period, the patient would appear confused and partially conscious in between the individual spasms. His EEG showed a well-organized background with a nicely modulated 9-10-Hz posterior dominant rhythm. There were brief runs of rhythmic theta with a frontal predominance. During sleep, there were generalized bursts of spike-wave discharges that occurred as single complexes or irregular non-rhythmic couplets. Shortly after the generalized spike-wave discharges, there were occasional medium to high-voltage slow waves with relative attenuation of faster frequencies. The clustered spasms were accompanied by electro-decrements, with a vertex maximal slow-wave discharge, followed by diffuse attenuation. PET and structural MRI were normal. The spasms persisted despite multiple medication trials,

at a frequency of one cluster of spasms lasting 5-8 minutes every day (two to three days/year, he could have two clusters in a day). During a period when he tried to withdraw all AEDs, seizures increased to 4-5 times per day. Zonisamide was started and seizures decreased back to about one per day, however, in addition to the spasms, he started having generalized tonic-clonic seizures, occurring once a day in the morning. There were typically spasms intermixed with the generalized seizure, or a cluster following it. Baseline neurological examination and development prior to seizure onset were appropriate for age.

Subsequently, seizures evolved to include the current seizure types; reported as:

- spasms in clusters, at that time lasting 5-8 minutes, with confusion lasting up to 15 minutes, and occurring daily;

- generalized tonic-clonic seizures; these typically started with stiffening of the arms (and slow bending over from the waist with arms stiff and extended). Some spasms were intermixed with convulsions or a cluster afterwards. The convulsion itself lasted less than two minutes. These were occurring daily.

The EEG initially showed background activity which was normal for age. Interictal slow generalized spike-and-wave discharges at 1.5 to 2 Hz lasting up to 10 seconds were noted, but no clinical seizures were captured. Clusters of spasms were captured during MEG and EEG recordings, with frequent paroxysms of 16-18-Hz sharply contoured waves of maximum amplitude in the bifrontal and bicentral derivations, lasting 2-3 seconds, and followed by 2-3 seconds of generalized suppression (illustrative EEG and EMG images not available).

Previous treatment with zonisamide, valproate, clobazam, levetiracetam, vigabatrin, ACTH, carbamazepine, prednisolone, and felbamate did not bring significant benefits. A ketogenic/modified Atkins diet allowed a decrease in the duration of clusters of spasms from 30 to 10 minutes.

Discussion

We report four patients with EMAS who presented with ES during the course of the disorder. In our series, ES were not witnessed or reported to be present at the onset of epilepsy. ES are characterized by a sudden flexion, extension, or mixed flexion-extension of predominantly proximal and truncal muscles, more sustained than a myoclonic movement, but not as sustained as a tonic seizure. ES are classically observed in West syndrome (WS) (Lux and Osborne, 2004), although they may be frequently encountered in epilepsies other than WS (Lee et al., 2015). Doose

identified a specific interictal EEG pattern resembling hypsarrhythmia in some patients with EMAS (Doose, 2002). However, to the best of our knowledge, ES have been reported in EMAS only in a single case (Goldstein and Slomski, 2008), without any specific details regarding the clinical presentation of the patient.

Various seizure types observed in EMAS share certain characteristics with spasms. For instance, myoclonia can be of variable intensity and may affect various groups of muscles. When they involve the trunk, they may cause a fall in which the individual appears to be forcefully thrown to the floor. Likewise, myoclonic-atonic seizures are characterized by a brief but severe loss of muscular tone preceded by myoclonus. Generalized tonic seizures may also be observed in EMAS and could be confounded with ES, especially if they are short-lasting. Differentiating spasms from tonic or atonic seizures may be indeed extremely difficult, and one may argue that the events reported here rather correspond to either one of them. Indeed, tonic seizures share certain clinical and electrophysiological characteristics with spasms, such as fixed muscular postures and diffuse attenuation or fast activity on EEG. Certain specific features may help in their differentiation. The typical EEG correlate of ES consists of a diffuse high-amplitude sharp wave, immediately followed by general attenuation (electro-decrement), superimposed with low-voltage fast activity. Although this EEG pattern is the most frequent in ES, other types of ictal EEG patterns, such as generalized spike-and-slow-wave complexes, generalized sharp-and-slow waves followed by a period of attenuation, or just the attenuation alone, can also be found (Kellaway et al., 1979). Classic spasms clinically start with a brisk axial and proximal limb contraction, correlated on EEG with a diffuse high-amplitude slow wave that precedes voltage attenuation (Kellaway et al., 1979; Vigeveno et al., 2001; Fusco et al., 2012), whereas tonic seizures lack this initial electroclinical phase. In addition, the low-voltage fast activity (likely corresponding to the briefly sustained posturing that follows the initial brisk contraction) frequently observed in spasms is closely related to the slow wave, superimposed on the ascending or descending phase, and is usually shorter than that noted in tonic seizures. On EMG recordings, true spasms often correlate with a diamond-shaped contraction, reflecting a progressive muscular contraction which rapidly reaches its peak and decreases in intensity as fast as it appears (Lee et al., 2015), as shown in Patient 3 (figure 5). A combination of a brief phasic and a longer tonic contraction has been shown in detailed polygraphic electrophysiological studies of spasms (Bisulli et al., 2002). Although tonic seizures can start with a diffuse “slow complex” on EEG (Fusco et al., 2012) or show a progressive increase

in contraction intensity on EMG (Fusco *et al.*, 2012), they are usually associated with a more regular and longer muscle contraction, leading to different electrophysiological features (Vigevano *et al.*, 2001). Both seizure types may be associated during the same event, such as in the case of tonic spasms observed in neonatal encephalopathies, in which a sustained tonic phase follows the classic spasm (Vigevano *et al.*, 2001; Fusco *et al.*, 2012; Mizrahi and Milh, 2012). Whether these seizure types represent a biological continuum with a common pathophysiology remains to be studied. Interestingly, the cluster of seizures itself had a crescendo-decrescendo aspect in Patient 3. In other words, the spasms gradually built up in the forcefulness of their expression as the cluster unfolded, and the time interval between them decreased, bit by bit. Then, after their intensity peaked, they gradually began to diminish and to have a longer inter-seizure interval. In this manner, the entire cluster closely resembled a typical cluster of infantile spasms, as previously reported in patients with this specific type of seizure (Fusco *et al.*, 2012). Similarly, atonic seizures may clinically resemble spasms, but they lack the short tonic contraction of axial and limb muscles often present in the second phase of the latter, and their EEG and EMG correlate are different. Atonic seizures may be present also in the absence of a preceding myoclonus (Oguni *et al.*, 1992). These complex aspects illustrate the fact that video-EEG with polygraphic recording is fundamental in order to characterize and distinguish these types of seizures (Oguni *et al.*, 1992). Based on the preceding events as well as the ictal semiology, EEG and (for one of the patients) EMG features of our patients, we consider the seizures reported here as true spasms. ES typically appear in clusters, although isolated events may also be observed.

The various epilepsies in which ES may be observed include Ohtahara syndrome, West syndrome, late-onset epileptic encephalopathy (Eisermann *et al.*, 2006), and Lennox-Gastaut syndrome (LGS) (Lee *et al.*, 2015). These epilepsies may evolve from one to another, and are considered as a spectrum of ES-related epilepsies with variable age-dependent expression.

Distinguishing patients who present with spasms in the context of EMAS from those with LGS may not be easy, initially. In this respect, a few characteristics may be helpful. First, most patients with LGS are developmentally delayed before seizure onset, which is typically not the case in children with EMAS. Patients with the latter may have periods of developmental or cognitive regression which may remain in most severe cases, but this is usually observed after months or years of evolution and incomplete seizure control. Second, interictal EEG features are quite different in both syndromes; patients with LGS typically exhibit

bilateral slow (2-Hz) spike-and-waves that predominate in frontal regions, isolated focal and multifocal spikes, and a slow background rhythm, whereas children with EMAS usually have normal background rhythms and superimposed generalized polyspike-wave discharges; suggestive bilateral theta discharges may also appear at some point during the course of their disease. Finally, cerebral imaging is, by definition, normal in patients with EMAS, whereas structural lesions are frequently found in those with LGS. Interestingly, many patients with EMAS may have been considered to be suffering from LGS in the past, when EMAS was less well defined, and such misclassification probably remains common today. This may have generated potential therapeutic issues in some of them, such as the use of lamotrigine, one of the first-choice medications for LGS, but considered as rather contraindicated for EMAs because of its potential to exacerbate myoclonia. A prompt recognition of the true nature of these events is therefore mandatory in order to avoid taking suboptimal investigatory or therapeutic decisions.

A potential corroboration of EMAs belonging to the spectrum of epileptic encephalopathies may derive from the recent development of functional neuroimaging. In particular, an EEG-fMRI study on patients with EMAs showed that the discharges associated with generalized spike-waves (GSWs) were associated with evidence of metabolic changes in the thalamo-cortical network, commonly found in generalized epilepsies, as well as brain structures associated with motor function, such as the putamen and the premotor cortex (Moeller *et al.*, 2014). Interestingly, the brainstem was also deactivated in relation to GSWs, presented by two of the 11 patients studied. A similar involvement of the brainstem has been described at group level in West syndrome and LGS, but not in other epileptic encephalopathies (Moeller *et al.*, 2013), suggesting that abnormal activity in the brainstem represents the common pathogenic pathway of these syndromes.

Efficient treatment options for ES in EMAs are still to be identified. As for "classic" ES in West syndrome, steroids may be the most effective treatment option (personal observations). Steroids and the ketogenic diet may be used simultaneously with efficacy and safety (Ville *et al.*, 2015). It remains to be determined whether earlier control of epileptic spasms in EMAS might, as seems to be the case with epileptic spasms in West syndrome, be associated with better average neuro-developmental outcomes and improved prognosis for later epilepsy outcomes. □

Acknowledgements and disclosures.

F. Pittau and C. Korff are recipients of a grant from the Swiss National Science Foundation (SPUM 140332).

None of the authors have any conflict of interest to disclose.

References

- Berg AT, Berkovic SF, Brodie MJ, et al. Revised terminology and concepts for organization of seizures and epilepsies: report of the ILAE Commission on Classification and Terminology, 2005-2009. *Epilepsia* 2010;51: 676-85.
- Bisulli F, Volpi L, Meletti S, et al. A. Ictal pattern of EEG and muscular activation in symptomatic infantile spasms: a videopolygraphic and computer analysis. *Epilepsia* 2002;43: 1559-63.
- Bourgeois BF, Douglass LM, Sankar R. Lennox-Gastaut syndrome: a consensus approach to differential diagnosis. *Epilepsia* 2014;55(4): 4-9.
- Doose H. Myoclonisch-astatische Epilepsie. *Das EEG bei Epilepsien im Kindes und Jugendalter* 2002; 145.
- Doose H, Gerken H, Leonhardt R, Volzke E, Volz C. Centrencephalic myoclonic-astatic petit mal. Clinical and genetic investigation. *Neuropadiatrie* 1970;2: 59-78.
- Eisermann MM, Ville D, Soufflet C, et al. Cryptogenic late-onset epileptic spasms: an overlooked syndrome of early childhood? *Epilepsia* 2006;47: 1035-42.
- Fusco L, Chiron C, Trivisano M, Vigeveno F, Chugani HT. Infantile spasms. In: Bureau M, Genton P, Dravet C, et al, eds. *Epileptic syndromes in infancy, childhood and adolescence*, 9, 5th ed. Montrouge, France: John Libbey Eurotext Ltd, 2012, 99-113.
- Goldstein J, Slomski J. Epileptic spasms: a variety of etiologies and associated syndromes. *J Child Neurol* 2008;23: 407-14.
- Kellaway P, Hrachovy RA, Frost Jr. JD, Zion T. Precise characterization and quantification of infantile spasms. *Ann Neurol* 1979;6: 214-8.
- Kelley SA, Kossoff EH. Doose syndrome (myoclonic-astatic epilepsy): 40 years of progress. *Dev Med Child Neurol* 2010;52: 988-93.
- Lee YJ, Berg AT, Nordli Jr. DR. Clinical spectrum of epileptic spasms in children. *Brain Dev* 2015;37: 37-48.
- Lux AL, Osborne JP. A proposal for case definitions and outcome measures in studies of infantile spasms and West syndrome: consensus statement of the West Delphi group. *Epilepsia* 2004;45: 1416-28.
- Mizrahi E, Milh M. In: Bureau M, Genton P, Dravet C, et al, eds. *Epileptic syndromes in infancy, childhood and adolescence*, 8, 5th ed. Montrouge, France: John Libbey Eurotext Ltd, 2012, 89-98.
- Moeller F, Stephani U, Siniatchkin M. Simultaneous EEG and fMRI recordings (EEG-fMRI) in children with epilepsy. *Epilepsia* 2013;54: 971-82.
- Moeller F, Groening K, Moehring J, et al. EEG-fMRI in myoclonic astatic epilepsy (Doose syndrome). *Neurology* 2014;82: 1508-13.
- Nabbout R, Dulac O. Epileptic syndromes in infancy and childhood. *Curr Opin Neurol* 2008;21: 161-6.
- Oguni H, Fukuyama Y, Imaizumi Y, Uehara T. Video-EEG analysis of drop seizures in myoclonic astatic epilepsy of early childhood (Doose syndrome). *Epilepsia* 1992;33(5): 805-13.
- Vigeveno F, Fusco L, Pachatz C. Neurophysiology of spasms. *Brain Dev* 2001;23: 467-72.
- Ville D, Chiron C, Laschet J, Dulac O. The ketogenic diet can be used successfully in combination with corticosteroids for epileptic encephalopathies. *Epilepsy Behav* 2015;48: 61-5.