

Definition of the epileptogenic zone in a patient with non-lesional temporal lobe epilepsy arising from the dominant hemisphere

Imad M. Najm, Richard Naugle, Robyn M. Busch, William Bingaman, Hans Lüders

Departments of Neurology, Neurosurgery and Psychiatry, The Cleveland Clinic Foundation, Cleveland, Ohio, USA

ABSTRACT – Pharmacoresistant epilepsy arising from the dominant temporal region in patients with intact memory and normal anatomical imaging, presents major challenges in the preoperative definition of the epileptogenic zone, and the planning of the extent of the surgical resection. We report on the case of a 42-year-old, right-handed male who presented with recurrent daily seizures that were resistant to antiepileptic drugs. Multiple, non-invasive (scalp) video-EEG evaluations revealed focal epilepsy arising from the left fronto-temporal region. Multiple high resolution MRIs that were performed at multiple Epilepsy Centers failed to show any abnormality. Fluoro-deoxyglucose PET scan showed extensive, left antero-mesial temporal hypometabolism, and ictal SPECT showed increased perfusion in the left insula in addition to the left mesial and anterior temporal pole. Neuropsychological testing and intracarotid methohexital testing revealed excellent memory to the left, dominant side. A two-stage invasive evaluation with subdural grid electrodes followed by depth electrode recordings allowed the localization of the epileptogenic region to the temporal pole. A selective resection of the left temporal pole (that spared the hippocampal formation) resulted in a seizure-free outcome (one year follow-up) with no significant consequences on memory function. We conclude that targeted, invasive recording techniques should be used for the accurate localization and delineation of the extent of the epileptogenic zone in cases of suspected, non-lesional, dominant hemisphere, temporal lobe epilepsy with preserved memory function. The use of the staged invasive approach may increase the chances for memory (function) sparing through tailored, temporal resection.

Keywords: epileptogenic zone, dominant hemisphere, temporal lobe epilepsy, presurgical evaluation

Correspondence:

Imad M. Najm, MD
Head, Section of Adult Epilepsy and Clinical Neurophysiology,
Director, Epilepsy Research Program,
The Cleveland Clinic Epilepsy Center,
9500 Euclid Avenue, S51,
Cleveland, OH 44195,
USA
<najmi@ccf.org>

The main goal of epilepsy surgery is complete seizure control without any resulting post-surgical functional deficits. In order to accomplish this goal, there is a need for an accurate localization of the epileptogenic region and

its relationships with the adjacent functional areas of the brain (Rosenow and Lüders 2001, Lüders *et al.* 2006). Over the last 20 years, the advent of various high resolution anatomical/structural imaging techniques (ma-

genetic resonance imaging, MRI) (Vattipally and Bronen 2004, Hogan *et al.* 2004b, Urbach *et al.* 2004), ictal single photon emission tomography (SPECT) (Van Paesschen 2004, Cascino *et al.* 2004, Hogan *et al.* 2004a) and metabolic imaging procedures such as positron emission tomography (PET) scans (Newberg and Alavi 2005, Koepp and Woermann 2005) allowed for a more accurate identification of the anatomical lesion, increased cerebral blood flow, and focal metabolic dysfunction respectively. These imaging techniques enabled the performance of epilepsy surgery in an increasing number of patients, without the reliance on invasive electroencephalographic (EEG) recordings. Despite these major advances in the imaging techniques for the evaluation of epilepsy patients, a large group of these patients are ruled out from surgical consideration because of a lack of accurate localization of the epileptogenic zone, the absence of anatomo-metabolic abnormalities, and/or inability to clearly assess the function of the proposed area of resection/disconnection. Therefore, there remains a need for invasive evaluation using subdural grids or depth electrodes for the accurate localization of the epileptogenic region, and to define its relationship with the eloquent cortex in its vicinity.

We report on the presurgical evaluation, surgical management, and postoperative seizure and memory outcome of a case of pharmacoresistant epilepsy arising from the left temporal lobe in a highly functional patient (a physician), with normal MRI and high memory scores.

Case report

The patient is a 42-year-old, right-handed male physician whose seizures started at the age of 20 years, with no seizure-risk factors identified. The first seizure consisted of a generalized motor convulsion while at work. His seizures are described as consisting of an aura of "mental slowing, fatigue and inability to think of words" followed by loss of awareness with body stiffening and whole body jerking. Despite many adequate trials of multiple antiepileptic drugs (AEDs, that included carbamazepine, lamotrigine, levetiracetam, phenytoin, topiramate, valproic acid, levetiracetam, oxcarbazepine, and zonisamide) in mono- and poly-therapy, and the implantation of a vagus nerve stimulator, he continued to exhibit recurrent seizures at a frequency of 1-2/day. Neurological examination was normal.

Presurgical epilepsy evaluation

He underwent a non-invasive scalp video-EEG monitoring at the Cleveland Clinic Epilepsy Center (after other evaluations at 3 other epilepsy centers), which showed interictal sharp waves that were mapped to the left anterior/mesial temporal region (maximum left sphenoidal electrode; Sp1, 100% of discharges) (*figure 1*) and intermittent slowing in the same distribution.

Six of his typical seizures were recorded and showed EEG seizure patterns that were mapped to the left anterior/mesial temporal region (*figure 2*). Two isolated

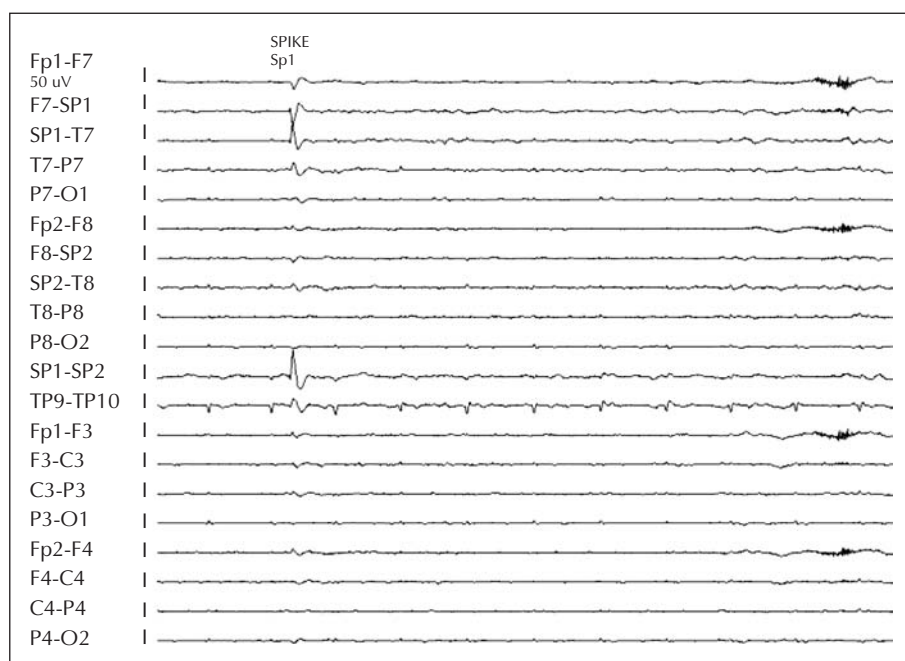


Figure 1. Left Anterior Temporal Interictal Spike.

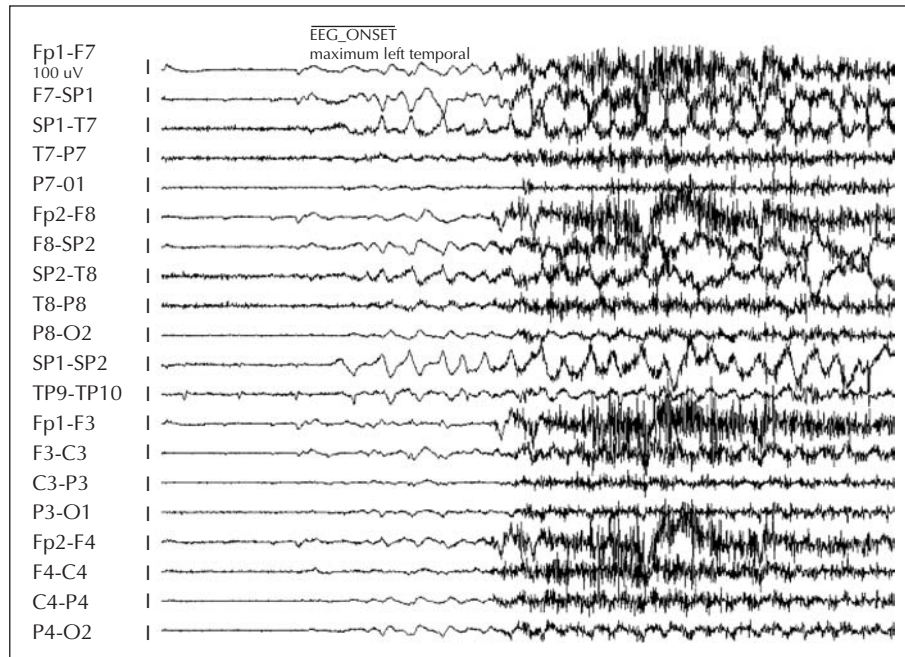


Figure 2. Left Anterior Temporal Seizure Onset.

auras were also recorded but were not associated with any surface EEG changes.

Multiple high-resolution magnetic resonance imaging studies were normal. An intracarotid methohexital test showed left speech dominance with excellent memory scores on the left (after right injection he remembered 10/12 items presented; after left injection he remembered 11/12 items presented).

His baseline neuropsychological examination indicated constricted word fluency, diminished confrontation naming and low-average, immediate and delayed free recall of visuospatial information; his performance on visual memory subtests of the Wechsler memory scale – Third Edition produced a Visual Immediate Memory Index of 88 (low-average) and a Visual Delayed Memory Index of 91 (average). His neuropsychological examination was otherwise regarded as unremarkable. In particular, it was noted that his immediate and delayed recall of verbal information-narrative passages and a series of word pairings, ranged from average to high-average. Together, these subtests produced an Auditory Immediate Memory Index of 111 (high-average), an Auditory Delayed Memory Index of 105 (average) and an Auditory Delayed Recognition Index of 95 (average). His ability to learn a list of unrelated words was high-average and his delayed free recall of those stimuli was superior. Although his average-to-high average performance on some verbal memory measures was somewhat lower than expected in light of the patient's academic and vocational background, his performance on measures that are relatively resistant to change over time suggested that this was consistent with his longstand-

ing level of ability. The absence of significant verbal memory compromise, prior to surgery, suggested that the patient was at risk of a decline in memory functioning after resection (Naugle and Lüders 1988, Chelune *et al.* 1991). His lower level of performance on visual memory measures also suggested an increased risk for a decrement in memory after surgery (Naugle *et al.* personal observation). Given his very high level of functioning, sparing of memory became a primary focus of the surgical plan.

Fluoro-deoxy glucose PET scan showed extensive left antero-mesial temporal hypometabolism.

Ictal SPECT (with SISCOM post-processing analysis) showed hyperperfusion in the left infero-mesial temporal and insular regions (*figure 3*).

After discussion of the results of the evaluation in the presurgical patient management conference (PMC), it was recommended that the patient underwent an invasive evaluation with placement of subdural grids and depth electrodes in the left temporo-frontal regions, with the main goals of accurate definition of the ictal onset (epileptogenic region) and the performance of a “memory sparing”, tailored surgical resection.

The invasive video-EEG evaluation for the definition of the seizure onset area and the mapping of cortical function in the left hemisphere consisted of two phases. During the first phase, subdural electrodes (seven subdural plates and strips for a total of 136 electrode contacts) and depth electrodes (two depth electrodes with eight contacts each) were placed over left lateral and basal temporal areas, as well as lateral, mesial, and basal frontal regions (*figure 4*).

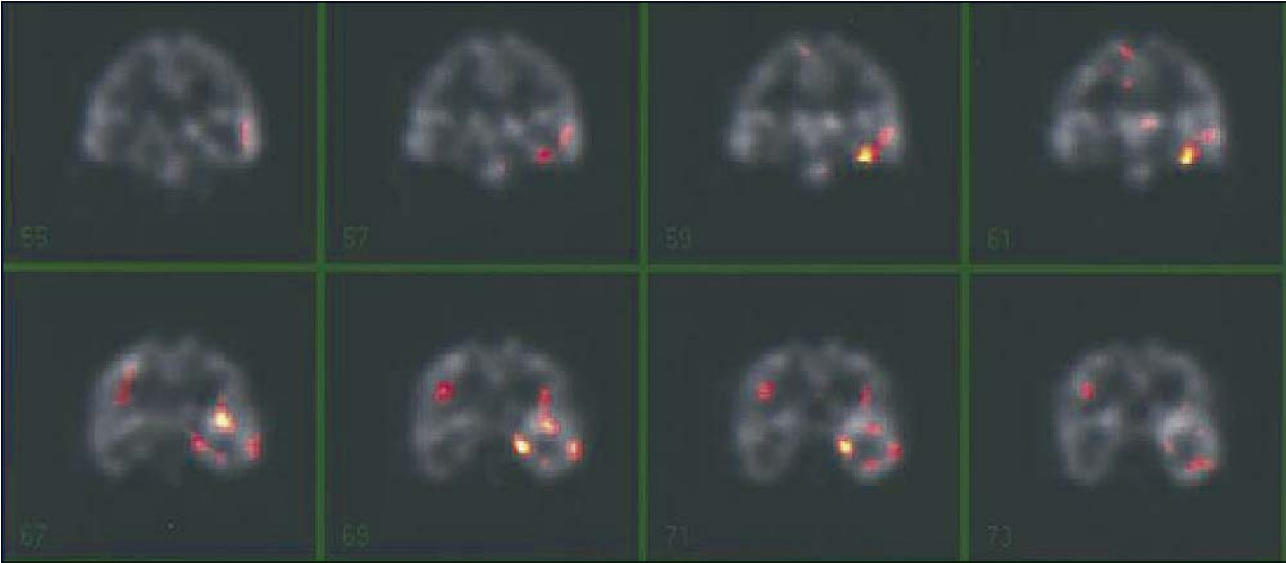


Figure 3. Ictal SPECT hyperfusion in the left infero-mesial temporal and insular regions.

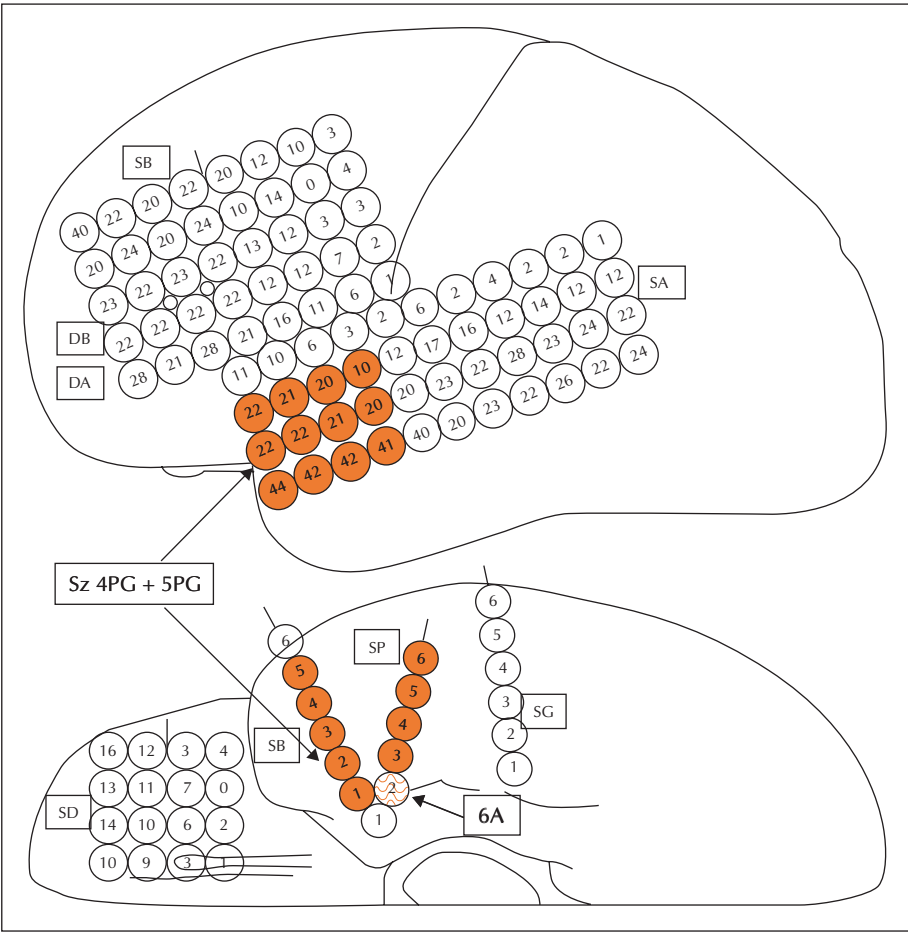


Figure 4. Places of the electrodes in invasive video-EEG.

Results of the first phase of the invasive evaluation

As shown in *figure 1*, interictal spikes were localized in the left basal temporal region (frequency once every 10 to 20 seconds, at times rhythmic, 80% of discharges), and in the left lateral temporal area (frequency once every 10 to 20 minutes, 20% of discharges).

Ictal recordings showed electrocorticographic (EcoG) patterns that were localized to the mid-basal temporal and

temporo-polar regions (*figures 5 and 6*). No ictal patterns were recorded from the orbito-frontal regions.

The second phase of the evaluation consisted of removal of subdural plates, strips, and depth electrodes, with re-insertion of depth electrodes into the left temporal lobe (as shown in *figure 7*; temporal pole, left amygdala, head and body of the left hippocampus). The goal of this phase was to determine if the epileptogenic zone was localized in the neocortical temporo-polar region, sparing the hippocampal formation or in the hippocampus.

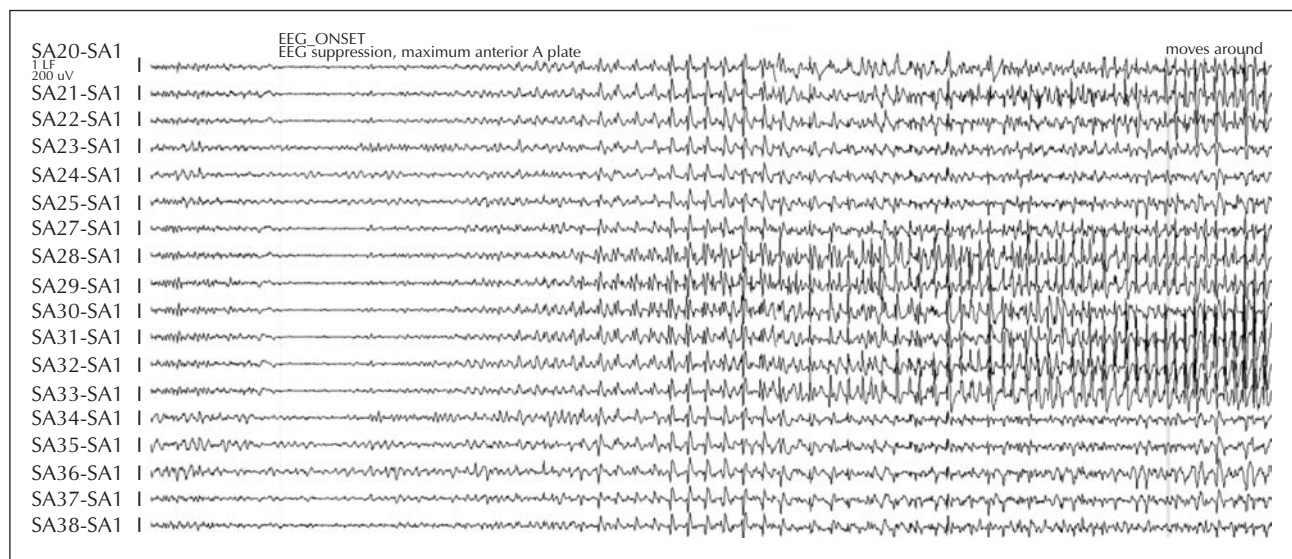


Figure 5. Electrographic Seizure Pattern.

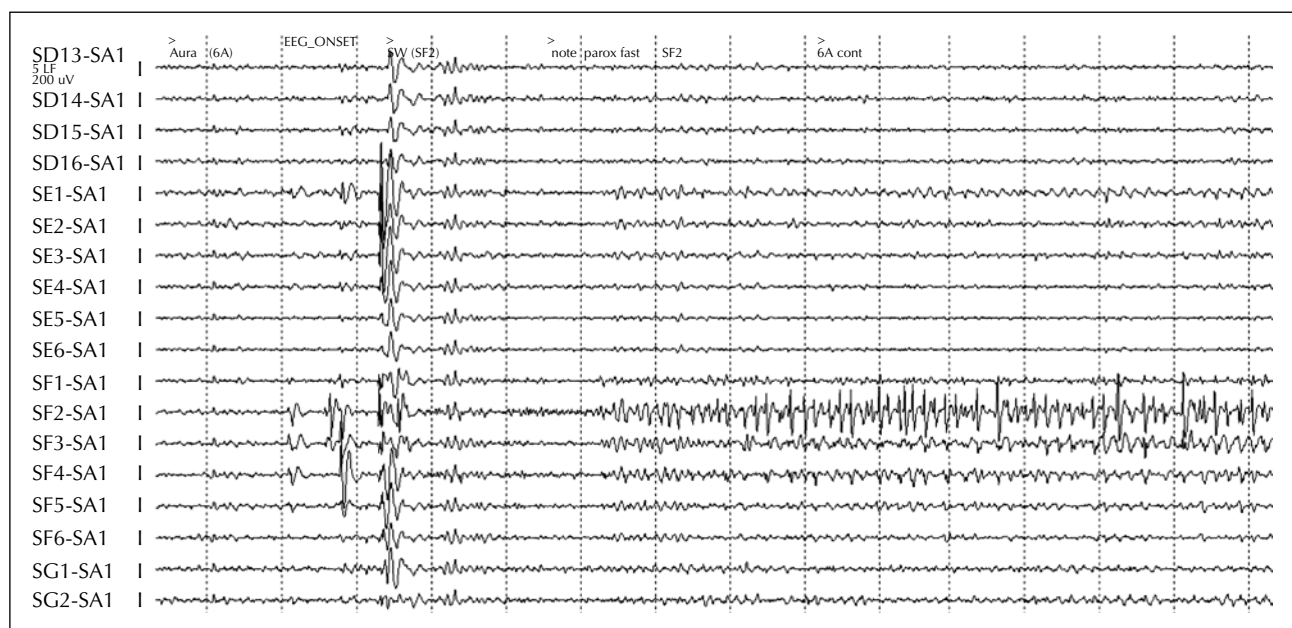


Figure 6. Electrographic Aura Ictal Pattern.

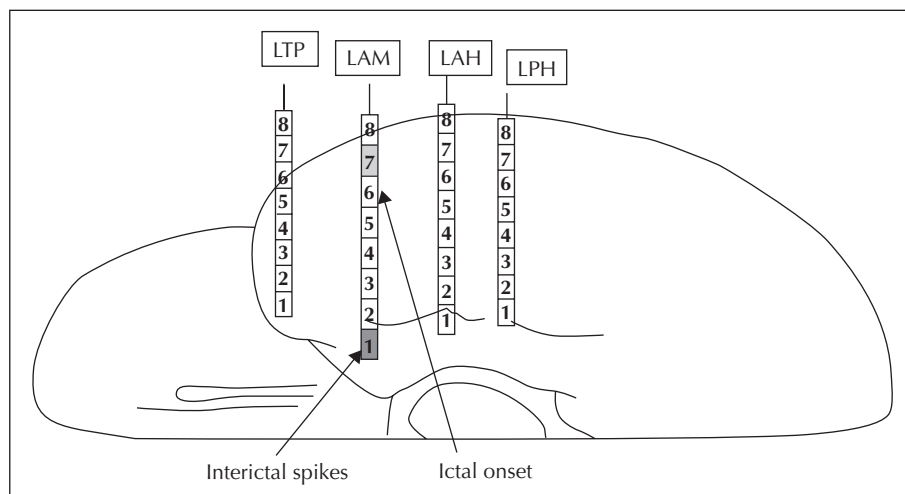


Figure 7. Second invasive evaluation. Topography of depth electrodes.

LTP = left temporal pole; LAM = left amygdala; LAH = left anterior hippocampus (head); LPH = left posterior hippocampus (body).

Results of the second phase of the invasive evaluation

As shown in figure 7, interictal spikes were localized in the left amygdala (occurring at a frequency of once every 10 to 20 seconds, 80% of discharges), and to a lesser extent in the left anterior hippocampus (at a frequency of once every 2 to 4 minutes, 20% of the discharges).

Ictal recordings

The ictal EcoG patterns of all three recorded seizures were mapped to the left anterior temporal lobe region (electrode LAM7 in figures 7 and 8).

In summary, the interictal epileptiform discharges were recorded from the left amygdala as well as the left anterior

basal temporal region, but electro-clinical seizures were mapped to the left lateral anterior temporal lobe. There was no clear evidence for any ictal EcoG patterns arising from the left hippocampus.

The subdural and depth electrodes were removed and two months later, the patient was readmitted for a tailored resection of the left amygdala and left anterior and lateral temporal neocortex, sparing the hippocampus (September 2004).

Pathological examination of the resected tissue showed changes consistent with neocortical columnar disorganization and dyslamination (Type 1A MCD) (Palmini *et al.* 2004).

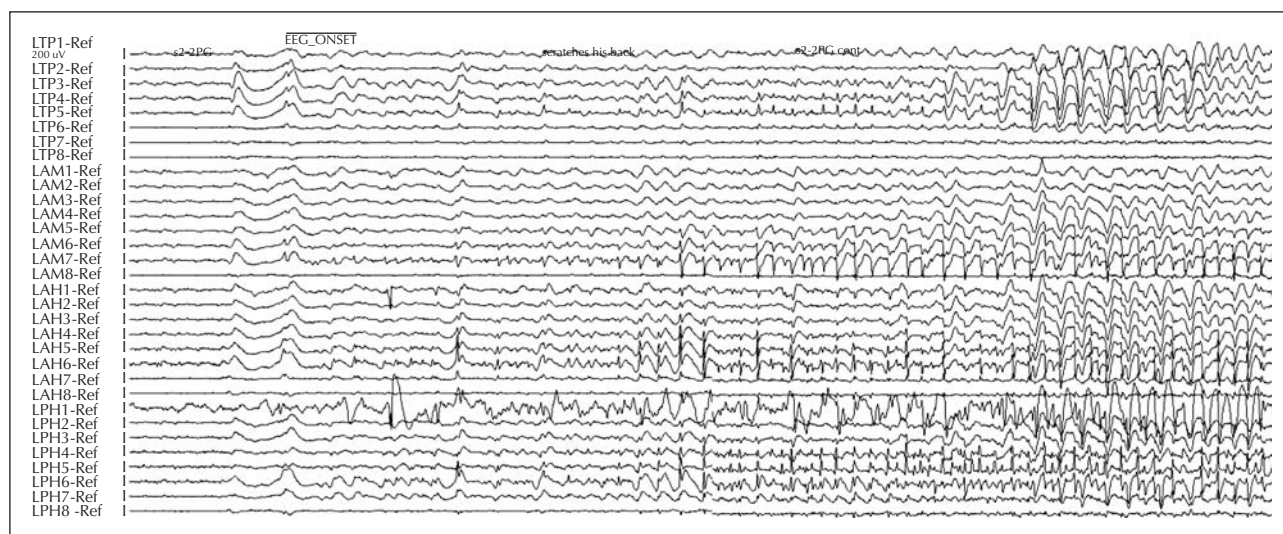


Figure 8. Depth electrodes Seizure Pattern.

Seizure and memory outcome

Twelve months after the resective surgery, the patient remains seizure-free on two anti-epileptic medications (Levetiracetam and oxcarbazepine). Repeat neuropsychological testing approximately six months after his surgery again revealed difficulty with the immediate recall of visuospatial stimuli and difficulty in naming items to confrontation. Re-administration of the Wechsler Memory Scale – Third Edition produced an Auditory Immediate Memory Index of 102, an Auditory Delayed Memory Index of 102, and an Auditory Delayed Recognition Index of 90, all of which are average. His Visual Immediate Memory Index score on re-testing was 84 (low-average) whereas his Visual Delayed Memory Index score was 103 (average). He also showed evidence of slowed, fine motor speed bilaterally and slowed manual dexterity with the dominant right hand. Comparison of the results of this re-testing with those of his baseline evaluation revealed modest declines in the immediate free recall of narrative passages and details of pictured scenes. These apparent declines were mild and, based on regression-based change norms (Martin *et al.* 2002), were within the range of normal variability given the test-retest reliability of those respective measures. His delayed recall of visuospatial information was also within the range of normal variability, but his delayed free recall of narrative passages exceeded that range. Rather than demonstrating mild improvement as a consequence of his previous exposure to test stimuli, his delayed free recall of paragraphs of information was slightly less efficient than noted at baseline. Using regression-based change norms (Martin *et al.* 2002), the patient's delayed free recall of narrative passages exceeded the 90% confidence interval, indicating that such a discrepancy on re-testing would occur less than ten times out of 100 by chance alone. His retention of the information that he was able to encode was quite good, however; he retained 78–100% of the verbal material that he was able to retrieve in the course of the immediate recall trials. His word fluency, in contrast, was more efficient than previously noted. Whereas his performance on a timed, word fluency task had been in the extremely low to borderline range, on re-testing his performance was well within the average range. His performance on other neuropsychological measures was comparable to his level of ability at baseline.

Discussion

The pre-surgical management of this case illustrates the role of invasive evaluation using a combination of subdural grids and depth electrodes in a staged approach for accurate definition of the epileptogenic zone in a case of left hemisphere dominant temporal lobe epilepsy with normal MRI and excellent memory function. The main goal of accurate localization and delineation of the epi-

leptogenic zone was to enable the performance of a tailored resection that would result in seizure control without postoperative memory decline (namely hippocampus-sparing resection).

As a group, patients with dominant hemisphere temporal lobe epilepsy suffer from seizures that are due to neocortical epileptic pathologies (e.g. cortical dysplasia) especially in the setting of normal MRI; there is a definite need for accurate localization of the epileptogenic zone and the mapping of its extent. In addition, the relationship between the epileptogenic cortex and the speech area needs to be adequately defined. The challenge presented by the above case was to accurately define the location of the seizure-onset zone within rather large and difficult to assess areas of the brain that included the posterior/mesial orbito-frontal region, the insula, the mesial parahippocampal/entorhinal neocortical region, and the amygdalo-hippocampal complex. Surface recordings are helpful in lateralizing the epileptogenic zone and enable its localization to one or two lobes (in our case these recordings lateralized the seizure-onset zone and approximated its localization to at least two large lobes; frontal and temporal). Subdural grids are essential for both epileptogenic area definition and functional mapping; invasive recordings with subdural grids are extremely helpful in the accurate localization of epileptogenic regions located on the cortical surface, but are inaccurate in the definition of EcoG patterns arising from deeper generators such as the insula (that is not well covered by subdural electrodes because of anatomic-technical reasons), and the amygdalo-hippocampal complex (Uematsu *et al.* 1990, Behrens *et al.* 1994, Dogali *et al.* 1994, Davis *et al.* 1999, Murphy *et al.* 2001, Murphy *et al.* 2002, Morris *et al.* 2004). The hippocampus poses major problems, as recording of epileptic activities from an electrode covering the parahippocampal gyrus may point to an epileptogenic neocortex or hippocampus. Alternatively, some epileptic activities arising from the hippocampus may not be detected on subdural electrodes (personal observation). The limitations of the subdural/cortical surface electrode mapping in the definition of deep epileptic foci are at least in part addressed in the technique of intracerebral depth electrodes (stereoencephalography, SEEG) that was introduced by Bancaud and Talairach and later was extensively used in many – mostly European – epilepsy surgery centers (Bancaud *et al.* 1970, Cabrini *et al.* 1975, Carapella *et al.* 1976, Bancaud 1980, Engel *et al.* 1990, Wieser 1991, Quesney *et al.* 1992, Avanzini 1994, Bartolomei *et al.* 2005). The advantages of SEEG include its ability to sample deep areas of the brain and anatomically distant regions, and both hemispheres (Kahane *et al.* 2006). In addition to the spatial advantages and limitations of both invasive techniques, there is the issue of temporal definition of the electrical epileptic “ictal” activities and their patterns. We believe that the epileptogenic area is defined by the onset of an evolving electrocorticographic

pattern (paroxysmal fast, and/or repetitive spiking) that is independent of its spread characteristic (Boonyapisit *et al.* 2003). The resection of this rather limited area should therefore result in the control of epilepsy (Lüders *et al.* 2006). This assumption is validated in this case and many other cases where patients became seizure-free after a resection of the ictal-onset region.

In the present case, the staged evaluation indicated a circumscribed epileptogenic focus that did not include the hippocampus. Had his surgery included resection of the hippocampus, the patient would most likely have experienced a considerably more dramatic decrement in his verbal memory ability, as he was at increased risk of such a decrement. His increased risk for verbal memory decline was suggested by his relatively intact verbal memory prior to surgery (Naugle *et al.* 1988, Chelune *et al.* 1991), the normal appearance of hippocampal structures on MRI (Seidenberg *et al.* 1996), and his intact recall of information that had been presented after right injection during Wada testing (Kneebone *et al.* 1995). Together, these risk factors indicated that the patient was at high risk of a decrement in verbal memory if he underwent a traditional or standard, dominant temporal lobectomy, including the hippocampus. The tailored surgery based on the two-tiered/two-staged monitoring approach seemed to have resulted in a more tailored resection, with a lesser effect on verbal memory functioning. By limiting the resection to the left amygdala and left anterior/lateral temporal neocortex and sparing the hippocampus along with the main input to the hippocampus via the fusiform and parahippocampal gyri in the medial temporal lobe, memory function was largely spared. With the exception of the mild apparent decrement in the delayed free recall of narrative passages, his performance on verbal memory tasks was within the range of normal variability. This high functioning individual, with intact memory functioning prior to surgery, retained sufficient memory ability to resume his responsibilities as a physician after surgery.

In conclusion, the presurgical and surgical management of this single case shows that a multi-stage invasive monitoring approach that combines subdural grids and depth electrodes recordings may lead to an excellent seizure outcome with preservation of memory function (through the sparing of the hippocampal formation) in a case of non-lesional temporal lobe epilepsy. □

References

- Avanzini G. Discussion of stereoelectroencephalography. *Acta Neurol Scand* 1994; 152(Suppl.): 70-3.
- Bancaud J. Surgery of epilepsy based on stereotactic investigations – the plan of the SEEG investigation. *Acta Neurochir Suppl (Wien)* 1980; 30: 25-34.
- Bancaud J, Angelergues R, Bernouilli C, *et al.* Functional stereotaxic exploration (SEEG) of epilepsy. *Electroencephalogr Clin Neurophysiol* 1970; 28: 85-6.
- Bartolomei F, Khalil M, Wendling F, *et al.* Entorhinal cortex involvement in human mesial temporal lobe epilepsy: an electrophysiologic and volumetric study. *Epilepsia* 2005; 46: 677-87.
- Behrens E, Zentner J, van Roost D, *et al.* Subdural and depth electrodes in the presurgical evaluation of epilepsy. *Acta Neurochir (Wien)* 1994; 128: 84-7.
- Boonyapisit K, Najm I, Klem G, *et al.* Epileptogenicity of focal malformations due to abnormal cortical development: direct electrocorticographic-histopathologic correlations. *Epilepsia* 2003; 44: 69-76.
- Cabrini GP, Ettore G, Marossero F, *et al.* Surgery of epilepsy: some indications for SEEG. *J Neurosurg Sci* 1975; 19: 95-104.
- Carapella C, Colicchio G, Gentilomo A, *et al.* "Chronic" electrodes in SEEG exploration of partial epilepsies. *Acta Neurochir (Wien)* 1976: 3-8.
- Cascino GD, Buchhalter JR, Mullan BP, *et al.* Ictal SPECT in non-lesional extratemporal epilepsy. *Epilepsia* 2004; 45(Suppl 4): 32-4.
- Chelune GJ, Lüders H, Awad IA. Prediction of cognitive change as a function of preoperative ability status among temporal lobectomy patients seen at 6-month follow-up. *Neurology* 1991; 41: 399-404.
- Davis LM, Spencer DD, Spencer SS, *et al.* MR imaging of implanted depth and subdural electrodes: is it safe? *Epilepsy Res* 1999; 35: 95-8.
- Dogali M, Devinsky O, Luciano D, *et al.* Invasive intracranial monitoring, cortical resection and multiple subpial transection for the control of intractable complex partial seizure of cortical onset. *Stereotact Funct Neurosurg* 1994; 62: 222-5.
- Engel Jr. J, Henry TR, Risperger MW, *et al.* Presurgical evaluation for partial epilepsy: relative contributions of chronic depth-electrode recordings versus FDG-PET and scalp-sphenoidal ictal EEG. *Neurology* 1990; 40: 1670-7.
- Hogan RE, Kaiboriboon K, Osman M. Composite SISCOM images in mesial temporal lobe epilepsy: technique and illustration of regions of hyperperfusion. *Nucl Med Commun* 2004; 25: 539-45.
- Hogan RE, Wang L, Bertrand ME, *et al.* MRI-based high-dimensional hippocampal mapping in mesial temporal lobe epilepsy. *Brain* 2004; 127: 1731-40.
- Kahane P, Landré E, Minotti L, Francione S, Ryvlin P. The Bancaud and Talairach view on the epileptogenic zone: a working hypothesis. *Epileptic Disord* 2006; 8(Suppl. 2): S16-26.
- Kneebone AC, Dinner DS, Naugle RI, *et al.* Use of the contralateral intracarotid amobarbital procedure to predict material specific memory change following anterior temporal lobectomy. *Epilepsia* 1995; 36: 857-65.
- Koepp MJ, Woermann FG. Imaging structure and function in refractory focal epilepsy. *Lancet Neurol* 2005; 4: 42-53.
- Lüders HO, Nair D, Bingman W. The epileptogenic zone: general principles. *Epileptic Disord* 2006; 8: S1-9.

- Martin R, Gilliam F, Mackey M, *et al.* Determining reliable cognitive change after epilepsy surgery; Development of reliable change indices and standardized regression-based change norms for the WMS-III and WAIS-III. *Epilepsia* 2002; 43: 1551-8.
- Morris K, O'Brien TJ, Cook MJ, *et al.* A computer-generated stereotactic "Virtual Subdural Grid" to guide resective epilepsy surgery. *AJNR Am J Neuroradiol* 2004; 25: 77-83.
- Murphy M, O'Brien TJ, Morris K, *et al.* Multimodality image-guided epilepsy surgery. *J Clin Neurosci* 2001; 8: 534-8.
- Murphy MA, O'Brien TJ, Cook MJ. Insertion of depth electrodes with or without subdural grids using frameless stereotactic guidance systems--technique and outcome. *Br J Neurosurg* 2002; 16: 119-25.
- Naugle RI, Chelune G, Lüders H. The relationship between pre-surgical memory function and memory changes following temporal lobectomy. *Epilepsia* 1988; 29: 669.
- Newberg AB, Alavi A. PET in seizure disorders. *Radiol Clin North Am* 2005; 43: 79-92.
- Palmini A, Najm I, Avanzini G, *et al.* Terminology and classification of the cortical dysplasias. *Neurology* 2004; 62: S2-S8.
- Quesney LF, Constain M, Rasmussen T, *et al.* How large are frontal lobe epileptogenic zones? EEG, ECoG, and SEEG evidence. *Adv Neurol* 1992; 57: 311-23.
- Rosenow F, Lüders H. Presurgical evaluation of epilepsy. *Brain* 2001; 124: 1683-700.
- Seidenberg M, Dohan FC, Wyler AR, *et al.* Hippocampal sclerosis and verbal encoding ability following anterior temporal lobectomy. *Neuropsychologia* 1996; 34: 699-708.
- Uematsu S, Lesser R, Fisher R, *et al.* Resection of the epileptogenic area in critical cortex with the aid of a subdural electrode grid. *Stereotact Funct Neurosurg* 1990; 54-55: 34-45.
- Urbach H, Hattingen J, von Oertzen J, *et al.* MR imaging in the presurgical workup of patients with drug-resistant epilepsy. *AJNR Am J Neuroradiol* 2004; 25: 919-26.
- Van Paesschen W. Ictal SPECT. *Epilepsia* 2004; 45(Suppl 4): 35-40.
- Vattipally VR, Bronen RA. MR imaging of epilepsy: strategies for successful interpretation. *Neuroimaging Clin N Am* 2004; 14: 349-72.
- Wieser HG. Temporal lobe epilepsy, sleep and arousal: stereo-EEG findings. *Epilepsy Res* 1991(Suppl. 2): 97-119.