

Benign neonatal sleep myoclonus

Catherine Marx¹, Marcelo Rodrigues Masruha², Eliana Garzon¹, Luiz Celso Pereira Vilanova²

¹ Epilepsy Treatment and Research Unit

² Division of Child Neurology, Department of Neurology and Neurosurgery, Federal University of São Paulo, São Paulo, Brazil

Received August 14, 2007; Accepted March 14, 2008

ABSTRACT – Benign neonatal sleep myoclonus is a non-epileptic disorder. This phenomenon of the first weeks of life is characterized by erratic myoclonic jerks occurring only during sleep and with no electroencephalographic changes. It is not associated with perinatal complications, disappears spontaneously within two to four months, and it does not compromise future development. We illustrate with a video this relatively frequent condition, which is often misdiagnosed as epileptic in nature, and discuss the clinical characteristics and differential diagnosis. [*Published with video sequences*].

Key words: myoclonus, benign neonatal sleep myoclonus, non-epileptic events, sleep

Case report

A 27-day-old, male newborn was transferred to our hospital because of a myoclonic “epileptic status”. He was born at a primary care hospital by normal delivery, following an uneventful term gestation, weighing 3.84 kg and with a normal cephalic measurement (35 cm). There was no family history of epilepsy or any other neurological impairment. In the first days of life, he started to present multiple episodes of myoclonic jerks, with a frequency of one to three per second, affecting all limbs, especially the upper extremities, occurring in clusters and only during sleep. He was transferred to the intensive care unit (ICU) and treated as status epilepticus. There were no changes in skin color, eye deviation, face movements, heart rate or oxygen saturation during any of the events. The pediatricians considered it to be an epileptic disorder and initiated antiepileptic drug (AED) treatment with phenobarbital. He

remained sleepy with the jerks worsening. At that time, the infant received intravenous phenytoin, with no improvement of the abnormal movements. After 27 days being treated for epilepsy without improvement, he was transferred to our hospital, a tertiary care unit with neurological support.

On admission to our hospital his vital signs, general physical and neurological examinations were normal. Normal values were obtained for the following parameters: blood glucose, complete blood count (CBC), serum electrolytes, LDH, CK, total and partial fat analysis, hepatic and renal function.

The patient underwent 24-hour video-EEG monitoring using colloidon-fixed electrodes in the neonatal arrangement, and simultaneous electro-oculogram, ECG and electromyogram from right upper and left lower limbs and head, including all sleep stages and wakefulness (*figures 1 and 2*).



Correspondence:

C. Marx
Department of Neurology and Neurosurgery,
Botucatu Street, 720,
Federal University of São Paulo,
São Paulo,
Brazil 04023-9000
<marxcatherine@hotmail.com>

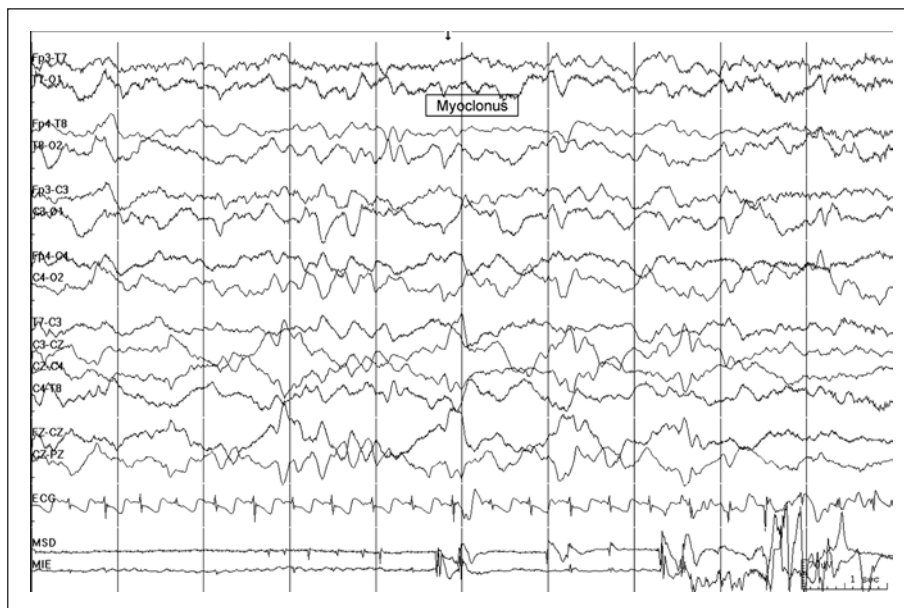

Figure 1. Neonatal electroencephalographic (EEG) montage, electrocardiogram (ECG) and electromyogram of right upper and left lower limbs (MSD and MIE) during sleepiness when occurs a brief myoclonic jerk with movement artifact represented in upper and lower limbs, without any alteration of EEG.

Continuous, twenty-four hour-registered traces demonstrated brief erratic myoclonic jerks, during sleep and sleepiness, affecting the head and upper limbs, involving mainly flexor muscle groups. Occasionally, some jerks of the low left limb were observed (*see video sequence*). Bouts of myoclonic jerks lasted, at most, 50 seconds.

These jerks were mostly of high amplitude. The movements stopped abruptly when the patient was aroused by touch or repositioning, and tended to recur a few minutes later. There were only muscular artifacts during the event, no paroxysmal discharges and no disturbances at the electrical baseline were observed. The heart rate did not

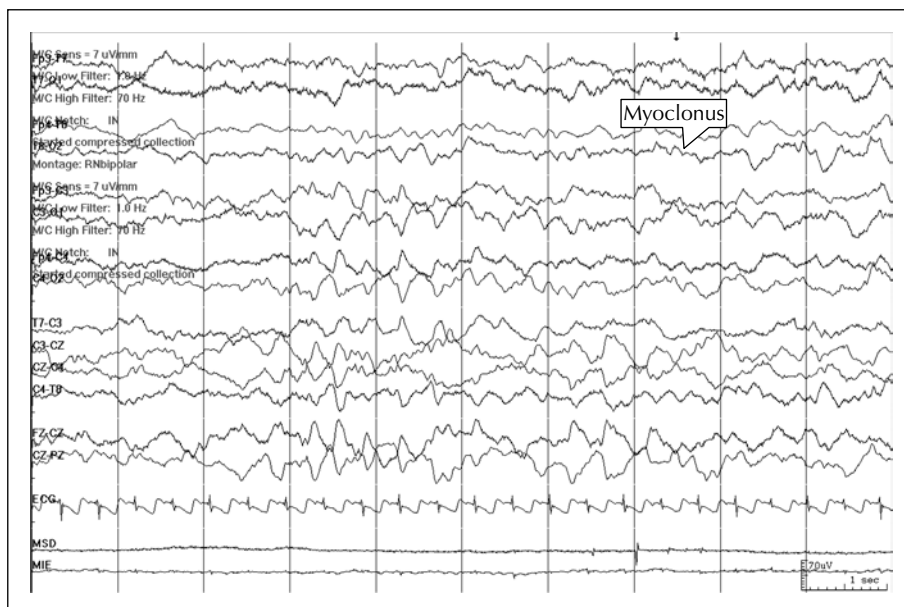


Figure 2. Another brief subtle myoclonic jerk occurs during sleepiness, this time of the lower limbs (not represented in the picture) showing no other alteration of the parameters monitored-EEG, ECG and EMG of upper limbs.

change much from baseline during the myoclonic jerks. Blood pressure was not taken. The jerks never occurred when the infant was awake.

A full re-evaluation of the infant was performed six months later. The neurological examination was normal and there was normal development. The episodes of myoclonic jerks resolved spontaneously over the third month of life.

Discussion

Benign neonatal sleep myoclonus (BNSM) should be considered a sleep disorder and the use of the term "seizure" in its description should be avoided (Daoust-Roy and Seshia 1992). It was first described in 1982 by Coulter and Allen. They reported three infants who presented with repetitive, bilateral, myoclonic jerks, involving mainly the forearms and hands. Neurological examination and electroencephalograms (EEG) were normal and remained normal during follow-up (Coulter and Allen 1982).

BNSM occurs in neurologically healthy neonates, with onset in the first month of life, more commonly in the first two weeks, usually disappearing before six months of age and requires no treatment (Richelme *et al.* 1990). The myoclonic jerks may be focal, multifocal or generalized, occurring in clusters with a frequency of one to 15 per second, and they do not stop with restraint, mimicking neonatal seizures. However, several features of BNSM help in its recognition: it only occurs during non-REM sleep or quiet sleep (mainly in stages III and IV), and tends to resolve during REM sleep, stopping abruptly and consistently when the child is aroused and electrographic seizures do not occur during events (Goraya *et al.* 2001). The episodes can be exacerbated or provoked by administration of benzodiazepines (Daoust-Roy and Seshia 1992). There are no sequelae, and psychomotor and cognitive development is normal. The syndrome is usually sporadic; only a few familial cases have been reported in the literature (Cohen *et al.* 2007, Paro-Panjan and Neubauer 2008).

The differential diagnoses for neonatal sleep myoclonus include benign familial and non-familial neonatal seizures, benign myoclonus of early infancy, essential myoclonus and myoclonic seizures (Daoust-Roy and Seshia 1992, Coulter and Allen 1982, Richelme *et al.* 1990, Goraya *et al.* 2001). In healthy, newborns the main differential diagnosis primarily concerns benign familial and non-familial neonatal seizures. BNSM usually manifests on the second or third postnatal day. Seizures occur 10 to 20 times a day and have a characteristic electroclinical presentation, which consists of EEG flattening accompanied by apnoea and tonic motor activity followed by bilateral discharge of spikes and slow waves accompanied by clonic activity. It is a self-limiting disorder usually resolving after one to six months of age, however 10% of infants exhibit subsequent non-febrile seizures and may

require long-term anticonvulsant therapy. Normal neurological development is expected (Volpe 2001).

Benign myoclonus of early infancy, first described by Fejerman and Lombroso, is a paroxysmal phenomenon of the first two years of life, which occurs in neurologically healthy infants during wakefulness, and is usually triggered by excitement or frustration (Lombroso and Fejerman 1977). It is characterized by a group of spasms that usually appears during meals, the intensity and severity of which increase after weeks or months and tending to resolve within three months. Occasional episodes may occur later. MRI and EEG studies are normal and no treatment is necessary (Pachatz *et al.* 1999).

Essential myoclonus is a sporadic or hereditary disorder with a benign course, exaggerated by muscle activation and suppressed by consumption of alcohol. Age-at-onset ranges from two months to 16 years, with involuntary movements of the face, neck, or extremities and with no known etiology. It has been linked to a mutation on chromosome 7 (Cohen *et al.* 2007).

Under most circumstances neonatal seizures occur in a setting of perinatal insult such as asphyxia and metabolic or infectious processes. The relationship of the attacks with quiet sleep, normal clinical and developmental status of the infant, and the normality of the EEG are important clues to a diagnosis of BNSM.

The etiology of BNSM is uncertain. Some authors have suggested that it is a maturation disorder of the brainstem/reticular activating system, an area of the brain known to be linked with both myoclonic movements and the control of normal sleep. Other authors have suggested that a transient disorder of the serotonergic system might play a role in the pathogenesis of this disorder (Resnick *et al.* 1986). Siblings have been seen with BNSM, suggesting a genetic link, but this also remains speculative (Noone *et al.* 1995).

Other authors have reported cases of BNSM, but few have been documented polygraphically. The progressive increase in the phenomenon up to the third week of life could depend of the increase in quiet sleep with respect to active sleep normal at this age (Di Capua *et al.* 1993). The antiepileptic drug treatment employed probably contributed to increase the frequency of myoclonic jerks. The infant was treated for status epilepticus with an AED causing sedation and an increase in quiet sleep time.

The prevalence is unknown; the condition is under-recognized (Ramelli *et al.* 2005). Maneuvers such as rocking in a head-to-toe direction and repetitive sound stimuli have been described as activating procedures for myoclonic jerks in BNSM (Alfonso *et al.* 1995, Paro-Panjan and Neubauer 2008). The consequences of misdiagnosing BNSM as an epileptic event in this case were troublesome, leading to lengthened hospitalisation, unnecessary expensive, complementary investigations, parental anxiety, and pointless administration of AED that exacerbated the clinical symptomatology.

BNSM is expressed as myoclonic jerks occurring only during sleep, soon after birth, interrupted on arousal or spontaneously, in a neurologically normal infant and naturally remitting in a few months. Recognition as an innocuous and non-epileptic entity is important so that needless treatment, unnecessary investigations and undue hospitalization can be avoided, and parental anxiety minimized (Lombroso and Fejerman 1977, Coulter and Allen 1982, Resnick et al. 1986, Richelme et al. 1990, Daoust-Roy and Seshia 1992, Di Camua et al. 1993, Noone et al. 1995, Ramelli et al. 2005, Pachatz et al. 1999, Goraya et al. 2001, Volpe 2001, Cohen et al. 2007). □

Acknowledgments. This study was sponsored by Fundação de Amparo à Pesquisa do Estado de São Paulo (FAPESP).

Legend for video sequence

Brief erratic myoclonic jerks occurring in upper and lower limbs simultaneously or not, during sleepiness and quiet sleep in a term newborn baby involving mainly flexor group muscles, ceasing when aroused.

References

- Alfonso I, Papazian O, Jeffries HE. A simple maneuver to provoke benign neonatal sleep myoclonus. *Pediatrics* 1995; 96: 1161-3.
- Cohen R, Shuper A, Strussberg R. Familial benign neonatal sleep myoclonus. *Pediatr Neurol* 2007; 36: 334-7.
- Coulter DL, Allen RJ. Benign neonatal sleep myoclonus. *Arch Neurol* 1982; 39: 191-2.
- Daoust-Roy J, Seshia SS. Benign neonatal sleep myoclonus - a differential diagnosis of neonatal seizures. *Am J Dis Child* 1992; 146: 1236-41.
- Di Capua M, Fusco L, Ricci S, et al. Benign neonatal sleep myoclonus: clinical features and video-polygraphic recordings. *Mov Disord* 1993; 8: 191-4.
- Goraya JS, Poddar B, Parmar VR. Benign neonatal sleep myoclonus. *Indian Pediatr* 2001; 38: 81-3.
- Lombroso CT, Fejerman N. Benign myoclonus of early infancy. *Ann Neurol* 1977; 1: 138-48.
- Noone PG, King M, Loftus BG. Benign neonatal sleep myoclonus. *Ir Med J* 1995; 88: 172.
- Pachatz C, Fusco L, Vigeveno F. Benign myoclonus of early infancy. *Epileptic Disord* 1999; 1: 57-61.
- Paro-Panjan D, Neubauer D. Benign neonatal sleep myoclonus: experience from the study of 38 infants. *Eur J Paediatr Neurol* 2008; 12: 14-8.
- Ramelli GP, Sozzo AB, Vella S, et al. Benign neonatal sleep myoclonus: an under-recognized, non-epileptic condition. *Acta Paediatr* 2005; 94: 962-3.
- Resnick TJ, Moshé SL, Perotta L, et al. Benign neonatal sleep myoclonus - relationship to sleep states. *Arch Neurol* 1986; 43: 266-8.
- Richelme C, Delpont E, Deswart M, et al. A propos d'un cas de myoclonies du sommeil profond du nouveau-né. *Pediatric* 1990; 45: 191-2.
- Volpe JJ. Neonatal seizures. In: Volpe JJ, ed. *Neurology of the newborn*. 4th ed. Philadelphia: Saunders, 2001: 178-214.