

Avoid falling into the depths of the insular trap

Philippe Ryvlin^{1,2}

¹ Department of Functional Neurology and Epileptology, Neurological Hospital, Hospices Civils de Lyon, France

² CTRS-IDEE, Hospices Civils de Lyon, France

ABSTRACT – Recent data have demonstrated that insular seizures can mimic those encountered in temporal lobe epilepsy (TLE), as well as nocturnal hypermotor attacks suggestive of nocturnal frontal lobe epilepsy (NFLE). To illustrate some of the issues raised by these observations, we report our first two patients with suspected TLE and NFLE, respectively, in whom we originally demonstrated an insular ictal onset zone. Patient 1 suffered from daytime seizures characterised by a rising and distressing epigastric sensation rapidly followed by oro-alimentary automatisms, associated with right temporal scalp-EEG ictal discharge. Neuroimaging showed consistent right temporal abnormalities, including MRI signs of hippocampal sclerosis, anterior and mesial glucose hypometabolism, and mesial decrease of benzodiazepine receptors. Intra-cerebral EEG investigation was primarily performed because of several ictal signs and symptoms suggesting a rapid involvement of the perisylvian region, and showed that the patient suffered two types of seizure, one of which arose from the mesial temporal structures, the other was sleep-related and originated in the posterior-inferior portion of the insula. Anterior temporal lobectomy failed to control this second type of seizure. Patient 2 suffered from brief, nocturnal, hypermotor seizures characterised by an indefinable aura followed by agitation, body rolling, scream and pelvic thrust. Interictal and ictal scalp-EEG failed to detect epileptiform discharges, whereas neuroimaging showed left mesial frontal, glucose hypometabolism and decreased benzodiazepine receptors associated with a left fronto-basal arachnoidal cyst. Invasive EEG monitoring was performed with the aim of identifying an orbital or mesial frontal ictal onset, but eventually demonstrated that the seizure originated in the anterior-superior portion of the left insula. The patient did not undergo surgery and died of SUDEP two years later. We discuss the heterogeneity of insular seizure semiology according to functional anatomy, the clinical signs and symptoms that might suggest an insular ictal onset, the indications and types of invasive EEG monitoring that are needed to identify an insular epileptogenic zone definitively, as well as potential surgical treatment.

Keywords: epilepsy, insula, temporal plus epilepsy, epileptogenic zone, temporal lobe epilepsy, nocturnal frontal lobe epilepsy

Correspondence:

Philippe Ryvlin,
Unité 301,
Hôpital Neurologique,
59 bd Pinel,
69003 Lyon,
France
<ryvlin@cermep.fr>

Failure to identify correctly the epileptogenic zone remains a major issue in epilepsy surgery, in particular when no causal brain lesion is observed on MRI. Such failures might be partly ex-

plained by misconceptions regarding the epileptogenic networks underlying specific seizure types, and the sub-optimal use of intra-cerebral EEG investigations. These two pitfalls are

particularly well illustrated by insular seizures which, on the one hand, mimic other seizure types including those encountered in mesial temporal lobe epilepsy (mTLE) and nocturnal frontal lobe epilepsy (NFLE), and on the other hand, require specific depth electrode implantation in order to be detected.

The possibility that insular seizures might be wrongly diagnosed as originating from the temporal lobe, eventually resulting in temporal lobe surgery failure, was suggested more than fifty years ago based on the observation of epileptogenic insular brain lesions and interictal paroxysms recorded over the insula during intraoperative electrocorticography (Guillaume and Mazars 1949a, 1949b, Guillaume *et al.* 1953, Penfield and Jasper 1954). However, this concept attracted little attention over the next half-century, with only a few published case reports of partial epilepsy associated with insular lesions (Roper *et al.* 1993, Taniguchi *et al.* 1998, Cukiert *et al.* 1998, Duffau *et al.* 2002, Seeck *et al.* 2003, Rossetti *et al.* 2005).

During the last ten years, our group as well as others have taken advantage of the safety and versatility of the stereoelectroencephalography (SEEG) method developed by Bancaud and Talairach, to investigate the insula in a large number of patients with drug-resistant, partial epilepsy undergoing long-term invasive monitoring. Using this approach, it was demonstrated that:

- 1) stimulation of the insular cortex can elicit viscerosensitive symptoms reminiscent of those observed in mTLE, including rising epigastric sensations;
- 2) TLE-like seizures can originate in a morphologically normal insula, and
- 3) an insular ictal onset might however, be suspected in seizures characterised by an early occurrence of laryngeal discomfort or throat tightening associated with unpleasant paresthesias or sensations of warmth affecting the perioral region or large somatic territories, followed by focal somatomotor manifestations (Ostrowsky *et al.* 2000, Isnard *et al.* 2000, 2004).

The identification of insular seizures might be further complicated in patients presenting a combination of two seizure types originating in the temporal lobe and in the insula, respectively. This situation, which suggests a temporo-insular epileptogenic zone, belongs to the spectrum of "temporal plus" epilepsies, and might be observed in patients fulfilling the criteria of mTLE, including MRI signs of hippocampal sclerosis (Ryvlin and Kahane 2005).

More recently, we have described another form of insular seizure, characterised by nocturnal hypermotor seizures suggesting either cryptogenic or idiopathic nocturnal frontal lobe epilepsy (NFLE) (Ryvlin *et al.* 2006a, 2006b).

In order to illustrate these various issues, we describe here the observation of the first mTLE and NFLE patients from our centre in whom we originally identified an insular ictal onset.

Observation n°1 (quoted observation n°4 in Isnard *et al.* 2004)

History

This right-handed female had a history of bacterial meningitis at two years of age, during which a convulsive seizure was noted. One year later, the patient suffered a non-febrile, secondarily generalised, complex partial seizure, and was then treated with barbiturates. During the next 20 years, the patient presented only a few seizures, primarily triggered by hyperthermia or poor medication compliance, with up to three years of seizure-freedom off treatment. Then, seizure frequency progressively worsened, despite multiple anti-epileptic drug trials, with up to ten seizures per month by the age of 34 years when a pre-surgical evaluation was initiated.

Seizure description

The majority of seizures occurred during sleep, and could not be recalled by the patient. Conversely, day-time seizures were characterised by an aura, combining a rising and distressing epigastric sensation, hot flush, bilateral simple auditory hallucinations, and at times, teleopsia. Whether the auditory hallucinations preceded or followed the viscerosensitive symptoms could not be fully clarified. During the early phase of the day-time seizures captured during video-EEG monitoring, the patient provided verbal and gesture indications of a rising epigastric sensation, while looking uncomfortable. Conversely, she never reported auditory symptoms during the recorded auras, although she once put her left hand on her left ear as if she were perceiving a sound.

The majority of auras were followed by the stereotyped sequence of ictal signs cited below, which were similarly described by the patient's husband and demonstrated by video-EEG recordings: the subtle, oro-alimentary automatisms would suddenly intensify, turning into chewing or mastication, while the patient started shouting and often put her right hand on her throat or mouth. She would then move her right arm as if calling for help, while saying "quick" repeatedly. Concomitantly, a left sided oculocephalic version would occur, together with a left face, tonic contraction and left arm dystonia, which then progressed to a very tonic posture of the entire body, which was turned to the left. Rubefaction, apnoea, and salivation were also noted. This ictal sequence lasted from one to two minutes, and was followed by post-ictal confusion without aphasia, and, very seldom, secondary generalisation. Nocturnal attacks awakened the patient, who usually first attempted to sit down abruptly, showing a facial expression of discomfort or perplexity, and then presenting a ictal sequence similar to that described for the day time attacks (right hand on the throat and shouting followed by left version and tonic posture). Whether lack of awareness occurred was difficult to assess, since the pa-

tient's response could not be tested once she started to shout for help. She did not remember this behaviour, or the major distress which she seemed to suffer at that time, and had no recollection of nocturnal seizures in general.

Scalp-EEG

Interictal scalp-EEG was usually normal and only rarely demonstrated right temporal, slow waves. Ictal EEG did not disclose any focal discharge prior to the first ictal sign, but then demonstrated a theta rhythmic activity, which clearly predominated over the right centro-temporal region. Right hemispheric post-ictal slowing was also observed.

Neuroimaging

MRI showed a clear-cut, right hippocampal sclerosis (*figure 1A*), but no other abnormality. FDG-PET demonstrated focal hypometabolism over the right mesial temporal and temporo-polar regions (*figure 1B*), whereas [^{11}C]Flumazenil-PET showed a decreased benzodiazepine receptor density restricted to the right hippocampus (*figure 1C*).

Neuropsychology

Neuropsychological testing revealed mildly altered verbal and visuo-spatial memory. The intra-carotid amobarbital procedure confirmed a left hemispheric dominance for speech, and showed impaired right hemispheric memory performance.

Rationale and design of the intra-cerebral EEG investigation

Many aspects of the observation of this patient were consistent with the diagnosis of mTLE, including the initial

rising epigastric sensation, the very early oro-alimentary automatisms, the right temporal scalp-EEG abnormality, and most notably, the MRI and PET findings that showed the typical features observed in mTLE. However, other findings were less indicative, including a past-history of bacterial meningitis rather than febrile convulsions, and the lack of interictal epileptiform discharges on scalp-EEG. The main incentive for performing an intra-cerebral investigation was the suspicion that the right perisylvian region might be part of the epileptogenic zone, based on the following considerations: auditory hallucination was an early symptom, indicating that seizures might originate in the vicinity of the first temporal gyrus; accordingly, the rapid occurrence of mastication and left face, tonic contraction indicated an early involvement of the frontal operculum region; finally, the contralateral version associated with the very tonic and bilateral posture observed during each complex partial seizure, strongly suggested a frontal lobe involvement that we considered unusually intense for mTLE.

Twelve intra-cerebral electrodes, each containing five to 15 leads, were implanted in the right hemisphere targeting the following structures (*figure 2*): amygdala, hippocampus, temporal pole, anterior portion of 1st and 2nd temporal gyrus; posterior portion of 1st, 2nd, 3rd and 4th temporal gyrus; anterior-superior, posterior-superior and posterior-inferior aspects of the insula, frontal operculum, orbito-frontal cortex; frontal pole and anterior portion of 3rd frontal gyrus; anterior and posterior cingulate gyrus, angular gyrus; lingual gyrus.

Intra-cerebral EEG findings

Interictal abnormalities mainly consisted of long trains of pseudo-rhythmic, high amplitude spike and wave or slow waves recorded over the amygdala, the temporal pole,

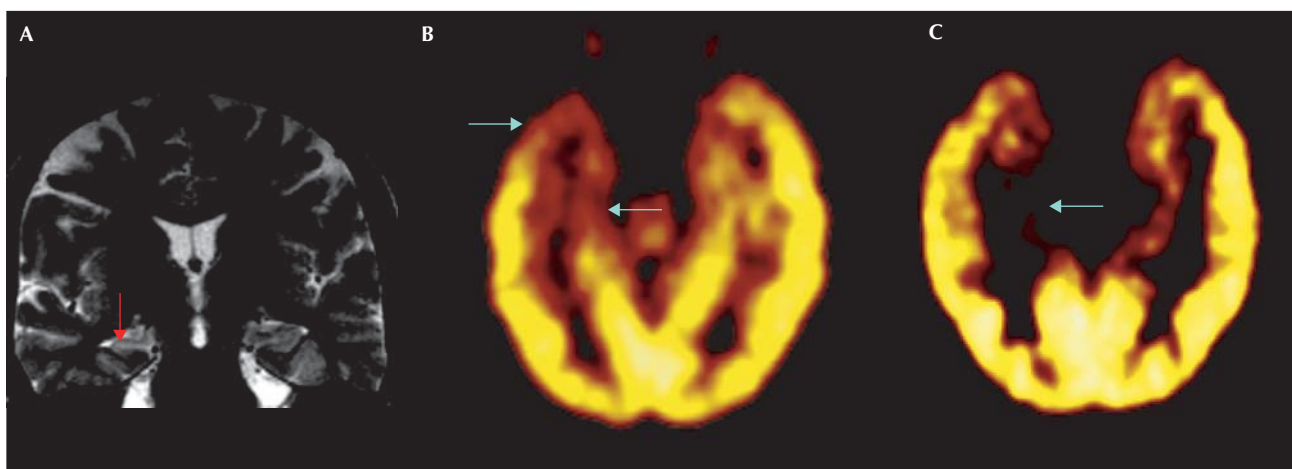


Figure 1. Neuroimaging data in **patient 1**: **A)** MRI shows a clear-cut, right hippocampal sclerosis, but no other abnormality; **B)** FDG-PET demonstrates focal hypometabolism over the right mesial temporal and temporo-polar regions; **C)** [^{11}C]Flumazenil-PET shows a decreased benzodiazepine receptor density restricted to the right hippocampus.

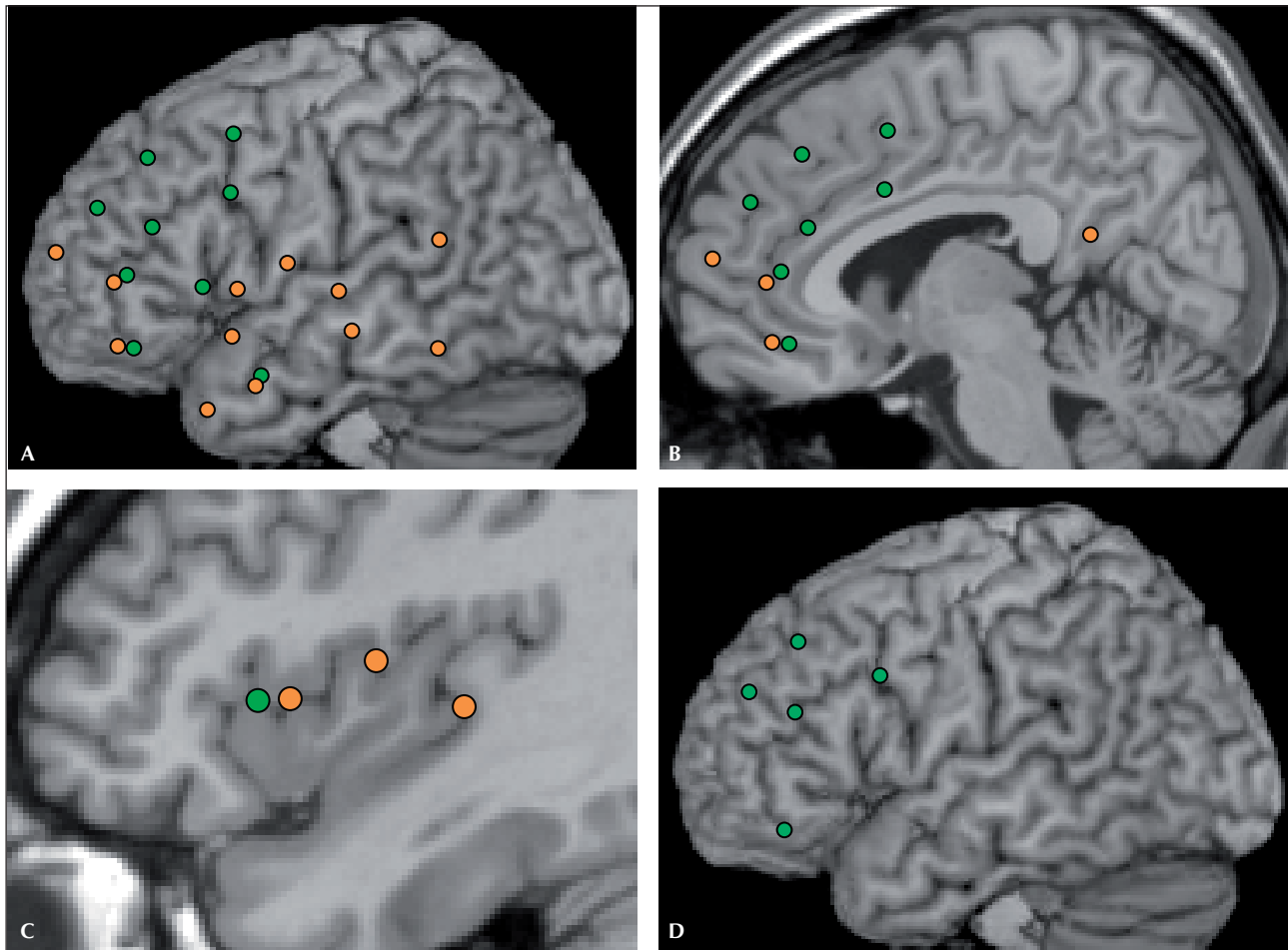


Figure 2. Electrode location of patient 1 (orange) and 2 (green) co-registered on a normal subject, sagittal T1 MRI. **A)** Lateral sagittal view of electrodes implanted ipsilateral to the seizure-onset zone (right hemisphere for patient 1 and left hemisphere for patient 2). Arrows indicate electrodes targeting the insula; **B)** Mesial sagittal view of electrodes implanted ipsilateral to the seizure-onset zone. **C)** Intermediate sagittal view of the electrodes targeting the insula, ipsilateral to seizure-onset; **D)** Lateral sagittal view of electrodes implanted contralateral to the seizure-onset zone (right hemisphere in patient 2).

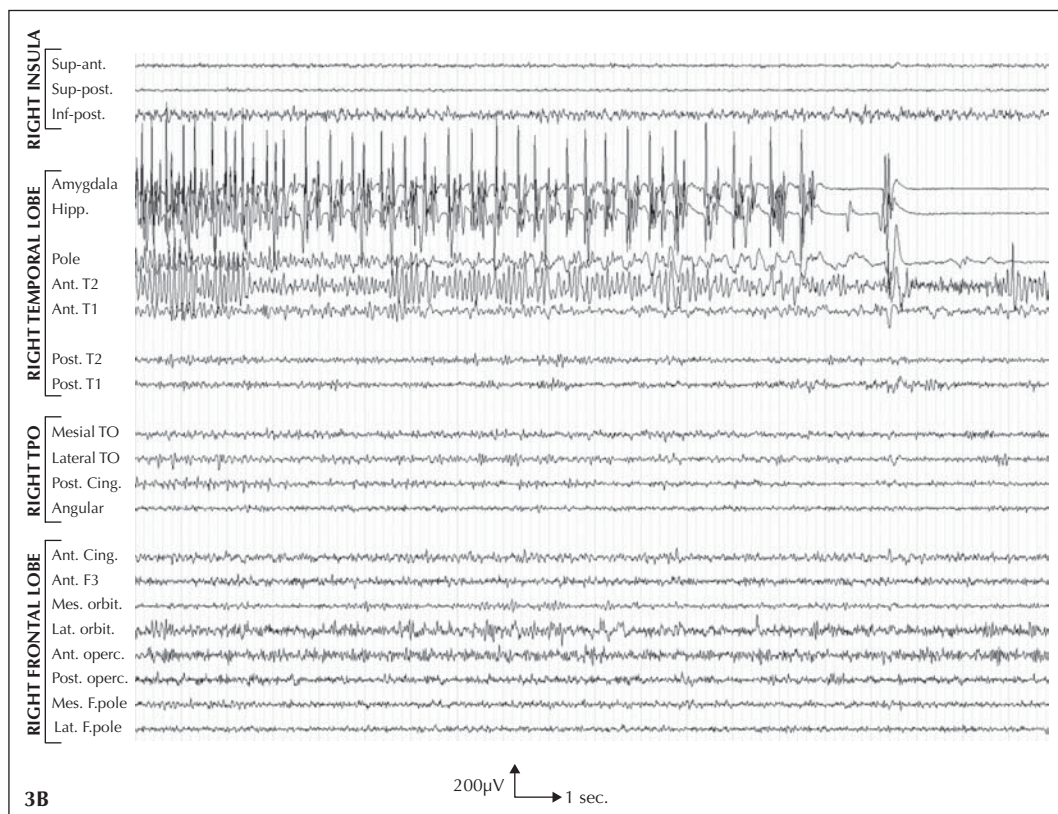
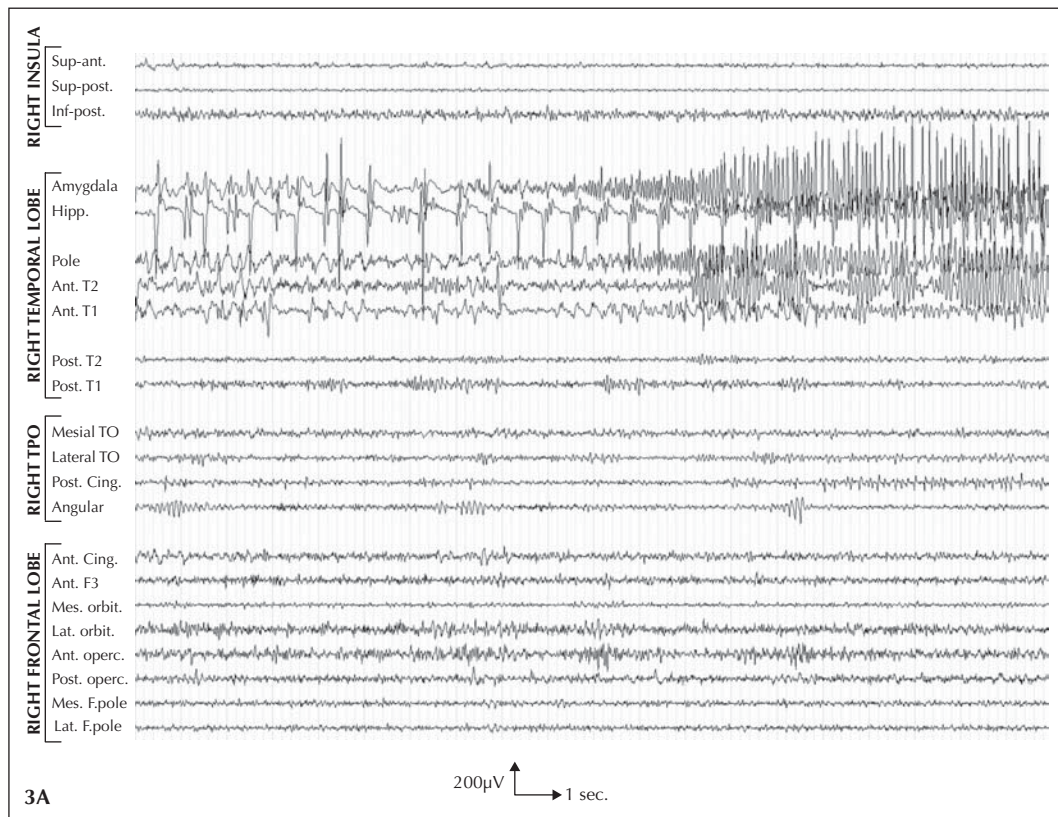
and the anterior aspect of the first and second temporal gyri. Less frequent high amplitude spikes and waves were observed in the hippocampus.

Eight spontaneous seizures were captured, including four which were nocturnal. Three were simple partial seizures during which the patient felt her usual distressing, epigastric sensation, while presenting subtle, oro-alimentary automatisms and facial expression of discomfort. EEG ictal onset was characterized by the occurrence of a few high

amplitude spikes in the right hippocampus, followed by a slowly recruiting theta discharge which affected the right amygdala, hippocampus, anterior aspect of the second temporal gyrus, and temporal pole, almost simultaneously (*figure 3*). This discharge remained localised within the right temporo-limbic and anterior temporal regions until seizure termination, and lasted about 30 seconds.

Three other seizures, one of which was nocturnal, demonstrated a similar electro-clinical pattern at onset, but

Figure 3. Short-lasting, temporo-limbic seizure in patient 1. **A)** EEG ictal onset is characterised by the occurrence of a few high amplitude spikes in the right hippocampus, followed by a slowly-recruiting theta discharge that affects the right amygdala, hippocampus, anterior aspect of the second temporal gyrus, and temporal pole, almost simultaneously. **B)** This discharge remained localised within the right temporo-limbic and anterior temporal regions until seizure termination. Note that all leads are displayed with a similar amplification. Ant = anterior, Post = posterior, Inf = inferior, Sup = superior, Hipp = hippocampus, T1 = first temporal gyrus, T2 = second temporal gyrus, TPO = temporo-parieto-occipital junction, TO = temporo-occipital junction, Cing = cingulate gyrus, F3 = third frontal gyrus, Mes = mesial, Lat = lateral, Orbit = orbito-frontal cortex, operc = operculum, F = frontal.



then progressed to the full blown, complex partial seizure previously described (*figure 4*). This progression was paralleled by an ipsilateral propagation of the ictal discharge to the anterior portion of the first temporal gyrus, all investigated aspects of the insula, the anterior cingulate gyrus, and the frontal operculum. Insular leads first demonstrated a low voltage, theta rhythmic activity that progressed to a sustained spike discharge, the intensity of which predominated over that of all other recorded leads by the end of the seizure. The hippocampus was only slightly involved during this phase of the ictal discharge, which spared the majority of the frontal regions investigated.

The two remaining nocturnal seizures started with a low amplitude theta discharge localised over the posterior and inferior aspect of the right insula, which was observed a few seconds before the first ictal sign (*figure 5*). This dis-

charge later propagated to the posterior superior and anterior superior portions of the right insular cortex, the anterior aspects of the first and second temporal gyri, as well as the ipsilateral temporo-limbic structures and frontal operculum, while increasing in frequency and amplitude. It remained more sustained within the insula during the clinically overt phase of the seizure, but was then followed by a focal, mesial temporal discharge that terminated the attack. From a clinical point of view, the two insular-onset seizures differed mainly from those originating in the temporal lobe by a more abrupt onset and a very rapid appearance of the tonic motor signs. However, the patient did not grab her throat during these two seizures, whereas she did so in two of the three complex partial seizures of temporal lobe origin.

Finally, two seizures were able to be elicited by a low frequency (1 Hz), low intensity (2 mA) electrical stimula-

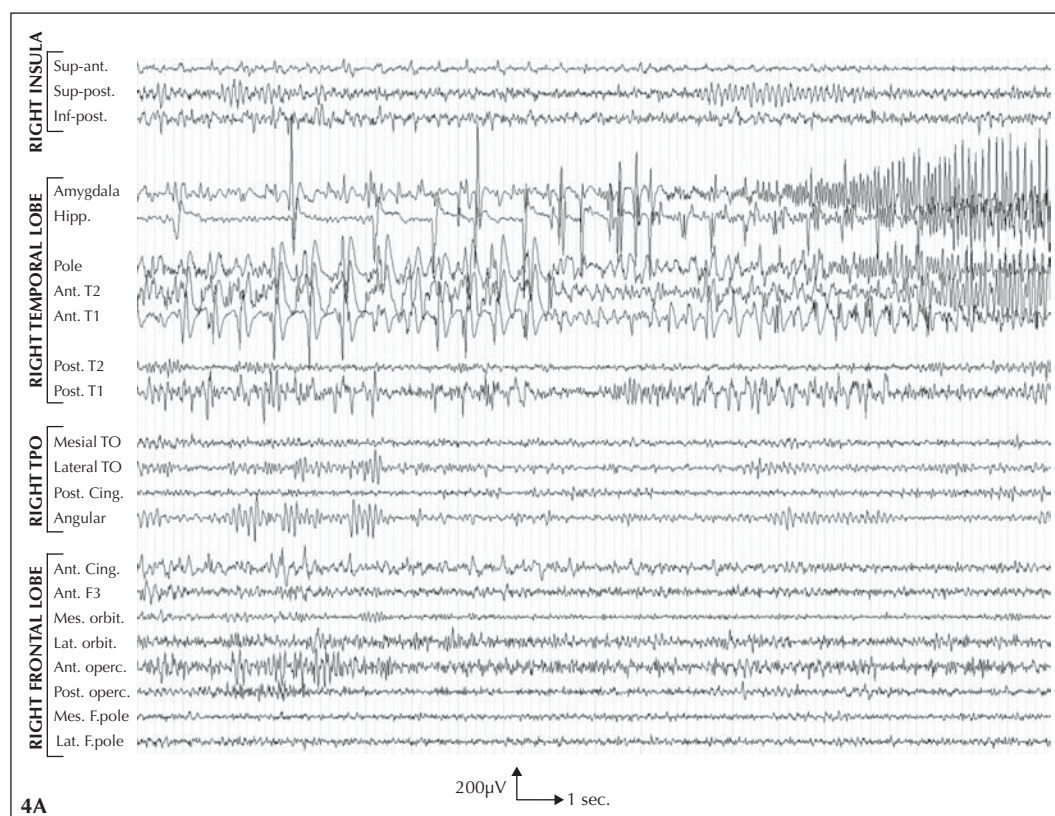
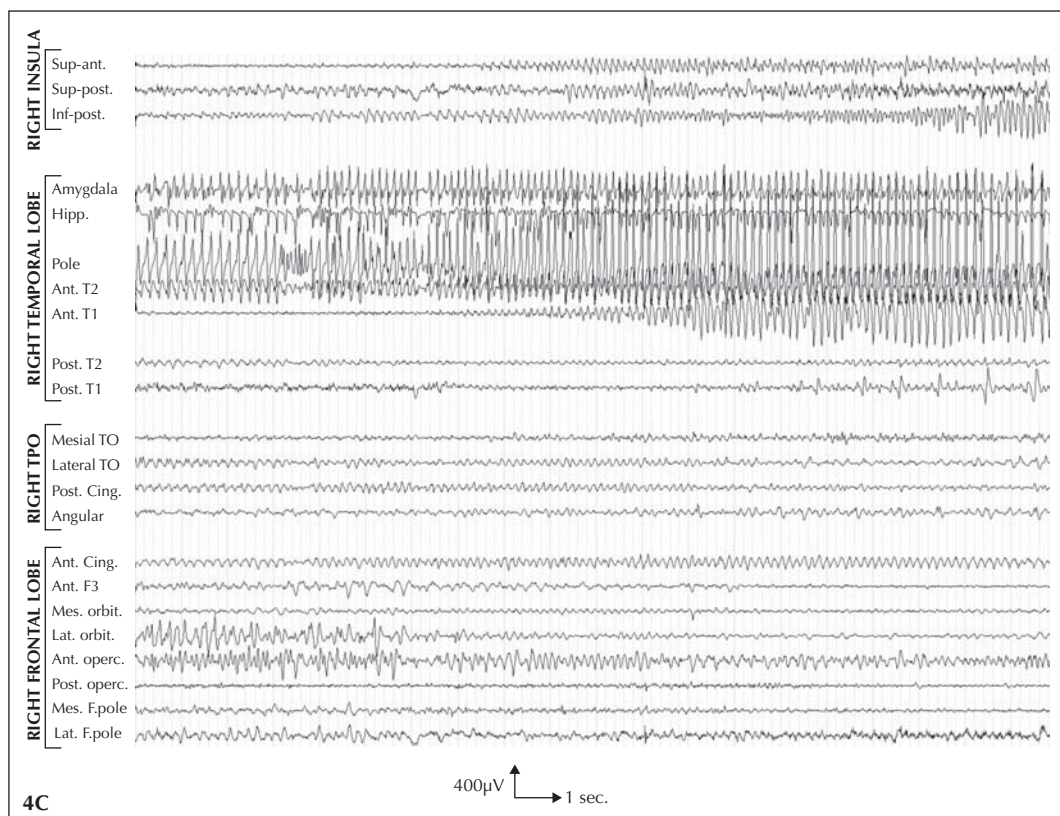
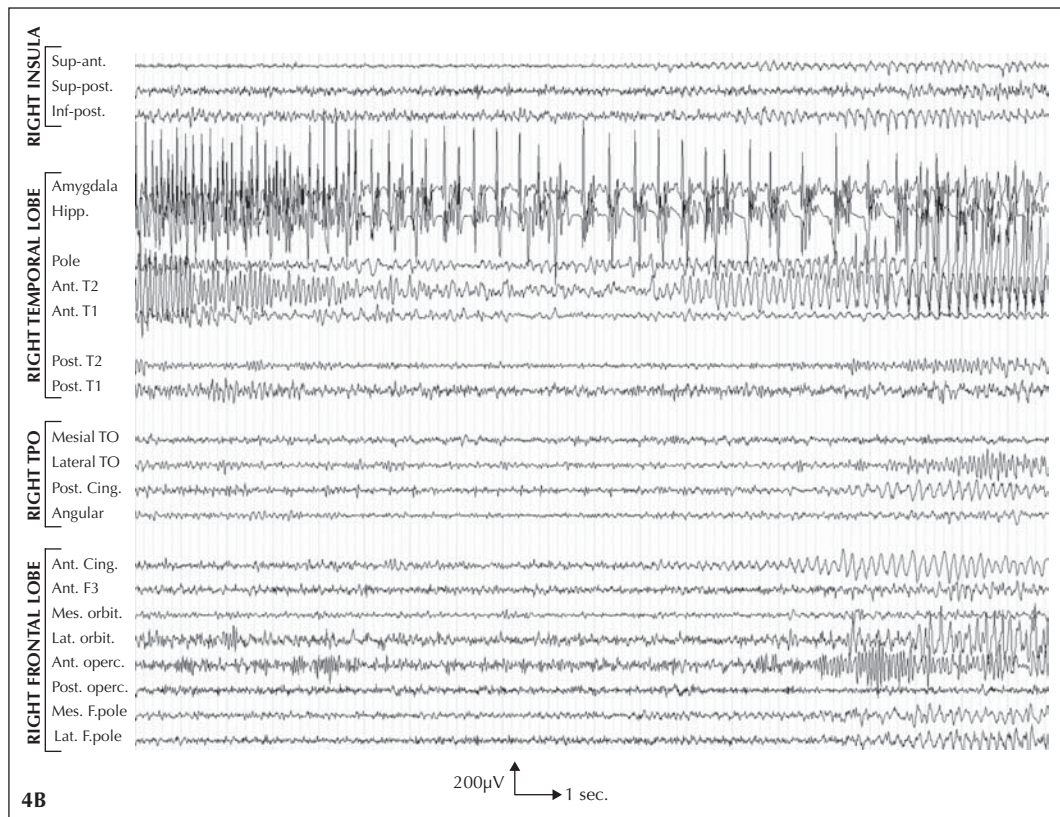
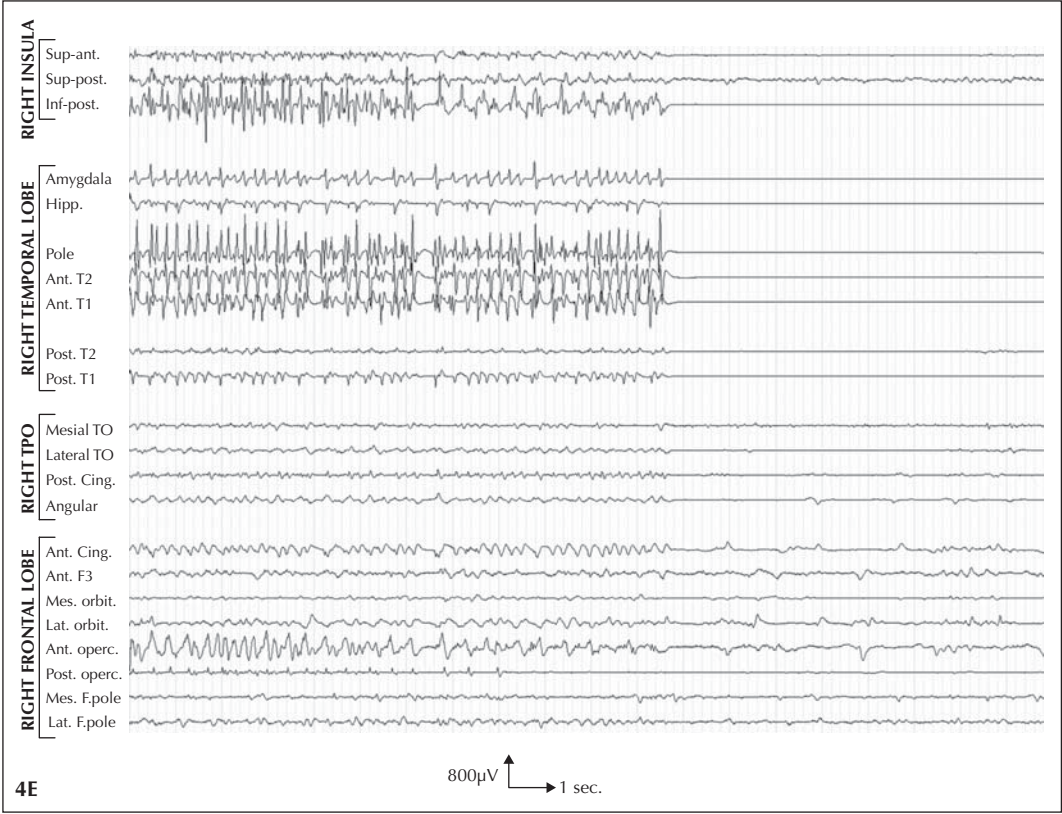
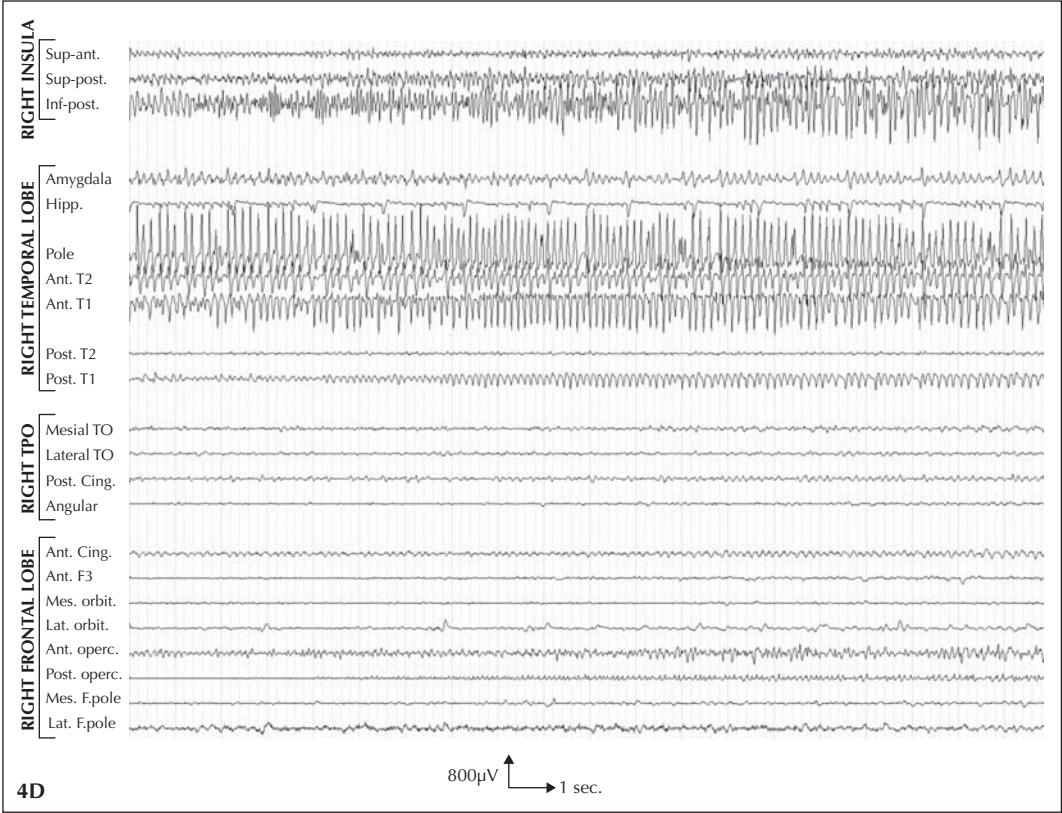


Figure 4. Temporo-limbic seizure propagating to the insula in **patient 1**:

A) An ictal discharge is first observed over the right hippocampus, amygdala, and temporal pole, rapidly propagating to the anterior portion of the 2nd temporal gyrus (T2); **B)** the discharge slows down over the temporo-limbic structures while vanishing at T2, but then accelerates or reappears in the region, while a low voltage theta rhythmic activity occurs in the insula, the anterior and posterior cingulate gyri, the frontal operculum, and the orbito-frontal and fronto-polar cortices; **C)** the ictal discharge remains steady in most regions, apart from the inferior and posterior aspect of the insula and the anterior part of the first temporal gyrus (T1) where it clearly intensifies; **D)** the discharge attenuates in the amygdalo-complex and intensifies in the posterior part of T1, while still predominating over the temporal pole, the anterior portions of T1 and T2, and the posterior inferior aspect of the insula, until seizure termination (**E**). Note that all leads are displayed with a similar amplification. Ant = anterior, Post = posterior, Inf = inferior, Sup = superior, Hipp = hippocampus, T1 = first temporal gyrus, T2 = second temporal gyrus, TPO = temporo-parieto-occipital junction, TO = temporo-occipital junction, Cing = cingulate gyrus, F3 = third frontal gyrus, Mes = mesial, Lat = lateral, Orbit = orbito-frontal cortex, operc = operculum, F = frontal.





tion of the right hippocampus, leading to the typical, full blown complex partial seizures previously described (figure 6). Seizure could not be induced by stimulating other brain regions, including the insula.

Surgical procedure and outcome

The patient underwent a right anterior, temporal lobectomy associated with a resection of a very limited portion of the inferior aspect of the ipsilateral insula. Resection of the insula was minimized in order to avoid an increased risk of vascular complications, and thus only included a very minor portion of the epileptogenic insula. Post-operative MRI demonstrated that the mesial temporal structures had indeed been removed (figure 7).

Nocturnal seizures recurred a few weeks after surgery. They were initially described by the patient's husband as comparable to the pre-operative attacks, but then progressively changed over time while day-time seizures also

relapsed. Six years after surgery, the patient was mainly suffering from complex partial seizures primarily characterised by lack of responsiveness, with or without a preceding aura that included a rising and distressing epigastric sensation and a feeling of suffocation.

Conclusion regarding the epileptogenic zone

At the present time, we cannot anticipate whether a complete resection of the suspected epileptogenic insula would have resulted in seizure-freedom. We can however, ascertain that a standard temporal lobectomy failed to do so, even though the patient fulfilled the major criteria of mTLE, including MRI signs of mesial temporal sclerosis. Based on this argument, and all other available findings, we conclude that this patient suffered from a right temporo-insular epileptogenic zone, involving both the temporo-limbic structures and a portion of the insula, the

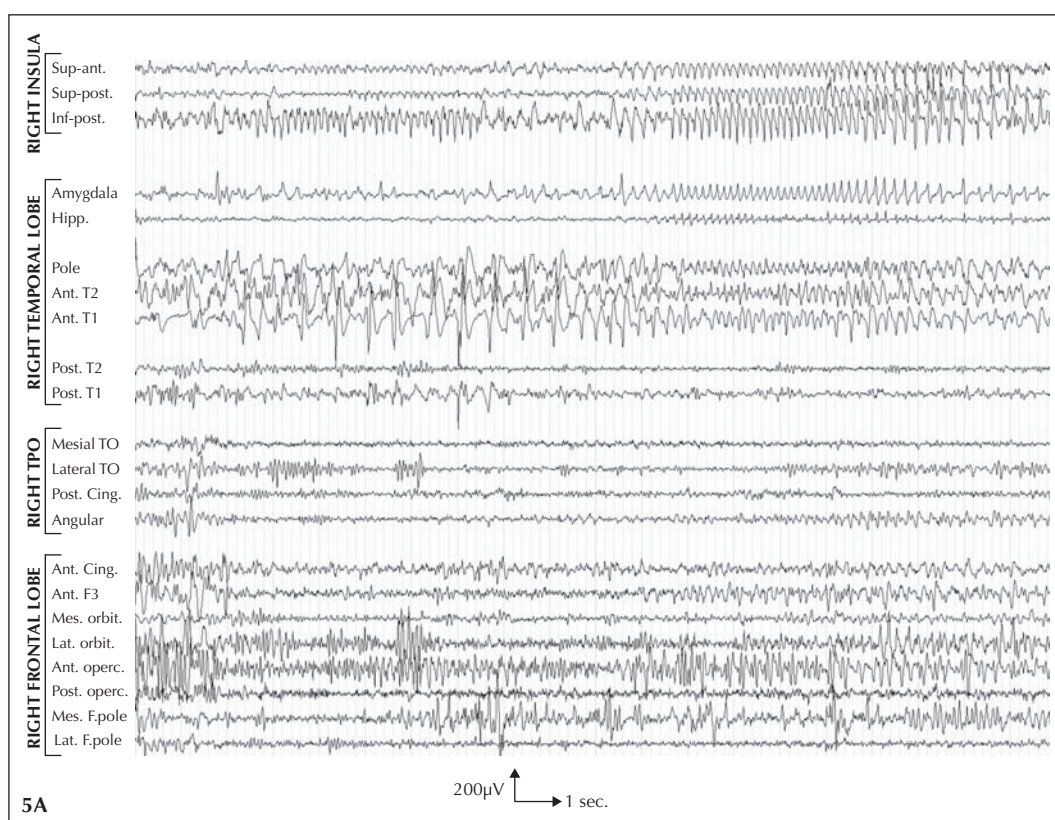
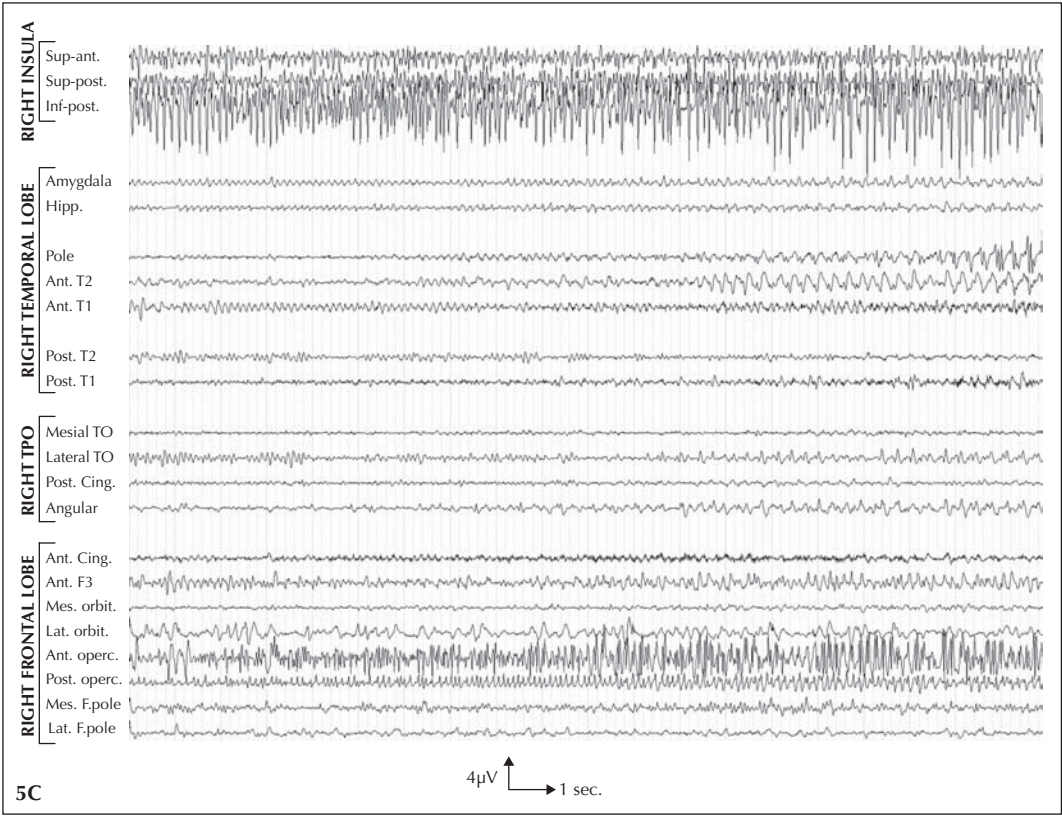
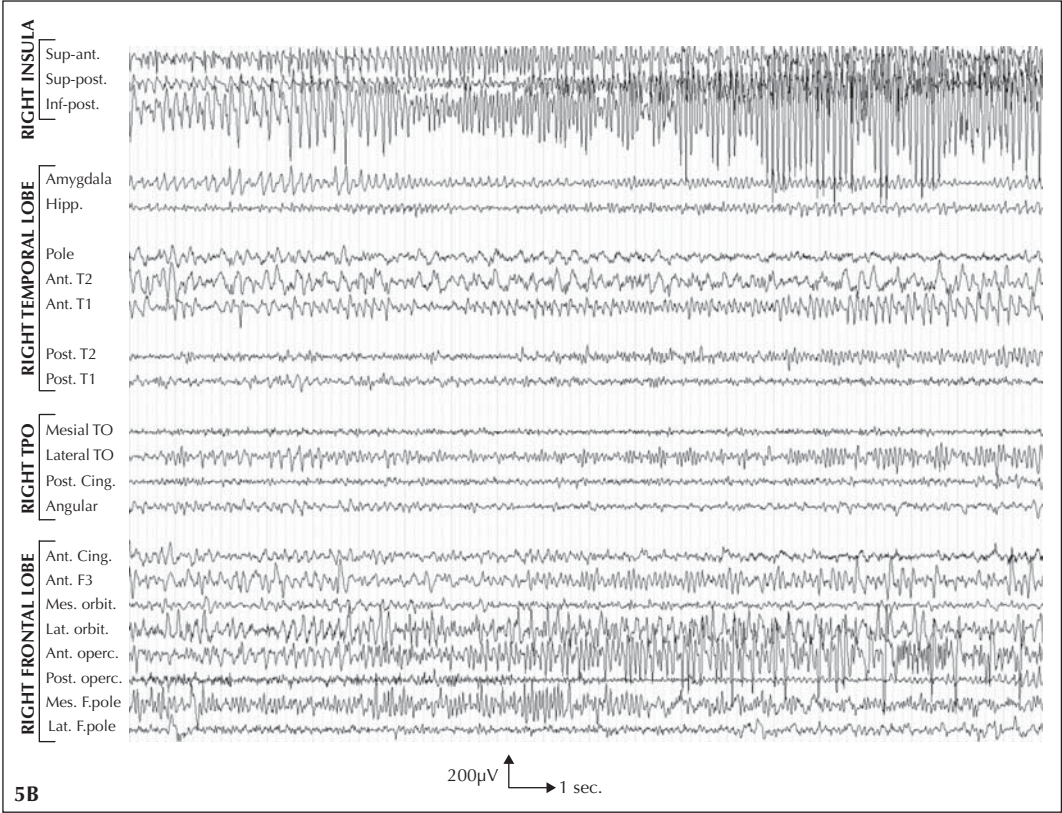
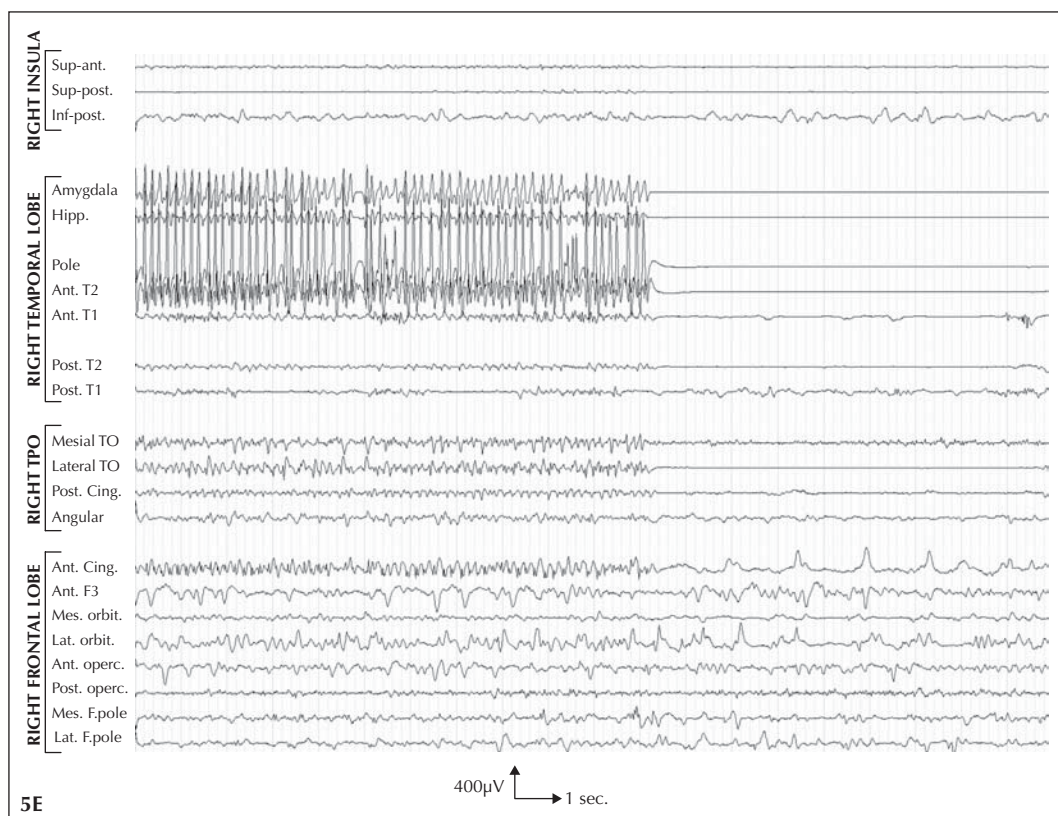
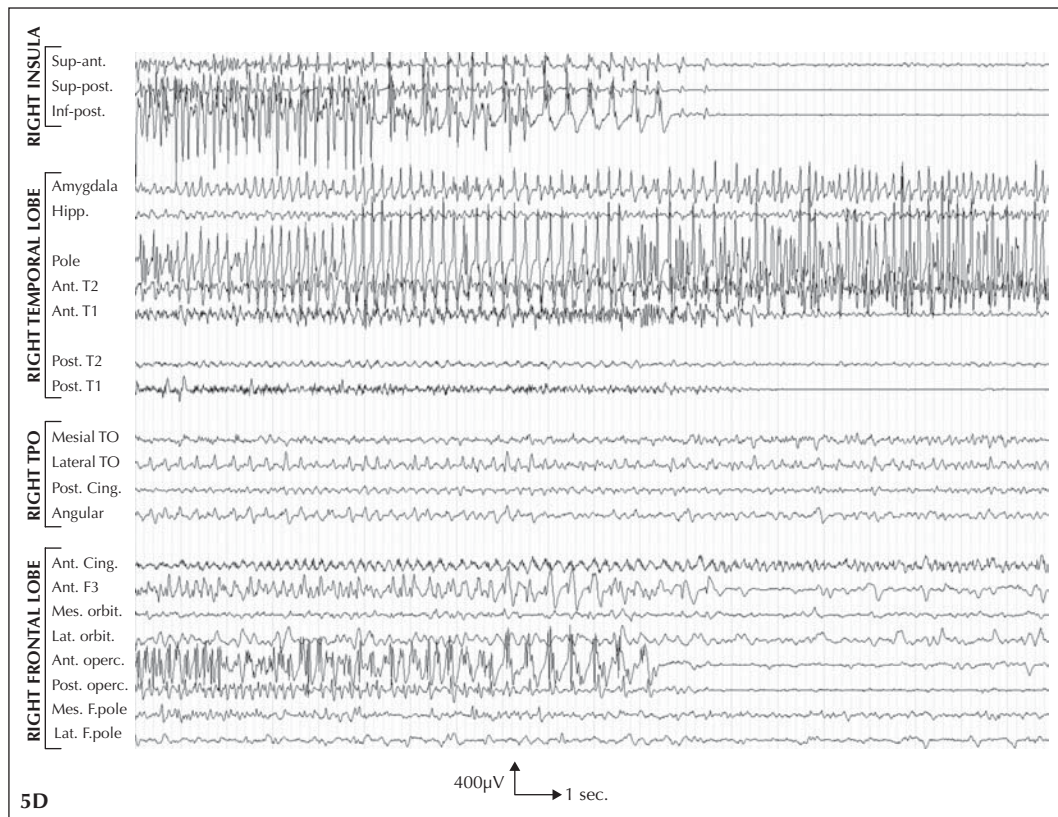


Figure 5. Insular seizure propagating to the temporal lobe in **patient 1:**

A) A 7-8 Hz rhythmic discharge is first observed within the insula, predominating over its anterior and posterior portion. It appears to vanish after a few seconds, but then immediately resumes, and is then also observed over the mesial temporal structures, the temporal pole and anterior parts of T1 and T2, and to a lesser extent, over the frontal operculum; **B)** the discharge strongly intensifies within the insula, and to a lesser degree, over the frontal operculum; **C)** the discharge keeps predominating over the inferior-posterior aspect of the insula and the frontal operculum; **D)** discharge stops over most affected regions, including the insula and operculum, while it intensifies over the amygdala, temporal pole and anterior part of T2 until seizure termination (**E**). Note that all leads are displayed with a similar amplification.

Ant = anterior, Post = posterior, Inf = inferior, Sup = superior, Hipp = hippocampus, T1 = first temporal gyrus, T2 = second temporal gyrus, TPO = temporo-parieto-occipital junction, TO = temporo-occipital junction, Cing = cingulate gyrus, F3 = third frontal gyrus, Mes = mesial, Lat = lateral, Orbit = orbito-frontal cortex, operc = operculum, F = frontal.





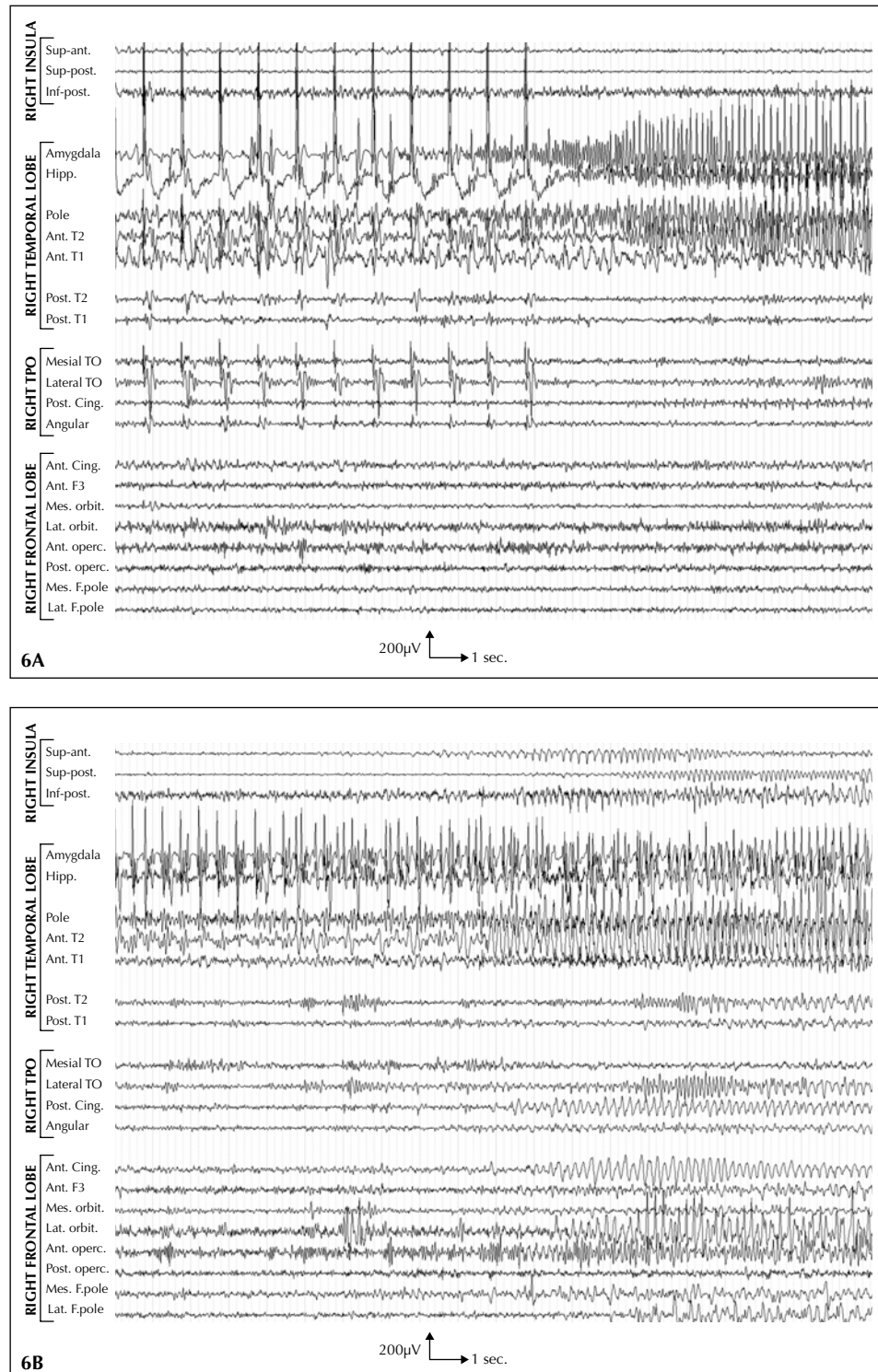


Figure 6. A) Low frequency (1 Hz), low intensity (2 mA) electrical stimulation of the right hippocampus in **patient 1** led to the development of an ictal discharge within the right amygdalo-hippocampal complex and adjacent temporal pole, that later propagated (B) to the ipsilateral anterior temporal neocortex, operculo-insular complex, orbito-frontal cortex, and anterior-posterior cingulate gyri. Note that all leads are displayed with a similar amplification. Ant = anterior, Post = posterior, Inf = inferior, Sup = superior, Hipp = hippocampus, T1 = first temporal gyrus, T2 = second temporal gyrus, TPO = temporo-parieto-occipital junction, TO = temporo-occipital junction, Cing = cingulate gyrus, F3 = third frontal gyrus, Mes = mesial, Lat = lateral, Orbit = orbito-frontal cortex, operc = operculum, F = frontal.

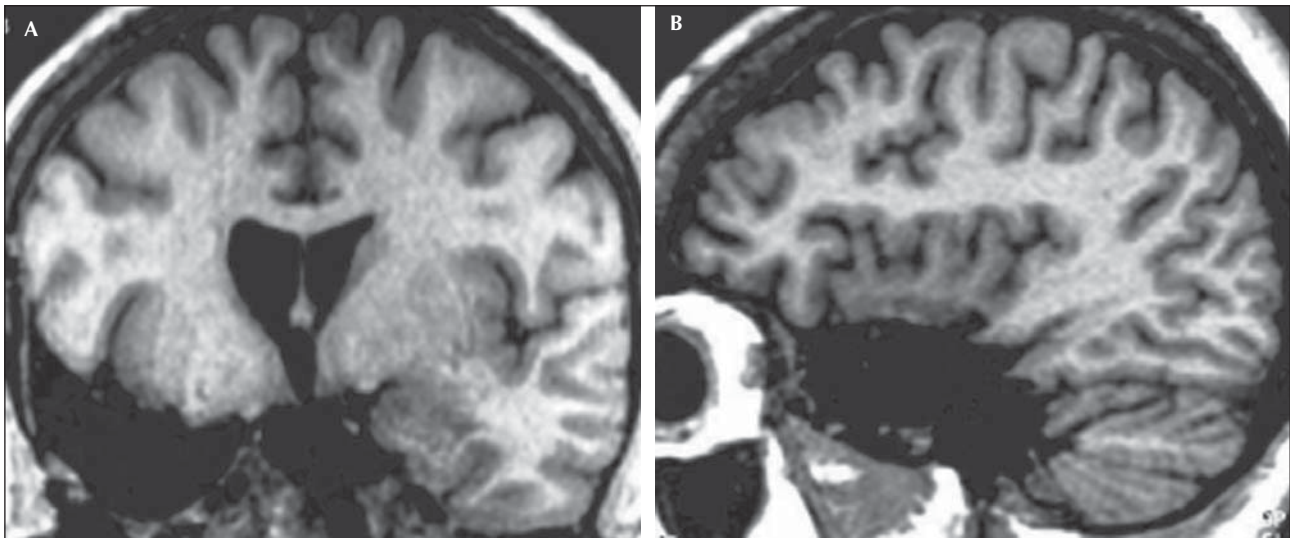


Figure 7. Post-operative MRI in patient 1 shows that the mesial temporal structures have been appropriately removed, whereas only a very limited portion of the inferior aspect of the ipsilateral insula has been resected.

extension of which remains difficult to delineate due to the limited spatial sampling of our intra-cerebral EEG investigation.

Observation n°2 (quoted observation n°3 in Ryvlin *et al.* 2006a)

Past-history

This right-handed male (with no remarkable past-history) started to suffer nocturnal seizures at the age of nine. The epilepsy was drug resistant from onset, but seizure frequency progressively worsened from a few attacks per month during adolescence, to one or more seizures every night at the age of 51 when the patient was referred to us for a presurgical evaluation. At this age he also started to suffer rare, day-time seizures.

Seizure description

The patient either lacked any warning symptom or could recollect only an indefinable cephalic aura. Seizures captured during video-EEG monitoring showed that he would suddenly become agitated, while grimacing and screaming. He would then turn over the bed, grab the rail, perform some kicking and tonic pelvic thrust movements. Rubefaction and tachycardia were also observed. The seizure lasted 30 to 40 seconds and stopped abruptly, with no post-ictal confusion or aphasia. Overall, this ictal sequence corresponded to a typical form of nocturnal hypermotor seizure, highly suggestive of NFLE.

Scalp-EEG

Interictal scalp-EEG had always proved normal. In addition, no ictal discharge could be detected during the

recorded seizure, although the EEG was obscured by movement artefacts during most of the attack. Similarly, we did not observe focal post-ictal slow waves. Likewise, in the largest NFLE series reported so far, only 56 out of 100 patients demonstrated ictal scalp-EEG abnormalities, which included diffuse flattening in 14%, and focal frontal or fronto-temporal discharges in 27% (Provini *et al.* 1999).

Neuroimaging

MRI showed a left fronto-basal arachnoid cyst (*figure 8A*), whereas interictal FDG and [¹¹C]Flumazenil-PET demonstrated left mesial frontal hypometabolism and decreased benzodiazepine receptor density, respectively (*figures 8B and C*).

Neuropsychology

Neuropsychological testing failed to demonstrate any significant abnormality. The intra-carotid amobarbital procedure confirmed that the left hemisphere was dominant for language in this right handed patient.

Rationale and design of the intra-cerebral EEG investigation

In our view, the patient's electro-clinical data, including the lack of detectable ictal EEG discharge, strongly suggested NFLE, and more specifically an orbital or mesial frontal seizure onset (Tharp 1972, Ludwig *et al.* 1975, Geier *et al.* 1976,1977, Williamson *et al.* 1985, Munari and Bancaud 1992, Rougier and Loiseau 1988, Nobili *et al.* 2003, Cascino *et al.* 2004). We thought that the fronto-basal arachnoid cyst, although typically considered non-epileptogenic, might bear some relation to the pathology underlying the patient's epilepsy, as it proved consistent

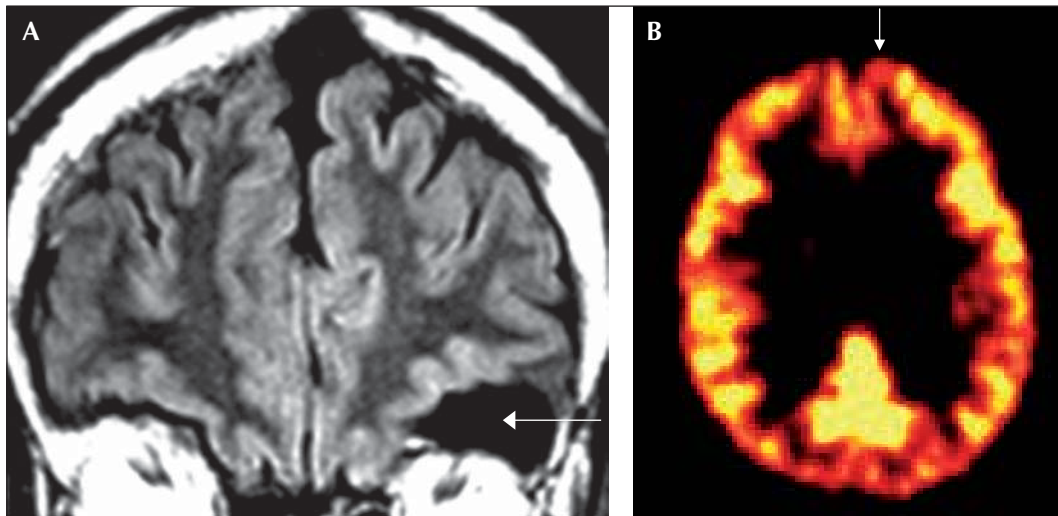


Figure 8. Neuroimaging in patient 2: **A)** MRI shows a left fronto-basal arachnoid cyst; **B)** interictal [^{11}C]Flumazenil-PET demonstrate left mesial frontal decreased benzodiazepine receptor density.

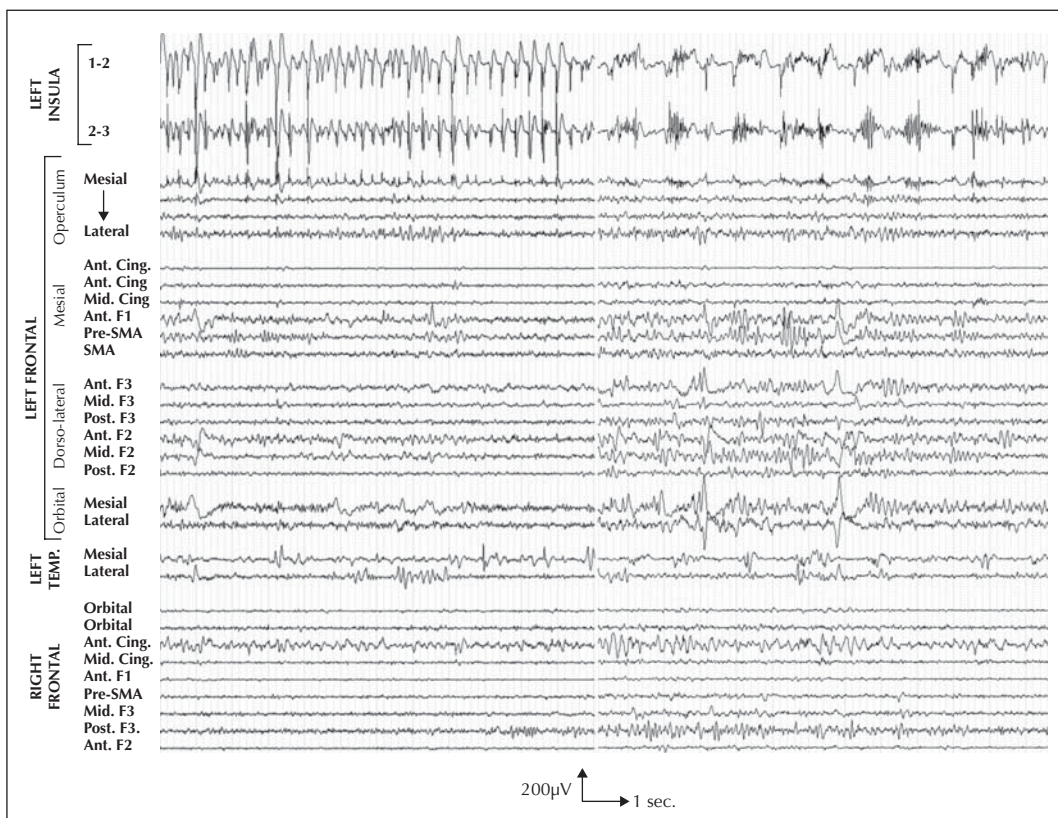


Figure 9. Interictal intra-cerebral EEG recordings in patient 2 shows almost permanent high amplitude spikes (left EEG traces), intermingled with bursts of high frequency discharges in the antero-superior portion of left insula (i1,i2), slightly diffusing to the nearby deepest aspect of the frontal operculum. *Note that all leads are displayed with a similar amplification.* Ant = anterior, Cing = cingulate gyrus, Mid = middle, F1 : first frontal gyrus, SMA = supplementary motor area, F3 = third frontal gyrus, Post = posterior, F2 = second frontal gyrus.

with an orbital-frontal ictal onset. Interestingly, in a series of 100 NFLE patients, MRI demonstrated an abnormal finding in 14, including three fronto-basal arachnoidal cysts (Provini *et al.* 1999). The PET abnormalities observed in our patient supported the alternative hypothesis of a mesial frontal seizure onset. Altogether, MRI and PET findings favoured a left-sided epileptogenic zone. We thus undertook an invasive EEG investigation with the primary aim of demonstrating a left orbital or mesial frontal ictal onset, while excluding the less likely hypothesis of a right frontal or left temporal focus.

A total of 14 depth electrodes, each containing 10 to 15 leads, were implanted, including eight in the left frontal lobe, five in the right frontal lobe, and one directed to the left amygdala (*figure 2*). Right and left frontal electrodes targeted the orbito-frontal cortex, the anterior and middle portions of the anterior cingulate gyrus, the anterior and mesial aspect of the first frontal gyrus, the pre-SMA, as well as the anterior middle and posterior parts of the second and third frontal gyri. In addition, left frontal electrodes also targeted the SMA and pre-central operculum, with the two deepest leads of this latter electrode located within the anterior and superior portion of the insula.

Intra-cerebral EEG findings

Interictal abnormalities were characterised by a very focal area of continuous very high amplitude spikes, intermingled with bursts of high frequency discharges, in the antero-superior portion of left insula (*figure 9*). These abnormalities slightly diffused to the nearby deepest aspect of the frontal operculum, but were not observed over the most lateral leads of the same electrode, although only located 1.5 cm away. Much less frequent spikes and slow waves were observed in the ipsilateral anterior and orbital frontal regions, and in the left amygdala.

Five, stereotyped, spontaneous seizures were recorded, including four during sleep and one while the patient was awake (*figure 10*). Ictal semiology was comparable to that observed during scalp-EEG monitoring. Ictal onset occurred after a series of high amplitude spikes observed over the anterior superior portion of the left insula, and consisted of a focal, fast activity discharge that clearly predominated in the same region (electrodes i1-2, i2-3). Two to four seconds later, this discharge built-up in several mesial and lateral frontal regions progressively, concurrent with the onset of hypermotor activities. During the entire course of the seizure, the epileptic discharge remained more sustained and of higher frequency and greater amplitude in the insula than in all other brain regions investigated. In particular, a very steep gradient was found between the insula and the nearby frontal operculum although separated by only a few millimetres. High frequency electrical stimulation of the anterior superior insula (50 Hz, 0.3 msec pulse duration; 1 mA inten-

sity, 5 sec. train duration), but of no other brain regions investigated, elicited the patient's typical seizure.

Outcome and conclusion

We did not offer a surgical resection of the suspected epileptogenic insula in this patient, because of the significant risk of such an operation, in particular when performed on the side dominant for language, and uncertainties regarding the precise extent of the ictal onset zone within the insular cortex. Thus, as for patient 1, we could not provide the ultimate demonstration that this cortex encompassed the epileptogenic zone. Nevertheless, the remarkably selective, interictal abnormalities and sensitivity to electrical stimulation observed in the insula, strongly suggested that this region played a major role in generating seizures, and that frontal lobe surgery would not have resulted in a favourable outcome. The patient eventually died of SUDEP, two years after the completion of his intra-cerebral EEG investigation.

Discussion

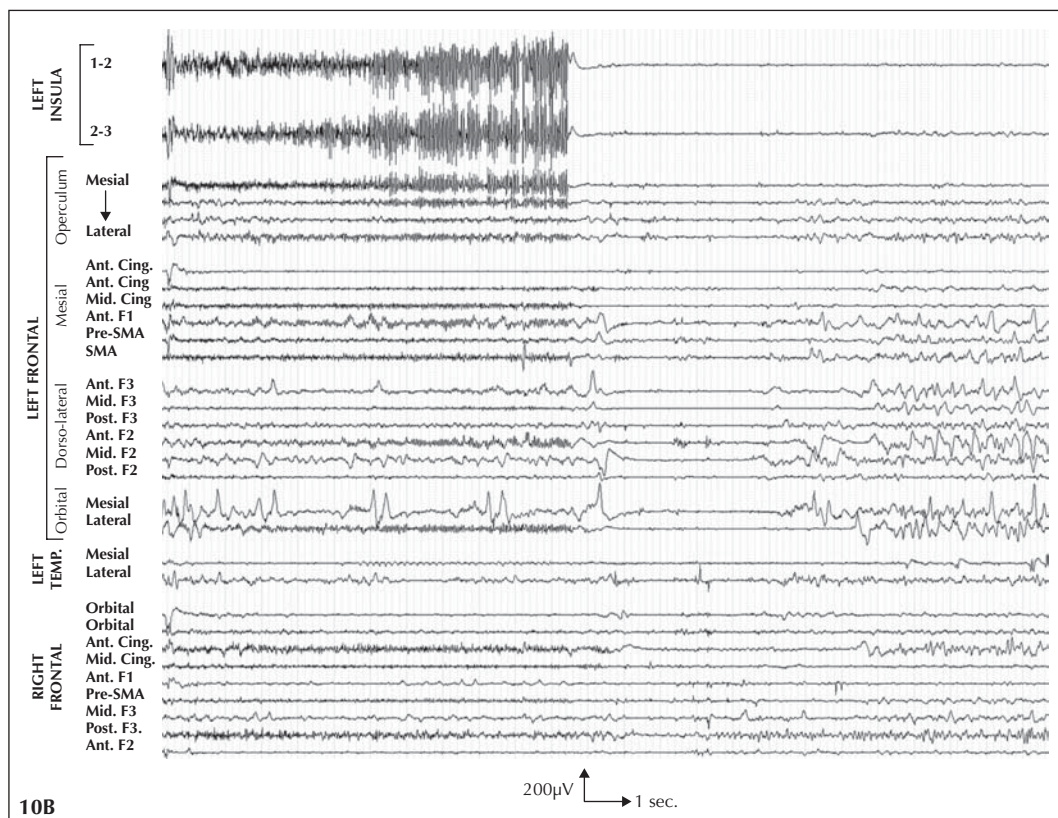
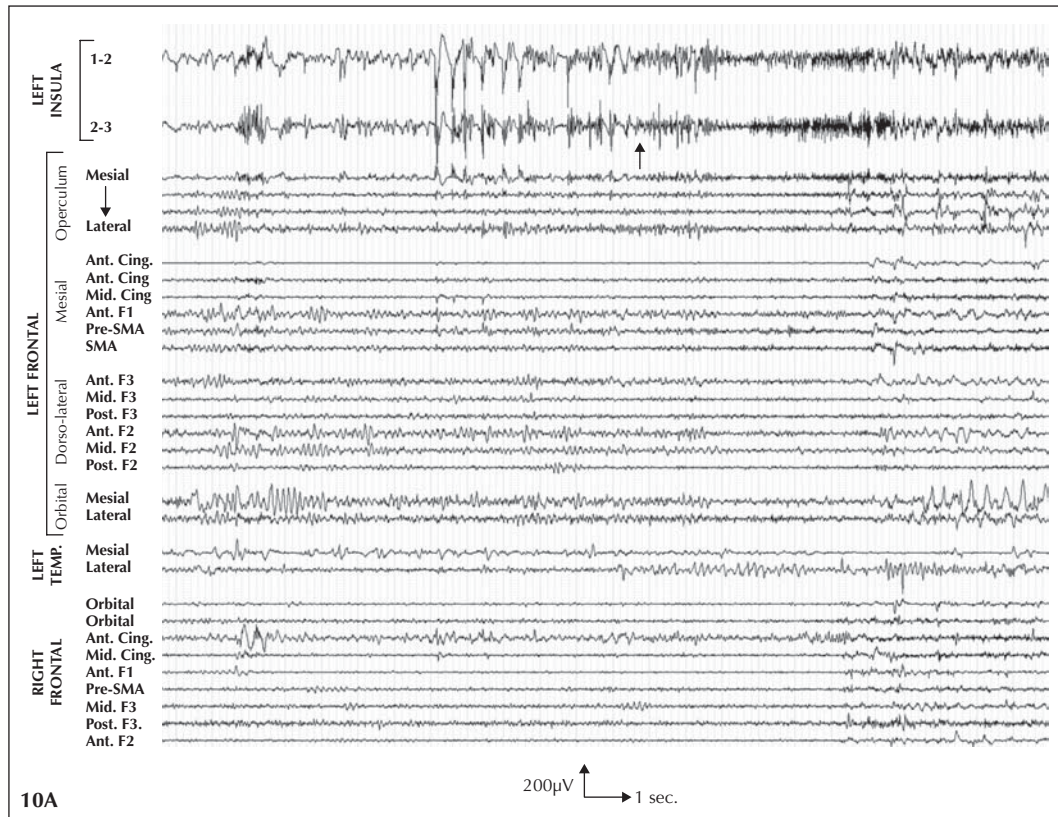
The two patients presented in this article illustrate some of the limitations of our current classification of partial epilepsy, which are likely to translate into erroneous identification of the epileptogenic zone, and ultimately, epilepsy surgery failure.

Patient 1 fulfilled the major criteria used to define mTLE, including typical early ictal signs and symptoms, with a rising and distressing epigastric sensation at seizure onset rapidly followed by oro-alimentary automatisms, MRI signs of unilateral hippocampal sclerosis, ipsilateral temporo-limbic interictal PET abnormalities and an anterior temporal scalp-EEG ictal discharge. It nevertheless proved to reflect an epileptogenic zone that extended outside the boundaries of a standard anterior temporal lobectomy (ATL), and which most likely involved the insula according to our intra-cerebral EEG data. In the majority of epilepsy surgery centres, this patient would have undergone surgery without prior invasive monitoring, and then would have been considered to belong to the subgroup of TLE patients who fail surgery for some unknown reason. Temporal lobe surgery failure remains an important and debated issue, despite seemingly consistent findings in systematic reviews. Indeed, whereas two, large, meta-analyses reported 68% and 69% of Engel's Class I outcome after ATL, detailed figures from individual centres ranged from 33% to 93% (Engel 1996 McIntosh *et al.* 2001). In the most recent surgical series of TLE patients with MRI signs of hippocampal sclerosis, Kaplan-Meier estimates of Engel's Class I at 10 years post-surgery varied between 47% and 81%, whereas in patients with a normal MRI, the rate of seizure-freedom at two years ranged from

24% to 80% (McIntosh *et al.* 2004, Carne *et al.* 2004, Paglioli *et al.* 2004). These controversial figures suggest an important heterogeneity in the criteria used by different centres to define TLE, and highlight the fact that many patients still suffer from unexplained surgical failure. In such patients, an extra-temporal seizure-onset zone, mimicking temporal lobe seizures, might be suspected. Accordingly, Aghanaki *et al.* (2004) reported six patients who failed temporal lobe surgery despite intra-cranial EEG evidence that the temporal lobe participated in generating seizures, but in whom a somato-sensory aura also supported a role of the parietal lobe. In the majority of these patients, the inferior parietal region was indeed involved at ictal onset, but its secondary removal did not result in a better seizure control. The authors acknowledged that the insula might have participated in the complex epileptogenic networks observed in their patients, in as much as one patient presented with an insular hyperperfusion on ictal SPECT. They could not confirm this hypothesis however, due to the lack of intra-cerebral electrodes directly placed within the insula. Conversely, Isnard *et al.* (2004) directly demonstrated the role of the insular cortex in generating temporal lobe-like seizures in a few patients, including the index case detailed in this article. In two of these patients, including one with an insular MRI abnormality, seizures were controlled by surgical resection or thermolesion of a portion of the insulo-opercular complex. In two other patients, including the one reported herein, different seizure types were observed, originating from the temporal lobe and the insula, respectively. Similarly, patients with TLE-like epilepsy might suffer from an epileptogenic network including a combination of brain regions located within the temporal lobe and other closely connected neighbored structures, such as the orbito-frontal cortex, the frontal and parietal operculum, and the temporo-parieto-occipital (TPO) junction (Ryvlin 2003). We have recently proposed the term “**temporal plus epilepsy**” (TPE) to better define these specific forms of multilobar epilepsy that are characterised by a prominent ictal involvement of the temporal lobe, electro-clinical features primarily suggestive of TLE, and MRI findings that are either unremarkable or showing signs of HS (Ryvlin and Kahane 2005). The latter might represent up to 20% of all temporal lobe surgery candidates.

The detection of TPE depends critically on the criteria used for undertaking an invasive investigation in patients where the diagnosis of TLE remains uncertain, as well as on the appropriate intra-cerebral investigation of extra-temporal structures, particularly the insula. At the present time, there is no consensus on these issues, except for the lack of any detectable MRI abnormality, which is generally considered to be a strong incentive for performing invasive monitoring in patients with suspected TLE. The presence of early ictal signs and symptoms suggesting the involvement of the perisylvian region (somato-sensory, gustatory, and auditory hallucinations, vertigo, hypersalivation, laryngeal constriction, hemifacial motor signs), the orbito-frontal cortex (urination), or the TPO junction (giration, aphasia), can also be used as evidence of temporal plus epilepsy, although their specificity remains uncertain (Munari *et al.* 1980,1995). Specifically, an insular ictal onset might be suspected in seizures characterised by an early occurrence of the laryngeal discomfort or throat tightening associated with unpleasant paresthesias or sensations of warmth affecting the perioral region or large somatic territories, followed by focal somatomotor manifestations (Isnard *et al.* 2004). Accordingly, our patient 1 presented part of this sequence, and in particular, grabbed her throat and looked as if she were suffocating, before showing a very tonic posture. However, she did not grab her throat during the insular seizures, but only during those originating in the mesial temporal lobe structures, although at a time when the insula had been invaded by the ictal discharge. Thus, this ictal sign might indicate the ictal involvement of the perisylvian region rather than specifically reflect an insular seizure. As with other perisylvian signs and symptoms, it represents a reliable red flag in suspected TLE, and should prompt consideration of an invasive EEG recording. The combination of day-time and nocturnal seizures has contributed to the complexity of our patient's assessment. Semiological differences between the two types of seizures were initially thought to reflect the fact that those occurring during sleep, awakened the patient during the late part of the aura, immediately before the onset of motor signs. In fact, some of these differences were due to the predominantly day-time occurrence of temporal lobe seizures, and the nocturnal timing of those originating in the insula. Indeed, as illus-

Figure 10. Intra-cerebral EEG recordings of a seizure in patient 2. **A)** Ictal onset occurred after a series of high amplitude spikes, followed by bursts of high frequency discharge observed over the antero-superior portion of the left insula (i1-2, i2-3). A diffusion of the high amplitude insular discharge is observed over the next adjacent lead in the mesial aspect of the frontal operculum, only 1.5 mm distant from the insular lead. None of the other opercular leads demonstrate an ictal discharge at this stage, suggesting that the opercular activity merely reflects the passive diffusion of the insular discharge rather than an autonomous epileptic activity. Two to four seconds later, an ictal discharge progressively builds up in several mesial and lateral frontal regions, bilaterally, which are better disclosed in **B)** The ictal discharge continues to clearly predominate over the left insula (i1-2, i2-3), but is also observed over the adjacent frontal operculum, the left and right anterior and middle cingulate gyrus, the left anterior mesial frontal cortex (F1), the left pre-SMA and SMA, the anterior portion of the second left frontal gyrus, the lateral aspect of the left orbito-frontal cortex, and the posterior portion of the third right frontal gyrus. Note that all leads are displayed with a similar amplification. Ant = anterior, Cing = cingulate gyrus, Mid = middle, F1 : first frontal gyrus, SMA = supplementary motor area, F3 = third frontal gyrus, Post = posterior, F2 = second frontal gyrus.



trated by *patient 2*, insular seizures might have a tendency to occur more frequently during sleep, a feature which might also be used as evidence of an insular epileptogenic zone. It must be noted however, that nocturnal clustering of temporal lobe seizures has also been observed (Bernasconi *et al.* 1998). Finally, *patient 1* had several risk factors for temporal lobe surgery failure, including a past-history of bacterial meningitis rather than febrile convulsions, and a lack of detectable interictal epileptiform discharge on scalp-EEG recording. Whether such factors are, indeed, associated with the type of epileptogenic network encountered in this patient and whether they should have been used in the decision to perform an invasive EEG recording remain open issues.

Patient 2 presented with a typical form of cryptogenic, nocturnal, frontal lobe epilepsy, characterised by sleep-related hypermotor attacks of brief duration, classically referred to as nocturnal paroxysmal dystonia (NPD) (Ryvlin *et al.* 2006b). As previously mentioned, the lack of detectable interictal and ictal scalp-EEG discharges noted in our patient is a common feature in NFLE (Provini *et al.* 1999). Similarly, the fronto-basal arachnoid cyst and mesial frontal interictal PET abnormalities observed in this patient have been reported in NFLE (Provini *et al.* 1999, Schlaug *et al.* 1997). In fact, these misleading neuroimaging findings supported the classic view that NPD or hypermotor seizures originate in the orbital or mesial frontal regions, accounting for their classification among the NFLE. However, only few intra-cerebral EEG and post-operative data are available in NFLE (Nobili *et al.* 2003; Cascino *et al.* 2004). In fact, the frontal origin of NPD is mainly suggested by their resemblance to the day-time attacks observed in well-assessed cases of symptomatic orbital or mesial frontal epilepsy, but the number and rate of successful operations in cryptogenic NFLE remains very limited (Tharp 1972, Ludwig *et al.* 1975, Geier *et al.* 1976, 1997, Williamson *et al.* 1985, Munari and Bancaud 1992, Rougier and Loiseau 1988). Ictal SPECT data also militate for the role of the anterior, orbital and mesial frontal regions in NFLE (Harvey *et al.* 1993, Vetrugno *et al.* 2005). However, the frontal hyperperfusion observed in this disorder might only reflect areas of seizure propagation as recently illustrated in a patient with NPD of insular origin (Ryvlin *et al.* 2006a).

Previous reports have demonstrated that nocturnal hypermotor seizures can originate in the temporal lobe, in particular when symptomatic of a temporo-basal cortical dysplasia (Nobili *et al.* 2002, 2004). We have recently reported three patients, including the one described in this article and two investigated in the epilepsy surgery centre of Grenoble, with clinically defined NFLE and an insular ictal onset zone as demonstrated by invasive EEG monitoring (Ryvlin *et al.* 2006a). To our knowledge, these patients are the first reported cases of nocturnal hypermotor seizures of insular origin. However, functional neuroimaging abnormalities were previously observed in the

insula of a few patients with hypermotor seizures or NFLE. Indeed, FDG-PET showed both frontal and insular interictal hypometabolism in patients with NHS, while ictal SPECT has revealed insular hyperperfusion in one such patient (Harvey *et al.* 1993, Schlaug *et al.* 1997). According to our database and that of the epilepsy surgery centre of Grenoble, an insular seizure onset might be found in 30% or more of patients with drug-resistant cryptogenic NFLE (Ryvlin *et al.* 2006a).

At the present time, electro-clinical and neuroimaging data do not allow us to distinguish these patients from those with an orbital or mesial frontal epileptogenic zone. It is thus recommended that the insula is systematically investigated when contemplating invasive EEG monitoring in patients with cryptogenic NFLE. The intra-cerebral EEG data recorded in *patient 2* also demonstrate that depth electrodes placed within the insula, but not grids, are appropriate for the investigation of this structure. Indeed, both interictal and ictal EEG abnormalities showed a very steep gradient between the affected insula and the most superficial opercular leads, located only 1.5 cm away on the same electrode, where these abnormalities could not be detected. It should also be stressed that insertion of depth electrodes within the insula has proved to be a very safe procedure, provided stereotactic placement guided by angiography.

As previously mentioned and illustrated by our two patients insular seizures might have the propensity to occur more frequently during sleep. Interestingly, two PET studies have demonstrated a significant decreased blood flow in the anterior insula during sleep (Braun *et al.* 1997, Dang-Vu *et al.* 2005). Future work is certainly warranted in this field. Apart from their nocturnal pattern of occurrence, the insular seizures observed in our two patients were strikingly different. This difference, which applies more generally to patients whose insular seizures mimic TLE versus NFLE, is likely to reflect the precise area of the insula involved at ictal onset. Indeed, its posterior or anterior-inferior aspects appear to be mainly involved in TLE-like seizures (Isnard *et al.* 2004), whereas only the anterior-superior portion of the insula was involved in patients with suspected NFLE (Ryvlin *et al.* 2006a). This framework is consistent with the anatomical connections of the insular cortex described in rhesus monkeys (Mesulam and Mufson 1982b, Mufson and Mesulam 1982), but partly contrasts with the results obtained by direct electrical stimulation of the human insula (Ostrowsky *et al.* 2000, 2002; Isnard *et al.* 2004). Indeed, whereas the majority of painful sensations and auditory hallucinations were well localised within the posterior portion of the insula, non-painful somatosensory and viscerosensitive responses, as well as sensations of laryngeal constriction, were equally distributed in the various insular sub-regions (Ostrowsky *et al.* 2000, 2002; Isnard *et al.* 2004). However, it should be noted that the most anterior, superior portion of the insula was not investigated in these studies.

Whether a surgical resection of a non-lesional epileptogenic insula should be considered in patients with drug-resistant insular epilepsy is an important, unresolved issue. The pioneering experience of the Montreal Neurological Institute showed that resection of residual, spiking, insular cortex following temporal lobectomy did not improve post-operative seizure outcome and was associated with significant morbidity (Silfvenius *et al.* 1964). To our knowledge, only a few attempts at removing epileptogenic brain lesions located within the insula have been performed since then (Roper *et al.* 1993, Taniguchi *et al.* 1998, Cukiert *et al.* 1998, Duffau *et al.* 2002, Seeck *et al.* 2003, Isnard *et al.* 2004, Rossetti *et al.* 2005). Very recently however, Duffau *et al.* (2005) reported a series of 42 patients who underwent a surgical resection of an insular epileptogenic, low grade glioma. An immediate post-operative deficit was observed in more than half of the patients, which improved in all but three cases whose surgery resulted in a vascular insult. This morbidity is significantly higher than that observed and accepted in epilepsy surgery. In addition, the specific rates of post-operative deficit and seizure-freedom after a partial or total insulectomy in patients with cryptogenic insular epilepsy remain unknown. These figures, whenever available, should also be balanced against the risk of SUDEP in patients with refractory partial epilepsy (Ryvlin and Kahane 2003). As illustrated by our second observation, patients with insular epilepsy might be at higher risk of ictal asystole than TLE patients (Ryvlin *et al.* 2005,2006c). □

References

- Aghakhani Y, Rosati A, Dubeau F, *et al.* Patients with temporoparietal ictal symptoms and inferomesial EEG do not benefit from anterior temporal resection. *Epilepsia* 2004 ; 45 : 230-6.
- Bernasconi A, Andermann F, Cendes F, *et al.* Nocturnal temporal lobe epilepsy. *Neurology* 1998 ; 50 : 1772-7.
- Braun AR, Balkin TJ, Wesenten NJ, *et al.* Regional cerebral blood flow throughout the sleep wake cycle. An H2(15)O PET study. *Brain* 1997 ; 120 : 1173-97.
- Carne RP, O'Brien TJ, Kilpatrick CJ, *et al.* MRI-negative PET-positive temporal lobe epilepsy : a distinct surgically remediable syndrome. *Brain* 2004 ; 127 : 2276-85.
- Cascino GD, Buchhalter JR, Mullan BP, *et al.* Ictal SPECT in non-lesional extratemporal epilepsy. *Epilepsia* 2004 ; 45(Suppl 4) : 32-4.
- Cukiert A, Forster C, Andrioli MS, *et al.* Insular epilepsy. Similarities to temporal lobe epilepsy. Case report. *Arq Neuropsiquiatr* 1998 ; 56 : 126-8.
- Dang-Vu TT, Desseilles M, Laureys S, *et al.* Cerebral correlates of delta waves during non-REM sleep revisited. *Neuroimage* 2005 ; 28 : 14-21.
- Duffau H, Capelle L, Lopes M, *et al.* Medically intractable epilepsy from insular low-grade gliomas : improvement after an extended lesionectomy. *Acta Neurochir (Wien)* 2002 ; 144 : 563-72.
- Duffau H, Taillandier L, Gatignol P, *et al.* The insular lobe and brain plasticity : Lessons from tumor surgery. *Clin Neurol Neurosurg* 2005.
- Engel Jr. J. Surgery for seizures. *N Engl J Med* 1996 ; 334 : 647-52.
- Geier S, Bancaud J, Talairach J, *et al.* Automatisms during frontal lobe epileptic seizures. *Brain* 1976 ; 99 : 447-58.
- Geier S, Bancaud J, Talairach J, *et al.* The seizures of frontal lobe epilepsy. A study of clinical manifestations. *Neurology* 1977 ; 27 : 951-8.
- Guillaume MMJ, Mazars G. Cinq cas de foyers épileptogènes insulaires opérés. *Soc Française de Neurol* 1949 : 766-9.
- Guillaume MMJ, Mazars G. Technique de résection de l'insula dans les épilepsies insulaires. *Rev Neurol* 1949 ; 81 : 900-3.
- Guillaume MMJ, Mazars G, Mazars Y. Surgical indications in so-called temporal epilepsy. *Rev Neurol* 1953 ; 88 : 461-501.
- Harvey AS, Hopkins IJ, Bowe JM, *et al.* Frontal lobe epilepsy : clinical seizure characteristics and localization with ictal 99mTc-HMPAO SPECT. *Neurology* 1993 ; 43 : 1966-80.
- Isnard J, Guenot M, Ostrowsky K, *et al.* The role of the insular cortex in temporal lobe epilepsy. *Ann Neurol* 2000 ; 48 : 614-23.
- Isnard J, Guenot M, Sindou M, *et al.* Clinical manifestations of insular lobe seizures : a stereo-electroencephalographic study. *Epilepsia* 2004 ; 45 : 1079-90.
- Ludwig B, Marsan CA, Van Buren J. Cerebral seizures of probable orbitofrontal origin. *Epilepsia* 1975 ; 16 : 141-58.
- McIntosh AM, Wilson SJ, Berkovic SF. Seizure outcome after temporal lobectomy : current research practice and findings. *Epilepsia* 2001 ; 42 : 1288-307.
- McIntosh AM, Kalnins RM, Mitchell LA, *et al.* Temporal lobectomy : long-term seizure outcome, late recurrence and risks for seizure recurrence. *Brain* 2004 ; 127 : 2018-30.
- Mesulam MM, Mufson EJ. Insula of the old world monkey. III : Efferent cortical output and comments on function. *J Comp Neurol* 1982 ; 212 : 38-52.
- Mufson EJ, Mesulam MM. Insula of the old world monkey. II : Afferent cortical input and comments on the claustrum. *J Comp Neurol* 1982 ; 212 : 23-37.
- Munari C, Bancaud J. Electroclinical symptomatology of partial seizures of orbital frontal origin. *Adv Neurol* 1992 ; 57 : 257-65.
- Munari C, Talairach J, Bonis A, *et al.* Differential diagnosis between temporal and 'perisylvian' epilepsy in a surgical perspective. *Acta Neurochir (Wien)* 1980(suppl 30) : 97-101.
- Munari C, Tassi L, Di Leo M, *et al.* Video-stereo-electroencephalographic investigation of orbitofrontal cortex. Ictal electroclinical patterns. *Adv Neurol* 1995 ; 66 : 273-95.
- Nobili L, Francione S, Cardinale F, *et al.* Epileptic nocturnal wanderings with a temporal lobe origin : a stereo-electroencephalographic study. *Sleep* 2002 ; 25 : 669-71.
- Nobili L, Francione S, Mai R, *et al.* Nocturnal frontal lobe epilepsy : intracerebral recordings of paroxysmal motor attacks with increasing complexity. *Sleep* 2003 ; 26 : 883-6.
- Nobili L, Cossu M, Mai R, *et al.* Sleep-related hyperkinetic seizures of temporal lobe origin. *Neurology* 2004 ; 62 : 482-5.

- Ostrowsky K, Isnard J, Ryvlin P, *et al.* Functional mapping of the insular cortex : clinical implication in temporal lobe epilepsy. *Epilepsia* 2000 ; 41 : 681-6.
- Ostrowsky K, Magnin M, Ryvlin P, *et al.* Representation of pain and somatic sensation in the human insula : a study of responses to direct electrical stimulation. *Cereb Cortex* 2002 ; 12 : 376-85.
- Paglioli E, Palmini A, Paglioli E, *et al.* Survival analysis of the surgical outcome of temporal lobe epilepsy due to hippocampal sclerosis. *Epilepsia* 2004 ; 45 : 1383-91.
- Penfield W, Jasper H. Summary of clinical analysis and seizure patterns. In : *Epilepsy and the functional anatomy of the human brain*. Boston : Little Brown, 1954 : 818-44.
- Provini F, Plazzi G, Tinuper P, *et al.* Nocturnal frontal lobe epilepsy. A clinical and polygraphic overview of 100 consecutive cases. *Brain* 1999 ; 122 : 1017-31.
- Roper SN, Levesque MF, Sutherling WW, *et al.* Surgical treatment of partial epilepsy arising from the insular cortex. Report of two cases. *J Neurosurg* 1993 ; 79 : 266-9.
- Rossetti AO, Mortati KA, Black PM, *et al.* Simple partial seizures with hemisensory phenomena and dysgeusia : an insular pattern. *Epilepsia* 2005 ; 46 : 590-1.
- Rougier A, Loiseau P. Orbital frontal epilepsy : a case report. *J Neurol Neurosurg Psychiatry* 1988 ; 51 : 146-7.
- Ryvlin P. Beyond pharmacotherapy : surgical management. *Epilepsia* 2003 ; 44(Suppl 5) : 23-8.
- Ryvlin P, Kahane P. Does epilepsy surgery lower the mortality of drug-resistant epilepsy? *Epilepsy Res* 2003 ; 56 : 105-20.
- Ryvlin P, Kahane P. The hidden causes of surgery-resistant temporal lobe epilepsy : extratemporal or temporal plus? *Curr Opin Neurol* 2005 ; 18 : 125-7.
- Ryvlin P, Montavont A, Kahane P. The impact of epilepsy surgery on mortality. *Epileptic Disord* 2005 ; 7(Suppl. 1) : 39-46.
- Ryvlin P, Minotti L, Demarquay G, *et al.* Nocturnal hypermotor seizures, suggesting frontal lobe epilepsy, can originate in the insula. *Epilepsia* 2006a ; 47 : 755-65.
- Ryvlin P, Rheims S, Risse G. Nocturnal frontal lobe epilepsy. *Epilepsia* 2006b ; (in press).
- Ryvlin P, Montavont A, Kahane P. Sudden unexpected death in epilepsy : from mechanisms to prevention. *Curr Opin Neurol* 2006c ; 19 : 194-9.
- Schlaug G, Antke C, Holthausen H, *et al.* Ictal motor signs and interictal regional cerebral hypometabolism. *Neurology* 1997 ; 49 : 341-50.
- Seeck M, Zaim S, Chaves-Vischer V, *et al.* Ictal bradycardia in a young child with focal cortical dysplasia in the right insular cortex. *Eur J Paediatr Neurol* 2003 ; 7 : 177-81.
- Silfvenius H, Gloor P, Rasmussen T. Evaluation of insular ablation in surgical treatment of temporal lobe epilepsy. *Epilepsia* 1964 ; 5 : 301-20.
- Taniguchi M, Yoshimine T, Kato A, *et al.* Dysembryoplastic neuroepithelial tumor in the insular cortex. Three dimensional magnetoencephalographic localization of epileptic discharges. *Neurol Res* 1998 ; 20 : 433-8.
- Tharp BR. Orbital frontal seizures. A unique electroencephalographic and clinical syndrome. *Epilepsia* 1972 ; 13 : 627-42.
- Vetrugno R, Mascalchi M, Vella A, *et al.* Paroxysmal arousal in epilepsy associated with cingulate hyperperfusion. *Neurology* 2005 ; 64 : 356-8.
- Williamson PD, Spencer DD, Spencer SS, *et al.* Complex partial seizures of frontal lobe origin. *Ann Neurol* 1985 ; 18 : 497-504.