

Atypical case of Aicardi-Goutières syndrome with late-onset myoclonic status

Andrea Berger^{1,2}, Christiane Schroeter¹,
Adelheid Wiemer-Kruel¹, Karl Strobl¹, Georg F. Hoffmann⁴,
Dietz Rating², Pierre Lebon³, Jan-Peter Ernst¹, Nicole I. Wolf²

¹ Centre of Epileptology, Paediatric Neurology, Kehl-Kork, Germany

² University Children's Hospital, Paediatric Neurology, INF 155, D-69120, Heidelberg, Germany

³ Université René Descartes, Hôpital Cochin-St. Vincent de Paul, Service de Virologie, Paris, France

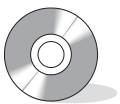⁴ University Children's Hospital, General Paediatrics, Heidelberg, Germany

Received September 22, 2006; Accepted January 25, 2007

ABSTRACT – Aicardi-Goutières syndrome (AGS) is a rare, progressive, autosomal recessive encephalopathy characterised by basal ganglia calcifications, chronic CSF lymphocytosis, and negative serological investigations for the common prenatal infections. The clinical profile is characterised by acquired microcephaly, mild to severe cognitive delay and dystonia. Epilepsy is usually not prominent. We report on a 19-year-old patient with an atypical clinical course, characterized by a relatively benign presentation at onset. Epilepsy with complex-focal seizures, possibly with a visual aura and sometimes with secondary generalization, started at the age of nine years. Clinical deterioration occurred later, and at the age of 17 years he experienced severe, generalized, myoclonic attacks lasting hours, which were partly controlled by the administration of piracetam.

[Published with video sequences]

Key words: Aicardi-Goutières syndrome, myoclonic status, myoclonia, leukencephalopathy



Correspondence:

Andrea Berger
University Children's Hospital,
Dept. of Paediatric Neurology,
INF 155,
D-69120 Heidelberg
Germany
Tel: (+00 49) 6221 56 39348/8488;
fax: (+00 49) 6221 56 5744
<andrea.berger@med.uni-heidelberg.de>

In their original report, J. Aicardi and F. Goutières (1984) described eight children affected by a severe, progressive, familial encephalopathy characterised by acquired microcephaly, severe mental and motor retardation, spastic and dystonic quadriplegia, intracranial calcifications and white matter abnormalities. A striking abnormality was the presence of cerebrospinal fluid lymphocytosis in the absence of other evidence of infection (Aicardi and Goutières 1984). Interferon-alpha (α -IFN) is elevated in the CSF of patients affected with AGS,

thus allowing diagnosis in the absence of metabolic markers. The level of α -IFN decreases over time and might be within the normal range in older AGS patients (Lebon *et al.* 1988, Goutières *et al.* 1998). Since the first description, more than 100 cases of Aicardi-Goutières syndrome have been reported, and its clinical, neuro-radiological and biological features have recently been reviewed (Goutières 2005).

Neuropathological examination of a patient with AGS showed severe microcephaly, diffuse nonhomogeneous

areas of myelin pallor associated with astrocytosis, calcified deposits in white matter, thalami and basal ganglia, and wedge-shaped microinfarctions in the neocortex and the cerebellar cortex with calcifications in the media, adventitia and perivascular spaces of small vessels, evoking a microangiopathy (Barth *et al.* 1999; Barth, 2002). This microangiopathy is also the likely cause of another characteristic feature of AGS, acrodermatitis presenting as “chilblain-like puffy swelling” (Tolmie *et al.* 1995, Stephenson 2002), which affects fingers, toes, ears and/or elbows. The pathogenesis of AGS is still incompletely understood. Transgenic mice with chronic overproduction of α -IFN show neuropathological abnormalities mimicking those found in AGS (Campbell *et al.* 1999). Skin lesions resembling AGS acrodermatitis have been reported during treatment with α -IFN (Bachmeyer *et al.* 1996, Campo-Vogeli *et al.* 1998). Chronic overproduction of IFN- α in AGS might thus be causally related to the microangiopathy found in brain and in skin (Barth *et al.* 1999).

We present the atypical clinical course of a 19 year old patient fulfilling the criteria of AGS. Diagnosis was only made at age 17 years. In addition to the well-known features of AGS, the patient developed long-lasting myoclonic attacks which were difficult to treat, but responded to piracetam.

Case report

This 19-year-old patient was referred to our epilepsy centre for refractory myoclonic attacks that first manifested at the age of 17 years. He was the second son of non-consanguineous German parents. An older brother aged 22 was in good health.

Pregnancy and delivery were uneventful. During the first days of life, he showed cyanosis of the lips and generalized hypotonia. Bacteriological and viral (TORCH) tests of blood and cerebrospinal fluid (CSF) were negative. CSF contained 344 cells/mm³, an elevated protein level (166 mg/dL), and normal glucose. After seven days, the CSF cell count normalized but protein remained elevated at 138 mg/dL. Cerebral ultrasound, head circumference and EEG were normal at that time. Developmental milestones were mildly delayed: he sat at nine months, walked at 18 months and spoke his first words at two years of age. At age six he was able to ride a bike but spoke only four to five word sentences. His IQ was 50. Recurrent infections (parotitis, panaritium, lymphadenitis) occurred from age one to school age. Physical examination at the age of seven years showed multiple enlarged cervical lymph nodes and neurodermitis. Tendon reflexes were brisk with negative plantar responses. Brain CT scan at the age of seven years showed multiple calcifications in the subcortical white matter and basal ganglia. MRI at age nine years showed slightly enlarged ventricles, abnormal white mat-

ter signal on T2 and FLAIR sequences, and contrast enhancement in the white matter of the medial temporal region and hippocampus. The white matter changes were interpreted as microinfarctions due to a heterozygous Factor V Leiden mutation, and antithrombotic therapy was initiated with fraxiparin.

When he was nine years old, the first seizure-suspicious episode occurred. The boy suddenly complained of headache followed by a visual hallucination of sunlight and then went to sleep. After a few hours he awoke disoriented. He clung to his father, his body stiffened and left-beating nystagmus was observed. Further episodes recurred, four and later six times a year: The boy said “Mom, I am going to have a seizure”, then, his body stiffened and head and eyes deviated to the left with clonus of the left limbs, sometimes propagating to the right. These events lasted up to 30 minutes and were often followed by deep somnolence. Interictal EEGs showed diffuse slowing without focal or epileptic changes. At age 12, the boy became increasingly disoriented. He had abrupt mood changes with depressive and aggressive outbursts. Over the course of one year, he had three episodes of tonic and myoclonic spasms of one or both legs. From age 12 to 16, the patient was treated with valproic acid, carbamazepine, clobazam, oxcarbazepine, lamotrigine, phenytoin, phenobarbital, and sultiame without any effect. The frequency of seizures increased to up to four or five a day associated with retrobulbar pain, shouting and left-sided or generalised myoclonus.

At age 17 years, the patient was admitted to our centre for recurrent episodes of generalized myoclonus lasting hours, accompanied by sweating and tachycardia, often without alteration of consciousness. During these episodes, he was not able to eat or drink. He had lost 4 kg over the preceding months and required a gastrostomy for feeding. General medical examination showed swollen neck and axillary lymph nodes. There were no signs of acrodermatitis. Head circumference was 54 cm (25th percentile). Neurological examination showed marked spastic/dystonic quadriparesis. Routine EEG showed continuous generalized slowing in the theta range without epileptic activity. EEG during the myoclonic episodes was contaminated by muscle artefact but did not appear epileptic. Back averaging was not done.

To improve the myoclonus, we started treatment with piracetam. The myoclonic attacks decreased significantly and the patient was able to eat and drink and sit in a chair. He drew simple pictures. Folinic acid, 4 mg/kg/day, was added to the piracetam without any noticeable clinical effect and was discontinued three months later. However, his cognitive status continued to decline. At age 19 years, while still on piracetam, he had further episodes of generalized myoclonus over a fortnight, which resolved spontaneously.

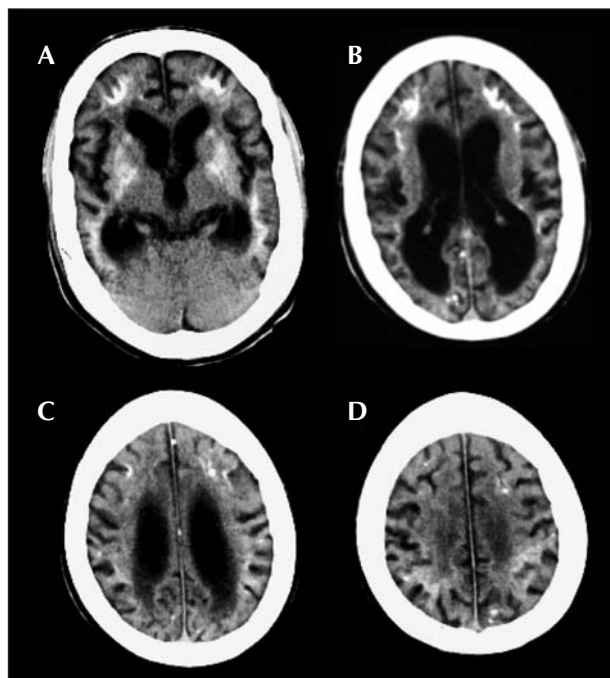


Figure 1. CT scan at age 18 years. **A)** Bilateral calcification of basal ganglia and periventricular white matter. There is supratentorial atrophy with enlarged ventricles and subarachnoid spaces. **B)** Periventricular calcifications and calcification in occipital cortex. **C)** and **D)** show multifocal, small, cortical calcifications.

Cranial CT scan revealed extensive white matter calcification and calcifications in the basal ganglia and cortex (*figure 1*). MRI showed progressive supratentorial atrophy and abnormal white matter signal (*figure 2*). Extensive metabolic and immunological tests at different hospitals, including a muscle biopsy with assessment of respiratory chain enzymes, were unrevealing. At age 17 years, the CSF was acellular with normal protein, glucose and lactate levels. Neopterin was extremely high at 258 nM/L (normal 10–31 nM/L) and 7,8-dihydrobiopterin 26 nM/L (normal < 18 nM/L), which is compatible with an inflammatory process. 5-methyltetrahydrofolate was 2 at the lower end of the normal range (26–118 nM/L) at 8 nM/L. IFN- α was not detectable in the CSF, but was elevated in serum at 3 IU/mL and 2 IU/mL one year later (normal < 2 IU/mL).

Discussion

Although microcephaly and acrodermatitis were absent in our patient, the picture of progressive psychomotor deterioration, intracranial calcifications and white matter changes along with elevated serum IFN- α (> 2 IU/mL) and CSF lymphocytosis in the newborn period, meet the criteria of Aicardi-Goutières syndrome. At age 17, serum IFN- α in our patient was still elevated, although most

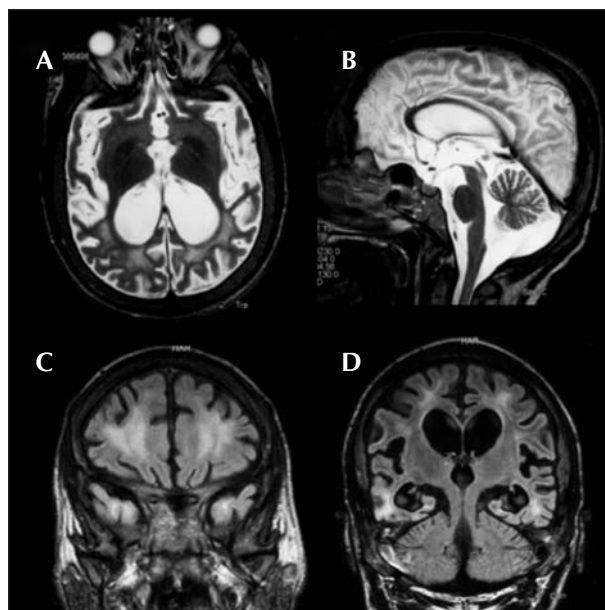


Figure 2. MRI scan at age 18 years. **A)** T2w axial image demonstrating progressive cerebral atrophy. White matter signal is hyperintense. **B)** T2w sagittal image. The cerebellar vermis is slightly atrophic, but not to the same extent as the supratentorial structures. **C)** and **D)** coronal FLAIR images demonstrating hyperintense white matter signal including subcortical white matter in both temporal lobes and severe supratentorial atrophy.

AGS patients show normalisation of CSF IFN- α with age, as well as a decline in lymphocytic pleocytosis (Goutières *et al.* 1998). An apparent susceptibility to infection, as found in our patient's history, has not been reported in AGS, but has been in Cree encephalitis (Black *et al.* 1988), which is allelic with AGS 1 (Crow *et al.* 2003).

The elevation of CSF neopterin is probably secondary to IFN- α activation and has also been described in other patients with AGS (Blau *et al.* 2003). Altogether, this picture is certainly compatible with AGS, but shows some atypical features – the initial presentation was relatively benign, the CSF lymphocytosis resolved quickly, and clinical deterioration occurred only late and might have been aggravated by the increasing frequency of seizures.

Possible differential diagnoses of AGS include mainly disorders with intracerebral calcifications. There was no evidence of pre- or perinatal infections including CMV, toxoplasmosis, rubella, *Herpes simplex* and HIV; the intracranial calcifications and the progressive clinical course have to be explained by a metabolic or neurodegenerative disorder. The “pseudo-TORCH syndrome”, also known as “microcephaly – intracranial calcification syndrome” (MICS), shares many features with AGS, but affected children have microcephaly at birth (Vivarelli *et al.* 2001). Fahr disease, Cockayne syndrome, mitochondrial cytopathies including Leigh's disease, Hoyerlaal-

Hreidarsson syndrome, 3-hydroxyisobutyric aciduria, dihydropteridine reductase deficiency and cases of neonatal and familial systemic lupus erythematosus are known to be accompanied by intracerebral calcifications and microcephaly. All these disorders could be excluded either by appropriate testing or because of an incompatible clinical picture.

Our patient developed, at age 9, complex-focal seizures, possibly with a visual aura and sometimes with secondary generalization, which were resistant to treatment. Late in the course of his disease he also developed myoclonic status, an unusual feature in AGS. Although patients with AGS suffering from myoclonic jerks have been reported, so far no patient with myoclonic status has been described. According to the literature, epilepsy complicates the disease in about a third of the patients, but precise descriptions of epileptic syndrome or seizure semiology are missing (Aicardi and Goutières 1984, Lanzi *et al.* 2005, Abdel-Salam *et al.* 2004). In our case, the contamination of the ictal EEG by muscle artefacts made it impossible to determine whether the myoclonus originated from cortical or from subcortical structures. Although interictal EEG showed only diffuse slowing, massive brain atrophy, enlargement of the skull bones and widened CSF spaces could have prevented reliable detection of epileptic potentials by surface EEG. The beneficial effect of piracetam does suggest a cortical origin, since piracetam is known to be effective for cortical myoclonus, but is only poorly effective for myoclonus of thalamocortical and subcortical origin (Dulac *et al.* 1998, Genton *et al.* 1999, Genton and Van Vleymen 2000). Cortical calcifications, as seen in the CT scan of our patient, also argue for altered cortical excitability and cortical myoclonus.

The genetic basis of AGS has now been elucidated. Mutations in four genes have been found in patients affected with AGS: the AGS1 gene located on chromosome 3p21 (Crow *et al.* 2000) is *TREX1*, a DNA exonuclease (Crow *et al.* 2006a). The AGS2 gene (locus 13q14-q21) (Ali *et al.* 2006), and two, further, recently identified genes (locus 11q13.2 and 19p13.3) are *RNASEH2B*, *RNASEH2C* and *RNASEH2A* forming the ribonuclease H2 enzymatic complex (Crow *et al.* 2006b). The precise disease mechanism is still not understood. Impaired function of one (or more) of the four nucleases could lead to elevated levels of endogenous DNA-RNA hybrids, possibly causing an inflammatory response with increased IFN- α production (Crow *et al.* 2006 a,b). Results of mutation analysis in our patient are still pending. In spite of these recent advances, the diagnosis of the syndrome still remains a clinical one. At present, there is no effective causal therapy for AGS. It is expected that the identification of the genetic basis of AGS will clarify the relationship between the genetic and immunological abnormalities in this syndrome and provide helpful clues for future therapy. □

Legends for video sequences

Video. Left-sided and generalised irregular myoclonic jerks. Note also myoclonus of the face, especially of the eyelids.

EEG. Artefacts caused by the myoclonic jerks.

Acknowledgements. We wish to express our gratitude to Dr. J. Scheidig, and Dr. J. Ohlmann, General Paediatrician in Schwäbisch Hall, Germany, for providing clinical details and blood samples for ongoing studies. We thank the patients' parents, the nursing team and technical staff of the Epilepsy Center Kehl Kork. We are grateful to Professor E. Fazzi, Professor G. Lanzi and the scientific committee of the IAGSA for discussing the case, and special thanks go to Dr. Deborah N. Black, Hôpital Louis-H. Lafontaine, Université de Montréal, for discussing the case and editing a first draft of this manuscript as a native speaker.

References

- Abdel-Salam GMH, Zaki MS, Lebon P, Meguid NA. Aicardi-Goutières syndrome: clinical and neuroradiological findings of 10 new cases. *Acta Paediatr* 2004; 93: 929-36.
- Aicardi J, Goutières F. A progressive familial encephalopathy in infancy with calcifications of the basal ganglia and chronic cerebrospinal fluid lymphocytosis. *Ann Neurol* 1984; 15: 49-54.
- Ali M, Highet LJ, Lacombe D, *et al.* A second locus for Aicardi-Goutières syndrome at chromosome 13q14-21. *J Med Genet* 2006; 43: 444-50.
- Bachmeyer C, Farge D, Gluckman E, *et al.* Raynaud's phenomenon and digital necrosis induced by interferon- α . *Br J Dermatol* 1996; 135: 481-3.
- Barth PG, Walter A, van Gelderen I. Aicardi-Goutières syndrome: a genetic microangiopathy? *Acta Neuropathol (Berl)* 1999; 98: 212-6.
- Barth PG. The neuropathology of Aicardi-Goutières syndrome. *Eur J Ped Neurol* 2002; 6(Suppl A): A27-A31.
- Black DN, Watters GV, Andermann E, *et al.* Encephalitis among Cree children in Northern Québec. *Ann Neurol* 1988; 24: 483-9.
- Blau N, Bonafé L, Krägeloh-Mann I, *et al.* Cerebrospinal fluid pterins and folates in Aicardi-Goutières syndrome. A new phenotype. *Neurology* 2003; 61: 642-7.
- Campbell IL, Krucker T, Steffenden S, *et al.* Structural and functional neuropathology in transgenic mice with CNS expression of INF- α . *Brain Res* 1999; 835: 46-61.
- Campo-Voegeli A, Estrach T, Marti RM, *et al.* Acrocyanosis induced by interferon α . *Dermatology* 1998; 196: 361-3.
- Crow YJ, Black DN, Ali M, *et al.* Cree encephalitis is allelic with Aicardi-Goutières syndrome: implications for the pathogenesis of disorders of interferon α metabolism. *J Med Gen* 2003; 40: 183-7.
- Crow YJ, Hayward BE, Parmar R, *et al.* Mutations in the gene encoding the 3'-5' DNA exonuclease TREX1 cause Aicardi-Goutières syndrome at the AGS1 locus. *Nat Genet* 2006a; 38: 917-20.

- Crow YJ, Jackson AP, Roberts E, et al. Aicardi-Goutières syndrome displays genetic heterogeneity within one locus (AGS1) on chromosome 3 p21. *Am J Hum Genet* 2000; 67: 213-21.
- Crow YJ, Leitch A, Hayward BE, et al. Mutations in genes encoding ribonuclease H2 subunits cause Aicardi-Goutières syndrome and mimic congenital viral brain infection. *Nat Genet* 2006b; 38: 910-6.
- Dulac O, Plouin P, Shewmon A. Myoclonus and epilepsy in childhood: 1996 Royaumont meeting. *Epilepsy Res* 1998; 30: 91-106.
- Genton P, Guerrini R, Remy C. Piracetam in the treatment of cortical myoclonus. *Pharmacopsychiatry* 1999; 32(S1): 49-53.
- Genton P, Van Vleymen B. Piracetam and levetiracetam: close structural similarities but different pharmacological and clinical profiles. *Epileptic Disord* 2000; 2: 209-12.
- Goutières F, Aicardi J, Barth PG, Lebon P. Aicardi-Goutières syndrome: an update and results of interferon-studies. *Ann Neurol* 1998; 44: 900-7.
- Goutières F. Aicardi-Goutières syndrome. *Brain Dev* 2005: 201-6.
- Lanzi G, Fazzi E, D'Arrigo S, et al. The natural history of Aicardi-Goutières syndrome: follow-up of 11 Italian patients. *Neurology* 2005; 64: 1621-4.
- Lebon P, Badoual J, Ponsot G, Goutières F, Hemeury-Cukier F, Aicardi J. Intrathecal synthesis of interferon-alpha in infants with progressive familial encephalopathy. *J Neurol Sci* 1988; 84: 201-8.
- Stephenson JBP. Aicardi-Goutières syndrome – observations of the Glasgow school. *Eur J Ped Neurol* 2002; 6(Suppl A): A67-A70.
- Tolmie JL, Shillito P, Hughes-Benzie R, Stephenson JB. The Aicardi-Goutières syndrome (familial, early onset encephalopathy with calcifications of the basal ganglia and chronic cerebrospinal fluid lymphocytosis). *J Med Genet* 1995; 32: 881-4.
- Vivarelli R, Grosso S, Cioni M, et al. Pseudo-TORCH syndrome or Baraitser-Reardon syndrome: diagnostic criteria. *Brain Dev* 2001; 23: 18-23.