

Advanced MRI analysis methods for detection of focal cortical dysplasia

Andrea Bernasconi

Department of Neurology and Brain Imaging Center, Montreal Neurological Hospital and Institute, McGill University, Montreal, Quebec, Canada

ABSTRACT – In many patients, lesions of focal cortical dysplasia (FCD) may go unrecognized by standard radiological analysis. This is due to the fact that identification of many of these malformations on visual inspection of conventional MRI is difficult due to their subtlety and the complexity of the brain's convolutions. Quantitative MR image processing methods have the potential to help identify lesions that may be overlooked by conventional radiological evaluation. To increase the sensitivity of MRI for the detection of subtle lesions of FCD, we recently developed voxel-based image post-processing methods, including first-order texture analysis and morphological processing modeled on known MRI features of FCD. Using these methods we were able to increase the sensitivity over conventional MRI analysis by more than 30%, while maintaining a high degree of reliability. The image processing methods we developed improve visual detection of FCD, even in cases where no lesion is obvious on MRI. Therefore, these techniques could allow a more precise evaluation of patients with partial epilepsy who could benefit from surgery.

KEY WORDS: focal cortical dysplasia, epilepsy, magnetic resonance imaging, image processing, texture analysis

Relevance of MRI in epilepsy surgery

The multidisciplinary approach to pre-surgical evaluation is based on clinical phenomena, EEG data, neuropsychological assessment and neuroimaging. The advent of magnetic resonance imaging (MRI) has had a major impact on the pre-surgical evaluation of patients with focal epilepsy by allowing the identification of a lesion in many patients previously considered to have cryptogenic epilepsy. Surgical removal of lesions identified by MRI that are considered to be part of the epileptogenic zone improves surgical outcome in patients [1,2].

Focal cortical dysplasia may be difficult to detect on conventional MRI

Malformations of cortical development are increasingly recognized as an important cause of intractable focal epilepsy. Compared to other brain lesions that cause epilepsy, these malformations tend to affect younger patients.

Taylor-type focal cortical dysplasia (FCD) [3] corresponds to a localized disruption of the normal cortical lamination associated with an excess of large, aberrant neurons, an increase in cortical thickness, and often, abnormal neuroglial elements in the underlying white matter (WM). On MRI, FCD is mainly characterized by vari-

Correspondence:

Andrea Bernasconi, M.D.
Montreal Neurological Institute
3801 University Street
Montreal, Quebec, Canada H3A 2B4
Phone: (514) 398-8524
Fax: (514) 398-2975
E-mail: andrea@bic.mni.mcgill.ca
Presented at the "Claudio Munari" Workshop
2002 on Focal Cortical Dysplasia, Roma 16th
March, 2002

able degrees of cortical thickening, a poorly defined transition between gray matter (GM) and WM, and hyperintense signal within the dysplastic lesion with respect to normal cortex [4]. FCD lesions are mostly located in extra-temporal areas.

MRI of the brain has made it possible to detect FCD in an increasing number of patients [5,6]. However, the number of cases treated surgically remains small and the prognosis sometimes poorer than in patients undergoing surgery for other types of lesions. This is partly due to the fact that identification of many FCD lesions on visual inspection of conventional MRI is difficult due to their subtlety and the complexity of the brain's convolutions. In patients with no detectable structural lesion, so-called "MRI-negative" or cryptogenic cases, intensive EEG monitoring with intracranially implanted electrodes is usually performed.

The potential of image processing in the detection of focal cortical dysplasia

Curvilinear reformatting of three-dimensional MRI [7] is a qualitative image analysis that attempts to improve lesion visualization by providing a more realistic anatomical display of the gyral structure of the hemispheric convexities. Compared to the standard orthogonal MRI evaluation, this approach also reduces the asymmetric sampling of GM and WM that may lead to false-positive results. However, the inherent complexity of the brain's convolutional pattern makes the visual identification of FCD lesions difficult. Consequently, the shortcoming of conventional MRI methodologies and curvilinear reformatting is that assessment is entirely subjective, and has to take the normal variations in gyral morphology into account. Novel quantitative MR images processing methods have the potential to help identify lesions that may be overlooked by conventional radiological evaluation of films.

To date, only a few imaging studies based on a limited number of patients have addressed the question of structural abnormalities associated with malformations of cortical development. In a volumetric study of 18 patients with heterotopias, volume reduction of extra-lesional hemispheric GM was found in 15 patients and in the contralateral hemisphere in 9/10 patients in whom there were apparently unilateral abnormalities [8]. Voxel-based morphometry in ten patients with different types of malformations of cortical development, mainly heterotopia, showed increases in GM density in the lesional areas [9]. Beside morphology, texture is an important feature for visual assessment of an image. The texture of an image can be described by the distribution of brightness and darkness within that image. Texture analysis is the term used for methods developed to quantify image texture. Computer-based texture analysis of digital images provides quantitative information about spatial gray level variations in pixel neighborhoods [10], and is more sensitive to image tex-

tural changes than the human eye. In medical imaging, texture analysis has been shown to increase the level of diagnostic information extracted from many modalities such as MRI and ultrasound, and facilitates characterization of differences in appearances unrecognizable by visual observation. Reported applications include classification of pathological tissue in liver, thyroid, breast, kidney, prostate and the heart, and characterization of brain tumors and human trabecular bone [11-13]. Texture analysis has also been used to identify pathology in Alzheimer's disease [14], temporal lobe epilepsy [15] and multiple sclerosis [16].

Texture analysis and morphological processing allow increased detection of focal cortical dysplasia

To improve our ability to detect dysplastic lesions in patients with intractable partial epilepsy, we recently developed voxel-based image processing techniques, including pixel intensities, with regard to GM and WM, local gradient and GM thickness. These features were chosen to model, *in vivo*, the pathological characteristics of FCD. We hypothesized that such image post-processing could increase the sensitivity of MRI for the detection of subtle lesions of FCD [17].

We selected 16 patients who had histologically proven FCD at surgery. All patients had focal corticectomies. In eight patients, FCD had been recognized on MRI, prior to surgery. In the remaining eight patients, the MRI had been reported as normal. In patients in whom no lesion was visible on MRI, surgery was based on strong clinical and EEG co-localizing data. Resections were carried out involving the parietal lobe in seven patients and the frontal lobe in nine patients. Fourteen patients became seizure-free and two had a significant reduction in frequency and severity of the attacks (mean follow-up 26 months). Pre-operative images were acquired on a 1.5 T scanner (Gyroscan, Philips Medical System, Best, The Netherlands) using a T1-fast field echo sequence. Image processing features were calculated for each individual voxel within the T1-weighted 3D MRI, resulting in a three-dimensional map for each feature. Details about modeling of the different characteristics of FCD have been published elsewhere [17]. In brief, to model cortical thickening, we calculated, for each voxel, the number of consecutive GM voxels in each possible direction. To model the blurring of the GM-WM transition, we calculated the absolute gradient of gray level intensities, a first-order texture feature. To model the hyperintense signal within the focal cortical dysplasia on T1-weighted images, we developed a feature that calculated the absolute difference between the intensity of a given voxel and the intensity at the boundary between GM and WM, defined using a histogram. To maximize visibility of FCD lesions, a ratio map (GM thickness x relative intensity/gray level intensity gradient) was generated.

MR images and ratio maps for the 16 patients and 20 healthy control subjects were presented, in random order, to two trained observers who were unaware of the final diagnosis. Sensitivity (predicted positives/ total positives) was 87.5% (14/16) for the *ratio* maps, compared to 50% (8/16) for MRI ($P < 0.003$). Specificity (predicted negatives/total negatives) was 95% (19/20) for ratio maps and 100% (20/20) for MRIs.

The figure shows an example of a patient with an obvious FCD lesion on preoperative MRI, and one example of a patient in whom the MRI was reported as normal, but for whom ratio maps showed a lesion.

Conclusion

Detection of subtle dysplastic lesions may be improved by performing computerized quantitative analysis of the structural changes that characterize FCD pathologically and *in vivo* on MRI. This approach makes use of the large amount of data available in volumetric MRI scans, much of which may be too subtle to be appreciated by visual analysis alone. It is our hope that these new techniques, ultimately, will become more widely available and permit identification of FCD in many more patients with intractable epilepsy undergoing evaluation in specialized centers. □

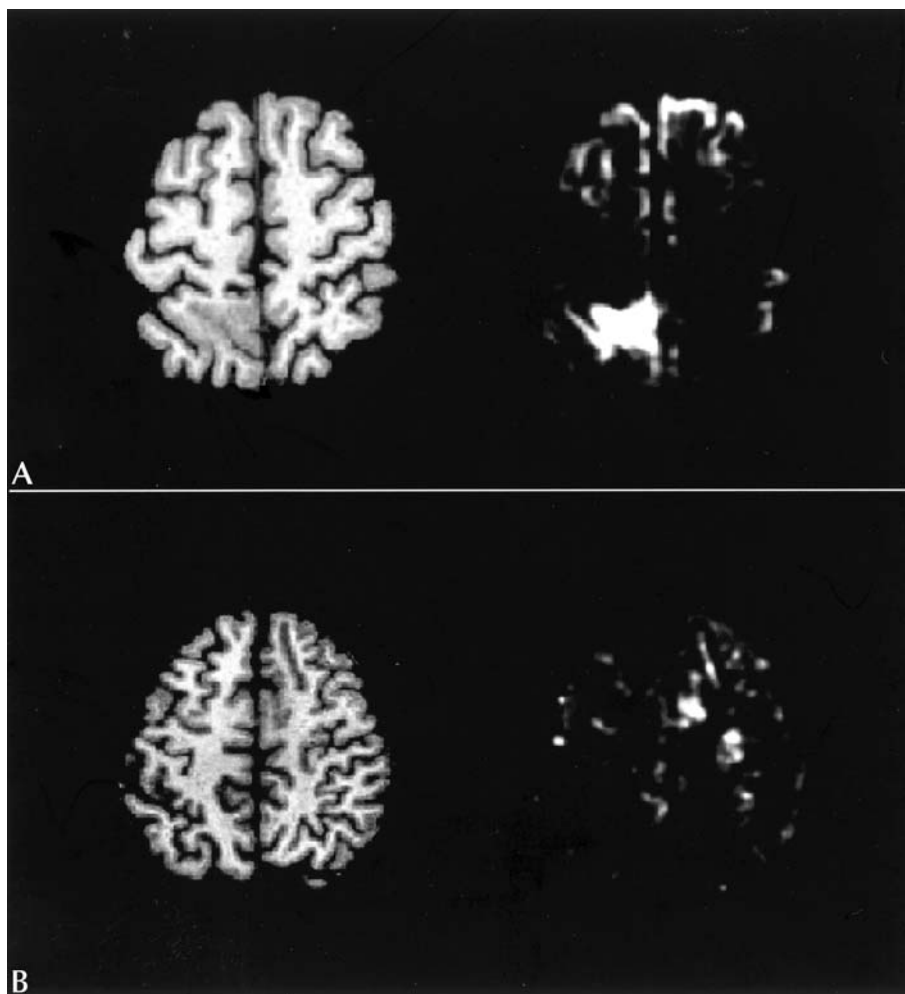


Figure 1. Two patients with focal cortical dysplasia are shown. T1-weighted MR images are on the left side of the panel, and ratio maps (see text for explanation) are on the right side (left is left on the panels). Only one representative image for the MRI and the ratio maps are presented. (A) Top panels show images of a patient with left parietal lobe epilepsy. A dysplastic lesion in the left parietal area is visible on MRI. The same lesion is clearly demonstrated on the ratio map. (B) Bottom panels show images of a patient with intractable right frontal lobe epilepsy, who had motor seizures of the left arm. The EEG showed interictal epileptic abnormalities in the right fronto-central area. Electroclinical seizures were recorded from the same area. The T1-weighted MRI was reported as normal. The ratio map shows an area of hyperintense signal in the right pre-central area. The patient underwent a corticectomy involving the right pre-central area. Histological examination of the resected tissue showed subtle focal cortical dysplasia of the Taylor type, with gliosis.

Acknowledgements

This work was supported by a grant of the Canadian Institutes of Health Research (CIHR #100203) and the Savoy Foundation for Epilepsy.

References

1. Fish DR, Smith SJ, Quesney LF, Andermann F, Rasmussen T. Surgical treatment of children with medically intractable frontal or temporal lobe epilepsy: results and highlights of 40 years' experience. *Epilepsia* 1993; 34: 244-7.
2. Olivier A. Surgery of frontal lobe epilepsy. [Review]. *Adv Neurol* 1995; 66: 321-48.
3. Taylor DC, Falconer MA, Bruton CJ, Corsellis JAN. Focal dysplasia of the cerebral cortex in epilepsy. *J Neurol Neurosurg Psychiatry* 1971; 34: 369-87.
4. Barkovich AJ, Kuzniecky RI. Neuroimaging of focal malformations of cortical development. *J Clin Neurophysiol* 1996; 13: 481-94.
5. Grant PE, Vingneron DB, Barkovich AJ. High-resolution imaging of the brain. *Magn Reson Imaging Clin N Am* 1998; 1: 139-54.
6. Barkovich AJ, Rowley HA, Andermann F. MR in partial epilepsy: value of high-resolution volumetric techniques. *Am J Neuroradiol* 1995; 16: 339-43.
7. Bastos AC, Comeau RM, Andermann F, et al. Diagnosis of subtle focal dysplastic lesions: curvilinear reformatting from three-dimensional magnetic resonance imaging. *Ann Neurol* 1999; 46: 88-94.
8. Sisodiya SM, Free S, Stevens JM, Fish DR, Shorvon SD. Wide-spread cerebral structural changes in patients with cortical dysgenesis and epilepsy. *Brain* 1995; 118: 1039-50.
9. Woermann FG, Free SL, Koepp MJ, Ashburner J, Duncan JS. Voxel-by-voxel comparison of automatically segmented cerebral gray matter-A rater-independent comparison of structural MRI in patients with epilepsy. *Neuroimage* 1999; 10: 373-84.
10. Haralick RM, Shanmugam K, Dinstein I. Textural features for image classification. *IEEE Trans Sys Man Cyber* 1973; SMC-3: 610-21.
11. Lerski RA, Straughan K, Schad LR, Boyce D, Bluml S, Zuna I. MR image texture analysis-an approach to tissue characterization. *Magn Reson Imaging* 1993; 11: 873-87.
12. Garra BS, Krasner BH, Horii SC, Ascher S, Muk SK, Zeman RK. Improving the distinction between benign and malignant breast lesions: the value of sonographic texture analysis. *Ultrasound Imaging* 1993; 15: 267-85.
13. Sinha S, Lucas-Quesada FA, DeBruhl ND, et al. Multifeature analysis of Gd-enhanced MR images of breast lesions. *J Magn Reson Imaging* 1997; 7: 1016-26.
14. Freeborough PA, Fox NC. MR image texture analysis applied to the diagnosis and tracking of Alzheimer's disease [letter]. *IEEE Trans Med Imaging* 1998; 17: 475-9.
15. Yu O, Mauss Y, Namer IJ, Chambron J. Existence of contralateral abnormalities revealed by texture analysis in unilateral intractable hippocampal epilepsy. *Magn Reson Imaging* 2001; 19: 1305-10.
16. Mathias JM, Tofts PS, Losseff NA. Texture analysis of spinal cord pathology in multiple sclerosis. *Magn Reson Med* 1999; 42: 929-35.
17. Bernasconi A, Antel SB, Collins DL, et al. Texture analysis and morphological processing of magnetic resonance imaging assist detection of focal cortical dysplasia in extra-temporal partial epilepsy. *Ann Neurol* 2001; 49: 770-5.