

Adult epileptic spasms: a clinical and video-polygraphic study

Giuseppe d'Orsi, Vincenzo Demaio, Mauro G. Minervini

Epilepsy Center, Neurological Unit, Casa Divina Provvidenza, Opera Don Uva, Bisceglie (BAT), Italy

Received February 5, 2007; Accepted May 2, 2007

ABSTRACT – Purpose. To analyse the video-polygraphic features of two patients with adult epileptic spasms (ES). **Methods.** Two patients with epileptic encephalopathy related to different cortical malformation; epileptic spasms had been present since the age of 18 and 25 years respectively. The patients underwent a clinical and neurophysiological examination (awake and sleep video-polygraphic monitoring).

Results. In patient 1, epileptic spasms were characterized by loss of contact and a drooping forward of the head and upper extremities. ES were in clusters, of brief duration, lasting for 20''-1'; all events occurred during eating. Awake and sleep interictal EEG disclosed asynchronous paroxysmal abnormalities in the temporo-parieto-occipital regions. The ictal EEG showed a diffuse slow wave complex with intermingled fast activity, prevalent on both anterior regions; on polygraphic recordings, the prevalence of the muscle activation, in *crescendo-decrescendo*, was in the neck and the right side. In patient 2, ES were characterized by loss of awareness, head deviation to the left, jerks of the head and left limbs. ES occurred in cluster, and were of brief duration (< 1''), usually on awakening. Interictal EEG showed epileptiform abnormalities in the right fronto-centro-temporal regions; abnormalities present in the awake EEG were enhanced during NREM sleep. The ictal EEG showed a diffuse, slow wave complex with intermingled fast activity, prevalent in the right regions, with concomitant muscle activation, in *crescendo-decrescendo*, on the left deltoid and tibialis anterior.

Conclusions. Our two cases of adult ES were characterized by distinct clinical and polygraphic features, which were of brief duration, mild intensity, rare frequency per minute, and with preservation of cluster organization. In one patient, ES were induced by eating (reflex periodic spasms triggered by eating). A firm diagnosis of adult ES can be reached using video-polygraphic monitoring.

Key words: epileptic spasms, adult onset, cortical malformation, video-polygraphy, eating epilepsy

Correspondence:

G. d'Orsi
Epilepsy Center, Neurological Unit,
Casa Divina Provvidenza, Opera Don Uva,
Via Bovio 78,
70052 Bisceglie (BAT),
Italy
Tel.: (+00 39) 080/3367427
Fax: (+00 39) 080/3367418
<giudorsis@yahoo.it>

Epileptic spasms (ES) are a distinct seizure type characterized by muscle contractions of variable duration that affect predominantly axial muscles, frequently occurring in clusters and usually consisting of abduction of arms in a "salaam" posture (Luders *et al.* 1998).

ES-onset is almost always during the first two years of life, rarely in children older than two years, and usually in children younger than one year (Lux and Osborne 2004). It may rarely persist, or re-emerge, after apparent remission (Camfield *et al.* 2003), into

doi: 10.1684/epd.2007.0114

mid-childhood and adult life, tending to be sporadic and often losing the feature of occurring in periodic clusters (Talwar *et al.* 1991, Sotero de Menezes *et al.* 2002). Consequently, the occurrence of ES beyond the first years may be underestimated. Moreover, adult-onset is very rare, however, usually with the same electrophysiological features as ES occurring in infancy (Cerullo *et al.* 1999, Maton *et al.* 2000). Nevertheless, the adult-onset of ES in these cases was not certain because of the lack of clinical and EEG documents and/or because it may have gone unrecognised in the first years of life (Cerullo *et al.* 1999). We describe the clinical and video-polygraphic characterization of two patients with adult onset ES (> 18 years). In fact, as both patients had experienced perinatal distress, they had undergone frequent check-ups ever since the early months of life, which included video-polygraphic recordings, and only when they were adults (> 18 years) did they start to present definite ES. We focussed our attention, in particular, on semiological and electrophysiological features of adult ES compared to infantile ES. To our knowledge, this is the first and certain electroclinical documentation of adult-onset ES.

Methods

The two patients underwent full clinical, video-polygraphic and neuroradiological studies (with particular attention to age at ES- and seizure-onset, ES description and course). EEG electrodes were placed according to the 10-20 International system with bipolar montage; several sessions of video-EEG-polygraphic monitoring were performed for each patient, during which ES were documented. Polygraphic parameters included ECG, thoracic respiration, electromyographic activity from neck, right and left sternocleidomastoideus, right and left flexor and extensor muscles of the hand, right and left tibialis muscles (case 1); chin, right and left deltoid, left flexor and extensor muscles of the hand, left tibialis muscles (case 2). Both patients also underwent overnight, in-lab. videopolysomnographic sleep recording, including EEG, electrooculogram, electromyography of the chin, recording of thoracic respiratory movements by means of strain gauges, measurement of heart and pulse rate, measurement of arterial oxygen haemoglobin saturation by means of a pulse oximeter with a finger probe. High-resolution 1.5-Tesla magnetic resonance imaging (MRI) studies were also available for both patients.

Results

Case 1

The patient was a 30-year-old, right-handed man who suffered severe asphyxia at birth. Delayed development and severe mental retardation were noted from the first months of life. From the age of 25 years, he began to present

a) generalized tonic-clonic seizures occurring once a month, b) atonic drop attacks occurring several times a month, c) repetitive daily seizures, usually during eating, characterized by sudden drooping of the head and upper limbs, with loss of consciousness. The response to various treatments with valproic acid (VPA), carbamazepine (CBZ), oxcarbazepine (OXC), clonazepam (CNZ), levetiracetam (LEV) and lamotrigine (LTG) was poor. Additional treatment with valproic acid and clobazam (CLB), one hour before meals, resulted in a reduction of seizure frequency. Neurological examination showed severe mental retardation, facial dysmorphism, spastic tetraparesis (left > right limbs). Brain MRI disclosed bilateral opercular dysplasia and corpus callosum hypoplasia. Wakeful interictal EEG recordings showed a diffuse alpha-like background activity modified by closure of the eyes, associated with theta activity and spike-wave complexes over the left temporo-parieto-occipital regions; sleep (in particular 2-3 NREM) disclosed paroxysmal abnormalities in the right temporo-parieto-occipital region. Continuous video-EEG recordings were performed before, during and after the meal. A train of eating-induced, repetitive, brief spasm seizures appeared some minutes after the beginning of the meal which were characterized by loss of consciousness and sudden drooping forward of the head and upper extremities (right>left). The ES lasted for 20''-1'', there being a refractory period of about one-two minutes after each attack (*table 1*). At the beginning of each cluster, the spasms were usually brief, often not easy to recognize and with quite insignificant motor manifestations; successively, the spasms became

Table 1. Duration and inter-spasms interval of a cluster of 19 ES triggered by a meal in *Patient 1*.

| Spasms | Duration | Inter-spasm interval |
|--------|----------|--------------------------|
| 1 | 20'' | 50'' after onset of meal |
| 2 | 1''6'' | 00'29''72'' |
| 3 | 72'' | 00'38''45'' |
| 4 | 56'' | 00'29''22'' |
| 5 | 30'' | 00'37''69'' |
| 6 | 84'' | 01'02''87'' |
| 7 | 56'' | 00'49''87'' |
| 8 | 62'' | 01'12''41'' |
| 9 | 92'' | 00'28''77'' |
| 10 | 76'' | 00'50''98'' |
| 11 | 1''12'' | 01'21''91'' |
| 12 | 68'' | 00'52''43'' |
| 13 | 96'' | 00'45''48'' |
| 14 | 1''08'' | 00'51''11'' |
| 15 | 52'' | 01'22''20'' |
| 16 | 1''04'' | 01'12''54'' |
| 17 | 64'' | 01'24''77'' |
| 18 | 80'' | 01'04''18'' |
| 19 | 96'' | 03'24''28'' |

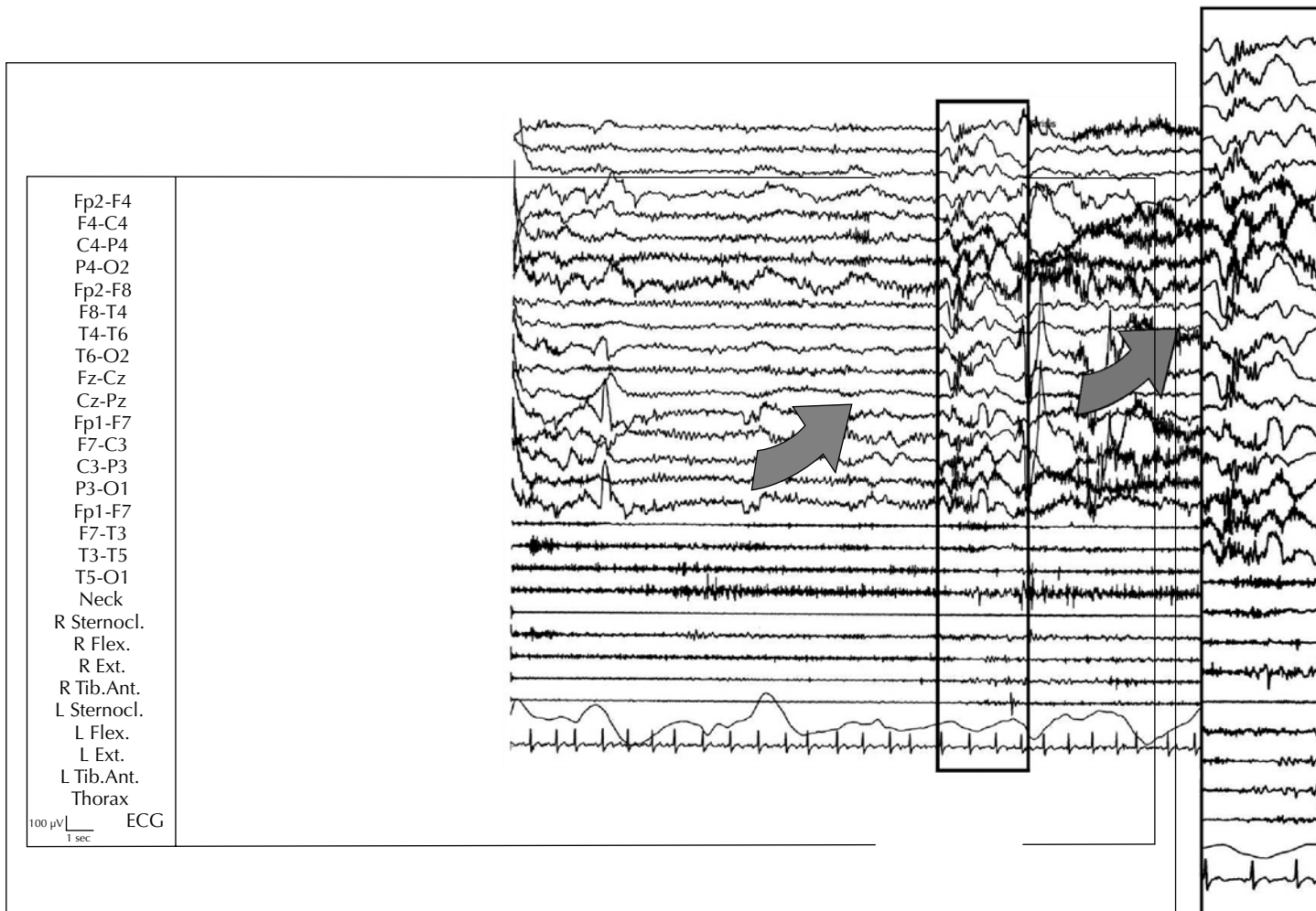


Figure 1. A longer spasm (> 1 second) evoked by meal in patient 1. The EEG shows a diffuse slow wave complex, prevalent on both anterior regions, with the prevalence of the muscle activation on the neck and the right side (in particular, sternocleidomastoideus). R, L. Sternocl.: right and left muscles sternocleidomastoideus. R., L. Flex.: right and left flexor muscles of the hand. R., L. Ext.: right and left extensor muscles of the hand. R, L. Tib. Ant.: right and left muscles tibialis anterior.

longer, and motor manifestations were more evident. In the same gradual way, the spasms stopped when the meal finished. All of the events occurred while eating, usually during lunch, less frequently at breakfast or dinner; chewing and swallowing with nothing in the mouth occasionally triggered the seizure. During the longer spasms (of at least 1 second), the ictal EEG (in part masked by muscle artefacts) showed a diffuse, slow wave complex, prevalent on both anterior regions (*figure 1*); on polygraphic recording, the prevalence of the muscle activation was in the neck and the right side (in particular, the sternocleidomastoideus). During the shorter spasms (hundredths of a second), the ictal EEG showed a slow wave complex of low amplitude with intermingled fast activity and with no obvious change in the concomitant polygraphic features (*figure 2*).

Case 2

The patient was a 19-year-old, right-handed man who was born at the 34st week of gestation, after emergency Caesarean section for premature labour.

Delayed development and mental retardation were noted from the first years of life. From the age of 16 years, he began to present generalised seizures, which were preceded by head turning to the left and myoclonic jerks of the left upper limb, and occurring several times a month. Two years later, repetitive daily seizures, usually on awakening, developed. These were accompanied by loss of awareness, head deviation to the left, jerks of the head, stiffening and jerks of the left limbs (in particular, left upper limb). The response to treatment with VPA and vigabatrin

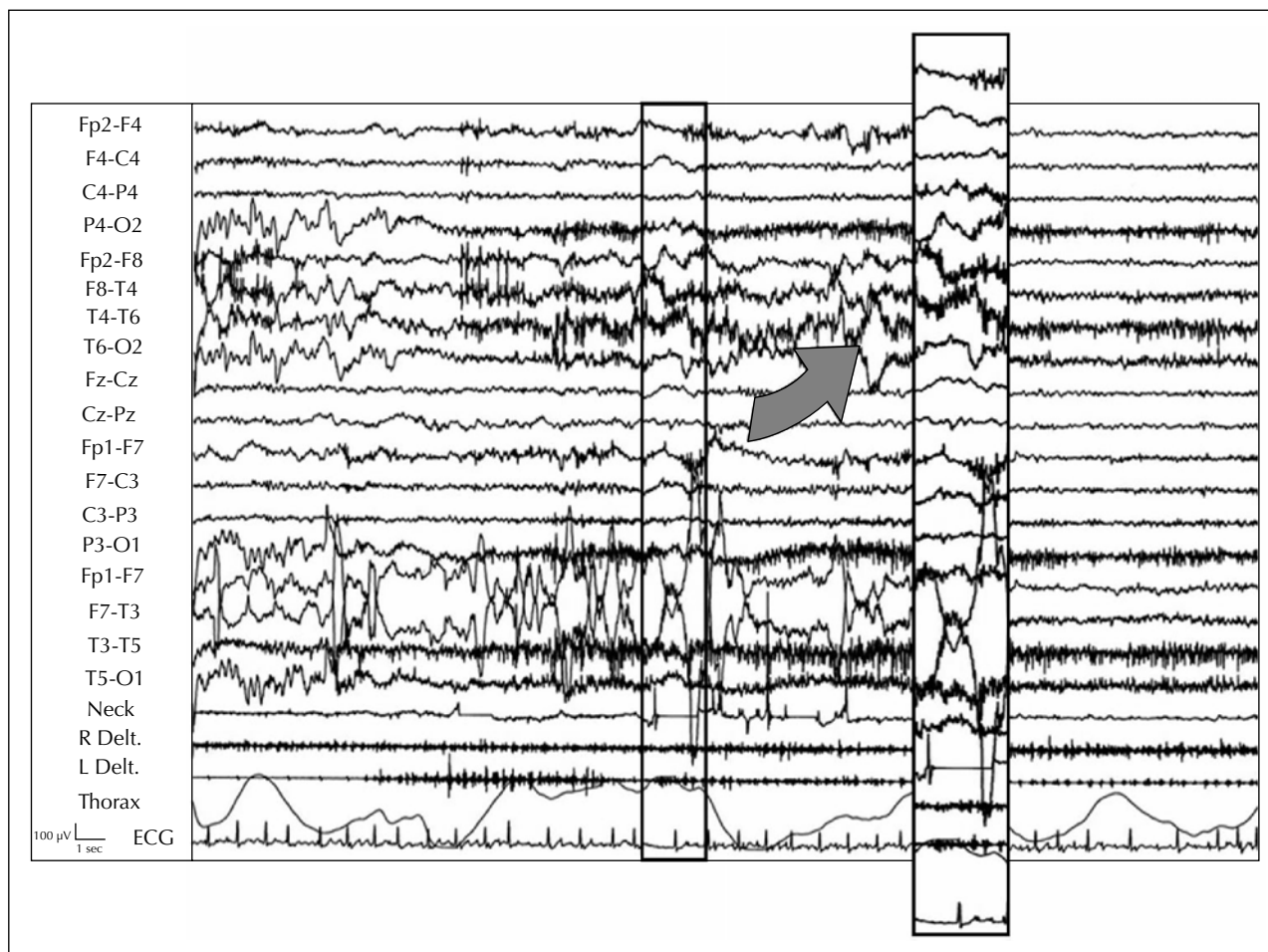


Figure 2. A shorter spasm (< 1 second) evoked by a meal in patient 1. The ictal EEG shows a slow wave complex of low amplitude with intermingled fast activity, with no evident change of concomitant polygraphic features. R., L. Delt.: right and left deltoid muscles.

(GVG) was poor. Treatment with LTG (200 mg/d) resulted in a consistent reduction of seizure frequency. Neurological examination showed mild mental retardation (IQ: 60). Brain MRI disclosed complex cortical and cerebral malformation (right subcortical heterotopia and polymicrogyria; agenesis of the corpus callosum). Awake interictal EEG recordings showed theta activity and spike-wave complexes over the right fronto-centro-temporal regions, NREM sleep enhanced abnormalities present in the awake EEG; during REM sleep, right paroxysmal abnormalities persisted, although there were fewer. Various spasm clusters were registered, both on awakening and during the day. In each cluster, only some of the spasms were clinically recognizable. These were characterized by clear myoclonic jerks of the head and the left limbs; in fact, only careful video-polygraphic analysis disclosed most of the spasms, which were characterized by rapid deviations of rima oris towards the left or by isolated myoclonic jerks of the head or the upper left limb, which were of brief duration (table 2).

During the longer spasms (of at least one second and with clear clinical evidence - myoclonic jerks of the head and the left limbs), the ictal EEG showed a diffuse, slow wave complex mainly on the right regions, accompanied by concomitant muscle activation, in *crescendo-decrescendo*, on the left deltoid and tibialis anterior (figure 3). In most of the spasms (of less than 1 second long and with poor clinical evidence), the ictal EEG showed a slow wave complex followed by fast activity on the right regions, with a minor, concomitant muscle activation, in *crescendo-decrescendo*, on the left deltoid (figure 4).

Discussion

Very little is known about adult-onset epileptic spasms, particularly the electroclinical features. In fact, several ILAE commissions and workshops (Lux and Osborne 2004, Commission on the Classification and Terminology of the International League Against Epilepsy, 1985, 1989; Commission on Pediatric Epilepsy of the International

Table 2. Duration and inter-spasms interval of a cluster of 17 ES activated after arousal from sleep in *Patient 2*.

| Spasms | Duration | Inter-spasm interval |
|--------|----------|------------------------------|
| 1 | 45'' | 14' after arousal from sleep |
| 2 | 56'' | 00'59''87'' |
| 3 | 52'' | 00'36''19'' |
| 4 | 60'' | 02'02''57'' |
| 5 | 96'' | 00'43''54'' |
| 6 | 12'' | 00'16''08'' |
| 7 | 56'' | 00'15''36'' |
| 8 | 56'' | 00'10''92'' |
| 9 | 28'' | 00'06''29'' |
| 10 | 88'' | 00'33''27'' |
| 11 | 44'' | 00'43''79'' |
| 12 | 60'' | 00'11''66'' |
| 13 | 72'' | 00'06''09'' |
| 14 | 60'' | 00'48''76'' |
| 15 | 76'' | 00'11''35'' |
| 16 | 52'' | 00'53''47'' |
| 17 | 99'' | 00'47''09'' |

League Against Epilepsy 1992) have suggested that cases of ES usually have their onset before the age of 12 months, and rarely after age 24 months, occurring in infancy or young childhood. Consequently, all studies have investigated the electroclinical features of infantile-onset ES.

Two electroclinical patterns have emerged related to age: 1) infantile-onset with persistence during infancy; 2) infantile-/adult-onset with persistence into adulthood.

Infantile-onset with persistence in infancy

Using video-EEG analysis, spasms can be divided into three types (flexor, extensor, and mixed flexor-extensor) based on postural manifestations and pattern of muscle involvement during the seizure (Lux and Osborne 2004, Kellaway *et al.* 1979). They can also be asymmetrical, but almost exclusively in symptomatic patients as a result of focal brain lesions (Fusco and Vigevano 1993). The true spasms consist of a characteristic muscular contraction that lasts from one to two seconds, typically occurring in clusters; in particular, the number of seizures per cluster varies considerably, with some clusters involving as many as 150 seizures. The number of clusters per day also varies, with some patients having as many as 60 clusters per day. Although spasms can rarely occur during sleep, clusters of spasms are frequently activated after awakening (Wong and Trevathan 2001). Finally, the intensity and frequency of the spasms in each cluster may increase in a crescendo fashion, peaking and then slowly decreasing in intensity. A hypsarrhythmic or modified hypsarrhythmic pattern is the most common type of interictal abnormality, whereas the ictal EEG may consist of a positive wave over the vertex-central regions, a spindle-like activity of low-

amplitude fast (14 to 16 Hz) activity, or diffuse, decremental activity with concomitant *crescendo-decrescendo* electromyogram activity (Sotero de Menezes *et al.* 2002, Fusco and Vigevano 1993).

Infantile-/adult-onset with persistence into adulthood

ES may also persist beyond the second year of life, with a tendency for the spasms to appear, at times, in isolation, but often occurring in series (Sotero de Menezes *et al.* 2002), and are characterized clinically by less prominent movements. Electrophysiological features are similar to ES occurring in infancy.

In contrast to infantile-onset, adult-onset ES have been rarely studied, and have been probably underestimated, because only a prolonged video-polygraphic recording would disclose them. In fact, when we compare our cases of ES with adult-onset, against infantile-onset spasms with persistence in infancy, the ES do not last as long (< 1 second), and are less frequent. Moreover, the intensity is usually milder, and although they also occur in clusters, their duration is shorter. All these clinical features show the importance of video-polygraphy as a useful method of diagnosis in adult-onset ES. In fact, only some spasms of each cluster can be clearly recognized, most of them having such bland clinical manifestations that they cannot be recognized clinically. Consequently, if video-polygraphy is not used, it could compromise a correct diagnosis, with the identification of episodes, not as part of a cluster of spasms, but as single epileptic seizures, with subsequent consequences, particularly in terms of treatment.

From an electrophysiological point of view, other differences can be seen. In fact, in our cases of adult-onset ES, the hypsarrhythmic interictal pattern disappears, with mainly focal abnormalities, and during sleep. The ictal pattern, even if compared against infantile-onset spasms, is not easy to recognize because of the brief duration of the attacks (slow wave, often of small amplitude). These clinical and polygraphic differences make necessary the use of appropriate video-polygraphic monitoring. In conclusion, adult-onset ES, in common with infantile-onset ES with persistence into adulthood, are clinically less prominent than in children, with fewer spasms per cluster. It seems more likely that the clinical presentation depends on the patient's age, and not on the age-at-onset. Finally, our cases of adult-onset ES are related to cortical malformations, such as the rare cases of adult-onset reported in the scientific literature (Cerullo *et al.* 1999) and the numerous cases of infantile-onset ES with persistence into adult life (Sotero de Menezes *et al.* 2002). Therefore, the spasm may represent a sort of dysplasia-dependent epileptic syndrome, beyond a simple coincidence. Future studies may confirm this possible link between a clinical manifestation (spasm) and its etiology (cortical malformation).

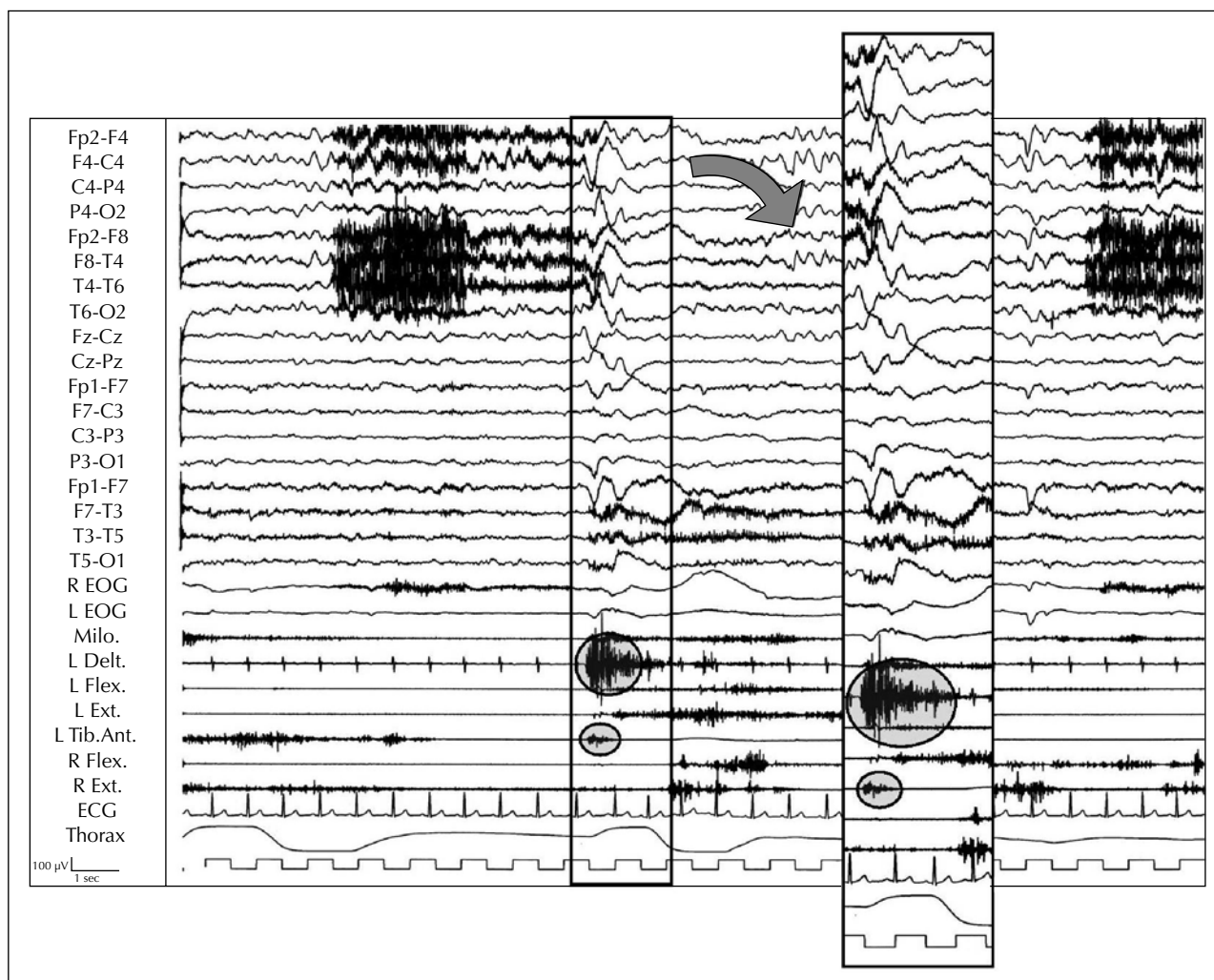


Figure 3. A longer spasm (> 1 second) in patient 2. The EEG showed a diffuse slow wave complex mainly on the right regions and with concomitant muscle activation, in crescendo-decrescendo, on the left deltoid and tibialis anterior. L. Delt.: left deltoid muscle. R., L. Flex.: right and left flexor muscles of the hand. R., L. Ext.: right and left extensor muscles of the hand. L. Tib. Ant.: left muscle tibialis anterior.

Epileptic spasms evoked by eating

In our first case, ES were induced by eating. In particular, the symptoms of the seizures and the ictal EEG findings in this patient were consistent with periodic spasms (Gobbi *et al.* 1987, Nakazawa *et al.* 2001, Labate *et al.* 2006). In fact, periodic spasms are characterized by a series of clinico-electrical events including clinical spasms and EEG complexes (Gobbi *et al.* 1987, Kobayashi *et al.* 2001, Labate *et al.* 2006). Each EEG complex consists of a slow wave and superimposed fast activity. Periodic spasms usually begin after the first year of life and persist without any age-dependent, evolutionary change; hypsarrhythmia is not noted on EEG and a cluster of periodic spasms is often preceded by a partial seizure. Spasms induced by eating in our first patient have many points in common with periodic spasms, including absence of hypsarrhythmia

and slow waves on the ictal EEG associated with the muscle activity associated with the spasms. Eating epilepsy represents a heterogeneous designation of seizures, with varying features and mechanisms (Loiseau *et al.* 1986), and has been classified into two distinct groups depending on whether seizure-onset is temporal or opercular. Eating-induced seizures are usually localization-related, and are most commonly of the complex partial type. Electroencephalographical studies have indicated that the epileptogenic abnormalities arise in inferio-mesial temporal structures (temporal type) and are evoked by relatively elaborate triggering stimuli (Remillard, *et al.* 1998). Less frequently, seizures are of the simple partial type and the ictal origin seems to be located in the suprasylvian region (opercular type) and triggered by proprioceptive or somatosensory stimuli (Remillard, *et al.* 1998). In particular, in the opercular group, electroclinical stud-

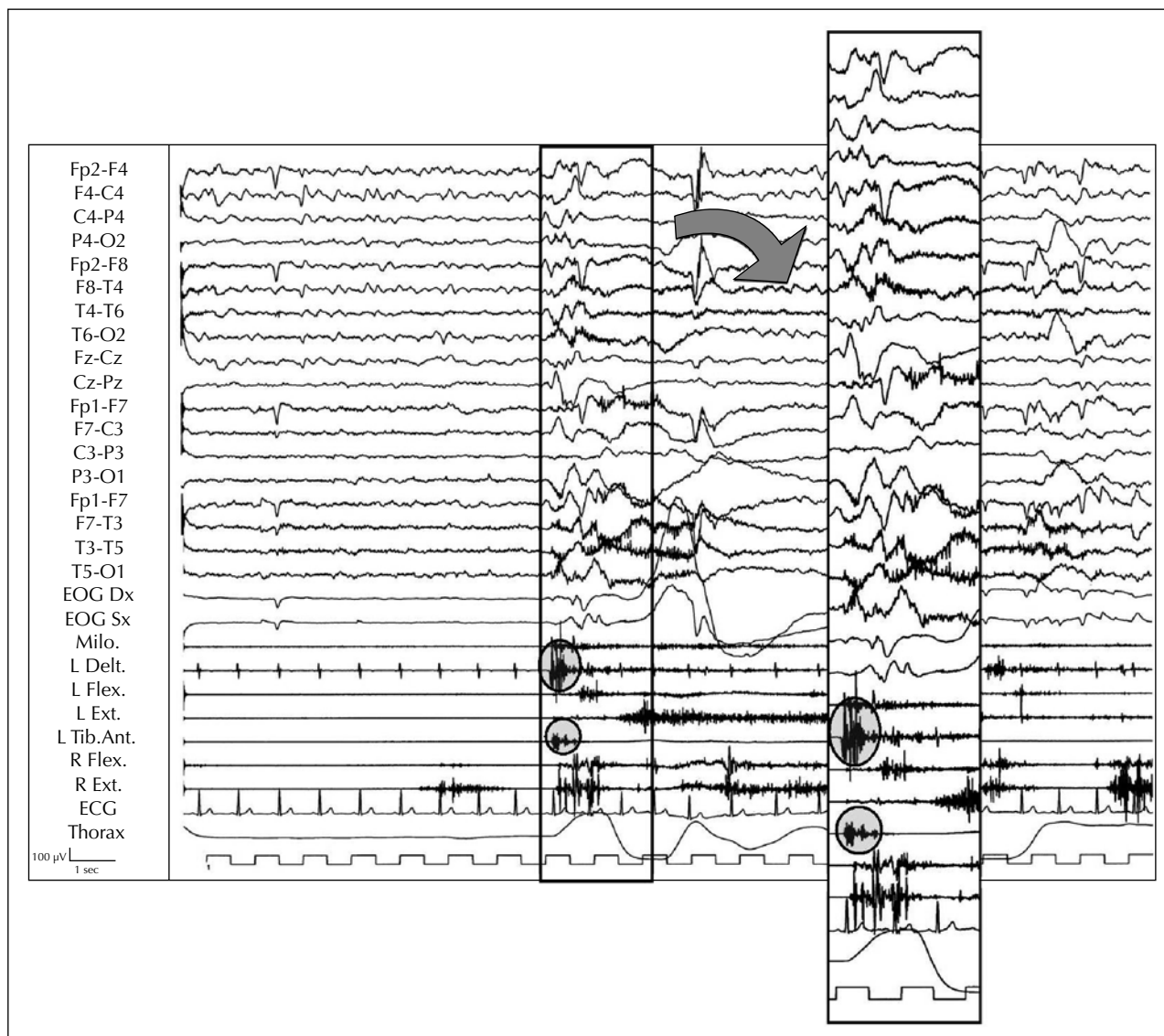


Figure 4. A shorter spasm (< 1 second) in patient 2. The ictal EEG showed a slow wave complex followed by fast activity on right regions with a minor concomitant muscle activation, in crescendo-decrescendo, on the left deltoid and tibialis anterior. L. Delt.: left deltoid muscle. R., L. Flex.: right and left flexor muscles of the hand. R., L. Ext.: right and left extensor muscles of the hand. L. Tib. Ant.: left muscle tibialis anterior.

ies point to an epileptogenic focus in the postcentral gyrus, frequently with evidence of a structural cortical lesion in the suprasylvian region. The physical features and the type of food seem to be important in triggering this form of eating epilepsy; in contrast, the temporal type of eating epilepsy is more dependent on the context of a meal.

In our first patient, the origin of the reflex periodic spasms was peri-rolandic suprasylvian because he had focal epilepsy associated with cortical malformation. The coexistence of a cortical malformation (bilateral opercular dysplasia) and eating epilepsy in our case was not coincidental. In fact, in the opercular type of eating epilepsy, electroclinical studies point to an epileptogenic

focus in the postcentral gyrus, which is identical with the malformed gyri in the opercular regions. These features show that the association of bilateral opercular dysplasia with eating epilepsy was not fortuitous, and that cortical malformation, and especially bilateral opercular dysplasia, is a distinct aetiology among those that underlie eating epilepsy. □

References

Camfield P, Camfield C, Lortie A, et al. Infantile spasms in remission may reemerge as intractable epileptic spasms. *Epilepsia* 2003; 44: 1592-5.

- Cerullo A, Marini C, Carcangiu R, *et al.* Clinical and video-polygraphic features of epileptic spasms in adults with cortical migration disorders. *Epileptic Disord* 1999; 1: 27-33.
- Commission on Classification and Terminology of the International League Against Epilepsy. Proposal for classification of epilepsies and epileptic syndrome. *Epilepsia* 1985; 26: 268-78.
- Commission on Classification and Terminology of the International League Against Epilepsy. Proposal for revised classification of epilepsies and epileptic syndrome. *Epilepsia* 1989; 30: 389-99.
- Commission on Pediatric Epilepsy of the International League Against Epilepsy. Workshop on infantile spasms. *Epilepsia* 1992; 33:195.
- Fusco L, Vigevano F. Ictal clinical electroencephalographic findings of spasms in West syndrome. *Epilepsia* 1993; 34: 671-8.
- Gobbi G, Bruno L, Pini A, *et al.* Periodic spasms: an unclassified type of epileptic seizure in childhood. *Dev Med Child Neurol* 1987; 29: 766-75.
- Kellaway P, Hrachovy RA, Frost JD, *et al.* Precise characterization and quantification of infantile spasms. *Ann Neurol* 1979; 6: 214-8.
- Kobayashi K, Ohtsuka Y, Ohno S, *et al.* Clinical spectrum of epileptic spasms associated with cortical malformation. *Neuropediatrics* 2001; 32: 236-44.
- Labate A, Colosimo E, Gambardella A, *et al.* Reflex periodic spasms induced by eating. *Brain Dev* 2006; 28: 170-4.
- Loiseau P, Guyot M, Loiseau H, *et al.* Eating seizures. *Epilepsia* 1986; 27: 161-3.
- Luders H, Acharya J, *et al.* Semiological seizure classification. *Epilepsia* 1998; 39: 1006-13.
- Lux AL, Osborne JP. A proposal for case definitions and outcome measures in studies of infantile spasms and West syndrome: consensus statement of the West Delphi group. *Epilepsia* 2004; 45: 1416-28.
- Maton B, Picard F, Njamshi A, *et al.* Encephalopathy with epileptic spasms resolved with corticoids in a 69-year-old patient. *Epileptic Disord* 2000; 2: 123-5.
- Remillard GM, Zifkin BG, Andermann F. Seizures induced by eating. In: Zifkin BG, Andermann F, Beaumanoir A, *et al.*, eds. *Reflex Epilepsies and Reflex Seizures: Advances in Neurology*, vol. 75. Philadelphia: Lippincot-Raven Publishers, 1998: 227-40.
- Sotero de Menezes MA, Rho JM. Clinical and electrographic features of epileptic spasms persisting beyond the second year of life. *Epilepsia* 2002; 43: 623-30.
- Talwar D, Baldwin MA, Hutzler R, *et al.* Epileptic spasms in older children: persistence beyond infancy. *Epilepsia* 1991; 32: 504-9.
- Wong M, Trevathan E. Infantile spasms. *Pediatr Neurol* 2001; 24: 89-98.