

The use of single bipolar scalp derivation for the detection of ictal events during long-term EEG monitoring

Frank C Bennis^{1,2,3}, Evelien E Geertsema¹,
Demetrios N Velis^{1,4,5}, Elise EM Reus¹, Gerhard H Visser¹

¹ Stichting Epilepsie Instellingen Nederland (SEIN), Heemstede

² University of Twente, MIRA-Institute for Biomedical Technology and Technical Medicine, Enschede

³ Present address: Department of Biomedical Engineering, Maastricht University, Maastricht

⁴ Academic Neurosurgical Center Amsterdam, Free University Medical Center - VUmc Campus, Amsterdam

⁵ Present address: Department of Neurology, Clinical Neurophysiology and MEG, VU University Medical Center, Amsterdam, The Netherlands

Received March 24, 2017; Accepted May 23, 2017

ABSTRACT – *Aim.* Epilepsy is difficult to diagnose using routine EEG recordings of short duration in patients who have low seizure frequency. Long-term EEG may be useful but is impractical in an out-of-hospital setting. We investigated whether single-channel scalp EEG placed behind the ear-lobe is suitable for seizure identification during prolonged EEG monitoring. *Methods.* Scalp EEG samples were selected from subjects over 15 years of age, and comprised two segments of either background followed by seizure or background followed by background. Bipolar EEG derivations in three directions (F8-T8, C4-T8 and T8-P8) were evaluated for the presence of a seizure by two experienced reviewers. For each EEG segment containing a seizure, one pair of electrodes was oriented towards the suspected region of seizure onset, while two pairs of electrodes were oriented elsewhere. *Results.* The EEG data contained five frontally localized seizures, five parietal, five temporal, two occipital, and four primary or secondary generalized seizures. The sensitivity and specificity for recognition of seizures was 86% and 95% for Reviewer 1, and 79% and 99% for Reviewer 2, respectively. When identifying a seizure with the lead orientation towards the region of seizure onset, both reviewers identified 20 out of 21 seizures (95%). When the lead was not oriented towards the region of seizure onset, the reviewers identified 34 and 30 out of 42 ictal records correctly, respectively. *Conclusions.* These results suggest that it is possible to identify epileptic seizures by bipolar EEG derivation using only two scalp electrodes. Lead orientation towards the suspected region of seizure onset is important for optimal detection sensitivity.

Key words: single bipolar scalp EEG, lead orientation, long-term EEG monitoring, epilepsy

Correspondence:

Evelien E. Geertsema
Stichting Epilepsie Instellingen Nederland (SEIN), Location “Meer & Bosch”,
Research Department, P.O. Box 540,
2130 AM Hoofddorp, The Netherlands
<egeertsema@sein.nl>

Epilepsy is a common disorder with an incidence of 50 per 100,000 and a prevalence of around 10 per 1,000 people in developed countries, which has a high impact on individuals' lives (Sander, 2003). Scalp EEG is a non-invasive technique that is particularly useful to support the diagnosis of epilepsy, establish the type of epileptic seizures, and classify some specific epilepsy syndromes. Indirectly, by improving the diagnostic yield of ancillary investigations, it also contributes to the appropriate management of epilepsies (Angeles, 1981).

To investigate the presence or absence of epileptiform activity, the first step is to record a relatively short EEG (30-60 minutes). With repeated measurements and appropriate stimulation, such as hyperventilation, visual stimulation and sleep deprivation, a maximum sensitivity of 80-90% for interictal epileptiform abnormalities can be reached using scalp EEG (Pillai and Sperling, 2006). This means that for at least 10% of individuals, it is not possible to provide evidence supporting a diagnosis of epilepsy based on standard EEG workup. The next step is to try to record a seizure event. With a relatively high seizure occurrence, a 24-hour or multiple-day recording might be appropriate, however, with a lower seizure frequency, even longer EEG recordings are required.

Long-term EEG monitoring is performed in settings such as intensive care units and epilepsy monitoring units (Tatum, 2001), usually with 21 electrode positions according to the international 10-20 system (Klem *et al.*, 1999). Long-term monitoring with a reduced montage or single-channel EEG is also possible and has been used mostly in neonates (Tekgul *et al.*, 2005; Shellhaas and Clancy, 2007). These methods, however, use scalp surface or needle electrodes which have limited lifespans of several days at the most. A reduced electrode set with a greater lifespan would be more practical for monitoring for a prolonged time, enabling ambulatory EEG recording. As the device would need to be small, easily placed, and preferably unobtrusive, we suggest using two electrodes worn closely behind or next to the ear, such as T7 and T8 of the international 10-10 EEG system of EEG sensor placement, measured using a single bipolar montage. An implanted device for the prediction of seizure likelihood in people with epilepsy (Cook *et al.*, 2013) is also possible and may perhaps be the next step. It is unclear, however, whether the sensitivity and specificity of detection of seizure activity using a single bipolar derivation is good enough for practical and reliable use for epilepsy diagnostic purposes. If a single bipolar derivation is sensitive enough, diagnostic EEGs could be recorded over many weeks or even months, comparable to long-term diagnostic monitoring for paroxysmal cardiac dysrhythmias.

In the present study, we aimed to investigate the feasibility of a single bipolar derivation of scalp EEG for the recognition of epileptic seizure activity. We also assessed whether recognition of seizure activity can be improved by preselection of the electrode position directed towards the brain area where ictal activity is most likely, based on the clinical history of ictal events, which may increase the feasibility of using this technique.

Materials and methods

Data collection

Scalp EEGs measured for presurgical evaluation over five days, diagnostic 24-hour EEGs, or standard EEGs were selected from our clinical database. All EEGs were sampled with a frequency of 256 Hz using Micromed's Systemplus Evolution v1.04.135 (Micromed SpA, Mogliano Veneto, Italy). In the original EEG recordings, Ag/AgCl scalp electrodes were positioned according to the international 10-20 system, often with additional electrodes according to the 10% system; therefore, we used the nomenclature of the 10% system.

EEG reports from an experienced clinical neurophysiologist were used to select EEGs with or without seizures. For EEGs with seizures, the type, lateralization, and location of the seizure was noted. EEG markers for the start and end of the seizure were checked for appropriate positioning.

We aimed to obtain 25 EEG segments containing a seizure and 25 EEG segments without seizures, each from different individuals. Segment length was limited by availability, as the database contained mainly short EEG segments. A 1-2.5-minute segment length was considered long enough to contain sufficient information for seizure detection; the short length also reduced the workload for the two reviewers. All segments were selected from different individuals aged over 15 years. This offered the advantage that, by excluding younger individuals, a more homogenous group, both in terms of background EEG and ictal pattern, was obtained.

From each selected EEG segment, the signals from different electrode positions (F8-T8, C4-T8 and T8-P8, and the corresponding left-sided positions) were extracted. As each bipolar derivation included the electrode position T8, the difference between these derivations can be considered as a difference in orientation, since each electrode configuration represents the potential of an area with a common electrode position (T8). The montages F8-T8, C4-T8 and T8-P8 (and corresponding left-sided positions) represent the device lead to frontal, central, and posterior temporal

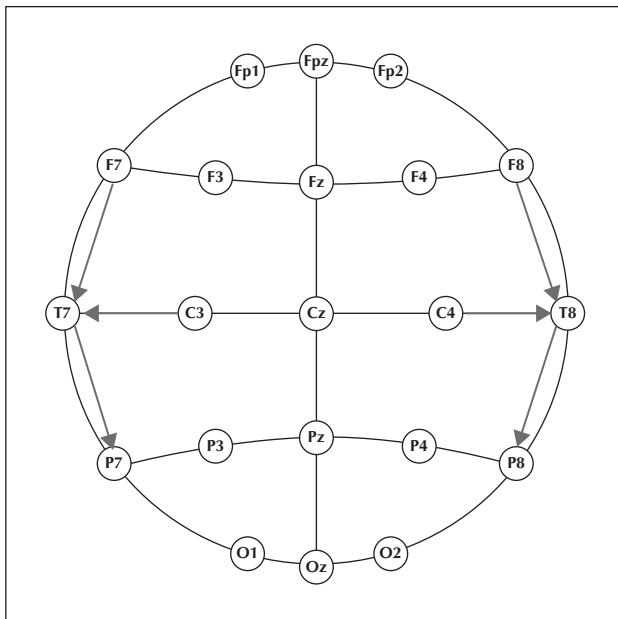


Figure 1. Orientation and position of the bipolar EEG derivations which were used, according to standard scalp EEG derivation of the international 10-20 system. The bipolar leads that were used are shown with arrows: F8-T8, C4-T8 and T8-P8 on the right and their counterparts on the left side of the scalp.

areas, respectively. Thus, the influence of lead orientation on seizure detection could be investigated. The orientation of the channels on the scalp is presented in *figure 1*. For the EEG segments containing a seizure, the derivations were selected ipsilateral to the hemisphere of seizure onset on the basis of the report of the full EEG recording. For the EEG segments without a seizure, lateralization was chosen randomly. No special care was taken to remove or avoid artefacts, in order to represent the real-life setting. No additional filtering was applied. An example of an EEG segment included in the dataset is presented in *figure 2*.

EEG samples with seizures

We grouped seizures corresponding to frontal, temporal, parietal, occipital seizure onset zones and seizures that were primary or secondary generalized in order to investigate the influence of channel selection with respect to seizure onset localization. Each group consisted of a maximum of five seizures.

Each EEG sample consisted of two segments; a background segment without seizure activity, followed by a segment with a seizure. Both segments originated from the same individual. The background segment served as a control for the EEG segment with a seizure. Because of the retrospective nature of this study, it was not always possible to select the background segment

immediately before the seizure. Control background segments ranged from one to two minutes, similar to the length of segments with seizures.

EEG samples without seizures

EEG segments without a seizure were selected from individuals, independent of the diagnosis. These were preceded by a control segment, ranging from one to two minutes long.

Review of EEG samples

Data was reviewed offline using MATLAB (Mathworks, Natick, MA USA, version 8.2.0.701). The EEG signals obtained from three bipolar derivations were reviewed independently and separately by a clinical neurophysiologist and a physician's assistant-in-training. The reviewers were blinded to any demographic or clinical information and to the time when the recordings were made.

Having reviewed one segment, reviewers were blinded to the segments from the same individual in other orientations. The reviewers used a custom EEG visual review and scoring program, presented in *figure 2*. This program shows a randomly selected segment from a randomly selected individual. A marker shows where the control segment stops and the segment with a possible seizure starts. Reviewers were able to change the high- and low-pass filters, amplitude gain, time basis, and part of data plotted. Reviewers indicated whether a seizure was present at the end of the control segment, after which a different segment was shown and scored. This was continued until all EEG segments from all individuals were scored.

Data analysis

The sensitivity and specificity of identification of seizure occurrence were used to evaluate the performance of our method in practice. Sensitivity was defined as the percentage of true seizures that were recognized, and specificity as the percentage of non-seizure segments recognized. Inter-observer variability was evaluated using Cohen's kappa score.

Results

A total of 46 EEG epochs were selected, of which 21 contained a seizure and 25 were without seizure activity. The EEG data contained five frontally localized seizures, five parietal, five temporal, two occipital, and four primary or secondary generalized seizures. We were unable to find 25 segments with seizures as too few suitable EEG epochs for occipital and

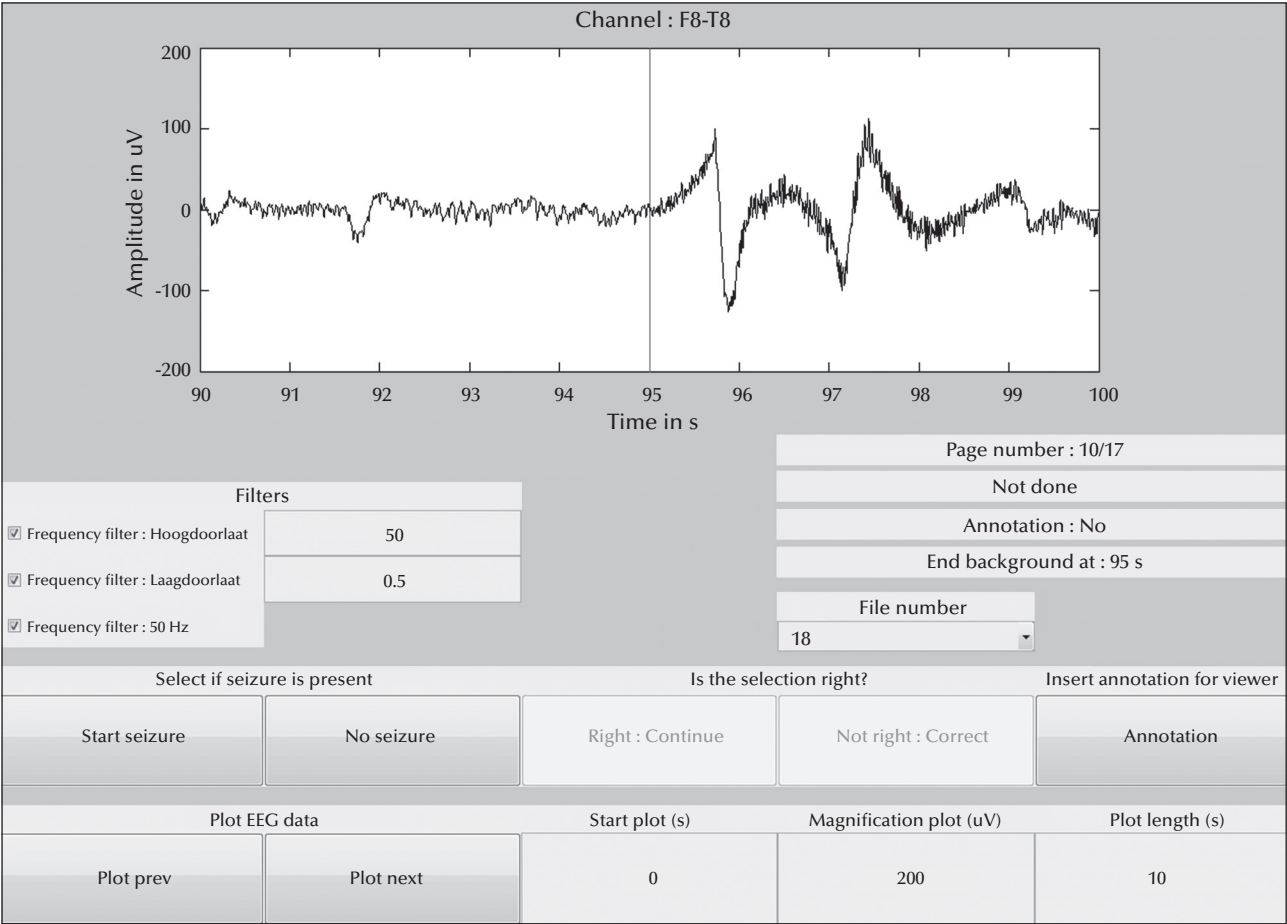


Figure 2. Illustration of the custom program which was used to review and score the EEG samples. One bipolar derivation is presented, in this case F8-T8, with the transition from control (interictal) EEG segment to a segment possibly containing a seizure, marked by a vertical line. Filters, the proportion plotted, the start of the plot, magnification (amplitude), and plot length (time base) could be adjusted by the reviewer for a detailed view.

generalized seizures were available. As three channels were extracted from each epoch, there were 138 segments to evaluate; seizure activity was present in 63 segments but absent in 75 segments. Reviewer 1 obtained a sensitivity of 86% and a specificity of 95%; 13 segments were wrongly classified, of which four were false positive and nine false negative. The wrongly classified EEGs for both Reviewer 1 and 2 are shown in *table 1*. The 13 misclassified segments for Reviewer 1 were recorded from 10 different individuals. The EEG was wrongly classified in one individual in all three channels, in one individual in two channels (both channels not directed towards the seizure onset zone), and in eight individuals in one channel. The number of correct classifications for EEG segments with a seizure, with respect to the location of the seizure onset zone and the direction of the electrodes, are shown in *table 2* for both Reviewer 1 and 2. Regarding the signals obtained from the leads

oriented towards the seizure onset zone, 20 out of 21 seizures (95%) were recognized. Regarding the signals obtained from leads not oriented towards the seizure onset zone, Reviewer 1 correctly classified the segment as containing a seizure in 81% of the cases. This indicates an increase of 14% in the yield of recognized seizures for Reviewer 1 when the lead was oriented towards the seizure onset zone. Reviewer 2 misclassified 14 segments, of which one was a false positive and 13 were false negative. This corresponds to a sensitivity of 79% and a specificity of 99%. The EEG was wrongly classified in one individual in all three segments, in four individuals in two segments (for all four individuals this occurred for signals obtained from leads not directed towards the seizure onset zone), and in three individuals in one signal. Regarding channels directed towards the seizure onset zone, 20 out of 21 seizures (95%) were recognized. Regarding the two channels not directed towards the

Table 1. Patients whose EEG samples were misclassified by Reviewer 1 or Reviewer 2, together with seizure onset zone, if present, and the lead orientation for the segment in which the misclassification was made. No seizure onset zone (None) corresponds to an EEG segment without seizure. Occipital corresponds to channel T8-P8, parietal to C4-T8, and frontal to F8-T8.

Pt no.	Seizure onset zone	Lead orientation Reviewer 1	Lead orientation Reviewer 2
5	Frontal	Posterior Temporal	Posterior Temporal, Central, Frontal
6	Frontal	-	Posterior Temporal
7	Occipital	-	Frontal
8	Fronto-temporal	Posterior Temporal, Central, Frontal	Posterior Temporal, Central
13	Parietal	Frontal	Posterior Temporal, Frontal
15	Parietal	Frontal	-
16	Parietal	Posterior Temporal, Frontal	Posterior Temporal, Frontal
17	Occipital	Central	Central, Frontal
28	None	Posterior Temporal	-
32	None	Posterior Temporal	-
34	None	Posterior Temporal	-
42	None	-	Central
45	None	Posterior Temporal	-

Table 2. Correctly classified EEG segments by Reviewer 1 and Reviewer 2 when a seizure was present. The score is presented using all three channels, using the channel directed towards the seizure onset zone, and using the channels not directed towards the seizure onset zone. Scores are presented according to different seizure onset zones.

Location of correctly classified seizure segments					
	Occipital	Temporal	Parietal	Frontal	Generalized
<i>All channels (%)</i>					
Reviewer 1	5/6 (83%)	15/15 (100%)	11/15 (73%)	11/15 (73%)	12/12 (100%)
Reviewer 2	3/6 (50%)	15/15 (100%)	11/15 (73%)	9/15 (60%)	12/12 (100%)
<i>Channel oriented towards seizure onset zone (%)</i>					
Reviewer 1	2/2 (100%)	5/5 (100%)	5/5 (100%)	4/5 (80%)	4/4 (100%)
Reviewer 2	2/2 (100%)	5/5 (100%)	5/5 (100%)	4/5 (80%)	4/4 (100%)
<i>Channel not oriented towards seizure onset zone (%)</i>					
Reviewer 1	3/4 (75%)	10/10 (100%)	6/10 (60%)	7/10 (70%)	8/8 (100%)
Reviewer 2	1/4 (25%)	10/10 (100%)	6/10 (60%)	5/10 (50%)	8/8 (100%)

seizure onset zone, Reviewer 2 correctly classified the segment containing a seizure in 71% of the cases. This indicates an increase of 24% in the yield of recognized seizures for Reviewer 2 when the lead was directed towards the seizure onset zone.

The inter-observer variability measured by Cohen's kappa score was 0.81, which is in line with reported inter-observer variation of EEG reviewing (Stroink *et al.*, 2006).

Discussion

Our results suggest that most epileptic seizures from different areas in the brain can be identified and thus detected on EEG using only a single bipolar derivation. This conclusion is supported by a sensitivity of 86% and 79% and specificity of 95% and 99% for the two reviewers in this study.

Lead orientation is also important for recognizing epileptic seizures and care should be taken to place the two electrodes with respect to the expected seizure onset zone. This is shown firstly by the increase in yield in seizure recognition for both reviewers when the lead is oriented towards the seizure onset zone. Secondly, additional evidence for this is found concerning the lead orientation in misclassified segments. For a number of segments with seizures, in which both leads were not pointing towards the seizure onset zone, the EEG was misinterpreted. Conversely, for segments in which the lead oriented towards the seizure onset zone, the EEG was correctly interpreted. Thirdly, seizures with a temporal seizure onset zone or seizures with primary or secondary generalization were classified correctly for all channels. As the electrodes T8 and T7 (for right and left lateralization, respectively) were common to each bipolar derivation and generalized seizures appeared in each brain area, it follows that these seizures were detected in all channels. However, seizures in different areas, such as frontal lobe seizures, may be harder to classify even on full scalp EEG, and this would be particularly challenging using this placement of electrodes. This underlines the importance of the orientation of the EEG leads with regards to the seizure onset zone and the need for careful placement of the electrodes with respect to the expected seizure onset zone.

It is, however, important to note that it is not always possible to correctly predict the location and lateralization of the seizure onset zone, despite the documentation of localizing and lateralizing features in the literature (Foldv ry-Schaefer and Unnwongse, 2011). This is especially the case when the clinical description of the seizure is vague. A corresponding sensitivity of 79% or 86% would be low for clinical purposes and it should be noted that this method may

be currently best used for those for whom seizure location is known or strongly suspected and may be complementary to current methods. For example, Rubin *et al.* found that a reduced EEG electrode array, compared to a 10-20 array, exhibited a sensitivity of 70% and a specificity of 96%, which was deemed insufficient for seizure detection (Rubin *et al.*, 2014). This is emphasized by the results of our study which show that for false lateralization of an occipital focus, sensitivity may drop to 25% when electrode placement is not oriented correctly. In the case of frontal and parietal seizures, anamnesis-based placement of electrodes can be challenging. Incorrectly oriented electrode placement may lead to a drop in sensitivity to 60% for true parietal seizures and from 50% to 70% for true frontal seizures. Thus, the aim of this approach was to provide complementary information for clinical evaluation rather than using it to replace standard procedures.

It is possible that the high level of specificity is due to data selection bias. In our clinical practice at the EEG recording site, only EEG records of clinically relevant events and an artefact-free segment of background (serving as a control) are archived; the rest of the data is discarded. Although seizures are recorded regardless of artefacts, and therefore unaltered, background EEG does not contain many artefacts. As a result of this, the non-epileptic EEG segments may contain fewer artefacts than an actual ambulatory EEG measurement and can therefore be easier to interpret, leading to high specificity for interictal epochs. However, multiple interictal and ictal EEG segments with artefacts were included in the present study and were correctly classified as such. Therefore, specificity is likely to be affected by data selection, but not to a great extent. On the other hand, the sensitivity is less likely to be affected by data selection bias, as seizures are archived irrespective of whether or not they contain artefacts.

In this study, the feasibility of seizure identification was investigated using 21 segments that contained a seizure and 25 segments without seizures. This ratio of ictal to normal EEG segments is clearly much higher than in real-life situations, as most EEG segments do not contain a seizure. Thus, this difference in ratio of ictal to normal EEG segments may have affected sensitivity and specificity, and usage of a dataset with a realistic ictal to normal EEG segment ratio is therefore recommended in further studies. Furthermore, in this study we reviewed short EEG segments, whereas the proposed application would be used to provide data sets corresponding to continuous ambulatory periods of long duration, which may lead to different outcomes. Ambulatory measurements with one-channel EEG recordings are necessary to evaluate the feasibility of this method for longer ambulatory data sets.

We emphasize that while this study takes the seizure onset zone into account, this does not mean that the

seizure is necessarily restricted to this area. Moreover, localization of onset was not the aim of the one-channel diagnostic device; the primary aim is seizure detection, in general, in order to support a possible diagnosis of epilepsy in patients with very low seizure occurrence. Seizures that remain focal and do not spread to the area of detection by the electrodes will not be identified; conversely, any seizure that begins or spreads to the electrode uptake area can be detected. In our study, it appears that a relatively large number of seizures demonstrated sufficient spread and a relatively good overall detection range was obtained.

Another benefit for long-term single-channel scalp EEG is surveillance for diagnosed and treated individuals with frequent seizures. The technique could be used, for example, to monitor the effect of treatment on reducing seizures. With this as a goal, seizure localization would likely be known, which would allow for correctly oriented electrode placement. For those with generalized seizures, however, the localization of electrodes is not important. To establish the most important channel during seizures and optimise orientation, it may also be possible to use a previously recorded ictal EEG (Duun-Henriksen *et al.*, 2012). In combination with automatic seizure recognition, this procedure may enable health care professionals to intervene in the event of a seizure without constant manual surveillance.

Future studies should investigate correct positioning and orientation of electrodes based on clinical descriptions of seizure-like symptoms. A larger cohort with suspected seizures should be included in any further studies to encompass a broad spectrum of seizures. Future studies to establish the diagnostic benefit of single-channel EEG will, however, for the moment, depend on standard EEG as a reference.

This study evaluated the possibility of identifying epileptic seizure occurrences using a single bipolar scalp EEG derivation, paving the way for long-term EEG monitoring using a single subcutaneous set of electrodes. We found that it is possible to recognize epileptic seizures from different areas in the brain using one EEG channel. Seizures were most often recognized in the EEG channel oriented towards the seizure onset zone, showing that both orientation and position of the leads are important. When used for identification of seizure occurrence in a clinical setting, the most likely seizure onset zone should be taken into account when placing the electrodes.

Supplementary data.

Summary didactic slides are available on the www.epilepticdisorders.com website.

Acknowledgements and disclosures.

This research was not funded by a specific grant from any funding agency in the public, commercial, or not-for-profit sectors. The authors have no conflict of interest to disclose.

References

- Angeles DKF. Proposal for revised clinical and electroencephalographic classification of epileptic seizures. *Epilepsia* 1981; 22(4): 489-501.
- Cook MJ, O'Brien TJ, Berkovic SF, *et al.* Prediction of seizure likelihood with a long-term, implanted seizure advisory system in patients with drug-resistant epilepsy: a first-in-man study. *Lancet Neurol* 2013; 12(6): 563-71.
- Duun-Henriksen J, Kjaer TW, Madsen RE, Remvig LS, Thomsen CE, Sorensen HB. Channel selection for automatic seizure detection. *Clin Neurophysiol* 2012; 123(1): 84-92.
- Foldvary-Schaefer N, Unnwongse K. Localizing and lateralizing features of auras and seizures. *Epilepsy Behav* 2011; 20(2): 160-6.
- Klem GH, Luders HO, Jasper HH, Elger C. The ten-twenty electrode system of the International Federation. *Electroencephalogr Clin Neurophysiol* 1999; 52: 3-6.
- Pillai J, Sperling MR. Interictal EEG and the diagnosis of epilepsy. *Epilepsia* 2006; 47(1): 14-22.
- Rubin MN, Jeffery OJ, Fugate JE, *et al.* Efficacy of a reduced electroencephalography electrode array for detection of seizures. *Neurohospitalist* 2014; 4(1): 6-8.
- Sander JW. The epidemiology of epilepsy revisited. *Curr Opin Neurol* 2003; 16(2): 165-70.
- Shellhaas RA, Clancy RR. Characterization of neonatal seizures by conventional EEG and single-channel EEG. *Clin Neurophysiol* 2007; 118(10): 2156-61.
- Stroink H, Schimsheimer RJ, de Weerd AW, *et al.* Interobserver reliability of visual interpretation of electroencephalograms in children with newly diagnosed seizures. *Dev Med Child Neurol* 2006; 48(5): 374-7.
- Tatum WO. Long-term EEG monitoring: a clinical approach to electrophysiology. *J Clin Neurophysiol* 2001; 18(5): 442-55.
- Tekgul H, Bourgeois BF, Gauvreau K, Bergin AM. Electroencephalography in neonatal seizures: comparison of a reduced and a full 10/20 montage. *Pediatr Neurol* 2005; 32(3): 155-61.

TEST YOURSELF



- (1) What are the possible clinical indications for long-term monitoring with a single EEG channel?
- (2) Is it feasible to use single-channel EEG to detect the majority of epileptic seizures?
- (3) Can the detection of seizures with single-channel EEG be improved by positioning the electrodes based on clinical information regarding the most likely seizure onset zone?

Note: Reading the manuscript provides an answer to all questions. Correct answers may be accessed on the website, www.epilepticdisorders.com, under the section "The EpiCentre".