

The role of EEG in the diagnosis and classification of the epilepsy syndromes: a tool for clinical practice by the ILAE Neurophysiology Task Force (Part 1)*

Michalis Koutroumanidis¹, Alexis Arzimanoglou², Roberto Caraballo³, Sushma Goyal⁴, Anna Kaminska⁵, Pramote Laoprasert⁶, Hirokazu Oguni⁷, Guido Rubboli⁸, William Tatum⁹, Pierre Thomas¹⁰, Eugen Trinkla¹¹, Luca Vignatelli¹², Solomon L Moshé¹³

¹ GSTT, Clin Neurophysiology and Epilepsies, St Thomas' Hospital, London, UK

² University Hospitals of Lyon, Department of Clinical Epileptology, Sleep Disorders and Functional Neurology in Children, Lyon, France

³ Hospital J P Garrahan, Neurology, Capital Federal, Buenos Aires, Argentina

⁴ Evelina Hospital for children GSTT, Clinical Neurophysiology, London, UK

⁵ APHP, Hopital Necker-Enfants Malades, Department of Clinical Neurophysiology, Paris, France

⁶ Children's Hospital, Neurology, Aurora, Colorado, 80045, USA

⁷ Tokyo Women's Medical University, Department of Pediatrics, Shinjuku-ku, Tokyo, Japan

⁸ Danish Epilepsy Centre, Department of Neurology, Dianalund, Denmark

⁹ Mayo Clinic, Neurology, Jacksonville, Florida, USA

¹⁰ Hopital Pasteur, Neurology, Hôpital Pasteur 24C, Nice, France

¹¹ Paracelsus Medizinische Privatuniversität, Salzburg, Austria

¹² IRCCS Istituto delle Scienze Neurologiche di Bologna, Bologna, Italy

¹³ Albert Einstein College of Medicine, Neurology, Neuroscience, and Pediatrics, Bronx, New York, USA



FIGURES ONLINE

Correspondence:

Michalis Koutroumanidis
GSTT, Clin Neurophysiology and Epilepsies
St Thomas' Hospital, London, UK
<michael.koutroumanidis@gstt.nhs.uk>

ABSTRACT – Rational. The concept of epilepsy syndromes, introduced in 1989, was defined as “clusters of signs and symptoms customarily occurring together”. Definition of epilepsy syndromes based on electro-clinical features facilitated clinical practice and, whenever possible, clinical research in homogeneous groups of patients with epilepsies. Progress in the fields of neuroimaging and genetics made it rapidly clear that, although crucial,

*This report was written by experts selected by the International League Against Epilepsy (ILAE) and was approved for publication by the ILAE. Opinions expressed by the authors, however, do not necessarily represent the policy or position of the ILAE.

the electro-clinical description of epilepsy syndromes was not sufficient to allow much needed development of targeted therapies and a better understanding of the underlying pathophysiological mechanisms of seizures. The 2017 ILAE position paper on Classification of the Epilepsies recognized that “as a critical tool for the practicing clinician, epilepsy classification must be relevant and dynamic to changes in thinking”. The concept of “epilepsy syndromes” evolved, incorporating issues related to aetiologies and comorbidities. A comprehensive update (and revision where necessary) of the EEG diagnostic criteria in the light of the 2017 revised terminology and concepts was deemed necessary.

Methods. The work was commissioned by the Neurophysiology Task Force of the ILAE Committee on the Diagnostic Methods. Diagnostic criteria and recording procedures were developed by group consensus, reached through an “informal”, internal decision-making process. Each working group member was allocated a number of syndromes, and a standard structured template was used. International literature was extensively reviewed.

Results. We developed a simple diagnostic system that is applicable to all epilepsy syndromes which allows the physician (i) to rate the strength of EEG diagnosis (degree of diagnostic certainty) by weighting EEG findings in relation to the *available* clinical information or the *specific* clinical question, and ii) to suggest further EEG diagnostics where conclusive diagnostic evidence is lacking. We also propose a system of syndrome-specific recording protocols that, used with the relevant clinical presentation or specific clinical question, may maximize activation of epileptic discharges and ultimately help with standardization of EEG recording across departments, worldwide. Because recording methodology also depends on available resources, a two-tier system was developed to embrace clinical EEG services in resource-limited and industrialized countries. A clinical practice statement for each of the epilepsy syndromes discussed underscores the crucial role of the clinical information with regards to both the optimization of the EEG recording and mainly its meaningful interpretation. Part I covers Genetic (Idiopathic) generalized epilepsies and syndromes, Reflex epilepsies, structural and genetic focal (lobar) syndromes and Progressive Myoclonus Epilepsies [Published with educational EEG plates on www.epilepticdisorders.com].

Key words: epilepsy syndromes, EEG and epilepsy diagnosis, EEG protocols

1. Introduction

The EEG is the most dependable “laboratory” investigation for epilepsy as it allows us to study its most relevant functional markers: the interictal and ictal epileptic discharges (ED). Furthermore, as certain clusters of abnormal graphoelements are strongly associated with (and sometimes specific to) distinct clinical epilepsy phenotypes, the EEG has been a decisive tool for the classification of seizures and epilepsies (Gastaut, 1970; Commission, 1981, 1985, 1989).

Our understanding of the epilepsies has progressed through clinical-EEG, imaging, genetic, and molecular biology research, and further approaches to classification have been attempted (Engel *et al.*, 2001; Engel, 2006), culminating with the latest ILAE position paper on revised terminology and concepts of seizures and epilepsies (Scheffer *et al.*, 2017). Despite substantial advances, the clinical and electroencephalographic

classification of epileptic seizures of 1981 marked the last official attempt of the ILAE to define EEG criteria, which are duly in keeping with the dichotomous approach of the 1981/1989 ILAE classification framework (Commission, 1981, 1985, 1989). A comprehensive update (and revision where necessary) of the EEG diagnostic criteria in the light of the revised terminology and concepts was deemed necessary and the work was commissioned by the Neurophysiology Task Force of the ILAE Committee on the Diagnostic Methods. A working group of EEG/clinical epileptology experts was formed to comprehensively cover the main paediatric and adult syndromes and epilepsies; Chair and Memberships were agreed after consultation with the ILAE Executive Committee (Liaison Prof Wiebe) and the ILAE Classification Committee (Liaison Prof Hirsch).

Abbreviations

ADNFLE: autosomal dominant frontal lobe epilepsy
ADPEAF: autosomal dominant partial epilepsy with auditory features
AED: antiepileptic drug
AM: action myoclonus
ASE: absence status epilepsy
BZD: benzodiazepines
CAE: childhood absence epilepsy
CAP: cyclical alternating pattern
CBM: carbamazepine
CLZ: clonazepam
DnASLO: *de novo* absence status of late onset
ED: epileptic discharges
ELMA: eyelid myoclonia with absences
E-PA: epilepsy with phantom absences
ESX: ethosuximide
fmTLE: familial mesial temporal lobe epilepsy
FOS: fixation-off sensitivity
FS: febrile seizures
GCTC: generalized clonic-tonic-clonic seizures
GGE: genetic generalized epilepsy
GPSWD: GSWD with a polyspike component
GSWD: generalized spike-wave discharge
GTCS: generalized tonic-clonic seizures
GTCSa: generalized tonic-clonic seizures alone
HFO: interictal high-frequency oscillations
HV: hyperventilation
IGE: idiopathic generalized epilepsy
IoC: impairment of consciousness
IPS: intermittent photic stimulation

JAE: juvenile absence epilepsy
JME: juvenile myoclonic epilepsy
LEV: levetiracetam
LTG: lamotrigine
MELAS: mitochondrial encephalomyopathy, lactic acidosis
MS: myoclonic seizures
mTLE: mesial temporal lobe epilepsy
MTS: mesial temporal sclerosis
NREM: non-rapid eye movement
nTLE: neo-cortical (lateral) temporal lobe epilepsy
OIRDA: occipital intermittent rhythmic delta activity
OLE: occipital lobe epilepsy
OPM: orbitofrontal photo myoclonus
PNES: psychogenic non-epileptic seizure
PPR: photoparoxysmal response
RBD: REM behavioural disorder
REM: rapid eye movement
SBS: secondary bilateral synchrony
SD: sleep deprivation
SDEEG: EEG after partial sleep deprivation
sec-GTC: secondary generalized tonic-clonic
SI: self-induction
SOZ: seizure onset zone
SSEPs: somatosensory evoked potentials
TA: typical absences
TIRDA: temporal interictal rhythmic delta activity
ULD: Unverricht-Lundborg disease
VG: video games
VPA: valproic acid

1.1 Aims

This report intends to propose:

– (1) A simple diagnostic system that is applicable to all epilepsy syndromes and could enable electroencephalographers:

- i) to rate the strength of EEG diagnosis (degree of diagnostic certainty) by weighting EEG findings in relation to the *available* clinical information or the *specific* clinical question;
- ii) to suggest further EEG diagnostics where conclusive diagnostic evidence is lacking.

It is anticipated that an effective and easy-to-use diagnostic rating system could also improve homogeneity in EEG interpretation and reporting.

The default rating system is organized at three levels of diagnostic certainty and explained below (*section 1.3*). The principles of the diagnostic EEG from the planning of the recording to its interpretation and reporting are fittingly discussed below in *section 1.4*.

– (2) A system of syndrome-specific recording protocols that, used in the relevant clinical presentation or the specific clinical question, may maximize

activation of ED and ultimately help with standardization of EEG recording across departments, worldwide. Because recording methodology also depends on available resources, a two-tier system was developed to embrace clinical EEG services in the resource-limited and the industrialized countries; the system is described in *section 1.5*.

The transition from the 1989 to the 2010-2017 terminology and concepts did not encounter significant difficulties because both clinical taxonomies are based on epilepsy syndromes. Particular concepts and terms that connote aetiology but are not directly adaptable to the 2010 proposal, such as that of “idiopathy”, are discussed in *section 1.6*.

It is very much hoped that this work becomes a useful educational tool for all EEG technologists and physicians who see people with epilepsy, report EEGs, or both, particularly outside tertiary epilepsy centres.

1.2 Methodology

Diagnostic criteria and recording procedures were developed by group consensus, reached through

“informal”, internal decision-making process (Fink et al., 1984; Qaseem et al., 2012). Each working group member was allocated a number of syndromes, and a standard structured template was used.

A formal systematic search was not performed. However, the literature was extensively reviewed (no restrictions regarding language or type of publication) and, to adhere to the practical and far-reaching educational character of this work, bibliography for each chapter is limited to a few most important recent and best accessible references and also to seminal papers describing the pertinent EEG characteristics of the syndromes, irrespective of their publication date. Widely accepted glossaries and guidelines, and working group consensus statements were taken into account (Chatrian et al., 1974; Noachtar et al., 1999; Blume et al., 2001; Flink et al., 2002), and EEG vocabulary was the same used by SCORE, the ILAE-endorsed computerized EEG reporting system (Beniczky et al., 2013); when deemed useful, additional adequately explained terms were used according to authors’ individual preferences.

Initial drafts of the chapters covering individual syndromes were discussed between smaller “paediatric” and “adult” groups and the chairperson. Interpretation of evidence, development of diagnostic certainty rating (including further diagnostics when evidence is lacking), and statements on recording protocols evolved for each syndrome through a series of iterations and critiques with any differences resolved by consensus.

The working group plans periodic revision and update of diagnostic criteria depending on new evidence and colleagues’ feedback.

1.3 Layout of the chapters-syndromes

A standard format was uniformly used, consisting of the following sections:

- **(1) Overview:** contains a short description of the syndrome or the epilepsy type, including its nosological co-ordinates.
- **(2) Seizures: symptoms and semiology:** provides a brief description of all associated seizure types and their important characteristics, including their relation to state of vigilance and other modulators and possible triggers. The section contains *essential* information for electroencephalographers to direct and interpret EEG recordings and for EEG technologists to collect important clinical data and to further develop their recording strategies (figure 1.01).
- **(3) EEG section:** contains pertinent information about **background** rhythms and the typical **interictal** and **ictal** paroxysmal findings in wakefulness and sleep, including the effects of possible activators and triggers. It also provides the rationale behind the proposed

recording protocols that follow. In some syndromes, a subsection of **atypical findings** contains EEG patterns that may be compatible with the class, in which the syndrome in question belongs, but are not suggestive of the particular syndrome.

– **(4) Recording protocols:** summarize the methodology and techniques that are more likely to activate ED and other EEG characteristics of the particular syndrome or epilepsy type to maximize diagnostic yield. This section aims to set up minimum recording standards and homogenize diagnostic EEG methodology across EEG departments, and to propose further diagnostic techniques and strategies depending on the available resources.

– **(5) Levels of EEG diagnosis:** the section essentially rates diagnostic confidence, assuming newly presented patients and available essential clinical information through sound medical referrals, data collection by the EEG technologist, or both. Because nowadays brain imaging may be available at the time of the recording, relevant information may be taken into account, particularly when focal syndromes and epilepsies are concerned.

Following successive rounds of internal deliberations and critiques, and a number of trials, diagnostic confidence for a particular working clinical hypothesis/question was simply, clearly and conveniently graded, from highest to lowest, into the following levels:

– **A) Confirmatory of clinical diagnosis.** The EEG contains: i) typical seizure(s); ii) typical interictal epileptic activity; iii) no atypical features.

– **B) High diagnostic certainty (probable).** No seizure is recorded, but the EEG contains: i) typical interictal epileptic activity; ii) no atypical features.

Note: In many syndromes levels A and B are essentially of similar diagnostic value. With the exception of mainly paediatric syndromes and epilepsies, which often manifest with frequent seizures or clusters of seizures (such as epileptic spasms), syndromes with typical absences (TA), and reflex epilepsies, a seizure is neither expected nor pursued during a waking or sleep EEG recording (for instance, in a patient with a working hypothesis of temporal lobe epilepsy and monthly seizures). In such cases, both levels A (when a temporal lobe seizure is recorded by chance) and B (unilateral temporal spikes) are sufficiently diagnostic.

– **C) Lower diagnostic certainty (possible).** When no seizure is recorded, but the EEG contains: i) typical interictal epileptic activity and ii) some atypical features. In this scenario, findings are diagnostic of the type (class) of epilepsy (for instance, genetic [idiopathic] generalized or structural focal), but not strictly suggestive of the particular syndrome in question. At this level of confidence, other possibilities within the given class of epilepsy remain open and further

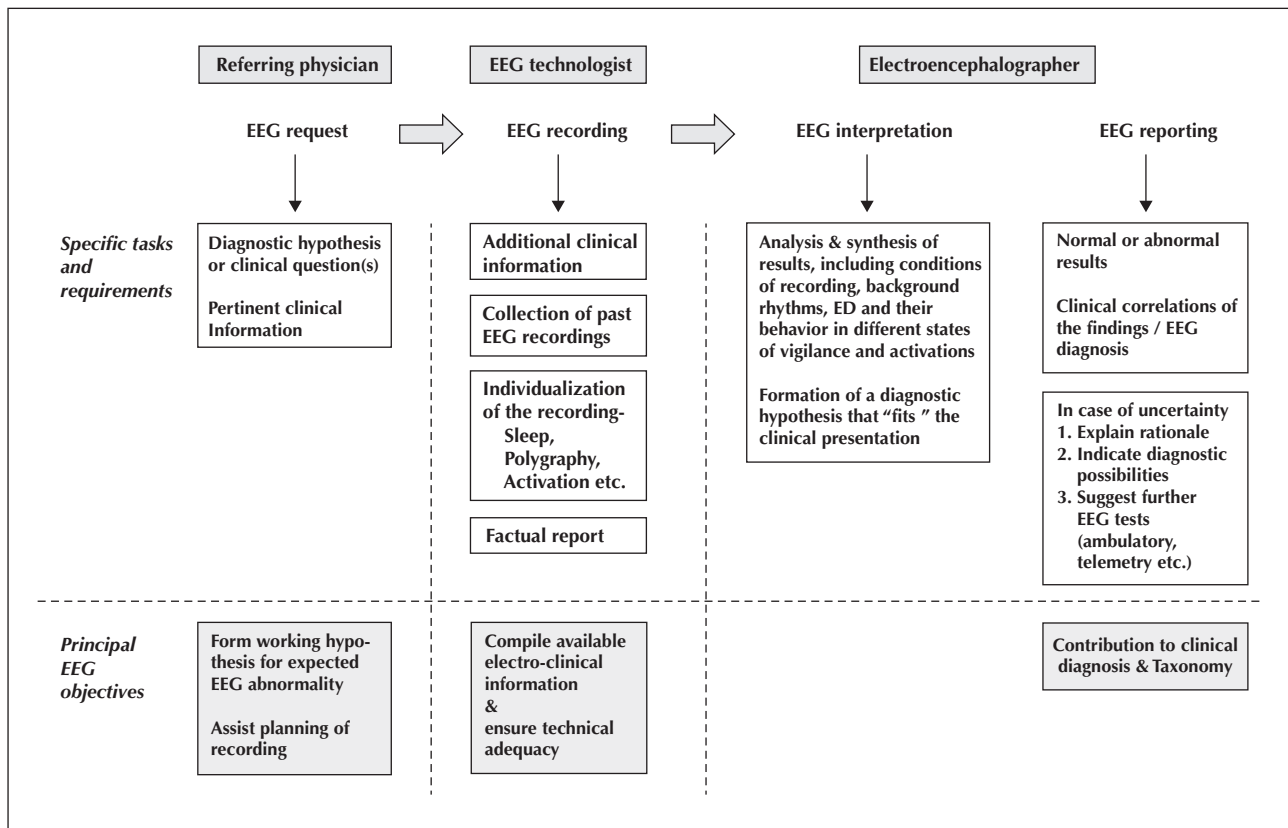


Figure 1.01. EEG diagnostic pathway; from the initial referral to the final report. The white boxes in the upper row show the main tasks and requirements in each stage of the orderly EEG process from the initial request to the final report to maximize its diagnostic contribution. For example, individualization of the recording relies on the completeness of the diagnostic hypothesis of the referring physician and the provided clinical information on the request form, but also on additional information obtained by the EEG technologist (see section 1.4 in the text). The grey boxes in the lower row show the main objectives of each stage of the EEG process, culminating in the important role of the EEG in clinical diagnosis and taxonomy.

diagnostic EEG strategies are recommended, depending on objectives (for instance possible presurgical evaluation) and available resources. This level is still clinically significant because it can guide treatment with specific antiepileptic agents, and is also important for clinical or epidemiological research.

Note 1: When the EEG findings are abnormal, but *different* to those expected from the referral, electroencephalographers need to inform referring physicians that findings do not support the working diagnosis/suspicion; instead, they may suggest a different class of epilepsy (for instance, focal instead of generalized), or the overall EEG/clinical evidence may be insufficient for confident classification.

Note 2: A normal EEG does not have the same meaning in all suspected syndromes. Although it does not exclude the diagnosis of most (Fowle and Binnie, 2000; Koutroumanidis and Smith, 2005), it *does* render unlikely the diagnosis of a few syndromes when the EEG recording is adequately performed, such as childhood absence epilepsy (CAE) in an untreated child with reported daily pyknoleptic "absences", who hyperventilated correctly during the EEG.

1.4 Overview of clinical EEG practice: from the initial request to the final report (figure 1.01)

Planning and recording the EEG

The occurrence and behaviour of diagnostic EEG graphoelements is dynamic, subject to a plethora of interplaying modulators that include the following: age of the patient, stage of the natural course of the given syndrome, time of day, state of arousal and sleep adequacy, antiepileptic and other medications, and possibly other environmental factors. The full EEG characterization of an epilepsy syndrome may not be possible from a standard "interictal" recording during wakefulness or even sleep; waking EEGs may show no ED in substantial numbers of people with known epilepsy (Pedley *et al.*, 2003; Pillai and Sperling, 2006), while sleep EEGs may recover ED in much higher numbers (Binnie and Stefan, 1999), particularly after sleep deprivation (SD) (Rowan *et al.*, 1982) and variably across epilepsy syndromes with the highest yield upon awakening in generalized epilepsies (Degen *et al.*, 1987). Moreover, the occurrence of defining ED or even seizures may depend on standard activation

(such as hyperventilation [HV] that can elicit generalized spike-wave discharges [GSWD] or absences) or specific activation (such as reading), the effect of which can be tested on suspicion under controlled conditions in the EEG laboratory. Therefore, EEG recordings can be “personalized” according to the diagnostic hypothesis and the available clinical information, maximizing diagnostic yield.

Despite some published guidance about the structure of the EEG referral (Noachtar *et al.*, 1999; Beniczky *et al.*, 2013), experience from both resource-limited (Birbeck *et al.*, 2011) and developed countries (Nicolaidis *et al.*, 1995; Smith *et al.*, 2001) indicates that EEG requests may not contain pertinent clinical information or a working hypothesis, while (not infrequently) the clinical question is misguided (“is it epilepsy?”/“rule out epilepsy”) (Fowle and Binnie, 2000; Koutroumanidis and Smith, 2005). Important information may be obtained during electrode application, when the EEG technologist (trained in basic epileptology) has ample time to discuss key clinical aspects, including seizure symptoms and semiology (as patients are frequently escorted), frequency, timing, and possible triggers with the view to test during the recording (*figure 1.01*).

The relevant information can be entered in a structured template, together with the standard personal and referral data, detailed recording conditions, and the factual report (*for a comprehensive list of entries, readers are referred to SCORE [Beniczky *et al.*, 2013]*).

Interpreting and reporting the EEG

EEG interpretation is based on expert visual analysis of the ED and other non-epileptiform abnormalities, including their response to activation and behaviour in different states of vigilance, and then their synthesis into a plausible diagnostic hypothesis, taking into account the available clinical information and possible previous EEG results. Early recordings can help, as robust patterns during childhood and adolescence may become subtle and ambiguous in adulthood.

The final clinical EEG report “translates” the EEG findings into clinically useful information and may suggest an epilepsy type or syndrome, implicitly with some reference to the possible aetiology and with varying degree of diagnostic certainty (*section 1.3.5*). Importantly, this business end of the EEG process also feeds taxonomy. The EEG report should be clear in content using common clinical terminology without special EEG terms (Noachtar *et al.*, 1999; Kaplan and Benbadis, 2013; Tatum *et al.*, 2016).

EEG interpretation is not always straightforward. In the process of EEG “reading”, simple and unequivocal in their clinical significance, but also complex and potentially ambiguous patterns of ED will have to be “rephrased” using standard widely accepted

terminology (Noachtar *et al.*, 1999; Beniczky *et al.*, 2013), or, if this is not possible, a finite gamut of EEG descriptors; both may have important semantic connotations. For example, a spike-and-wave discharge that occupies all scalp electrodes but has a regional lead-in can be interpreted as either focal with fast generalization (implying focal epileptogenesis), or as generalized with an incompletely generalized onset (suggesting genetically determined generalized epilepsy). Similarly, a lateralized spike-and-wave discharge that occupies several adjacent scalp electrodes can only be interpreted as either *regional* (Noachtar *et al.*, 1999), or as *incompletely generalized* (Browne *et al.*, 1974). Although the fundamental distinction between “focal” and “generalized” has been partially addressed (with respect to seizure onset) in the 2010 ILAE report (Berg *et al.*, 2010), EEG interpretation of phenomenologically ambiguous interictal ED remains unresolved. Therefore, this dichotomy is implicitly liable to subjective expert opinions that account for the moderate inter-observer agreement (van Donselaar *et al.*, 1992), potentially leading to double taxonomy standards.

When the available EEG evidence is insufficient for electroencephalographers to suggest a diagnosis without being overly subjective in their opinion, it is recommended that the rationale and the EEG evidence are fully explained in the report, all diagnostic possibilities are included and further testing is advised depending on the available resources (for instance, sleep or ambulatory EEG, video telemetry, etc.). Differentiation between genetic (idiopathic) generalized epilepsies and secondary bilateral synchrony (SBS) is a typical example of such limitations (*see relevant diagnostic criteria in section 2.2*). The roles of the referring physician, the EEG technologist, and the electroencephalographer in the optimal diagnostic clinical EEG process are summarized in *figure 1.01*. It is emphasized that the diagnostic and taxonomic value of the EEG report depends on the competence of each contribution. Although the roles and their weightings in the EEG process are different, each stage feeds the next and any deficiency in this flow will affect the clinical usefulness of the final report.

1.5 Levels of EEG recording

For best patient care and farthest reach, a comprehensive EEG recording-reporting methodological framework should be versatile and adaptable to the diverse levels of clinical EEG service worldwide, taking into account the available material and human resources, including the variable training and expertise of the clinicians who interpret EEG and the EEG technologists alike.

There is substantial variability in the provision of the EEG service worldwide, reflecting the large gap in the

epilepsy care between resource-limited countries and the industrialized countries of Europe, North America, and East Asia. In the former, mainly located in Latin America, Africa, Asia, and the Caribbean, epilepsy is not amongst the first public health priorities despite its high annual incidence that ranges from 92.7 to 190 per 100,000, mostly in relation to preventable parasitic and infectious diseases and under-resourced perinatal care (Carpio and Hauser, 2009); neurologists are very few and practice in major cities (Mani, 1998), referral services are frequently poor and people with epilepsy are often managed by primary-care physicians, or remain untreated (de Bittencourt *et al.*, 1996). EEG services are variably available in only three quarters of resource-poor countries (Dua *et al.*, 2006), operating without minimum standards by untrained laboratory technologists (Radhakrishnan, 2009; Birbeck *et al.*, 2011). Digital video-EEG equipment is scarce, usually concentrated in the private sector and only in major cities and hence inaccessible to the majority of the population (WHO, 2004, 2005; PAHO, 2011). When available in the public sector, waiting times may be extremely long (Caraballo and Fejerman, 2015) and brief recordings are common (Birbeck *et al.*, 2011). In Africa, although EEG services are becoming more available than neuroimaging (Wilmshurst *et al.*, 2011), EEG is still not routinely performed in patients hospitalized with convulsive epilepsy (Kariuki *et al.*, 2015a), physicians trained to basic EEG interpretation are few, and educational guidelines for the EEG interpretation are lacking (Kander and Wilmshurst, 2015). Well-conducted EEG studies on children and adults (Igwe *et al.*, 2014; Lagunju *et al.*, 2015; Kariuki *et al.*, 2015b) are still scarce and mostly concern routine recordings on patients with convulsive seizures. Electroclinical diagnosis primarily focuses on the distinction between focal and generalized epilepsy, pragmatically reflecting fundamental clinical needs.

Recording and reporting standards vary also amongst the industrialized countries of Europe, North America, and the Far East, where digital video-EEG is readily available. The proportion of abnormal EEGs may differ between hospital- and community-based samples (Binnie and Stefan, 2003), while training of technologists and recording protocols vary across EEG departments. In some district hospitals, EEGs may be reported by clinical neurophysiologists primarily interested in electromyography, while at epilepsy centres and university hospitals, inter-observer agreement may only be moderate (van Donselaar *et al.*, 1992).

We have pragmatically distinguished two levels of EEG recording, according to the available departmental facilities and material resources (including capability for lengthy and sleep recordings and specific activation, multiple channels, and availability

for polygraphy, synchronized video) and the skills and trained expertise of the EEG technologist: a) *basic*, suitable for most district general hospitals and for tertiary/university hospitals in resource-limited countries, and b) *advanced*, with the minimum requirements expected for tertiary epilepsy centres and university hospitals in developed countries (box 1). The requirements for the *basic* level may appear more complex and demanding than those currently employed by many EEG departments in district general hospitals, but our primary aim is to gradually raise the standards of practice at this level. It can be sensibly inferred that for the majority of the epilepsy syndromes, notwithstanding some differences in material resources, *basic* EEG may diagnostically offer almost as much as the *advanced* when recorded by skilled EEG technologists with appropriate training in epileptology (sections 1.1 and 1.4).

To provide EEG technologists/nurses with the rationale for the syndrome-specific recording protocols, we have included information about the behaviours of ED in different states of vigilance and their response to specific and non-specific activation.

1.6 EEG diagnostic and taxonomic criteria within the context of the revised terminology and concepts for the organization of seizures and epilepsies (Berg *et al.*, 2010; Scheffer *et al.*, 2017)

The purpose of the diagnostic process in epilepsies is twofold: i) to identify the full clinical semiology and define the epilepsy type or syndrome, and ii) to find the underlying cause. The EEG directly contributes to the clinical, but not to the aetiological diagnosis. A distinctive EEG pattern (such as a focal spike-wave) may transcend different aetiologies, while epilepsies within a given class of aetiology may have different EEG characteristics; for instance, CAE, Dravet syndrome and autosomal dominant nocturnal frontal lobe epilepsy are genetically determined and yet exhibit distinctively different EEG profiles.

To fulfil its diagnostic and taxonomic role within the new framework, the EEG and essentially its effective clinical contribution, the EEG report, should be in compliance with the new concepts, though ensuring that replacement of the 1989 concepts and terms will not impact on its clinical usefulness.

EEG and clinical classification

The syndrome approach remains the backbone of the clinical classification (Scheffer *et al.*, 2017) and the revision of the EEG criteria at this level needs no particular amendments *when officially recognized epilepsy syndromes are concerned*.

Box 1. The two levels of EEG recording.**A. Basic:**

HV and IPS (standard activating procedures).

Basic EMG polygraphy (unless channels are limited).

Digital machines and video (may be variably available in resource-limited countries).

Recording during sleep (when difficult to schedule, encourage drowsiness/light sleep, if possible).

B. Advanced:

HV, IPS, other specific activation, video, multichannel polygraphy.

Sleep EEG after partial (or 24-hour in some departments) sleep deprivation (SDEEG) or pharmaceutically-induced.

Prolonged daytime video or overnight recordings, video-telemetry, etc., as indicated.

Note that all recordings can be individualized according to clinical information/questions.

EEG and aetiological classification

The 2017 ILAE position paper (Scheffer *et al.* 2017) on Classification of the Epilepsies recognizes a range of aetiological groups, with emphasis on those that have implications for treatment: structural (in the presence of an MRI lesion), genetic, infectious, metabolic, and immune, as well as an unknown group. It also recognizes the fact that aetiologies are not mutually exclusive, a patient's epilepsy may be classified into more than one aetiological category; the aetiologies are not hierarchical, and the importance given to the patient's aetiological group may depend on the circumstance. For instance, a patient with tuberous sclerosis has both a structural and a genetic aetiology; the structural aetiology is critical for epilepsy surgery, whereas the genetic aetiology is key for genetic counselling and consideration of novel therapies such as mammalian target of rapamycin (mTOR) inhibitors.

The EEG *per se* may suggest a certain class of aetiology *only indirectly*; as a rule, such *suggestion* is *non-specific*, although some EEG patterns may imply that a certain aetiology is more likely than another, introducing a *degree of probability*. For instance, the combination of interictal spikes and slow wave activity over one temporal lobe in a patient with focal seizures suggests a structural cause, although it may also occur in the rare familial temporal lobe epilepsy (Crompton *et al.*, 2010). Similar EEG features also occur in patients without family history or an identifiable cause, as for instance, in those with normal imaging or non-specific histopathological findings and good seizure outcome after ipsilateral temporal lobectomy (Koutroumanidis *et al.*, 2004). In this example, the good one-to-one correlation between the 1989 and the 2017 aetiological taxonomies (structural vs. symptomatic, unknown vs. cryptogenic or probably symptomatic, and genetic) does not influence the clinical usefulness of the EEG report.

However, associations between the two aetiological taxonomies can be more complex when certain types of idiopathic generalized epilepsy (IGE) are concerned

with potentially significant clinical impact on the EEG report. While reporting on *officially recognized syndromes* of genetic generalized epilepsy (GGE), such as Childhood Absence Epilepsy (CAE), juvenile absence epilepsy (JAE), juvenile myoclonic epilepsy (JME), and epilepsy with generalized tonic-clonic seizures alone (GTCSa), communicates exactly the same clinical information in either taxonomy (see *EEG and clinical classification above*), there may be potentially significant pitfalls when patients with clinical phenotypes, previously understood within the spectrum of IGE, but *not officially recognized as distinctive syndromes* and therefore not currently featuring within the GGE, are concerned. Examples include the syndromes of eyelid myoclonia with absences (ELMA) (Jeavons, 1977), absence status epilepsy (ASE) (Genton *et al.*, 2008), epilepsy with phantom absences (E-PA) (Panayiotopoulos *et al.*, 1997), and also a number of unclassifiable clinical phenotypes (Valentin *et al.*, 2007). They all share with the recognized genetic generalized syndromes of CAE, JAE, JME, and GTCSa the characteristic GSWD, a genetic marker *par excellence*, and also defining seizure symptoms, such as TAs, but with little evidence of substantial genetic contribution to their aetiology (as in epilepsy with PA [Koutroumanidis *et al.*, 2008]) or no evidence at all (as in ASE [Genton *et al.*, 2008]), at least according to our current knowledge. From the EEG perspective, it would be misleading to classify some of the non officially recognized IGE syndromes as of "*unknown aetiology*". For this reason we classified them as "*possibly genetic*" (table 1).

A similar adjustment was felt necessary for the group of idiopathic (self-limited) focal epilepsies of childhood, for which conclusive evidence for primary genetic aetiology is still elusive (Vadlamudi *et al.*, 2014). Again, the clinical usefulness of the EEG report is not affected when typical electroclinical forms of the three officially recognized main syndromes (benign Rolandic epilepsy, Panayiotopoulos syndrome, and occipital epilepsy of Gastaut) are concerned, but intermediate

Table 1. Main EEG patterns in the 2017 aetiological taxonomy of the epilepsy syndromes and epilepsies.

Genetic	Possibly Genetic†	Unknown	Structural and Other††
EPILEPSIES WITH GENERALIZED SEIZURES*			
<ul style="list-style-type: none"> – GSWD >2.5 Hz (variations across sub-syndromes) – Non-localizing focal spikes – Normal background 	<ul style="list-style-type: none"> – CAE – JAE – JME – GTCSa – Reflex (photosensitive) 	<ul style="list-style-type: none"> – Absence epilepsy < 3 years – Eyelid myoclonia – Myoclonic-atonic – Epilepsy with phantom absences – Absence status epilepsy – Unclassified phenotypes 	
<ul style="list-style-type: none"> – GSWD < 2.5 Hz & gen. bursts of polyspikes/fast in sleep – Diffusely slow background 	Lennox-Gastaut syndrome	Lennox-Gastaut syndrome	Lennox-Gastaut syndrome
<ul style="list-style-type: none"> – GSWD of variable frequencies – Focal/multifocal spikes – Diffusely slow background 			<ul style="list-style-type: none"> – Former symptomatic generalized epilepsies/epileptic encephalopathies, including most cases of Lennox-Gastaut syndrome – Progressive myoclonic epilepsies**
EPILEPSIES WITH FOCAL SEIZURES*			
<ul style="list-style-type: none"> – Focal spikes of syndrome or lobe specific topography – Normal background 	<ul style="list-style-type: none"> – BFIS – ADNLE – Familial mesial TLE – Familial lateral TLE 	<ul style="list-style-type: none"> – Reflex (hot water) 	
<ul style="list-style-type: none"> – Focal spikes of syndrome specific topography – GSWD >2.5 Hz may occur – Normal background 		<ul style="list-style-type: none"> – Gastaut (& photosensitive) OLE – Panayiotopoulos syndrome – Rolandic epilepsy – Intermediate phenotypes – Atypical benign focal epilepsy 	

Table 1. Main EEG patterns in the 2017 aetiological taxonomy of the epilepsy syndromes and epilepsies.

Genetic	Possibly Genetic†	Unknown	Structural and Other††
– Focal spikes ± focal slowing of syndrome (lobe) specific topography – Normal or abnormal background		– Focal (former cryptogenic) epilepsies	
– Spikes ± focal slowing of lesion related topography – Rarely SBS Background normal or abnormal			– Mesial TLE – Post-trauma, infection, stroke, neoplasms, autoimmune – Cortical malformations*** – Tuberous sclerosis**
EPILEPSIES WITH FOCAL AND GENERALIZED SEIZURES			
– Syndrome-dependent patterns of spike-wave – Normal background	– Dravet syndrome – FS+ phenotypes	– Reflex (photosensitivity, reading, FOS, video games)	

The syndromes presented are examples for each major diagnostic EEG pattern and by no means form a comprehensive list.

†“expanded” genetic group for the purpose of the EEG report to retain its clinical usefulness when not recognized syndromes or unclassifiable clinical-EEG phenotypes of idiopathic generalized epilepsy (IGE) are concerned (*discussed in the last section of the Introduction*); †† including infectious, metabolic and immune aetiologies; *focal ictal symptoms/signs and rarely focal seizures may occur in the group of the genetic (idiopathic) generalized epilepsies, while absences may occasionally occur in the group of possibly genetic self-limited focal epilepsies of childhood; **epilepsies part of a genetic disorder; ***polymicrogyria may also be secondary to gene mutations.

CAE: childhood absence epilepsy; JAE: juvenile absence epilepsy; GTCs: generalized epilepsy with tonic clonic seizures alone; GSWD: generalized spike-wave discharge; BFIS: benign familial infantile seizures; ADNFLE: autosomal dominant nocturnal frontal lobe epilepsy; TLE: temporal lobe epilepsy; OLE: occipital lobe epilepsy; FOS: fixation-off sensitivity; FS: febrile seizures; SBS: secondary bilateral synchrony.

phenotypes of similar aetiology that cannot be classified in any of the three main syndromes do exist (Covanis *et al.*, 2003). From the EEG perspective, a genetic substrate was suspected 50 years ago (Bray and Wiser, 1964, 1965) and is supported by evidence from linkage and association analysis of centrottemporal spikes (Neubauer *et al.*, 1998; Strug *et al.*, 2009; Pal *et al.*, 2010) and the close association between these focal spikes and GSWD in many of these children. The relevant proportions of GSWD reach a third of children with idiopathic occipital epilepsy of Gastaut (Gastaut and Zifkin, 1987; Caraballo *et al.*, 2008), up to a quarter of those with Panayiotopoulos syndrome (Ohtsu *et al.*, 2003; Specchio *et al.*, 2010) with some children showing only GSWD at seizure onset (Caraballo *et al.*, 2015), and

up to 15% of children with benign rolandic epilepsy (Beydoun *et al.*, 1992); a few of these children may even have absences (Gastaut and Zifkin, 1987; Caraballo *et al.*, 2004).

An “expansion” of the genetic group to include all the idiopathic focal epilepsies and the IGE syndromes that are not officially recognized was deemed the only satisfactory way to maintain the clinical-taxonomic role of the EEG.

Table 1 shows examples of epilepsy syndromes and epilepsies for each major diagnostic EEG pattern, tabulated according to the main aetiologies, with the important caveat that aetiological classification is a dynamic process and that future research is anticipated to demonstrate varying genetic contribution in

a number of epilepsies and syndromes currently considered of unknown aetiology. In *table 1*, the idiopathic focal epilepsies of childhood and adolescence and the non-recognized IGE syndromes and phenotypes feature under the subheading of “*possibly genetic*”, stressing their EEG links to the four major syndromes of GGE. We emphasize that this organization serves EEG purposes and is in keeping with the freedom of organizing epilepsies according to a defining feature that is useful for a particular purpose (Berg and Scheffer, 2011), in this case the GSWD. Accordingly, ELMA, epilepsy with PA, ASE, patients with unclassifiable IGE, and at least a subset of children with absences before the age of three years or with epilepsy with myoclonic absences are *possibly genetic* with mainly generalized seizures and EEG abnormalities; the idiopathic focal epilepsies of childhood are *possibly genetic*, self-limited epilepsies with mainly focal seizures and EEG abnormalities; and the idiopathic reflex epilepsies are genetic (photosensitive epilepsy) or *possibly genetic* (reading/language-induced epilepsy) with generalized and focal seizures and EEG abnormalities (*table 1*). To avoid confusion, and also to limit the social stigma and consequences that may exist in different countries and cultures (Scheffer *et al.*, 2017), both terms “genetic generalized epilepsy” (GGE) that include the “expanded” possibly genetic epilepsies and IGE will be used together as GGE/IGE throughout this document.

2. Genetic (idiopathic) generalized epilepsies (GGE/IGE)

2.1. Typical EEG features - attributes and dynamics

The generalized spike-wave discharge (GSWD) at >2.5 Hz

The interictal EEG hallmark of the GGE/IGEs is the GSWD at >2.5 Hz, occurring against normal background activity. Incomplete GSWD and non-localizing focal spikes may variably occur.

The GSWD: morphology and distribution.

The GSWD consists of regular or almost regular sequences of bilateral synchronous spike-and-wave complexes at the classic frequency of 3-3.5 Hz (measured *after* the first second of the discharge), or faster at 4-5 Hz. Frequency may be faster and irregular at its very onset (within the first 500 ms-1 sec), gradually slowing down towards its termination, although intra-discharge irregularities may occur. The spike component, prominent at onset, may become inconspicuous towards the end of the paroxysm. The amplitude of the spike-wave complexes is typically maximal over the frontal areas and displays an

anterior to posterior gradient, frequently fading over the occipital areas.

The term “generalized” indicates that the paroxysm occupies all areas of the cerebrum (visible over all EEG leads), while the term “incompletely generalized” (Browne *et al.*, 1974) describes discharges that occupy at least two lobes on each side.

Voltage asymmetries between the hemispheres or any regional (anterior, posterior, or lateral, lateralized or not) lead-in may occur; when lateralized, the regional lead-in typically switches sides in the same or successive recordings. A lead-in consistently lateralized to the same side is not necessarily an exclusion diagnostic criterion for GGE/IGE in its own right (Lombroso, 1997) (*see also section on SBS [2.2]*).

Effect of sleep and other activation.

Slow (non-REM) sleep, mainly Stages 3 and 2 and to a lesser degree Stage 1, activates GSWD, although Stage 3 is rarely reached in outpatient sleep EEG recordings; discharge activation is particularly enhanced when sleep is achieved by SD (Degen *et al.*, 1987). GSWD tend to acquire a polyspike component (GPSWD) and become shorter in duration, incomplete or fragmented (*figure 2.01*). GSWD usually attenuate or are inhibited during REM sleep. GSWD are typically activated after awakening, irrespective of the time of the day. HV usually provokes GSWD for the period of the exercise and shortly after, although the effect varies across GGE/IGE syndromes and may not be evident in all patients. Specific triggers may include photic stimulation (and eye closure), reading and other linguistic activities, thinking, and elimination of central vision and fixation (*see sections on reflex seizures and epilepsies in chapter 4*).

Generalized spike-wave discharges and typical absences.

GSWD/GPSWD may occur in association with demonstrable behavioural changes, such as impairment of consciousness (IoC), motor and autonomic manifestations on video and polygraphy, or be subclinical. The length of the GSWD is not relevant to the degree of IoC (Shimazono *et al.*, 1953), although the latter is easier to appreciate by simple clinical observation in lengthier absences. Elegant early experiments have shown that impairment of responsiveness (as a major measurable constituent of consciousness) to paroxysm-controlled auditory stimuli occurs and maximizes within the initial 0.5 sec of the GSWD in at least 80% of the discharges, while starts to gradually recover after 1.5 sec from discharge onset (Porter and Penry, 1973; Browne *et al.*, 1974; Blumenfeld, 2012); on careful clinical assessment, mild IoC or mild but clear

Box 2. Assessment of consciousness during GSWD

Clinical basic: Explain the procedure before starting the recording. Give simple commands and auditory stimuli (numbers or words) clearly and loudly *as soon as possible after the onset of the discharge* and repeat during the absence, depending on its length. Check for possible direct responses during the discharge and, immediately after its offset, ask patients to repeat what they were told. The method is sensitive only for absences associated with severe IoC/responsiveness. Recommended first-line assessment of spontaneous and HV-induced discharges longer than 3-4 seconds (shorter discharges may already be fading by the time of the first stimulation).

Clinical advanced: Ask the patient to perform a simple motor task - counting breaths during HV or tapping - repetitively and at a comfortable rate (Giannakodimos *et al.*, 1995). The method aims to demonstrate defective concentration or motor execution (hesitations, delays, repetition of the same number) in very brief (~1.5-2-sec) GSWD (figure 2.03) or longer but mild absences, in which clinical basic assessment has been unremarkable (figure 3.20 and figures 3.36 and 3.37). This can be performed in all subjects older than five years of age, irrespective of their level of education. Although video monitoring is desirable, trained EEG technologists can closely observe patients and accurately annotate their performance on *basic* digital or paper recordings.

Clinical research: Continuous Performance Tests (CPT) use visual or auditory stimuli to assess attention, reception of information, and motor output. CPT is applicable only in fully co-operative patients.

motor hesitancy can be identified in GSWD of just 2 sec (Koutroumanidis *et al.*, 2008; Sadleir *et al.*, 2009). Ictal IoC is milder when the associated GSWD is incomplete (Browne *et al.*, 1974), or asymmetric. There is empirical evidence that IoC may also depend on the frequency and regularity of the GSWD; it is typically severe in association with the regular 3-Hz GSWD in CAE and JAE and appears milder in association with the faster GSWD as in JME, or the slower frequency in atypical absences (table 1). Motor manifestations include head and eye retropulsion, regional (eyelid, facial, and upper limb) myoclonus, facial (typically perioral/oroalimentary) and limb automatisms, and less frequently automatic speech.

There is no universally agreed definition of the TA seizure, as IoC, its *sine qua non* element, can vary widely not only in terms of severity, but also in terms of the constituents of consciousness that are involved (i.e. attention or memory), the detection of which depends on the method used (simple observation of the patient “blinking and staring”, unresponsiveness to verbal stimuli given during the discharge or no recall after the end of the discharge, discontinuation or faltering in breath counting during HV or other simple repetitive motor tasks, continuous performance tests, etc.) (box 2).

Normal background

Normal background is expected by default. In the presence of GSWD, as defined above, diffusely slow background activity may still be compatible with GGE/IGE when a *reversible* cause for such slowing can be demonstrated or assumed, including toxicity with antiepileptic or other drugs (such as neuroleptics, lithium, MAO inhibitors, and tricyclics) and coexisting

conditions (such as metabolic derangements or hypothyroidism, postictal suppression, etc.). In such cases, background normalizes after the removal of the offensive factor.

Non-localizing focal or multifocal spikes

These may occur variably over anterior, posterior, or lateral temporal regions (Seneviratne *et al.*, 2014). The term “non-localizing” distinguishes them from the ED of stable (“localizing”) epileptic foci that relate to structural causes. Typically, topography is frontal (supplementary figure 2.01) or occipital, but unstable, switching sides in the same or successive recordings, or multifocal. A stable topography, even in successive recordings, may still be compatible with GGE/IGE (Lombroso, 1997) when not associated with regional background disturbance (supplementary figure 2.02) (for section on SBS [2.2]).

Clinical Practice Statement: *in the appropriate clinical context, these EEG features can indicate the diagnosis of GGE/IGE with the highest degree of certainty. The EEG report may further suggest a particular age-related sub-syndrome according to particular EEG/video-EEG findings (see specific GGE/IGE syndromes).*

2.2. EEG features that, in the presence of >2.5-Hz GSWD/GPSWD, may indicate coexistence of GGE/IGE and focal epilepsy of structural or other aetiology, or secondary bilateral synchrony (SBS)

A consistent (stable) focus of spike or sharp wave activity, *associated with* regional background disturbance (i.e. irregular slowing with or without some attenuation

of fast rhythms). Such consistent focal abnormalities should not be attributable to other causes, such as concurrent cerebrovascular (vertebrobasilar) insufficiency (Niedermeyer, 1963), or other lately acquired brain insults. Focal epileptic abnormalities of such morphology and consistency raise the possibilities of a) SBS, or b) concurrent structural epilepsy with focal seizures (*supplementary figure 2.04*).

GSWD against an otherwise unexplained diffusely slow background raise the suspicion of epileptic encephalopathy, particularly when associated with subnormal cognitive function and their frequency is at, or close to, the lower end of the GGE/IGE spectrum (≤ 2.5 Hz).

GGE/IGE vs. Secondary Bilateral Synchrony (SBS)

Although frequently referred to, SBS has rarely received critical analysis, and defining neurophysiological evidence is conspicuously absent. For the purpose of the present revision the *clinical-EEG phenomenon* of SBS is *operationally* defined as a bilateral synchronous (generalized) spike-wave discharge (SBS-GSWD) that appears to be triggered by a *stable* epileptogenic focal abnormality (as defined above); such causal association can be reasonably assumed when the *stable* focal abnormality has *consistently* the same topography with the lateralized/regional lead-in of the GSWD (*spatial constraint*), or when focal sharp activity leads in a SBS-GSWD (*temporal constraint*). With regard to the spatial constraint, it is the *persistence* of the topographic concordance between the focal discharge and the lead-in of the GSWD that distinguishes SBS from the typically variable association between focal discharges and “onsets” of GSWD in GGE/IGEs. With regard to the temporal constraint, Blume and Pillay (1985) required sequential ED leading to SBS-GSWD to occur for at least 2 seconds, and the morphology of the focal triggering ED to clearly differ from that of the bisynchronous paroxysm, and to resemble that of other focal spikes from the same region (*supplementary figures 2.05, 2.06 and 2.07*). In their study, SBS-GSWDs were slower than 3 Hz in three quarters of the patients, most of whom had frontal lobe foci.

Such obvious EEG evidence may be lacking in some cases of presumed SBS; cortical foci may lie within deep sulci impeding recording of the triggering focal ED, or secondary generalization may be rapid. Corroborative *clinical* features for SBS may include frequent or predominating nocturnal seizures, focal seizures, and sub-normal cognitive state, while brain imaging may provide important diagnostic clues (*supplementary figure 2.08*).

Occasionally, tumours may underlie regular 3-Hz SW (Ajmone-Marsan and Lewis, 1960; Raymond *et al.*,

1995). In such cases, the overall association between GSWD (and sometimes TA) with focal brain pathology is uncertain; a lack of clear EEG evidence of SBS may be either coincidental, reflecting mere coexistence of symptomatic focal epilepsies with IGE, or be due to the strategic position of the lesion in the midline (Tükel and Jasper, 1952; Bancaud *et al.*, 1974), perhaps in some association with a genetic predisposition. Caution is needed to avoid confusion between SBS and the diffuse discharge from a single parasagittal generator whose field extends across the midline. Distinction of SBS requires the demonstration of two independent but synchronously firing foci that occupy homologous brain areas, shown in coronal montages that employ midline electrodes (Daly, 1997).

Clinical Practice Statement: in the presence of the above temporal and spatial EEG constraints and within the appropriate clinical context, the EEG report should explain the evidence and indicate the high probability of SBS, particularly when there are suggestive imaging findings. Depending on the available resources, electroencephalographers may also recommend further EEG diagnostics, including ambulatory EEG and video telemetry (to record focal seizures), or referral to a tertiary epilepsy centre and for brain imaging.

It is acknowledged that confident EEG differentiation between GGE/IGE and SBS may be impossible in a number of patients with “intermediate” EEG findings and complex/atypical (or unknown) clinical features. In such cases, it is recommended that electroencephalographers recognize the diagnostic limits of the EEG and strive to avoid unduly subjective opinions; instead, the EEG report should present the evidence and discuss the diagnostic possibilities, and advise further EEG/imaging diagnostics, as above.

Coexistence of genetic generalized and focal epilepsy of structural/metabolic aetiology

Such coexistence is expected to produce a complex picture with the relevant clinical and EEG characteristics being recognizable when sought (Koutroumanidis *et al.*, 1999; Radhakrishnan *et al.*, 2011). From the EEG viewpoint, subclinical GSWD or TAs and/or myoclonic seizures (MS), with or without non-localizing focal or multifocal spikes, should occur together with a stable focus over a cerebral lobe *without* consistent temporal or spatial associations between them.

Clinical Practice Statement: In the appropriate clinical context, the EEG report should indicate the possibility of coexistent focal epilepsy, explain the evidence, and

suggest video telemetry to record focal seizures and brain imaging, or referral to epilepsy centres with such facilities (see sections on focal epilepsies).

3. Syndromes of Genetic Generalized (idiopathic) Epilepsies

This section includes the four main and officially recognized syndromes of GGE (Scheffer *et al.*, 2017), namely, CAE, JAE, JME, and epilepsy with GTCS-a. It also contains a number of distinctive electroclinical phenotypes that, over the last few decades, have been well documented in the peer reviewed literature within the IGE spectrum. These are also characterized by the “genetic EEG marker” of GSWD and herein complement the four main syndromes as possibly genetic generalized epilepsies (see *introduction*).

3.1. CHILDHOOD ABSENCE EPILEPSY (CAE)

Overview

CAE is the archetype GGE/IGE syndrome of childhood onset absences, associated with the “classic” 3-4-Hz GSWD on the EEG. It affects neurologically normal children, the majority of which are girls. TAs start between 4 and 10 years of age, with a peak at 5-7 years, and in most children, remit in early adolescence. Infrequent GTCS may occur later in adolescence or adulthood, but not before or during the active phase of absences. MS are not a feature of CAE. Their early occurrence in a child newly diagnosed with absences may instead indicate JME of pre-adolescence onset, with absences as the first seizure type; a later occurrence may denote transition of CAE to JME, although the timing for this transition remains to be ascertained. Other absence GGE/IGE phenotypes during childhood, such as absences before the age of three years and photosensitive epilepsy with photically-induced absences are not included in this section; these are discussed in the respective chapters.

Seizures: symptoms and semiology

Typical absences (TA). In untreated children, TA occur daily with a tendency to cluster in great numbers (hence the classic term “pyknolepsy” from πυκνός meaning “dense” and λαμβάνειν meaning “take hold of”); they are typically provoked by HV without difficulty. Indeed, the diagnosis of CAE is seriously doubted in an untreated child with reported frequent blank spells, who does not have absences during well-performed HV. Onset is sudden with arrest of voluntary activities, although perseveration of some semi-voluntary preictal behaviours may linger for a few seconds into the absence. Most TA last up to

20 seconds and are typically associated with severe IoC/responsiveness; eyes become vacant, staring or drifting upwards, and eyelids may blink. Such TA are commonly referred to as *simple*, as opposed to those associated with automatisms that are commonly called *complex*. *De novo* automatisms occur in the majority of TA and relate to the duration of seizures, and are present in up to 95% of those longer than 16 seconds (Penry *et al.*, 1975); automatisms are oroalimentary, manual or speech, usually in this order of frequency and time of occurrence after seizure onset, and may be lateralized but not stereotyped. Bilateral clonic movements of the eyelids or face, head turning, autonomic changes, and reduction of muscle tone can occur, but are mild and do not persist throughout the seizure. Sudden and sufficiently loud auditory stimuli (calling a child’s name or clapping of hands) may interrupt the absence. Offset is also sudden with resumption of the preictal activities as though the latter were never interrupted. There are no postictal symptoms.

Generalized tonic-clonic seizures (GTCS) are not expected early in the active absence phase. Their early occurrence may indicate a poor prognosis (Trinka *et al.*, 2004).

EEG section

Background. Normal; occipital intermittent rhythmic delta activity (OIRDA) can occur (see *below*).

Interictal paroxysmal abnormalities.

During wakefulness

Given that HV can reliably provoke TA in untreated children with CAE, the diagnostic significance of interictal ED is commonly superfluous. Subclinical 3-3.5-Hz GSWD are brief (although as already mentioned in the introductory section on GGE/IGE, some disturbance of cognition can be shown in GSWD as short as 2 sec) showing frontal-central or less frequently posterior dominance. Onset is bilateral synchronous, but regional (usually frontal or occipital) bilateral or lateralized onsets are not infrequent, typically switching sides in the same or subsequent recordings.

Spike-and-wave discharges may be incompletely generalized or even focal, typically frontal or frontotemporal, but also posterior (occipital or parietal), again switching sides and location in the same or subsequent EEGs (Holmes *et al.*, 1987; Mariani *et al.*, 2011). Their topography may be similar to the regional onset of the GSWD, but such concordance is not suggestive of focal epilepsy with SBS as long as the EEG and clinical diagnostic criteria for the latter are not met (*supplementary figure 3.01*) (see also *section on SBS [2.2]*).

OIRDA is often closely associated with CAE, particularly when fast at 3-4 Hz (Watemberg *et al.*, 2007).

It can be intermixed with “occult” spikes in at least 30% of children, enhances with HV, and sometimes evolves into the GSWD-associated TAs (*supplementary figure 3.02*).

During sleep

In general, sleep recordings in CAE are sparse as waking EEG with adequate HV is usually sufficient for confident diagnosis. GSWD become more frequent and brief (fragments of the longer discharges during wakefulness) in Stages 2 and 3, and may acquire a clear polyspike component, although less than in JME. Focal discharges may become more apparent during sleep (*supplementary figure 3.03*) (Koutroumanidis et al., 2012).

EEG paroxysms that accompany ictal events.

Typical Absences (TAs). onset and morphology of the typical 3-4-Hz GSWD as above; it is emphasized that the GSWD may be faster, asymmetric or asynchronous in the first 500 ms-2 sec, and sometimes with a polyspike component with \leq three spikes, particularly at onset (*supplementary figure 3.04*).

TA can “start” conceivably from the occipital areas, following a run of OIRDA (*supplementary figure 3.02*), or from the frontal areas, not infrequently in the same child (*supplementary figure 3.05*).

The duration of absences varies from two to usually less than 20 seconds. Following the brief opening phase, the intra-discharge frequency is regular with gradual smooth decline; occasional brief interruptions may occur spontaneously or in response to auditory stimuli (*supplementary figure 3.06*), however, no irregular fragmentations occur as in JME. Sometimes the opening phase may be more prolonged, or asymmetric (*supplementary figure 3.07*).

For myoclonic seizures that may signal transition to JME, see relevant chapter.

Atypical EEG/video EEG features.

- (1) Generalized polyspike-wave discharges (with >three spikes per wave) *during wakefulness*.
- (2) Marked variations of the intra-discharge frequency or fragmentations *during wakefulness*.
- (3) Prominent photosensitivity with photically-induced absences clearly outnumbering possible spontaneous or HV-induced absences; consistent associated eye closure paroxysms.
- (4) Prominent myoclonic features occurring throughout the absences (eyelid or other facial, head, body, or extremities), rhythmic or arrhythmic.
- (5) Prominent tonic or atonic component associated with polyspikes or EEG flattening (shown by EMG polygraphy).

Recording protocols

Basic level

– In untreated children with CAE, absences are expected to occur during or immediately after HV. If video is not available, EEG technologists should carefully observe the children throughout the absences and try to note any associated behavioural changes (*for recommended stimulations during the absences, see assessment of consciousness/responsiveness below and box 2*).

– Activation: HV (with the child sitting up and arms outstretched forwards) performed twice or more if needed using a toy windmill to blow on in younger children; IPS.

– Use bilateral deltoid EMG polygraphy if enough channels are available.

Advanced level

– Activations: HV as in basic level; video recording allows full documentation of the associated ictal behavioural changes; IPS.

– Bilateral deltoid EMG polygraphy is mandatory.

– As absences are easily provoked by HV, recordings during sleep are not required for the vast majority of children with CAE. When needed (*see main indications below*), facilitate sleep by partial SD, attempt to reach Stage 2 for at least 15-20 minutes (if possible, Stage 3 also), then record for at least 30 minutes after awakening, including HV and IPS, as above.

Assessment of consciousness/responsiveness during GSWD (*box 2*).

Clinical basic. Essential, and probably sufficient, as CAE is defined by absences associated with severe IoC/unresponsiveness.

Clinical advanced. This may be redundant for clinical diagnostic purposes if **basic** assessment demonstrates TAs. It is *doable* at both recording levels, with the additional benefit of detailed video analysis at advanced level.

Immediately after each absence, children should be asked to repeat the given auditory stimuli and be questioned about possible symptoms.

Levels of EEG diagnosis

A) Confirmatory of CAE (based on clinical suspicion of CAE in untreated children). Recording of TAs with the typical ictal and interictal presentation; no atypical clinical or EEG features. There is no clinical need to perform advanced sleep-deprived recording (for both basic and advanced waking recordings).

B) High diagnostic certainty (probable). No TAs recorded, but typical interictal presentation; no atypical clinical or EEG features (for both basic and advanced waking recordings). Note that it is *unusual* for HV not to activate TA, unless if sub-optimally performed. In this scenario, findings are supportive of

CAE, but advanced recording during sleep after partial sleep deprivation (SDEEG) with >1 session of HV on awakening is recommended to record and study TAs and move diagnostic certainty up to the confirmatory level A.

Note 1: if still no TAs are recorded during sleep-deprived advanced EEG that contains typical interictal, with or without some atypical, EEG features, a diagnosis of CAE is *no longer acceptable*. Findings may still be consistent with GGE/IGE, including absences (given the history), but are not suggestive of CAE. In very young children, consider other diagnostic possibilities, including glucose transporter type 1 deficiency syndrome (see also chapter on absences with early onset), especially if absences are drug resistant.

Note 2: In the untreated child with suspected absences, the diagnosis of CAE can be excluded when the EEG remains normal despite satisfactory HV, particularly when sleep-deprived recordings are concerned.

Indications for performing or repeating sleep-deprived advanced EEG or prolonged video recording.

- (1) Failure to record absences (at basic and advanced EEG levels).
- (2) Persistent occurrences of focal spikes and focal onsets of absences over a single area.
- (3) Atypical features during wakefulness (at basic and advanced EEG levels), particularly in very young children.
- (4) Resistance to appropriate AEDs (VPA, LTG, ESX).
- (5) GTCS or MS of early onset, or a history of possible focal seizures.

3.2. JUVENILE ABSENCE EPILEPSY (JAE)

Overview

JAE is the main absence syndrome of adolescence, although onset can range from around eight years (therefore overlapping with that of CAE) to early adulthood. Onset peaks between 10 and 13 years of age. Both sexes are equally affected. GTCS occur in the vast majority of patients, and MS in about 15%. JAE is not a self-limiting syndrome, but satisfactory seizure control with appropriate pharmacological treatment can be achieved in the majority of patients (Trinka et al., 2004; Hirsch et al., 2007; Wirrell, 2013).

Seizures: symptoms and semiology

As in CAE, **absences** are usually associated with severe disturbance of consciousness/responsiveness and automatisms, and are provoked by HV, however, they occur less frequently than in CAE, and usually sporadically at any time of the day without tendency to cluster.

In contrast to CAE, **GTCS** often occur early during the natural course, and may even be the first overt seizure. When present, **MS** are infrequent and usually occur sporadically any time during the day.

EEG section

Background. Normal.

Interictal paroxysmal abnormalities.

During wakefulness

GSWD, incompletely generalized and focal SWD with activation by HV occur, as in CAE. There may be more evident polyspike component (>3 spikes per wave), but a constant relationship with the associated slow wave is usually maintained.

During sleep

Discharges become more frequent and brief with an enhanced polyspike component during Stages 1 and 2 of non-REM sleep (*supplementary figure 3.08*) and even briefer, typically consisting of single spike/polyspike and wave complexes in Stage 3 (*supplementary figure 3.09*) (Sadleir et al., 2009). GSWD attenuate during REM periods, but may persist, particularly in patients with treatment-resistant JAE (*supplementary figure 3.10*). Brief regular GSWD may occur during sleep, but the frequency is usually slower than in wakefulness (*compare GSWD in supplementary figures 3.11 and 3.12*).

EEG paroxysms that accompany ictal events.

Typical absences. Onset, morphology of the associated classic 3-3.5-Hz GSWD, and termination occur as in CAE; duration varies but seizures may be longer than in CAE, sometimes exceeding 30 sec (*supplementary figure 3.13*).

Absences are associated with severe IoC (*supplementary figure 3.13*), but in general, they are considered less severe than in CAE (*supplementary figure 3.11*). There may be a more evident polyspike component (>three spikes per wave), but unlike JME, a constant relationship with the associated slow wave is usually maintained (Panayiotopoulos et al., 1989a).

Given the typically long duration of absences in JAE, automatisms are frequent, as in CAE (*supplementary figure 3.14*).

Generalized convulsions. These may occur independently or follow an absence (absence-tonic-clonic sequence) with transition from the classic 3-Hz spike-wave GSWD to the pattern of generalized fast rhythms of the GTCS (*supplementary figure 3.15*). The actual frequency of this sequence is uncertain because long recordings that are more likely to record a GTCS (such as inpatient video telemetry) are infrequently employed in patients with GGE/IGE.

Myoclonic seizures: as in JME (see next section).

Atypical EEG/video EEG features.

- (1) Consistent irregular discharge fragmentations during wakefulness.
- (2) Discharges of fast rhythms/polyspikes (either at the onset, within the GSWD or independently) during wakefulness (*supplementary figure 3.16*).
- (3) Prominent photosensitivity with photically-induced absences clearly outnumbering possible spontaneous or HV-induced absences; consistent associated eye closure paroxysms.
- (4) Prominent myoclonic features occurring throughout the absences (eyelid or other facial, head, body or extremities), rhythmic or arrhythmic.
- (5) Prominent tonic or atonic component (on video, but appropriately shown by EMG polygraphy), associated with polyspikes or EEG flattening.

Recording protocols

Basic level

- In untreated patients with JAE, absences or GSWD are expected to occur during or immediately after HV, performed with the patient sitting up with arms outstretched or standing; the exercise can be performed twice, or more if needed. If no absences occur, encourage light sleep when time allows, and repeat HV after awakening, as above. If video is not available, EEG technologists should carefully observe the patient for the duration of the GSWD and annotate any associated behavioural changes as fully as possible (*for recommended stimulations during the absences, see assessment of consciousness/responsiveness below and box 2*).
- IPS.
- Use bilateral deltoid EMG polygraphy if enough channels are available.

Advanced level

- At this level, and particularly for older patients on treatment, SDEEG is recommended for initial assessment. If a waking recording has been already planned, encourage light sleep, provided that time allows.
 - Bilateral deltoid EMG polygraphy is mandatory.
 - Activation with IPS and HVV as in basic level on awakening : HV more than twice if needed. Assess consciousness/responsiveness during discharges (see *below and box 2*). In partially sleep-deprived EEG, try to reach Stage 2 and maintain sleep for at least 15-20 minutes, if possible, record for at least 20-30 minutes after awakening, including HV.
- In both recording levels, patients can be questioned about possible symptoms immediately after an absence.

Assessment of consciousness/responsiveness during GSWD (*box 2*).

Clinical basic. Essential, and probably sufficient, as JAE is defined by absences associated with severe IoC/responsiveness. Immediately after each absence, patients should be asked to repeat the given auditory stimuli (and be questioned about possible symptoms, as above).

Clinical advanced. This may be a redundant step if absences are demonstrated by **basic** assessment, as it usually happens in newly diagnosed, drug-naïve patients. However, it may be useful in older adults, who may have milder/briefer absences, particularly when they are already on treatment.

Levels of EEG diagnosis

A) Confirmatory of JAE (based on clinical suspicion of JAE in untreated children/adolescents/adults).

Recorded TAs with the typical ictal and interictal presentation, without atypical clinical or EEG features. There is no clinical need to perform advanced sleep-deprived recording (for both basic and advanced waking recordings), however, see clinical indications for SDEEG below.

B) High diagnostic certainty (probable). No TAs recorded, but typical interictal presentation; no atypical clinical or EEG features (for both basic and advanced waking recordings). Note that, in contrast to CAE, HV may not always activate TA in JAE; therefore, in the presence of suggestive history and typical interictal EEG findings, the diagnosis of JAE is still highly probable. Nevertheless, advanced recording during sleep after partial SD with >1 session of HV on awakening is recommended to record and study TAs and move diagnostic certainty up to the confirmatory level A.

C) Low diagnostic certainty (possible). Typical, but also any of the atypical, video-EEG/EEG features, as above (for both basic and advanced recording levels): findings are consistent with GGE/IGE, but not suggestive of typical JAE. An atypical presentation of JAE is still possible, and prolonged advanced level SD EEG recording or video telemetry is recommended to explore the whole electroclinical picture.

Note: normal basic or advanced level EEG does not negate a diagnosis of JAE when clinical history is suggestive. Proceed with, or repeat, advanced level SD EEG.

Indications for repeating advanced SD recording.

- (1) Failure to record absences in basic or advanced waking EEGs.
- (2) Resistance to first-line AEDs (*i.e.* VPA, LTG).
- (3) Clinical evidence of new-onset myoclonic jerks.

Indications for video telemetry.

- (1) Failure to record absences in repeated advanced level SD EEG recordings.

- (2) Atypical presentation (see *diagnosis level C* above) or clinical suspicion of additional seizure type (i.e. with focal features).
- (3) Clinical suspicion of non-convulsive (absence) status.

3.3. JUVENILE MYOCLONIC EPILEPSY (JME)

Overview

JME is the main myoclonic syndrome of adolescence and one of the most typical epilepsy syndromes. Onset can range from before the age of 10 (therefore overlapping with that of CAE) to mid-20s, or even later. MS, typically occurring on or after awakening, are the defining seizure and can be the only seizure type in some patients. GTCS occur in most patients and mild absences in about a third when video-EEG is optimally used. SD, early or forced awakening, and stress are principle precipitants for MS and GTCS. In many patients, JME is not self-limiting; response to appropriate antiepileptic medication is in most patients satisfactory, although it is generally deemed inferior to that of JAE with a probably greater risk for relapse when antiepileptic treatment is stopped (Panayiotopoulos et al., 1994; Kasteleijn-Nolst Trenité et al., 2013).

Seizures: symptoms and semiology

The characteristic spontaneous **MS** are typically described as more or less symmetric brief sudden jerks of mainly the shoulders and upper arms, which - when strong - may cause abduction and flexion of the upper limbs at the elbow and of the lower limbs (when involved) at the hip and knee, with associated extension of the neck (*supplementary figure 3.17*). However, topography and laterality may vary and MS may be mild and only felt rather than seen, predominate on one side, or involve the distal parts of the upper limbs. Indeed, some patients describe their jerks as unilateral or even focal, not infrequently misleading to a diagnosis of focal epilepsy, particularly when an EEG is not performed, is sub-optimally recorded or poorly interpreted. Typically, MS occur within the first couple of hours after awakening, either in the morning or after a daytime nap; they occur as solitary events or in clusters, particularly upon early or forced awakening after a night of short or poor sleep, or during evening relaxation. Triggers include movements (praxis-induced) in a sizable number of patients, photic stimulation in a tenth, and reading or other linguistic activities in a few (Oguni et al., 1994; Genton et al., 2013).

GTCS typically start soon after the onset of MS and usually follow a cluster of MS (clonic-tonic-clonic sequence) (*supplementary figure 3.18*); their diurnal distribution is similar to that of MS.

Absences are usually infrequent, brief and mild, reported by only a tenth of patients. However, video-EEG recordings with appropriate assessment of cognition during GSWD identify mild absences in more than a third of patients (Panayiotopoulos et al., 1989b), including phantom absences (*supplementary figure 3.19*). Absences starting in childhood may be more severe or prolonged in the beginning, but become milder and less frequent with age (see also *transition of CAE to JME in the section on CAE [3.1]*).

EEG section

Background. Within normal limits.

Interictal paroxysmal abnormalities.

During wakefulness

Typical generalized pattern:

Generalized polyspike-wave discharges with anterior predominance and more than three spikes in the polyspike component (*supplementary figure 3.20B*) can be asymmetric with lateralized onset, frequently switching sides in the same or sequential recordings (*supplementary figure 3.21A and C; supplementary figure 3.22A and C*); intra-discharge frequency is fast but frequently unstable, showing irregular fragmentations (*supplementary figure 3.23A*). GSWD of apparently posterior lead-in can occur (*supplementary figure 3.21A*) (Serafini et al., 2013).

Other generalized patterns:

- (1) Classic (3-3.5-Hz) GSWD (*supplementary figure 3.22A*); this is most likely to associate with brief and mild IoC (see *absences below*).
- (2) Fast pattern (>4-Hz) GSWD (*supplementary figure 3.20A*).

All generalized patterns tend to occur more in the morning than in the evening, are brief, and are activated by HV. Photoparoxysmal responses (PPRs) to IPS are elicited in >35% of patients with or without clinical photosensitivity.

(Non-localizing) focal spikes, typically frontal or frontotemporal (*supplementary figure 3.21D; supplementary figure 3.22B and D*), but also posterior (*supplementary figure 3.21B*), unilateral or bilateral, have been reported in up to 40% of patients (Serafini et al., 2013) and represent a major EEG factor for misdiagnosis of JME as focal epilepsy, along with the asymmetric/lateralized GSWD and the lateralization of the myoclonic jerks.

During sleep

Generalized discharges become more frequent and briefer in slow sleep, with increased number of spikes per discharge (*supplementary figure 3.20C; supplementary figure 3.23C*). They tend to occur in phases of enhanced vigilance (cyclical alternating pattern A; CAP A) and may initiate such phases in patients

with poorly controlled seizures (Serafini *et al.*, 2013), or during brief arousals (*supplementary figure 3.24*). Focal spikes tend to occur in phases of reduced alertness (CAP B) (*supplementary figure 3.22D*). All patterns of generalized discharge attenuate or are inhibited during rapid eye movement (REM) sleep (*supplementary figure 3.25*).

EEG paroxysms that accompany ictal events.

Myoclonic seizures (MS). Brief, generalized high-amplitude polyspike-wave discharges with multiple spikes (>5) in the polyspike component; symmetric or asymmetric (*supplementary figure 3.17*). Some patients (or bed partners) may report myoclonus during sleep, but this is usually hypnagogic. Typically, MS occur following arousals (*supplementary figure 3.26*).

Absences. Brief, usually 3-5 sec, associated with the "classic" 3-4-Hz GSWD pattern; typically mild and simple. HV with breath counting may also reveal phantom absences (*supplementary figure 3.19*).

Generalized convulsions. These may occur independently of MS or immediately follow a cluster of MS, showing the typical clonic-tonic-clonic sequence in which discrete generalized bursts of polyspike-wave precede the pattern of generalized fast rhythms of the CTCS (clonic-tonic-clonic sequence) (*supplementary figure 3.18*).

Recording protocols

Basic level

– **Time:** morning (first appointment of the day, if possible).

– **Activation:** HV: In untreated patients with JME, the above described interictal spike-wave discharges are very likely to occur during or immediately after HV, performed with the patient sitting up with arms outstretched or standing. HV can be performed twice or more, if needed. If no discharges occur and time allows, encourage light sleep and repeat HV after awakening, as above. MS may occur in a small number of patients. Possible *absences* are typically expected to be brief and mild. Therefore, the **clinical basic** assessment of consciousness/responsiveness during the classic 3-3.5-Hz or the faster (>4-Hz) GSW discharges is likely to be unremarkable (*supplementary figure 3.20A*); **clinical advanced** assessment is recommended with annotations by the physiologist on a digital or paper recording (*supplementary figure 3.19*), if video-EEG is not available.

– IPS

– **Polygraphy:** bilateral deltoid EMG is very important and, if not enough channels are available, it may be worth using two EEG channels for EMG (omitting the mastoid or mid-temporal, *but not the frontal*).

Advanced level

– SDEEG are recommended for initial EEG assessment as waking EEG can be normal or inconclusive, sometimes more than once (Serafini *et al.*, 2013); allow the patient to reach Stage 2, or even 3 if possible, and maintain sleep for a minimum of 15-20 minutes; record for at least 30 minutes after awakening, including activation. Note that the occasional noises in a busy EEG department may not be avoided at all cost because consequent EEG arousals may activate ED!

– **Time:** less important if SDEEG has been planned; otherwise offer first appointment of the day as in basic level. If a waking recording has been already planned, encourage light sleep, provided that time allows.

– **Activation:** HV performed with the patient sitting up, at least twice, with **clinical advanced** assessment of cognition/responsiveness during classic 3-3.5-Hz and the faster discharges (see CAE and box 2); test for praxis- or reading-induced MS or ED, particularly if suggested by history.

– IPS

– **Polygraphy:** bilateral deltoid EMG is mandatory; this can record subtle MS that may defy visual detection on video analysis, be ignored by the patient, or be felt but not reported; consider using *additional* jaw EMG electrodes if reading-induced symptoms are suggested by history (see also section on reading epilepsy [4.2]).

Levels of EEG diagnosis

A) Confirmatory of JME (based on clinical suspicion of JME in untreated children/adolescents/young adults). Recorded typical MS with the typical ictal and interictal presentation.

B) High diagnostic certainty (probable). No typical MS recorded, but typical interictal presentation (particularly with GPSWD, but also with classic 3-Hz GSWD and fast pattern of GSWD; for both basic and advanced waking recordings). A diagnosis of JME is still highly probable and diagnostic value is almost equal to level A (*above*).

In both levels A and B, advanced recording during sleep after partial SD with >1 session of HV on awakening is important to 1) evaluate sleep and possible epileptic arousals that could impact on responsiveness to treatment (Bonakis and Koutroumanidis, 2009; Serafini *et al.*, 2013), and 2) record and study possible coexistent TAs to obtain the full expression in a given patient.

C) Low diagnostic certainty (possible). Focal, non-localizing spikes, without interictal generalized discharges (for both basic and advanced waking recordings). Findings are still in keeping with a diagnosis of JME (in the presence of suggestive clinical

Table 2. Epilepsy with GTCS alone, absence status epilepsy and epilepsy with phantom absences: distinguishing and overlapping features.

	GTCS-a	ASE	E-PA
Age at onset	Childhood to early-mid adulthood; typically peaks in adolescence/early adulthood.	Adolescence to early-mid adulthood	Adolescence to mid-adulthood; typically peaks in early adulthood*
GTCS	<u>Defining seizure type</u>	In most patients	In most patients
Absence status (AS)	In a few patients - infrequent	<u>Defining seizure type</u>	In up to 50% (variable frequency)
Phantom absences**	Exclusion criterion	Not reported yet	<u>Defining seizure type</u>
Absences	Exclusion criterion	Infrequent***	Exclusion criterion
Myoclonic seizures	Exclusion criterion	Not reported yet	Exclusion criterion
PPR	Up to 30%	Not reported yet	Infrequent

* refers to the first GTCS or episode of AS, as the age at PA onset is, by definition, impossible to ascertain; **diagnosed only by EEG (see text for appropriate methodology); ***not classifiable as childhood or juvenile absence epilepsy; PPR: photoparoxysmal response.

evidence), but advanced level SDEEG recording is recommended to activate interictal GSWD/GPSWD and move diagnostic certainty up to level B (or to level A if MS occur on awakening). Evaluation of sleep and possible coexistent absences are additional reasons.

Note 1: normal basic or advanced level waking and sometimes SDEEG do not negate a diagnosis of JME when clinical history is suggestive. Proceed with, or repeat, advanced level SD EEG.

Note 2: It is important to emphasize once more that all IGE syndromes show polyspike-wave during sleep and therefore, as readers have already noticed, none of the indications for advanced SDEEG in this section refer to recording GPSWD for the purpose of JME diagnosis.

Indications for repeating SD recording level 2.

- (1) First EEG(s) (basic or advanced) is normal or inconclusive.
- (2) Resistance to appropriate AEDs (VPA, LEV).
- (3) Suspected cognitive deterioration, particularly if there is a hint of mild diffuse background slowing; clinical suspicion of action myoclonus (AM) (see chapter 6 on progressive myoclonic epilepsies)

Indications for video telemetry.

- (1) Clinical suspicion of additional seizure type (i.e. with focal features).
- (2) Clinical suspicion of myoclonic or non-convulsive status.

3.4. OTHER GENETIC AND PROBABLY GENETIC GENERALIZED EPILEPSIES

The following section examines three GGE/IGE syndromes that mainly manifest in the second and third decades of life, clinically with GTCS and variably with episodes of absence status (AS) and GSWD on the EEG. Only the syndrome of GTCS-a has been formally recognized by the ILAE. The term E-PA emphasizes the characteristic seizure type (phantom absences [PA]), identified only by appropriate EEG methodology, while the term ASE emphasizes the clinically most prominent seizure type (AS), identified by good history taking and EEG. *Table 2* provides an overview of the three syndromes, illustrating their distinguishing and also overlapping features. The following EEG diagnostic criteria and protocols are based on the currently available evidence, but are subject to modifications pending further clinical research.

Epilepsy with GTCS alone (GTCS-a) (previously known as IGE with GTCS on awakening)

Overview.

As the name indicates, GTCS are the defining (and sole) seizure type; absences and MS (either as part of the clinical picture or identified on EEG) are not constituents of this syndrome. Therefore, diagnosis of GTCS-a in patients with history of GTCS and GSWD on the EEG effectively relies on the exclusion of both MS and TAs (including phantom absences), and by

implication, on the extent and thoroughness of the initial clinical and EEG assessment and subsequent clinical/EEG follow-up. Despite the lack of absences, infrequent episodes of absences status (AS) have been reported in some patients. The age at onset of GTCS-a ranges from childhood to mid adulthood, peaking during the second decade. The syndrome is not self-limiting; response to antiepileptic medication is in most patients satisfactory, although efficacy is difficult to ascertain in patients with infrequent GTCS. Seizure frequency is generally low (Camfield and Camfield, 2010).

Seizures: symptoms and semiology.

GTCS typically occur within 1-2 hours of awakening, but may also infrequently occur during periods of relaxation and in some patients randomly. SD, early forced awakening particularly after short or poor sleep, tiredness, and stress are principle precipitants (Janz, 2000; Unterberger *et al.*, 2001).

Episodes of AS can occur in up to 20% of these patients and are not clinically different to those of any other syndrome of GGE/IGE (Koutroumanidis *et al.*, 2008). As a rule, they are infrequent and do not dominate the clinical picture, as in **absence status epilepsy (ASE)** (Genton *et al.*, 2008), from which GTCS-a should be differentiated (see section on ASE [5.3] and table 2).

GTCS-a should also be differentiated from the **epilepsy with phantom absences (E-PA)** (Koutroumanidis *et al.*, 2008), in which phantom absences (inconspicuous to patients and observers, and therefore not a reported clinical feature of the syndrome) are recorded on the EEG, are *the only type of absence*, and combine with GTCS and often with episodes of AS. Differential diagnosis relies mainly on EEG studies that can identify or exclude phantom absences (see also section on E-PA [3.4] and table 2).

EEG section.

Background. Normal.

Interictal paroxysms.

During wakefulness

- (1) Generalized spike/polyspike-wave discharges as in JAE; brief, usually up to 3-4 sec and exceptionally longer. GSWD can be activated by HV but do not amount to absences, including PA (*supplementary figure 3.27B and C, supplementary figure 3.28A*).
- (2) Incompletely generalized SWD and focal SWD, as in JAE (*supplementary figure 3.28C and D*).
- (3) PPRs may occur in 25-30% of these patients.

During sleep

In non-REM sleep, GSWD may become more frequent, briefer and incomplete (*supplementary figure 3.27A, supplementary figure 3.28B and D*) and may acquire a

polyspike component, or importantly, may appear for the first time; GSWD typically attenuate during REM periods, although they may still occur (*supplementary figure 3.29*).

EEG paroxysms that accompany ictal events.

Generalized convulsions (tonic-clonic). Sudden onset of low-voltage generalized fast rhythms (epileptic recruiting rhythm); a brief lead-in of generalized 3-4-Hz spike-wave discharges (absence-tonic-clonic sequence) or of generalized polyspike-wave discharges (clonic-tonic-clonic sequence) may be in keeping with the diagnosis of GTCS-a, provided that no independent absences or MS occur. EEG changes are usually obscured by diffuse tonic muscle activity.

Absence status. EEG features are not different to AS of other GGE/IGE syndromes (see section on E-PA and ASE below and box 3).

Note: absences (including phantom absences) and MS do not feature in GTCS-a (exclusion criteria).

Recording protocols.

Note: the diagnosis of GTCS-a in a patient with a history of GTCS as the *only* seizure type requires: (1) EEG demonstration of the typical interictal GSWD, **and** (2) absence of any behavioural evidence of IoC in association with them.

Regarding the first requirement, and as routine EEGs may be normal or inconclusive, sleep recordings after partial sleep deprivation (SDEEG) increase the possibility of recovering GSWD by employing three potent activators: SD, sleep itself, and awakening (Genton *et al.*, 2005; Koutroumanidis *et al.*, 2008) (*supplementary figure 3.27*). At the *advanced recording level*, it is strongly recommended to begin patients' assessment with a SDEEG straightaway rather than resorting to it after an inconclusive routine recording. At the *basic level*, when a sleep EEG is impractical to organize, it is recommended to encourage a brief light sleep, provided that time allows; although less satisfactory, such methodology still makes some use of two GSWD activators, sleep and awakening, missing out SD.

As to the second requirement, SDEEG with HV and breath counting on awakening has been shown to successfully activate GSWD, *but not phantom or other absences*, in patients with GTCS-a (*supplementary figure 3.30*), while at the same time it can detect phantom absences in patients with E-PA (Koutroumanidis *et al.*, 2008). Therefore, SDEEG with appropriate activation on awakening is the most important tool for effective differentiation between the two syndromes (see also the section on *epilepsy with E-PA* below). It follows that consciousness and responsiveness during the GSWDs should be thoroughly assessed, not only by

Box 3. Typical absence status (AS)

Typical AS is a state of variably altered consciousness, responsiveness, and behaviour, observable or subjectively perceived that occurs in patients with GGE/IGE and is associated with continuous or sub-continuous, rhythmic or arrhythmic ≥ 2.5 -Hz generalized spike or polyspike-wave EEG activity. This lies in contrast to the *atypical* AS which is associated with slower spike wave discharges (*table 1*). Episodes of typical AS (or AS hereafter in this section) can last from several minutes to days, or rarely weeks, and can be punctuated by, or terminate with, GTCS. Subtle eyelid myoclonus is frequently noticeable. No syndrome of GGE/IGE is immune to AS, but frequency of occurrence and clinical features can be syndrome-related (Agathonikou *et al.*, 1998). AS is a type of generalized seizure and can occur spontaneously, sharing with the other seizure types of GGE/IGE the same facilitating factors, or be caused by inappropriate use of AEDs (Thomas *et al.*, 2006).

Diagnosis of AS can be either direct, when actually recorded on video-EEG/EEG, or indirect, when clear history of prolonged episode(s) of confusion is available for patients with clinical and EEG evidence of GGE/IGE (absences, myoclonic jerks or GTCS, associated with GSWD on the EEG) (Andermann and Robb, 1972). Recording of AS should not necessarily be left to chance. Given the long duration and recurrent nature often associated with recurrent AS episodes, patients with suggestive history may be brought by specifically instructed relatives to the EEG department for acute recordings, which can be diagnostic. Alternatively, home video telemetry, available in some tertiary epilepsy centres, can be used (*figure 3.46*). AS should be differentiated from the situation-related *de novo* AS of late onset.

De novo absence status of late onset (*dnASLO*)

dnASLO is a situation-related (or acute symptomatic; Beghi *et al.*, 2010) prolonged epileptic confusional state that may be fairly similar to AS in terms of ictal symptoms and EEG findings (*figures 3.47 and 3.48*). However, like any other acute symptomatic seizure, *dnASLO* is not considered as a seizure-symptom of an epilepsy syndrome or type.

dnASLO occurs in middle-aged or elderly patients with no previous history of epilepsy, and is characteristically precipitated by toxic or metabolic factors. Patients often have a history of psychiatric illness, treated with multiple psychotropic drugs.

Emergency EEG is diagnostic. However, only rarely does the ictal activity occur at precisely 3 Hz; in most cases, the frequency of spike-wave or polyspike-wave discharges ranges from 1-2.5 Hz. (Granner and Lee, 1994). IV injection of benzodiazepines (BZD) should prove EEG and clinical normalization (*figure 3.48*).

IV administration of anti-seizure medication is necessary to confirm the ictal nature of the episode, because, due to the frequently slow intra-discharge frequency, it may be difficult to distinguish true ictal epileptic EEG patterns from interictal or non-ictal EEG discharges such as, for example, runs of triphasic sharp waves in hepatic encephalopathy (Kaplan, 2002) or in drug-induced encephalopathy. In such cases, IV BZD may or may not produce resolution of the epileptiform discharges, but even when it does- emerging background rhythms will be abnormal and there will be no clinical improvement (*figures 3.49, 3.50 and 3.51*). However, it appears that some drugs (such as cefepime) can both induce toxic encephalopathy and in rarer but well-documented instances, *dnASLO*.

dnASLO is an acute symptomatic seizure and may not recur if the triggering factors can be identified and corrected. Therefore, long-term treatment with AEDs may not be needed (Thomas *et al.*, 1992). Diagnosis requires: (1) emergency EEG with IV BZD trial; (2) unequivocal evidence of an exogenous trigger, mainly psychotropic drug withdrawal and acute metabolic or toxic insults; and (3) no evidence of GGE/IGE based on history or during prospective clinical EEGs performed during follow-up.

basic clinical protocol (in any case applicable only for discharges of ~ 4 sec or longer), but **by clinical advanced** protocols (*box 2*). The latter can be used even in *basic level* EEG 1 (without video capabilities), provided that EEG technologists are suitably trained.

Basic level

- **Time:** first recording of the day (particularly, if occurrence of GTCS on awakening is suggested by history)
- **Activation:** as for JAE and JME.

Encourage light sleep as above, and repeat HV with breath counting or another clinical advanced protocol

on awakening. If no video is available, EEG technologists must observe the patient carefully and timely annotate possible behavioural changes on digital and paper recordings.

– IPS.

– Use bilateral deltoid EMG polygraphy when sufficient electrode channels are available.

Advanced level

– **Time:** same as in *basic level*.

– **Activation:** as for JAE and JME; avoid routine recordings and perform SDEEG straightaway with at least

two sessions of HV after awakening, with assessment for IoC according to clinical advanced protocol (box 2). As cited in the preceding text, lack of any clinical evidence of IoC associated with GSWD strongly pushes diagnosis towards GTCS-a, and away from the syndrome of E-PA (see also section on E-PA below).

Note: The actual length of the GSWD cannot substitute clinical advanced protocol as measure of IoC; it is emphasized that GSWD of 4 sec or even lengthier may be subclinical, while GSWD of 2 sec can be associated with fleeting IoC (box 2).

- IPS.
- Bilateral deltoid EMG polygraphy is mandatory.

Levels of EEG diagnosis.

A) Confirmatory of GTCS-a in patients with GTCS without history of earlier vacant spells or myoclonic jerks.

Recording the typical GSWD without evidence of associated IoC by clinical advanced assessment with a sufficient number of GSWD (for advanced SDEEG, but also for basic level recordings that contain a period of sleep).

B) High diagnostic certainty (probable). Recording the typical GSWD without evidence of IoC by clinical basic or advanced assessment (for both basic and advanced EEG levels without sleep or SD). SDEEG advanced level recording is recommended to assess IoC with a sufficient number of GSWD and move diagnostic certainty up to confirmatory level A, by excluding mild IoC associated with the discharges (or alternatively indicate E-PA by detecting PA). If an advanced level recording is not available, repeat basic level including sleep with appropriate activation and assessment on awakening.

Note 1: Normal waking EEG should prompt SDEEG advanced level to record GSWD and move diagnostic certainty to at least level 2 (probable GTCS-a).

Note 2: Diagnosing GTCS-a in the absence of the genetic EEG trait of GSWD is not appropriate, particularly when patients are likely to participate in clinical/genetic studies. Patients with GTCS and persistently normal or inconclusive EEG, including long recordings (see indications below), should be classified (on clinical grounds only) as having epilepsy with generalized convulsive seizures of unknown aetiology.

Indications for video telemetry/ambulatory EEG.

- (1) Failure to record GSWD in sequential advanced level SDEEGs.
- (2) Clinical suspicion of additional seizure type (i.e. with focal features).
- (3) Clinical suspicion of non-convulsive (absence) status (AS).

EPILEPSY WITH PHANTOM ABSENCES (E-PA)

Overview.

The key diagnostic feature and the *defining* seizure type is *phantom absences* (PA), as the *only* type of absence on the EEG of typically young adults, who present with a first GTCS, or with an episode of AS frequently culminating in a GTCS. There is no past history of absences or myoclonic jerks, including childhood and early adolescence. All patients have GTCS and half of them may have one or more episodes of AS that do not dominate the clinical presentation. Absences (apart from phantom) and MS are not parts of this syndrome. Photosensitivity is rare. The syndrome is not self-limiting, but response to appropriate antiepileptic medication is satisfactory in most patients (Panayiotopoulos *et al.*, 1997; Koutroumanidis *et al.*, 2008).

Seizures: symptoms and semiology.

Note: *Phantom absences* have been recognized as a distinct type of TA (Engel, 2006), associated with very mild IoC that is imperceptible to patients and observers alike and detectable only with EEG recordings when clinical advanced protocols for detection of IoC during GSWD are used (box 2). As a type of seizure in GGE/IGE, PA can occur in the context of any absence syndrome, but it is the *only* type of absence in the syndrome of E-PA.

Phantom absences clinically manifest as brief hesitations, omissions or repetitions of a number or any other mistake during HV with breath counting (*supplementary figure 3.31*), a fleeting behavioural arrest (such as a momentary interruption of the respiratory rhythm during HV (*supplementary figure 3.32*), or errors detected by any method of clinical advanced assessment (box 2), which coincide with a 3-4-Hz GSWD, and reflect impaired concentration, motor execution, or both. Because of their clinical imperceptiveness, the age of their onset cannot be ascertained, and therefore the onset of E-PA has to be defined by the first overt clinical manifestation, usually a GTCS or an episode of AS that typically ends with, or is punctuated by, a GTCS.

GTCS occur in all patients, as in GTCS-a, but are generally more frequent and of later onset. Although they can also occur early after morning awakening, their circadian distribution varies more than in GTCS-a, as they may punctuate, or more frequently conclude variably long episodes of AS (Koutroumanidis *et al.*, 2008).

Episodes of AS can occur in about 50% of these patients and are not clinically different to those of any other syndrome of GGE/IGE (*supplementary figure 3.33*). They are more frequent than in GTCS-a, but do not dominate the clinical picture, as in the syndrome of ASE (see section on ASE and table 2).

SD, tiredness, and stress are principle precipitants for all seizure types.

EEG section.

Background. Normal.

Interictal paroxysms.

During wakefulness

Generalized spike/polyspike-wave discharges.

Incompletely generalized SWD.

Focal SWD.

All types of discharge are activated by HV (*supplementary figure 3.34*), particularly on awakening (*supplementary figure 3.35B*).

During sleep

Discharges are activated during non-REM sleep (*supplementary figure 3.35*).

EEG paroxysms that accompany ictal events.

Phantom absences. GSWD, usually with a polyspike component (GPSWD), from two to several seconds.

Note: it is important to bear in mind that PA are defined by the mild/clinically imperceptible IoC and not by their (brief as a rule) duration: a long GSWD that appears subclinical to basic conventional testing, but is associated with mild IoC to clinical advanced testing (*box 2*), is still a phantom absence and does not indicate another absence syndrome, such as JAE, unless of course the patient has also other absences of overt clinical presentation, either by history or recorded on the EEG (*supplementary figures 3.36 and 3.37*).

GTCS may punctuate or conclude an episode of ASE, or occur independently.

ASE (*box 3*).

Absences (other than phantom) and **MS** are not parts of this syndrome.

Recording protocols.

Note: the diagnosis of E-PA in a patient with GTCS without history of absences or MS requires the EEG demonstration of phantom absences as described above, but not of conventional absences and MS. PA may be demonstrable on routine EEGs, but for the reasons stated in the section of GTCS-a, it is recommended to encourage light sleep, even in level 1 recordings, provided that time allows. Consciousness during the typically brief GSWDs should be thoroughly assessed by *clinical advanced protocols* (*box 2*) on both basic and advanced recordings, provided that EEG technologists are suitably trained (see also *note in recording recommendations for GTCS-a*). Phantom absences may be associated with surprisingly brief discharges (*supplementary figure 3.38*).

Basic level

As for GTCS-a.

Advanced level

As for GTCS-a.

Levels of EEG diagnosis.

A) Confirmatory of E-PA in patients presenting with GTCS without history of earlier vacant spells or myoclonic jerks. Most of such patients would suffer from GTCS-a, however, electroencephalographers should be aware of, and explore the alternative possibility of E-PA, particularly when there is evidence of possible episodes of AS.

Recording phantom absences using clinical advanced assessment with a sufficient number of GSWD, but no conventional (clinically overt) absences or MS (for both SD advanced and basic EEG levels, particularly when the basic EEG contains spontaneous sleep).

B) High diagnostic certainty (probable). For both advanced and basic EEG levels without sleep or SD: recording of the typical brief GSWD without evidence of IoC by clinical basic or advanced assessment is highly supportive of GTCS-a, but still cannot rule out the probability of E-PA (see *levels of EEG diagnosis for GTCS-a*). Advanced SDEEG is recommended to assess IoC with a sufficient number of GSWD and move diagnostic certainty up to level A by detecting PA (or push diagnosis towards GTCS-a by excluding IoC in association with the GSWD). If advanced SD EEG is not available, repeat basic level including sleep with appropriate activation and assessment on awakening.

Note: Normal waking EEG (for both advanced and basic EEG levels) should prompt SDEEG advanced level to record GSWD and allow testing of the possibility of PA (see also *notes 1 and 2 in the relevant section of GTCS-a*).

Indications for video telemetry/ambulatory EEG.

- (1) Failure to record GSWD in sequential advanced SDEEGs, as in GTCS-a.
- (2) Clinical suspicion of additional seizure type (*i.e.* with focal features).
- (3) Clinical suspicion of non-convulsive (absence) status.

ABSENCE STATUS EPILEPSY (ASE)

Overview.

As the term indicates, ASE is characterized by recurrent, unprovoked episodes of AS, which is the *predominant and defining* seizure type for this syndrome. Most patients may have infrequent GTCS while few may have a history of, also infrequent, absences. Phantom absences and MS are not part of this syndrome, and photosensitivity has not been reported (*table 2*). In most patients, the syndrome starts between adolescence and early to mid-adulthood and,

although it is not self-limiting, response to appropriate antiepileptic medication is usually satisfactory (Genton *et al.*, 2008). As in the epilepsy with PA, episodes of AS occur without provocation and are not merely due to the aggravating effects of AEDs inappropriate for GGE/IGE (Thomas *et al.*, 2006).

Seizures: symptoms and semiology.

Recurrent episodes of AS is the key diagnostic feature (table 2). The severity of clouding of consciousness ranges from very mild to severe (*supplementary figure 3.39*).

GTCS occur in most patients, either in association with an episode of AS, or independently; in some patients, they may be the first overt clinical manifestation, but do not predominate the clinical presentation (*supplementary figure 3.40*).

Absences may occur in a few patients, either in childhood or later, but are infrequent and the whole clinical profile resists classification into the two recognized absence syndromes of CAE or JAE.

Independent **MS** and **phantom absences** (using clinical advanced protocols; box 2) are not parts of the syndrome (Genton *et al.*, 2008).

EEG section.

Background. Expected normal, or with non-specific abnormalities.

Interictal paroxysms.

During wakefulness

GSWD are at 3 Hz and typically brief (2-4 sec), occasionally reaching 5-6 sec. incompletely generalized and focal non-localizing discharges occur, as in other GGE/IGE (*supplementary figure 3.41*).

Hyperventilation can induce GSWD in some patients but not phantom absences (tested by clinical advanced methodology; box 2, *supplementary figure 3.41*, left trace and *supplementary figure 3.42*).

During sleep

Discharges are activated during non-REM sleep (*supplementary figure 3.43*) and awakening.

EEG paroxysms that accompany ictal events.

Absence status. For a description of the ictal EEG, the reader is referred to box 3. It is important to emphasize that arrhythmic patterns and slower frequencies than 2.5 Hz can occur late into the status and therefore do not indicate atypical AS, but they are still compatible with GGE/IGE (*supplementary figures 3.40 and 3.44*).

Generalized convulsions. These may punctuate or conclude an episode of AS (absence-tonic-clonic sequence; *supplementary figure 3.40*) (Genton *et al.*, 2008), or occur independently (tonic-clonic sequence).

TAs are rare.

Recording protocols.

Note 1: Diagnosis of AS **as a seizure type** in any given patient does not necessarily require actual EEG/video-EEG recording of AS (box 3).

Note 2: No syndrome of GGE/IGE is immune to AS. Therefore, actual recording of AS at the basic or the advanced EEG level does not necessarily indicate the diagnosis of the syndrome of ASE. The latter still requires that AS is the main seizure type.

Therefore, diagnosis of ASE requires the EEG demonstration of the typical interictal GSWD (or the actual recording of AS) in the appropriate clinical setting of episodes of AS, as the *dominant* seizure type. Genton and colleagues (2008) indicate that, although TAs may infrequently occur in some patients, phantom absences (PA) are not a feature of ASE; therefore, their exclusion as the sole type of absence is a secondary diagnostic requirement to differentiate ASE from E-PA, which also manifests with GTCS and in some patients with episodes of AS. It follows that the recommended diagnostic EEG strategy is identical to that described in the GTCS-a section, as it also aims to exclude PA (*supplementary figure 3.45*).

Levels of EEG diagnosis.

A) Confirmatory of ASE in patients presenting with a history of prolonged episodes of impaired cognition and GTCS. For both advanced SD and basic EEG levels when the latter include a period of sleep and awakening: Recording of the typical GSWD/GPSWD without evidence of IoC by advanced assessment.

B) High diagnostic certainty (probable). For basic waking recordings: recording of the typical GSWD/GPSWD without evidence of IoC by clinical basic or advanced assessment. Advanced SDEEG is recommended to rule out phantom absences with a sufficient number of GSWD and move diagnostic certainty up to level A. If advanced SDEEG is not available, repeat basic recording, trying to include sleep with appropriate activation on awakening and advanced assessment of cognition during GSWD.

Note 1: Normal waking EEG for both basic and advanced EEG levels should prompt advanced level SDEEG and assessment as above (see also notes in the relevant sections for GTCS-a and E-PA [3.4]).

Note 2: Although not indicated by the current evidence (Panayiotopoulos, 1998; Genton *et al.*, 2008; Koutroumanidis *et al.*, 2008), an overlap between ASE and E-PA may exist. It is possible, for instance, that some patients with clinically prominent episodes of AS may have phantom absences with advanced SDEEG and appropriate activation and testing of cognition during brief GSWD. This is an area where further

clinical EEG studies, using SDEEG with HV on awakening and any type of clinically assessment of cognition during GSWD, are needed.

Indications for video telemetry/ambulatory EEG.

- (1) Failure to record GSWD in sequential SDEEGs level 2, as in GTCS-a.
- (2) Clinical suspicion of additional seizure type (*i.e.* with focal features).

3.5. EYELID MYOCLONIA WITH or WITHOUT ABSENCES or Jeavons syndrome

Overview

Described by Jeavons in 1977, this syndrome is characterized by eyelid myoclonia, a distinctive type of regional epileptic myoclonus that is typically induced by eye closure in a sufficiently lit environment and can be associated with brief impairment of awareness (ELMA) and photosensitivity. Eyelid myoclonia is associated with eye closure EEG abnormalities, which are posterior or generalized with frequent accentuation over the occipital areas and typically disappear in darkness. Onset occurs in childhood with peak between six and eight years. Girls are affected 3-4 times more than boys. Most patients may have infrequent GTCS, while episodes of AS can occur in 20-25% of cases. Neurological examination and intellect are normal and neuroimaging is unremarkable. Jeavons syndrome may partially overlap with JME.

The clinical and EEG attributes of Jeavons syndrome place it within the spectrum of GGE/IGE with a defining strong reflexive component. Although photosensitivity can subside and even disappear with time and/or treatment, mainly with VPA, Jeavons syndrome is not self-limiting. It is probably the most pharmacoresistant of all the GGE/IGE with most patients improving on appropriate antiepileptic drugs (AEDs), but rarely attaining seizure freedom on moderate doses (Giannakodimos and Panayiotopoulos, 1996; Sadleir *et al.*, 2012).

Note: Eyelid myoclonia has been officially recognized by the ILAE as a distinctive type of epileptic seizure (Engel, 2006), but it must not be equalled to Jeavons syndrome. Some children (most with onset before the age of three years) and adults with typical eyelid myoclonia remain refractory to antiepileptic treatment and develop mild-to-moderate intellectual disability; some of them may have GTCS arising from sleep, or additional focal seizures. Presently, it is uncertain whether such phenotypes constitute variants of the eyelid myoclonia syndrome or are

distinct conditions (Capovilla *et al.*, 2009; Caraballo *et al.*, 2009).

Seizures: symptoms and semiology

Eyelid myoclonia is the defining seizure type. It consists of marked repetitive jerking of the eyelids often associated with upward eye movements and retropulsion of the head, and sometimes with jerks of the shoulders/upper limbs, head, or axial. There may be an associated tonic component, which may force the eyelids into a dystonic semi-open position. Eyelid myoclonia is typically activated by eye closure (not simple blinking) in *well-lit* environments, becoming maximal upon direct exposure to bright light, for instance, on bright sunny days, and to IPS. On the other hand, the electroclinical response attenuates in dim lighting and is abolished in darkness. Seizures may last for up to 5-6 seconds and can be associated with typically brief and subtle impairment of awareness (ELMA). Liability to eyelid myoclonia with or without absences is highest on awakening and typically increases by HV, SD, tiredness, and stress. Children and adults, when newly diagnosed or misdiagnosed and treated with AEDs suitable for focal seizures, may have hundreds of episodes per day.

Note: As an epileptic seizure, eyelid myoclonia is associated with eye-closure ED, described in the EEG section below. After many years of treatment, particularly with VPA, some adults may still exhibit episodes of eyelid myoclonia but without eye-closure epileptic EEG discharges. In such patients, paroxysmal clinical phenomena may be identical to the epileptic eyelid myoclonus, but cannot be classified as epileptic seizures.

Episodes of absence status may occur in about a fifth of patients, particularly those who are untreated, or treated with inappropriate AEDs, usually in the presence of facilitating conditions, such as awakening, SD, stress, alcohol, *etc.* Such patients report days with almost continuous eyelid jerking (and sometimes body jerks), associated with difficulty with concentration and other higher cognitive functions; some of these episodes of AS may end with a GTCS (*supplementary figure 3.52*).

Infrequent **GTCS** probably occur in most patients, following direct photic stimulation, in association with an episode of AS, or spontaneously. Precipitants are the same as for AS.

Independent **TAs** (not associated with eye-closure-induced eyelid myoclonia) may occur in some patients, mainly during HV and photic stimulation with eyes open, but also spontaneously. As a rule, they are infrequent and brief (*supplementary figure 3.53*).

Independent **MS** occur infrequently in patients with Jeavons syndrome (overlap with JME)

EEG section

Note: The EEG, particularly with video, is indispensable for the diagnosis and follow-up of people with Jeavons syndrome. From the preceding discussion on eyelid myoclonia as distinctive MS, it follows that patients with Jeavons syndrome can have three possible eye-closure electroclinical associations: (1) eyelid myoclonia, associated with eye-closure epileptic EEG activity with or without absences; (2) eye-closure epileptic EEG activity without associated obvious clinical changes (eyelid myoclonia or absences); and (3) eyelid myoclonia without associated eye-closure epileptic activity. (1) is the overt epileptic seizure and is treated in the section of ictal paroxysmal findings, (2) represents subclinical interictal activity and is described under the section of interictal abnormalities, while (3) is a non-epileptic event.

Background. Expected normal (or with non-specific abnormalities).

Interictal paroxysms.

During wakefulness

Eye-closure abnormalities occur within the first couple of seconds after the actual closure of the eyes and are brief, consisting of generalized spike/polyspike-wave discharges, frequently with occipital onset or accentuation (*supplementary figure 3.54*). The polyspike component is usually less prominent than in the (ictal) eyelid myoclonia in the same subject (see *ictal EEG features below*).

Interictal paroxysmal abnormalities not associated with eye-closure include:

- Generalized and incompletely generalized SWD, with anterior (*supplementary figure 3.55*) or posterior accentuation.
- Focal SWD, mainly occipital but also frontal (*supplementary figures 3.56 and 3.57*).

Hyperventilation can activate interictal generalized and focal SWD (*supplementary figure 3.58*), and episodes of eyelid myoclonia with or without absences (see *ictal EEG findings below*).

Intermittent photic stimulation (IPS) is most likely to induce eye-closure abnormalities, associated with eyelid myoclonia (see *ictal EEG findings below*). Subclinical generalized PPRs may occur in treated patients; some adults on chronic treatment with VPA may have mainly posterior PPRs only or (after many years) no PPRs at all.

During sleep

Generalized and focal discharges are activated during non-REM sleep, with anterior or posterior topography (*supplementary figure 3.59 and right panel of supplementary figure 3.60*).

Awakening activates discharges and susceptibility to eyelid myoclonia on eye closure (see *ictal findings below*).

EEG paroxysms that accompany ictal events.

Eyelid myoclonia with or without absences.

Ictal discharges occur within the first second after eye closure, typically with an obvious onset during the ascending slope of the positive eye-closure movement artefact. On occasions, the onset of the epileptic activity occurs just before the onset of the descending (positive) slope of the eye movement artefact, indicating the possibility that the eye closure itself could be part of the ictal manifestations rather than merely the seizure trigger (*supplementary figure 3.61*).

The typical discharge associated with marked eyelid myoclonia consists of high-voltage polyspikes or polyspikes-and-wave complexes and is generalized, occupying the whole of the cerebrum (*supplementary figure 3.62*).

A less common, paroxysmal pattern consists of diffuse low-voltage fast rhythms, also generated by eye closure. This may also give way to brief generalized “classic” 3-Hz spike-wave discharges that can be associated with mild impairment of awareness (ELMA) (*supplementary figure 3.60*).

The clinical/EEG ictal phenomena are typically short-lived even when eyes remain closed for longer (*supplementary figure 3.63*).

Activation and inhibition.

The occurrence of eyelid myoclonia requires that brightness of the environmental lighting is above a critical level for the epileptogenic threshold of the individual patient at a given time. The threshold is determined by the combined facilitating function of external factors (including SD and stress) on the inherent epileptic pressure, keeping also in mind that the latter fluctuates during the day (maximal on awakening); on the other hand, both clinical and EEG responses attenuate in dim lighting and disappear in darkness, or by any means that reduce the amount of light stimulation, for instance simple sunglasses (*supplementary figure 3.64*).

The susceptibility to eyelid myoclonia with or without absences is enhanced by **hyperventilation** when episodes can occur if eye closure is attempted during or immediately after the exercise (*supplementary figure 3.65*).

Susceptibility is maximal on awakening and for some time after, usually several minutes; during this period, eye closure is very likely to trigger eyelid myoclonia with or without absences.

Intermittent photic stimulation can trigger eyelid myoclonia, sometimes associated with axial jerks (*supplementary figure 3.66*), particularly in untreated patients or in those treated with the inappropriate AED. Unless PPRs occur when eyes are open, it is very difficult to convincingly distinguish the effect of eye closure from that of photic stimulation, which in most photosensitive patients tends to occur upon eye closure (see *section on photosensitivity [4.1]*). Occasionally, a dual response can be seen, probably reflecting eye closure/photosensitivity dissociation (*supplementary figure 3.67*).

Other seizures.

Absence status (see also *box 3*) may occur under conditions of extreme excitability with features characteristic for the syndrome (Agathonikou et al., 1998). Ictal recordings have shown repetitive (every 2 to 4 sec) generalized discharges of polyspikes and slow waves, associated with marked eyelid myoclonia. The flicker effect of the protracted eyelid jerking/tonic contraction and the associated movements of the eyes upwards (Evans-Mulholland effect) may kindle spike-wave discharges and patients appear unable to control their eyes open for several seconds. When they finally do manage to hold their eyes open, discharges may block with EEG normalization only until the next eye closure that will trigger a new cluster of eyelid myoclonia. Therefore, the electrographic pattern of AS is typically discontinuous with brief epochs of normal activity (*supplementary figure 3.52*).

Generalized convulsions may punctuate or conclude episodes of AS, but there is insufficient evidence to establish which of the sequences (absence-tonic-clonic, clonic-tonic-clonic, or tonic-clonic) is the commonest, if any.

Absences are associated with regular or irregular 3-4-Hz GSWD (*supplementary figure 3.53*).

MS are associated with high-voltage spike/polyspike-wave discharges (*supplementary figure 3.64*) (see also *section on JME [3.3]*).

A note on self-induction (SI).

SI is not part of Jeavons syndrome, but it may occur and complicate treatment if not identified. As SI may not be clinically suspected before the first EEG, a brief description of suggestive electroclinical features is provided here.

There are two principal eyelid/eye movement-related manoeuvres that, in the presence of adequate light, can induce spike-wave activity, and can be suspected from the EEG and video EEG: (1) fast blinking, and (2) voluntary, prolonged eye closure with extreme rolling of the eyes upwards. It is conceivable that the former

aims to produce a fast flicker-like effect, while the latter increases alpha activity more than a normal eye closure (such as an eye closure on command), facilitating paroxysmal activity. A combination of both is commonly employed.

In terms of EEG, volitional fast blinking may produce some identifiable eye movement artefacts and can be recorded on video when the patient is left alone and bored (*supplementary figure 3.68*).

The voluntary prolonged eye closure differs from the eye closure on command in that the produced positive biphasic eye closure artefact is longer and followed by a high-voltage negative deflection (responsible for the Evans-Mulholland effect) that corresponds to the upwards rolling of the eyeballs (*supplementary figure 3.69*). As with fast blinking, the complex manoeuvre of slow eye closure and upward rolling of the eyeball can be more easily identified when patients are inactive and bored, particularly in a moderately lit EEG room (*supplementary figure 3.70*).

Hand-waving is the preferred manoeuvre for SI of photosensitive patients with learning disabilities and is not seen in patients with Jeavons syndrome.

Recording protocols

Basic level

– **Time:** morning (first appointment of the day, if possible).

– **Activation:**

Encourage light sleep, if the patient appears drowsy and time allows. Record a number of eye closures on command before HV with the room well-lit and in relative darkness. Repeat a number of eye closures on command on awakening (if sleep is achieved) and after HV, again with good ambient light and in relative darkness. If eyelid myoclonia occurs, ask the patient to close their eyes several times while counting to assess for IoC (ELMA). As eye closure abnormalities are brief, **clinical basic** assessment of consciousness/responsiveness (for instance, by loudly providing numbers or names by the technologist) is likely to be negative and breath counting is recommended instead. It is also advisable to use this method in case absences occur during HV, as they are typically brief and mild (*supplementary figure 3.53*).

– IPS as per photosensitivity protocols (see *section 4.1*).

– **Polygraphy:** bilateral deltoid EMG is important if there is a history of limb jerking, and it may be worth using one or two EEG channels for EMG if additional channels are not available.

Advanced level

– **Time:** first appointment of the day.

– **Sleep recordings** after partial SD are recommended for initial EEG assessment; allow the patient to reach Stage 2 and maintain sleep for at least 15-20 minutes; record for at least 30 minutes after awakening, including activation.

If two video cameras are available, one should focus on the patient's eyes/face and the other should include the whole body.

– **Activation:** as per basic level (above), before sleep and on awakening. If overlap with JME is suspected, proceed according to the relevant chapter.

– **Polygraphy:** bilateral deltoid EMG, even without history of limb jerking (see also JME [3.3]).

If self-induction is suspected based on history or EEG findings, compare voluntary eye closures to those on command, and if possible, leave the patient alone in the recording room under video monitoring.

Levels of EEG diagnosis

A) Confirmatory based on clinical suspicion of eyelid myoclonia with or without absences. (For both basic and advanced recordings): recording of typical episodes of eyelid myoclonia consistently associated with eye closure paroxysms (*with* absences if there is evidence of IoC based on clinical advanced assessment). As for the other GGE/IGE syndromes, initial assessment at the advanced level should employ SDEEG. Nevertheless, there is no clinical need to perform SDEEG if a basic level waking EEG is already diagnostic of the syndrome. *For overlap with JME, see section 3.3.*

B) High diagnostic certainty (probable). For basic level: recording of the typical "interictal" and consistent eye closure paroxysms without associated eyelid myoclonia. Advanced level SDEEG may record the clinical hallmark of the syndrome (eyelid myoclonia) and move diagnostic certainty up to level A. If advanced level SDEEG is not available, repeat basic EEG, trying to include sleep with appropriate activation and assessment on awakening.

C) Low diagnostic certainty (possible). For both basic and advanced EEG levels: inconsistent eye closure paroxysms (for example, based on a few eye closures on command only) with photosensitivity without eyelid myoclonia. Findings are indicative of photosensitive epilepsy, but not sufficiently supportive of Jeavons syndrome, and should prompt advanced SDEEG, as above.

Indications for video telemetry/ambulatory EEG.

- (1) Clinical suspicion of additional seizure type (*i.e.* with focal features).
- (2) Suspicion of self-induction from EEG level 1 or 2.

4. Reflex epilepsies

4.1. PHOTSENSITIVITY and VISUAL SENSITIVITY

Overview

Visually-induced seizures are by far the most common type of reflex seizures and they can be observed in a wide spectrum of epilepsy types and epilepsy syndromes. Visually-induced seizures can be triggered by IPS in the EEG laboratory, as well as by environmental stimuli. Environmental precipitating factors include flickering sunlight, artificial intermittent lights, television, computer screens, and striped black and white patterns. Videogames (VG) can also precipitate seizures and indeed VG-induced seizures can reveal photosensitivity in the age groups that are most likely to use VG, or in subjects that never had seizures before. A distinction has been made between the epileptiform EEG response to IPS, *i.e.* the PPR (*see below for the definition*), and the clinical manifestations evoked by IPS and/or other types of visual stimuli. The detection of an IPS-induced PPR defines the patient as IPS-positive or photosensitive, whereas visual sensitivity refers to the susceptibility toward experiencing seizures that are triggered by IPS or by the physical properties of other types of visual stimuli, and not by their perceptual properties (*i.e.* reflex seizures induced by the cognitive effects of visual stimuli) (Kasteleijn-Nolst Trenité *et al.*, 2001, 2012a).

Classification of EEG responses to IPS

IPS can elicit a variety of EEG responses, with different clinical significance. Since methodological aspects are crucial, efforts have been made in recent years to standardize the methods and the interpretation of the results of IPS (Kasteleijn-Nolst Trenité *et al.*, 2012b). A recent classification proposal has identified the following types of IPS-induced EEG responses (Kasteleijn-Nolst Trenité *et al.*, 2001; Rubboli *et al.*, 2004):

- (1) Photic following: a normal response that ends with termination of the stimulation.
- (2) Orbitofrontal photomyoclonus: a mainly electromyographic (although a frontal cortical component has been hypothesized) response occurring at the same flash frequency, terminating at the end of stimulation or when the eyes open (*supplementary figure 4.01*).
- (3) Posterior stimulus-dependent response, representing an anomalous unusually sharp visual evoked potential of high amplitude, at the stimulus frequency.
- (4) Posterior stimulus-independent response, which includes theta-delta activity, and clear-cut epileptiform patterns, not following the flash frequency or its

harmonics, with two subtypes: (a) limited to the stimulus train, or (b) self-sustained; the latter may evolve to an overt seizure.

– (5) Generalized PPR, consisting of multiple spikes or spike-wave activity, apparently generalized, with anterior predominance. This can be limited to the stimulus train or be self-sustaining (*i.e.* continuing after stimulation). This response is considered to be linked to epilepsy and visually induced seizures (Waltz *et al.*, 1992; Kastelien-Nolst Trenité *et al.*, 2001) (*supplementary figure 4.02*).

– (6) Activation of pre-existing epileptogenic areas: this refers to the rare possibility of the activation of a spontaneously, posteriorly located, epileptogenic cortex. Its significance as a PPR is still debated.

The photoparoxysmal response (PPR).

The PPR is an epileptiform EEG response to IPS, related to epilepsy and visually induced seizures (Waltz *et al.*, 1992; Kastelien-Nolst Trenité *et al.*, 2001). PPR is characterized by multiple spikes or by spike-wave activity, apparently generalized, with anterior voltage predominance and not infrequently posterior lead-in, limited to the stimulus train or self-sustaining (*i.e.* continuing after stimulation) (*supplementary figure 4.02*). It must be pointed out that, depending on the flash frequency used, age at investigation, use of medication, and possibly sleep adequacy, the topography of the PPR can vary even in the same patient, being posterior with variable forward spread or generalized (Koutroumanidis *et al.*, 2015). A PPR has been reported in normal subjects with prevalence rates varying from 1.4% to 8.9%. In addition, a PPR has been found in up to 30% of patients with migraine with aura (Kasteleijn-Nolst Trenité *et al.*, 2012a).

Seizures: symptoms and semiology

Clinical manifestations associated with visual sensitivity, either related to IPS or other types of visual stimuli can be (Kasteleijn-Nolts Trenité *et al.*, 2001):

– Mild subjective symptoms, such as seeing coloured lines or colours, dizziness, eye pain, epigastric discomfort, nausea, or simple visual hallucinations.

– Orbitofrontal photo myoclonus (OPM) (also called frontopolar or photomyogenic, or photo-oculoclonic response): rapid myoclonic jerking of the periorbital muscles, producing eyelid fluttering and blinking (*supplementary figure 4.01*); induced only when eyes are closed, and blocked by eye opening or cessation of stimulation. If IPS continues, myoclonia can spread to other muscles. It is more common in adults and older subjects.

– Eyelid myoclonus: this can be a very short phenomenon, lasting 1-2 seconds or more prolonged, and associated with an absence seizure as in “absences

with eyelid myoclonia” (*section 3.5*). At variance with OPM, the delay between triggering stimulus and ensuing eyelid myoclonia is longer. Deliberate fluttering of the eyelids associated with hyperextension of the head in front of intense light occurs in the context of self-induction (*see relevant section on eyelid myoclonia - Jeavons syndrome [3.5]*).

– Generalized myoclonus: this predominates in the upper limbs and can be asymmetric (*supplementary figure 4.03*). Rhythmic jerks at the same frequency of IPS have been reported in the context of photic reflex myoclonus (Rubboli *et al.*, 1999); if IPS is protracted, a GTCS may ensue.

– Absence seizures: absences may be triggered by IPS or by other visual stimuli (*supplementary figure 4.04*).

– Tonic versive seizure: eye and head deviation induced by IPS have been described as a feature of simple partial seizures that can evolve to complex partial seizures or eventually to GTCS.

– Partial seizures: an occipital onset can be detected in up to 65% of the patients with visually induced seizures. Symptoms often consist of a sequence of visual and vegetative phenomena, sometimes accompanied by headache. Visual symptoms include both simple (bright, multicoloured rings, continuous or flashing geometric forms, followed by amaurosis or severe blurring of vision, located in a quadrant, hemifield or entire field) as well as complex visual symptoms (macropsia, micropsia, and a wide range of visual hallucinations or illusions). Rapid spread, as well as a remarkably slow propagation with ictal activity confined to the occipital regions for minutes, have been described (Guerrini *et al.*, 1995) (*supplementary figure 4.05*).

– GTCS: these occur usually, but not always, after prolonged exposure to visual stimuli, and can be preceded by an absence, myoclonic jerks, or by a partial seizure.

Photosensitivity, visually induced seizures and epilepsy.

A wide spectrum of epileptic conditions with different aetiologies (*i.e.* idiopathic, cryptogenic, and symptomatic) can show a photosensitivity trait and visual sensitivity (Kasteleijn-Nolst Trenité *et al.*, 2012a).

The epilepsy types and syndromes in which photosensitivity and visually induced seizures are predominantly found are:

- In idiopathic generalized epilepsies:
 - Benign myoclonic epilepsy in infancy
 - Childhood absence epilepsy
 - JAE
 - JME
 - GTCS on awakening
 - Primary reading epilepsy

- Visually sensitive IGE (that include pure photosensitive IGE, in which seizures are triggered only by visual stimuli, and ELMA)
- In other epilepsies with or without encephalopathies:
 - Myoclonic-astatic epilepsy
 - Dravet syndrome
 - Progressive myoclonus epilepsies
- In focal epilepsies:
 - Idiopathic photosensitive occipital lobe epilepsy (OLE)
 - Non-idiopathic photosensitive OLE
- In patients with self-induction behaviour: this phenomenon is observed in photosensitive patients who deliberately perform certain manoeuvres (such as waving one's hand rhythmically in front of the eyes or eye blinking, or looking at a bright light) or expose themselves to certain situations (such as looking closely at a TV set) that are effective in eliciting their own seizures. Some data suggest that self-induction behaviour can be observed in up to 30% of visually-sensitive patients. Video-EEG recording can be extremely useful to detect this phenomenon (see also the note on self induction in the preceding section).

EEG section

Background. Depends on the epilepsy syndrome or type.

Interictal paroxysms during wakefulness and sleep. As above, occurrence and features of interictal ED is related to the epilepsy syndrome or epilepsy type. During IPS, the EEG responses listed above can be observed.

EEG paroxysms that accompany ictal events (after visual activation).

Ictal EEG features of visually induced seizures are primarily related to the seizure type. For example:

- An IPS-induced absence seizure occurring in a visually-sensitive patient with GGE/IGE can show a typical 3-Hz spike-and-wave discharge triggered by the stimulus train (*supplementary figure 4.04*).
- An IPS-induced MS is characterized by a myoclonic EMG burst associated with an irregular spike-polyspike-wave discharge, triggered by the visual stimulus (*supplementary figure 4.03*).
- An occipital seizure, as in idiopathic photosensitive occipital epilepsy, can be characterized by a prolonged focal discharge that is initially confined to the posterior areas, for up to several minutes, but can eventually become more diffuse, or even evolve into a GTCS (*supplementary figure 4.05*). Onset of the ictal discharge over the temporal-parietal-occipital regions,

with spread to other areas and eventually evolution to a GTCS, has also been reported.

- A visually-induced GTCS can show an abrupt onset with a diffuse tonic contraction (often preceded by some myoclonic bursts, the EMG correlate of which may mask the initial EEG) (*supplementary figure 4.06*). On some occasions, an onset characterized by a burst of slow waves or of diffuse polyspike-slow wave activity, or even by a brief posterior discharge, can be observed.

Recording protocols

As previously mentioned, the detection of photosensitivity in the EEG laboratory can be significantly affected by the visual stimulation methods. A European algorithm that includes a basic level (level 1) and a higher level of sophistication (level 2) for the IPS procedure has been recently proposed (Kasteijn-Nolst Trenité *et al.*, 2012b). We outline here the main features of the two levels (*for further details see Kasteijn-Nolst Trenité et al. [2012b]*).

Level 1 aims to gather as much information as possible and in a concise way for clinical purposes, without the goal to lower the epilepsy threshold but simply to assess whether there is a susceptibility to visual stimuli in daily life. Assessment of photosensitivity at level 1 should be performed according to the following procedure:

- Collect relevant clinical information before starting IPS: the probability to obtain a PPR is affected by several factors, such as SD, alcohol abuse, and drug withdrawal. Previous occurrence of seizures provoked by TV, sunlight, or computers, and history of visually induced seizures in family members should be investigated.
- Perform simultaneous video-EEG recording, if possible.
- Record EMG activity from both deltoids to detect subtle myoclonic phenomena, if adequate channels are available.
- Perform IPS at least 3 mins after HV or before HV.
- Use dim room lighting with the patient sitting upright.
- For patients with suspected fixation-off sensitivity (FOS), perform additional testing (see section 4.3).
- Record at least for 2.5 mins with eyes open and 2.5 mins with eyes closed before starting the actual IPS procedure.
- Use a lamp with a circular reflector (with flash intensity of at least 0.70 Joule) and viewing distance of 30 cm.
- Stop the visual stimulus immediately as soon as generalized epileptiform discharges occur during any flash frequency.
- Determine IPS sensitivity in three eye conditions with separate trains of flashes of 5-sec duration each

during eyes open, eye closure, and eyes closed. If there is not enough time, choose eye closure (closure of the eyes on command at the start of a flash train) and stimulate for 7 secs per flash frequency.

- Use the following flash frequencies separately. Recommended IPS frequencies and order of stimulus delivery are: 1 - 2 - 8 - 10 - 15 - 18 - 20 - 25 - 40 - 50 - 60 Hz. If there is a generalized PPR at a certain frequency (lower threshold), skip the remaining frequencies of the series and start again from 60 Hz with subsequent decrease (60 - 50 - 40 - 25 Hz- ...) until again a generalized PPR occurs (upper threshold). Self-limiting and self-sustaining PPR have the same clinical significance and therefore both can define the upper and lower thresholds. When in doubt whether a particular frequency has provoked a generalized PPR, repeat the frequency after a pause of 10 sec or use a frequency with a difference of 1 Hz.

- Whenever possible, test other known precipitating stimuli (for instance, the patient's own videogame).

- Test the protective effects of coloured lenses (Capovilla *et al.*, 2006); sometimes patients' own ordinary sunglasses may also be effective.

- Observe clinical signs during the PPRs and ask the patient about any complaints he/she might have felt.

The procedure described above requires 5 mins of IPS at maximum when the patient is either not sensitive or sensitive to only one frequency; in this case, all frequencies are performed only once and upon reaching 60 Hz, the stimulation can be stopped. Otherwise, the duration will be shorter; in fact, the more sensitive a patient, the less time it will take, because stimulation stops at the lower and upper threshold frequencies. This procedure allows the identification of a sensitivity range for the individual patient that relates to their likelihood of seizures in daily life, and can be modified according to age and use of AEDs.

Level 2 aims to gather as much information as possible either for clinical or research purposes. By using a greater range of visual stimuli, a more precise individualized advice about potential provocative visual stimuli and therapeutic measures can be given. This level should be performed in patients with a history of seizures, possibly precipitated by visual stimuli other than flickering lights (such as patterns, videogames, or TV), in particular if they resulted negative to level 1 investigations, and also as a further step in the investigation of photosensitivity/visual sensitivity in patients that resulted photosensitive in level 1.

Level 2 assessment should be performed according to the following procedure:

- Allow extra time, as adequate number of trials and additional stimulation procedures will be performed. This might also require recording after sleep-deprivation.

- The whole recording procedure must be performed with video-EEG recording.

- Use electrodes for recording eye movements. This may allow more precise discrimination between the different eye conditions and might also help to detect self-induction with slow eye closures.

- Record surface EMG activity electrodes from the deltoids. When necessary, other muscles may be monitored to investigate topography and spread of visually-induced myoclonic phenomena.

- Test IPS sensitivity separately under three eye conditions (eye closure, eyes closed, and eyes open).

- Use the following flash frequencies in this order: 1 - 2 - 6 - 8 - 9 - 10 - 13 - 15 - 18 - 20 - 23 - 25 - 30 - 40 - 50 - 60 Hz. If there is a generalized PPR at a certain frequency, skip the remaining frequencies of the series and start again from 60 Hz with subsequent decrease (60 - 50 - 40 - 30 - 25 Hz- ...) until again a PPR occurs. Retesting the photosensitive patient with an expanded range of frequency, as compared to level 1, allows for more precise determination of the photosensitivity range.

- Perform stimulation sessions with coloured flashes in patients with a history of TV and videogame seizures.

- Perform pattern stimulation with black and white, evenly striped patterns (central fixation of gratings that are circular in outline must be assured; spatial frequency between 2 and 4 cycles per degree, Michelson contrast >0.8, mean luminance of at least 300 cd/m) in a well-lit room or on an LCD monitor with a steady backlight. Present patterns of increasing size (radii of 3, 6, 12, and 24 degrees); terminate the series if a PPR occurs. In one series, the stripes are black and white and in a second series they are red and blue.

- Test the patient with video games and cartoons on TV and computer screens, including the patient's own videogame if appropriate.

- As for level 1, test the protective effects of coloured lenses.

- As for level 1, observe clinical signs during the PPRs and ask the patient about any complaints he/she might have felt.

Levels of EEG diagnosis

A) Confirmatory of photosensitivity (definite). (Both recording levels 1 and 2): detection of a PPR to IPS allows the patient to be diagnosed as photosensitive. This can be a confirmatory finding in a patient with a clear history of visually-induced seizures. However, detection of a PPR can be an unexpected finding in a patient not known to be photosensitive or visually sensitive; in this case, the clinical history should be further investigated to search for unreported or unrecognized visually-induced clinical manifestations or seizures.

B) High diagnostic certainty (probable) photosensitivity. (Recording level 1): detection of stimulus-independent EEG responses, other than generalized PPR (for instance posterior), particularly when self-sustained, in a patient with a history of seizures, probably precipitated by visual stimuli. Level 2 recording is recommended. Detection of a generalized PPR at recording level 2 will provide level A diagnosis; absence of a generalized PPR will maintain a level B diagnosis (probable).

C) Low diagnostic certainty (possible) photosensitivity. (Recording level 1): no detection of a PPR induced by IPS in subjects with a history of epileptic seizures, probably or possibly precipitated by visual stimuli. Level 2 recording is recommended: as above, occurrence of a PPR will provide level A diagnostic evidence (definite photosensitivity); absence of abnormal response to IPS at level 2 rules out photosensitivity (Kasteleijn-Nolst Trenité *et al.*, 2012b).

Precipitation of clinical manifestations or seizures by IPS or other visual stimuli (recording levels 1 and 2) is confirmatory of **visual sensitivity**.

4.2. READING EPILEPSY

(including also language epilepsy)

Overview

Reading epilepsy is a distinct form of reflex epilepsy in which all or almost all seizures are triggered by reading. The term “language epilepsy” is appropriate when other linguistic activities, such as writing or talking, are also consistent seizure triggers. The age at onset of seizures ranges between 10 and 30 years, and up to a quarter of the affected people report positive family history of epilepsy, including reading-induced seizures. Reading-induced seizures include: (1) typically, brief myoclonic jerks/abnormal sensation of jaw, tongue or perioral regions; (2) less frequently, prolonged focal seizures, manifested by paroxysmal alexia/dyslexia; and (3) occasionally, absences. Resting routine EEG is typically normal, showing focal, diffuse or even generalized sharp/spike-wave discharges only during activation with reading. Neurological and neuropsychological examinations and brain MRI are normal. There is variable and, not infrequently, limited response to antiepileptic treatment, but seizures tend to abate with age (Radhakrishnan *et al.*, 1995; Koutroumanidis *et al.*, 1998). Therefore, reading or language-induced epilepsy is a possibly genetic form of reflex epilepsy with generalized and focal seizures (see also *introduction*); occasionally though, it may associate with a clear focal structural lesion, mainly involving the dominant frontal areas.

Seizures: symptoms and semiology

Myoclonic. Most frequently, reading-induced seizures consist of brief jaw or oro-facial myoclonus, or a “clicking sensation”, occurring in clear consciousness; EEG-polygraphy shows usually bilateral sharp/spike-wave discharges of variable distribution (but often with left sided emphasis), associated with EMG potentials from the perioral or sub-mental muscles. Reading-induced perioral myoclonus may progress into GTCS if reading continues (see *below*).

Focal seizures associated with alexia/dyslexia. Far less frequently, though, this may be underestimated, reading-induced seizures are *prolonged*, associated with alexia and focal ictal EEG activity, typically involving the left posterior temporal/parietal areas. These seizures can also evolve into GTCS.

Absences. Reading-induced absences are exceptional.

Generalized tonic-clonic seizures. These can either follow reading-induced MS or evolve from focal seizures with ictal dyslexia of typically lateral-posterior temporal onset.

Note: As in other complex reflex epilepsies, reading-induced seizures develop after a certain amount of reading time, the duration of which may depend on the overall hyperexcitability of the neuronal system that serves language function in relation to other seizure threshold modulators (such as SD), at a given time. Due to this latency and the need to assess possible additional language-related triggers, it is essential to *allow adequate time* when planning diagnostic EEG recordings in patients with suspected reading-induced seizures, *employ partially sleep-deprived EEG*, and activate with reading *after awakening* (see *recording protocols*).

Other epilepsies with reading-induced seizures. Some patients with JME may experience reading-induced MS that may also involve the upper limbs. Also, there are very few reported patients with reading-induced seizures or epilepsy of structural aetiology, typically with left frontal vascular lesions (Lee *et al.*, 1980; Ritaccio *et al.*, 1992; Radhakrishnan *et al.*, 1995).

EEG section

Background. Normal; possible focal disturbance when aetiology is structural.

Interictal paroxysms during wakefulness and sleep.

Variant with jaw myoclonus. Typically, there are no ED; occasionally, bilateral spike-wave discharges and even unilateral (mostly left-sided) spike-wave complexes can occur.

Variant with prolonged ictal alexia. Typically, there are no ED; some patients may have left posterior temporal

spikes (Radhakrishnan *et al.*, 1995; Koutroumanidis *et al.*, 1998; Maillard *et al.*, 2010) or fast rhythms during sleep (Koutroumanidis *et al.*, 1998).

EEG paroxysms that accompany ictal events (activation upon reading).

Variant with jaw myoclonus. Ictal discharges typically consist of mostly single sharp waves, or sharp-and-wave/spike-and-wave complexes that occur *intermittently*, punctuating the normal background (*supplementary figure 4.07*). Their topographic distribution may vary widely despite the remarkably uniform and stereotyped ictal manifestation (jaw myoclonus); bilateral synchronous, symmetric or asymmetric, and strictly lateralized topographies have all been reported in fairly similar proportions. Asymmetric or focal discharges are usually temporal-parietal, more often lateralized to the language-dominant hemisphere (Radhakrishnan *et al.*, 1995; Koutroumanidis *et al.*, 1998). Not all ictal discharges are associated with EMG potentials from the jaw muscles (*see recording recommendations below*).

Variant with prolonged ictal alexia. Subclinical spike-wave or delta wave activation of the left posterior temporal areas may occur shortly after the onset of reading (*supplementary figure 4.08A*), but actual seizures typically occur after reading for longer with reported times in the literature ranging from 3 to 19 minutes (*supplementary figure 4.08B and C*). To date, rhythmic spikes and theta and fast activities have been associated with alexia in 14 reported seizures from eight patients in separate publications; 11 seizures occurred on the left and three patients had bilateral independent seizure onsets.

Recording protocols

General instructions applying to both basic and advanced levels

- (1) Allow extra time.
- (2) Before the actual EEG activation, technologists should interview the patient with suspected reading-induced seizures to compile a personalized working list of possible effective triggers to test in addition to standard testing (*see basic level below*), as well as possible reading-induced ictal symptoms which should be investigated, in order to shape an optimal recording strategy (position of EMG electrodes, close-up camera, etc.).
- (3) Technologists should also instruct patients to signal their habitual symptoms; EEG discharges may or may not produce symptoms, and when they do they are not always associated with identifiable EMG potentials (*supplementary figure 4.07C*), for instance, in patients with mainly sensory - “clicking sensation” - symptoms, those with paroxysmal alexia, or simply in the case

of excessive perioral physiological EMG activity when reading aloud.

Basic level

- Prolonged waking EEG with HV and photic stimulation; include sleep if possible, in which case perform activation with reading on awakening.
- Specific activation with reading silently and aloud for a few minutes aiming to induce asymptomatic ED or reproduce the habitual reading-induced symptoms; use the most provoking triggers, as reported by the patient (for example, small prints or complex text). Depending on the particular clinical evidence, the availability of time, and the expertise of the technologist, modified versions of the full protocol, as proposed in the advanced level below, can also be tested.
- Polygraphy: sub-mental EMG if possible.

Advanced level

- Prolonged EEG during wakefulness and sleep after partial SD with HV, photic and, if possible, *pattern* stimulation.
- Specific activation under continuous video-EEG monitoring should be performed after awakening and include: reading, silently and aloud, of material that patients believe is most provocative (as in basic recording above). Activation should also include reading of simple and complex texts in the native and foreign languages, known and unknown, speaking and listening to conversation, writing to dictation and performing crossword puzzles, and drawing and copying geometrical figure.
- Subclinical focal or generalized EEG activation usually occurs soon after the onset of reading, therefore each of the above activities would require a few minutes to test, and screening of the full protocol may take less than 30-45 minutes to complete.
- Polygraphy: sub-mental and deltoid EMG. Sub-mental electrodes are mandatory even when video monitoring is in use, while deltoid electrodes should be used when overlap with JME is suspected by history.

Levels of EEG diagnosis

[Clinical suspicion of reading or language-induced seizures/epilepsy]

A) Confirmatory of the diagnosis of reading epilepsy in untreated adolescents/young adults without (or with only rare) spontaneous seizures. (For both basic and advanced recording levels): recording of jaw myoclonus or paroxysmal alexia with typical subclinical build-up upon activation with reading, and typical ictal EEG presentation.

B) High diagnostic certainty (probable reading epilepsy). (For both basic and advanced recording levels): no reading-induced seizure recorded, but sub-clinical activation of the EEG during reading (for

example, spikes over the left posterior temporal area; *supplementary figure 4.09*).

Subclinical EEG activation can be operationally defined as the consistent occurrence of paroxysmal activity (spikes, sharp or theta/delta) in response to reading or any other linguistic activity. Typically, the resting waking EEG is normal, but when it contains spontaneous discharges, a *consistent* clear increase of the spike density (spikes per minute) during the task may also be considered as activation. Such findings support the clinical diagnosis with **high diagnostic certainty**. Proceed with (or repeat) advanced EEG to trigger a seizure and move diagnostic certainty to level A.

C) Low diagnostic certainty (possible). (For basic recording when the resting waking EEG contains epileptiform discharges): no jaw myoclonus or paroxysmal alexia recorded, but increased density of epileptic activity under provocation, although less than twice the baseline rate. Reading epilepsy or reading-induced seizures cannot be ruled out and advanced recording (under SD) is recommended. If the latter does not fall within A or B, the diagnosis of reading epilepsy is unlikely.

Indications for repeating advanced SD recording.

- (1) Resistance to appropriate AED (VPA, LEV, CLZ, CBM).
- (2) New trigger reported/suspected.

Indication for video telemetry.

Clinical suspicion of additional (spontaneous) seizures.

4.3. FIXATION-OFF SENSITIVITY (FOS)

Overview

FOS is a reflex EEG phenomenon triggered by elimination of visual fixation, which is mediated by central vision (Panayiotopoulos, 1998). FOS can be *suspected* from the very first “pages” of the EEG when epileptiform discharges constantly occur for as long as the eyes are closed and substantially attenuate (or disappear) upon eye opening; such behaviour should prompt formal testing. FOS is more pronounced after awakening and can habituate. FOS is considered as a mainly electrographic phenomenon and seizures related to FOS have rarely been reported (*supplementary figure 4.10*). FOS is mainly encountered in Gastaut occipital epilepsy and Panayiotopoulos syndrome (when the latter is associated with occipital paroxysms) and in GGE/IGE, but only occasionally in occipital epilepsies of structural/unknown aetiology (Gobbi, 2005; Ferlazzo *et al.*, 2010) (see also section on OLE [5.3]). FOS has also been reported in generalized epilepsies of unknown cause, and even in some children and adults without

epileptic seizures. Despite the distinctly contrasting conditions that are required for photosensitivity and FOS (PPRs depend on central vision and fixation), the two occipitally-based reflex mechanisms may co-exist in some patients with GGE/IGE (Koutroumanidis *et al.*, 2009).

Diagnosis of FOS requires the demonstration of epileptiform discharges in a well-lit EEG room, when eyes are open but visual fixation is impeded, for instance, by using translucent spherical lenses (*supplementary figure 4.11*).

Seizures: symptoms and semiology

Occipital and generalised FOS EEG discharges are typically subclinical and reports on patients with seizures related to FOS are rare. The type of seizure depends on the syndrome or the epilepsy type: examples have included wandering and lack of balance/falls in Gastaut occipital epilepsy (Beaumanoir *et al.*, 1989), multiple, erratic and arrhythmic twitching in the face, head and limbs in a patient with MERRF syndrome (Garcia Silva *et al.*, 1987), absences (Koutroumanidis *et al.*, 2009) and AS (Ming and Kaplan, 1998) in GGE/IGEs with absences, and myoclonic jerks in JME (*supplementary figure 4.12*).

EEG section

Background. Depends on the epilepsy syndrome or type; expected normal in most cases.

Interictal paroxysms during wakefulness and sleep.

Depending on the epilepsy syndrome, ED can be generalized, often with posterior emphasis, or occipital (see *relevant chapters*).

Note 1: FOS occurs when *volitional* fixation is abolished and appears to involve alpha rhythm generators (alpha can be induced by blocking fixation without changing the lighting conditions). It follows that FOS-related EEG abnormalities will not occur after alpha dropout and throughout sleep. However, a sleep EEG (particularly after partial SD) is useful as, beyond the additional diagnostic information about the underlying epilepsy syndrome or epilepsy type, it is expected to augment FOS upon awakening (*supplementary figures 4.10 and 4.12*).

Note 2: FOS is manifested with “eyes closed” EEG abnormalities that appear *after* the eye closure artefact and continue to occur *for as long as* eyes remain closed, while photosensitivity is often associated with “eye closure” abnormalities that are brief and transient and coincide with the positive deflection of the eye closure artefact (see *relevant chapter*). Sometimes, photosensitivity and FOS may co-exist in the same patient, resulting in complex EEG patterns (*supplementary figure 4.13*).

EEG paroxysms that accompany ictal events (activation with fixation-off).

FOS-triggered seizures are rare, and ictal findings depend on the underlying epilepsy syndrome (*supplementary figures 4.10 and 4.12; see also relevant chapters*).

Recording protocols

Both recording levels

Allow extra time, as adequate number of eyes open/eyes closed trials with different goggles are needed to show consistency of the FOS-related responses.

Instruct patients with EEG evidence of FOS to report any symptoms when their eyes are shut or while goggles are “on”.

Trials with different goggles are the same for both levels.

Complete darkness can be achieved by common underwater goggles completely covered by black adhesive tape; simply turning off the lights may still allow fixation if a tiny spot of light is “on”. Underwater goggles covered with common semitransparent adhesive tape can be a simple, effective, and inexpensive alternative to spherical lenses, while Ganzfeld stimulation can be used in less co-operative patients.

Basic level

- Prolonged waking EEG with HV, and photic stimulation.
- Polygraphy: bilateral (deltoid) EMG, if possible.

Advanced level

- Record during sleep after partial SD with FOS assessment on awakening; HV and photic stimulation.
- Polygraphy: bilateral (deltoid) EMG.

Levels of EEG diagnosis

Like photosensitivity, electrographic-only FOS can occur in a number of epilepsy syndromes, but also in people without epileptic seizures; FOS-related seizures can also be part of various epilepsy syndromes, but far less frequently relative to photically-induced seizures. There are only a handful of reported patients with possible reflex FOS epilepsy, perhaps not only because of its rarity. A possible role of FOS as a seizure trigger can be sought *after* the demonstration of the phenomenon on video-EEG and, unless seizures occur during FOS testing, a clear cause-effect relationship is difficult to establish based on history; for instance, seizures occurring in periods of relative inattention do not necessarily indicate FOS.

A) Confirmatory of FOS. (Both recording levels): ED consistently occur only when volitional visual fixation is prevented, as shown using dark and semitransparent goggles, and allowing for a degree of habituation after

a number of trials. FOS is considered clinical when associated with seizure symptoms.

B) High diagnostic certainty (probable). Basic level: clear tendency of ED to occur when eyes are closed or when semitransparent goggles are “on” and abate visual fixation, but the effect is not entirely consistent. Proceed with sleep-deprived video-EEG (advanced level) with testing on awakening to improve consistency and move diagnostic certainty up to level A.

C) Low diagnostic certainty (possible). Basic level: clear tendency of ED to occur when eyes are closed and abate when eyes are open (raising the suspicion of FOS). Repeat the EEG to assess with dark and semitransparent goggles at basic level, or proceed with a sleep-deprived video-EEG (advanced level), as above.

5. STRUCTURAL and GENETIC FOCAL (LOBAR) SYNDROMES

5.1. TEMPORAL LOBE EPILEPSY (TLE)

5.1.1. Adult mesial TLE (mTLE)

Overview.

Temporal lobe epilepsy is the most common focal epilepsy in adults. Mesial TLE comprises the largest group of TLEs (*table 3*) with a distinct electroclinical profile, characteristic history, and clinical course.

Birth history, development, cognition, and neurological examination are typically normal. The pathology is variable though many experience febrile seizures (FS) in early childhood. Focal seizures, with and without IoC, often recur in early adolescence. Rare convulsive seizures occur. The cause is frequently structural due to hippocampal sclerosis (HS) (*supplementary figure 5.01*). Anterior temporal epileptiform discharges are often present on interictal EEG, supporting a clinical diagnosis of mTLE. Many patients become resistant to anti-seizure drugs. Surgical therapy is a treatment of choice (Williamson *et al.*, 1993).

Seizures: symptoms and semiology.

Most patients with mTLE report an aura. Focal seizures usually occur with an epigastric/viscerosensory experiential or psychic aura (e.g. *déjà vu*). Focal seizures that evolve to include IoC usually begin with a motionless stare. Oroalimentary automatisms, such as lip licking or smacking, chewing or swallowing motions, may be prominent. The presence of unimpaired ictal speech and ictal vomiting or other autonomic signs suggests a non-dominant hemispheric origin, while postictal aphasia is associated with a dominant hemisphere onset in mTLE. Unilateral eye blinking tends to localize to the ipsilateral hemisphere. Manual automatisms are less localizing, though when they consistently involve one hand and occur in association with dystonic

Table 3. Epilepsies of temporal lobe origin.

	mTLE	nTLE	fmTLE
Age at onset	Early adolescence-early adulthood; typically follows childhood FS	Adolescence to early-mid adulthood	Adolescence to mid-adulthood; typically peaks in early adulthood
Focal seizures with and without IoC	Primary seizure	In most patients	Yes
sec-GTC seizures	Infrequent in some patients	Primary seizure	In up to 50% (variable frequency)
Family History	Exclusion criterion	Not reported yet	Defining feature
Risk Factors	Often	Rare	Exclusion criterion
MRI	Often MTS	Often normal	Normal
Interictal EEG	Anterior-mid temporal spikes/TIRDA	Mid-posterior temporal spikes	Anterior temporal spikes
Ictal EEG	Anterior-mid temporal theta/alpha	Mid-temporal delta	Rarely reported

mTLE: mesial temporal lobe epilepsy; nTLE: neo-cortical (lateral) temporal lobe epilepsy; fmTLE: familial mesial temporal lobe epilepsy; FS: febrile seizures; IoC: impairment of consciousness; sec-GTC: secondary generalized tonic-clonic.

posturing of the other upper limb, they are typically ipsilateral to the site of seizure onset; dystonic posturing is contralateral. While focal seizures that evolve to convulsions are rare in mTLE, the signs associated with transition can be valuable clues for seizure lateralization. Features, such as head version, unilateral tonic posturing, or clonic jerking, are most frequently contralateral to the seizure onset. Postictal manifestations, including cough, may occur with right mTLE. Unilateral postictal nose wiping tends to be ipsilateral to seizure onset. The importance of seizure symptoms and signs in mTLE is enhanced by a confluence of several features. The value of semiology in the presurgical evaluation of mTLE cannot be over-emphasized (Gil-Nagel and Risinger, 1997).

EEG section.

Background. The background is typically normal in mTLE or demonstrates non-specific slowing if anti-seizure drug toxicity or a seizure has recently occurred (*supplementary figure 5.02*).

Interictal paroxysmal abnormalities.

Intermittent slowing in the temporal derivations on scalp EEG is frequently encountered and accentuated by drowsiness and HV. Focal slowing is commonly associated with ED (*supplementary figure 5.02*). Temporal interictal rhythmic delta activity (TIRDA) (Geyer *et al.*, 1999) (*supplementary figure 5.03*) may appear in a significant minority of patients. It has localizing

capability despite the non-epileptiform morphology and may occur in prolonged runs of up to several seconds. Temporal slowing may become more pronounced with longer bursts of TIRDA.

Surface-negative anterior temporal ED are a characteristic feature of mTLE. During prolonged EEG recording, >90% of patients with mTLE demonstrate anterior temporal ED (Williamson *et al.*, 1993). Spikes or sharp waves, with and without after-going slow waves, possess a regional temporal field (*supplementary figure 5.04*). HV may accentuate focal slowing in mTLE. Photic stimulation usually has no activating effect on the interictal EEG.

The maximum voltage is expressed in the basal temporal electrode derivations (T1/T2, FT 9/FT10; see *recording recommendations below*) or the anterior to mid-temporal electrodes (F7/8-T3/4) of the standard 10-20 system. Mid-temporal ED only should raise the suspicion of non-mTLE. Strong localizing capability of the seizure onset zone (SOZ) exists for unilateral temporal ED on EEG and evidence of mesial temporal sclerosis (MTS) on MRI. Topographic analysis may demonstrate contralateral central-parietal electropositivity. ED recorded during wakefulness (and REM sleep) are more likely to be correctly lateralized, show a more restricted field, and are more likely to be associated with the SOZ. In N1 and N2 sleep, the frequency of the ED may increase, discharges may appear bilaterally, and in slow sleep the morphological appearance of temporal spikes may change. Approximately a third to a half of patients with unilateral mTLE have

bitemporal ED (*supplementary figure 5.05*), especially when prolonged recording is performed (Williamson *et al.*, 1993). On the other hand, unilateral surface temporal ED do not exclude the possibility of bilateral independent ictal onset. In most cases of mTLE, scalp EEG with extra electrodes and evidence of MTS on brain MRI will be adequate to localize seizures during a pre-surgical evaluation.

EEG paroxysms that accompany ictal events.

The EEG is often unremarkable during an aura. The characteristic ictal EEG finding in mTLE with recurrent focal seizures and dyscognitive features is an evolving unilateral temporal 5-9-Hz rhythmic ictal theta or alpha pattern (*supplementary figure 5.06*) which is maximal over the anterior-inferior temporal scalp electrodes (F7/8 and T3/4 of the 10-20 system). When focal ictal EEG findings occur before the clinical onset of symptoms and within 30 seconds after the clinical onset, this feature has been reported to lateralize the seizure with a specificity of nearly 95% in patients with mTLE (Williamson *et al.*, 1993). The overall accuracy of scalp lateralization has been reported to be 60-83%. Seizures initially confined to the hippocampus require recruitment of the inferior-basal cortex to produce the scalp EEG correlate. Less commonly, when the maximum involvement of the basal temporal neocortex occurs, vertex positivity may dominate the ictal activity that is seen (Ebersole and Pacia, 1996). Postictal slowing is seen in up to 70% of seizures and has been used to localize the site of seizure onset (Ebersole and Pacia, 1996). The intracranial EEG features of mTLE demonstrate high frequencies and oscillations at seizure onset in either the hippocampal contacts of a depth electrode or the mesial contacts of subtemporal subdural strips. Frequencies higher than 5 Hz on scalp ictal EEG appeared only when propagation occurred outside of the hippocampus to reach the inferior-basal temporal neocortex on invasive EEG monitoring (Ebersole and Pacia, 1996).

Recording protocols.

Basic level

- Attempt to partially sleep deprive, perform a sedated sleep EEG, or continue recording if possible to achieve sleep.
- HV may accentuate focal slowing in cases of mTLE and may be useful to differentiate episodes of staring by separating out GSWD in absence seizures from those with focal features in mTLE in clinically deceptive cases.
- Consider using extra electrodes (e.g. T1/T2 or FT9/FT10; see *advanced level below*) to facilitate diagnostic recovery of ED, if possible.

Advanced level

- Recording sleep is mandatory either after partial SD or using sedation.
- HV (see basic level).
- Repeated EEGs may increase the yield of demonstrating an epileptiform abnormality.
- Consider using extra electrodes (*supplementary figure 5.07*) placed in accordance with the 10-10 system (include midline sites to assess for vertex electropositivity), particularly in patients who are likely to become candidates for epilepsy surgery.

Indications for prolonged EEG/video-EEG telemetry.

Overnight EEG. For recovery of EDs, subclinical seizures, or seizures without awareness and therefore unreported by patients. More accurate localization of interictal ED is possible in REM sleep.

Video-EEG monitoring. When episodes with impaired consciousness and normal interictal EEGs (basic or advanced) raise the suspicion of a non-epileptic origin, or when the clinical history is not compatible with epilepsy and temporal epileptiform activity (e.g. possible normal variant) is reported on EEG (differential diagnosis).

To classify staring episodes for treatment purposes (absences vs. temporal lobe seizures).

When patients with mTLE are unaware of their seizures and the semiology is subtle (for seizure quantification). When seizures associated with mTLE remain resistant to anti-seizure drugs for seizure characterization/pre-surgical evaluation.

Invasive EEG is performed when epilepsy surgery is being considered and non-invasive tests during presurgical evaluation reveal discordant results. Indications include the following:

- (1) Non-lesional mTLE is suspected with localized temporal electrophysiology (to distinguish mTLE from non-mTLE).
- (2) Severe HS and contralateral scalp electrophysiology (to address the possibility of false lateralization).
- (3) When interictal EEG demonstrates posterior temporal ED, polyspikes, or multi-focal hemispheric epileptiform discharges.
- (4) When the scalp ictal EEG demonstrates unilateral repetitive interictal spiking at seizure onset, bilateral attenuation at seizure onset, or when bitemporal independent seizures or seizures that “switch” sides are present.
- (5) When “temporal plus” epilepsies are suspected (e.g. dual pathology).

Levels of EEG diagnosis.

The diagnosis of mTLE is readily made with interictal scalp EEG when TIRDA and unilateral or bilateral

epileptiform discharges are present with typical clinical history and course.

A) Confirmatory. Interictal ED unilaterally over one temporal lobe at F7/F8 and T3/T4 (or T1/T2 and FT9/FT10), if additional derivations are used), or asymmetrically lateralized to the most involved temporal lobe when they are bilaterally present (basic and advanced recording levels) in patients with evidence of HS on brain MRI and the appropriate clinical semiology of mTLE. Focal seizures with a unilateral temporal rhythmic ictal discharge within the 5-9-Hz frequency range.

B) High diagnostic certainty (probable). Intermittent bilateral independent anterior-to-mid temporal interictal ED on EEG with equal distribution (basic and advanced recording levels). Unilateral HS on brain MRI with the appropriate history and semiology moves the diagnostic certainty to confirmatory level.

C) Low diagnostic certainty (possible). Repeatedly normal interictal EEG, additional or solely extra-temporal ED, temporal polyspikes, or slowing in patients with frequent GTC seizures or prominent motor features and a lesion on brain MRI, not contained within the temporal lobe or involving the lateral temporal neocortex, should be red flags for non-mTLE.

5.1.2. Adult neocortical (lateral) TLE (latTLE)

Overview.

Neocortical temporal lobe epilepsy (latTLE) arises in the neocortex of the lateral surface of the temporal lobe of the brain. It comprises a heterogeneous group of focal seizures characterized by language, auditory, or somatosensory auras when they occur (Kennedy and Schuele, 2012). Early insults are less often encountered in latTLE. The typical semiology includes a motionless stare and early contralateral clonic jerking, evolving into a convulsion. Neuroimaging is frequently normal or demonstrates lateral temporal structural abnormalities. The electrophysiological features of latTLE cannot reliably distinguish latTLE from mTLE, however, the interictal EEG may reveal mid-temporal interictal epileptiform discharges with an ictal pattern that consists of an irregular, hemispheric delta discharge.

Seizures: symptoms and semiology.

Auras occur, as in mTLE, but reflect symptoms that relate to the function of the lateral temporal neocortex (Gil-Nagel and Risinger, 1997). Auras may be characterized by involvement of language when the dominant hemisphere is involved (e.g. speech arrest aka aphasic seizures). Elemental auditory auras may suggest the onset near Heschl's gyrus. Somatosensory symptoms and psychic auras may reflect posterior or mesial propagation of neocortical onset to produce the

symptomatogenic source of the symptoms. Auras may be followed subsequently by a motionless stare and contralateral clonic jerking that occurs early during the course of the seizure. When this occurs, seizures frequently evolve into a convulsion. Facial twitching and grimacing may also occur early during seizures of lateral temporal lobe origin. These signs are more likely than the contralateral dystonic posturing that is seen in patients with mTLE. Temporal lobe connections facilitate propagation to the mesial temporal area and, in addition, to the frontal neocortex and posterior cortex, leading to a greater likelihood of focal seizures evolving into convulsions, in contrast to mTLE in which convulsions are rarely a prominent feature (O'Brien *et al.*, 1996).

EEG section.

Background. The background is typically normal in latTLE or may demonstrate non-specific slowing if anti-seizure drug toxicity or a seizure has recently occurred.

Interictal paroxysmal abnormalities.

Intermittent regional temporal slowing on scalp EEG (*supplementary figure 5.08*) is frequently encountered and accentuated by drowsiness and HV.

Focal slowing may or may not be associated with ED. TIRDA may appear in a minority of patients, however, this carries localizing potential. Surface-negative mid-temporal epileptiform discharges are the characteristic feature on the interictal EEG (*supplementary figure 5.09*). HV may accentuate focal slowing in latTLE. Photoc stimulation usually has no effect. Postictal slowing may serve to localize the site of seizure onset in latTLE, though seizure propagation or a "switch" from onset to contralateral hemisphere is also possible.

No differences may be noted in the interictal EEG of patients with latTLE and mTLE (Kennedy and Schuele, 2012; Barba *et al.*, 2007). Spikes or sharp waves with or without after-going slow waves occur in a regional temporal field. The maximum voltage is often expressed in the mid-temporal electrode derivations (T7/T8 in the 10-10 system or T3/T4 in the 10-20 system), and this location should raise a suspicion of latTLE. Lateralizing capability of the SOZ is often facilitated by unilateral temporal epileptiform discharges on EEG. Frequent temporal interictal spikes (>60 spikes/hour) appear to be more likely with latTLE, as opposed to mTLE, probably because of the proximity to the recording electrodes (Kennedy and Schuele, 2012). In some cases, the interictal EEG may contain abnormalities of greater localizing value than the ictal EEG in extrahippocampal epilepsy, including latTLE. Similar to mTLE, a significant number of patients manifest with bitemporal ED, especially when prolonged recording is performed. N1 and N2 sleep often facilitates

the appearance of ED and may increase their frequency, while temporal slowing may become more pronounced with longer bursts. Slow-wave sleep alters the morphological appearance of temporal spikes. REM is similar to wakefulness with epileptiform discharges that appear less frequently; when they are present, they often lateralize the SOZ.

EEG paroxysms that accompany ictal events.

The characteristic ictal EEG in latTLE typically has a slower discharge frequency than in mTLE (*supplementary figure 5.10*). In one intracranial surface-based EEG study (Tao et al., 2005), an evolving irregular, polymorphic 2-5-Hz delta frequency at ictal onset was characteristic of latTLE.

The ictal EEG is lateralized, but less often localizing due to a broad hemispheric field. Morphology may also be suggestive of latTLE with ictal discharges that appear more irregular and less rhythmic. Crescendo semi-periodic sharp waves at seizure onset appear more frequently than in patients with mTLE (Tao et al., 2005). This study showed that seizures arising from the lateral convexity and mesial temporal regions were differentiated by a high incidence of repetitive epileptiform activity at ictal onset in the former and rhythmic theta activity in the latter. The maximal activity was seen over the mid temporal scalp electrodes in latTLE. Patients with lesional latTLE may develop bilateral ictal EEG changes more often than patients with mTLE (O'Brien et al., 1996). Ictal discharges were also likely to propagate more rapidly than those in mTLE and were more likely to spread bilaterally. Intracranial EEG may be required if false temporal localization is suspected on scalp EEG (Barba et al., 2007).

Recording protocols.

Basic level

- Attempt to partially sleep deprive or perform a sedated sleep EEG; if this is not possible, allow patients to drowse/enter light sleep (N1/N2).
- HV may accentuate focal slowing in latTLE.
- Use extra electrodes (e.g. 10-10 system of electrode placement), if possible.

Advanced level

- Recording sleep is mandatory either after partial SD or using sedation (see *basic level*).
- HV, as for basic level.
- Use of extra electrodes is recommended (see *basic level*).
- Repeating EEGs may increase the yield of demonstrating an epileptiform abnormality.

Indications for prolonged EEG/video-EEG telemetry.

Overnight EEG. For recovery of ED, subclinical seizures or seizures without awareness.

Video-EEG monitoring. When episodes with impaired consciousness and normal basic or advanced EEGs suggest a non-epileptic aetiology, or when the clinical history is not compatible with epilepsy and temporal epileptiform activity (e.g. possible normal variant) is reported on EEG (*supplementary figure 5.11*).

Staring episodes requiring classification for treatment (absences vs. complex partial seizures).

When patients with latTLE are unaware of their seizures and the semiology is subtle (seizure quantification).

When seizures remain resistant to antiseizure drugs, or ongoing focal seizures with dyscognitive features (seizure characterization/pre-surgical evaluation).

Indications for invasive EEG.

- (1) Non-lesional latTLE is suspected with localized temporal electrophysiology in the dominant hemisphere (where language functional mapping may be required) or where >1 pathology is encountered (e.g. HS and cortical dysplasia).
- (2) Clinical seizure onset prior to the first ictal EEG change or absent scalp ictal EEG changes despite impaired consciousness on scalp pre-surgical evaluation.
- (3) When interictal EEG demonstrates posterior temporal ED, polyspikes, or multi-focal hemispheric ED, or ictal EEG demonstrates unilateral repetitive interictal spiking at seizure onset, or bilateral attenuation at seizure onset, or when there is bitemporal independent seizure onset, or when seizures that “switch” sides are present on scalp EEG.

Levels of EEG diagnosis (in patients with clinical manifestations in keeping with latTLE).

A) Confirmatory. Interictal ED unilaterally over one temporal lobe in the T7/T8 (T3/T4) derivations or asymmetrically over both temporal derivations during light sleep (basic and advanced recording levels) and regional temporal delta slowing in association with a lateral temporal lesion on brain MRI.

Focal seizures with a lateralized hemispheric irregular polymorphic 2-5-Hz ictal discharge with a broad or bilateral field of spread in the same clinical context.

B) High diagnostic certainty (probable). Intermittent asymmetric bilateral mid-temporal interictal ED on EEG with equal distribution, or anterior or posterior-temporal ED (basic and advanced recording levels). A neocortical lesion on brain MRI with the appropriate history and semiology moves the diagnostic certainty to level A.

C) Low diagnostic certainty (possible). Repeatedly normal interictal EEGs, extratemporal ED, and secondary bilateral synchronous discharges on interictal EEG. Semiologies with frequent GTC seizures or prominent

motor features with a lesion on brain MRI, not contained within the temporal lobe.

5.1.3. Familial mesial temporal lobe epilepsy (fmTLE)

Overview.

The syndrome of fmTLE is more common than familial lateral TLE. The family history is the defining characteristic. Inheritance is autosomal dominant with incomplete penetrance (Hedera *et al.*, 2007). A complex inheritance exists in some families with a single gene mutation being elusive (Crompton *et al.*, 2010). Seizures begin in adolescence or early adulthood and represent a benign syndrome with late seizure onset, absence of FS, and normal mesial structures on brain MRI (Berkovic *et al.*, 1996). Overall, fmTLE cannot be reliably distinguished from the non-familial form on the basis of semiology, MRI, or EEG features. Seizures are usually subtle, infrequent, and responsive to anti-seizure drugs, compared with other forms of mTLE (Berkovic *et al.*, 1996). Brain MRI is usually normal (Kobayashi *et al.*, 2003).

Seizures: symptoms and semiology.

fmTLE occurs with similar semiology to that of mTLE. Auras are far more common than focal seizures with impaired consciousness and may exist as the sole seizure type. The symptoms associated with seizure onset are typically subjective and non-lateralizing, and reflect seizure onset in the mesial temporal lobe structures often with an aura of a psychic or an experiential warning (Morita *et al.*, 2012). *Déjà-vu* and *jamaïs-vu* are the most common symptoms of seizure onset in fmTLE. Autonomic symptoms may coexist and be associated with fmTLE, including ictal fear and panic, reflecting involvement of the mesial temporal lobe structures. Alteration in visual perception and auditory stimuli may also occur in fmTLE. The rising epigastric sensation that is characteristic of mTLE is uncommon as an ictal symptom in fmTLE. Auras in fmTLE often evolve into focal seizures with impaired responsiveness and, less frequently, convulsions that occur in two thirds of patients. Generalized seizures usually herald the diagnosis in half of patients prior to treatment; subsequently, they are rarely encountered throughout the clinical course that is punctuated primarily with infrequent focal seizures associated with impaired consciousness (Crompton *et al.*, 2010).

EEG section.

Background. The background in fmTLE is usually normal. Abnormalities are typically composed of

intermittent temporal slowing that is usually mild if and when it occurs.

Interictal paroxysmal abnormalities.

Usually, no epileptiform discharges (ED) are encountered on the EEG. Rare ED in the form of sharp-and-slow waves may be seen localized to the temporal electrode derivations in 22-39% of patients with a similar distribution between left and right hemispheric involvement (Berkovic *et al.*, 1996; Compton *et al.*, 2010). When interictal ED occur in fmTLE, they are unilateral, maximal in the mesiotemporal regions. Bilateral ED rarely occur.

When EDs are seen, they are typically regional temporal spikes or sharp waves, usually unilateral, and may occasionally be activated during sleep (*supplementary figure 5.12*). Co-existence with genetic generalized epilepsy, JME, and generalized spike-and-polyspike waves, as well as a PPR, has been reported in one patient (Compton *et al.*, 2010).

EEG paroxysms that accompany ictal events.

The ictal EEG is without unique features when compared with mTLE (see section on mTLE [5.1]). Ictal discharges are commonly regional temporal in onset, although occasionally no scalp ictal EEG changes can be recovered. Although the majority of patients with fmTLE have a benign clinical course including spontaneous remission, drug-resistant fmTLE may occur in up to 29% of patients and prompt ictal recordings in the context of pre-surgical evaluation (Kobayashi *et al.*, 2003). Ictal recordings on scalp EEG presented as a unilateral temporal discharge in 13/19 patients in one study of two affected family members with fmTLE (Kobayashi *et al.*, 2003). Recording with depth electrodes, used for lateralization, has shown right mesial ictal onset in the depth electrode and early ictal spread to superior temporal and parietal subdural grid electrodes.

Recording protocols.

Basic level

- Attempt to partially sleep deprive or perform a sedated EEG to achieve sleep.
- Use extra electrodes (e.g. T1/T2 or FT9/FT10), if possible.
- HV may accentuate focal slowing in cases of mTLE and may be useful to differentiate episodes of staring by separating out GSWD in absence seizures from those with focal features in mTLE in clinically deceptive cases.
- Photoc stimulation should be included to exclude the presence of a PPR.
- Repeating EEGs may increase the yield of eliciting epileptiform discharges.

Advanced level

As for basic level, plus:

Obtaining sleep is mandatory; it is important for recovering abnormal ED and separating them from non-pathological temporal patterns such as wicket waves, and for assessing the presence of subclinical seizures or seizures without awareness.

Perform continuous overnight EEG recording if possible (ambulatory or video-EEG).

Indications for prolonged EEG/video-EEG telemetry.

- Persistently normal/inconclusive EEGs.
- Recurrent events not suggestive of epilepsy despite a family history of recurrent seizures (differential diagnosis).
- Staring episodes requiring classification for treatment (absence vs. mTLE).
- When patients with mTLE are unaware of their seizures and the semiology is subtle (for quantification).
- When patients are drug-resistant with ongoing focal seizures associated with dyscognitive features (for characterization/pre-surgical evaluation).

Indications for invasive EEG.

- Epilepsy surgery is being considered (rarely).
- Non-lesional fmTLE is suspected with localized temporal electrophysiology (distinguish mTLE from non-mTLE).
- Brain MRI with HS, contralateral electrophysiology and a family history of seizures not compatible with autosomal dominant inheritance (to address the possibility of symptomatic mTLE and false lateralization).
- When interictal EEG demonstrates posterior temporal epileptiform discharges, polyspikes, or multi-focal hemispheric epileptiform discharges, or ictal EEG demonstrates unilateral repetitive interictal spiking at seizure onset or bilateral attenuation at seizure onset, or in the presence of bitemporal independent seizure onset or discharges that “switch” on scalp EEG in patients with drug-resistant fmTLE.
- When temporal plus epilepsies are suspected (e.g. dual pathology) and patients are resistant to anti-seizure drugs (pre-surgical assessment).

Levels of EEG diagnosis.

[In patients with typical of fmTLE focal seizures and clinical course and positive family history in which an autosomal dominant inheritance pattern is established.]

A) Confirmatory. Anterior temporal spikes on interictal EEG; ictal recordings are unexpected (for both basic and advanced EEG).

B) High diagnostic certainty (probable). Interictal EDs over the anterior temporal electrode derivations with

a broad extratemporal field with or without associated focal temporal slow wave activity (for both basic and advanced EEG).

C) Low diagnostic certainty (possible). Unilateral interictal extratemporal EDs without temporal regional involvement but with a familial pattern of inheritance consistent with fmTLE (for both basic and advanced EEG). The interictal EEG in these cases does not support a diagnosis of fmTLE but does not exclude it either. Proceed with, or repeat advanced or video-EEG telemetry to record temporal lobe seizure onset and move diagnostic certainty to levels A or B. Similarly, an absence of surface scalp ictal EEG changes during auras should prompt advanced recording or video-EEG telemetry.

5.1.4. Autosomal dominant partial epilepsy with auditory features

Overview.

Autosomal dominant partial epilepsy with auditory features (ADPEAF) has also been referred to as the lateral form of familial TLE. ADPEAF was the first non-ion channel familial localization-related epilepsy with a single gene inherited by autosomal dominance linked to the leucine-rich, glioma-inactivated 1 (*LGI-1*) gene on chromosome 10 (Ottman *et al.*, 2004). The onset is during teenage or early adult life, but may present earlier or later (range: 4-50 years) in life. FS and other risk factors for epilepsy are not expected. Seizures manifest primarily as simple auditory hallucinations, though other visual and olfactory symptoms may occur. Brain MRI and EEG are often normal. Like familial (mesial) TLE, seizures are usually mild and respond readily to antiseizure drugs.

Seizures: symptoms and semiology.

ADPEAF is characterized by focal seizures with subjective symptoms. Auditory hallucinations are the hallmark (Michelucci *et al.*, 2000). The typical symptoms include elemental sounds, such as buzzing, clicking, or ringing, which are usually referred to the contralateral ear, though may be bilateral. Less frequently, ADPEAF may be composed mainly of brief aphasic seizures. The aphasia usually consists of a sudden onset of inability to understand language without confusion. A wide range of auras exist with other special sensory symptoms that include visual hallucinations of colours, lights, or simple images. In addition, vertigo, olfactory, and subjective, non-specific, non-lateralizing auras may also occur. Infrequently, these sensations may progress to subtle focal seizures with impaired consciousness, though they typically occur in isolation. Generalized seizures are usually rare with nocturnal predominance when they occur.

EEG section.

Background. The background in ADPEAF is typically normal. When abnormalities in the background do occur, they are typically mild and non-specific and composed of intermittent temporal slowing.

Interictal paroxysmal abnormalities.

Epileptiform discharges (ED) are encountered in up to two thirds of patients, and they are typically identified as regional mid-temporal spikes or sharp waves (Winawer *et al.*, 2002) (*supplementary figure 5.13*). Electrode derivations representing the regional lateral temporal neocortex involve T7 (T3)/T8 (T4) and the anterior and posterior electrode derivations are typically involved. When ED occur, they are usually unilateral. Activation with HV may disclose enhancement of intermittent temporal slowing. IPS is not expected to activate ED. In ADPEAF, obtaining N1 and N2 sleep is important in potentially activating interictal ED.

EEG paroxysms that accompany ictal events.

Seizures are believed to originate at, or propagate into, Heschl's gyrus in the primary auditory or the auditory association cortices. Only a few cases have been described (Brodtkorb *et al.*, 2002). A left hemispheric onset involving the anterior-mid temporal or left frontotemporal region is the most common ictal onset. Paroxysmal rhythmic ictal activity in the left frontotemporal region occurs during automatisms but generalized slowing is detected when IoC is demonstrable. Propagation recruits the neocortical regions and may appear bilaterally with posterior predominance as the focal seizures of ADPEAF intensify. Morphologically, seizure onset in ADPEAF has included low-voltage ictal fast activity, followed by delta activity and rhythmic sharp waves when arising from the anterior-middle temporal region (Di Bonaventura *et al.*, 2009). Ictal discharges, initially regional temporal in onset, evolve to become more widespread when seizures become convulsive.

Recording protocols.

Basic level

- Instruct patients to report any subjective symptoms and their duration that are typical of a seizure or aura if they occur during the recording.
- Enhanced recovery of interictal abnormalities may be obtained by applying extra electrodes over the temporal regions.
- Allow patients to drowse/enter light sleep (when a routine EEG has been arranged) to facilitate recovery of epileptiform discharges.
- HV may induce focal temporal slowing. Polygraphy is generally unnecessary in patients with ADPEAF.

Advanced level

- As for basic level.
- If sleep is not obtained during an initial routine EEG, then repeat EEG with partial SD.
- Sufficient periods of sleep recording maximize the chance to recover interictal discharges or seizures.

Indications for prolonged video-EEG monitoring.

- Scalp EEG is repeatedly normal and a non-epileptic aetiology is possible (differential diagnosis).
- Drug-resistant focal seizures have a temporal lobe semiology mimicking ADPEAF, necessitating a pre-surgical evaluation.

Indications for invasive EEG monitoring.

Invasive EEG monitoring is rarely required for ADPEAF given that the syndrome is typically treatment-responsive and the brain MRI normal. Invasive EEG may be required for a few patients that remain treatment-resistant.

Levels of EEG diagnosis (in patients with clinical manifestations in keeping with ADPEAF).

Note: The use of interictal EEG in the diagnosis of ADPEAF will be based upon the appropriate symptoms and clinical course (*see overview*) and supported by recovering temporal interictal epileptiform discharges.

A) Confirmatory of ADPEAF. Appropriate clinical symptoms and family history/*LGI-1* gene mutation with interictal epileptiform discharges in the frontotemporal regions (usually left) on scalp EEG.

B) High diagnostic certainty (probable). (Both levels of recording): clinical symptoms of auditory hallucinations or auras occur without EEG changes with frequent interictal epileptiform discharges in one or both temporal regions.

C) Low diagnostic certainty (possible). A normal interictal EEG or focal temporal slowing with typical auditory hallucination or aphasia. This should prompt a repeat advanced sleep-deprived recording or pursuit of prolonged video-EEG telemetry (*see indications above*). Unilateral or bilateral extratemporal or multifocal interictal ED during routine scalp EEG, especially when they are frequent, should raise doubt of ADPEAF. In these cases, proceed with advanced sleep-deprived recording.

5.2. FRONTAL LOBE EPILEPSIES (FLE)

Overview

The frontal lobe comprises a third of the brain. It is anatomically subdivided into dorsolateral, medial, and inferior orbital regions (Salanova *et al.*, 1995). The diagnosis of FLE is largely based upon

clinical features. Various semiologies and electroclinical syndromes occur based upon seizure localization. A structural cause is present in a third of cases including low grade tumours, cortical dysplasia, vascular malformations, and trauma. However, aetiology also includes genetic forms with a genetic defect isolated to the gene *CHRNA4*, coding for the $\alpha 4$ subunit of the neuronal nicotinic acetylcholine receptor, and FLE inherited in an autosomal dominant fashion. An abnormal MRI involving the frontal lobe may be both diagnostic and localizing in structural FLE, though neuroimaging is frequently normal. In addition, the interictal EEG and even ictal EEG may be unrevealing. The treatment approach is appropriate for patients with focal seizures.

Seizures: symptoms and semiology

In general, frontal lobe seizures are composed of motor symptoms at the onset. An aura is typically a non-specific or cephalic aura. Patients may experience symptoms of dizziness or an indescribable or vague sensation before a seizure. Common symptoms that arise from the dorsolateral frontal lobe include tonic posturing and clonic jerking. GTCS are common in FLE. Focal seizures may exhibit semiologies with lateralized head and eye version and unilateral or asymmetric bilateral tonic extension. Contralateral dystonic posturing also occurs in TLE but in FLE it occurs at seizure onset. Consciousness may be seemingly unimpaired, especially when seizures are brief. Loud vocalizations including swearing, yelling, and laughing may occur with bizarre automatisms such as biting, spitting, and kicking, especially when seizures arise from the supplementary motor area. Very complex hypermotor behaviour without lateralizing or localizing signs may appear bizarre. Orbitofrontal seizure onset may mimic TLE and be difficult to separate. Frontal lobe seizures are typically very brief and are activated by sleep with an absent or minimal postictal state (Jeha *et al.*, 2007). When they are hypermotor and associated with vocalizations or verbalization, frontal lobe seizures are subject to misdiagnosis. They may be mistaken for psychogenic non-epileptic attacks or paroxysmal hyperkinetic movement disorders during wakefulness, and nocturnal FLE and sleep disorders during sleep (table 4). The behavioural patterns encountered in NREM arousal parasomnias, REM behaviour disorders, and nocturnal FLE may all appear similar in semiology.

EEG section

Background. Normal or regionally abnormal, depending upon the presence of a structural lesion (supplementary figure 5.14).

Interictal paroxysmal abnormalities.

The interictal EEG is often normal. Regional or unilateral frontal theta or delta slowing is ipsilateral to seizure onset, though frequently, bilateral abnormalities are present. Frontal or frontopolar spikes are the typical interictal finding (supplementary figure 5.14), but in up to 40%, the EEG does not reveal epileptiform discharges (Bautista *et al.*, 1998). Deep mesial frontal signals remote from the recording scalp electrodes make recovery of ED challenging even with midline and closely spaced electrodes. Focal spikes and sharp waves arising from the frontal midline typically exhibit greatest amplitude at the vertex. SBS, focal paroxysmal fast activity, and high-voltage rhythmic sharply contoured slow waves have a higher detection rate if intracranial subdural recordings are used (Salanova *et al.*, 1995). A burst of frontal or frontopolar high-voltage sharply contoured slow waves suggests orbitofrontal epilepsy (supplementary figure 5.15).

Children manifest with a variety of abnormalities including multifocal, bilateral synchronous and lateralized discharges (supplementary figure 5.16), or may show normal features. An epileptogenic unilateral focus of the mesial or inferior frontal lobe may produce bifrontal synchronous discharges (supplementary figure 5.17). This pattern occurs in up to two thirds of patients (see also section on SBS [2.2]).

Interictal high-frequency oscillations (HFO) have localizing value in FLE with their pre-operative presence predicting a post-operative seizure-free outcome when seen in FLE (Wu *et al.*, 2010).

EEG paroxysms that accompany ictal events.

Patients with FLE have a non-localized ictal onset in more than 50% of cases (Salanova *et al.*, 1995). Mesial FLE may be represented by generalized ED at onset that are maximal at the vertex. This is due to the extensive functional networks of the frontal lobe and inaccessibility to the recording electrodes to the deep sulci and gyri of the frontal lobe. Myogenic artefact during hypermotor activity, rapid seizure propagation to the temporal regions (*i.e.* from orbitofrontal or cingulate gyrus), and an absent scalp ictal EEG change (*i.e.* when seizures emanate from mesial and orbitofrontal cortex) are limiting factors (supplementary figure 5.18). Non-localized seizures may manifest as diffuse attenuation of the background activity and non-localized rhythmic theta or delta at onset is due to rapid propagation. Dorsolateral FLE is probably most likely to be localized with scalp ictal EEG (supplementary figure 5.19). Focal rhythmic ictal fast activity in dorsolateral FLE has been reported to occur in up to 80% of patients (Bautista *et al.*, 1998) (supplementary figure 5.20). When present, it predicts a favourable outcome following resective surgery (Jeha *et al.*, 2007).

Table 4. Differential diagnosis of frontal lobe epilepsy.

Characteristics	Frontal lobe epilepsy	PNES	REM Parasomnias	NREM Parasomnias
Age at onset	Any age	Usually 20-40 years	Children - nightmares elderly - RBD	Children
Family history	Yes - in ADNFLE	No	No	No
Psychiatric history	May vary	Frequent	Not usually (but may occur in post-traumatic stress disorder)	No (but frequency may increase with stress)
Event frequency	Several / night	Usually frequent	Several / night	Weekly or monthly
Event duration	Brief (seconds)	Long (min)	Long (min)	Long (min)
Clinical manifestations	Stereotyped motor pattern	Non-stereotyped weeping, on-off, eyes closed	Non-stereotyped, goal-directed, autonomic activation	Confusion, disorientation
Stereotyped	Yes	No	No	No
MRI	Often normal	Normal	Abnormal degenerative features	Normal
EEG pattern	Ictal*	Normal	REM	N3
Nocturnal	Yes - Any time, usually from Stage 2	Pseudo-sleep	Last third of night	First third of night
Post-event recall	Yes	Variable	Yes (dream)	No

* Ictal patterns may be absent and demonstrate abrupt arousal directly from sleep. Abbreviations: ADNFLE: autosomal dominant frontal lobe epilepsy; PNES: psychogenic non-epileptic seizure; REM: rapid eye movement; NREM: non-rapid eye movement; RBD: REM behavioural disorder. Based on Tinuper and Bisulli (2017).

False localization to the temporal lobe is not uncommon due to rich frontotemporal connections. Rhythmic epileptiform activity, rhythmic delta, and suppression on ictal EEG have decreasing representation in FLE (Foldvary *et al.*, 2001) (*supplementary figure 5.21*).

Recording protocols

Basic level

- Attempt to partially sleep deprive or, when a routine EEG has been arranged, continue recording to ensure sleep has been obtained, if possible.
- Use midline electrodes (Fz, CZ and PZ), if possible, to ensure minimal coverage of midline and deep cortex.
- Use deltoid or limb EMG, if possible, to identify subtle motor movements.
- HV may accentuate focal slowing in cases of structural FLE and be useful to differentiate the characteristic features of SBS and the GSWD in GGE/IGE in clinically deceptive cases. Photoc stimulation is not expected to elicit a PPR.

Advanced level

- Recording after partial SD to include sufficient periods of sleep Stage 2 is mandatory to maximize the chance to record interictal and even subclinical ictal discharges or actual seizures.
- Use deltoid EMG (mandatory).
- Use extra electrodes placed in accordance with the 10-10 system (include midline sites), if possible.
- Repeating SDEEG, particularly after a recent seizure (<24 hours), may increase the yield of demonstrating an epileptiform abnormality.

Indications for prolonged EEG/video-EEG telemetry.

- Employ overnight ambulatory EEG if available for recovery of ED during N3 and REM sleep, and record subclinical seizures or focal seizures without awareness (*supplementary figure 5.22*).
- When interictal EEG is repeatedly normal, or when the diagnosis of psychogenic non-epileptic seizures (PNES) or of movement or a sleep disorder is suspected

as part of the clinical differential diagnosis (*supplementary figure 5.23*).

- Characterization of bizarre episodic behavioural changes when a frontal lesion is present on MRI.
- Ancillary testing if documentation of the semiology or number of seizures (quantification) is required.

Indications for invasive EEG.

- During frontal lobe seizures, localized rhythmic ictal beta, gamma, and HFO on subdural EEG may characterize the frontal lobe onset that is not detected by scalp recording (Jeha et al., 2007). Intracranial (with subdural and depth electrodes) EEG recordings are often necessary to localize or lateralize frontal lobe seizure onset when epilepsy surgery is being considered (Bautista et al., 1998).
- Invasive electrodes may be required for functional brain mapping with electrocortical stimulation when seizures arise close to eloquent cortex (e.g. motor or language functional areas).

Levels of EEG diagnosis (in patients with the appropriate clinical semiology of FLE)

Note: The use of interictal EEG in the diagnosis of FLE has many challenges with the multiple clinical subtypes and semiologies and the variety of electrographic presentations that range from normal to lateralized or bilateral interictal epileptiform discharges that may also include SBS. Even when a seizure occurs, obtaining a diagnostic EEG is extremely difficult due to the brief duration, lack of postictal changes, and prominent motor activity during seizures that often obscures the ictal EEG. The variety of findings in the interictal EEG from normal to lateralized, to bilateral features often requires intracranial EEG if precise localization is required for epilepsy surgery.

A) Confirmatory. An ictal EEG demonstrating localized frontal discharges, for instance lateralized low-voltage ictal fast activity (>13 Hz).

Interictal epileptiform discharges unilaterally over one or asymmetrically over both frontal regions (basic and advanced recording levels) associated with a frontal lobe lesion on brain MRI.

B) High diagnostic certainty (probable). Intermittent asymmetric bifrontal interictal epileptiform EEG (basic and advanced recording levels).

A brief hypermotor seizure that occurs directly out of sleep and captured on video makes a strong case for FLE with the appropriate semiology and moves the diagnostic certainty to level A. Appropriate genetic mutations (gene mutations of *nACHR*, *KCNT1*, and *DEPDC5*), if accompanied by stereotyped nocturnal focal seizures, move the diagnostic certainty to level A.

C) Low diagnostic certainty (possible). Nocturnal seizures based upon the clinical history and a normal interictal EEG, with fronto-temporal epileptiform discharges with or without a lesion on brain MRI, not contained within the frontal lobe.

5.3. OCCIPITAL LOBE EPILEPSIES

Overview

Occipital lobe epilepsies (OLE) manifest with seizures arising from the occipital cortex (occipital seizures) and include those of structural or yet unknown cause and Gastaut syndrome.

Occipital seizures also occur:

- (1) In a subset of children with Panayiotopoulos syndrome;
- (2) In other epilepsy syndromes of early onset (such as the migrating focal seizures and benign familial or non-familial neonatal-infantile seizures), in which they are not the characteristic seizure type; and
- (3) As a seizure symptom of some genetic (i.e. Lafora disease, MELAS) or metabolic (i.e. Celiac disease) disorders that can be associated with epilepsy.

Finally, OS not requiring the diagnosis of epilepsy, can occur as acute reactive events, for instance, in posterior leucoencephalopathy/eclampsia, in non-ketotic hyperglycaemia, and in hypercalcaemia.

This section deals with the OLEs of structural or yet unknown cause. The syndromes of Gastaut and Panayiotopoulos are described elsewhere.

Seizures: symptoms and semiology

Note: Irrespective of aetiology, clinical ictal manifestations, indicative of occipital onset, are common in all types of OLE:

Initial ictal symptoms are mainly visual hallucinations (typically contralateral to the occipital focus with frequent movement across, or bilateral [Blume et al., 1991]) and sensations of eye movement or pulling, oscillopsia, and ocular pain that relate to oculomotor semiology (oculoclonic movements, blinking, and nystagmus). Elementary visual hallucinations are characteristic (Panayiotopoulos, 1999) and indicate involvement of the primary visual cortex, while formed hallucinations and illusions reflect involvement of the visual association areas. Conscious eye deviation to the side of the visual field that contains the visual hallucinations is one of the most typical motor phenomena, usually with ipsilateral deviation of the head; of note, it may be ipsilateral to the occipital focus in a minority of patients (Williamson et al. 1992; Salanova et al., 1992). Deficient visual symptoms, such as scotomata, hemianopsias or transient amaurosis may follow, invading the visual fields transiently and swiftly in contrast to the slow spread of the scintillating scotomas of migraine.

Table 5. EEG findings in possibly genetic and structural OLE.

	Occipital epilepsy of Gastaut	Panayiotopoulos syndrome with occipital spikes	Structural OLE
Topography	Occipital	Occipital	Occipital “plus” in 46-70% (Salanova <i>et al.</i> , 1992; Ibrahim <i>et al.</i> , 2012)
Electronegativity over O1, O2	By default	By default	As low as 18% (Salanova <i>et al.</i> , 1992)
Laterality of occipital spikes/paroxysms	Bilateral up to 60%	Unilateral or bilateral	Usually unilateral, overlying the lesion
Regional slowing	No	No	As a rule
Topography of extra-occipital focal spikes (when present)	Mostly centrottemporal (up to 24%), less often temporal or frontal	Typically multifocal	Typically temporal, unilateral or bilateral (Blume <i>et al.</i> , 1991)
Generalized spike-wave	In up to 1/3	Up to 25%	Exceptional
Occipital ictal onset (scalp EEG)	Typical occipital	Occipital, but also multifocal	In about 20%; mostly, onset occurs over the wider posterior quadrant or the temporal lobe
Responsiveness to eye opening and fixation-off sensitivity (FOS)	Typically block in up to 90%; FOS is common	Typically block when occipital paroxysms are present; FOS is common	May attenuate in some cases, but FOS is exceptional (Gobbi, 2005; Koutroumanidis <i>et al.</i> , 2009; Ferlazzo <i>et al.</i> , 2010)
Photosensitivity	In 11-15%	Exceptional	Exceptional

Some patients with definite OLE may never report visual symptoms at seizure onset (Blume *et al.* 1991).

Rapid or slow propagation below the sylvian fissure to the mesial and lateral temporal areas may produce the typical ictal symptoms of TLE that include experiential phenomena, epigastric sensation, automatisms, reduced responsiveness, vomiting, headaches, and other autonomic symptoms. Occasionally, patients with confirmed OLE have loss of consciousness at seizure onset, consistently without warning (complex partial seizures only), mimicking TLE (Blume *et al.*, 1991). Suprasylvian propagation to frontal (motor and supplementary motor) areas is typically swift, leading to contralateral jerking/numbness or asymmetric tonic posturing. Secondary generalization can occur.

Postictal symptoms include blindness and migrainous headaches with the former specifically associated with occipital involvement.

Occipital seizures are typically brief, but simple visual status epilepticus and status epilepticus amauroticus have been reported.

EEG section

Note: Interictal occipital spikes are the cornerstone of EEG diagnosis and occur in all syndromes of OLE. However, there are significant differences between structural and presumed genetic occipital epilepsies that mainly concern consistency of appearance, topography, dependence on the condition of the eyes (open or closed), and patterns of extra-occipital discharges when these occur. Of note, occipital spikes may also occur in children without epilepsy. *Table 5* shows the principal EEG differences between the two major types of possible genetic (idiopathic) types of OLE and the structural occipital or posterior cortex epilepsy. The EEG findings of structural OLE, derived mainly from the literature on surgery series, are detailed here, while those of Gastaut and Panayiotopoulos syndromes are detailed in the relevant sections.

Background. Normal or regionally abnormal depending on the type and extent of the underlying pathology (*supplementary figures 5.24 and 5.25*). Interictal unilateral posterior slowing with or without distortion of the regional physiological background rhythms (alpha,

lambda, POSTS, and photic driving) is, as in TLE, commonly associated with ED.

Interictal paroxysms during wakefulness and sleep.

In general, the localization of interictal epileptiform activity is inferior to that in mesial and lateral TLE. Between 20 and 50% of patients with OLE may show no posterior spikes (Salanova *et al.*, 1992), whereas in the remainder, posterior spike topography may be more extensive, propagating to neighbouring lobes, or bilateral (Ibrahim *et al.*, 2012) (*supplementary figure 5.26*). Proper occipital (electronegative over O1/O2) spikes (*supplementary figures 5.24, 5.25 and 5.26*) are rather unusual (Salanova *et al.*, 1992). Unilateral or bilateral anterior to mid-temporal spikes have been described in all surgical series, reaching 58% (Blume *et al.*, 2005). Such temporal lobe topography reflects interictal propagation rather than independent epileptogenicity, and can be misleading in the absence of occipital spikes in up to 20-25% of patients with OLE (Salanova *et al.*, 1992).

HV does not seem to have an effect on posterior abnormalities, at least in the major surgical series, but sleep does activate posterior spikes (*supplementary figures 5.24, 5.26-5.28*).

EEG paroxysms that accompany ictal events.

Ictal discharges are commonly more widespread, involving also parietal and posterior temporal electrodes, and are therefore helpful in localizing the region of seizure origin in the wider “posterior cortex” rather than in the occipital lobes (Blume *et al.*, 1991; Salanova *et al.*, 1992). Seizures with visual symptoms only (simple partial) may not be associated with clear EEG changes.

Recording protocols

Basic level

Attempt to include sleep by letting the patient drowse even when a sleep recording has not been scheduled (see advanced level). Include HV and photic stimulation.

Advanced level

Waking and sleep EEG after partial SD with HV and photic stimulation. Sleep Stages 1 and 2 are important to activate ED, particularly when routine EEGs during wakefulness are normal (*supplementary figure 5.29*). Occurrence of occipital or posterior ED only or predominantly when the eyes are closed should prompt assessment for FOS (see section 4.3).

Levels of EEG diagnosis (based on clinical suspicion of OLE)

A) Confirmatory of diagnosis. For both recording levels: ictal recording with appropriate clinical symptoms

and EEG discharge with onset over the posterior cortex; typical interictal spikes.

B) High diagnostic certainty (probable). For both recording levels: no occipital seizure recorded, but typical interictal ED over the posterior cortex, with or without extra-occipital (temporal or frontal) spikes.

C) Low diagnostic certainty (possible). For both recording levels: unilateral interictal temporal, bi-temporal or other extra-occipital ED without ED over the posterior cortex. *Per se*, such findings do not support a clinical diagnosis of occipital or posterior cortex epilepsy, but they do not rule it out either, particularly when suggestive clinical symptoms are present. Employ advanced level EEG or telemetry to record posterior cortex seizures or ED and move diagnostic certainty up to either level A or B.

Note 1: A normal interictal basic or advanced EEG does not rule out OLE in the presence of convincing clinical symptoms. Proceed with, or repeat advanced SDEEG (*supplementary figure 5.29*), or telemetry.

Note 2: No EEG changes during a typical visual seizure without IoC should also prompt recording level 2 or telemetry.

Note 3: In patients with focal seizures and IoC from onset (without visual or other initial symptoms suggestive of posterior cortex onset), recording of posterior ED with or without associated temporal or other extra-occipital ED should raise the possibility of posterior cortex epilepsy.

Indications for video telemetry.

- (1) Repeatedly normal or with only extra-occipital ED EEGs in clinically suggested OLE/occipital seizures.
- (2) Normal EEG during visual symptoms suggestive of OLE.

6. PROGRESSIVE MYOCLONUS EPILEPSIES (PMEs)

PME occur in the context of rare genetic neurodegenerative disorders, most of which are inherited as autosomal recessive traits. They are generally characterized by: (1) action, but also resting, myoclonus; (2) generalized tonic-clonic or clonic-tonic-clonic seizures, but also clonic and focal seizures; and (3) progressive mental and motor deterioration, which mainly consists of cerebellar/extrapyramidal symptoms and signs (Marseille Consensus Group, 1990; Franceschetti *et al.*, 2014). This section includes the comparatively more frequent Unverricht-Lundborg disease (ULD) and the Lafora disease (LD), in which epileptic seizures are a core characteristic of the genetic disorder. Prognosis depends on the specific disease; LD is always fatal while ULD has a much slower progression. Diagnosis is important for genetic counselling, psychosocial

support, and rehabilitation, but can be challenging particularly during the initial stages when PME may mimic JME. Gene testing, when positive, confirms the specific disease. Genetic diagnostics are guided by a constellation of indicators that include age at onset, clinical symptoms including the order of their appearance and course, ethnic and geographical background, and pattern of inheritance (when not sporadic). Specific investigations, such as enzyme measurements and skin/muscle biopsy, may also be helpful. Polygraphic EEG recordings during the clinical course can provide significant diagnostic information.

6.1 Unverricht-Lundborg disease (ULD)

Overview

ULD (formerly called “Mediterranean” or “Baltic” myoclonus) is an autosomal recessive disease that has the highest incidence amongst PME (Marseille Consensus Group, 1990). Dodecameric expansions of the cystatin B gene, which is located on the 21q21.3 domain (EPM1), is the most classic genetic defect of ULD. The age at onset ranges between 6 and 18 years with a peak between 9 and 13 years of age. The cardinal and most disabling symptom is AM, which is, in the vast majority of cases, associated with epileptic seizures. Subtle segmental, arrhythmic, and asynchronous AM, more evident in the morning after awakening, is usually the presenting symptom. AM insidiously progresses impairing daily activities, including eating and drinking. Spontaneous (resting) myoclonus is rare. Myoclonus can also occur in response to stimuli such as noise, mental tasks, and stress. Nocturnal generalized clonic (GC) or clonic-tonic-clonic (GCTC) seizures are usually associated with AM, and a number of patients are photosensitive. As a rule, cognition remains grossly intact or becomes mildly affected either before the onset of motor symptoms or during the course of the disease; in general, it is much less impaired than motor function, but reactive depression may be severe. Although action myoclonus and ataxia progressively get worse, epileptic seizures remain generally well controlled. Treatment of choice includes VPA, LEV and CLZ (Genton *et al.*, 2012; Kälviäinen *et al.*, 2008). In a number of patients, high-dose piracetam (6–24 grams a day) may be very useful to control AM.

Seizures: symptoms and semiology

Myoclonic seizures. Action myoclonus (AM), mainly involving distal parts of the limbs and sometimes the face, is induced or exacerbated by active movements or intention of movement, and when maintaining a posture. AM may develop into a sequence of clonic seizures or status myoclonicus, or into a GTCS (clonic-tonic-clonic sequence). Myoclonus can also occur in

response to stimuli such as light, touch, noise, and increases with stress, while it tends to be less severe or even absent at rest or during sleep.

While resting, action and other reflex myoclonus are typically intermittent-erratic and multifocal, myoclonic activity may sometimes appear rhythmical like a tremor. The condition is called “cortical tremor” because it can be associated with high-frequency cortical potentials (Rubboli *et al.*, 2011). Cortical tremor can be seen early during the course of the disease.

Generalized clonic (GC) or clonic-tonic-clonic (GCTC) seizures. GTCS may or may not be preceded by myoclonus and typically occur after awakening or during sleep. Often, clusters of MS and GCTC may alternate with periods of lesser seizure activity.

Absences and focal seizures are not part of the disease.

EEG section

Background. Normal background activity is always present in the early stages and it may remain strictly normal for years. In some patients, moderate diffuse slowing may occur with time, but background never becomes disorganized, which is characteristic in LD.

Interictal paroxysmal abnormalities.

During wakefulness

Brief epileptic paroxysms of fast spikes or polyspikes may occur, associated or not with spontaneous isolated myoclonic jerks on EMG polygraphy (*supplementary figures 6.01 and 6.02*).

During sleep

Physiological sleep patterns are maintained unaffected in most patients. ED are not particularly activated in slow sleep, but in REM, fast spikes and polyspikes occur over the vertex in a number of patients (Genton *et al.*, 2012), which constitutes a clue for positive diagnosis (*supplementary figure 6.03*).

EEG paroxysms that accompany ictal events.

Myoclonus. At rest, the EMG expression of myoclonus is a burst of myoclonic potentials of brief (100 ± 50 ms) duration, typically occurring synchronously in agonist and antagonist muscles. The EMG correlate of a single action myoclonus is a potential of short duration (20 to 30 msec), which appears synchronously in agonist and antagonist muscles. It is usually followed by an EMG-silent period lasting 40 to 200 msec (post-myoclonic inhibition; *supplementary figure 6.04*).

Most myoclonic jerks in ULD are not associated with obvious time-locked spikes or other paroxysmal activity on the EEG. Spontaneous and action-induced segmental myoclonic jerks that comprise the prominent symptoms are typically unrelated to obvious EEG epileptic paroxysms (*supplementary figure 6.01*). Sometimes, the individual cortical EEG paroxysm that

drives the myoclonus may be difficult to notice without guidance from concurrent EMG polygraphy, or is not detectable on visual inspection at all. In rare instances, massive myoclonic jerks are associated with fast generalized spike waves or polyspike waves on the EEG. Therefore, myoclonic jerks can only be studied by concurrent EEG/EMG-polygraphy, the importance of which cannot be overemphasized (Avanzini *et al.*, 2016).

Recording protocols

Basic level

– In untreated children or adolescents with a suspicion of ULD (suggestive symptoms, or ethnic/geographical background and positive family history), an attempt to provoke and record AM with video-EEG and EMG polygraphy using bilateral deltoid/distal electrodes is strongly recommended. If channel availability is limited, EMG recording of the clinically relevant muscles (those which twitch) is advisable. If video is not available, close observation and accurate annotations by the EEG technologist are important.

– Activation methods include:

– HV and IPS to show EEG and possible clinical photosensitivity.

– Ask the patient to perform volitional movements; attempt to trigger segmental myoclonus with passive movements of the limbs, touching, and noises. As MS are activated by awakening, it is advisable to encourage a brief nap even when a routine EEG has been scheduled.

Advanced level

– It is mandatory that video-EEG includes sleep, and EMG polygraphy from proximal (deltoid) and distal, clinically relevant muscles, agonists and antagonists, and on both sides. Activation of AM is easier on awakening and should be performed, as for the basic level. EEG and clinical photosensitivity are also easier to elicit after awakening.

– Advanced level neurophysiological diagnostics should include **somatosensory evoked potentials (SSEPs)**. In PME patients, early SSEP components are typically enlarged (giant potentials), with major emphasis of the P25-N33 waves, which are thought to be related to the occurrence of reflex myoclonus.

Levels of EEG diagnosis

Note: Diagnosis of ULD can only be confirmed by genetic testing. Clinical and neurophysiological evidence has a complementary diagnostic role and guides genetic tests. Technically, therefore, the highest diagnostic certainty in this section is “probable ULD” and not “confirmatory of ULD”.

Full assessment of the EEG, video-EEG/EMG polygraphy, and SSEPs (with evaluation of changes over time)

is important to differentiate ULD from JME at a relatively early stage; erroneous diagnosis of the latter may be suspected when patients appear resistant to treatment with appropriate AEDs, EEG/EMG polygraphy demonstrates segmental multifocal action myoclonus, or when spike-wave discharges become less frequent or abate during sleep.

Neurophysiological studies may also help distinguish ULD from other adolescent-onset PME, such as Lafora disease, in which EEG changes are much more florid (see below).

High diagnostic certainty (probable ULD) (based on clinical suspicion of PME in untreated children)

Recording of typical action myoclonus with EMG polygraphy, and of the typical interictal spike-wave discharges and EEG photosensitivity; a mildly slow background may not be possible to appreciate early. In such cases, there is no need to perform diagnostic advanced sleep-deprived recordings.

Indications for performing or repeating sleep-deprived advanced EEG or prolonged video recording.

Failure to record action myoclonus in patients with suspected ULD. The degree of diagnostic certainty relies significantly on the longitudinal evaluation of the neurophysiological evidence.

Also, in patients with an initial working diagnosis of JME, who have, however, shown poor response to appropriate AED treatment (see also section on JME [3.3]).

6.2 Lafora disease (LD)

Overview

LD is a devastating autosomal recessive disease, caused by mutations in one of two known genes: *EPM2A* and *EPM2B* (*NHLRC1*). A third gene (*PRDM8*) may cause an early onset form of the disease. *EPM2A* encodes the protein laforin, while *EPM2B* encodes the protein malin. All three discovered genes are present on chromosome 6p23-27 in humans. Age at onset is similar to that of ULD (6-19 years), but in contrast to the latter, LD is associated with medication-refractory generalized clonic (GC), clonic-tonic-clonic (GCTC) and visual seizures, rapidly progressive dementia, and visual loss. Cognitive impairment progresses over months or years into an irreversible dementia. Resting and action myoclonus are severe, rapidly progressive, and typically resistant to anti-myoclonus treatment, and patients inevitably become bedridden and die within a decade from symptom onset. Nevertheless, mild forms of LD have also been described (Ferlazzo *et al.*, 2014). As in ULD, the initial EEG presentation may be similar to that in JME, but becomes rapidly

characteristic with diffuse slowing of background rhythms, distortion of sleep patterns, and increase of generalized spike/polyspike-wave discharges that parallels the progressive worsening of myoclonus. Photosensitivity and multifocal, mainly posterior, ED typically occur. Therefore, the diagnostic yield provided by the EEG is timely and important, and in some clinically typical cases it can suggest the diagnosis with a high degree of certainty. However, in view of the invariably dismal outcome, the diagnosis of LD needs to be secured with axillar skin biopsy, in search of PAS+ Lafora bodies in eccrine sweat gland ducts (*supplementary figure 6.05*), and genetic tests (*EPM2A* and *EPM2B* mutations).

Seizures: symptoms and semiology

MS. At first, MS are usually misdiagnosed as JME symptoms. Severe, intractable resting and AM then rapidly progress. Positive myoclonus is frequently associated with negative myoclonus. The latter is a brief involuntary jerky movement that is compensatory to a sudden postural lapse (due to a brief interruption of muscle tone). Negative myoclonus is associated with a sudden brief (100 to 500 msec) loss of the ongoing EMG signal from a muscle, which is tonically contracted at the time to maintain an antigravity posture, *without* antecedent myoclonus (*supplementary figure 6.06*).

Generalized clonic (GC) or clonic-tonic-clonic (GCTC) seizures. GC seizures are associated with GSWD/GPSWD at fast frequency. GCTC seizures are frequently the initial clinical manifestation of LD together with visual seizures (see *below*); they soon become resistant to anti-seizure treatment.

Visual seizures. These occur in half of the patients and are manifested with simple and complex hallucinations or scotomas. Their existence in the appropriate clinical context are highly suggestive of LD (Roger *et al.*, 1983).

EEG section

Background. Normal in the early stages; in contrast to ULD, the EEG becomes rapidly diffusely slow and disorganised, sometimes within a few months (*supplementary figure 6.06*).

Interictal paroxysmal abnormalities.

During wakefulness

Bilateral frontal-central, incompletely generalized and generalized spike and polyspike-wave discharges, isolated and singular or brief in the early stages of the disease course, become progressively longer and tend to cluster, and eventually become almost continuous (*supplementary figure 6.07*).

Focal/multifocal SWD occur, including the occipital areas (*supplementary figure 6.08; left panel*).

During sleep

In contrast to ULD, physiological sleep patterns become distorted early during the course of the disease and eventually disappear. In contrast to GGE/IGE, paroxysmal discharges including generalized spike-wave or polyspikes wave do not appear to increase in sleep. Diffuse multiple fast spikes show variable amplitude and topography and can be intermixed with fast activity, while posterior spikes persist during slow sleep and can appear enhanced during REM sleep.

EEG paroxysms that accompany ictal events.

MS. As in ULD (*supplementary figure 6.06*).

Visual seizures. In the few documented occipital seizures, onset with rhythmic spikes over the occipital areas has been described (Tinuper *et al.*, 1983).

Recording protocols are the same as in ULD for both the basic and the advanced level.

Levels of EEG diagnosis

Note: The diagnostic role of the EEG in LD is the same as in ULD (see *above*). The early background deterioration and the posterior spikes in combination with the early cognitive changes and possible visual seizures provide strong corroborative evidence for LD.

High diagnostic certainty (probable LD) (based on clinical suspicion of PME in untreated children)

Recording of the typical action myoclonus with EMG polygraphy, and of the typical interictal spike-wave discharges, including posterior spikes and EEG photosensitivity; early slowing/disorganization of background rhythms. In such cases, there is no need to perform diagnostic advanced sleep-deprived recordings.

Indications for performing or repeating sleep-deprived advanced EEG or prolonged video recording.

Failure to record action myoclonus; preserved background rhythms at initial EEG. As in ULD, the degree of diagnostic certainty relies on the longitudinal evaluation of the neurophysiological evidence.

Also, in patients with an initial working diagnosis of JME, who have, however, shown poor response to appropriate AED treatment (see *chapter on JME*).

Acknowledgements and disclosures.

Prof Samuel Wiebe, Liaison to the ILAE Executive Committee; Prof Edouard Hirsch, Liaison to the ILAE Classification Committee; and Dr Oliver Gubbay, Editorial Office, Epileptic Disorders. The authors have no conflict of interest to disclose.

References

- Agathonikou A, Panayiotopoulos CP, Giannakodimos S, Koutroumanidis M. Typical absence status in adults: diagnostic and syndromic considerations. *Epilepsia* 1998; 39(12): 1265-76.
- Ajmone-Marsan C, Lewis WR. Pathologic findings in patients with "centroencephalic" electroencephalographic patterns. *Neurology* 1960; 10: 922-30.
- Andermann F, Robb JP. absence status a reappraisal following review of thirty-eight patients. *Epilepsia* 1972; 13: 177-87.
- Avanzini G, Shibasaki H, Rubboli G, et al. Neurophysiology of myoclonus and progressive myoclonus epilepsies. *Epileptic Disord* 2016; 18(S2): 11-27.
- Bancaud J, Talairach J, Morel P, et al. Generalized" epileptic seizures elicited by electrical stimulation of the frontal lobe in man. *Electroencephalogr Clin Neurophysiol* 1974; 37: 275-82.
- Barba C, Barbari G, Minotti L, Hoffmann D, Kahane P. Ictal clinical and scalp-EEG findings differentiating temporal lobe epilepsies from temporal "plus" epilepsies. *Brain* 2007; 130: 1957-67.
- Barrington SF, Koutroumanidis M, Agathonikou A, et al. Clinical value of "ictal" FDG-positron emission tomography and the routine use of simultaneous scalp EEG studies in patients with intractable partial epilepsies. *Epilepsia* 1998; 39(7): 753-66.
- Bautista R, Spencer D, Spencer S. EEG findings in frontal lobe epilepsies. *Neurology* 1998; 50(6): 1765-71.
- Beaumanoir A, Capizzi G, Nahory A, Yousfi Y. Scotogenic seizures. In: Beaumanoir A, Gastaut H, Roger J. Reflex seizures and reflex epilepsies. *Geneve: Medecine and Hygiene* 1989: 219-23.
- Beghi E, Carpio A, Forsgren L, et al. Recommendation for a definition of acute symptomatic seizure. *Epilepsia* 2010; 51(4): 671-5.
- Beniczky S, Aurlen H, Brøgger JC, et al. Standardized computer-based organized reporting of EEG: SCORE. *Epilepsia* 2013; 54(6): 1112-24.
- Berg AT, Scheffer IE. New concepts in classification of the epilepsies: entering the 21st century. *Epilepsia* 2011; 52(6): 1058-62.
- Berg AT, Berkovic SF, Brodie MJ, et al. Revised terminology and concepts for organization of seizures and epilepsies: report of the ILAE Commission on Classification and Terminology, 2005-2009. *Epilepsia* 2010; 51: 676-85.
- Berkovic SF, McIntosh A, Howell A, Mitchell A, Sheffield IJ, Hopper JL. Familial temporal lobe epilepsy: a common disorder identified in twins. *Ann Neurol* 1996; 40(2): 227-35.
- Beydoun A, Garofalo EA, Drury I. Generalised spike-waves, multiple loci and clinical course in children with EEG features of benign epilepsy of childhood with centrottemporal spikes. *Epilepsia* 1992; 33: 1091-6.
- Binnie CD, Stefan H. Modern electroencephalography: its role in epilepsy management. *Clin Neurophysiol* 1999; 110: 1671-97.
- Binnie C, Stefan H. *The EEG in epilepsy*. Amsterdam: Elsevier Science BV, 2003.
- Birbeck GL, Chomba E, Atadzhanov M, et al. Evidence-Based Guidelines for EEG Utilization at the University Teaching Hospital (UTH). *Medical journal of Zambia* 2011; 38(3), <http://www.mjz.co.zm/content/neurological-psychiatric-society-zambias-evidence-based-guidelines-eeeg-utilization>.
- Blume WT, Lüders HO, Mizrahi E, Tassinari C, van Emde Boas W, Engel J Jr. Glossary of descriptive terminology for ictal semiology: report of the ILAE task force on classification and terminology. *Epilepsia* 2001; 42(9): 1212-8.
- Blume WT, Pillay N. Electrographic and clinical correlates of secondary bilateral synchrony. *Epilepsia* 1985; 26: 636-41.
- Blume WT, Whiting SE, Girvin JP. Epilepsy surgery in the posterior cortex. *Ann Neurol* 1991; 29(6): 638-45.
- Blume WT, Wiebe S, Tapsell LM. Occipital epilepsy: lateral versus mesial. *Brain* 2005; 128(5): 1209-25.
- Blumenfeld H. Impaired consciousness in epilepsy. *Lancet Neurol* 2012; 11(9): 814-26.
- Bonakis A, Koutroumanidis M. Epileptic discharges and phasic sleep phenomena in patients with juvenile myoclonic epilepsy. *Epilepsia* 2009; 50(11): 2434-45.
- Bray PF, Wiser WC. Evidence for a genetic etiology of temporal-central abnormalities in focal epilepsy. *N Engl J Med* 1964; 271: 926-33.
- Bray PF, Wiser WC. The relation of focal to diffuse epileptiform EEG discharges in genetic epilepsy. *Arch Neurol* 1965; 13: 223-37.
- Brodtkorb E, Gu W, Nakken KO, Fischer C, Steinlein OK. Familial temporal lobe epilepsy with aphasic seizures and linkage to chromosome 10q22-q24. *Epilepsia* 2002; 43: 228-35.
- Browne TR, Penry JK, Proter RJ, Dreifuss FE. Responsiveness before, during, and after spike-wave paroxysms. *Neurology* 1974; 24(7): 659-65.
- Camfield P, Camfield C. Idiopathic generalized epilepsy with generalized tonic-clonic seizures (IGE-GTC): a population-based cohort with >20 year follow up for medical and social outcome. *Epilepsy Behav* 2010; 18(1-2): 61-3.
- Capovilla G, Gambardella A, Rubboli G, et al. Suppressive efficacy by a commercially available blue lens on PPR in 610 photosensitive epilepsy patients. *Epilepsia* 2006; 47(3): 529-33.
- Capovilla G, Striano P, Gambardella A, et al. Eyelid fluttering, typical EEG pattern, and impaired intellectual function: a homogeneous epileptic condition among the patients presenting with eyelid myoclonia. *Epilepsia* 2009; 50(6): 1536-41.
- Caraballo R, Fejerman N. Management of epilepsy in resource-limited settings. *Epileptic Disord* 2015; 17(1): 13-8, quiz 18.
- Caraballo RH, Sologuestua A, Grañana N, et al. Idiopathic occipital and absence epilepsies appearing in the same children. *Pediatr Neurol* 2004; 30: 24-8.

- Caraballo RH, Cersosimo RO, Fejerman N. Childhood occipital epilepsy of Gastaut: a study of 33 patients. *Epilepsia* 2008; 49(2): 288-97.
- Caraballo R, Fontana E, Darra F, et al. A study of 63 cases with eyelid myoclonia with or without absences: type of seizures or an epileptic syndrome? *Seizure* 2009; 18: 440-5.
- Caraballo RH, Pasteris MC, Portuondo E, Fortini PS. Panayiotopoulos syndrome and diffuse paroxysms as the first EEG manifestation at clinical onset: a study of nine patients. *Epileptic Disord* 2015; 17(2): 143-9.
- Carpio A, Hauser WA. Epilepsy in the developing world. *Curr Neurol Neurosci Rep* 2009; 9: 319-26.
- Chatrjian GE, Bergamini L, Donday M, Klass DW, Lennox-Buchthal M, Petersén I. A glossary of terms most commonly used by clinical electroencephalographers. *Electroencephalogr Clin Neurophysiol* 1974; 37(5): 538-48.
- Commission on Classification Terminology of the International League Against Epilepsy. Proposal for Revised Clinical and Electroencephalographic Classification of Epileptic Seizures. *Epilepsia* 1981; 22: 489-501.
- Commission on Classification Terminology of the International League Against Epilepsy. Proposal for Classification of Epilepsies and Epileptic Syndromes. *Epilepsia* 1985; 26: 268-78.
- Commission on Classification Terminology of the International League Against Epilepsy. Proposal for Revised Classification of Epilepsies and Epileptic Syndromes. *Epilepsia* 1989; 30: 389-99.
- Covanis A, Lada C, Skiadas K. Children with rolandic spikes and ictus emeticus: Rolandic epilepsy or Panayiotopoulos syndrome? *Epileptic Disord* 2003; 5: 139-43.
- Crompton DE, Scheffer IE, Taylor I, et al. Familial mesial temporal lobe epilepsy: a benign epilepsy syndrome showing complex inheritance. *Brain* 2010; 133(11): 3221-31.
- Daly DD. Epilepsy and Syncope. Secondary Bilateral Synchrony. In: Daly DD, Pedley T.A, eds. *Current practice of clinical electroencephalography*. 2nd ed. Philadelphia, PA, USA: Lippincott-Raven, 1997: 310-1.
- de Bittencourt PR, Adamolekun B, Bharucha N, et al. Epilepsy in the tropics: I. Epidemiology, socioeconomic risk factors, and etiology. *Epilepsia* 1996; 37(11): 1121-7.
- Degen R, Degen HE, Reker M. Sleep EEG with or without sleep deprivation? Does sleep deprivation activate more epileptic activity in patients suffering from different types of epilepsy? *Eur Neurol* 1987; 26(1): 51-9.
- Di Bonaventura C, Carni M, Diani E, et al. Drug resistant ADLTE and recurrent partial status epilepticus with dysphasic features in a family with a novel LIG1 mutation: electroclinical, genetic, and EEG/fMRI findings. *Epilepsia* 2009; 50: 2481-6.
- Dua T, de Boer HM, Prilipko LL, Saxena S. Epilepsy care in the world: results of an ILAE/IBE/WHO global campaign against epilepsy survey. *Epilepsia* 2006; 47: 1225-31.
- Ebersole JS, Pacia SV. Localization of temporal lobe foci by ictal EEG patterns. *Epilepsia* 1996; 37: 386-99.
- Engel Jr. J. Report of the ILAE Classification core group. *Epilepsia* 2006; 47: 1558-68.
- Engel Jr J, International League Against Epilepsy (ILAE). Jr J. A proposed diagnostic scheme for people with epileptic seizures and with epilepsy: report of the ILAE Task Force on Classification and Terminology. *Epilepsia* 2001; 42(6): 796-803.
- Ferlazzo E, Calarese T, Genton P. Pharmacoresistant occipital lobe epilepsy with fixation-off sensitivity in a patient with cerebral calcifications: a video/EEG study. *Epilepsy Behav* 2010; 19(4): 647-9.
- Ferlazzo E, Canafoglia L, Michelucci R, et al. Mild Lafora disease: clinical, neurophysiologic, and genetic findings. *Epilepsia* 2014; 55(12): e129-33.
- Fink A, Kosecoff J, Chassin M, Brook RH. Consensus methods: characteristics and guidelines for use. *Am J Public Health* 1984; 74(9): 979-83.
- Flink R, Pedersen B, Guekht AB, et al. Guidelines for the use of EEG methodology in the diagnosis of epilepsy. International League Against Epilepsy: commission report. Commission on European Affairs: Subcommittee on European Guidelines. *Acta Neurol Scand* 2002; 106(1): 1-7.
- Foldvary N, Klem G, Hammel J, Bingaman W, Najm I, Lüders H. The localizing value of ictal EEG in focal epilepsy. *Neurology* 2001; 57(11): 2022-8.
- Fowle AJ, Binnie CD. Uses and Abuses of the EEG in Epilepsy. *Epilepsia* 2000; 41: S1068.
- Franceschetti S, Michelucci R, Canafoglia L. Collaborative LICE study group on PME. Progressive myoclonic epilepsies: definitive and still undetermined causes. *Neurology* 2014; 82(5): 405-11.
- Garcia Silva MT, Aicardi J, Goutières F, Chevrie JJ. The syndrome of myoclonic epilepsy with ragged-red fibers. Report of a case and review of the literature. *Neuropediatrics* 1987; 18: 200-4.
- Gastaut H. Clinical and electroencephalographical classification of epileptic seizures. *Epilepsia* 1970; 11: 102-12.
- Gastaut H, Zifkin BG. *Benign Epilepsy of Childhood With Occipital Spike and Wave Discharges*. In: Andermann F, Lugaresi E, eds. *Migraine and Epilepsy*. Boston: Butterworths, 1987: 47-81.
- Genton P, Bureau M. Progressive myoclonic epilepsies: myth or reality? *Epileptic Disord* 2006; 8(1): 37-43.
- Genton P, Gonzalez Sanchez M, Thomas P. Epilepsy with Grand Mal on Awakening. In: Roger J, Bureau M, Dravet P, Genton P, Tassinari CA, eds. *Epileptic Syndromes in Infancy Childhood and Adolescence*, 4th Ed. London: John Libbey Eurotext, 2005: 389-94.
- Genton P, Ferlazzo E, Thomas P. Absence status epilepsy: delineation of a distinct idiopathic generalized epilepsy syndrome. *Epilepsia* 2008; 49(4): 642-9.

- Genton P, Delgado-Escueta A, Serratosa JM, Bureau M. Progressive myoclonus epilepsies. In: Bureau M, Genton P, Dravet C, Delgado-Escueta A, Tassinari CA, Thomas P, Wolf P, eds. *Epileptic Syndromes in Infancy, Childhood and Adolescence 5th edition*. Paris: John Libbey Eurotext, 2012: 575-606.
- Genton P, Thomas P, Kasteleijn-Nolst Trenité DG, Medina MT, Salas-Puig J. Clinical aspects of juvenile myoclonic epilepsy. *Epilepsy Behav* 2013; 28(1): S8-14.
- Geyer JD, Bilir E, Faught RE, Kuzniecky R, Gilliam F. Significance of interictal temporal lobe delta activity for localization of the primary epileptogenic region. *Neurology* 1999; 52: 202-5.
- Giannakodimos S, Panayiotopoulos CP. Eyelid myoclonia with absences in adults: a clinical and video-EEG study. *Epilepsia* 1996; 37: 36-44.
- Giannakodimos S, Ferrie CD, Panayiotopoulos CP. Qualitative and quantitative abnormalities of breath counting during brief generalized 3 Hz spike and slow wave 'subclinical' discharges. *Clin Electroencephalogr* 1995; 26: 200-3.
- Gil-Nagel A, Risinger MW. Ictal semiology in hippocampal versus extrahippocampal temporal lobe epilepsy. *Brain* 1997; 120: 183-92.
- Gobbi G. Coeliac disease, epilepsy and cerebral calcifications. *Brain Dev* 2005; 27(3): 189-200.
- Granner MA, Lee SI. Nonconvulsive status epilepticus: EEG analysis in a large series. *Epilepsia* 1994; 35: 42-7.
- Guerrini R, Dravet C, Genton P, et al. Idiopathic photosensitive occipital lobe epilepsy. *Epilepsia* 1995; 36: 883-91.
- Hedera P, Blair MA, Andermann E, et al. Familial mesial temporal lobe epilepsy maps to chromosome 4q13.2-q21.3. *Neurology* 2007; 68(24): 2107-12.
- Hirsch E, Thomas P, Panayiotopoulos CP. Childhood and juvenile absence epilepsies. In: Engel J, Pedley T, eds. *Epilepsy: a Comprehensive Textbook*. Philadelphia: Lippincott William & Wilkins, 2007: 2397-411.
- Holmes GL, McKeever M, Adamson M. Absence seizures in children: clinical and electroencephalographic features. *Ann Neurol* 1987; 21: 268-73.
- Ibrahim GM, Fallah A, Albert GW, et al. Occipital lobe epilepsy in children: characterization, evaluation and surgical outcomes. *Epilepsy Res* 2012; 99(3): 335-45.
- Igwe SC, Brigo F, Beida O. Patterns of diagnosis and therapeutic care of epilepsy at a tertiary referral center in Nigeria. *Epilepsia* 2014; 55(3): 442-7.
- Janz D. Epilepsy with grand mal on awakening and sleep-waking cycle. *Clin Neurophysiol* 2000; 111(2): S103-10.
- Jeavons PM. Nosological problems of myoclonic epilepsies in childhood and adolescence. *Dev Med Child Neurol* 1977; 19: 3-8.
- Jeha LE, Najm I, Bingaman W, Dinner D, Widdess-Walsh P, Luders H. Surgical outcome and prognostic factors of frontal lobe epilepsy surgery. *Brain* 2007; 130(2): 574-84.
- Kälviäinen R, Khyuppenen J, Koskenkorva P, Eriksson K, Vanninen R, Mervaala E. Clinical picture of EPM1-Unverricht-Lundborg disease. *Epilepsia* 2008; 49(4): 549-56.
- Kander V, Wilmschurst JM. Training doctors in basic EEG: analysis of a learning tool relevant to resource-limited settings. *Epileptic Disord* 2015; 17(1): 58-66.
- Kaplan PW. Behavioral manifestations of nonconvulsive status epilepticus. *Epilepsy Behav* 2002; 3: 122-39.
- Kaplan PW, Benbadis SR. How to write an EEG report: dos and don'ts. *Neurology* 2013; 80(1): S43-6.
- Kariuki SM, White S, Chengo E, et al. Electroencephalographic features of convulsive epilepsy in Africa: A multicentre study of prevalence, pattern and associated factors. *Clin Neurophysiol* 2015a. pii: S1388-2457(15)00749-X.
- Kariuki SM, Chengo E, Ibinda F, Odhiambo R, Etyang A, Ngugi AK, et al. Burden, causes, and outcomes of people with epilepsy admitted to a rural hospital in Kenya. *Epilepsia* 2015bb; 56: 577-84.
- Kasteleijn-Nolst Trenité DGA, Guerrini R, Binnie CD, Genton P. Visual sensitivity and epilepsy: a proposed terminology and classification for clinical and EEG phenomenology. *Epilepsia* 2001; 42: 692-701.
- Kasteleijn-Nolst Trenité DGA, Waltz S, Rubboli G. Photosensitivity and syndromes. In: Bureau M, Genton P, Dravet C, Delgado-Escueta A, Tassinari CA, Thomas P, Wolf P, eds. *Epileptic syndromes in infancy, childhood and adolescence*, 5th ed. Philadelphia: John Libbey Eurotext Ltd, 2012: 507-28.
- Kasteleijn-Nolst Trenité D, Rubboli G, Hirsch E, et al. Methodology of photic stimulation revisited: updated European algorithm for visual stimulation in the EEG laboratory. *Epilepsia* 2012b; 53: 16-24.
- Kasteleijn-Nolst Trenité DG, Schmitz B, Janz D, et al. Consensus on diagnosis and management of JME: From founder's observations to current trends. *Epilepsy Behav* 2013; 28: S87-90.
- Kennedy JD, Schuele SU. Neocortical temporal lobe epilepsy. *J Clin Neurophysiol* 2012; 29(5): 366-70.
- Kobayashi E, D'Agostino MD, Lopes-Cendes I, et al. Outcome of surgical treatment in familial mesial temporal lobe epilepsy. *Epilepsia* 2003; 44(8): 1080-4.
- Koutroumanidis M, Smith S. Use and abuse of EEG in the diagnosis of idiopathic generalized epilepsies. *Epilepsia* 2005; 46(9): 96-107.
- Koutroumanidis M, Koepp MJ, Richardson MP, et al. The variants of reading epilepsy. A clinical and video-EEG study of 17 patients with reading-induced seizures. *Brain* 1998; 121: 1409-27.
- Koutroumanidis M, Hennessy MJ, Elwes RD, Binnie CD, Polkey CE. Coexistence of temporal lobe and idiopathic generalized epilepsies. *Neurology* 1999; 53(3): 490-5.
- Koutroumanidis M, Martin-Miguel C, Hennessy MJ, et al. Interictal temporal delta activity in temporal lobe epilepsy: correlations with pathology and outcome. *Epilepsia* 2004; 45(11): 1351-67.

- Koutroumanidis M, Aggelakis K, Panayiotopoulos CP. Idiopathic epilepsy with generalized tonic-clonic seizures only versus idiopathic epilepsy with phantom absences and generalized tonic-clonic seizures: one or two syndromes? *Epilepsia* 2008; 49(12): 2050-62.
- Koutroumanidis M, Tsatsou K, Sanders S, et al. Fixation-off sensitivity in epilepsies other than the idiopathic epilepsies of childhood with occipital paroxysms: a 12-year clinical-video EEG study. *Epileptic Disord* 2009; 11(1): 20-36.
- Koutroumanidis M, Tsiptsios D, Kokkinos V, Kostopoulos GK. Focal and generalized EEG paroxysms in childhood absence epilepsy: topographic associations and distinctive behaviors during the first cycle of non-REM sleep. *Epilepsia* 2012; 53(5): 840-9.
- Koutroumanidis M, Tsirka V, Panayiotopoulos C. Adult-onset photosensitivity: clinical significance and epilepsy syndromes including idiopathic (possibly genetic) photosensitive occipital epilepsy. *Epileptic Disord* 2015; 17: 275-86.
- Lagunju IOA, Oyinlade AO, Atalabi OM, et al. Electroencephalography as a tool for evidence-based diagnosis and improved outcomes in children with epilepsy in a resource-poor setting. *Pan Afr Med J* 2015; 22: 328.
- Lee SI, Sutherling WW, Persing JA, Butler AB. Language-induced seizure. A case of cortical origin. *Arch Neurol* 1980; 37(7): 433-6.
- Lombroso CT. Consistent EEG focalities detected in subjects with primary generalized epilepsies monitored for two decades. *Epilepsia* 1997; 38: 797-812.
- Maillard L, Vignal JP, Raffo E, Vespignani H. Bitemporal form of partial reading epilepsy: further evidence for an idiopathic localization-related syndrome. *Epilepsia* 2010; 51(1): 165-9.
- Mani KS. Global campaign against epilepsy. Agenda for IEA/IES. *Neurol India* 1998; 46: 1-4.
- Mariani E, Rossi LN, Vajani S. Interictal paroxysmal EEG abnormalities in childhood absence epilepsy. *Seizure* 2011; 20(4): 299-304.
- Marseille Consensus Group. Classification of progressive myoclonus epilepsies and related disorders. *Ann Neurol* 1990; 28(1): 113-6.
- Michelucci R, Passarelli D, Pitzalis S, Dal Corso G, Tassinari CA, Nobile C. Autosomal dominant partial epilepsy with auditory features: description of a new family. *Epilepsia* 2000; 41: 967-70.
- Ming X, Kaplan PW. Fixation-off and eyes closed catamenial generalized nonconvulsive status epilepticus with eyelid myoclonic jerks. *Epilepsia* 1998; 39: 664-8.
- Morita ME, Yasuda CL, Betting LE, et al. MRI and EEG as long-term seizure outcome predictors in familial mesial temporal lobe epilepsy. *Neurology* 2012; 79: 2349-54.
- Neubauer BA, Fiedler B, Himmelein B, et al. Centrottemporal spikes in families with rolandic epilepsy: linkage to chromosome 15q14. *Neurology* 1998; 51(6): 1608-12.
- Nicolaides P, Appleton RE, Beirne M. EEG requests in paediatrics: an audit. *Arch Dis Child* 1995; 72(6): 522-3.
- Niedermeyer E. The electroencephalogram and vertebralbasilar artery insufficiency. *Neurology* 1963; 13: 412-22.
- Noachtar S, Binnie C, Ebersole J, Mauguire F, Sakamoto A, Westmoreland B. A glossary of terms most commonly used by clinical electroencephalographers and proposal for the report form for the EEG findings. In: Deuschl G, Eisen A. *Recommendations for the practice of clinical neurophysiology: guidelines of the international federation of clinical neurophysiology*. Electroencephalography and clinical neurophysiology Elsevier Science, 1999; 52: 21-41.
- O'Brien TJ, Kilpatrick C, Murrie V, Vogrin S, Morris K, Cook MJ. Temporal lobe epilepsy caused by mesial temporal sclerosis and temporal neocortical lesion: A clinical and electroencephalographic study of 46 pathologically proven cases. *Brain* 1996; 119(6): 2133-41.
- Oguni H, Mukahira K, Oguni M, et al. Video-polygraphic analysis of myoclonic seizures in juvenile myoclonic epilepsy. *Epilepsia* 1994; 35(2): 307-16.
- Ohtsu M, Oguni H, Hayashi K, Funatsuka M, Imai K, Osawa M. EEG in children with early-onset benign occipital seizure susceptibility syndrome: Panayiotopoulos syndrome. *Epilepsia* 2003; 44(3): 435-42.
- Ottman R, Winawer MR, Kalachikov S, et al. LGI1 mutations in autosomal dominant partial epilepsy with auditory features. *Neurology* 2004; 62: 1120-6.
- PAHO (Pan American Health Organization). *World Health Organization 51st directing council, 63rd session of the regional committee*. Washington DC (USA): 26-30 September 2011.
- Pal DK, Li W, Clarke T, Lieberman P, Strug LJ. Pleiotropic effects of the 11p13 locus on developmental verbal dyspraxia and EEG centrottemporal sharp waves. *Genes Brain Behav* 2010; 9(8): 1004-12.
- Panayiotopoulos CP. Fixation-off, scotosensitive, and other visual-related epilepsies. *Adv Neurol* 1998; 75: 139-57.
- Panayiotopoulos CP. Visual phenomena and headache in occipital epilepsy: a review, a systematic study and differentiation from migraine. *Epileptic Disord* 1999; 1(4): 205-16.
- Panayiotopoulos CP, Obeid T, Waheed G. Absences in juvenile myoclonic epilepsy: a clinical and video-electroencephalographic study. *Ann Neurol* 1989a; 25(4): 391-7.
- Panayiotopoulos CP, Obeid T, Waheed G. Differentiation of typical absence seizures in epileptic syndromes. A video EEG study of 224 seizures in 20 patients. *Brain* 1989b; 112(4): 1039-56.
- Panayiotopoulos CP, Obeid T, Tahan AR. Juvenile myoclonic epilepsy: a 5-year prospective study. *Epilepsia* 1994; 35(2): 285-96.
- Panayiotopoulos CP, Koutroumanidis M, Giannakodimos S, Agathonikou A. Idiopathic generalised epilepsy in adults manifested by phantom absences, generalised tonic-clonic seizures, and frequent absence status. *J Neurol Neurosurg Psychiatry* 1997; 63(5): 622-7.

- Pedley TA, Mendiratta A, Walczack TS. Seizures and epilepsy. In: Ebersole JS, Pedley TA, eds. *Current Practice of Clinical Electroencephalography*, 3rd edition. New York: Lippincott Williams & Wilkins, 2003: 506-87.
- Penry JK, Porter RJ, Dreifuss RE. Simultaneous recording of absence seizures with video tape and electroencephalography. A study of 374 seizures in 48 patients. *Brain* 1975; 98: 427-40.
- Pillai J, Sperling MR. Interictal EEG and the diagnosis of epilepsy. *Epilepsia* 2006; 47(1): 14-22.
- Porter RJ, Penry JK. Responsiveness at the onset of spike-wave bursts. *Electroencephalogr Clin Neurophysiol* 1973; 34(3): 239-45.
- Qaseem A, Forland F, Macbeth F, Ollenschläger G, Phillips S, van der Wees P, for the Board of Trustees of the Guidelines International Network P. Guidelines International Network: Toward International Standards for Clinical Practice Guidelines. *Ann Intern Med* 2012; 156: 525-31.
- Radhakrishnan K. Challenges in the management of epilepsy in resource-poor countries. *Nat Rev Neurol* 2009; 5: 323-30.
- Radhakrishnan K, Silbert PL, Klass DW. Reading epilepsy. An appraisal of 20 patients diagnosed at the Mayo Clinic, Rochester, Minnesota, between 1949 and 1989, and delineation of the epileptic syndrome. *Brain* 1995; 118: 75-89.
- Radhakrishnan A, Menon RN, Radhakrishnan K. Coexistence of idiopathic generalized epilepsy among surgically treated patients with drug-resistant temporal lobe epilepsy. *Epilepsy Res* 2011; 96(1-2): 151-7.
- Raymond AA, Fish DR, Sisodiya SM, Alsanjari N, Stevens JM, Shorvon SD. Abnormalities of gyration, heterotopias, tuberous sclerosis, focal cortical dysplasia, microdysgenesis, dysembryoplastic neuroepithelial tumour and dysgenesis of the archicortex in epilepsy. Clinical, EEG and neuroimaging features in 100 adult patients. *Brain* 1995; 118: 629-60.
- Ritaccio AL, Hickling EJ, Ramani V. The role of dominant premotor cortex and grapheme to phoneme transformation in reading epilepsy. A neuroanatomic, neurophysiologic, and neuropsychological study. *Arch Neurol* 1992; 49(9): 933-9.
- Roger J, Pellissier JF, Bureau M, Dravet C, Revol M, Tinuper P. Early diagnosis of Lafora disease. Significance of paroxysmal visual manifestations and contribution of skin biopsy. *Rev Neurol (Paris)* 1983; 139(2): 115-24.
- Rowan AJ, Veldhuisen RJ, Nagelkerke NJ. Comparative evaluation of sleep deprivation and sedated sleep EEGs as diagnostic aids in epilepsy. *Electroencephalogr Clin Neurophysiol* 1982; 54(4): 357-64.
- Rubboli G, Meletti S, Gardella E, et al. Photic reflex myoclonus: a neurophysiological study in progressive myoclonus epilepsies. *Epilepsia* 1999; 40(4): 50-8.
- Rubboli G, Parra J, Seri S, Takahashi T, Thomas P. EEG diagnostic procedures and special investigations in the assessment of photosensitivity. *Epilepsia* 2004; 45(1): 35-9.
- Rubboli G, Franceschetti S, Berkovic SF, et al. Clinical and neurophysiologic features of progressive myoclonus epilepsy without renal failure caused by SCARB2 mutations. *Epilepsia* 2011; 52: 2356-63.
- Sadleir LG, Scheffer IE, Smith S, Carstensen B, Farrell K, Connolly MB. EEG features of absence seizures in idiopathic generalized epilepsy: impact of syndrome, age, and state. *Epilepsia* 2009; 50(6): 1572-8.
- Sadleir LG, Vears D, Regan B, Redshaw N, Bleasel A, Scheffer IE. Family studies of individuals with eyelid myoclonia with absences. *Epilepsia* 2012; 53(12): 2141-8.
- Salanova V, Andermann F, Olivier A, Rasmussen T, Quesney LF. Occipital lobe epilepsy: electroclinical manifestations, electrocorticography, cortical stimulation and outcome in 42 patients treated between 1930 and 1991. *Surgery of occipital lobe epilepsy*. *Brain* 1992; 115: 1655-80.
- Salanova V, Morris HH, Van Ness P, et al. Frontal lobe seizures: electroclinical syndromes. *Epilepsia* 1995; 36(1): 16-24.
- Scheffer IE, Berkovic S, Capovilla G, et al. ILAE classification of the epilepsies: Position paper of the ILAE Commission for Classification and Terminology. *Epilepsia* 2017 ; 58(4) : 512-21.
- Seneviratne U, Cook M, D'Souza W. Focal abnormalities in idiopathic generalized epilepsy: a critical review of the literature. *Epilepsia* 2014; 55(8): 1157-69.
- Serafini A, Rubboli G, Gigli GL, Koutroumanidis M, Gelisse P. Neurophysiology of juvenile myoclonic epilepsy. *Epilepsy Behav* 2013; 28(1): S30-9.
- Shimazono Y, Hirai T, Okuma T, Fukuda T, Yamamasu E. Disturbance of consciousness in Petit Mai epilepsy. *Epilepsia* 1953; C2: 49-55.
- Smith D, Bartolo R, Pickles RM, Tedman BM. Requests for electroencephalography in a district general hospital: retrospective and prospective audit. *BMJ* 2001; 322(7292): 954-7.
- Specchio N, Trivisano M, Di Ciommo V, et al. Panayiotopoulos syndrome: a clinical, EEG, and neuropsychological study of 93 consecutive patients. *Epilepsia* 2010; 51(10): 2098-107.
- Strug LJ, Clarke T, Chiang T, et al. Centrottemporal sharp wave EEG trait in rolandic epilepsy maps to Elongator Protein Complex 4 (ELP4). *Eur J Hum Genet* 2009; 17: 1171-81.
- Tao JX, Ray A, Hawes-Ebersole S, Ebersole JS. Intracranial EEG substrates of scalp EEG interictal spikes. *Epilepsia* 2005; 46(5): 669-76.
- Tatum WO, Selioutski O, Ochoa JG, Munger-Clary H, et al. American Clinical Neurophysiology Society Guideline 7: Guidelines for EEG Reporting. *J Clin Neurophysiol* 2016; 33(4): 328-32.
- Thomas P, Beaumanoir A, Genton P, Dolisi C, Chatel M. "De novo" absence status of late onset: report of 11 cases. *Neurology* 1992; 42: 104-10.
- Thomas P, Valton L, Genton P. Absence and myoclonic status epilepticus precipitated by antiepileptic drugs in idiopathic generalized epilepsy. *Brain* 2006; 129: 1281-92.

- Tinuper P, Aguglia U, Pellissier JF, Gastaut H. Visual ictal phenomena in a case of Lafora disease proven by skin biopsy. *Epilepsia* 1983; 24(2): 214-8.
- Tinuper P, Bisulli F. From nocturnal frontal lobe epilepsy to sleep-related hypermotor epilepsy: a 35-year diagnostic challenge. *Seizure* 2017; 44: 87-92.
- Trinka E, Baumgartner S, Unterberger I, et al. Long-term prognosis for childhood and juvenile absence epilepsy. *J Neurol* 2004; 251(10): 1235-41.
- Tükel K, Jasper H. The electroencephalogram in parasagittal lesions. *Electroencephalogr Clin Neurophysiol* 1952; 4: 481-94.
- Turnbull J, Tiberia E, Striano P, et al. Lafora disease. *Epileptic Disord* 2016; 18(2): 38-62.
- Unterberger I, Trinka E, Luef G, Bauer G. Idiopathic generalized epilepsies with pure grand mal: clinical data and genetics. *Epilepsy Res* 2001; 44: 19-25.
- Vadlamudi L, Milne RL, Lawrence K, et al. Genetics of epilepsy: the testimony of twins in the molecular era. *Neurology* 2014; 83(12): 1042-8.
- Valentin A, Hindocha N, Osei-Lah A, et al. Idiopathic generalized epilepsy with absences: syndrome classification. *Epilepsia* 2007; 48: 2187-90.
- van Donselaar CA, Schimsheimer RJ, Geerts AT, Declerck AC. Value of the electroencephalogram in adult patients with untreated idiopathic first seizures. *Arch Neurol* 1992; 49: 231-7.
- Waltz S, Christen HJ, Dooze H. The different patterns of the photoparoxysmal response—a genetic study. *Electroencephalogr Clin Neurophysiol* 1992; 83: 138-45.
- Watemberg N, Linder I, Dabby R, Blumkin L, Lerman-Sagie T. Clinical correlates of occipital intermittent rhythmic delta activity (OIRDA) in children. *Epilepsia* 2007; 48: 330-4.
- WHO. *Epilepsy in the African region: Bridging the gap*. Geneva: World Health Organization, 2004.
- WHO. *Atlas epilepsy care in the world 2005*. Geneva: World Health Organization, 2005.
- Williamson PD, Thadani VM, Darcey TM, Spencer DD, Spencer SS, Mattson RH. Occipital lobe epilepsy: clinical characteristics, seizure spread patterns, and results of surgery. *Ann Neurol* 1992; 31: 3-13.
- Williamson PD, French JA, Thadani VM, et al. Characteristics of medial temporal lobe epilepsy. II. Interictal and ictal scalp electroencephalography, neuropsychological testing, neuroimaging, surgical results and pathology. *Ann Neurol* 1993; 34(6): 781-7.
- Wilmshurst JM, Badoe E, Wammanda RD, et al. Child Neurology services in Africa. *J Child Neurol* 2011; 26: 1555-63.
- Winawer MR, Martinelli Boneschi F, Barker-Cummings C, et al. Four new families with autosomal dominant partial epilepsy with auditory features: clinical description and linkage to chromosome 10q24. *Epilepsia* 2002; 43: 60-7.
- Wirrell EC. Outcome of idiopathic generalized epilepsy and the role of EEG discharges. In: Arts WF, Arzimanoglou A, Brouwer OF, Camfield C, Camfield P, eds. *Outcome of childhood epilepsies*. Montrouge: John Libbey Eurotext, 2013: 149-62.
- Wu JY, Sankar R, Lerner JT, Matsumoto JH, Vinters HV, Mathern GW. Removing interictal fast ripples on electrocorticography linked with seizure freedom in children. *Neurology* 2010; 75(19): 1686-94.



FIGURES ONLINE

Visit www.epilepticdisorders.com to discover the commented educational figures with EEG plates (see Legends below).

Appendix 1. Legends of supplementary figures

Figure 2.01. Focal non-localizing 3-Hz spike-wave discharge during light sleep (Stage 2) in a child with CAE. Note the incomplete expression of the 3-Hz GSWD and the normal background.

Figure 2.02. Non-localizing focal spike-wave discharge over the left frontal area in a child with CAE. This child also had similar focal discharges over the right frontal area. Note the normal background that distinguishes this focal spike-wave from a stable epileptogenic focus that relates to a structural change (symptomatic), as in *figure 2.03*, and also the lack of spatial or temporal associations with the ensuing GSWD (see *diagnostic constraints for secondary bilateral synchrony below*) (from Koutroumanidis et al. [2012]).

Figure 2.03. The patient hesitates after reciting the number “5”, but is able to continue counting with the correct numerical sequence. Note that the responsible GSWD is briefer than two seconds.

Figure 2.04. Focal regular 3-Hz spike-wave discharge over the right frontal area in a child with a history of “blank spells” and left focal motor seizures. Note the similarities with the discharge in *figure 2.01*, but also the regional background disturbance which consists of irregular slow rhythms and sharp waves (arrow) maximal over the right central area. Brain MRI showed a large subependymal heterotopia on the right associated with cortical thickening.

Figure 2.05. SBS: Almost continuous pseudo-rhythmic theta and delta activity with intermixed sharp waves over the right anterior temporal inferior frontal area, leading to a high voltage, apparently generalized polyspikes-and-wave discharge (temporal constraint). Note the different morphology of the “triggering” focal ED compared to that of the SBS-GSWD.

Figure 2.06. SBS in a child with atypical absences and generalized convulsions: continuous sharp theta-fast delta activity over the right frontal area (arrows), leading to a high-voltage, apparently generalized 2.5-Hz spike-and-wave discharge (temporal constraint). As in *figure 2.04*, the morphology of the “triggering” focal ED is different to that of the SBS-GSWD.

Figure 2.07. A 22-year-old woman referred for “absences” that last for 1-2 mins, followed by some confusion and generalized convulsions. (A) Left temporal spikes during wakefulness; (B) left temporal sharp and slow waves during Stage 2 sleep, giving way to apparently generalized polyspike-wave discharges that cause epileptic arousal. The MRI scan showed left temporal cortical dysplasia involving the mesial neocortex and the temporal pole.

Figure 2.08. Long, 23-second GSWD of bilateral and synchronous onset, associated with motionless staring during a positron emission tomography (PET) scan. There are no “triggering” focal ED leading to the GSWD (the criteria of spatial and temporal constraints), but SBS can be assumed from the faster activities over the left temporal-parietal areas compared to the right in the first four seconds of the GSWD. The PET scan revealed left frontal hypometabolism (from Barrington et al., [1998]).

Figure 3.01. Focal spike-wave discharge over the right frontal area without associated regional background disturbance (left trace) and right frontal onset of a 3-Hz GSWD of a typical absence (right trace) in a girl with CAE (video-EEG; 1998). Such topographic correlation does not meet the diagnostic EEG criteria of SBS; the locations of both the focal spike-wave and the onset of GSWD switched sides during the recording (see *spatial constraint for SBS*), while their morphology is similar to that of the “bi-synchronous paroxysm”, the GSWD of the typical absence and the lead-in is short (see *temporal constraint for SBS*). The clinical picture was typical for CAE without features to suspect SBS. TA remitted at the age of 11 years and she has remained completely seizure-free and off antiepileptic treatment to date.

Figure 3.02. Complex TA during hyperventilation with breath counting in a girl with CAE (video-EEG): she stops over breathing and counting in the second of the GSWD (grey vertical arrow) and then engages in perioral automatisms until the end. The absence appears to end by hand clapping (white arrow). Note the bilateral OIRDA that becomes “spiky” before the onset of the GSWD (black arrow).

Figure 3.03. Focal spike-wave discharges during Stage 2 of sleep: (A) bi-frontal with the right side leading and skipping the mid-frontal position (Fz); (B) bi-occipital; (C) bilateral synchronous discharge, followed by a run of spike-wave complexes over the left frontal area and (D) bi-occipital (as in [B]), this time “triggering” a generalized polyspike-wave discharge.

Figure 3.04. Complex TA in a child with CAE (*de novo* bilateral hand automatisms on video-EEG). Note the asymmetric (in terms of voltage) onset of the GSWD with a prominent polyspike component within the first 500 ms over the right frontal areas. Note also the bilateral activation of the temporalis muscle, indicated by muscle artefact over the temporal areas.

Figure 3.05. Same girl as in *figure 3.04* following hyperventilation. She stopped ongoing motor activities (moving her hands) at onset and stares. She then swallows (vertical arrow) and presents hand automatisms during the last third of the absence. Note the bilateral frontal onset (more pronounced over the left frontal on this occasion) and the late occurrence of the manual automatisms.

Figure 3.06. Hyperventilation with breath counting in a boy with CAE (video-EEG): he swallows shortly after onset (vertical grey arrow) and 4 seconds later whistles for about 5 seconds; a rare *de novo* automatism (horizontal grey arrow). Note the temporary discontinuation of the GSWD, caused by noises made by the EEG technologist (white arrow). The GSWD resumed for a while until its spontaneous termination. Also, note a focal spike-wave discharge over the left frontal area 2 seconds before the absence started (black arrow).

Figure 3.07. Spontaneous TA with lateralized *de novo* automatisms 6 seconds from onset (grey arrow). The black arrow indicates the exact time of the video screen shot. Note the fast frequency and asymmetry of the GSWD during the initial 2 seconds (opening phase) before it becomes regular at 3-4 Hz.

Figure 3.08. Video-EEG of a 50-year-old woman with JAE and persisting absences (but not GTCS). Note the polyspike component in both discharges, which are subclinical.

Figure 3.09. Full EEG montage polysomnography of the same patient as in *figure 3.08*. Note the single spike/polyspike-wave discharges during Stage 3 (timing shown by the red arrow in the hypnogram), which do not appear to cause any EEG or autonomic arousal. The top two channels record eye movements; montage: longitudinal bipolar (double banana); 20 sec per page.

Figure 3.10. Full montage polysomnography of a 45-year-old woman with JAE and persisting absences and GTCS despite treatment with VPA and LTG. GSWD and bursts of polyspike-wave occurred during all periods of REM sleep (red arrows in top right panels in both [A] and [B] showing different REM phases). Montage: double banana; (A) 60 seconds per page; (B) 30 sec per page. The top two channels record eye movements; other channels have been omitted.

Figure 3.11. Typical absence during hyperventilation with breath counting in a 46-year-old man with JAE; he started having absences at the age of 11 years and GTCS in his early teens. He seems to maintain a minimum level of awareness during the absence as he restarted hyperventilation after being prompted by the EEG technologist (with some delay), and at the end of the seizure he appears to recall the last number he had pronounced when the absence occurred.

Figure 3.12. Light sleep of the patient in *figure 3.11*. Note on the left part of the trace the brevity of the regular GSWD that have slowed down in frequency compared to the absences while awake (*figure 3.11*), the emergence of polyspikes, and the “degradation” into solitary brief bursts of GSWD in the right half of the trace.

Figure 3.13. Long absence in an untreated 18-year-old woman with JAE. The patient remained completely unresponsive throughout the seizure that lasted 25 seconds (grey arrow). She had five long absences during this video recording, with the longest lasting 45 seconds (black arrow).

Figure 3.14. Video-EEG of the patient in *figures 3.13*, showing a variety of *de novo* motor automatisms.

Figure 3.15. Transition from an absence seizure to generalized tonic-clonic seizure (modified from Panayiotopoulos [2000]).

Figure 3.16. This brief diffuse burst of polyspikes-fast rhythm activity that precedes an otherwise regular 3-Hz GSWD is amongst the atypical JAE EEG features (see *text*).

Figure 3.17. Massive MS associated with generalized polyspike-wave discharge in a 22-year-old patient with drug-naïve JME. Note the abduction of both arms and legs and their flexion at the elbows, hips, and knees, as well as the slight extension of the neck. The patient hiccups loudly and his eyes open appearing blank for a split second.

Figure 3.18. Onset of a generalized clonic-tonic-clonic seizure in the patient presented in *figure 3.17* (same recording). A cluster of three massive MS precedes the onset of the tonic phase of the convulsion.

Figure 3.19. Phantom absence in a 32-year-old woman with JME: a 3.5-second GSWD is associated with hesitation in sequential breath counting; the patient still continues with the correct number but slightly later (at the time marked with the red arrow compared to that marked with the grey arrow). In all probability, she would have recalled a number or a word given by the EEG technologist during the GSWD (as she did on other occasions in that recording).

Figure 3.20. Video-EEG of a 28-year-old woman with resistant JME. (A) Fast GSWD pattern at 4-5 Hz. The arrow marks the time when a number was given by the EEG technologist, which the patient was perfectly able to recall. (B) Polyspike-and-wave discharge on eye closure a few seconds later (A). Note the slight right frontal predominance. (C) Generalized polyspike-wave during light slow sleep, again with right frontal emphasis.

Figure 3.21. SD video-EEG of a 26-year-old woman with JME; she had visual seizures at the age of 3.5 years, which stopped a few years later. She then suffered a GTCS on awakening at 11 years of age, and continued with early morning MS and brief absences soon thereafter. (A) Brief GSWD in early drowsiness, showing right posterior “onset”. (B) Focal right occipital and left frontal spikes. (C) GSWD during light slow sleep, this time with left frontal “onset”. (D) Right frontal spike-wave discharges during light slow sleep.

Figure 3.22. (A) Classic 3-Hz GSWD during wakefulness in a 34-year-old woman with JME. Note the right frontal emphasis of the GSWD at onset. (B) Focal right frontal spike-wave in the same patient. (C) GSWD during Stage 2 of sleep in the same patient. Note the left frontal emphasis of the discharge on this occasion. (D) Focal, non-localizing spikes in a 37-year-old man with JME.

Figure 3.23. SD video-EEG of a 50-year-old woman with JME. (A) GSWD during wakefulness showing typical JME fragmentations; the GSWD on the right side of (A) is independent, separated from the fragmented GSWD by clear normal background rhythms. (B) Fast brief GSWD during early drowsiness. (C) Brief spike and polyspike-wave discharges during Stage 2 sleep (same patient).

Figure 3.24. Generalized polyspike-wave discharge in a 27-year-old man with JME, which occurs following a spontaneous arousal. Note the fast rhythms and the bursts of EMG activity that immediately precede and follow the epileptic discharge.

Figure 3.25. Full EEG montage video polysomnography of the patient presented in figure 3.22D. Note the occurrence of GSWD during REM (shown by the white arrow in the hypnogram).

Figure 3.26. Full EEG montage video polysomnography of a 19-year-old man with JME. Repetitive GSWD during “sleep” (A) evolving into myoclonic status (B); note the spontaneous high-voltage delta arousal from Stage 3 of sleep (blue arrow), followed by the appearance of fast rhythms (green arrow) that precedes the first GSWD. Therefore, despite the apparent occurrence of the MS out of sleep (as a bed-partner would indicate), MS actually occurred post arousal. Also, note that despite their rhythmicity, GSWD are not at 3 Hz but consist of discrete discharges with clear biological activity between them.

Figure 3.27. Video-EEG after partial sleep deprivation in a 36-year-old woman with GTCS-a. (A) Light sleep; (B, C) hyperventilation (HV) with breath counting. During HV, GSWD were activated and became longer (2 sec in [B] and 2.5 sec in [C]) but were not associated with any hesitation or mistake in breath counting (see also box 2). This patient previously had a normal routine EEG during wakefulness, including HV.

Figure 3.28. Video-EEG after partial sleep deprivation in a 41-year-old man with GTCS-a. (A) Brief GSWD during wakefulness; (B) incompletely generalized GSWD during light sleep. Note the right frontal emphasis; (C) focal non-localizing spike-wave discharge over the right superior frontal (F4) electrode; (D) focal non-localizing spike-wave discharge, this time over the left superior frontal electrode (F3) during light sleep. The term “non-localizing” expresses the topographic versatility of the GSWD to “fragment” into focal spike-wave discharges in GGE/IGE (see also introduction on GGE/IGE and SBS).

Figure 3.29. Generalized polyspikes-and-wave discharge during tonic REM sleep in a 45-year-old man with valproate-resistant GTCS-a. Note the absence of rapid eye movements from the top two channels in the left half of the trace and the appearance of phasic REM in the right half of the trace.

Figure 3.30. Breath counting during HV on awakening in a 35-year-old woman with GTCS-a. Sleep had been achieved after partial sleep deprivation the night before this video-EEG. Sequential counting (arrows) showed no mistakes or hesitations.

Figure 3.31. SD video-EEG of a 31-year-old man with six GTCS since the age of 19 years and two episodes of absence status within a week that both ended in GTCS at the age of 26 when he came under our care. He had no history of absences or myoclonic seizures. In this first SDEEG, he had a number of phantom absences after awakening, which manifested with hesitations and mistakes in serial breath counting. In this example, note the brief duration of the GSWD which occurred within the first few seconds of HV, and resulted in clear hesitation (“10” would be expected around the time point indicated by the green arrow). Follow-up EEGs showed the occasional GSWD but no phantom absences. On valproate acid 300 mg bd, he has remained without any seizures during the six years of follow-up.

Figure 3.32. SDEEG of a 35-year-old man with a single episode of absence status (AS) that ended in GTCS at age 26 and a second GTCS a month later. HV after awakening with breath counting activated a number of brief GSWD that were associated with cessation of breathing but no errors in counting. He had no past history of previous absences, myoclonic seizures or prolonged dyscognitive episodes. On valproate acid, he has remained free of GTCS and episodes of AS for nine years, although follow-up EEGs have shown ongoing GSWD and a few PA, but never overt absences. He also reported no absences during these nine years.

Figure 3.33. Video-EEG of a 64-year-old woman with about 35 GTCS since the age of 30. This patient is in AS with moderate clouding of consciousness and is fully ambulatory. The AS was successfully treated with valproate acid and a follow-up video-EEG showed PA. The patient had been treated with carbamazepine for a number of years; she became seizure-free when carbamazepine was replaced by valproate acid.

Figure 3.34. Activation of brief GSWD by HV in E-PA. The patient (same as in figure 3.32) counts his breaths. The discharge on the left is subclinical while that on the right corresponds to a phantom absence.

Figure 3.35. (A) Long GSWD in early drowsiness in a 30-year-old woman with three GTCS, the first at age 18. She had no history of absences, myoclonic seizures or episodes of confusion or difficulty in concentration to suggest AS. (B) Incomplete GSWD on awakening prior to starting HV (same montage and calibration as in [A]).

Figure 3.36. A long, ~7-second GSWD during HV, performed after awakening in the patient in figure 3.35. The technologist calls loudly and clearly the number “four”, which the patient recalled and repeated after the end of the GSWD. She showed no clear behavioural change during the GSWD. During this HV session, the patient was not counting her breaths.

Figure 3.37. Phantom absence in the same patient as in *figures 3.35 and 3.36*. In this second HV session, the patient counts her breaths aloud (arrows). Note the hesitation that is apparently due to the second GSWD, which is shorter than the GSWD in *figure 3.36*. This was the only behavioural change, and the patient continued counting correctly. One would have expected similar hesitation during the GSWD of *figure 3.36* had the patient been counting her breaths on that occasion.

Figure 3.38. HV with breath counting in a 27-year-old woman with three GTCS during a period of seven years. She had no history of absences, myoclonic jerks or long dyscognitive periods suggestive of absence status (AS). Note the hesitation in breath counting before repeating the same number, caused by a GSWD of less than 2 seconds (phantom absence). She had no overt absences, while previous EEGs elsewhere had revealed subclinical 3-Hz GSWD.

Figure 3.39. Home video telemetry of a 50-year-old woman with monthly episodes of AS, probably since her early 20s. She had infrequent absences as a child, and four GTCS in total, the first at age 17 and three within one month at age 47. Note that the pattern is discontinuous and arrhythmic. She was able to perform all her usual activities at home (here she irons), including socializing with relatives in the evening, apparently without any undue behavioural changes. However, on other occasions, she reported mild difficulty in maintaining concentration.

Figure 3.40. Absence status ending in GTCS in a 39-year-old woman with absence status epilepsy manifesting with recurrent monthly confusional episodes lasting 3–24 hours. Left trace: ictal EEG showing continuous generalized spike-wave discharges at 2 Hz while the patient shows a moderate confusional state with slurred speech and temporo-spatial disorientation. Right trace: after 88 min of recording, a generalized tonic-clonic seizure occurs starting with a recruiting 7-Hz spike activity that interrupts the AS. The time between the two traces is 23 minutes.

Figure 3.41. Video-EEG of a 63-year-old man with a history of at least 10 prolonged episodes of reduced awareness since the age of 16 years, some of which ended in a GTCS. Left trace: a subclinical GSWD during HV with breath counting. The patient did not hesitate or make any counting error, therefore this is not a PA. Right trace: incomplete GSWD during light slow sleep.

Figure 3.42. Video-EEG of the same patient as in *figure 3.41*, two years later. GSWD are activated during HV, again without any mistakes or hesitations during breath counting (in two HV sessions).

Figure 3.43. SDEEG of the patient in *figure 3.39* (different recording). Brief GSWD during Stage 1 of sleep are followed by a brief delta hypersynchrony and emergence of alpha activity (epileptic arousal).

Figure 3.44. Video-EEG showing AS in a 59-year-old woman with frequent attendances to the emergency department for episodes of prolonged confusion. Throughout this EEG, performed several hours after the onset of AS, she remained in a sitting position with her eyes open and was unresponsive to commands, though she seemed vaguely aware of the presence of people around her. She had some semi-purposeful movements and at times slight shaking of the hands and feet. Note the arrhythmic pattern of the generalized discharge, the frequency of which ranges from ≤ 2 Hz to 4 Hz.

Figure 3.45. Video-EEG of a 29-year-old woman with a history of a single GTCS at age 23, terminating a two-hour period of severely clouded consciousness. She had several episodes of difficulty in concentration since then that became almost weekly over the three months preceding this recording. She had no history of absences or myoclonic seizures during her childhood or adolescence. Note the brief GSWD that are activated during HV, however, these did not disrupt correct and timely sequential breath counting.

Figure 3.46. Absence status (AS) in a 30-year-old woman with absences since the age of seven years and GTCS since her teens (three-day long home video telemetry). The test recorded a small number of mild fleeting absences and a 34-minute long episode of AS that was not associated with clinically overt behavioural changes or symptoms that would prompt her to activate the event marker. During the AS, she had a sensible conversation with her mother without either of them signalling that something was not right. Consciousness was reportedly more affected in other episodes of AS with the patient not being able to finish sentences, giving the wrong answers to simple questions, perseverating in her speech, and feeling “wobbly” with her body twitching and eyes “wondering off”. (A) Onset of AS at 7.16 am; (B–C) at 7.41 am; (D) spontaneous termination of AS at 7.49 am ([B] and [C]) are continuous).

Figure 3.47. *De novo* absence status in a 72-year-old woman after benzodiazepine withdrawal. IV levetiracetam resulted in clinical and EEG normalization. She had no past history of epileptic seizures, including prolonged states of confusion. She had no further symptoms and her follow-up EEG six months later was normal. Note that the continuous GSWD has maximal amplitude over the anterior areas and its frequency is 2.5 Hz (at the lower end of the GGE/IGE range).

Figure 3.48. *De novo* absence status of late onset in a 83-year-old woman after non-ketotic hyperglycaemia and multiple drug withdrawal. (A) Continuous, frontally accentuated 1.5-2-Hz GPSWD. (B) IV 1-mg clonazepam produces perfect EEG normalization and a clear clinical improvement.

Figure 3.49. This 81-year-old woman with no previous neurological problem had a false diagnosis of dnASLO with a progressive confusion shortly after she was treated for a systemic infection with IV cefepime. EEG shows diffuse 2.5-3-Hz triphasic sharp waves. IV 1-mg clonazepam, as well as various IV antiepileptic drug trials (IV fosphenytoin and IV levetiracetam), had no effect. Complete resolution occurred three days after cefepime discontinuation.

Figure 3.50. Semi-continuous rhythmic triphasic waves at around 2 Hz in a patient with hepatic encephalopathy.

Figure 3.51. Diffuse rhythmic triphasic waves at 1.5-2 Hz in a patient with hypoxic encephalopathy.

Figure 3.52. Video-EEG showing absence status in a 34-year-old man with eyelid myoclonia with absences (from Agathonikou *et al.* [1998]).

Figure 3.53. Video-EEG of the patient in *figure 3.52*. The typical absence on the left half of the trace occurs when eyes are open and is associated with regular 2.7-Hz GSWD. Note the eye closure-induced GSWD on the right end of the trace, which is associated with eyelid myoclonia.

Figure 3.54. Video-EEG of a 43-year-old woman with eyelid myoclonia with absences, showing interictal eye closure abnormalities with posterior emphasis in the first discharge on the left, and posterior “lead-in” of the GSWD on the right, which is of maximal voltage over the frontal areas.

Figure 3.55. Video-EEG of the patient in *figure 3.52*, showing interictal, frontally predominant GSWD in brief distinctive bursts (A) and repetitive/confluent GSWD.

Figure 3.56. Video-EEG of a 12-year-old girl with eyelid myoclonia with absences. Note the left posterior focal spikes in (A) and (B) and the right lateral temporal spikes in (C). Note that the GSWD in (A) is prompted by eye closure.

Figure 3.57. Same patient as in *figure 3.56*. Two eye closure EEG abnormalities were observed at commonly used sensitivity (A) and at higher sensitivity (B). In (A), the first discharge appears as abortive (incompletely) generalized with posterior emphasis, while the second appears generalized. At higher sensitivity, it becomes clear that both are more restricted; the first is posterior focal and the second incompletely generalized with posterior emphasis.

Figure 3.58. Video-EEG of the patient in *figure 3.54*. Note the activation of subclinical eye closure abnormalities during HV.

Figure 3.59. (A) 3-Hz incompletely generalized spike/polyspike-wave discharges during Stage 2 of sleep in a 22-year-old man with Jeavons syndrome; (B) occipital spike-wave discharges during Stage 1 of sleep in the patient in *figures 3.56 and 3.57*.

Figure 3.60. Video-EEG of a 64-year-old man with episodes of eyelid myoclonia and absences since childhood and sporadic GTCS. Left trace: diffuse recruiting rhythm giving way to 3-Hz GSWD; right trace: frontally predominant generalized polyspike-wave discharges during Stage 2 of sleep.

Figure 3.61. Video-EEG of the patient in *figure 3.52*, showing an episode of eyelid myoclonia. Note the GSWD that occurs just before the eye closure (arrow).

Figure 3.62. Typical ictal irregular GSWD/GPSWD in the patient of *figure 3.52*.

Figure 3.63. Patient of *figure 3.52*; showing eye closure abnormalities that do not persist over the whole period, during which eyes remain closed. This is in contrast to fixation-off sensitivity (FOS), in which discharges continue for as long as eyes remain closed (see also *chapter on FOS*).

Figure 3.64. Left trace: episodes of eyelid myoclonia in a 29-year-old woman, facilitated by bright sunlight that may also include a component of pattern effect (window blinds). Right trace: only a few seconds later, dark sunglasses completely abolished the clinical/EEG phenomenon by reducing the amount of epileptogenic stimulus; note that the orientation of the patient towards the sunlight and the shape of the eye closure artefact remained the same.

Figure 3.65. HV with breath counting performed after awakening during SDEEG in a 21-year-old woman with Jeavons syndrome and infrequent independent early morning myoclonic jerks. The patient stops counting in each episode of eyelid myoclonia (eyelid myoclonia with absences).

Figure 3.66. Patient of *figures 3.56 and 3.57*. Left side of the trace: prolonged eye closure provokes bilateral runs of fast occipital spikes ending with a spike-wave, but does not trigger eyelid myoclonia. Right side of trace: monocular IPS at 30 Hz, performed after awakening and HV. Note that the photoparoxysmal response is far more substantial and appears to be temporarily inhibited by brief eye opening (white arrow), but resumes promptly on the second eye closure, and is also associated with an axial jerk (black arrow).

Figure 3.67. Dissociated response to eye closure and IPS in a 20-year-old woman with eyelid myoclonia with absences. A brief GSWD of posterior emphasis occurs during the ascending (positive) deflection of the eye closure artefact, coinciding with the onset of the IPS (black arrow); a second regular 3-Hz GSWD occurs probably after adequate temporal summation of IPS, showing posterior lead-in (white arrow).

Figure 3.68. Video-EEG day telemetry of a 20-year-old man with eyelid myoclonia with absences and additional SI. Note the “attempts” to induce absences by multiple voluntary eye blinks.

Figure 3.69. Video-EEG of the patient in *figure 3.66*. Left side of the trace: eye closures on command generate only brief traces of fast alpha activity. Right side of trace: self-motivated eye closures are longer and generate brief bursts of occipital spikes. Pronounced rolling of the eyeball upwards (Evans-Mulholland effect) occurs in both types.

Figure 3.70. Video-EEG day telemetry of a 28-year-old woman with eyelid myoclonia, absences, and infrequent GTCS. She made a few unsuccessful long eye closures (producing only alpha activity but no spikes) after she was left alone for some time reading a magazine. (A) and (B) show the same eye closure at different times (arrows). Note the muscle activity in the frontal channels that reflects eyelid flickering and the substantial upward rolling of her eyeballs indicated by the high-voltage positive deflection following the negative deflection of the eye closure. The complex eye movement is associated with head turning upwards, appreciated on the video (B). The EEG room is moderately lit.

Figure 4.01. Orbitofrontal photomyoclonus. Note the self-limiting EMG response that is induced when eyes are closed, which is maximal frontally and has the same frequency as the IPS.

Figure 4.02. Photoparoxysmal response to IPS when eyes are open.

Figure 4.03. Generalized photoparoxysmal responses associated with symmetric (left) or asymmetric (right) myoclonic jerks.

Figure 4.04. A typical absence provoked by IPS at 8 Hz. The patient remained unresponsive throughout the seizure.

Figure 4.05. IPS-provoked occipital seizure evolving into GTCS.

Figure 4.06. Generalized PPR at 8-Hz IPS, evolving into a GTCS in a patient with a history of photically-induced generalized seizures. Note the asymmetric tonic posturing at the time point marked by the green arrow.

Figure 4.07. Reading-induced jaw myoclonus, associated with left-sided ictal sharp wave discharge in trace (A) and with bilateral synchronous low-voltage spike-wave discharges with left-sided emphasis in traces (B) and (C). Note that while both ictal discharges in traces (B) and (C) correlate with clinically evident jaw jerks, only the ictal discharge in trace (B) appears to associate with a brief EMG potential (from Koutroumanidis *et al.* [1998], with permission).

Figure 4.08. Reading-induced interictal activation (A) and focal seizure manifesting with alexia and dysphasia (B and C). (A) Reading induces subclinical delta transients over the left (dominant) temporal areas (red arrows), which abate as soon as the patient ceases to read (blue arrow). (B) Soon after the patient started reading aloud, rhythmic monomorphic delta activity at 0.8-1 Hz appeared over the left temporal area (red arrows). The patient was still able to read until he suddenly hesitated and repeated a word for a couple of times (green arrow) as though he tried to understand it, and pressed the event button (black arrow). The EEG normalized for few seconds and then an irregular low-voltage 3.5-5-Hz activity appeared over the left temporal areas (right end of trace [B]), followed by a sharpened rhythmic theta activity at 5 Hz (beginning of trace [C]). The electrical seizure ceased 94 seconds after the onset of the first behavioural changes, followed by a short period of postictal suppression on the left. The patient remained conscious throughout and able to understand simple questions and execute simple commands (yellow arrow), but was unable to make sense of the text and showed expressive dysphasia responding only by nodding of his head. The seizure is depicted in a discontinuous manner to include only the periods during which distinct behavioural and electrical changes occurred (modified from Koutroumanidis *et al.* [1998], with permission).

Figure 4.09. Video-EEG activated by reading of a 25-year-old student of English literature with reading-induced paroxysmal dyslexia. He had his first generalized convulsion while reading on a train. Treatment with carbamazepine for three years has prevented further GTCS, but reading for a long time still induces episodes of dyslexia. He now reads taking short breaks. Resting EEG is entirely normal, while reading aloud induces brief episodic stuttering, associated with brief runs of left mid- to posterior temporal spike-wave discharges (double arrows) and subclinical discharges (single arrows).

Figure 4.10. Myoclonic seizures associated with solitary and 3-Hz generalized spike/polyspike-wave discharges in a 20-year-old woman with first GTCS. Note the associated deltoid EMG potentials (arrows). No discharges occurred while her eyes remained open fixating, and formal testing revealed FOS (HFF: 70 Hz; TC: 0.3 sec).

Figure 4.11. Diagnostic process in FOS. Top left trace: bilateral synchronous occipital paroxysms (OP), occurring when eyes are closed are promptly inhibited by eye opening and visual fixation; this pattern should arouse suspicion of FOS. Top right trace: ongoing OP when dark goggles are “on” irrespective of whether eyes are open or shut; such reaction suggests that FOS is highly probable, but cannot rule out pure scotosensitivity (scotos: darkness). Lower trace: FOS is demonstrated using translucent goggles that let light through but abolish fixation; eyes are open with dark goggles “on” (left third), dark goggles “off” and visual fixation (middle third), and +10 translucent goggles “on” (right third). Sub-clinical generalised polyspike-wave discharges interspersing OP are marked with arrows (HFF: 70 Hz; TC: 0.3 sec) (from Koutroumanidis et al. [2009]).

Figure 4.12. Generalized spike/polyspike-wave and 3-Hz spike-wave discharges shortly after awakening in the patient of figure 4.10 with newly diagnosed JME and FOS (sleep-deprived video-EEG; HFF: 70 Hz, TC: 0.3 sec). Note the associated myoclonic jerks on the EMG polygraphy (arrows)

Figure 4.13. FOS in an 18-year-old woman with IGE/GGE with absences and photosensitivity since age eight. Top trace: “eyes closed”-related posterior high-voltage 3-4-Hz delta rhythm with intermixed spikes and more generalised bursts of spike-wave activity (white arrows). Both types of discharge relate to FOS, appear >2 seconds after eye closure, occur while eyes remain closed, and block on eye opening and volitional visual fixation. Note also the brief discharge of polyspike-wave that occurs upon “eye closure” (grey arrow) and relates to her photoparoxysmal response (not shown here). Lower trace: the patient wears goggles completely covered by black tape for absolute darkness. Both posterior high-voltage delta rhythm (black arrow) and the generalised bursts of sharp activity (white arrows) also occur when eyes are open. Note that in complete darkness, the eye closure (photosensitivity-related) paroxysms are blocked (grey arrow) (HFF: 70 Hz, TC: 0.3 sec) (from Koutroumanidis et al. [2009]).

Figure 5.01. Coronal T1-weighted high-resolution brain MRI with (A) left hippocampal atrophy (circle) and (B) high-signal lesion on coronal FLAIR sequences (arrow). Note the cavum septum vergae incidentally. This patient subsequently underwent successful stereotactic laser ablation to become seizure-free.

Figure 5.02. Diffuse slowing of the posterior dominant rhythm to 6 Hz (red arrow) following a recent series of focal seizures with impaired consciousness. Note the lateralized periodic right mid-temporal spikes (black arrows). This patient had a lesion in the mid-hippocampus and was being evaluated for epilepsy surgery.

Figure 5.03. Right temporal intermittent rhythmic delta activity (TIRDA), augmented by hyperventilation. Depth electrode recordings showed right hippocampal onset for his habitual seizures.

Figure 5.04. Right anterior temporal spike-and-slow-wave discharge (sixth second) with ipsilateral regional temporal delta slowing in a patient with right mTLE due to HS.

Figure 5.05. Independent bitemporal epileptiform discharges with a regional temporal field (arrows). This patient had mTLE due to HS and underwent successful laser ablation of the left amygdalohippocampal complex.

Figure 5.06. Scalp ictal EEG demonstrating a unilateral right temporal rhythmic ictal theta discharge in a patient with right mTLE due to HS.

Figure 5.07. Change in electrode nomenclature (black) in the 10-10 system of electrode placement on scalp EEG.

Figure 5.08. Focal right mid-temporal slowing in a male with post-infarction focal seizures after a right middle cerebral artery stroke.

Figure 5.09. Interictal EEG with a right mid-temporal spike and slow wave in a patient with right temporal neocortical epilepsy due to an arteriovenous malformation.

Figure 5.10. Aphasic status epilepticus in a 28-year-old with left neocortical temporal lobe epilepsy. Note the rhythmic left regional temporal 1.5-2.5-Hz delta activity and intermixed lateralized periodic discharges (arrow) and the interictal anterior temporal spike (seconds 7 and 12). Brain MRI was normal.

Figure 5.11. A left mid-temporal isolated wicket spike in a patient without epilepsy referred for an EEG due to complaints of dizziness.

Figure 5.12. EEG with a single left anterior temporal spike-and-slow-wave during sleep in a 19-year-old with episodes of *déjà vu*. The patient had normal brain MRI, and neurological examination, and three generations of family members had similar symptoms.

Figure 5.13. Left mid-temporal spike with a regional temporal field in a patient with rare temporal lobe seizures preceded by an aura of hearing crickets.

Figure 5.14. Frequent right fronto-polar spikes in a patient with post-traumatic epilepsy and bilateral orbitofrontal encephalomalacia on brain MRI. Note the very focal field identified using a transverse bipolar montage (arrows).

Figure 5.15. Frontal intermittent rhythmic delta activity in a patient with orbitofrontal epilepsy.

Figure 5.16. Video-EEG obtained in a six-year-old girl demonstrating nearly continuous focal bilateral right > left frontal-frontopolar spikes associated with right frontal cortical dysplasia that involves the superior and middle frontal gyrus. This EEG was obtained during the “interictal” state.

Figure 5.17. Left frontal spike (third second) coupled with sleep elements prior to a generalized discharge composed of mixed spikes and polyspike-and-slow waves in a patient with mesial frontal lobe epilepsy (SBS).

Figure 5.18. A 7-second right frontal lobe seizure in a 28-year-old female with left hemiparetic cerebral palsy, manifesting as brief nocturnal left-sided tonic posturing. Note the superimposed myogenic artefact preventing localization.

Figure 5.19. Right frontal seizure occurring in N3 in the girl of *figure 5.16*. Semiology is subtle with eye deviation to the left and subtle eyelid clonus. Note the paucity of the nearly continuous right frontal spiking, a few seconds prior to the electrographic onset (arrow).

Figure 5.20. Brief left frontal electrographic seizure in a 30-year-old man with left frontal epilepsy and nocturnal seizures since childhood. MRI was normal. He remained unaware of this event. Note the initial attenuation prior to the low-voltage fast ictal discharge that progressively increases in amplitude (arrow).

Figure 5.21. Left panel: ictal EEG with a right frontal lobe seizure in a patient with post-traumatic epilepsy. Ictal symptoms included headache, gustatory hallucinations associated with “sickness” and “emptiness in his head”. He remained conscious and responsive throughout the attack that lasted one minute. Right panel: postictal slowing over the right anterior quadrant persisted for 20 minutes without any associated symptoms. Interictal spikes occurred over the right central area (arrow).

Figure 5.22. Full montage polysomnography obtained for a man with medically intractable non-lesional FLE with seizures arising exclusively from sleep. Note the localization of rhythmic spiking in the left frontal region during REM sleep.

Figure 5.23. Diagnostic video telemetry of a 17-year-old woman with nocturnal “events” since her early teens. Two previous EEGs had been unremarkable. (A) Rhythmic spiking over the left frontal area; the patient simply wakes and sits up. (B) Interictal abnormalities were limited to occasional small spikes over F3. Brain MRI and PET were normal.

Figure 5.24. Sleep-deprived video-EEG of a 28-year-old woman with right OLE since her early teens; brain MRI was normal. During early drowsiness (A), right occipital spike-wave discharges intersperse on-going regional irregular delta rhythm (green arrow). Brief bursts of low-voltage fast polyspike discharges occurred over the right occipital area during sleep ([B]; red arrow). Note the different polarity of the physiological positive occipital transients of sleep (POSTs) (blue arrow), compared to the occipital negativity of the occipital spikes.

Figure 5.25. Right occipital spikes diffusing to the left posterior areas and attenuating on eye opening in a 19-year-old woman with right OLE. Note the occipital electronegativity of the spikes and the lack of regional background disturbance despite the structural lesion. Brain MRI showed a sizable right dysembryoplastic neuroepithelial tumour (DNET); (A) coronal FLAIR and (B) axial TW2 (from Koutroumanidis *et al.* [2009]).

Figure 5.26. Sleep EEG of a 22-year-old man with right OLE. (A) High-voltage right occipital sharp waves followed by polyspikes that appear to propagate anteriorly amidst sleep spindles. (B) Bilateral occipital high-voltage “triphasic” sharp waves with a very short time lag between the sides (blue arrow), implying propagation to the left occipital areas rather than “diffusion” as in *figure 5.25*. Note that occasional occipital sharp waves occur independently on the left. Brain MRI was normal.

Figure 5.27. Preoperative (A) and post-operative (B) sleep EEG of the patient in *figure 5.25* (both traces are from sleep Stage 1). Note that, post-operatively, spikes do not appear to diffuse to the left posterior areas as they did pre-operatively (see also *figure 5.25*) and also that their polarity has changed, now phase reversing over the right temporal area (arrow). There is also some irregular delta activity in-between the spikes, which was absent in all her pre-operative recordings.

Figure 5.28. Right occipital spikes of a 12-year-old boy with formed visual hallucinations during wakefulness (A) and sleep Stages 1-3 (B, C and D). Brain MRI was normal.

Figure 5.29. Bilateral bursts of occipital polyspikes (centre of the trace) in a 28-year-old woman with stereotyped formed visual hallucinations since age 14 years, previously misdiagnosed for psychogenic non-epileptic seizures. She had several normal waking EEGs until this recording. Brain MRI was normal.

Figure 6.01. Action myoclonus in Unverricht-Lundborg disease (ULD). Left: this 23-year-old woman with genetically-proven ULD has normal resting EEG. Voluntary movement induces marked action myoclonus superimposed on the EMG traces without associated EEG changes. Intermittent photic stimulation (ILS) triggers fast generalized spike-waves with a posterior predominance and myoclonic jerks without clear EEG/EMG associations. Right: this 13-year-old girl has also genetically-proven ULD. (A) Fast generalized spike-waves with no clinical correlate. (B) Left then right asynchronous myoclonic jerks are followed by bilateral, low-amplitude myoclonus which coincides with a generalized polyspike and polyspike-wave discharge on the EEG (Courtesy of Michelle Bureau, MD Centre Saint-Paul/Hôpital Henri Gastaut, Marseilles, France).

Figure 6.02. EEG/EMG correlates in Unverricht-Lundborg disease (ULD). Four different patients with genetically-proven ULD. Left, middle-left, and middle-right samples show short bursts of 3-4-Hz generalized spike-waves with a rolandic predominance against a normal background. These patients were initially diagnosed with idiopathic generalized epilepsy. Right sample shows left rolandic spike-wave activity that correlates with myoclonic jerks of the right arm (Courtesy of Michelle Bureau, MD Centre Saint-Paul/Hôpital Henri Gastaut, Marseilles, France).

Figure 6.03. Sleep EEG/EMG recording of a 21-year-old patient with ULD, four years after onset. During REM sleep, long bursts of fast, semi-rhythmic, moderate-amplitude 4-5-Hz spike-waves are recorded over the vertex and rolandic areas, with unrelated myoclonus of the chin (Mylo) (Courtesy of Michelle Bureau, MD Centre Saint-Paul/Hôpital Henri Gastaut, Marseilles, France).

Figure 6.04. Post-myoclonic inhibition. These polygraphic examples show positive myoclonic jerks, time-locked to polyspike-wave discharges and followed by a 150-ms EMG silent period, consistent with post-myoclonic inhibition.

Figure 6.05. Axillar skin biopsy in Lafora disease. Electron microscopy of axillar skin biopsy showing characteristic Lafora inclusion bodies (white arrow) in the cells of sweat gland ducts.

Figure 6.06. EEG/EMG correlates in Lafora disease. This EEG of a 14-year-old girl with cognitive decline and myoclonic jerks related to Lafora disease (EPM2A) was recorded less than a year after the presumed onset of the disease, which was initially diagnosed as juvenile myoclonic epilepsy. The patient was asked to raise and keep her arms outstretched. Fast generalized spike-wave discharges of varying amplitude and frequency occur against a slow, disorganized background. The EMG shows negative myoclonus of seemingly cortical origin. Volleys of high-amplitude spike-wave discharges correlate with brief interruptions of muscular contraction without immediate antecedent positive myoclonus (asterisks).

Figure 6.07. Progression of EEG changes in a patient with Lafora disease. (A) At the time of disease onset (age 17 years), the EEG demonstrated normal to slightly slowed background activity. (B) Two years later (age 19 years), the EEG demonstrated asymmetric generalized spikes and polyspikes, maximum over the anterior regions on a slowed background. (C) At age 20 years, the occurrence of fast (4-6 cycles per second) spike-waves was concomitant with head drops. During the final stages of the disease, EEG recordings showed long bursts of diffuse spike-waves and fast polyspikes associated with major volleys or massive myoclonic jerks (D), dramatically enhanced by photic stimulation at low frequency (E) (from Turnbull et al., 2016).

Figure 6.08. A 13-year, four-month-old girl, presenting with Lafora disease. Left: discharges of spikes in the posterior regions of both hemispheres during wakefulness. Centre: eyes closed with a discharge of diffuse spike waves. Right: a posterior polyspike-wave discharge induced by photic stimulation (from Genton and Bureau, 2006).