

Super-refractory status epilepticus related to COVID-19 in a paediatric patient with *PRRT2* mutation

Diane Vergara^{1,2}, Carla Rubilar^{1,2}, Scarlet Witting^{1,2}, Mónica Troncoso^{1,2}, Roberto Caraballo³

¹ Pediatric Neuropsychiatry Service, Hospital Clínico San Borja Arriarán, Santiago, Chile

² Pediatric Department, Central Campus, Facultad de Medicina, Universidad de Chile, Santiago, Chile

³ Department of Neurology, Hospital de Pediatría Prof Dr. Juan P Garrahan. Buenos Aires, Argentina

Received February 23, 2021;
Accepted May 22, 2021

Neurological manifestations affect more than 35% of patients with COVID-19 [1], but are rare in children [2], and its association with status epilepticus (SE) is being increasingly documented [3, 4]. We report a case of super-refractory status epilepticus (SRSE) as the initial presentation of COVID-19 in a paediatric patient with an unusually severe phenotype associated with *PRRT2* mutation.

The patient was a 14-year-old girl, without a family history of neurological conditions or consanguinity. She had a previous history of moderate intellectual disability (ID), right hemiparesis, four-limb spasticity, ataxia, dystonia and focal epilepsy. Her first seizure occurred at 12 months of age. She achieved seizure control with lamotrigine and clonazepam, but EEG persisted with occasional focal and generalized epileptic activity. Metabolic neurodegenerative disorders were excluded and repeat brain MRIs were normal. At age 14, a *PRRT2* pathogenic heterozygous mutation, c.649dupC, was identified. Carbamazepine was then added as treatment for dystonia. A month later, she was brought to the emergency department after one hour of new-onset recurrent focal clonic seizures with impaired awareness, without recovery between seizures. There was no history of contact with COVID-19 patients. She had no respiratory symptoms, but four days before, she presented with fever up to 39.5°C. At admission, general physical examination

was normal. Neurological examination revealed faciobrachial clonic seizures, without meningismus. Seizures stopped after IV diazepam administration. Brain CT, chest X-ray, white blood cell count and C-reactive protein were normal. Seizures recurred 90 minutes later. She received a second dose of IV diazepam, phenytoin, IV midazolam bolus and levetiracetam (*figure 1*). Seizures stopped, but she continued to be lethargic and later presented with intermittent brief myoclonic and clonic focal seizures. Non-convulsive status epilepticus was suspected. Scalp EEG showed very frequent generalized spike-slow-wave activity. Valproate was initiated, while carbamazepine was withdrawn because of its potential effect on myoclonic seizure exacerbation.

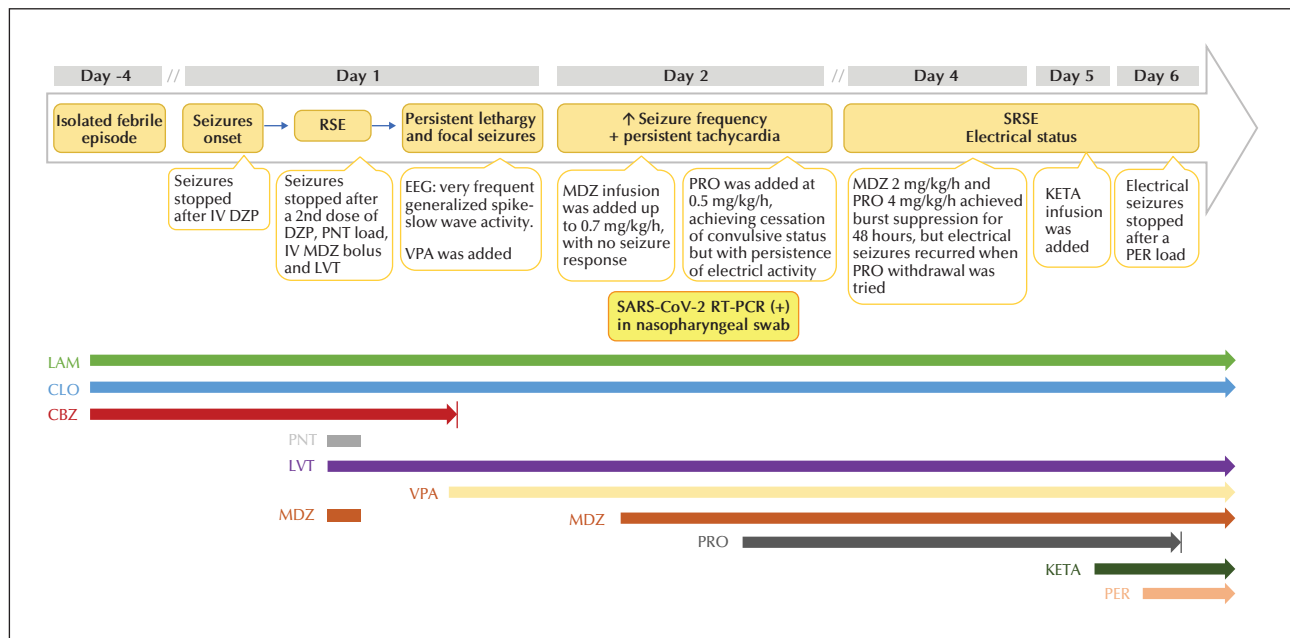
On Day 2, SARS-CoV-2 reverse transcriptase polymerase chain reaction (RT-PCR) based on a nasopharyngeal sample obtained on admission was reported positive. That same day, very frequent myoclonic and clonic focal seizures recurred. Ictal EEG showed continuous generalized and frequent focal seizures emanating from the right temporal region. Midazolam continuous infusion was initiated, without response. Propofol was added, achieving cessation of convulsive status but with persistence of electrical activity.

Routine CSF analysis was normal, and culture and FilmArray[®] Meningitis/Encephalitis panel were negative. Treatment with midazolam and propofol

• **Correspondence:**

Diane Vergara
Pediatric Neuropsychiatry Service,
Hospital Clínico San Borja Arriarán,
Pediatric Department, Central Campus,
Facultad de Medicina, Universidad de Chile,
Avenida Santa Rosa 1234, Santiago, Región Metropolitana, 8360160, Chile
<dianevergara@gmail.com>,
<dianevergara@uchile.cl>

doi:10.1684/epd.2021.1346



■ **Figure 1.** Temporal evolution of SRSE in relation to treatments.

DZP: diazepam; LVT: levetiracetam; MDZ: midazolam; KETA: Ketamine; PER: perampanel; PNT: phenytoin; PRO: propofol; RSE: refractory status epilepticus; SRSE: super-RSE; VPA: valproate.

achieved burst suppression for 48 hours, but electrographic seizures recurred when propofol withdrawal was attempted. Brain MRI showed increased T2 signal in bilateral hippocampi, attributed to SE. Ketamine infusion was started along with a perampanel load, achieving electrical seizure cessation on Day 5 after admission. However, extubation repeatedly failed due to critical illness myopathy. She died on Day 135 due to multiple healthcare-associated infections.

Our patient developed SRSE as the initial presentation of SARS-CoV-2 infection, without pulmonary or systemic COVID-19 manifestations. She had a well-controlled genetic epilepsy associated with a *PRRT2* pathogenic mutation as a predisposing condition without previous history of SE. To the best of our knowledge, this is the first reported paediatric case of SRSE as the initial presentation of COVID-19.

SRSE could be due to autoimmune encephalitis, however, the patient did not fulfil the diagnostic criteria. Although her clinical course and bilateral hippocampal signal abnormalities on MRI were suggestive of FIERES (febrile infection-related epilepsy syndrome), this does not apply in her case, as she had a genetic epilepsy as a predisposing condition [5].

PRRT2 epilepsy typically consists of infantile-onset self-limiting seizures [6]. Severe epilepsy, SE and epileptic encephalopathy have been reported only in a few

cases, and always early during the disease course [7]. To our knowledge, this is the first case of SRSE in a patient with a *PRRT2* mutation not related to infantile-onset seizures. Its classic description is an autosomal dominant condition with paroxysmal manifestations, such as paroxysmal kinesigenic dyskinesia, hemiplegic migraine, paroxysmal torticollis, and episodic ataxia [6]. Our patient presented with several atypical non-paroxysmal manifestations, infrequently reported in patients with *PRRT2* mutation [8, 9]. The severity of her phenotype may have been a predisposing factor for the development of COVID-19-related SRSE. In our case, we hypothesize SARS-CoV-2 neurotropism [10] as a triggering factor for encephalopathy and SRSE, emphasizing the absence of elements suggesting encephalitis. This is supported by several reports of neurological manifestations as the initial presentation of COVID-19 without evidence of neuroinflammation [2]. ■

Supplementary material.

Summary slides accompanying the manuscript are available at www.epilepticdisorders.com.

Acknowledgements and disclosures.

We thank Dr. Daniel Vicentini for his assistance in reviewing the manuscript.

None of the authors have any conflicts of interest to declare.

References

1. Jiang F, Deng L, Zhang L, Cai Y, Cheung CW, Xia Z. Review of the clinical characteristics of Coronavirus Disease 2019 (COVID-19). *J Gen Intern Med* 2020; 35(5): 1545-9.
2. Ellul MA, Benjamin L, Singh B, Lant S, Michael BD, Easton A, et al. Neurological associations of COVID-19. *Lancet Neurol* 2020; 19(9): 767-83.
3. Vollono C, Rollo E, Romozzi M, Frisullo G, servidei G, Borghetti A, et al. Focal status epilepticus as unique clinical feature of COVID-19: a case report. *Seizure* 2020; 78: 109-12.
4. Somani S, Pati S, Gaston T, Chitlangia A, Agnihotri S. *De novo* status epilepticus in patients with COVID-19. *Ann Clin Transl Neurol* 2020; 7(7): 1240-4.
5. Hirsch LJ, Gaspard N, van Baalen A, Nabbout R, Demeret S, Loddenkemper T, et al. Proposed consensus definitions for new-onset refractory status epilepticus (NORSE), febrile infection-related epilepsy syndrome (FIRES), and related conditions. *Epilepsia* 2018; 59: 739-44.
6. Ebrahimi-Fakhari D, Saffari A, Westenberger A, Klein C. The evolving spectrum of PRRT2-associated paroxysmal diseases. *Brain* 2015; 138(Pt 12): 3476-95.
7. Okumura A, Shimojima K, Kurahashi H, Numoto S, Shimada S, Ishii A, et al. PRRT2 mutations in Japanese patients with benign infantile epilepsy and paroxysmal kinesigenic dyskinesia. *Seizure* 2019; 71: 1-5.
8. Guerrero-López R, Ortega-Moreno L, Gir Idez BG, Alarçon-Morcillo C, Sanchez-Martin G, Nieto-Barrera M, et al. Atypical course in individuals from Spanish families with benign familial infantile seizures and mutations in the PRRT2 gene. *Epilepsy Res* 2014; 108(8): 1274-8.
9. Castelnovo G, Renard D, De Verdal M, Luc G, Thouvenot E, Riant F, et al. Progressive ataxia related to PRRT2 gene mutation. *J Neurol Sci* 2016; 367: 220-1.
10. Baig AM, Khaleeq A, Ali U, Syeda H. Evidence of the COVID-19 virus targeting the CNS: tissue distribution, host-virus interaction, and proposed neurotropic mechanisms. *ACS Chem Neurosci* 2020; 11(7): 995-8.

TEST YOURSELF

- (1) Which features in this case are compatible with the diagnosis of FIRES (febrile infection-related epilepsy syndrome) and why was this discarded?
- (2) Which manifestations comprise the classic phenotypic spectrum of PRRT2 mutation-related disorders?
- (3) Why was COVID-19-related encephalopathy diagnosed rather than encephalitis in this case?

Note: Reading the manuscript provides an answer to all questions. Correct answers may be accessed on the website, www.epilepticdisorders.com.
