

# Reflex seizures induced by micturition and defecation, successfully treated with clobazam and phenytoin

Tsukasa Higuchi<sup>1,2</sup>, Tetsuhiro Fukuyama<sup>1</sup>, Yuka Misawa<sup>1</sup>, Yuji Inaba<sup>1</sup>, Motoki Ichikawa<sup>1</sup>, Kenichi Koike<sup>1</sup>

<sup>1</sup> Department of Pediatrics, Shinshu University School of Medicine, Matsumoto

<sup>2</sup> Department of Pediatrics, Nagano Prefectural Suzaka Hospital, Suzaka City, Japan

Received February 23, 2010; Accepted February 28, 2011

**ABSTRACT** – We report a six-year-old girl with seizures induced by both micturition and defecation. Several days after unprovoked generalised tonic-clonic seizures, she developed reflex seizures characterised by the extension of both arms and rhythmic jerking of her upper body. No abnormal findings were noted on brain magnetic resonance imaging. Interictal electroencephalography (EEG) showed spike-and-wave activity on central electrode recording, and rhythmic fast activity was recorded by central electrodes during the ictal EEG upon micturition. The combination of clobazam and phenytoin was effective for both unprovoked and reflex seizures. Although some previous reports have described reflex seizures triggered by either micturition or defecation, this is the first case report of reflex seizures induced by both micturition and defecation in the same patient. Based on a comparison with previous cases of reflex seizures induced either by micturition or defecation, the neuronal pathway from the pelvic base musculature to the supplementary motor area may be responsible for the condition in our patient.

**Key words:** reflex seizure, micturition, defecation, supplementary motor area, pelvic base musculature, excretion-induced seizures

Reflex seizures are evoked by a specific stimulus which is often individual to each case (Ritaccio, 1994). Although visual stimuli are the most frequent triggers of reflex seizures, reading, writing, being startled, auditory stimuli, immersion in hot water, eating, and somatosensory stimulation can also induce seizures (Ritaccio, 1994). Micturition

and defecation are recognized as very rare triggers of reflex seizures. We describe a case of an epilepsy patient with reflex seizures caused by micturition and defecation, based on ictal electroencephalographic findings. The literature on reflex seizures induced by micturition and/or defecation is also reviewed.

**Correspondence:**

T. Higuchi  
Department of Pediatrics,  
Nagano Prefectural Suzaka Hospital,  
1332 Suzaka, Suzaka City, 382-0091, Japan  
<higuchit@suzakahp.jp>

## Case report

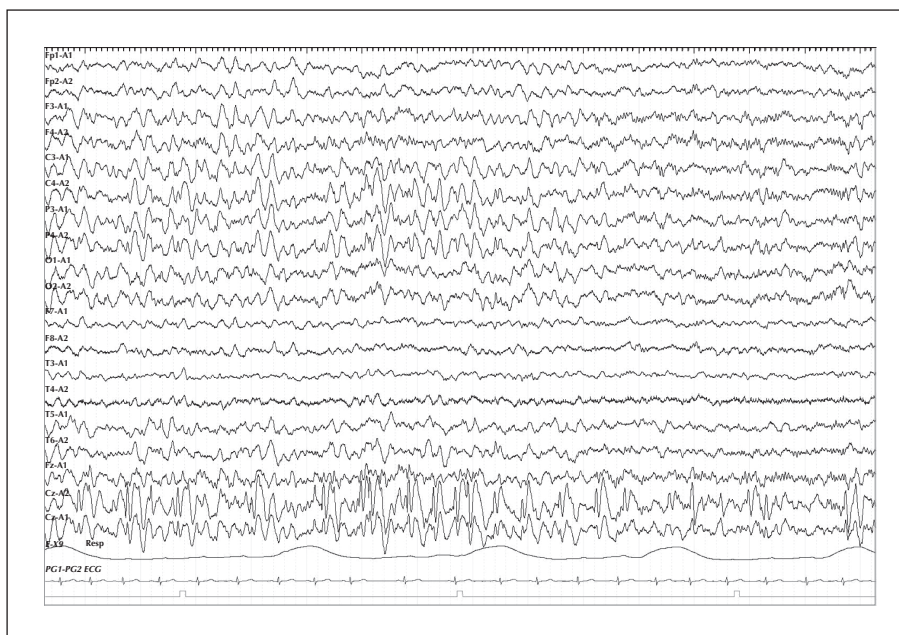
A five-year-old girl had a mild delay in language development and received speech therapy. She had no history of febrile convulsions or head injury. Her uncle had epilepsy, but detailed information could not be obtained.

At the age of six years, she was admitted to a nearby hospital because of recurrent generalised tonic-clonic seizures (GTCS) without fever. Several days later, she developed another type of seizure immediately following micturition, characterised by brief growling, eye-opening, the symmetrical extension of both arms as if to hug or hold someone, and rhythmic jerking of her upper body. These seizures lasted for 10 to 20 seconds. She remained conscious and reported experiencing fear at the time of these seizures, and thus became hesitant to urinate. Since both types of seizure occurred one to two times daily even after the administration of sodium valproate (up to 30 mg/kg/day), she was transferred to our hospital, 14 days after the onset of her seizures.

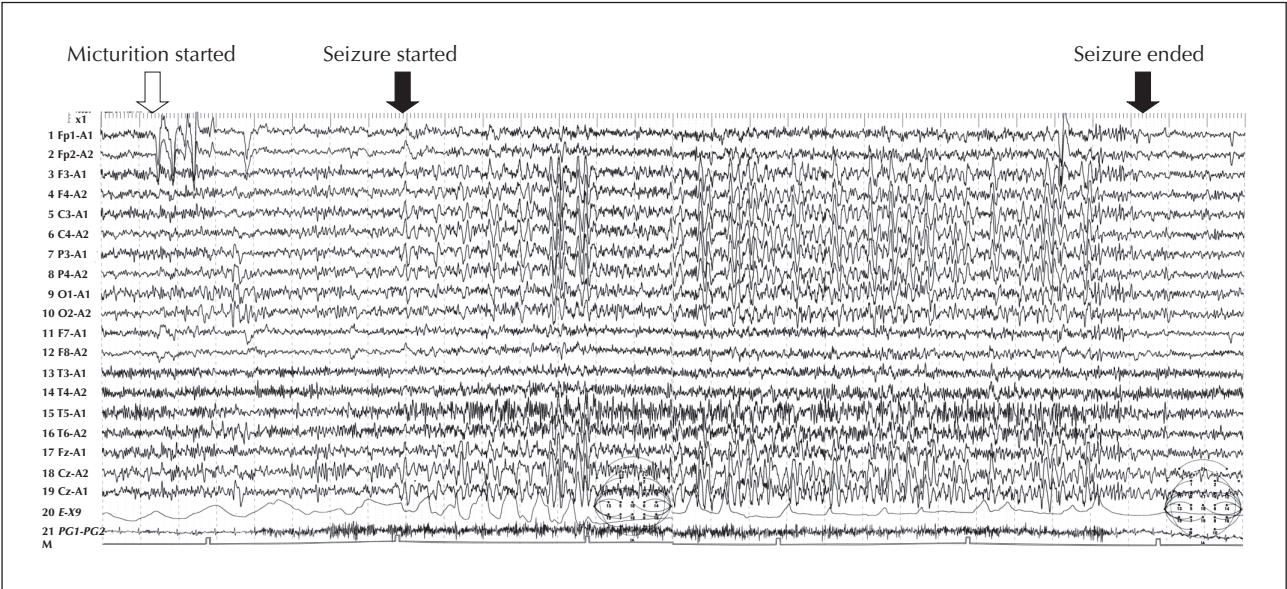
On admission, she was alert and physical, neurological, blood, and cerebrospinal fluid examinations revealed no abnormalities. The KIDS questionnaire-based developmental scale evaluated her developmental quotient (DQ) as 65. No abnormalities were detected on brain magnetic resonance imaging (MRI). Interictal  $^{99m}\text{Tc}$ -ethyl-cysteinate dimer (ECD) single photon emission computed tomography (SPECT) indicated

increased blood flow in her left angular gyrus and left temporal lobe, and decreased flow in her left hippocampus. An interictal electroencephalogram (EEG) showed continuous 20-Hz beta activity in the frontal region, intermittent high-voltage theta waves in the frontal and central regions, and some spike-and-waves in Cz (figure 1). An ictal EEG recorded on micturition revealed the initiation of rhythmic theta waves through the central electrodes (figure 2).

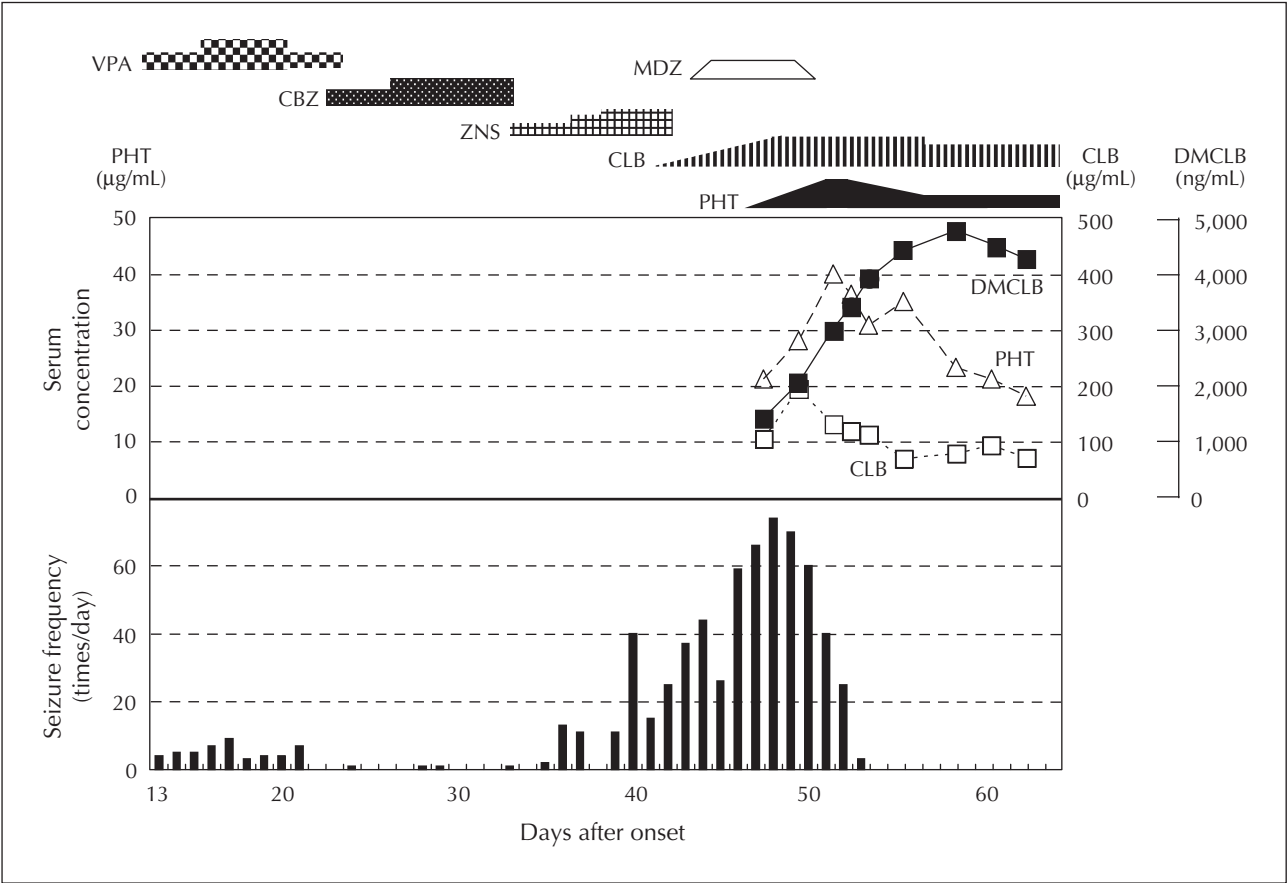
She was diagnosed with focal epilepsy with reflex seizures on the basis of her seizure manifestations and ictal EEG findings. Her clinical course is shown in figure 3. The administration of carbamazepine (CBZ) resulted in significant decreases in the frequency of both GTCS and reflex seizures, but was discontinued because of an allergic rash. Zonisamide was not beneficial and did not reduce the frequency of seizures. The patient then developed brief tonic partial seizures of her left shoulder which occurred in clusters, 39 days after the onset of her seizures. Her reflex seizures began to occur not only upon every micturition but also on defecation. Clobazam (CLB) was started on day 41 after seizure onset, at gradually increasing doses. Frequent seizures prompted us to begin continuous intravenous infusion of midazolam (MDZ) on day 43. However, the medication made her somewhat drowsy and her seizure frequency increased to more than 60 per day. Treatment with phenytoin (PHT) was attempted on the 46<sup>th</sup> day in progressively increasing doses. Despite PHT levels higher than 40  $\mu\text{g/mL}$ , the



**Figure 1.** Interictal electroencephalography recorded during sleep.



**Figure 2.** Ictal electroencephalography recorded on micturition.



**Figure 3.** Clinical and laboratory course.  
CBZ: carbamazepine; CLB: clobazam; DMCLB: desmethyclobazam; MDZ: midazolam; PHT: phenytoin; VPA: sodium valproate; ZNS: zonisamide.  
Serum concentrations of PHT, CLB, and DMCLB are shown.

seizures did not decrease in frequency and so the dose was lowered. The seizures disappeared on the 54<sup>th</sup> day after seizure onset, as the serum concentration of desmethylclobazam (DMCLB), the major metabolite of CLB which also exhibits antiepileptic properties, increased. She subsequently had no seizures for two years with the combination of 11 mg/day of CLB and 120 mg/day of PHT. The serum concentrations of CLB, DMCLB, and PHT were 110-180 (reference range: 50-300)  $\mu$ g/mL, 1,400-2,200 (reference range: 1,000-4,000) ng/mL and 9.7-12.1 (reference range: 10-20)  $\mu$ g/mL, respectively. When the PHT dose was decreased in a stepwise fashion to 50 mg/day, micturition-induced seizures occurred three times in one week. At that time, serum concentrations of CLB, DMCLB, and PHT were 132  $\mu$ g/mL, 1,442 ng/mL, and 3.1  $\mu$ g/mL, respectively. Accordingly, the PHT dose was raised to 110 mg/day, which resulted in complete control of the seizures.

## Discussion

Reflex seizures often occur together with unprovoked seizures and are rarely triggered by micturition and defecation. In the literature, we were able to find only nine reports of reflex seizures induced by micturition or defecation, but not by both, (Zivin and Rowley, 1964; Yamatani *et al.*, 1987; Pradhan and Kalita, 1993; Ikeno *et al.*, 1998; Bourgeois, 1999; Harbord and Mitchell, 2002; Glass *et al.*, 2006; Okumura *et al.*, 2007) (*table 1*). Six cases were also reported with unprovoked seizures, consistent with the high prevalence of spontaneous seizures in patients with reflex seizures (Ritaccio, 1994). While reflex seizures occur at any age, those induced by either micturition or defecation are observed only in childhood (6 to 14 years). Additionally, developmental delay is documented in four cases, including the present patient. Taken together, pre-existing brain impairment as well as brain immaturity may be important in the pathogenesis of this type of reflex seizure. In reflex seizures, readily excitable cortical regions are considered to be present at or near areas physiologically activated by specific stimuli (Ferlazzo *et al.*, 2005). Using SPECT and functional MRI, Fukuyama *et al.* and Bittorf *et al.* showed, respectively, that the activity of sphincters involved in micturition/defecation is neurally transmitted to the supplementary motor area (SMA) (Fukuyama *et al.*, 1996; Bittorf *et al.*, 2006). Using positron emission computed tomography (PET), Blok *et al.* revealed that the SMA is one of the regions physiologically activated by contraction of the pelvic floor muscles (external urethral sphincter, external anal sphincter, levator ani muscle, and puborectal muscle) involved in micturition/defecation (Blok *et al.*, 1997). In our case, spike-and-wave activity was detected

only at Cz on interictal EEG records and seizure activity started at Cz. The electrical activity in the SMA is recorded at or near the Cz electrode on EEG. In six of seven cases with evident EEG foci, the seizure focus was observed at Cz, C3, or F4 (*table 1*). This supports the possibility that the SMA is a seizure focus in many cases of reflex seizures induced by micturition and/or defecation.

The reflex seizures induced by micturition or defecation in this case were characterised by tonic posturing of the upper limbs, preserved consciousness, and growling, and suggested involvement of a common neuronal pathway. These characteristics closely resembled those of reflex seizures in cases reported previously (Ikeno *et al.*, 1998; Glass *et al.*, 2006; Okumura *et al.*, 2007). Bass *et al.* clarified, using video-EEG and subdural electrodes, that such seizure attacks, characterised by sudden tonic posturing of the limbs and often accompanied by unintelligible fearful vocalization, were derived from the SMA (Bass *et al.*, 1995). These findings also provide supporting evidence that seizure activity induced by micturition/defecation originates in the SMA in some cases.

Reflex seizures generally respond to conventional antiepileptic drugs (Ferlazzo *et al.*, 2005). However, there is no standard antiepileptic drug regime effective against all reflex seizures, as illustrated in nine reported cases of patients who achieved remission with different drugs (*table 1*). In our case, her seizures responded well to CBZ at the beginning of the clinical course. After the discontinuation of CBZ, because of a skin rash, her seizures became uncontrolled. Finally, an increase in the serum concentration of DMCLB (>3,000 ng/mL), in combination with PHT, resulted in seizure disappearance. Interestingly, her seizures responded to CLB, but not to MDZ, despite both drugs being benzodiazepines which enhance the inhibitory action of  $\gamma$ -aminobutyric acid receptors in the nervous system. The reason for the difference in action between the two benzodiazepines may be attributed to the drowsiness that accompanied the continuous infusion of MDZ, but not CLB administration. It is well known that drowsiness or oversedation can activate seizures (Gayatri and Livingston, 2006), which may have been the case here. Another possibility is the structural difference between the two drugs; MDZ has a 1, 4-benzodiazepine structure, whereas CLB has a 1, 5-benzodiazepine structure. Meldrum *et al.* reported that different benzodiazepines bind to each of the three benzodiazepine-receptor subtypes with varying affinities, which contributes to the different action and efficacy of each drug (Meldrum and Chapman, 1986). Accordingly, the discrepancy observed between the clinical effects of the two benzodiazepines may have been due, in part, to their different chemical structures.

**Table 1.** Reported cases of micturition- and/or defecation-induced seizures.

| Case No. | Age | Sex | Developmental delay | Stimuli                    | Other stimuli          | Spontaneous seizure | EEG focus | Treatment                       | Outcome    | Author                 | Year |
|----------|-----|-----|---------------------|----------------------------|------------------------|---------------------|-----------|---------------------------------|------------|------------------------|------|
| 1        | 14  | M   | -                   | Micturition                | -                      | -                   | NE        | PRM                             | Remission  | Zivin and Rowley       | 1964 |
| 2        | 8   | F   | -                   | Micturition                | -                      | -                   | C3        | CBZ→CBZ + CZP→CBZ+VPA           | Remission  | Yamatani <i>et al.</i> | 1987 |
| 3        | 10  | M   | -                   | Micturition                | -                      | +                   | F4        | CBZ→VPA                         | Remission  | Pradhan and Kalita     | 1993 |
| 4        | 9   | F   | -                   | Micturition                | -                      | +                   | Cz        | CBZ                             | Remission  | Ikeno <i>et al.</i>    | 1998 |
| 5        | 8   | M   | +                   | Micturition                | Immersion in hot water | +                   | Cz        | CBZ→CBZ+VPA                     | Remission  | Bourgeois              | 1999 |
| 6        | 9   | M   | +                   | Defecation                 | -                      | -                   | F7        | CBZ→LTG                         | Remission  | Harbord and Mitchell   | 2002 |
| 7        | 12  | F   | +                   | Micturition                | Emotion                | +                   | Cz        | PB, VPA, CZP, TPM, LTG, CLB, KD | Refractory | Glass <i>et al.</i>    | 2006 |
| 8        | 8   | F   | -                   | Micturition                | -                      | +                   | NE        | CBZ, CZP→PHT                    | Remission  | Okumura <i>et al.</i>  | 2007 |
| 9        | 6   | F   | +                   | Micturition and defecation | -                      | +                   | Cz        | VPA, CBZ, ZNS, MDZ→PHT+CLB      | Remission  | The present case       | 2009 |

CBZ: carbamazepine; CLB: clobazam; CZP: clobazepam; KD: ketogenic diet; LTG: lamotrigine; MDZ: midazolam; NE: not evident; PB: phenobarbital; PHT: phenytoin; PRM: primidone; TPM: topiramate; VPA: valproate; ZNS: zonisamide.

In conclusion, reflex seizures triggered by micturition or defecation appear to be rare and only reported in children. This is the first case report where seizures triggered by both occurred in the same patient. These seizures often respond to antiepileptic medication, although no standard effective regimes have been established. □

#### Disclosure.

None of the authors has any conflict of interest or financial support to disclose.

#### References

- Bass N, Wyllie E, Comair Y, Kotagal P, Ruggieri P, Holthausen H. Supplementary sensorimotor area seizures in children and adolescents. *J Pediatr* 1995; 126: 537-44.
- Bittorf B, Ringler R, Forster C, Hohenberger W, Matzel KE. Cerebral representation of the anorectum using functional magnetic resonance imaging. *Br J Surg* 2006; 93: 1251-7.
- Blok BF, Sturms LM, Holstege G. A PET study on cortical and subcortical control of pelvic floor musculature in women. *J Comp Neurol* 1997; 389: 535-44.
- Bourgeois BF. A retarded boy with seizures precipitated by stepping into the bath water. *Semin Pediatr Neurol* 1999; 6: 151-6.
- Ferlazzo E, Zifkin BG, Andermann E, Andermann F. Cortical triggers in generalized reflex seizures and epilepsies. *Brain* 2005; 128: 700-10.
- Fukuyama H, Matsuzaki S, Ouchi Y, et al. Neural control of micturition in man examined with single photon emission computed tomography using 99mTc-HMPAO. *Neuroreport* 1996; 7: 3009-12.
- Gayatri NA, Livingston JH. Aggravation of epilepsy by anti-epileptic drugs. *Dev Med Child Neurol* 2006; 48: 394-8.
- Glass HC, Prieur B, Molnar C, Hamiwka L, Wirrell E. Micturition and emotion-induced reflex epilepsy: case report and review of the literature. *Epilepsia* 2006; 47: 2180-2.
- Harbord MG, Mitchell C. Reflex seizures induced by defecation, with an ictal EEG focus in the left frontotemporal region. *Epilepsia* 2002; 43: 946-7.
- Ikeno T, Morikawa A, Kimura I. A case of epileptic seizure evoked by micturition (in Japanese). *Rinsho Nouha* 1998; 40: 205-8.
- Meldrum B, Chapman A. Benzodiazepine receptors and their relationship to the treatment of epilepsy. *Epilepsia* 1986; 27: S3-S13.
- Okumura A, Kondo Y, Tsuji T, et al. Micturition induced seizures: ictal EEG and subtraction ictal SPECT findings. *Epilepsy Res* 2007; 73: 119-21.
- Pradhan S, Kalita J. Micturition induced reflex epilepsy. *Neurol India* 1993; 41: 221-3.
- Ritaccio AL. Reflex seizures. *Neurol Clin* 1994; 12: 57-83.
- Yamatani M, Murakami M, Konda M, et al. An 8-year-old girl with micturition-induced epilepsy. *No To Hattatsu (in Japanese)* 1987; 19: 58-62.
- Zivin I, Rowley W. Psychomotor Epilepsy With Micturition. *Arch Intern Med* 1964; 113: 8-13.