

# Paroxysmal eyelid movements in patients with visual-sensitive reflex seizures

Mario Brinciotti, Maria Matricardi

Department of Pediatrics and Child Neuropsychiatry, Interdepartmental Research Centre for Social Diseases (CIMS), Childhood Epilepsy Section, Faculty of Medicine and Dentistry, Sapienza University of Rome, Rome, Italy

Received March 01, 2015; Accepted July 03, 2015

**ABSTRACT** – *Aim.* Paroxysmal eyelid movements (PEM) are non-epileptic episodes characterized by eyelid closure, upturning of the eyes, and rapid eyelid flutter. The aim of this study was to report clinical and EEG data of patients with PEM and its relationship with visual sensitivity.

*Methods.* We studied 26 patients with epilepsy (12 males and 14 females; mean age:  $14.0 \pm 6.9$  years) who presented PEM. The epilepsy was idiopathic generalized (eight cases), idiopathic focal (six cases), symptomatic focal (five cases), and reflex epilepsy (seven cases). PEM and blinking were analysed by video-EEG recordings at rest and during intermittent photic stimulation, pattern stimulation, and TV watching. Blink rate was evaluated during three different conditions: at rest, during a TV-viewing period, and at the occurrence of PEM. Analysis of variance (ANOVA) was used for statistical comparisons.

*Results.* Repeated episodes of PEM were recorded in all patients. The frequency of PEM ranged from 8 to 12.5 Hz (average:  $9.6 \pm 1.5$ ). PEM were accompanied by a significant increase in blinking compared to the rest condition and TV watching (blink rate:  $56.5 \pm 21.1$  vs  $25.0 \pm 16.2$  vs  $11.3 \pm 11.8$ , respectively;  $p < 0.0001$ ). Photoparoxysmal EEG responses (measured as sensitivity to photic stimulation) were found in 25 cases, associated with pattern sensitivity in 22; only one patient was sensitive to pattern but not photic stimulation. Visually-induced seizures were recorded in 20 cases, triggered by both stimuli (photic and pattern stimulation) in 11 patients; seizures were triggered by pattern stimulation (but not photic stimulation) in five, photic stimulation (but not pattern stimulation) in three, and TV watching (but not photic or pattern stimulation) in one. Epileptic eyelid myoclonia was noted in 17 patients.

*Conclusion.* The coexistence of PEM, photoparoxysmal EEG responses, increased blinking, and epileptic eyelid myoclonia suggests an underlying dysfunction involving cortical-subcortical neural networks, according to the recent concept of system epilepsies. [Published with video sequences]

**Key words:** paroxysmal eyelid movements, visual sensitivity, eyelid myoclonia, blinking, non-epileptic paroxysmal disorders

Abnormal ictal movements of eyes and eyelids are common clinical features of different types of seizures, and proper assessment of their semeiotics often plays a relevant

diagnostic role. Moreover, some oculomotor abnormalities such as paroxysmal tonic upward gaze, oculomotor apraxia, blepharospasm, and ocular tics can mimic epileptic



**Correspondence:**

Mario Brinciotti  
Department of Pediatrics and Child Neuropsychiatry,  
Sapienza University of Rome,  
Via dei Sabelli 108,  
00185 Rome, Italy  
<mario.brinciotti@uniroma1.it>

seizures, especially in children (Boghen, 1997; Hallett, 2002; Khalifa and von Knorring, 2005; Ouvrier and Billson, 2005; Obeid and Mikati, 2007). In 2004, Camfield *et al.* reported non-epileptic paroxysmal eyelid movements (PEM) in a sample of patients with idiopathic generalized epilepsies and photoparoxysmal EEG responses (PPR). The episodes were characterized by eyelid closure, upturning of the eyes, and rapid eyelid flutter. Attacks were usually stereotyped and very frequent, with several hundred occurring per day, especially when the patient was upset, stressed, or embarrassed. No EEG abnormalities were recorded during PEM, and episodes were not triggered by hyperventilation or photic stimulation. The authors suggested that PEM were non-epileptic manifestations genetically linked to idiopathic photosensitive generalized epilepsies.

In the present study, we report a group of patients with PPR and different types of epilepsy in which the presence of PEM was associated with short periods of increased frequency of blinking. The aim of the study was:

- to describe clinical and EEG data of these patients;
- to analyse the semiotics of PEM and its relationship to PPR.

## Materials and methods

### Patient selection

Patients were recruited from the outpatients examined from January 2008 to March 2011 at the epilepsy centre at the Department of Pediatrics and Child Neuropsychiatry, Sapienza University of Rome. Older patients were included if their seizures began in childhood and they had ongoing follow-up at our epilepsy centre. Selection was based on the following criteria:

- clinical history of reflex seizures induced by visual stimuli;
- occurrence of PEM;
- confirmed diagnosis by video-EEG monitoring.

Poorly cooperative patients due to age or clinical conditions (intellectual disability or behaviour disorders) were excluded. Other exclusion criteria were the presence of other eyelid abnormalities (such as apraxia of eyelid opening, tics, or blepharospasm).

### Diagnostic criteria and clinical assessment

Seizures and epilepsies were diagnosed and classified according to the criteria of the Commission on Classification and Terminology of the International League Against Epilepsy (1989) (Berg *et al.*, 2010).

PEM were diagnosed according to semeiotics and video material reported by Camfield *et al.* (2004).

Demographic features, medical and family history, disease course, and treatment were collected from parents during a face-to-face interview. All patients were clinically evaluated by standard general and neurological examinations. CT and/or MRI were performed according to the clinical needs.

### Studied sample

From a total of 239 consecutive patients with documented visually-induced seizures, 26 patients (12 males and 14 females) aged 4.0-35.2 years (mean age:  $14.0 \pm 6.9$  years) fulfilled our selection criteria and were enrolled in this study (*table 1*). The type of epilepsy was idiopathic generalized (IGE) in eight cases (four juvenile myoclonic epilepsy [JME], three childhood absence epilepsy [CAE], and one juvenile absence epilepsy [JAE]), idiopathic focal in six (four occipital and two temporal), and symptomatic focal in five; seven patients had only reflex seizures triggered by visual stimuli without spontaneous seizures and were diagnosed with reflex epilepsies according to ILAE classification (Berg *et al.*, 2010). Symptomatic cases had cerebral vascular malformation (one), cerebral ulegiria (one), right frontal arachnoid cyst (one), and Sotos syndrome with *NSD1* mutation (two patients; a brother and sister).

### Recording methods

To assess the occurrence of PEM, we recorded a digital video-EEG (using 21 electrodes) at rest and during a standard procedure of visual stimulation with intermittent photic stimulation (IPS), pattern stimulation (PS) and at least 30 minutes of TV watching. IPS was tested, according to internationally recommended guidelines (Kasteleijn-Nolst Trenité *et al.*, 2012), in a darkened room by flashing non-patterned white light at 30 cm from the patient's eyes (frequency range: 1-60 Hz). Each frequency was tested by separate trains of flashes, during the eye closure condition (closure of the eyes on command at the start of a flash train) and eyes open, with a five-second inter-stimulus-free period. Pattern sensitivity was tested by a standard procedure of PS, partially modified from that previously described elsewhere (Brinciotti *et al.*, 1994), according to recommended guidelines (Wilkins *et al.*, 2005). Briefly, we used three types of black-and-white full-field pattern (checks, horizontal stripes, and vertical stripes), two black-and-white hemi-field patterns (left and right, horizontal stripes), and one red/blue full-field pattern (horizontal stripes). All stimuli were presented in reversal mode (at 1.6 Hz) with high contrast (Michelson  $>0.8$ ) and different sizes of the constituent elements subtending a spatial frequency (pairs of light-dark elements) from

**Table 1.** Main clinical features of patients with Paroxysmal Eyelid Movements.

Case	Sex	Age (years)	Family history of epilepsy	Aetiology	Epilepsy		Reflex seizures		Stimuli
					Onset (years)	Type	Onset (years)	Type	
1	M	4.0	Mother	I	4.0	Reflex	4.0	Focal motor Eyelid myoclonia	Light
2	F	17.9	Mother Sister	I	3.7	JME	7.0	Focal tonic Absence Eyelid myoclonia	TV
3	F	17.0	Sister	I	17.0	Reflex	17.0	Focal sensory	TV
4	F	8.9	No	I	5.8	CAE	8.1	Focal sensory with elementary symptoms Focal myoclonic Eyelid myoclonia	Light, TV
5	F	7.9	Brother	I	6.0	Reflex	6.0	Focal sensory with experiential symptoms Eyelid myoclonia	TV, videogames, light
6	M	11.4	Sister	S	1.7	Focal	11.2	Focal sensory with experiential symptoms Eyelid myoclonia	TV, videogames, light
7	F	18.5	Father	I	5.1	JME	6.0	Absence Eyelid myoclonia	Light, TV
8	M	6.7	No	I	6.3	Reflex	6.3	Focal secondarily generalized	TV
9	F	35.2	No	S	8.4	Focal	13.8	Focal sensory with experiential symptoms Eyelid myoclonia	Pattern
10	M	8.1	No	S	1.5	Focal	7.3	Focal tonic	Light
11	F	22.8	Mother	S	6.9	Focal	6.9	Focal sensory with experiential symptoms Eyelid myoclonia	Light, TV
12	F	10.5	No	I	10.5	Reflex	10.5	Focal motor	TV, pattern
13	F	14.0	Mother	I	12.6	Focal	12.6	Focal sensory with elementary symptoms Eyelid myoclonia	Light, sun, TV
14	M	13.4	No	I	7.1	CAE	8.6	Focal sensory with elementary symptoms Eyelid myoclonia	Light, sun, TV, pattern
15	F	11.7	No	I	11.4	Reflex	11.4	Focal sensory with elementary symptoms Eyelid myoclonia	Light, disco light, sun, TV, pattern
16	M	9.6	Sister	I	8.0	Focal	8.8	Focal clonic Focal sensory with experiential symptoms Eyelid myoclonia	TV

Table 1. (Continued)

Case	Sex	Age (years)	Family history of epilepsy	Aetiology	Epilepsy		Reflex seizures		Stimuli
					Onset (years)	Type	Onset (years)	Type	
17	M	11.0	No	S	10.2	Focal	10.6	Focal sensory with elementary symptoms Focal sensory with experiential symptoms	TV
18	M	15.3	No	I	12.6	JAE	12.6	Absence	TV
19	M	10.4	Brother	I	6.9	CAE	11.8	Focal sensory with elementary symptoms Eyelid myoclonia	TV
20	F	26.9	No	I	12.6	JME	13.0	Eyelid myoclonia Generalized t-c	TV, disco light
21	F	16.9	No	I	11.6	JME	12.0	Eyelid myoclonia	Light, TV
22	F	8.4	No	I	8.0	Focal	8,6	Focal sensory with experiential symptoms	Light
23	F	14.1	No	I	9.4	Reflex	9.4	Eyelid myoclonia Focal clonic Focal secondarily generalized	Light, TV
24	M	14.6	No	I	14.2	Focal	14.6	Focal clonic	Light, TV
25	M	9.6	No	I	8.6	Focal	9.6	Eyelid myoclonia	Light, TV
26	M	4.0	Cousin	I	5.1	Focal	5.3	Focal sensory with elementary symptoms	TV

CAE: childhood absence epilepsy; JME: juvenile myoclonic epilepsy; JAE: juvenile absence epilepsy; I: idiopathic; S: symptomatic.

1.3 to 5.7 cycles per degree. The duration of each stimulus was 15 seconds, with a rest interval of at least ten seconds. If any paroxysmal activity appeared, the stimulus was promptly stopped to avoid seizure induction, then it was presented again to verify the reproducibility of the EEG activation. To ascertain the occurrence of stimulus-related ictal symptoms (hallucinations, micro/macropsias, etc.), at the end of video-EEG recording, all patients underwent a semi-structured interview concerning subjective sensations they experienced during stimulation. We also asked cooperative patients to describe visual symptoms by drawing. Polygraphic channels (horizontal and vertical electro-oculogram) were used in selected cases, when the nature of the paroxysmal eyelid episodes was not clearly definable.

The video-EEG recordings were manually processed off-line to analyse the frequency of blinks. A blink was defined as a transient, bilateral, and synchronous

short-duration (<1 second) of eyelid drop without lowering of the eyebrows (Tulen *et al.*, 1999). We calculated blink rate (BR), expressed as blinks per minute, in three different conditions:

- at rest with eyes open (150 seconds);
- during a ten-minute TV-viewing period;
- at the occurrence of PEM within a time window of ten seconds (PEM-related eyelid movement was not considered as blinking).

Statistical analysis was performed using StatSoft Inc. (Tulsa, OK, USA 2010) STATISTICA (data analysis software system), version 9.1 for Windows. Analysis of variance (ANOVA) was used to analyse changes of BR. All values are expressed as mean±SD, and a *p* value of 0.05 was considered to indicate statistical significance. All enrolled patients or their parents provided written informed consent prior to participation, and the study was approved by the institutional review board at Sapienza University of Rome.

## Results

Repeated PEM episodes of short duration (1-4 seconds) were recorded during video-EEG in all patients, and were characterized by slow closing of the eyes followed by opening with deviation of the eyes upward and fast eyelid flutter. Even though we did not undertake any detailed tests for vigilance, consciousness was fully preserved during the events in all patients; they continued to speak and understood questions and commands with proper response to stimuli.

The frequency of PEM ranged from 8 to 12.5 Hz (average:  $9.6 \pm 1.5$  Hz) and the attacks were usually preceded or accompanied by short bursts of rapid blinks (table 2). No epileptic EEG abnormalities were recorded during PEM (figure 1A). The procedure of visual stimulation with video-EEG monitoring showed PPR (figure 1B) in 25 cases (measured as sensitivity to IPS), associated with pattern sensitivity in 22 (figure 2); only one patient was sensitive to PS but not IPS (table 2). Visually-induced seizures were recorded in 20 patients, triggered by both stimuli (IPS and PS) in 11 cases; seizures were triggered by PS (but not IPS) in five, IPS (but not PS) in three, and TV watching (but not PS or IPS) in one. Ictal EEG features were characterized by spikes, sharp waves and spike-wave complexes in the occipital areas with spreading to other regions in 16 patients, and generalised PPR in four cases (figure 3A-B). Epileptic eyelid myoclonia (figure 3B) were recorded in 17 patients (ten during reflex seizures, six during both reflex and spontaneous seizures, and one only during spontaneous seizures). Self-induced seizures were noted in eight cases; these patients induced their seizures by viewing TV at close proximity (seven cases) and/or by blinking in front of light sources (four cases). On the video-EEG, the episodes of PEM were never related to self-induced seizures.

Fifteen patients reported one or more symptoms and/or subjective sensations during PPR: visual symptoms (12 cases; simple visual hallucinations [nine cases], micropsia [two cases], and amaurosis [one case]), intraorbital pain (four cases), fear (two cases), confusion (two cases), and dizziness (one case). Subjective sensations were not reported during episodes of PEM.

The blinking showed a significant increase of BR mean values in relation to the occurrence of PEM compared to both rest and TV-watching conditions ( $56.5 \pm 21.1$  vs  $25.0 \pm 16.2$  vs  $11.3 \pm 11.8$ , respectively;  $p < 0.0001$ ) (figure 4).

At the end of follow-up (mean:  $8.2 \pm 7$  years), 13 patients were seizure-free for at least two years. AEDs were usually ineffective against PEM, and PEM did not disappear in the patients who became seizure-free.

## Discussion

Diagnosis of epilepsy is based on an appropriate assessment of ictal signs and symptoms, as recently stressed by the ILAE Commission on Classification and Terminology (Berg *et al.*, 2010). Since movements of eyes and eyelids are common clinical features in different types of epileptic and non-epileptic episodes, their correct semeiotics is essential for diagnosis. The addition of video recording to standard EEG is a particularly useful technique to establish the nature of paroxysmal eye movements (Waternberg *et al.*, 2005).

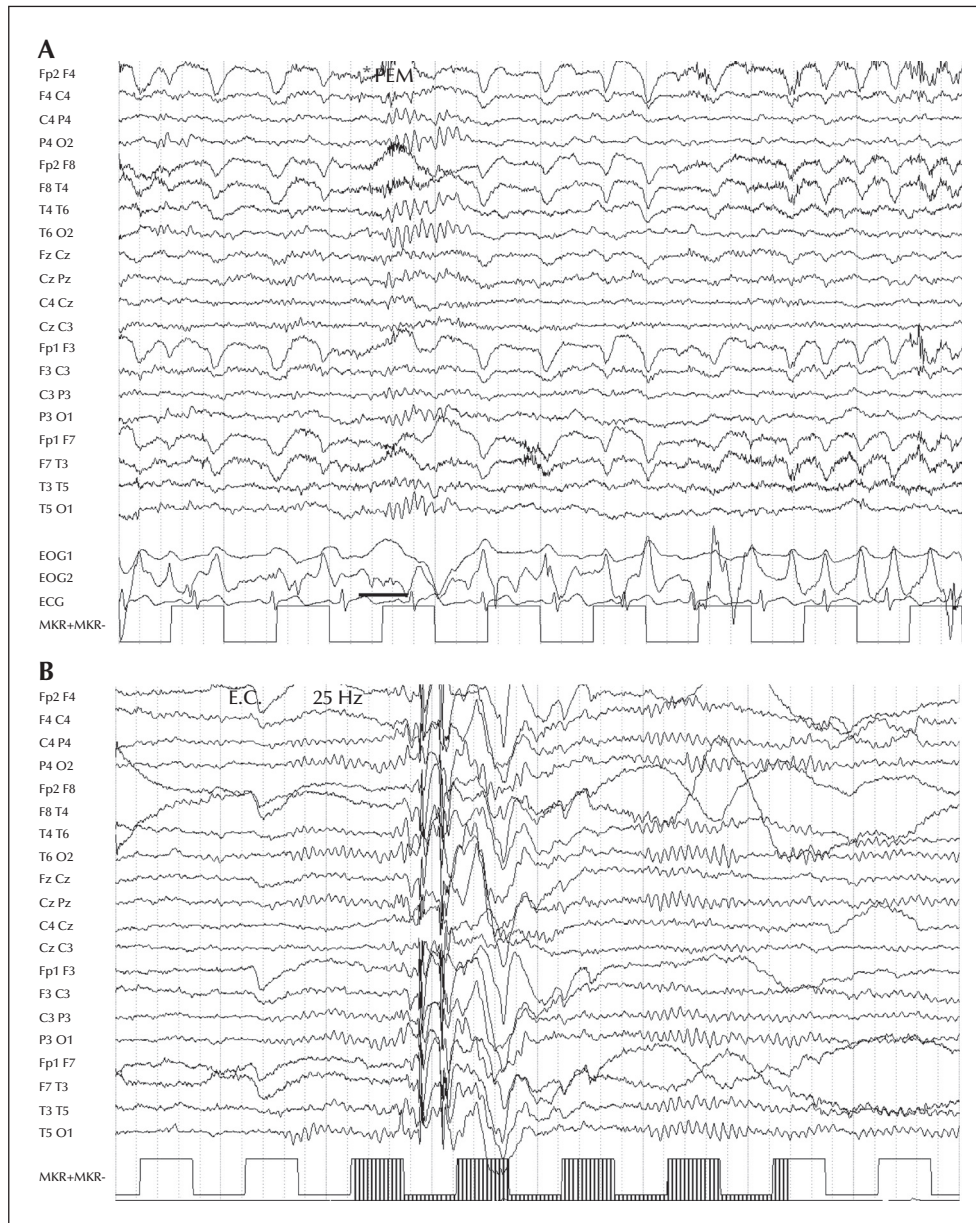
In 2004, Camfield *et al.* reported the occurrence of PEM in 19 patients suffering from IGE (three with CAE, eight with JME, and eight with absence plus generalized tonic-clonic seizures) with photosensitivity. In our sample, the clinical features and lack of epileptic EEG abnormalities during the episodes suggest that these are the same type of attack. The main initial sign of PEM was eye closure with rapid eyelid flutter, no unconsciousness, and no epileptic EEG abnormalities. These findings support a non-epileptic nature of these events, as suggested by Camfield *et al.* (2004). Ictal eye opening or closure has been reported as a highly reliable clinical sign to distinguish between epileptic seizures and psychogenic non-epileptic attacks (DeToledo and Ramsay, 1996; Flügel *et al.*, 1996; Chung *et al.*, 2006; Syed *et al.*, 2008). Chung *et al.* (2006) reviewed long-term video-scalp EEG monitoring of 234 consecutive patients and found that ictal eye closure indicated a high likelihood of psychogenic non-epileptic seizures, while eye opening had a high positive predictive value for true epileptic seizures. Eyelid movements have been noted in 28% of absence seizures (Sadleir *et al.*, 2006) and opening of the eyes has been reported as a characteristic clinical manifestation of typical absence seizures, usually occurring within two seconds from the onset of the EEG paroxysms (Panayiotopoulos *et al.*, 1989).

In our patients, PEM were usually preceded or accompanied by short bursts of rapid blinks. Usually, spontaneous blinking has an interindividual variable rate, ranging between 10 and 20 blinks per minute, and is highly influenced by multiple factors, especially of an emotional and attentive nature (Zametkin *et al.*, 1979; Karson *et al.*, 1981; Sun *et al.*, 1997; Esteban *et al.*, 2004; Pult *et al.*, 2013). Rates are low in infancy, increase in childhood, and stabilize in adulthood (Zametkin *et al.*, 1979; Sun *et al.*, 1997). Variation of blinking rate has been observed in a number of neurological diseases. Patients with either schizophrenia or Huntington's disease show higher blink rates than normal subjects (Karson, 1983; Stevens, 1978), and blink frequency is increased in blepharospasms especially during the

**Table 2.** Visual sensitivity and Paroxysmal Eyelid Movements frequency recorded during video-EEG with visual stimulations.

Case	EEG at rest	Visual sensitivity						PEM frequency (Hz)
		EEG			Reflex seizures			
		IPS	PS	TV	IPS	PS	TV	
1	Focal (right FCT + TO)	+	+	+	+	-	-	12.0
2	Generalized 3-5 Hz S-W and PS-W	-	+	+	-	+	+	10.0
3	Focal (PO) with spreading	+	+	+	+	+	+	9.0
4	Generalized 3-5 Hz S-W and PS-W	+	+	+	+	+	+	9.0
5	Focal (left FCT + bilateral O)	+	+	+	+	+	+	8.0
6	Multifocal	+	+	+	+	+	+	8.0
7	Generalized + Focal (right TO)	+	+	+	+	+	+	9.0
8	Focal (right C)	+	+	-	+	+	-	9.0
9	Focal (left FCT + TO) with spreading	+	+	+	-	+	+	8.0
10	Focal (right FCT + TO)	+	+	+	+	-	-	8.0
11	Multifocal	+	+	+	-	+	+	10.0
12	Focal (TO)	+	+	+	-	+	+	10.0
13	Focal (TO)	+	+	+	+	+	+	12.0
14	Focal (PO) with spreading	+	+	+	-	+	+	10.0
15	Focal (PTO) with spreading	+	+	-	+	+	-	10.0
16	Focal (TO)	+	+	+	+	+	+	8.0
17	Focal (right FCT + PTO) with spreading	+	+	-	+	+	-	12.5
18	Generalized 3-5 Hz S-W and PS-W	+	*	*	-	*	*	9.0
19	Generalized + Focal (O) with spreading	+	*	-	-	*	-	8.0
20	Generalized 3-5 Hz S-W and PS-W	+	+	-	-	-	-	8.0
21	Generalized 3-5 Hz S-W and PS-W	+	+	+	-	-	-	10.0
22	Focal (left TO)	+	*	-	-	*	-	12.0
23	Focal (right TO) with spreading	+	+	+	+	-	+	12.0
24	Focal (TO) with spreading	+	+	+	-	-	+	8.0
25	Focal (right O)	+	+	+	+	+	+	10.0
26	Focal (bilateral O)	+	*	*	-	*	*	9.0
	Focal	17	IPS	25	IPS	14		Mean 9.6 ± 1.5
	Generalized	5	PS	22	PS	16		
	Generalized + Focal	2	TV	18	TV	15		
	Multifocal	2						

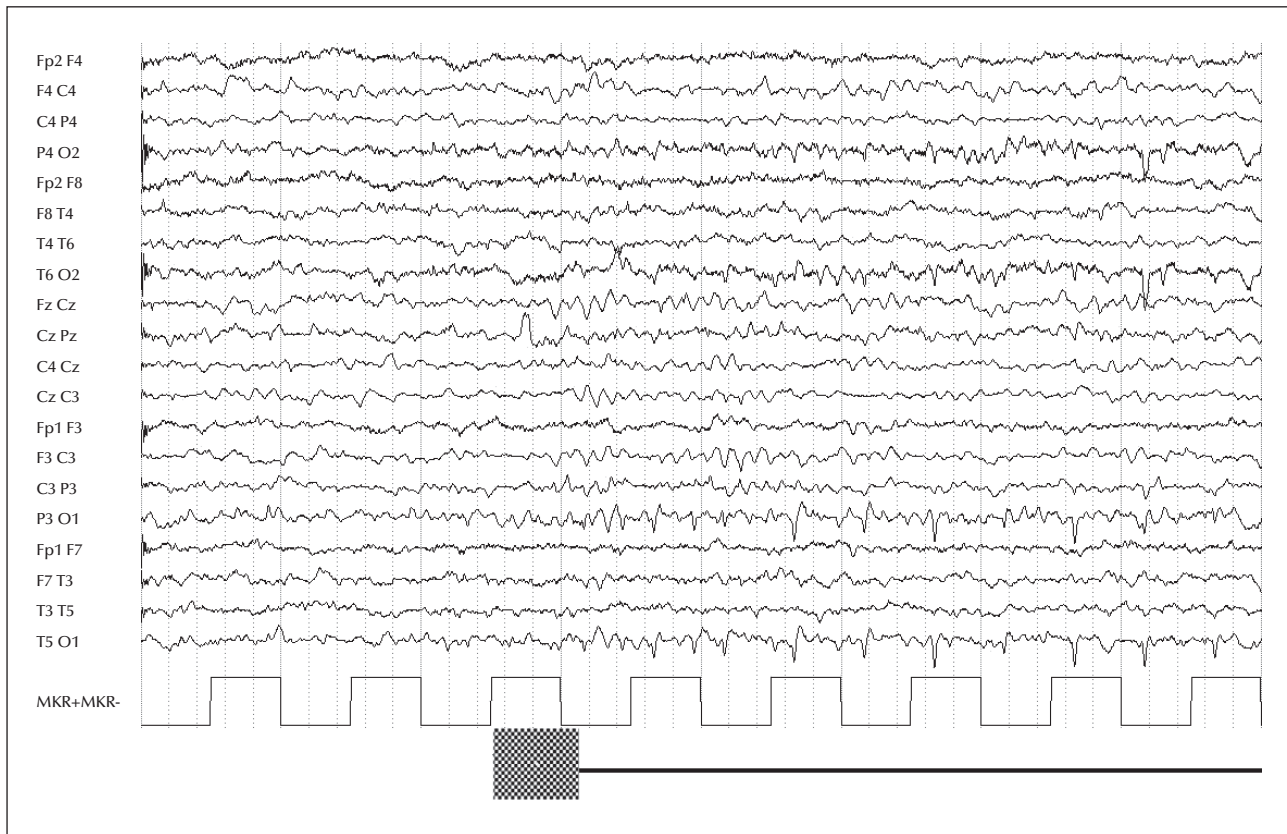
IPS: intermittent photic stimulation; PS: pattern stimulation; PEM: paroxysmal eyelid movements; F: Frontal, C: central; T: temporal; P: parietal; O: occipital; S-W: spike-wave complexes; PS-W: polyspike-wave complexes; + present; - absent; \* not available.



**Figure 1.** (A) Short episode (one second) of eyelid closure followed by upturning of the eyes, associated with rapid eyelid flutter at about 10 Hz (bold line). The EEG shows occipital alpha rhythm, without epileptic abnormalities. Note the high blink rate associated with the PEM. EOG-1: horizontal oculogram; EOG-2: vertical oculogram; ECG: electrocardiogram. (B) Generalized polyspikes and spike-wave complexes of high amplitude, induced by IPS in the same patient (Case 21). EC: eye closed. EEG channel settings: sensitivity: 7.5  $\mu$ V/mm; time: 30 mm/s; filters: 0.5-70 Hz.

onset of disease (Conte *et al.*, 2013), however, none of our cases were consistent with these diagnoses. Epileptic eyelid myoclonia occurred in most of our patients, often associated with reflex seizures, but none of them had the syndrome of eyelid myoclonia with absences (EMA). Even though the recent ILAE classification does not list EMA among the epilepsy syndromes (Berg *et al.*, 2010), these patients present with well-defined electroclinical features characterized

by brief myoclonic jerks of the eyelids, with or without absences, usually precipitated by eye closure and associated with EEG generalized 3-6-Hz poly-spike-wave discharge and photosensitivity. Capovilla *et al.* (2009) recently described a homogeneous population of patients with eyelid myoclonia, but separate from EMA. In all these cases, it is particularly important to differentiate PEM from epileptic eyelid myoclonia to ensure appropriate clinical and therapeutic



**Figure 2.** Spikes and sharp waves in the left occipital area elicited by PS (Case 4). EEG channel settings: sensitivity: 7.5  $\mu\text{V}/\text{mm}$ ; time: 30 mm/s; filters: 0.5-70 Hz.

management. Slow eye closure, as well as repeated opening/closing of the eyes in front of light, has been reported as a self-induction behaviour (Binnie *et al.*, 1980; Bebek *et al.*, 2006), especially in patients with EMA. Eight of our patients had self-induced seizures, and four of them induced their seizures by blinking in front of light sources. In these patients, the episodes of PEM were never related to self-induced seizures, moreover, no patients reported pleasurable feeling during the episodes of PEM.

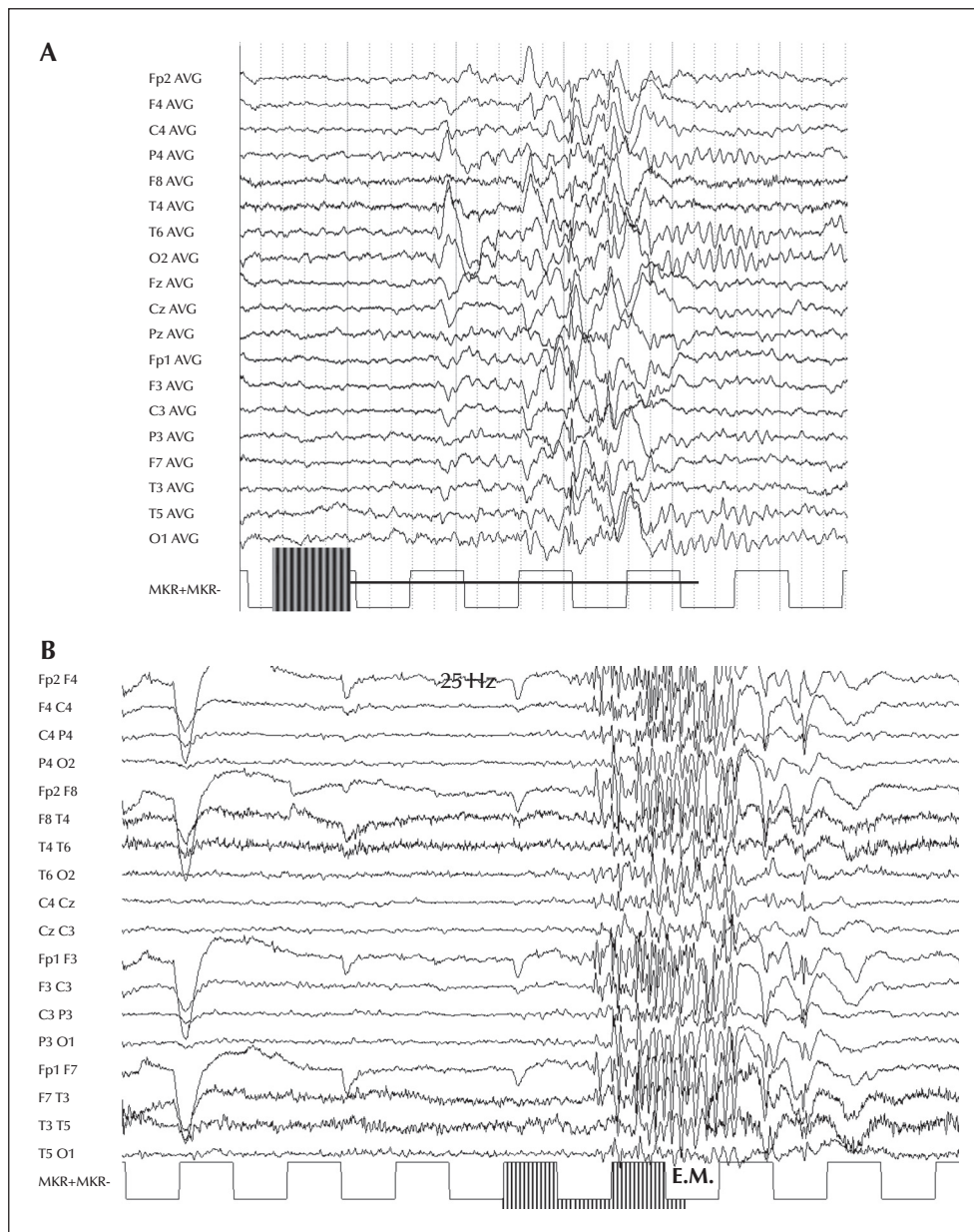
All our patients showed PPR but, unlike the sample of Camfield *et al.* (2004), they had different types of epilepsy in addition to IGE, such as focal idiopathic and focal symptomatic epilepsies. These observations suggest a complex relationship between PEM and epilepsy in which the PPR, more than seizure type, seems to play a main aetiological role. The PPR is a highly heritable EEG trait characterized by an abnormal cortical response to visual stimuli (Fisher *et al.*, 2005). Recent genome-wide linkage studies identified three suggestive loci for PPR at 5q35.3, 8q21.13, and 16p13.3 (de Kovel *et al.*, 2010). Other studies (Tauer *et al.*, 2005) identified a locus on 6p21.2 for the PPR itself and a different locus on 13q31.3 for the PPR related to IGE. Even though commonly associated with IGE, PPR can

occur in focal epilepsies (Lu *et al.*, 2008), and typically in patients with idiopathic photosensitive occipital lobe epilepsy (IPOE) (Guerrini *et al.*, 1994). Family studies on idiopathic photosensitive epilepsies showed a phenotypic spectrum with overlap between the focal features of IPOE and the IGE syndromes (Taylor *et al.*, 2013). These complex genetic aspects of PPR could explain its occurrence in our patients with focal epilepsies.

The coexistence of PEM, PPR, increased blinking during PEM, and epileptic eyelid myoclonia suggests that their pathophysiological mechanisms are closely related to an underlying dysfunction involving cortical-subcortical neural networks. Several pieces of evidence in the literature support this hypothesis:

- patients with JME show abnormal activation of the striato-thalamocortical network in response to IPS when studied by EEG-fMRI (Bartolini *et al.*, 2014);
- clinical and experimental data support functional connectivity between the thalamus and visual cortex related to the eyes closed/open condition as well as to spontaneous blinking (Zou *et al.*, 2009; Kaminer *et al.*, 2011);
- EEG-fMRI studies of patients with eyelid myoclonia show a pattern of activation in the thalamus (Liu *et al.*, 2008; Vaudano *et al.*, 2014).

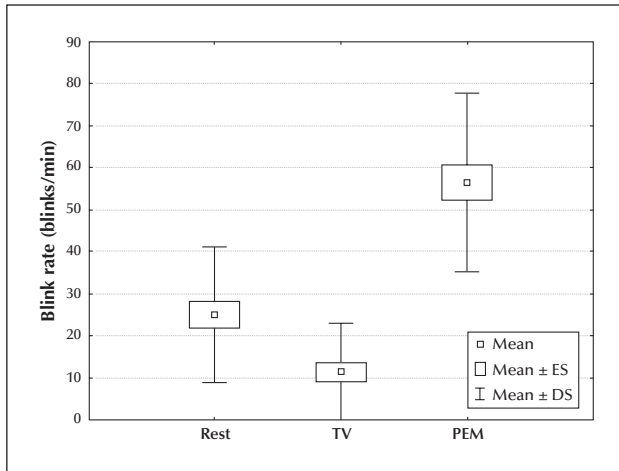




**Figure 3.** Ictal EEG features. (A) Spikes, sharp waves, slow waves, and spike-wave complexes in the parieto-temporo-occipital areas with spreading to other regions, associated with simple visual hallucinations evoked by PS in Patient 17. (B) Generalised PPR with epileptic eyelid myoclonia (E.M.) induced by IPS in Patient 20. EEG channel settings: sensitivity: 7.5  $\mu$ V/mm; time: 30 mm/s; filters: 0.5-70 Hz.

In particular, Vaudano *et al.* (2014) found altered anatomo-functional properties of the visual system in patients with EMA, encompassing the occipital cortex and the cortical/subcortical systems physiologically involved in the motor control of eye closure and eye movements. According to these findings, the occurrence of different clinical signs that express a dysfunction, probably genetically determined, in cortical-subcortical neural networks, is consistent with the concept of system epilepsies (Avanzini *et al.*, 2012). Recent data of functional imaging with high spatio-

temporal resolution support this pathophysiology of reflex epilepsy, showing the involvement of both cortical and subcortical networks (Sandhya *et al.*, 2014). Finally, for differential diagnosis of PEM, one should consider other paroxysmal disorders of movement, such as blepharospasm, paroxysmal tonic upward gaze, and motor tics. Blepharospasm is a spasm of the orbicularis muscle, accompanied by wrinkling of the eyebrow and narrowing of the palpebral fissures (Hallett, 2002). Paroxysmal tonic upward gaze is manifested by episodes of deviation of the eyes upward, not



**Figure 4.** Blink rate of patients during three different conditions: at rest with eyes open, during TV viewing, and during the occurrence of PEM. The box plots represent mean values with standard errors; standard deviation is marked by whiskers.

associated with eyelid winks; typically, episodes start within the first year of life and tend to remit spontaneously after one or two years (Ouvrier and Billson, 2005). Motor tics are repetitive but not rhythmic movements (Khalifa and von Knorring, 2005). When affecting eyes and face, tics may appear as complex movements or fractions of motor actions expressed in an inappropriate context. Movements tend to change over time in location, intensity, and frequency and may be associated with phonic tics.

In conclusion, PEM are a non-epileptic manifestation that must be differentiated from other types of attacks to avoid misdiagnosis and unnecessary treatments. Even though these are relatively frequent in photosensitive patients with IGE, these attacks may occur in other types of epilepsy. In addition, as our study is cross-sectional, we cannot exclude the possibility that PEM occur in other pathological conditions. In any case, their presence seems closely linked to the following factors: reflex seizures induced by visual stimuli, occurrence of spontaneous and/or reflex eyelid myoclonia, increased frequency of blinking, and abnormal EEG response to visual stimuli (PPR). These findings suggest a possible genetic relationship between PEM and epilepsy, which appears to be closely related to the abnormal sensitivity of the visual system more than to the type of epilepsy. A complex inheritance model with shared genetic determinants may explain the occurrence of PPR in both generalized and focal epilepsies. From a practical standpoint, PEM must be differentiated from other paroxysmal episodes in order to prevent inappropriate treatment, since AEDs are usually ineffective against non-epileptic manifestations. □

#### Supplementary data.

Summary didactic slides are available on the [www.epilepticdisorders.com](http://www.epilepticdisorders.com) website.

#### Acknowledgements and disclosures.

We would like to thank Dr. Antonio Mittica for his valuable contribution and technical assistance in performing standardized procedures of visual stimulations.

None of the authors have any conflict of interest to disclose.

### Legends for video sequences

#### Video sequence 1

Patient with CAE (Case 4): episode of eyelid closure with rapid eyelid flutter.

**Keywords for the video research on [www.epilepticdisorders.com](http://www.epilepticdisorders.com)**

*Syndrome:* childhood absence epilepsy (CAE)

*Aetiology:* idiopathic

*Phenomenology:* nonepileptic paroxysmal event

*Localization:* not applicable

#### Video sequence 2

Patient with JME (Case 21): PEM characterized by eyelid closure, upturning of the eyes, and rapid eyelid flutter. The attack was preceded and accompanied by short bursts of rapid blinking.

**Keywords for the video research on [www.epilepticdisorders.com](http://www.epilepticdisorders.com)**

*Syndrome:* juvenile myoclonic epilepsy (JME)

*Aetiology:* idiopathic

*Phenomenology:* nonepileptic paroxysmal event

*Localization:* not applicable

#### Video sequence 3

Patient with focal symptomatic epilepsy (Case 11): two short episodes of eyelid closure and rapid eyelid flutter, preceded and accompanied by rapid blinks.

**Keywords for the video research on [www.epilepticdisorders.com](http://www.epilepticdisorders.com)**

*Syndrome:* focal non-idiopathic (localization not specified)

*Aetiology:* symptomatic

*Phenomenology:* nonepileptic paroxysmal event

*Localization:* not applicable

## References

- Avanzini G, Manganotti P, Meletti S, *et al.* The system epilepsies: a pathophysiological hypothesis. *Epilepsia* 2012; 53(5): 771-8.
- Bartolini E, Pesaresi I, Fabbri S, *et al.* Abnormal response to photic stimulation in Juvenile Myoclonic Epilepsy: an EEG-fMRI study. *Epilepsia* 2014; 55(7): 1038-47.
- Bebek N, Baykan B, Gürses C, Emir O, Gökyiğit A. Self-induction behavior in patients with photosensitive and hot water epilepsy: a comparative study from a tertiary epilepsy center in Turkey. *Epilepsy Behav* 2006; 9(2): 317-26.
- Berg AT, Berkovic SF, Brodie MJ, *et al.* Revised terminology and concepts for organization of seizures and epilepsies: report of the ILAE Commission on Classification and Terminology, 2005-2009. *Epilepsia* 2010; 51(4): 676-85.
- Binnie CD, Darby CE, de Korte RA, Wilkins AJ. Self-induction of epileptic seizures by eye closure: incidence and recognition. *J Neurol Neurosurg Psychiatry* 1980; 43: 386-9.
- Boghen D. Apraxia of lid opening: a review. *Neurology* 1997; 48: 1491-503.
- Brinciotti M, Matricardi M, Pelliccia A, Trasatti G. Pattern sensitivity and photosensitivity in epileptic children with visually induced seizures. *Epilepsia* 1994; 35(4): 842-9.
- Camfield CS, Camfield PR, Sadler M, *et al.* Paroxysmal eyelid movements. A confusing feature of generalized photosensitive epilepsy. *Neurology* 2004; 63: 40-2.
- Capovilla G, Striano P, Gambardella A, *et al.* Eyelid fluttering, typical EEG pattern and impaired intellectual function: a homogeneous epileptic condition among the patients presenting with eyelid myoclonia. *Epilepsia* 2009; 50(6): 1536-41.
- Chung SS, Gerber P, Kirilin KA. Ictal eye closure is a reliable indicator for psychogenic nonepileptic seizures. *Neurology* 2006; 66: 1730-1.
- Commission on Classification and Terminology of the International League Against Epilepsy. Proposal for revised classification of epilepsies and epileptic syndromes. *Epilepsia* 1989; 30: 389-99.
- Conte A, Defazio G, Ferrazzano G, *et al.* Is increased blinking a form of blepharospasm? *Neurology* 2013; 80(24): 2236-41.
- de Kovel CG, Pinto D, Tauer U, *et al.* Whole-genome linkage scan for epilepsy-related photosensitivity: a mega-analysis. *Epilepsy Res* 2010; 89(2-3): 286-94.
- DeToledo JC, Ramsay RE. Patterns of involvement of facial muscles during epileptic and nonepileptic events: review of 654 events. *Neurology* 1996; 47: 621-5.
- Esteban Á, Traba A, Julio Prieto J. Eyelid movements in health and disease. The supranuclear impairment of the palpebral motility. *Neurophysiologie Clinique* 2004; 34: 3-15.
- Fisher RS, Harding G, Erba G, Barkley GL, Wilkins A. Photic and pattern-induced seizures: a review for the Epilepsy Foundation of America Working Group. *Epilepsia* 2005; 46: 1426-41.
- Flügel D, Bauer J, Käseborn U, Burr W, Elger CE. Closed eyes during a seizure indicate psychogenic etiology: a study with suggestive seizure provocation. *J Epilepsy* 1996; 9(3): 165-9.
- Guerrini R, Ferrari AR, Battaglia A, Salvadori P, Bonanni P. Occipito-temporal seizures with ictus emeticus induced by intermittent photic stimulation. *Neurology* 1994; 44: 253-9.
- Hallett M. Blepharospasm: recent advances. *Neurology* 2002; 59(9): 1306-12.
- Kaminer J, Powers AS, Horn KG, Hui C, Evinger C. Characterizing the spontaneous blink generator: an animal model. *J Neurosci* 2011; 31: 11256-67.
- Karson CN. Spontaneous eye-blink rates and dopaminergic systems. *Brain* 1983; 106: 643-53.
- Karson CN, Berman KF, Donnelly EF, Mendelson WF, Kleinman JE, Wyatt RJ. Speaking, thinking, and blinking. *Psychiatry Res* 1981; 5: 243-6.
- Kasteleijn-Nolst Trenité D, Rubboli G, Hirsch E, *et al.* Methodology of photic stimulation revisited: updated European algorithm for visual stimulation in the EEG laboratory. *Epilepsia* 2012; 53(1): 16-24.
- Khalifa N, von Knorring AL. Tourette syndrome and other tic disorders in a total population of children: clinical assessment and background. *Acta Paediatr Scand* 2005; 94: 1608-14.
- Liu Y, Yang T, Liao W, *et al.* EEG-fMRI study of the ictal and interictal epileptic activity in patients with eyelid myoclonia with absences. *Epilepsia* 2008; 49: 2078-86.
- Lu Y, Waltz S, Stenzel K, Muhle H, Stephani U. Photosensitivity in epileptic syndromes of childhood and adolescence. *Epileptic Disord* 2008; 10(2): 136-43.
- Obeid M, Mikati MA. Expanding spectrum of paroxysmal events in children: potential mimickers of epilepsy. *Pediatr Neurol* 2007; 37: 309-16.
- Ouvrier R, Billson F. Paroxysmal tonic upgaze of childhood - A review. *Brain Dev* 2005; 27: 185-8.
- Panayiotopoulos CP, Obeid T, Waheed G. Differentiation of typical absence seizures in epileptic syndromes. A video EEG study of 224 seizures in 20 patients. *Brain* 1989; 112(4): 1039-56.
- Pult H, Riede-Pult BH, Murphy PJ. A new perspective on spontaneous blinks. *Ophthalmology* 2013; 120: 1086-91.
- Sadlir LG, Farrell K, Smith S, Connolly MB, Scheffer IE. Electroclinical features of absence seizures in childhood absence epilepsy. *Neurology* 2006; 67(3): 413-8.
- Sandhya M, Bharath RD, Panda R, *et al.* Understanding the pathophysiology of reflex epilepsy using simultaneous EEG-fMRI. *Epileptic Disord* 2014; 1: 19-29.
- Stevens JR. Disturbances of ocular movements and blinking in schizophrenia. *J Neurol Neurosurg Psychiatry* 1978; 41: 1024-30.
- Sun WS, Baker RS, Chuke JC, *et al.* Age-related changes in human blinks. Passive and active changes in eyelid kinematics. *Invest Ophthalmol Vis Sci* 1997; 38: 92-9.

Syed TU, Arozullah AM, Suci GP, *et al.* Do observer and self-reports of ictal eye closure predict psychogenic nonepileptic seizures? *Epilepsia* 2008; 49: 898-990.

Tauer U, Lorenz S, Lenzen KP, *et al.* Genetic dissection of photosensitivity and its relation to idiopathic generalized epilepsy. *Ann Neurol* 2005; 57(6): 866-73.

Taylor I, Berkovic SF, Scheffer IE. Genetics of epilepsy syndromes in families with photosensitivity. *Neurology* 2013; 80(14): 1322-9.

Tulen JH, Azzolini M, de Vries JA, Groeneveld WH, Passchier J, van de Wetering BJM. Quantitative study of spontaneous eye blinks and eye tics in Gilles de la Tourette's syndrome. *J Neurol Neurosurg Psychiatry* 1999; 67: 800-2.

Vaudano AE, Ruggieri A, Tondelli M, *et al.* The visual system in eyelid myoclonia with absences. *Ann Neurol* 2014; 76: 712-27.

Watemberg N, Tziperman B, Dabby R, Hasan M, Zehavi L, Lerman-Sagie T. Adding video recording increases the diagnostic yield of routine electroencephalograms in children with frequent paroxysmal events. *Epilepsia* 2005; 46(5): 716-9.

Wilkins A, Emmett J, Harding G. Characterizing the patterned images that precipitate seizures and optimizing guidelines to prevent them. *Epilepsia* 2005; 46(8): 212-8.

Zametkin AJ, Stevens JR, Pittman R. Ontogeny of spontaneous blinking and of habituation of the blink reflex. *Ann Neurol* 1979; 5: 453-7.

Zou Q, Long X, Zuo X, *et al.* Functional connectivity between the thalamus and visual cortex under eyes closed and eyes open conditions: a resting-state fMRI study. *Hum Brain Mapp* 2009; 30: 3066-78.

## TEST YOURSELF



- (1) What are the main clinical features of Paroxysmal Eyelid Movements?
- (2) Which other clinical manifestation occurs coincidentally with Paroxysmal Eyelid Movements?
- (3) Which differential diagnoses must be considered in relation to Paroxysmal Eyelid Movements?

*Note: Reading the manuscript provides an answer to all questions. Correct answers may be accessed on the website, [www.epilepticdisorders.com](http://www.epilepticdisorders.com), under the section "The EpiCentre".*