

Supplementary material

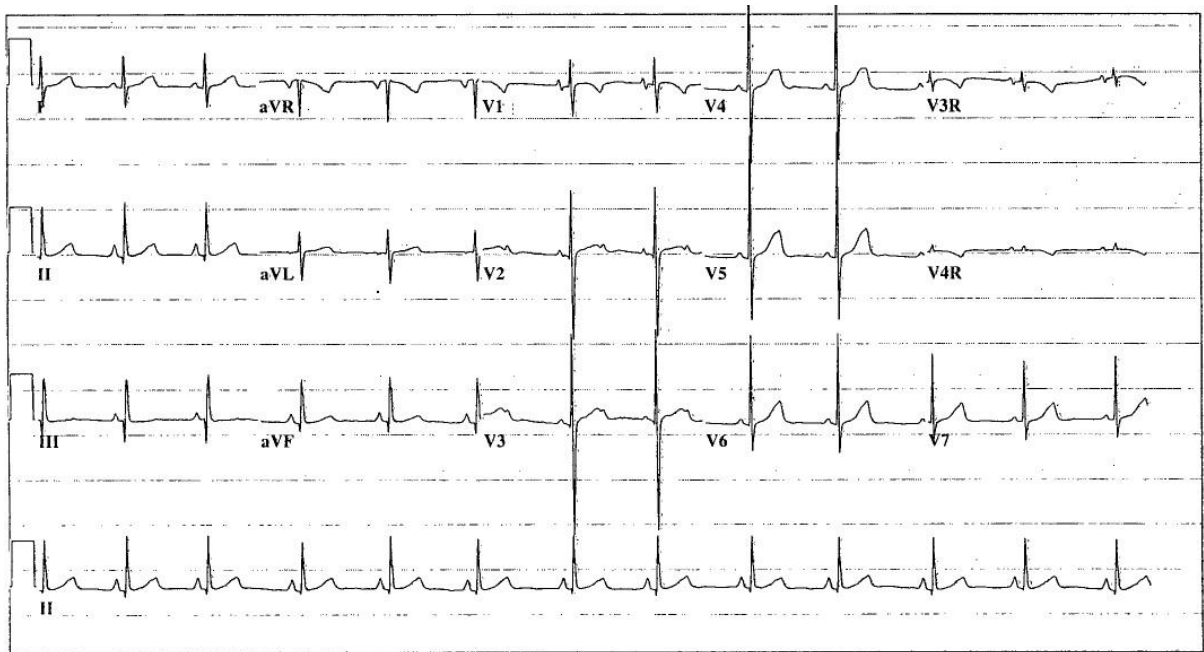


Figure 1.

Electrocardiogram (ECG) at 12 months of age showing sinus bradycardia (heart rate: 75 beats per minute) and normal calculated QT interval (QTc: 396 ms).