

# Genetic literacy series: genetic epilepsy with febrile seizures *plus*

Kenneth A. Myers<sup>1</sup>, Ingrid E. Scheffer<sup>1,2,3</sup>,  
Samuel F. Berkovic<sup>1</sup>, on behalf of the ILAE Genetics  
Commission\*

<sup>1</sup> Epilepsy Research Centre, Department of Medicine, The University of Melbourne,  
Austin Health, Heidelberg, Victoria

<sup>2</sup> Department of Paediatrics, Royal Children's Hospital, The University of Melbourne,  
Flemington, Victoria

<sup>3</sup> The Florey Institute of Neuroscience and Mental Health, Heidelberg, Victoria, Australia

Received March 24, 2018; Accepted May 27, 2018

**ABSTRACT** – Genetic epilepsy with febrile seizures *plus* (GEFS+) is a familial epilepsy syndrome in which affected individuals within a family typically have a variety of epilepsy phenotypes, varying from simple febrile seizures and febrile seizures *plus* with a good outcome to severe epileptic encephalopathies. Here, we review the spectrum of epilepsy phenotypes, the genetic architecture of GEFS+, and the implicated genes. Using an illustrative clinical case study, we describe important steps in managing patients with GEFS+: making the diagnosis of GEFS+, appropriate genetic testing, and counselling.

**Key words:** genetic epilepsy with febrile seizures *plus*, GEFS+, *SCN1A*, epilepsy, febrile seizures, *SCN1B*

\* Full list of ILAE Genetics Commission Members:

**Helen Cross**, UCL-Institute of Child Health, Great Ormond Street Hospital for Children, London & Young Epilepsy, Lingfield, UK; **Peter De Jonghe**, Neurogenetics Group, Department of Molecular Genetics, VIB, Laboratory of Neurogenetics, Institute Born-Bunge, University of Antwerp, and Division of Neurology, Antwerp University Hospital, Antwerp, Belgium; **Alica Goldman**, Department of Neurology, Baylor College of Medicine, Houston, Texas, USA; **Ingo Helbig**, Division of Neurology, The Children's Hospital of Philadelphia, Philadelphia, PA, U.S.A. and Department of Neuropediatrics, University Medical Centre Schleswig-Holstein, Christian-Albrechts-University, Kiel, Germany; **Yuwu Jiang**, Department of Pediatrics, Peking University First Hospital, Beijing, China; **Mitsuhiro Kato**, Department of Pediatrics, Showa University School of Medicine, Tokyo, Japan; **Daniel H Lowenstein**, Department of Neurology, University of California, San Francisco, USA; **Heather C Mefford**, Department of Pediatrics, Division of Genetic Medicine, University of Washington, Seattle, WA, USA; **Steve Petrou**, The Florey Institute of Neuroscience and Mental Health, Parkville VIC 3052, Australia; **Parthasathy Satishchandra**, National Institute of Mental Health & Neuro Sciences (NIMHANS), Bangalore, India; **Nigel CK Tan**, Department of Neurology, National Neuroscience Institute, Singapore, Singapore.

## Correspondence:

Samuel Berkovic  
Epilepsy Research Centre,  
Level 2, Melbourne Brain Centre,  
Austin Health, 245 Burgundy St,  
Heidelberg, VIC 3084,  
Victoria, Australia  
<s.berkovic@unimelb.edu.au>

## Illustrative case study

A three-year-old girl, accompanied by her mother, is seen in the emergency room for a new type of seizure. She had been having seizures every two to three months, since the age of 18 months. The seizures involved bilateral stiffening and clonic movements, with eyes deviated upwards, lasting 30 to 90 seconds. All had occurred with temperatures between 38.5°C and 40°C, when she was ill with rhinorrhoea and coughing. Her mother was told that these were febrile seizures (FS) and that the girl did not require any investigations or treatment. However, she now presents with another similar seizure, this time with a temperature of 36.8°C and no symptoms of illness.

The girl was born following an uncomplicated pregnancy and delivery at term. Her past medical history is otherwise unremarkable. There had been no concerns regarding her development; she sat at six months and walked independently at 12 months. She spoke her first word at one year, and is speaking in two to three-word sentences. Her general and neurological examinations were normal.

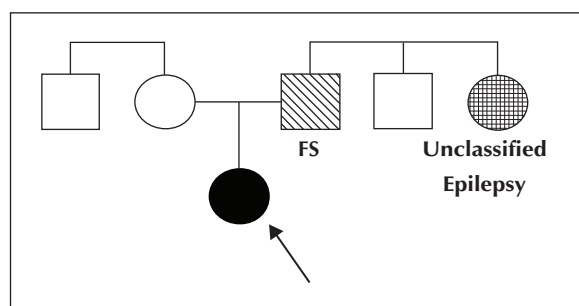
Based on the family history (*figure 1*), the girl's father had "convulsions" as a baby when he was sick, which disappeared as he grew up. The girl also has a paternal aunt with epilepsy; the girl's mother does not know the details of the aunt's presentation, but will ask the girl's father.

## Questions

- (1) What is the girl's syndromic diagnosis?
- (2) What counselling is appropriate?
- (3) What, if any, genetic testing should be considered/offered?

## GEFS+ spectrum

Genetic (formerly "generalized") epilepsy with febrile seizures *plus* (GEFS+) was conceived as a familial



**Figure 1.** Genogram for the case study (the proband is indicated by the arrow).

FS: febrile seizures.

epilepsy syndrome in which affected individuals within a family typically have a variety of epilepsy presentations or phenotypes (Scheffer and Berkovic, 1997). FS are the most common phenotype in the GEFS+ spectrum, followed by febrile seizures *plus* (FS+). Additional phenotypes in the GEFS+ spectrum include FS or FS+ with other generalized seizure types such as absence, myoclonic, atonic seizures or focal seizures (Abou-Khalil *et al.*, 2001; Zhang *et al.*, 2017). The majority of affected individuals have mild epilepsy with normal development.

The developmental and epileptic encephalopathies, Dravet syndrome (DS) and epilepsy with myoclonic-atonic seizures (MAE), also occur in GEFS+ families (Scheffer and Berkovic, 1997; Singh *et al.*, 1999; Singh *et al.*, 2001; Zhang *et al.*, 2017). Within GEFS+ families, there may also be individuals with focal epilepsy or genetic generalized epilepsy phenotypes *without* FS/FS+ (Zhang *et al.*, 2017). A GEFS+ family is defined as a family with  $\geq$  two individuals with GEFS+ phenotypes, including at least one with FS or FS+.

Key clinical features of the epilepsy syndromes within the GEFS+ spectrum are summarized as follows.

## Febrile seizures (FS)

Febrile seizures are the most common phenotype in GEFS+, present in 41% of affected individuals in GEFS+ families (Zhang *et al.*, 2017). FS are tonic-clonic seizures associated with fever ( $\geq 38^\circ\text{C}$ ), occurring between three months and six years (Consensus Development Panel, 1980; Scheffer and Berkovic, 1997). Seizures are typically bilateral convulsions and spontaneously terminate within several minutes in most cases, but may continue for more than 30 minutes (Chevrie and Aicardi, 1975; Storz *et al.*, 2015; Vitaliti *et al.*, 2017). FS are the most common seizure disorder with an estimated prevalence of 3-4%, though certain ethnic groups, including those from Finland, Japan and Guam, have an increased frequency (Van den Berg and Yerushalmy, 1969; Hauser and Kurland, 1975; Verity *et al.*, 1985; Annegers *et al.*, 1987; Hamdy *et al.*, 2007). The precise percentage of patients with FS that fall within the GEFS+ spectrum is unclear. In one study, 6% of FS cases had a history of seizures, febrile or afebrile, affecting a first-degree family member (Nelson and Ellenberg, 1990).

## Febrile seizures *plus* (FS+)

FS+ occur in 20% of affected individuals in GEFS+ families (Zhang *et al.*, 2017). Of patients initially presenting with FS, 9% of cases had FS+ (Eckhaus *et al.*, 2013). The FS+ syndromic diagnosis was initially defined as individuals with FS that continued past six years, with or without co-occurring afebrile generalized tonic-clonic

seizures (Scheffer and Berkovic, 1997). The definition has subsequently been broadened to include two criteria, and patients can have one or both.

First, FS that extend beyond the typical age range (*i.e.* before three months or after six years). Second, the occurrence of both febrile and afebrile generalized tonic-clonic seizures, either limited to the usual age for FS (three months to six years) or occurring outside that time period (Eckhaus *et al.*, 2013). Most commonly, generalized tonic-clonic seizures continue after age six years, with or without fever, and typically stop by adolescence, although rare adult afebrile generalized tonic-clonic seizures may occur (Singh *et al.*, 1999; Singh *et al.*, 2001). FS+ typically occur in individuals of normal intellect (Zhang *et al.*, 2017).

### Complex GEFS+ phenotypes

FS and FS+ can occur with a variety of other seizure types including absence, myoclonic or atonic seizures (Scheffer and Berkovic, 1997). Within GEFS+ families, focal seizures with temporal or frontal lobe semiology may also occur, not always preceded by FS (Abou-Khalil *et al.*, 2001; Baulac *et al.*, 2001; Scheffer *et al.*, 2007). When FS or FS+ occur with other seizure types, this can be conceptualized as “FS or FS+ with \_\_\_\_ seizures” (*e.g.* “FS+ with absence seizures”).

In addition, classic genetic generalized epilepsies occur in 5% of affected individuals in GEFS+ families, sometimes with preceding FS (Zhang *et al.*, 2017). Recently, afebrile generalized tonic-clonic seizures alone, without preceding FS, have been observed in GEFS+ families (Zhang *et al.*, 2017). When these focal or generalized epilepsy syndromes occur without FS, but in the context of a GEFS+ family, they may also be considered to lie within the GEFS+ spectrum.

### Associated developmental and epileptic encephalopathies

GEFS+ may involve more severe epilepsy syndromes; specifically, DS and MAE (Scheffer and Berkovic, 1997; Singh *et al.*, 1999; Singh *et al.*, 2001). DS is a developmental and epileptic encephalopathy that classically presents with FS at around six months, often with hemiclonic status epilepticus. Other seizure types subsequently develop, most commonly including afebrile generalized tonic-clonic, focal impaired awareness, myoclonic, and absence seizures (Dravet, 2011). Development is initially normal, however, by two years of age individuals usually show developmental plateauing or regression, and ultimately have intellectual disability that varies from severe to mild.

### Key points

- The most common GEFS+ phenotype is febrile seizures (FS) followed by febrile seizures *plus* (FS+).
- FS+ is defined as either or both of the following: (A) febrile tonic-clonic seizures that begin before three months and/or continue after six years; (B) the occurrence of both febrile and afebrile generalized tonic-clonic seizures.
- The GEFS+ spectrum comprises a heterogeneous group of generalized and focal epilepsy phenotypes including the developmental and epileptic encephalopathies of epilepsy with myoclonic-atonic seizures and Dravet syndrome.
- Mutations in *SCN1A* are the most common identified genetic cause of GEFS+, accounting for 19% of families.
- Whether clinical molecular genetic testing in patients with FS+ or other GEFS+ phenotypes is indicated is currently under debate. If genetic testing is offered, *SCN1A* sequencing should be included, and this may be most efficiently performed as part of a panel or whole-exome sequencing.

MAE (formerly known as myoclonic-astatic epilepsy or Doose syndrome) is a childhood-onset generalized epilepsy characterized by drop attacks which are myoclonic-atonic, myoclonic or atonic in nature, with onset between two and six years of age. Patients typically develop additional seizure types including absence and generalized tonic-clonic seizures, as well as episodes of non-convulsive status epilepticus; focal seizures are not seen. In two thirds of cases, FS precede the myoclonic-atonic and atonic seizures (Bureau *et al.*, 2012). Early development is typically normal with regression at seizure onset, indicating that it should be considered an epileptic encephalopathy in at least some cases. Long-term developmental outcome is variable; some individuals have normal intellect while others have intellectual disability (Bureau *et al.*, 2012).

### Genetic architecture of GEFS+

#### Inheritance

GEFS+ was originally described in a large Australian family, in which inheritance followed an autosomal dominant pattern with variable expressivity (Scheffer and Berkovic, 1997). Subsequently, many families have been reported with a similar pattern of inheritance (Baulac *et al.*, 1999; Singh *et al.*, 1999), leading to the initial concept that GEFS+ was an autosomal dominant disorder.

However, in smaller families and sporadic cases, inheritance may be polygenic or due to *de novo* mutations

(Wallace *et al.*, 1998; Singh *et al.*, 1999; Eckhaus *et al.*, 2013; Myers *et al.*, 2017). Further, two small consanguineous GEFS+ families have been reported with likely autosomal recessive inheritance (Brunklaus *et al.*, 2015). As GEFS+ phenotypes have become better recognized, it is clear that not all occur in a familial context, and they can be diagnosed in sporadic cases, in which *de novo* mutations in GEFS+ genes may be found (Myers *et al.*, 2017).

## Implicated genes

### SCN1A

*SCN1A* (OMIM #182389) encodes the alpha-1 neuronal voltage-gated sodium channel subunit Na<sub>v</sub>1.1, and was the second gene associated with GEFS+ to be discovered (Escayg *et al.*, 2000). Of GEFS+ patients with known mutations, *SCN1A* mutation accounts for the largest fraction, with mutations identified in 19% of families (Marini *et al.*, 2007; Zhang *et al.*, 2017). Although inheritance is usually autosomal dominant with variable expressivity and penetrance, *de novo* mutations and autosomal recessive inheritance have also been described (Brunklaus *et al.*, 2015; Myers *et al.*, 2017). Patients with FS/FS+ due to *SCN1A* mutations have an earlier median onset of FS of 11-12 months compared with the population median of 18 months (Sijben *et al.*, 2009).

*SCN1A* mutations are identified in >80% of DS patients, and the vast majority of individuals have *de novo* mutations. However, for approximately 10% of apparently “*de novo*” inheritance, one parent is a mosaic carrier and, depending on the percentage mosaicism, may exhibit a milder phenotype including FS or FS+ (Xu *et al.*, 2015). GEFS+ is typically associated with missense *SCN1A* mutations, while DS may occur with both missense and truncation mutations (Zuberi *et al.*, 2011).

### SCN1B

*SCN1B* (OMIM #600235) encodes the beta-1 subunit of the voltage-gated sodium channel. *SCN1B* was the first gene discovered for GEFS+, described in a large family with autosomal dominant inheritance with variable expressivity (Wallace *et al.*, 1998). *SCN1B* mutations are identified in up to 8% of GEFS+ families (Zhang *et al.*, 2017). Patients with FS/FS+ and *SCN1B* mutations have later onset of FS compared to patients with mutations in *SCN1A* (24 months *versus* 12 months) (Sijben *et al.*, 2009). When focal epilepsy occurs in such GEFS+ families with *SCN1B* mutations, the phenotype is that of temporal lobe epilepsy which may or may not be preceded by FS (Scheffer *et al.*, 2007).

### GABRG2

Multiple GEFS+ families have been reported with mutations in *GABRG2* (OMIM #137164), the gene encoding the GABA-A gamma-2 receptor subunit (Baulac *et al.*, 2001; Wallace *et al.*, 2001; Tian *et al.*, 2013; Ishii *et al.*, 2014). Overall, *GABRG2* mutations are identified in up to 9% of GEFS+ families (Zhang *et al.*, 2017). Individuals with genetic generalized epilepsies, particularly childhood absence epilepsy, may be more common in GEFS+ families with *GABRG2* mutations (Wallace *et al.*, 2001; Marini *et al.*, 2003).

### Other genes

Other genes have been implicated in GEFS+ based on the identification of mutations in families or individuals with FS+, including *STX1B* (Schubert *et al.*, 2014), *SCN9A* (Singh *et al.*, 2009; Mulley *et al.*, 2013), *GABRD* (Dibbens *et al.*, 2004), and *FGF13*, and have been suggested as susceptibility alleles for GEFS+ (Puranam *et al.*, 2015; Rigbye *et al.*, 2016), however, an understanding of the role of these genes requires further investigation.

Variants in *SCN2A* have also been reported in a small GEFS+ family (Sugawara *et al.*, 2001) and a single individual with FS and childhood absence epilepsy (Haug *et al.*, 2001). However, both variants have subsequently been identified in control populations suggesting that they may not be pathogenic or perhaps contribute as a susceptibility allele for the phenotype in these individuals.

## Current practical management considerations

When faced with a patient such as the girl presented here, making a correct diagnosis with appropriate counselling and judicious use of genetic testing is essential. This girl had febrile and afebrile generalized tonic-clonic seizures, thus her diagnosis is FS+.

The first step is discussing the epilepsy diagnosis with the family, including the likelihood of seizure recurrence, need for medical therapy, and risk of comorbidities, including the risk of sudden unexpected death in epilepsy. The family can be counselled and informed that for most individuals with FS+, seizures will spontaneously resolve by puberty, however, there is a small risk of seizures occurring in adult life. Development is expected to be normal.

Families may ask whether evolution to DS is possible; in the present case, the patient's presentation is clearly not in keeping with DS. However, when infants present in the first year of life with febrile and afebrile convulsions, differentiating DS from FS+ may not be straightforward; we suggest following with developmental surveillance, serial EEGs, and counselling with a

“time will tell” approach until there are clinical features that allow for more clear differentiation.

Regarding the risk for future offspring, inheritance in the small family of the presented case appears to be autosomal dominant with variable penetrance, though other modes of inheritance are possible. The parents of the girl can be informed that the risk for any of their future offspring is likely to be less than 50% based on the available information.

Regarding genetic testing, there is ongoing debate as to whether this is appropriate for individuals with GEFS+ phenotypes (Hirose et al., 2013; Myers et al., 2017; Zhang et al., 2017). Some argue that, while clinical care is unlikely to change, identifying a mutation would be useful in terms of prognosis and family planning. If genetic testing is offered, *SCN1A* sequencing should be included, although this would be more efficiently performed as part of a panel or via whole-exome sequencing. In the presented case, the family should be informed that although the girl and her father (with FS) both appear to be mildly affected, there is a potential for other individuals who inherit a mutation affecting certain genes to have a more severe phenotype.

## Resolution

In the present case, the girl was diagnosed with GEFS+. Her parents elected to undergo whole-exome sequencing which did not reveal any mutations in known GEFS+ genes. The parents subsequently had a second child, who was healthy and developmentally normal, and did not have seizures. The first girl was treated with valproate and was seizure-free for two years, at which point she was weaned off medication. She was last seen at six years of age, at which time she had been seizure-free off medication for over a year. She was discharged from the clinic, however, the family was informed that she has an ongoing elevated risk for recurrent seizures, in which case she should return to the clinic. □

## Supplementary data.

Summary didactic slides are available on the [www.epilepticdisorders.com](http://www.epilepticdisorders.com) website.

## Disclosures.

IES and SFB are named inventors on a patent for diagnosis involving *SCN1A*. The patent, held by Bionomics Inc., is licensed to Athena Diagnostics and Genetics Technologies Ltd. KAM has no conflict of interest to declare.

This report was written by experts selected by the International League Against Epilepsy (ILAE) and was approved for publication by the ILAE. Opinions expressed by the authors, however, do not necessarily represent the policy or position of the ILAE.

## References

- Abou-Khalil B, Ge Q, Desai R, et al. Partial and generalized epilepsy with febrile seizures plus and a novel *SCN1A* mutation. *Neurology* 2001; 57: 2265-72.
- Annegers JF, Hauser WA, Shirts SB, et al. Factors prognostic of unprovoked seizures after febrile convulsions. *N Engl J Med* 1987; 316: 493-8.
- Baulac S, Gourfinkel-An I, Picard F, et al. A second locus for familial generalized epilepsy with febrile seizures plus maps to chromosome 2q21-q33. *Am J Hum Genet* 1999; 65: 1078-85.
- Baulac S, Huberfeld G, Gourfinkel-An I, et al. First genetic evidence of GABA(A) receptor dysfunction in epilepsy: a mutation in the gamma2-subunit gene. *Nat Genet* 2001; 28: 46-8.
- Brunklaus A, Ellis R, Stewart H, et al. Homozygous mutations in the *SCN1A* gene associated with genetic epilepsy with febrile seizures plus and Dravet syndrome in 2 families. *Eur J Paediatr Neurol* 2015; 19: 484-8.
- Bureau M, Genton P, Dravet C, et al. *Epileptic syndromes in infancy, childhood and adolescence*. 5th ed. Montrouge, France; John Libbey Eurotext, 2012.
- Chevrie JJ, Aicardi J. Duration and lateralization of febrile convulsions. Etiological factors. *Epilepsia* 1975; 16: 781-9.
- Consensus Development Panel. Consensus statement. Febrile seizures: long-term management of children with fever-associated seizures. *Pediatrics* 1980; 66: 1009-12.
- Dibbens LM, Feng HJ, Richards MC, et al. GABRD encoding a protein for extra- or peri-synaptic GABAA receptors is a susceptibility locus for generalized epilepsies. *Hum Mol Genet* 2004; 13: 1315-9.
- Dravet C. The core Dravet syndrome phenotype. *Epilepsia* 2011; 52: 3-9.
- Eckhaus J, Lawrence KM, Helbig I, et al. Genetics of febrile seizure subtypes and syndromes: a twin study. *Epilepsy Res* 2013; 105: 103-9.
- Escayg A, MacDonald BT, Meisler MH, et al. Mutations of *SCN1A*, encoding a neuronal sodium channel, in two families with GEFS+2. *Nat Genet* 2000; 24: 343-5.
- Hamdy NA, Ginby D, Feltbower R, et al. Ethnic differences in the incidence of seizure disorders in children from Bradford, United kingdom. *Epilepsia* 2007; 48: 913-6.
- Haug K, Hallmann K, Rebstock J, et al. The voltage-gated sodium channel gene *SCN2A* and idiopathic generalized epilepsy. *Epilepsy Res* 2001; 47: 243-6.
- Hauser WA, Kurland LT. The epidemiology of epilepsy in Rochester, Minnesota, 1935 through 1967. *Epilepsia* 1975; 16: 1-66.
- Hirose S, Scheffer IE, Marini C, et al. *SCN1A* testing for epilepsy: application in clinical practice. *Epilepsia* 2013; 54: 946-52.
- Ishii A, Kanaumi T, Sohda M, et al. Association of non-sense mutation in *GABRG2* with abnormal trafficking of GABAA receptors in severe epilepsy. *Epilepsy Res* 2014; 108: 420-32.

- Marini C, Harkin LA, Wallace RH, *et al.* Childhood absence epilepsy and febrile seizures: a family with a GABA(A) receptor mutation. *Brain* 2003; 126: 230-40.
- Marini C, Mei D, Temudo T, *et al.* Idiopathic epilepsies with seizures precipitated by fever and *SCN1A* abnormalities. *Epilepsia* 2007; 48: 1678-85.
- Mulley JC, Hodgson B, McMahon JM, *et al.* Role of the sodium channel *SCN9A* in genetic epilepsy with febrile seizures plus and Dravet syndrome. *Epilepsia* 2013; 54: e122-6.
- Myers KA, Burgess R, Afawi Z, *et al.* De novo *SCN1A* pathogenic variants in the GEFS+ spectrum: not always a familial syndrome. *Epilepsia* 2017; 58: e26-30.
- Nelson KB, Ellenberg JH. Prenatal and perinatal antecedents of febrile seizures. *Ann Neurol* 1990; 27: 127-31.
- Puranam RS, He XP, Yao L, *et al.* Disruption of *Fgf13* causes synaptic excitatory-inhibitory imbalance and genetic epilepsy and febrile seizures plus. *J Neurosci* 2015; 35: 8866-81.
- Rigbye KA, van Hasselt PM, Burgess R, *et al.* Is *FGF13* a major contributor to genetic epilepsy with febrile seizures plus? *Epilepsy Res* 2016; 128: 48-51.
- Scheffer IE, Berkovic SF. Generalized epilepsy with febrile seizures plus. A genetic disorder with heterogeneous clinical phenotypes. *Brain* 1997; 120: 479-90.
- Scheffer IE, Harkin LA, Grinton BE, *et al.* Temporal lobe epilepsy and GEFS+ phenotypes associated with *SCN1B* mutations. *Brain* 2007; 130: 100-9.
- Schubert J, Siekierska A, Langlois M, *et al.* Mutations in *STX1B*, encoding a presynaptic protein, cause fever-associated epilepsy syndromes. *Nat Genet* 2014; 46: 1327-32.
- Sijben AE, Sithinamsuwan P, Radhakrishnan A, *et al.* Does a *SCN1A* gene mutation confer earlier age of onset of febrile seizures in GEFS+? *Epilepsia* 2009; 50: 953-6.
- Singh R, Scheffer IE, Crossland K, *et al.* Generalized epilepsy with febrile seizures plus: a common childhood-onset genetic epilepsy syndrome. *Ann Neurol* 1999; 45: 75-81.
- Singh R, Andermann E, Whitehouse WP, *et al.* Severe myoclonic epilepsy of infancy: extended spectrum of GEFS+? *Epilepsia* 2001; 42: 837-44.
- Singh NA, Pappas C, Dahle EJ, *et al.* A role of *SCN9A* in human epilepsies, as a cause of febrile seizures and as a potential modifier of Dravet syndrome. *PLoS Genet* 2009; 5: e1000649.
- Storz C, Meindl M, Matuja W, *et al.* Community-based prevalence and clinical characteristics of febrile seizures in Tanzania. *Pediatr Res* 2015; 77: 591-6.
- Sugawara T, Tsurubuchi Y, Agarwala KL, *et al.* A missense mutation of the Na<sup>+</sup> channel alpha II subunit gene *Na(v)1.2* in a patient with febrile and afebrile seizures causes channel dysfunction. *Proc Natl Acad Sci USA* 2001; 98: 6384-9.
- Tian M, Mei D, Freri E, *et al.* Impaired surface alpha-betagamma GABA(A) receptor expression in familial epilepsy due to a *GABRG2* frameshift mutation. *Neurobiol Dis* 2013; 50: 135-41.
- Van den Berg BJ, Yerushalmy J. Studies on convulsive disorders in young children. I. Incidence of febrile and nonfebrile convulsions by age and other factors. *Pediatr Res* 1969; 3: 298-304.
- Verity CM, Butler NR, Golding J. Febrile convulsions in a national cohort followed up from birth. I. Prevalence and recurrence in the first five years of life. *Br Med J (Clin Res Ed)* 1985; 290: 1307-10.
- Vitaliti G, Castagno E, Ricceri F, *et al.* Epidemiology and diagnostic and therapeutic management of febrile seizures in the Italian pediatric emergency departments: a prospective observational study. *Epilepsy Res* 2017; 129: 79-85.
- Wallace RH, Wang DW, Singh R, *et al.* Febrile seizures and generalized epilepsy associated with a mutation in the Na<sup>+</sup>-channel beta1 subunit gene *SCN1B*. *Nat Genet* 1998; 19: 366-70.
- Wallace RH, Marini C, Petrou S, *et al.* Mutant GABA(A) receptor gamma2-subunit in childhood absence epilepsy and febrile seizures. *Nat Genet* 2001; 28: 49-52.
- Xu X, Yang X, Wu Q, *et al.* Amplicon resequencing identified parental mosaicism for approximately 10% of "de novo" *SCN1A* mutations in children with Dravet syndrome. *Hum Mutat* 2015; 36: 861-72.
- Zhang YH, Burgess R, Malone JP, *et al.* Genetic epilepsy with febrile seizures plus: refining the spectrum. *Neurology* 2017; 89: 1210-9.
- Zuberi SM, Brunklaus A, Birch R, *et al.* Genotype-phenotype associations in *SCN1A*-related epilepsies. *Neurology* 2011; 76: 594-600.

## TEST YOURSELF



**(1) Which is the most common phenotype seen in GEFS+?**

- A. Febrile seizures
- B. Febrile seizures plus
- C. Absence seizures
- D. Epileptic encephalopathies

**(2) Which of the following patients fulfils the criteria for FS+?**

- A. A three-year-old boy who had a single febrile seizure at age 24 months
- B. A 10-year-old girl who had febrile seizures at age 3, 7, 8 and 9 years.
- C. A 12-year-old boy who had myoclonic seizures since age 11 years
- D. A four-year-old boy diagnosed with Dravet Syndrome at age three years

*Note: Reading the manuscript provides an answer to all questions. Correct answers may be accessed on the website, [www.epilepticdisorders.com](http://www.epilepticdisorders.com), under the section "The EpiCentre".*