

Gaucher disease: successful treatment of myoclonic status epilepticus with levetiracetam

Guadalupe Fernandez-Baca Vaca¹, Timothy Lenz²,
Elia M Pestana Knight³, Ingrid Tuxhorn³

¹ Epilepsy Center, Neurological Institute, University Hospitals Case Medical Center, Cleveland, Ohio

² Department of Emergency Medicine, University Hospitals Case Medical Center, Cleveland, Ohio

³ Department of Pediatrics, Division of Pediatric Epilepsy, Rainbow Babies and Children's Hospital, Cleveland, Ohio, USA

Received July 02, 2011; Accepted March 14, 2012

ABSTRACT – We present the first reported case of a rapid clinical and electroencephalographic response to intravenous levetiracetam infusion of myoclonic status epilepticus in a patient with progressive myoclonus epilepsy due to Gaucher disease. Under continuous video-EEG monitoring, the clinical myoclonic status and the electrographic ictal discharges resolved within 10 minutes after the infusion was initiated. The patient tolerated the treatment well without any reported side effects. This case suggests that levetiracetam may be a safe, effective, and well tolerated intravenous drug in patients with metabolic myoclonic status epilepticus such as Gaucher disease.

Key words: Gaucher disease, myoclonic status epilepticus, progressive myoclonus epilepsy, levetiracetam, myoclonic seizures, EEG

Gaucher disease is an autosomal recessive lysosomal storage disease due to insufficient glucocerebrosidase activity, which results in failure of degradation of glucocerebroside into glucose and ceramide. Gaucher disease can be divided into three types, distinguished by the absence (type 1) or presence and severity (type 2 and 3) of neurological symptoms. Type 2 disease is characterised by a rapidly progressive neurodegenerative disorder resulting in death by two to three years of age. Type 3 disease is characterised by a slower neurological deterioration. Patients with type 2 or

type 3 disease may develop epileptic seizures in the context of a progressive myoclonic epilepsy showing electrographic abnormalities with multifocal sharp waves maximum over the posterior head regions and generalised spike and wave discharges that are activated by photic stimulation with photomyogenic or photo-paroxysmal response (Brady *et al.*, 1965; Nishimura *et al.*, 1980; Frei and Schiffmann, 2002). Phenytoin has been reported as a successful antiepileptic treatment for status epilepticus in one patient with progressive myoclonic epilepsy and Gaucher disease

Correspondence:

Elia M Pestana Knight
Department of Pediatrics, CWRU,
Division of Pediatric Epilepsy,
Rainbow Babies and Children's Hospital,
11100 Euclid Ave, RBC 740D,
mail stop MS 6009, Cleveland, Ohio,
44106, USA
<elia.pestana-knight@uhhospitals.org>

(Miyahara *et al.*, 2009). As there are few reports of the acute management of myoclonic status in Gaucher disease, we report our experience with a case of rapid clinical and EEG response to intravenous levetiracetam in a patient with myoclonic status epilepticus under continuous video-EEG monitoring.

Case study

A 14-year-old male with type 1 Gaucher disease was admitted to the paediatric epilepsy unit because of concerns for new onset seizures. A few weeks prior to hospitalisation, he began falling from his bed at night. It was difficult to arouse him following the falls and he had no recollection of the events. There was no clear history of a witnessed convulsion. On interview, he provided information about daily myoclonic jerks that had been ongoing for almost a year and had become almost continuous in the last few weeks. There was also a history of a worsening of mood with crying, poor appetite, and a withdrawn affect for the last two weeks even though his depressive symptoms had been under control for over a year with daily fluoxetine at 20 mg. He was on several other medications: fexofenadine, fluticasone propionate, levalbuterol, and enzyme replacement therapy (cerezyme). On admission, he was uncooperative for interview and physical examination. Affect was withdrawn and flat. He cried easily. He was unwilling to answer any questions to his mother or any member of the team. His mood was inappropriate. He was angry. He refused to eat. He was awake and oriented. Cranial nerves II-XII were intact. Muscle strength, tone, and bulk were full. He had diffuse hyperreflexia with clonus at the knees. Sensation was intact. He exhibited no cerebellar signs.

He was diagnosed with Gaucher disease at the age of seven years. He presented with a long-standing history of recurrent pneumonias, bone pain, thrombocytopenia, and hepato-splenomegaly since infancy, requiring multiple hospitalisations. He has been receiving enzyme replacement therapy every other week since seven years of age. Medical history included eczema, multiple food allergies, asthma, pulmonary hypertension, sleep apnoea, and depression.

Video-EEG recording documented myoclonic status epilepticus. The EEG recording showed a 7 to 8-Hz, poorly sustained, posterior background rhythm and frequent interictal and ictal generalised polyspike and wave discharges with amplitude between 100 and 200 μ V and duration of one to six seconds (*figure 1*). The average frequency of the discharges was three every 15 seconds. He received a single loading dose of intravenous levetiracetam, at 20 mg/kg. There was a dramatic resolution of the myoclonic status 10 minutes

after the infusion was started. Signs of electrographic improvement were: a) a progressive decrement in duration of the generalised epileptiform discharges to less than one second; b) fragmentation of the generalised epileptiform discharges into independent multifocal sharp waves maximum over the central (C3, C4) and posterior head regions (O1, O2, Pz, P8, P7); and c) decreased frequency of the generalised polyspike and wave discharges (*figure 1*) to one every 10 minutes, around one hour after the infusion. The frequency of the remaining multifocal sharp waves over central and posterior head regions was one every 15 to 30 seconds (*figure 2*).

Clinically, in addition to the resolution of the myoclonus, there was a significant mood improvement. He was more cooperative and very talkative. He sat in bed, requested food, and asked questions regarding epilepsy and his quality of life. He was discharged to go home the next day with instructions to continue levetiracetam, 500 mg orally twice daily.

Discussion

We have documented the first patient with Gaucher disease whose myoclonic status epilepticus had a dramatic response, both clinically and electroencephalographically, to treatment with levetiracetam. Based on the clinical history, the patient had myoclonic seizures for almost one year, in addition to nocturnal events that resembled generalised tonic-clonic seizures. These seizures and events were not previously evaluated. The patient was never prescribed any antiepileptic medications.

His interictal epileptiform abnormalities were similar to the previous abnormalities described for Gaucher disease, including multifocal sharp waves over the posterior head regions and generalised spike and wave discharges, in addition to a photo-convulsive response with bilateral myoclonic jerks (Nishimura *et al.*, 1980). In Gaucher disease, the enzyme deficiency leads to accumulation of glucocerebroside within the macrophages, producing Gaucher cells. In patients with Gaucher disease type 1 and 2, Gaucher cells, neuronal degeneration, cell loss, and astrocytosis are found in the cerebral cortex (especially in the occipital region) and cerebellum, based on neuropathological studies. These abnormalities might give rise to an alteration of neuronal function and a defect in cortical inhibition, as well as an increased sensibility to glutamate (increased excitability), required to produce a cortical myoclonus (Frei and Schiffmann, 2002).

In Gaucher disease, only response to phenytoin has been reported in a 16-year-old patient with myoclonic status epilepticus (Miyahara *et al.*, 2009). Phenytoin was not used in our patient because of potential

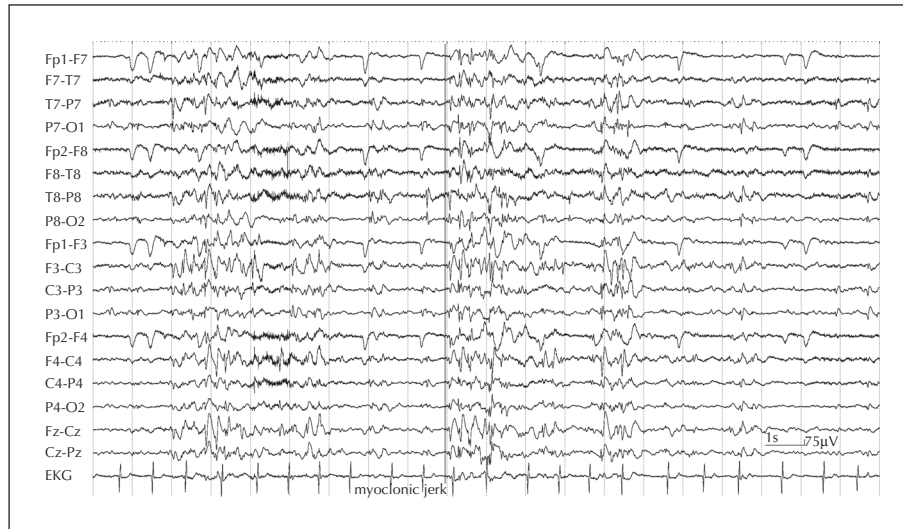

Figure 1. EEG during the myoclonic status epilepticus (before the administration of levetiracetam). Frequent myoclonic seizures correlated with a generalised and irregular polyspike pattern.

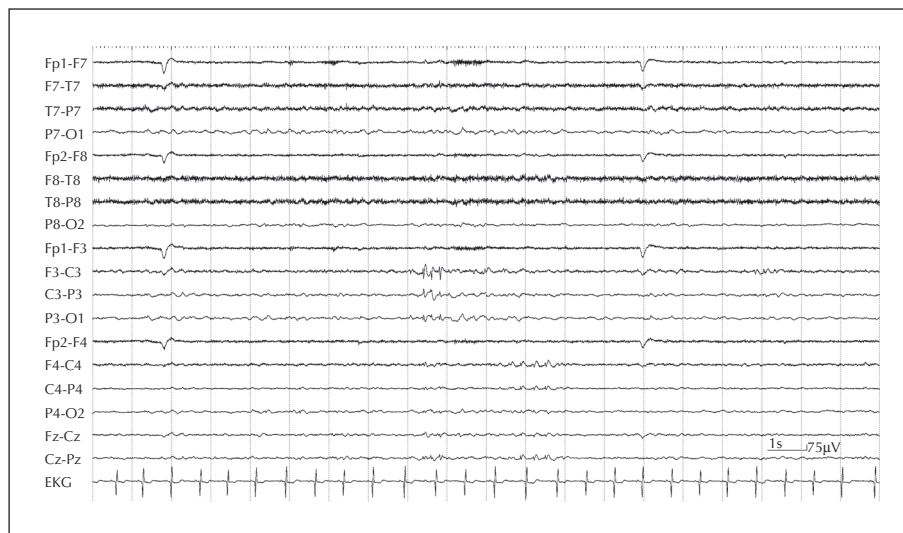


Figure 2. EEG one hour after the levetiracetam infusion.

moderate interaction with fluoxetine. Although phenytoin has been used for the treatment of myoclonic status epilepticus, some authors suggest that phenytoin should be avoided for the treatment of progressive myoclonic disease (Kälviäinen *et al.*, 2008). Levetiracetam has been found to have an anti-myoclonic effect and is useful for the control of progressive myoclonic epilepsy produced by other diseases such as post-hypoxic and post-encephalitic myoclonus, Uverricht-Lundborg disease, and myoclonic epilepsy with ragged red fibres (Mancuso *et al.*, 2006). In addition to decreased myoclonus, there was a significant improvement of the quality of life without relevant side effects (Genton and Gelisse, 2000; Papacostas *et al.*, 2007).

Evidence suggests that levetiracetam reduces epileptiform neuronal bursting induced by GABA-A antagonists, bicuculline, and the excitatory glutamate receptor, N-methyl D-aspartate. This indicates that levetiracetam is active in conditions when normal neuronal inhibition is decreased or excessive excitation occurs, which may be the case for the cortical myoclonus produced in Gaucher disease type 2 and 3 (Hovinga, 2001).

Levetiracetam has been shown to effectively control focal and generalised epilepsy in the paediatric population as monotherapy and as add-on therapy (Vigevano, 2005; Glauser *et al.*, 2006). It has favourable pharmacokinetic characteristics such as good bio-availability, insignificant protein binding, low drug

interactions, and is not affected by hepatic metabolism and demonstrates rapid achievement of steady-state concentrations (Hovinga, 2001). Since the introduction of the intravenous formulation, multiple case reports and case series show good seizure control after intravenous levetiracetam infusion in children with status epilepticus (Alehan et al., 2008; Goraya et al., 2008; Abend et al., 2009). In our case, even though the levetiracetam peak occurs one hour after the infusion, we observed clinical and EEG improvement 10 minutes after the intravenous infusion was initiated. The frequency and amplitude of the epileptiform discharges decreased significantly. The first EEG change after the infusion of levetiracetam was fragmentation of the generalised discharges. It was at this point that the myoclonic seizures stopped. One hour after the infusion was started, the EEG showed infrequent multifocal sharp waves over the posterior and central head regions and generalised intermittent slowing. Clinically, after the resolution of the myoclonus, the patient's mood and behaviour improved significantly. Levetiracetam was well tolerated without any side effects.

In the currently available medical literature, there are no previous reports of treatment with levetiracetam in patients with myoclonic status epilepticus due to Gaucher disease. Even though our patient did not show any sign of liver dysfunction, in Gaucher disease glucocerebroside accumulates in the liver resulting in hepatic enlargement and dysfunction (Brady et al., 1965). In these cases, levetiracetam would be particularly useful as it is not metabolised in the liver. Also, the lack of interactions between levetiracetam and other drugs makes this antiepileptic medication a very attractive choice for the treatment of children with multiple medical conditions and polytherapy, as in the case for patients with Gaucher disease.

Conclusions

Levetiracetam, in addition to being a good therapeutic option for patients with progressive myoclonic epilepsies, is a safe, effective, and well tolerated drug in patients with myoclonus status epilepticus in the setting of Gaucher disease. □

Acknowledgements.

We thank Mark Johnson, Ph.D. and Sheryl Nehamkin, registered electroencephalography and evoked potential technician (R. EEG/EPT) for their help with the illustrations of this manuscript.

Disclosures.

None of the authors has any conflict of interest to disclose. This work was not supported by a grant and was not previously presented at any meeting

References

- Abend NS, Monk HM, Licht DJ, Dlugos DJ. Intravenous levetiracetam in critically ill children with status epilepticus or acute repetitive seizures. *Pediatr Crit Care Med* 2009; 10: 505-10.
- Alehan F, Ozcay F, Haberal M. The use of levetiracetam in a child with nonconvulsive status epilepticus. *J Child Neurol* 2008; 23: 331-3.
- Brady RO, Kanfer JN, Shapiro D. Metabolism of glucocerebrosides II. Evidence of an enzymatic deficiency in Gaucher disease. *Biochem Biophys Res Commun* 1965; 18: 221-5.
- Frei KP, Schiffmann R. Myoclonus in Gaucher Disease. *Adv Neurol* 2002; 89: 41-8.
- Genton P, Gelisse P. Antimyoclonic effect of levetiracetam. *Epileptic Disord* 2000; 2: 209-12.
- Glauser TA, Ayala R, Elterman RD, et al. Study group double blind placebo-controlled trial of adjunctive levetiracetam in pediatric partial seizures. *Neurology* 2006; 66: 1654-60.
- Goraya JS, Khurana DS, Valencia I, et al. Intravenous levetiracetam in children with epilepsy. *Pediatr Neurol* 2008; 38: 177-80.
- Hovinga CA. Levetiracetam: a novel antiepileptic drug. *Pharmacotherapy* 2001; 21: 1375-88.
- Kälviäinen R, Khyuppenen J, Koskenkorva P, Eriksson K, Vanninen R, Mervaala E. Clinical picture of EPM1-Unverricht-Lundborg disease. *Epilepsia* 2008; 49: 549-56.
- Mancuso M, Galli R, Pizzanelli C, Filosto M, Siciliano G, Murri L. Antimyoclonic effect of levetiracetam in MERRF syndrome. *J Neurol Sci* 2006; 243: 97-9.
- Miyahara A, Saito Y, Sugai K, et al. Reassessment of phenytoin for treatment of late stage progressive myoclonus epilepsy complicated with status epilepticus. *Epilepsy Res* 2009; 84: 201-9.
- Nishimura R, Omos-Lau N, Ajmone-Marsan C, Barranger JA. Electroencephalographic findings in Gaucher disease. *Neurology* 1980; 30: 152-9.
- Papacostas S, Kkolou E, Papathanasiou E. Levetiracetam in three cases of progressive myoclonus epilepsy. *Pharm World Sci* 2007; 29: 164-6.
- Vigevano F. Levetiracetam in pediatrics. *J Child Neurol* 2005; 20: 87-93.