

# Focal epilepsy due to *de novo* SCN1A mutation

Domitille Laur<sup>1,2</sup>, Blandine Dozières-Puyravel<sup>1</sup>, Adina Iléa<sup>1</sup>, Caroline Nava<sup>3</sup>, Catherine Delanoë<sup>4</sup>, Hala Nasser<sup>4</sup>, Eric Le Guern<sup>3</sup>, Stéphane Auvin<sup>1,2</sup>

<sup>1</sup>Service de Neurologie Pédiatrique, Hôpital Robert Debré, Paris, France

<sup>2</sup>Université de Paris, INSERM U1141, F-75019, Paris, France

<sup>3</sup>Service de biologie moléculaire, Hôpital de la Pitié-Salpêtrière, Paris, France

<sup>4</sup>Service des explorations fonctionnelles, Hôpital Robert Debré, Paris, France

Received June 20, 2020;  
Accepted March 15, 2021

## ABSTRACT

**Objective.** Our aim was to identify patients with *SCN1A*-related epilepsy with a phenotype of pure focal epilepsy.

**Methods.** We conducted a retrospective study and a systematic review in Pubmed to identify patients with focal epilepsy associated with *SCN1A* pathogenic variants.

**Results.** We found three patients among 1,191 in our rare epilepsy database in 2017. The literature search from January 2000 to September 2019 led to identification of four patients with limited data. Our three patients had a common phenotype with focal-onset seizures as the only seizure type. All patients showed normal psychomotor development in the first years of life, and no intellectual disability although they displayed some cognitive or behavioural problems. Fever or hyperthermia were triggers in all three patients. In addition, all had a history of brief recurrent febrile seizures in their first year, followed by a phenotype of pharmacoresistant focal epilepsy with normal brain imaging. Two of them were initially investigated for epilepsy surgery. Seizure precipitation by fever has also been reported in previously published patients.

**Significance.** Focal epilepsy associated with *SCN1A* gene mutation should be recognized in patients with suggestive features, in particular among surgical candidates.

**Key words:** epilepsy; focal-onset seizure; gene; *SCN1A*

Voltage-gated sodium channels play an important role in action potentials in neurons allowing normal neuronal firing. Disruption of genes encoding voltage sodium channels cause a variety of epilepsy syndromes in humans. The *SCN1A* gene, encoding the alpha1 subunit of neuronal sodium channels (Nav1.1), represents the most clinically relevant among all the epilepsy genes currently known [1]. *SCN1A* mutations have been linked to a large variety of epilepsy syndromes with overlapping clinical characteristics with divergent clinical severity, with a spectrum of

epilepsy phenotypes that ranges from mild to severe [1-4].

The majority of *SCN1A* mutations are associated with Dravet syndrome (DS), and 70 to 80% of DS cases carry *de novo* *SCN1A* mutations [1,5]. However, a significant number of *SCN1A* mutations has also been reported in less severe syndromes, including generalized epilepsy with febrile seizure plus (GEFS+). More recently, the spectrum of the *SCN1A* phenotypes has expanded with the description of infantile epileptic encephalopathies including severe infantile multifocal epilepsy [6,7]. This

## Correspondence:

Stéphane Auvin  
Service de Neurologie Pédiatrique  
CHU Hôpital Robert Debré,  
48, boulevard Sérurier,  
75935 Paris Cedex 19, France  
<stephane.auvin@aphp.fr>

severe phenotype is characterized by early-onset multifocal seizures and later cognitive decline. Epilepsy with only focal-onset seizures (FOS), related to *SCN1A* mutations, has also been described, mainly in GEFS+ families with individuals exhibiting Panayiotopoulos syndrome. More rarely, patients with focal epilepsy and a *SCN1A* pathogenic variant have been reported without any family history of GEFS+ [8, 9]. Most *SCN1A*-related epilepsy phenotypes exhibit generalized seizures. The aim of this retrospective study was to describe the electroclinical phenotype of patients with *SCN1A*-related focal epilepsy.

## Patients and methods

We conducted a retrospective study in the Department of Paediatric Neurology at Robert Debré University Hospital, Paris, France. We used two databases (rare epilepsy database of the paediatric epilepsy team and neurophysiology team) to identify patients with both *SCN1A* variants and epilepsy with FOS only.

The inclusion criterion was patients with a pathogenic variant in the *SCN1A* gene and FOS as the only seizure type. The exclusion criteria were: any possible other aetiology for FOS, an electroclinical diagnosis of DS, or any spontaneous generalized-onset seizure in the clinical history.

We considered the following data for each patient: familial and personal history; psychomotor development at both the age at onset and during follow-up; epilepsy features upon neurological examination (age at onset, seizure type, response to antiepileptic drugs); ictal and interictal EEG findings during wakefulness and sleep; and brain magnetic resonance imaging (3T MRI).

In addition to our case study, we also analysed all published cases of focal epilepsy associated with *SCN1A* pathogenic variants based on a search on the Pubmed database. The search was performed with the key words "*SCN1A*" and "epilepsy" from January 2000 to September 2019. We reviewed all published cases with sufficient clinical data to investigate epilepsy with FOS only, associated with *SCN1A* mutation and without a family history of GEFS+.

## Results

### Patients

We found three patients with focal epilepsy associated with a *SCN1A* pathogenic variant, who were identified among our cohort of 1,191 rare epilepsy patients in

2017 (patient seen in our centre with Orpha codes). In 2017, we had 43 patients with pathogenic *SCN1A* variants in our database (32 DS [two inherited mutations], five GEFS + [one inherited mutation] and six others including the three patients reported here).

The main characteristics of the patients are listed in *table 1* (detailed histories are provided in the *supplementary material*). The patients were two males and one female with a *de novo* *SCN1A* pathogenic variant. Two of them had a family history of febrile seizures (Patient 2 and 3).

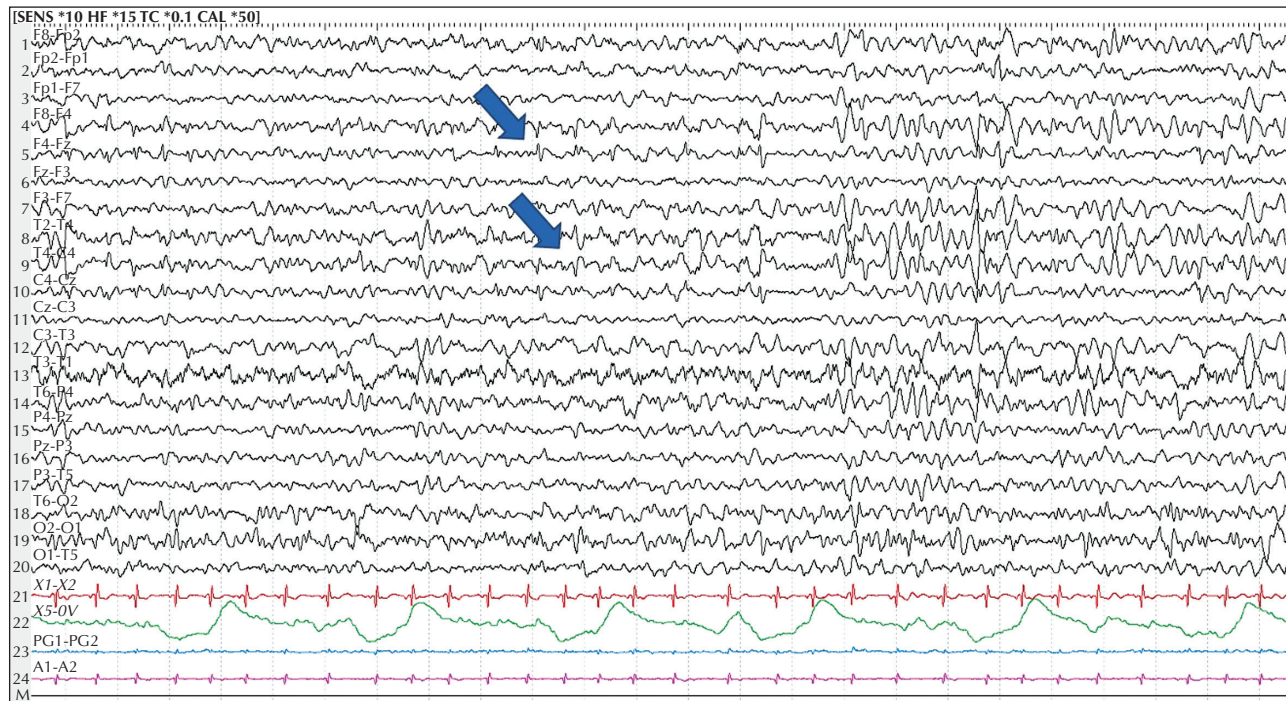
All patients had initial seizures triggered by fever and a first brief seizure before the age of one year, described as a simple febrile seizure. None of them experienced status epilepticus. Afebrile focal seizures started between the three and four years. In each patient, the FOS were consistent over time. Evolution from focal to bilateral tonic-clonic involvement was reported in all patients. None of the patients experienced generalized-onset seizures except for Patient 1, who experienced myoclonic seizures when he was treated with lamotrigine. The seizure frequency was variable but none of the patients were free of seizures for more than one year. All had seizure triggers, such as hyperthermia due to physical exercise or a hot bath, or fever.

Of the antiseizure medication received by the three patients, seizures were aggravated by lamotrigine in one patient and no aggravation was seen with the use of carbamazepine or oxcarbazepine.

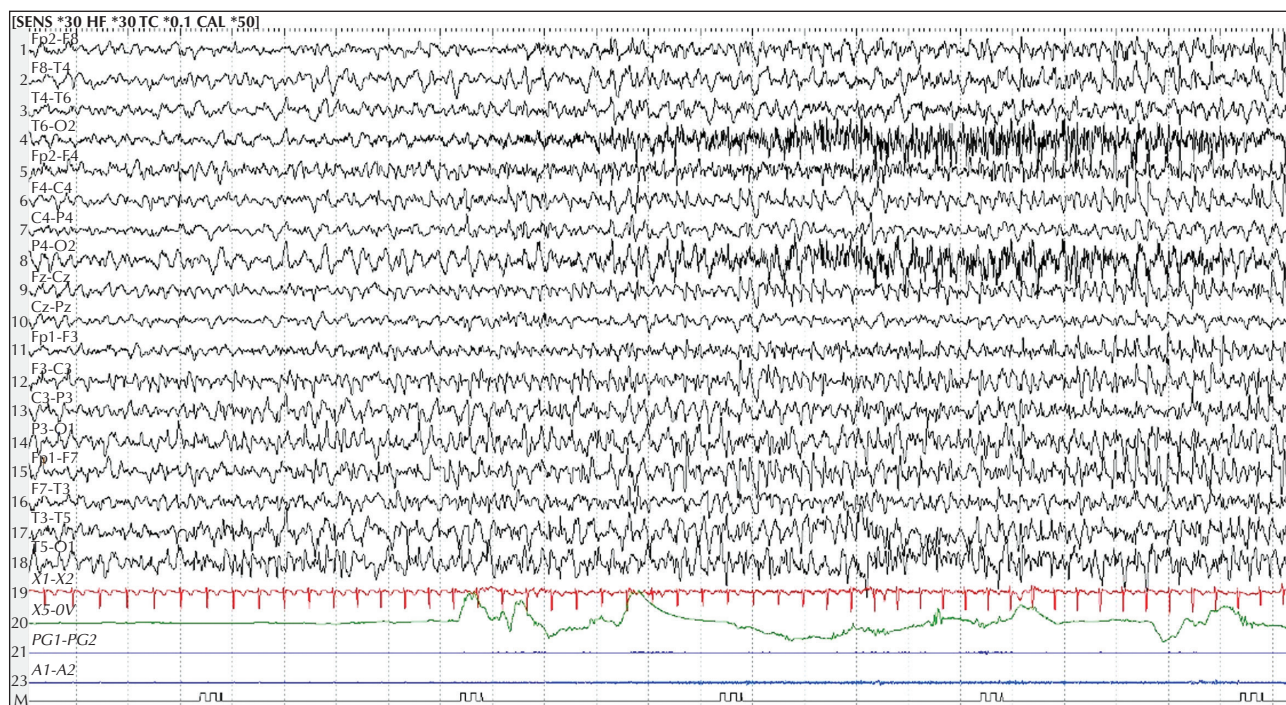
The first EEG recordings were normal in all patients. Later EEG recordings showed only focal interictal abnormalities in all patients (*figure 1*). For Patient 1 and Patient 3, the first abnormalities were seen at the age of three years. For Patient 2, abnormalities were seen at five years old. Generalized epileptiform activity was never observed in our patients. For all patients, repeat brain MRI was normal. Patients 2 and 3 underwent a presurgical evaluation. The seizure onset zone was identified in the right frontocentral region for Patient 2 and in the left frontotemporal area for Patient 3 (*figure 2*). Both patients had an FDG-PET scan which was normal. Patient 1 was never investigated for epilepsy surgery treatment. None of the patients had surgery.

Psychomotor development was deemed normal in the first years of life. All patients displayed a cognitive profile consistent with ADHD, and normal or subnormal intellectual abilities. Cognitive evaluation using the Wechsler Intelligence Scale for Children showed heterogeneous performance, with normal Verbal Comprehension Index and Fluid Reasoning Index for Patient 1 and subnormal verbal comprehension index for Patient 2, with lower scores in Working Memory Index and Processing Speed Index for both. Patient 1 presented with a specific language impairment with





■ **Figure 1.** Interictal EEG recording of Patient 2 with right frontocentral spikes (20 sec/page) during presurgical evaluation.



■ **Figure 2.** Ictal EEG recording of Patient 3 with a seizure arising from the left temporal area (20 sec/page) showing the start of the seizure, lasting 20-30 seconds, with gaze fixation and associated impairment of awareness, and motor arrest followed by version of the head and eyes to the right, associated with a rhythmic discharge of temporal spikes.

stammering at the age of six and dyslexia associated with school difficulties at the age of eight. Patient 2 was oriented to a special needs class at the age of seven. No quantitative evaluation was performed for Patient 3 as he did not experience any learning difficulty with the normal school curriculum.

*SCN1A* gene analysis was performed in all patients and their parents in view of the pharmacoresistance and febrile-induced seizures. The *de novo* pathogenic variants cause truncations in Patient 1 and 3 and are missense in Patient 2 based on 5/5 algorithms Align-GVGD, SIFT, MutationTaster, PolyPhen-2 HumDiv and HumVar (table 1).

### Review of the literature

A total of 938 articles were identified, of which 34 referred to published cases of FOS only associated with *SCN1A* mutation. After exclusion of familial epilepsy or variants reported in the data base without pathogenic significance, four patients remained based on our literature review; for one patient, the data were limited. The clinical details of three of the patients are listed in table 2. The epilepsy onset age ranged from 4.5 to 34 months. Fever was a trigger of the initial seizure in two of four patients and remained a trigger during the disease course in all patients. FOS was the only seizure type. Most of the time, interictal EEG recordings were normal. Limited data were available on antiseizure medication, and most patients were pharmacoresistant.

### Discussion

In this study, we report three patients with focal epilepsy related to *SCN1A* gene pathogenic variants. The phenotype with FOS only represented 7% of all our *SCN1A* epilepsy patients. Our three patients exhibited a common phenotype with FOS as the only seizure type, without intellectual disability. In all patients, seizures were triggered by fever or hyperthermia. All had a history of brief recurrent febrile seizures beginning in their first year, followed by a phenotype of pharmacoresistant focal seizures and normal brain imaging. Except for the occurrence of myoclonic seizures with lamotrigine in one patient, the use of sodium channel blockers did not worsen seizures, and seemed to improve seizures in Patient 2. The literature review revealed only three patients over a 20-year-period suggesting the rarity of FOS concomitant with *SCN1A* mutation (table 2).

Mutations in *SCN1A* are responsible for various phenotypes, from DS to other severe encephalopathies associated with epilepsy, such as intractable childhood

epilepsy with generalised tonic-clonic seizures and severe infantile multifocal epilepsy. The *SCN1A* gene is also associated with less severe phenotypes such as febrile seizures and GEFS+. Our study is the first detailed report of *SCN1A*-related epilepsy with FOS only. Our review of the literature highlights the scarcity of previous patients. Indeed, FOS are common in *SCN1A*-related syndromes, but often associated with other seizure types.

The pathogenic variant of Patient 1 was reported in a case of severe infantile multifocal epilepsy with developmental delay by Harkin *et al.* [6] and in a case of DS by Rodda *et al.* [10]. The pathogenic variant of Patient 2 was reported in a case of early-onset encephalopathy starting with focal motor status epilepticus by Tang *et al.* [11]. The pathogenic variant of Patient 3 has been described in patients with DS by Catarino *et al.* [12] and de Lange *et al.* [13]. The fact that a single mutation in a GEFS+ family may be associated with various different phenotypes is well established. This is also illustrated here with the reports of various electro-clinical phenotypes for the same pathogenic variants found in our patients. The underlying mechanisms that account for the different phenotypes associated with a single mutation are not fully understood. Experimental studies suggest that the genetic background could strongly influence the consequences of gene dysfunction [14]. In our patients, we wonder whether the treatment contributed to their true phenotype, as none of them received treatment usually used for patients with DS. We used sodium channel blockers before *SCN1A* pathogenic variants were identified, and these ASMs should not be advised in patients with DS.

The mechanisms leading to a phenotype with FOS only are unknown. Some hypotheses may be discussed. First, the *SCN1A* gene mutation could arise in a patient who already has an underlying cause of epilepsy with FOS. The gene mutation would act as a double hit, leading to some features related to *SCN1A* dysfunction, such as fever-induced seizure and pharmacoresistance. The absence of investigation using gene panel analysis or exome analysis is a limitation in our study. Second, mosaicism affecting a small part of the brain with *SCN1A* mutation may explain the phenotype. Third, *SCN1A* mutation might be responsible for subtle malformation of cortical development. Indeed, evidence of focal cortical dysplasia has been described in a few patients with *SCN1A* mutations and a DS-like phenotype [15-17]. Neuropathological studies of brains from patients carrying *SCN1A* mutations are very rare, which makes it difficult to rule out any subtle developmental brain abnormality. The role of ion channel disorders in the pathogenesis of brain migration abnormalities is possible as suggested by experimental studies [18]. Finally, we may also suggest

▼ **Table 1.** Summary of the electroclinical features and outcome of our patients with *SCN1A*-related FOS epilepsy.

Pt	Gender	Family history	Early development	First seizure type / Age at onset	Seizure type	Trigger	EEG (ictal and interictal)	MRI	Age at screening for SCN1A	SCN1A gene analysis	AEDs	Age at last follow-up visit	Outcome		
1	M	Brother: sudden infant death syndrome	Speech delay	FS / 9 Mo	Focal FS followed by afebrile FOS after 3Y	Fever, hyperthermia	NA	Interictal: focal abnormalities (3Y) Photic stimulation and hyperpnea: inactive	Normal	15 Y	NM_001165963.1:c.1724del / p.Phe575Serfs*48	Truncation / De novo	CBZ, CLB LEV, LCS, PER, TPM, VPA, ZNS	17Y LEV+ZNS	Focal seizure (1-2/year) Normal intellectual ability, ADHD, school adaptation
2	F	FS in a cousin	Speech delay	FS / 9 Mo	Focal FS followed by afebrile FOS after 3Y; sometimes evolution from focal to bilateral tonic-clonic	Hyperthermia, fever, physical activity	Right fronto-central, secondary generalised	Interictal: focal abnormalities (5Y) Photic stimulation and hyperpnea: inactive	Normal	6 Y	NM_001165963.1:c.5309T>A / p.Ile1770Asn	Missense / de novo	CBZ, LEV, LTC, TPM, VPA, ZNS	10Y LTG+CBZ	Focal seizure (1-2/year) Borderline intellectual ability, ADHD, Special needs school
3	M	1 FS maternal uncle, paternal uncle had epilepsy	Normal	FS / 7 Mo	Focal FS followed by afebrile FOS after 2Y; rare evolution from focal to bilateral tonic-clonic	Hyperthermia, fever, physical activity, emotions	Left fronto-temporal secondary generalised	Interictal: focal abnormalities (3Y) Photic stimulation and hyperpnea: inactive	Normal	5 Y	NM_001165963.1:c.992del / p.Leu331* / nonsense truncation	Truncation / de novo	CBZ, CLB, LEV, LCS, LTC, VPA, ZNS	9Y ZNS+VPA+CLB	Focal seizure (1-2/year) Normal intellectual ability, ADHD, school adaptation

CBZ: carbamazepine; CLB: Clobazam; F: female; FOS: focal-onset seizure; FS: febrile seizure; LCS: lacosamide; LEV: levetiracetam; LTC: lamotrigine; M: male; Mo: Months; NA: not available; TPM: topiramate; VPA: valproate; Y: years; ZNS: zonisamide



▼ Table 2. Summary of the clinical details and outcome of the published patients with SCN7A-related FOS epilepsy.

Reference	Sex	Family history	Early development / Neurological sign	Age at onset (Mo)	First seizure type	Seizure type during follow-up	Myoclonic seizure	Trigger	EEG		MRI	Epilepsy syndrome	SCN7A mutation	AEDs trialled	Age at last follow-up (years)	Seizure outcome	Cognitive outcome
									Ictal	Interictal							
Okumura et al., 2007 [19]	F	No	Delayed/ ataxia	5	Prolonged FS to BTCsz with fever (20min)	GOsz until 17m. Since 32m: FOS (autonomic signs). GOsz rare. (Brief w/ fever and prolonged seizures w/o fever)	No	Seizures initially only w/ fever	NA	Spikes on the left frontocentral area during sleep at 18m. Other EEGs normal	Normal	Epilepsy with FOS	c.5311A>T; T1771F Missense mutation De novo	Unknown	3.5	NA	Mild cognitive impairment
Skjelt et al., 2015 [9]	M	Yes	Normal / -	12	GTCSz fever	FOS	NA	Seizures initially only w/ fever	1 Left frontal onset, 1 unknown	Slow, disorganized background	Normal / area of left frontal encephalomalacia due to trauma	Epilepsy with FOS	c.5018T>G; p.J1673T Presumed pathogenic Unknown	8 failed medication trials. Surgery at 17y of lesionectomy	19	NA	Borderline IQ, ADHD
Harkin et al., 2007 [6]	NA	NA	Unknown / -	18	NA	FOS, FOS to BTCsz, SE	No	NA	NA	NA	Normal	Epilepsy with FOS	R1657H De novo	NA	5	Died at 5 years (complications of status epilepticus)	Normal

F: female; M: male; FS: febrile seizure; BTCsz: bilateral tonic-clonic seizure; GTCSz: generalized tonic-clonic seizure; GOs: generalized onset seizure; FOS: focal-onset seizure; SE: status epilepticus; NA: not available.

that a milder phenotype may be due to mosaicism involving only a small number of cells harbouring a pathogenic variant.

Our report illustrates that *de novo* SCN1A gene pathogenic variants may be responsible for pharmacoresistant epilepsy with FOS only, without intellectual disability, but with some cognitive or behavioural problems, as expected based on previous genetic findings. Two of our patients underwent presurgical evaluation. The absence of a clear hypothesis for the epileptic focus and the history of triggered seizures led to the genetic analysis. Although the outcome of epilepsy surgery for patients with a SCN1A mutation is unlikely to be beneficial [9,15], we strongly suggest that SCN1A is screened in patients with FOS, particularly surgical candidates, with a history of fever, hyperthermia or emotion induced-seizures or when the epilepsy onset is characterized by febrile seizures starting early in life. In the presurgical work-up, genetic analysis could be discussed in cases of atypical features, as seen in our patients. ■

#### Supplementary material.

Supplementary material accompanying the manuscript are available at [www.epilepticdisorders.com](http://www.epilepticdisorders.com).

## References

- Mulley JC, Scheffer IE, Petrou S, Dibbens LM, Berkovic SF, Harkin LA. SCN1A mutations and epilepsy. *Human Mutat* 2005; 25: 535-42.
- Claes L, Del-Favero J, Ceulemans B, Lagae L, Van Broeckhoven C, De Jonghe P. *De novo* mutations in the sodium-channel gene SCN1A cause severe myoclonic epilepsy of infancy. *J Hum Genet* 2001; 68: 1327-32.
- Escayg A, MacDonald BT, Meisler MH, Baulac S, Huberfeld G, An-Gourfinkel I, et al. Mutations of SCN1A, encoding a neuronal sodium channel, in two families with GEFS+2. *Nat Gene*. 2000; 24: 343-5.
- Wallace RH, Scheffer IE, Parasivam G, Barnett S, Wallace GB, Sutherland GR, et al. Generalised epilepsy with febrile seizures plus: mutation of the sodium channel subunit SCN1B. *Neurology* 2002; 58: 1426-9.
- Depienne C, Trouillard O, Saint-Martin C, Gourfinkel-An I, Bouteiller D, Carpentier W, et al. Spectrum of SCN1A gene mutations associated with Dravet syndrome: analysis of 333 patients. *J Med Genet* 2009; 46: 183-91.
- Harkin LA, McMahon JM, Iona X, Dibbens L, Pelekanos JT, Zuberi SM, et al. The spectrum of SCN1A-related infantile epileptic encephalopathies. *Brain* 2007; 130: 843-52.
- Carranza Rojo D, Hamiwka L, McMahon JM, Dibbens LM, Arsov T, Suls A, et al. *De novo* SCN1A mutations in migrating partial seizures of infancy. *Neurology* 2011; 77: 380-3.
- McDonald CL, Saneto RP, Carmant L, Sotero de Menezes MA. Focal seizures in patients with SCN1A mutations: response to treatment. *J Child Neurol* 2017; 32: 170-6.
- Skjei KL, Church EW, Harding BN, Santi M, Holland-Bouley KD, Clancy RR, et al. Clinical and histopathological outcomes in patients with SCN1A mutations undergoing surgery for epilepsy. *J Neurosurg Pediatr* 2015; 16: 668-74.
- Rodda JM, Scheffer IE, McMahon JM, Berkovic SF, Graham HK. Progressive gait deterioration in adolescents with Dravet syndrome. *Arch Neurol* 2012; 69: 873-8.
- Tang S, Lin JP, Hughes E, Siddiqui A, Lim M, Lascelles K. Encephalopathy and SCN1A mutations. *Epilepsia* 2011; 52: e26-e30.
- Catarino CB, Liu JY, Liagkouras I, Gibbons VS, Labrum RW, Ellis R, et al. Dravet syndrome as epileptic encephalopathy: evidence from long-term course and neuropathology. *Brain* 2011; 134: 2982-3010.
- de Lange IM, Koudijs MJ, van 't Slot R, Gunning B, Sonsma ACM, van Gemert LJJM. Mosaicism of *de novo* pathogenic SCN1A variants in epilepsy is a frequent phenomenon that correlates with variable phenotypes. *Epilepsia* 2018; 59: 690-703.
- Mistry AM, Thompson CH, Miller AR, Vanoye CG, George AL Jr, Kearney JA. Strain- and age-dependent hippocampal neuron sodium currents correlate with epilepsy severity in Dravet syndrome mice. *Neurobiol Dis* 2014; 65: 1-11.
- Barba C, Parrini E, Coras R, Galuppi A, Craiu D, Kluger G, et al. Co-occurring malformations of cortical development and SCN1A gene mutations. *Epilepsia* 2014; 55: 1009-19.
- Le Gal F, Korff CM, Monso-Hinard C, Mund MT, Morris M, Malafosse A. A case of SUDEP in a patient with Dravet syndrome with SCN1A mutation. *Epilepsia* 2010; 51: 1915-8.
- Striano P, Mancardi MM, Biancheri R, Madia F, Gennaro E, Paravidino R, et al. Brain MRI findings in severe myoclonic epilepsy in infancy and genotype-phenotype correlations. *Epilepsia* 2007; 48: 1092-6.
- Bando Y, Hirano T, Tagawa Y. Dysfunction of KCNK potassium channels impairs neuronal migration in the developing mouse cerebral cortex. *Cereb Cortex* 2014; 24: 1017-29.
- Okumura A, Kurahashi H, Hirose S, Okawa N, Watanabe K. Focal epilepsy resulting from a *de novo* SCN1A mutation. *Neuropediatrics* 2007; 38: 253-6.