

# Convulsive syncope: a condition to be differentiated from epilepsy

Cigdem Ozkara<sup>1</sup>, Baris Metin<sup>1</sup>, Serdar Kucukoglu<sup>2</sup>

<sup>1</sup> Department of Neurology, Cerrahpasa Medical School

<sup>2</sup> Institute of Cardiology, University of Istanbul, Turkey

Received June 16, 2009; Accepted October 12, 2009

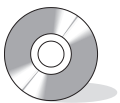**ABSTRACT** – The clinical presentation of epilepsy and syncope can be confusingly similar. We present a patient with reflex syncopal episodes that mimic seizures using video-EEG recordings. During the episodes, head/eye deviations, automatisms and dystonic movements, suggesting an epileptic seizure, were observed. The EEG revealed diffuse slow waves when the patient lost consciousness and complete cessation of the cerebral activity occurred when the dystonic movements started. On ECG recordings, bradycardia, followed by complete asystolia lasting for 40 seconds, was observed. We conclude that the differential diagnosis of epilepsy and syncope can be quite misleading and clinical features may not always be reliable. In cases where diagnosis is uncertain, circulatory and cardiac causes should always be kept in mind and video-EEG with simultaneous cardiac recordings are mandatory for accuracy of diagnosis. *[Published with video sequences]*

**Key words:** syncope, reflex seizure, cardiac arrhythmia, convulsive syncope

In clinical practice, the differential diagnosis between epilepsy and syncope is not always easy. Although the aetiologies of the two entities are completely different, their clinical presentation may be quite similar and even totally indistinguishable when based on clinical history taking. The term “convulsive syncope” was first used by Marcus Gerbezius (1658-1718) to describe a patient with “slow pulse, dizziness and slight epileptic attacks” (Acierno, 1994). This phenomenon was later described as a Stokes-Adams attack. In this report, we present a patient with unexplained episodes of loss of consciousness, elucidated only after video-EEG and cardiac evaluations.

## Case study

A 22-year-old young lady presented with episodes of loss of consciousness. The first episode occurred at the age of nine during blood drawing. The second episode was triggered by a sudden unexpected fall and subsequent episodes occurred as a reaction to a painful stimulus. The witnesses reported that the patient was staring without expression and irregular tonic postures and sometimes diffuse jerks occurred. The episodes were reported to last about 1-5 minutes and the patient always regained consciousness without confusion soon afterwards. The patient described a feeling of falling down



## Correspondence:

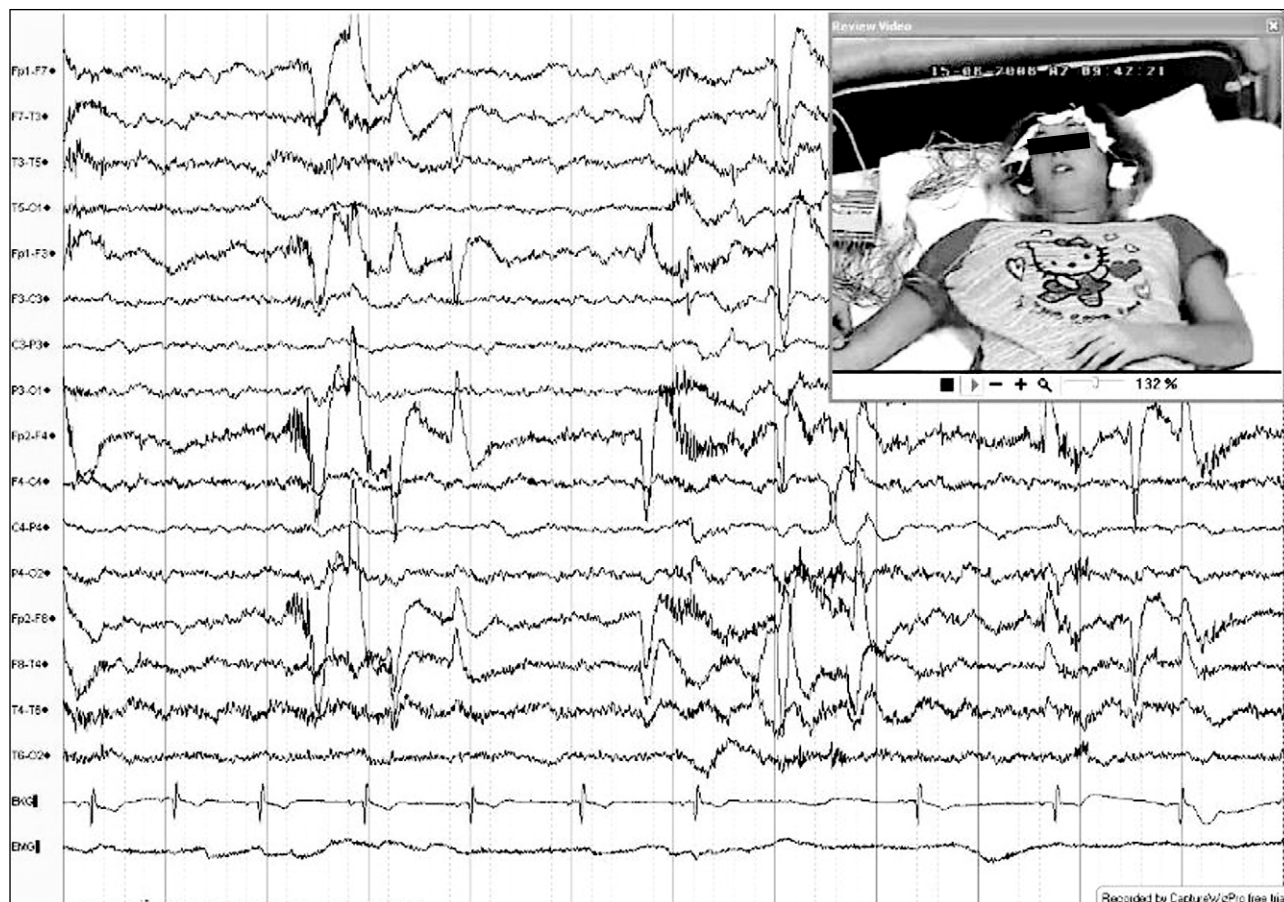B. Metin  
Cerrahpasa Tıp Fakültesi,  
Nöroloji ABD, 34098,  
Fatih, İstanbul, Turkey  
<drbarismetin@yahoo.com>

before the episodes. Her routine EEG and cranial MRI were normal. Medical history was not significant. Her father and uncle experienced some episodes of fainting in reaction to seeing blood, although the family history was otherwise normal. She was admitted to our video-EEG unit to draw blood from her for another medical condition. The recorded parameters were 16 channel EEG (standard international electrodes), one channel ECG, EMG and simultaneous video recordings. During the procedure, we withdrew blood from the right antecubital fossa. Soon after the blood withdrawal was complete, she reported that she felt dizzy and heart rate began to slow down (*figure 1*). About 20 seconds later, complete asystole ensued and she lost her consciousness, with an expressionless stare. At first, her head and eyes turned to the right side with brief automatisms on the left arm, followed by head and eye deviation to the opposite side with an asymmetric dystonic posture of the upper extremities (*figure 2*). Hyperventilation and profuse sweating were observed. These dystonic postures subsided after about 40 seconds as the heart rhythm reappeared. After a silent period of 10 seconds, generalized irregular clonic jerks of the body were observed for 15 seconds. She finally

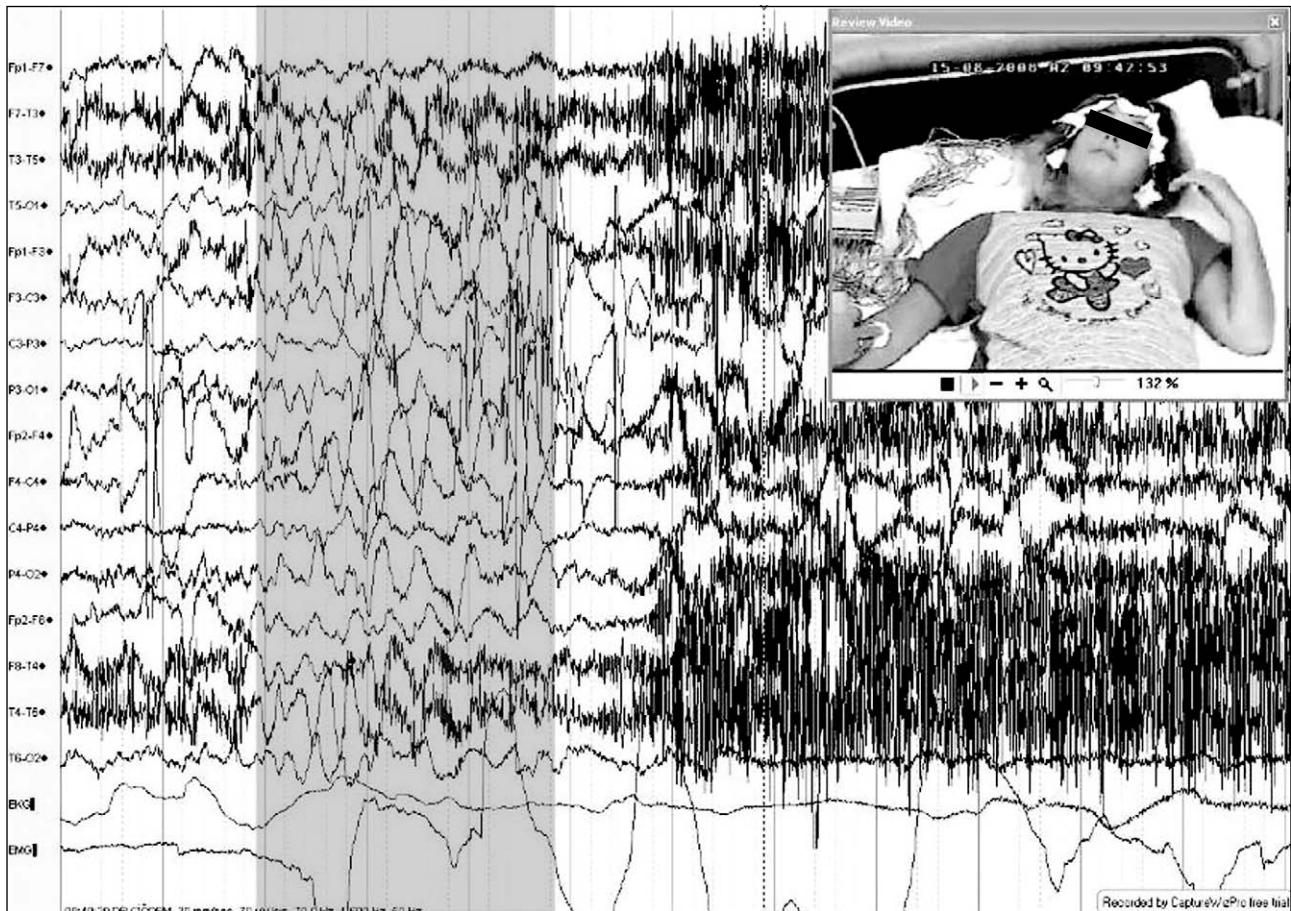
began to snore and regained consciousness after a brief state of confusion. As she recovered, she cried and reported that she was feeling poorly.

On EEG recordings, there was diffuse slowing when the heart rate began to slow down. When the patient lost her consciousness and heart beating stopped, diffuse generalized slow delta waves with high amplitude appeared, followed by complete suppression of cerebral activity. During 40 seconds of the asystolia period, head and eye deviation, brief automatisms and dystonic extremity movements were observed whereas the EEG was masked by muscle artefacts. After a silent period of 10 seconds (*figure 3*), body jerks started at the same time as diffuse high amplitude delta discharges on EEG. As these movements ceased, an irregular slow rhythm reappeared.

In the first part of the episode with bradycardia and asystolia, the clinical semiology was very much similar to an epileptic event with head/eye deviations, automatism and dystonic posture. In particular, the second phase of massive body jerks implied a convulsive episode, although this was induced by cerebral hypoxia with diffuse delta discharges without any epileptiform activity on EEG.



**Figure 1.** When the heart rate began to slow down, the patient warned that she was feeling dizzy.



**Figure 2.** Diffuse delta waves (grey) followed by cessation of brain activity, accompanied by head/eye deviations and automatisms.

The patient was subsequently evaluated by the cardiology department and was re-admitted to be evaluated for cardiac parameters. The same procedure that caused the episode was reproduced. During the blood withdrawal, sinus bradycardia was followed by complete sinus arrest. In addition, the blood pressure dropped markedly but no convulsive movements were seen. According to these findings, she was diagnosed with sinus arrest mediated by vasovagal mechanisms.

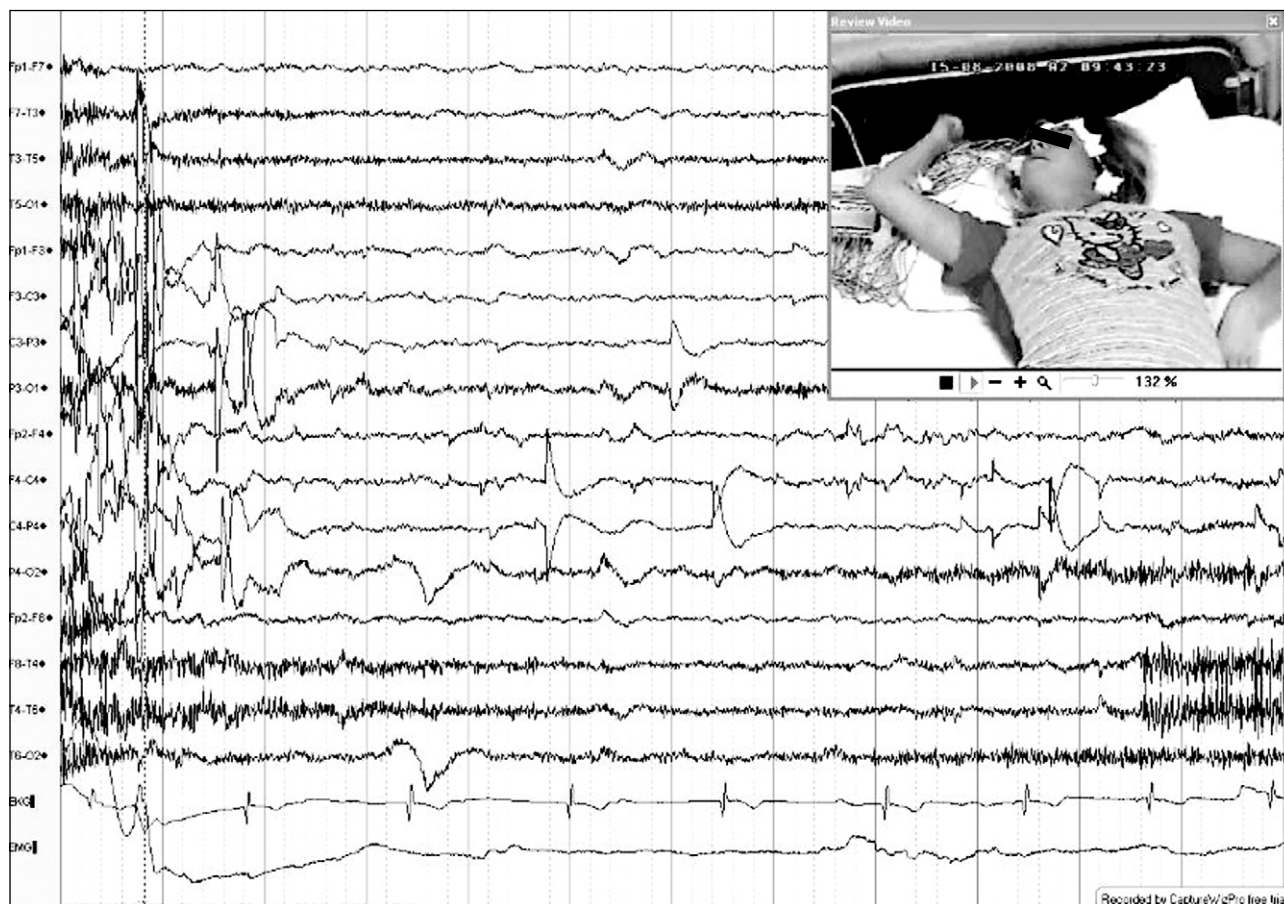
## Discussion

It is well known that cardiac diseases and syncope may strongly resemble seizures. The studies investigating the similarities between these conditions date back to the 1970s. It was reported that 20% of those referred to a neurology department with a possible diagnosis of epilepsy were subsequently considered to have cardiac arrhythmia as a cause of their symptoms (Schott *et al.*, 1977). The characteristics of convulsive symptoms occurring during the syncopal episodes were investigated by several studies. In a study with blood donors, the prevalence of

the convulsive syncope was found to be 0.03% (Lin *et al.*, 1982). The authors reported that tonic extensor spasm was the most common convulsive movement and other complex phenomena also occurred simulating epileptic seizures. In another study, the videometric analysis of the episodes of the cerebral hypoxia was performed and the most commonly observed activity was myoclonus, occurring either as multifocal myoclonic jerks or generalized myoclonus. Additional motor activities observed in this report were: head turns, oral automatisms and righting movements (Lempert *et al.*, 1994).

The cerebral electrical activity during the convulsive syncope was also investigated. Background slowing evolving into loss of cerebral activity was reported in patients with malignant ventricular arrhythmias (Aminoff *et al.*, 1988). Later studies also confirmed that the ictal patterns consisted of diffuse slowing without paroxysmal activity (Fernandez Sanmartin *et al.*, 2003). Gelisse *et al.* (2007) conducted a video-EEG study of a 14-year-old boy misdiagnosed with epilepsy. They proved clinically and neurophysiologically that the patient actually experienced syncopal episodes. The video-EEG demonstrated





**Figure 3.** Silent period following reappearance of the heart rhythm. At the end of this epoch diffuse body jerks with associated high amplitude delta waves appeared.

a syncopal episode due to cardiac asystole triggered by ocular compression. During the episode, the EEG showed generalized slowing evolving into complete cessation of cerebral electrical activity.

In order to relieve diagnostic confusion, the utility of some diagnostic tests has been investigated. In one study, 24-hour electrocardiographic recordings were not found to be useful (Gibson and Heitzman, 1984). The authors reported that arrhythmia was a useful diagnostic symptom for only 2% of the patients and argued against the diagnostic utility of this method for syncope. Zaidi *et al.*, (2000) investigated patients who were previously diagnosed with epilepsy and unresponsive to drug treatment. The patients were subjected to a head-up tilt test and carotis sinus massage during continuous electrocardiography, EEG and blood pressure recordings. For 41% of the patients, an alternative diagnosis other than epilepsy was given to explain their condition. The authors concluded that many patients with unexplained convulsive black-outs have a cardiovascular problem and suggested a non-invasive cardio-

vascular examination for such patients. Other studies suggest the tilt table test to be a reliable method to differentiate between epilepsy and syncope (Grubb *et al.*, 1992; Sabri *et al.*, 2006).

In agreement with previous reports, the observations of our patient demonstrate that cardiovascular diseases may impose a great diagnostic difficulty in the evaluation of the patients with presumed epilepsy. To overcome this, a diligent and elaborate investigation is needed. The interpretation of seizure semiology in such paroxysmal events may also be misleading and other parameters, such as ECG, should also be included during the recording and meticulously checked during the review. When there is a doubt, the neurologist should not hesitate to call for further cardiological investigation. □

#### Disclosure.

None of the authors has any conflict of interest to disclose. This work was not supported by a grant or any other means and has not been presented anywhere before.

**Legend for video sequence**

00:15 The heart rate slows down and the patient says that she felt dizzy.

00:37 The patient loses her consciousness due to asystolia.

00:47 High amplitude delta waves are followed by cessation of the brain activity. Head/eye deviations and automatisms occur.

01:12 The patient takes a dystonic posture.

01:19 Heart rate reappears.

01:41 Diffuse clonic jerks occur.

02:58 The patient regains consciousness.

**References**

- Acierno L. *The History of Cardiology*. New York: Parthenon Publishing Group Inc, 1994.
- Aminoff MJ, Scheinman MM, Griffin JC, Herre JM. Electroencephalographic accompaniments of syncope associated with malignant ventricular arrhythmias. *Ann Intern Med* 1988; 108: 791-6.
- Fernández Sanmartín M, Rodríguez Núñez A, Martínón-Torres F, Eirís Puñal J, Martínón Sánchez JM. Convulsive syncope: characteristics and reproducibility using the tilt test. *An Pediatr (Barc)* 2003; 59: 441-7.
- Gelisse P, Serafini A, Davy JM, Balbe M, Coubes P, Crespel A. Video-EEG in syncopal attack due to ocular compression in an adolescent mistreated for epilepsy. *Epileptic Disord* 2007; 9: 174-8.
- Gibson TC, Heitzman MR. Diagnostic efficacy of 24-hour electrocardiographic monitoring for syncope. *Am J Cardiol* 1984; 53: 1013-7.
- Grubb BP, Gerard G, Wolfe DA, et al. Syncope and seizures of psychogenic origin: identification with head-upright tilt table testing. *Clin Cardiol* 1992; 15: 839-42.
- Lempert T, Bauer M, Schmidt D. Syncope: a videometric analysis of 56 episodes of transient cerebral hypoxia. *Ann Neurol* 1994; 36: 233-7.
- Lin JT, Ziegler DK, Lai CW, Bayer W. Convulsive syncope in blood donors. *Ann Neurol* 1982; 11: 525-8.
- Sabri MR, Mahmodian T, Sadri H. Usefulness of the head-up tilt test in distinguishing neurally mediated syncope and epilepsy in children aged 5-20 years old. *Pediatr Cardiol* 2006; 27: 600-3.
- Schott GD, McLeod AA, Jewitt DE. Cardiac arrhythmias that masquerade as epilepsy. *Br Med J* 1977; 1: 1454-7.
- Zaidi A, Clough P, Cooper P, Scheepers B, Fitzpatrick AP. Misdiagnosis of epilepsy: many seizure-like attacks have a cardiovascular cause. *J Am Coll Cardiol* 2000; 36: 181-4.