

Temporal lobe epilepsy? Things are not always what they seem

Irena Doležalová¹, Milan Brázdil^{1,2}, Philippe Kahane³

¹ Brno Epilepsy Center, First Department of Neurology, St. Anne's University Hospital and Faculty of Medicine, Masaryk University

² Central European Institute of Technology (CEITEC), Masaryk University, Brno, Czech Republic

³ Clinique de Neurologie, University Hospital of Grenoble, France

Received August 21, 2016; Accepted December 29, 2016

ABSTRACT – Temporal lobe epilepsy is the most frequent form of drug-resistant epilepsy referred to epilepsy surgery centres. The vast majority of lesional cases can be operated on without invasive investigation which is often not the case for non-lesional cases. Invasive investigation in non-lesional cases, however, may lead to unexpected results, as illustrated in the following case report. [*Published with video sequence on www.epilepticdisorders.com*]

Key words: temporal lobe epilepsy, invasive EEG, pseudotemporal epilepsy, posterior cingulate

Clinical data

A 33-year-old left-handed female patient started to have seizures at the age of 14. She was born from a normal uncomplicated pregnancy, and was treated for asthma in childhood. Familial history was irrelevant with the exception of a paternal cousin who suffered from moderate intellectual disability associated with epilepsy. The patient had a secondary school education and was working episodically as a civil servant. Her neurological examination was normal, except for a discrete right inferior facial palsy.

The first episode was described as an abrupt loss of contact accompanied by abnormal verbal behaviour (she repeated the same questions

several times), followed by headache. A diagnosis of epilepsy was established and the patient was subsequently treated with valproic acid, which failed to control the seizures. The seizures persisted on a weekly to monthly basis despite different AEDs used in monotherapy or in combination (carbamazepine, clobazam, lamotrigine, and levetiracetam). Aura was described as an epigastric constriction, sometimes associated with gustatory hallucinations. A seizure was observed by her neurologist who described a behavioural change (the patient seemed “confused”), a preserved ability to denominate objects, right-handed nose rubbing, and amnesia (with no recollection of denominating objects).



VIDEO ONLINE

Correspondence:

Irena Doležalová
Brno Epilepsy Center,
First Department of Neurology,
St. Anne's University Hospital and Faculty
of Medicine, Masaryk University,
Pekarska 53, Brno 65691 Czech Republic
<irena.dolezalova@fnusa.cz>

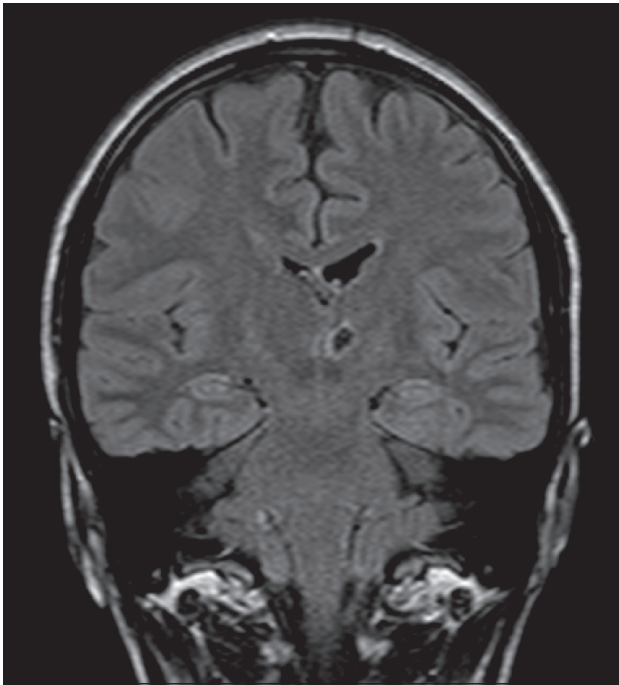


Figure 1. Preoperative MRI showing a left-sided thalamic infarction. Hippocampal sclerosis or other possible epileptogenic lesions were not identified.

EEG showed infrequent right fronto-temporal sharp waves and left frontal spikes during drowsiness. MRI showed the cavity of a left thalamic infarct, without any other abnormalities (*figure 1*).

Comments

The overall clinical presentation appears to be similar to that of temporal lobe epilepsy (TLE), which can be considered “cryptogenic” despite the presence of a left thalamic infarct. The inconsistent gustatory aura, however, could suggest an early perisylvian involvement during the seizures (Hausser-Hauw and Bancaud, 1987). The neurological examination (right inferior facial palsy) indicates the involvement of the left hemisphere (Robillard *et al.*, 1983), while ictal semiology (right-handed nose rubbing) could suggest right hemispheric involvement (Catenox *et al.*, 2004). Preservation of speech suggests the involvement of the non-dominant hemisphere for language (Gillig *et al.*, 1988).

Non-invasive investigations

During video-EEG monitoring, seizures were characterized by an unpleasant epigastric constriction, inconsistent preservation of speech, loss of contact,

a change in facial expression, oroalimentary automatisms (mastication), upper limb automatisms (mainly left), and nose wiping or face rubbing (without clear lateralization) (*video sequence 1*). Seizures lasted approximately one minute and the patient sometimes remained confused during the postictal state, without language deficit.

Interictal EEG activity mainly showed, during sleep, interictal epileptiform discharges (IEDs) over the left fronto-temporal region (phase reversal at Fb1, T3; *figure 2A*) and, much less frequently, over the right frontal region (phase reversal at F4; *figure 2B*) or the left frontal region (phase reversal at F3; *figure 2C*). Seizures slightly differed in their EEG pattern, but typically indicated seizure onset over the left anterior temporal lobe, with secondary left hemispheric involvement and contralateral spread (*figure 3*).

Neuropsychological examination showed visual and verbal encoding difficulties; executive functions and attention were described as normal. Functional MRI supported bilateral speech representation. 18-FDG-PET showed bitemporal, but left-predominant, hypometabolism (*figure 4*).

Comments

Based on interictal EEG abnormalities, neuropsychological findings, and PET results, the patient could appear to have bitemporal epilepsy. However, ictal EEG consistently indicated the left hemisphere at seizure onset, and seizures systematically propagated over the contralateral hemisphere, which could explain bilateral dysfunctions.

The association of left-sided TLE with seizures arising from the dominant hemisphere and preserved ictal speech would be rare. In these cases, an extratemporal lobe seizure origin with temporal propagation of ictal activity seems to be more probable (Kaiboriboon *et al.*, 2006). However, the structural or functional damage of a dominant hemisphere by epileptic activity can cause neuronal reorganization and redistribution of “critical” functions, as has been reported for speech and handedness which were shown to shift to the other hemisphere (Orsini and Satz, 1986; Adcock *et al.*, 2003). This could be supported by left-handedness and bilateral speech representation on functional MRI. However, the distribution of IEDs over both frontal regions raised a red flag which forced us to also consider extra-TLE with propagation of ictal activity to the temporal region.

Invasive EEG (iEEG) was considered as mandatory to answer the following question: does this patient have TLE, temporal “plus” epilepsy (Barba *et al.*, 2007), or extra-TLE?

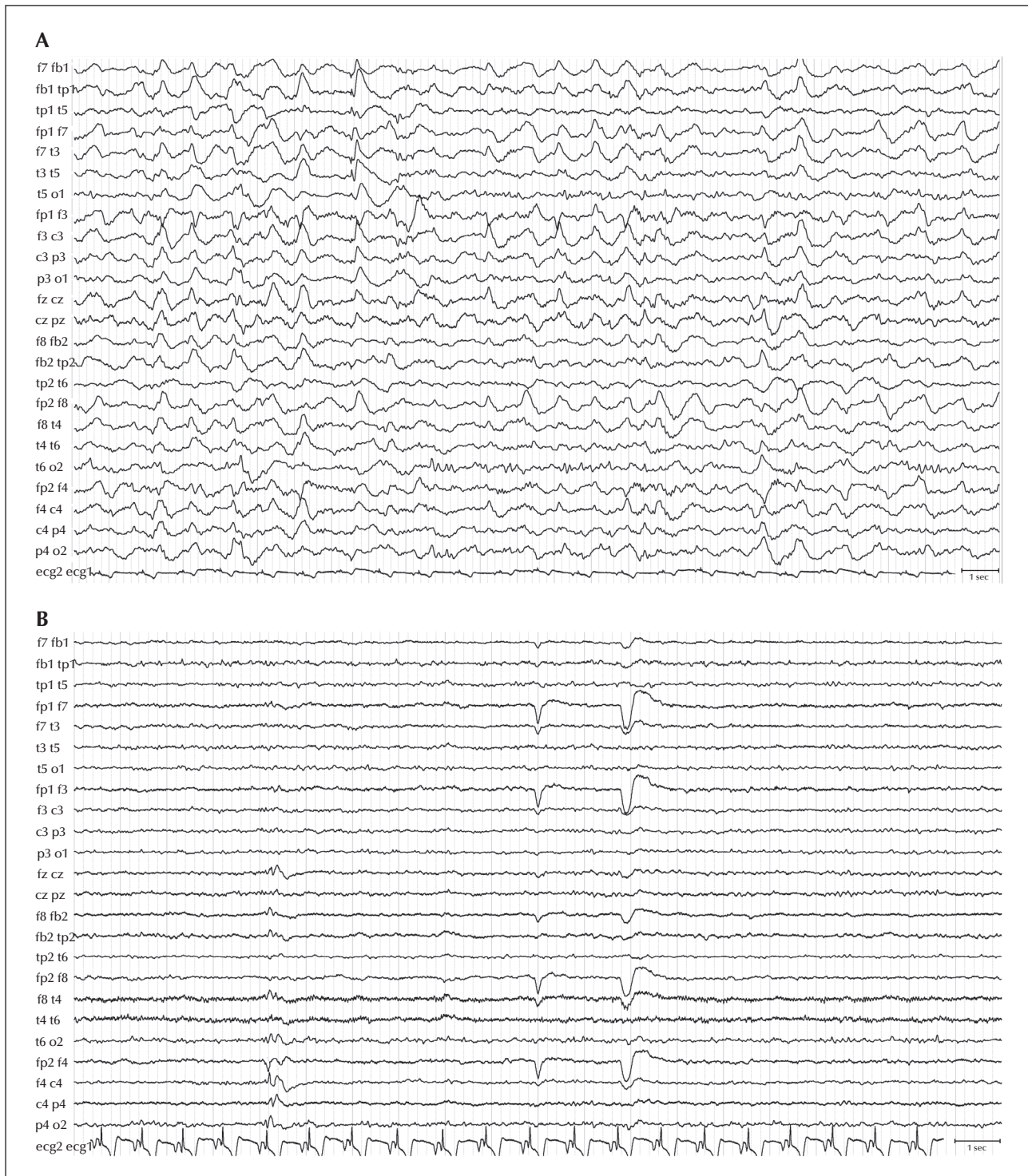


Figure 2. Distribution of interictal epileptiform discharges (IEDs) on scalp EEG. (A) The majority of IEDs were present in the left-sided fronto-temporal area (phase reversal at electrodes Fb1, T3). (B) There were also less frequent IEDs over the right-sided frontal area (phase reversal at electrodes F4).

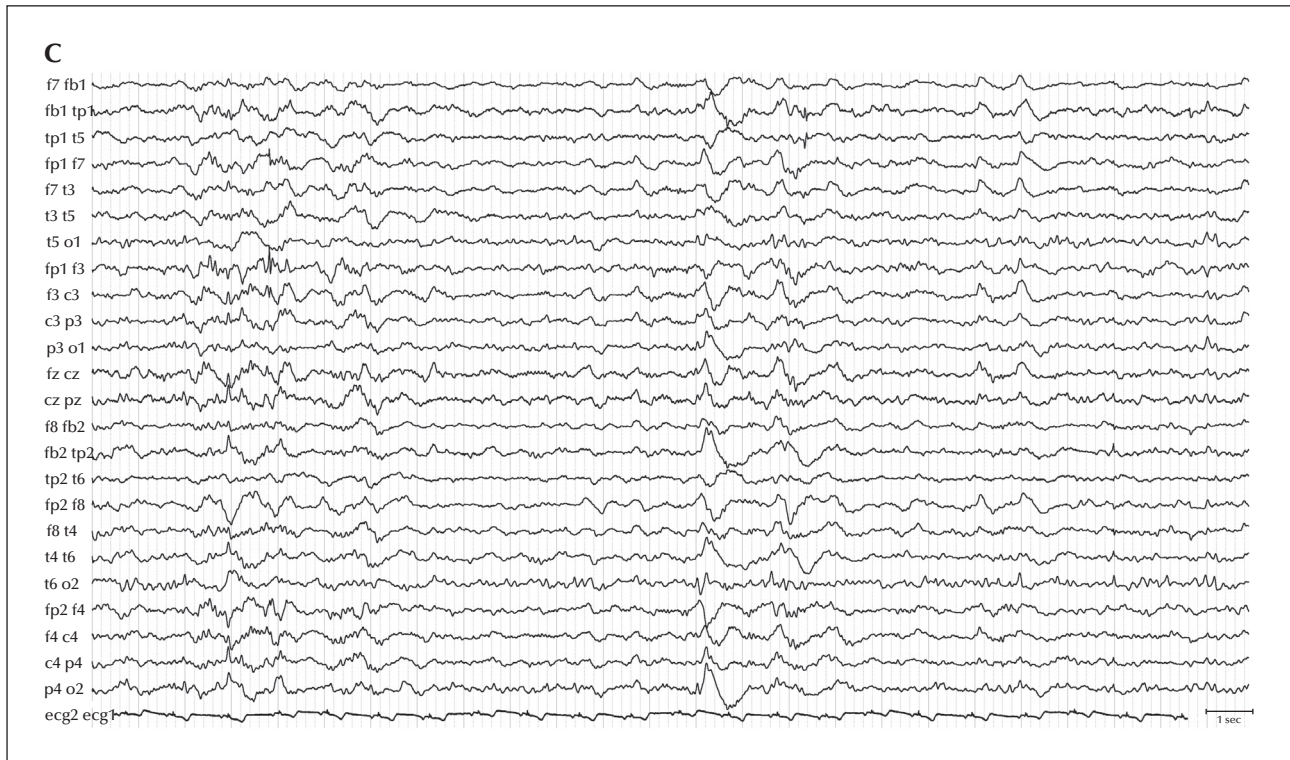


Figure 2. (Continued). (C) Rarely, IEDs could be found over the left frontal regions (phase reversal at electrode F3).

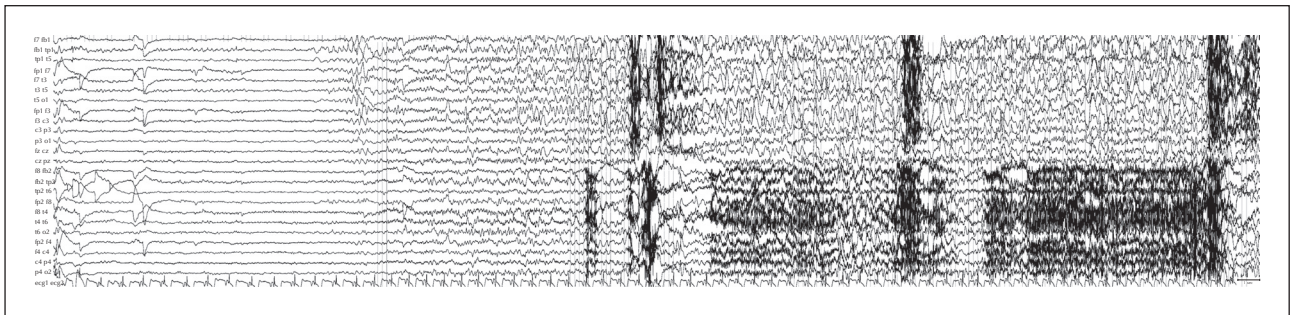


Figure 3. Ictal scalp EEG showing the typical pattern for the patient. The seizures started with a short flattening over the left anterior temporal lobe, followed by irregular theta waves in the same area. After, clear-cut rhythmic activity appeared; this rhythmic activity started on the left side, but rapidly spread over the right hemisphere. The left-sided ictal activity predominated throughout the entire seizure.

Invasive investigation

A large temporo-perisylvian stereoelectroencephalography (sEEG) study was performed that targeted the mesial and lateral temporal lobe structures, as well as the extra-temporal lobe regions that can trigger temporal lobe symptoms (e.g. the orbito-frontal cortex, insular cortex, and posterior cingulate cortex) (figure 5).

IEDs either involved mesiotemporal structures or, independently, the posterior cingulate region

(figure 6A). All seizures, however, started within the posterior cingulate before becoming symptomatic when they involved the mesiotemporal lobe structures (figure 6B and 7).

Comments

This patient is a typical example of what has been described as pseudo-temporal epilepsy, in which seizures start in extra-temporal lobe structures and later spread over the temporal lobe region, therefore

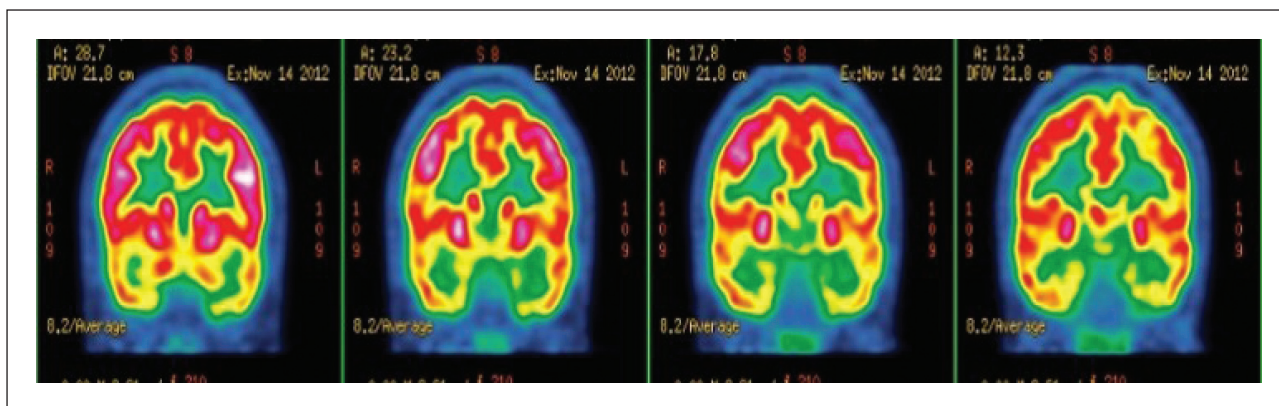


Figure 4. Preoperative positron emission tomography (PET) showing bilateral temporal hypometabolism, which was slightly more pronounced on the left side.

mimicking temporal semiology (Andermann, 2003). Extra-temporal lobe regions include the orbito-frontal cortex (Shihabuddin *et al.*, 2001), the insula (Isnard *et al.*, 2000), and the parieto-occipital regions (Williamson *et al.*, 1992; Palmini *et al.*, 1993; Liava *et al.*, 2014; Francione *et al.*, 2015), especially the posterior cingulate (Devinsky *et al.*, 1995; Alkawadri *et al.*, 2013; Enatsu *et al.*, 2014). Alkawadri *et al.* (2013) reported a group of 14 patients with cingulate epilepsy; within this group there were also four patients with posterior cingulate epilepsy and their seizures resembled temporal lobe seizures in all patients (Alkawadri *et al.*, 2013). Enatsu *et al.* (2014) analysed a case series of seven patients with posterior cingulate epilepsy, four of whom exhibited temporal lobe seizures and the rest had motor seizures (including bilateral tonic seizures and hypermotor seizures).

The differential diagnosis between temporal and pseudo-temporal epilepsy remains a diagnostic challenge, especially in non-lesional cases. The distribution of IEDs can be very helpful in terms of searching for a solution. IEDs in TLE often remain limited to the temporal lobe region; in other types of epilepsies they spread over different regions (Remi *et al.*, 2011). However, IEDs in posterior cingulate epilepsy have a large tendency to propagate into the temporal region, as was demonstrated by Alkawadri *et al.* (2013). These authors reported “typical” temporal IEDs in three out of four patients (in two patients over anterior temporal areas and in one patient over posterior temporal areas); in contrast, frontal IEDs were found only in one patient (Alkawadri *et al.*, 2013). Also, Elwan *et al.* (2013) did not find any statistical significant differences between temporal and pseudo-TLE when analysing the distribution of IEDs and seizure-onset pattern on scalp EEG (Elwan *et al.*, 2013). To sum up, IEDs often also propagate over temporal areas in extra-temporal epilepsies. However,

the presence of IEDs over extra-temporal areas is very often associated with an extra-temporal seizure origin despite typical temporal seizure semiology.

Action taken

Three surgical strategies could be considered:

- perform a standard temporal lobe resection, i.e. a resection of the symptomatogenic zone; this

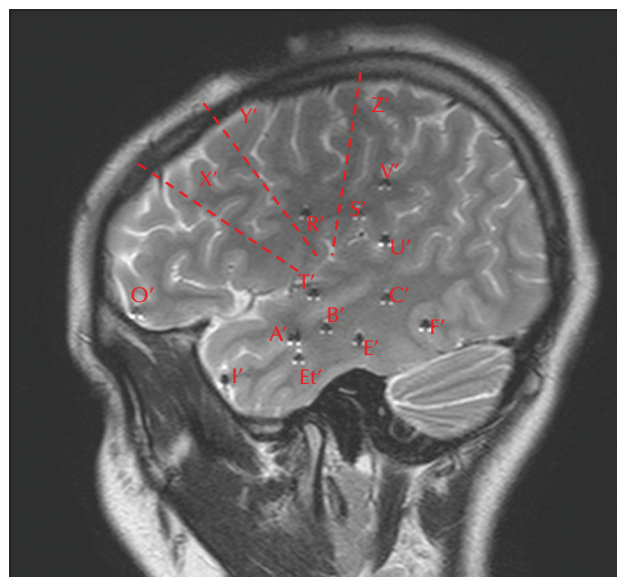


Figure 5. Electrode positions for invasive EEG monitoring. The positions of electrodes in the left temporal lobe are the following: A': amygdala; B': anterior hippocampus; C': posterior hippocampus; I': temporal pole; Et': entorhinal cortex; T', U': temporal operculum; E', F': temporobasal region. The positions of electrodes in the left extra-temporal lobe structures are the following: O': fronto-orbital cortex; R': frontal operculum; S': parietal operculum; V': cingulum (posterior part); X': anterior insula (dotted line); Y': posterior insula (dotted line); Z' (dotted line).

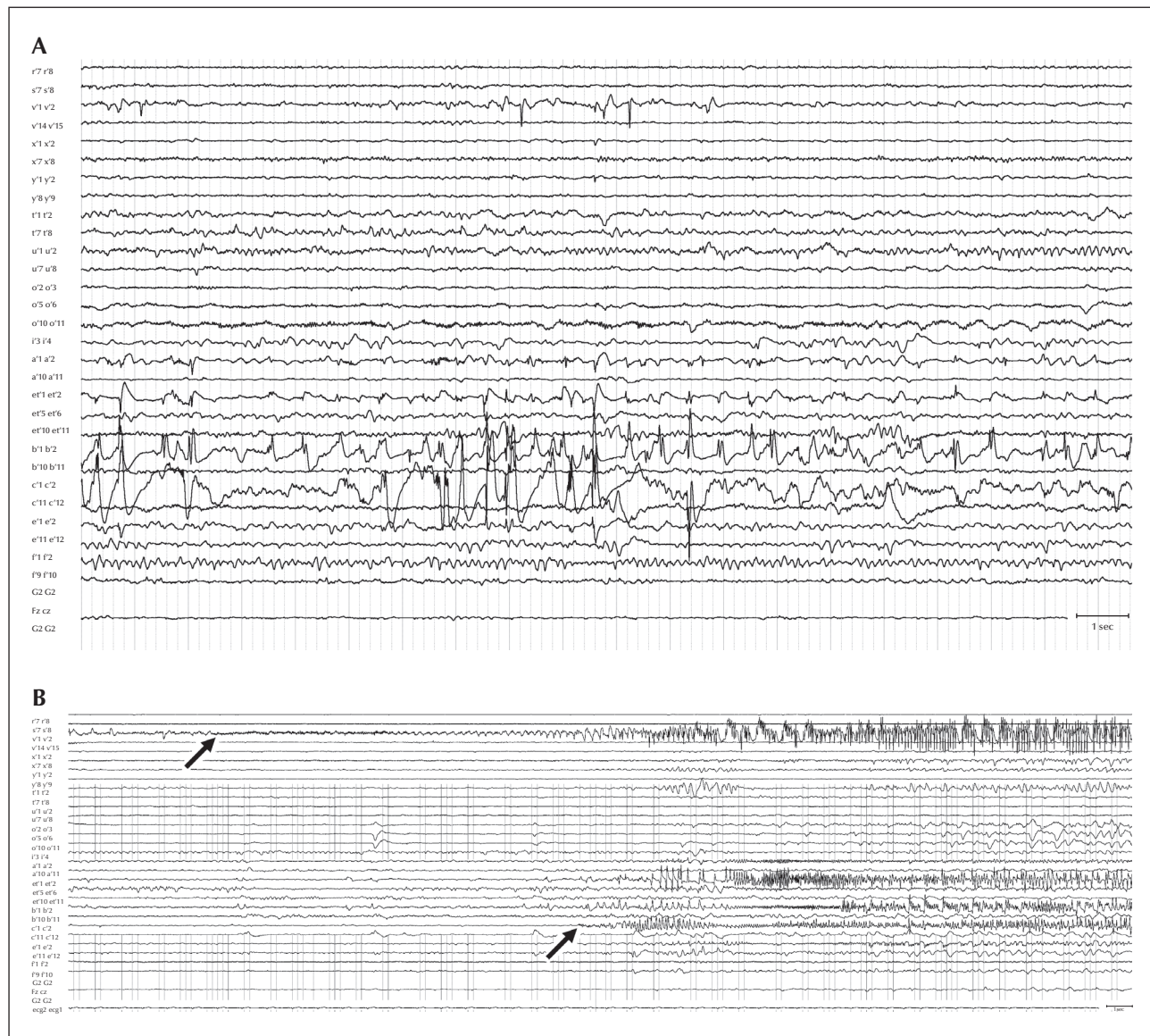


Figure 6. The results of invasive EEG. (A) Distribution of interictal epileptiform discharges (IEDs) on invasive EEG. IEDs dominated in the area of left-sided mesiotemporal structures (left amygdala: electrode A1-2; left entorhinal cortex: electrode Et1-2; and left hippocampus: electrodes B1-2 and C1-2), but there were also IEDs and bursts of rapid activity (blue arrow) in the area of the left posterior cingulum (electrode V1-2). (B) Ictal findings on invasive EEG. The seizures started with low-voltage fast (LVF) activity in the left side of the posterior cingulum (first arrow); LVF activity propagated to the left-sided mesiotemporal structures, where the symptomatic zone was localized (second arrow).

strategy should be considered as only palliative and could postoperatively aggravate the memory deficit;

- perform a new iEEG study in order to better delineate the amount of the mesial parietal cortex that should be resected; this is a possible option, although the benefit/risk ratio cannot be clearly evaluated;
- perform a very focal resection of the posterior cingulate cortex surrounding the cingulate electrode.

The latter strategy was finally chosen, as the shape and signal of that part of the posterior cingulate retrospectively appeared “abnormal” (figure 8). The histopathological specimen, however, proved negative. Another possibility would be to perform thermocoagulation in the area of the posterior cingulum. The effectiveness of this procedure is not very high; only 7% of patients remain seizure-free one year after surgery (Bourdillon *et al.*, 2016).

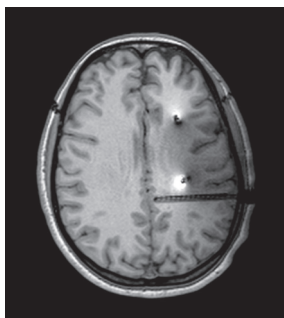


Figure 7. More detailed view of the position of electrode Vi. The low-voltage fast activity started in the mesial contacts of this electrode, encompassing the left side of the posterior cingulum, as seen in this image.

Follow-up

The patient is completely seizure-free three years after surgery (Class 1; according to International League Against Epilepsy Classification [Wieser *et al.*, 2001]). AEDs have been substantially reduced and at present, the patient is only being given 800 mg of carbamazepine. Interictal EEG shows infrequent right temporal sharp waves.

Conclusion

This case report illustrates that atypical presentation of non-lesional TLE epilepsy must be referred for iEEG evaluation. Invasive evaluation must be designed to allow a distinction between mesial and neocortical temporal lobe onset, as well as consideration for possible extra-temporal onset, as in the present case. □

Supplementary data.

Summary didactic slides are available on the www.epilepticdisorders.com website.

Disclosures.

None of the authors have any conflict of interest to declare.

Legend for video sequence

A typical patient seizure. The seizure semiology appears late (approximately 30 seconds from the first change in EEG). In this first seizure, limb automatisms of the right arm are observed and speech is preserved during the seizure. In the post-ictal state, the patient was amnesic for the seizure.

Key words for video research on www.epilepticdisorders.com

Phenomenology: aura (abdominal), automatisms
Localisation: cingulate gyrus, temporal (left)
Epilepsy syndrome: focal non-idiopathic parietal
Aetiology: not applicable

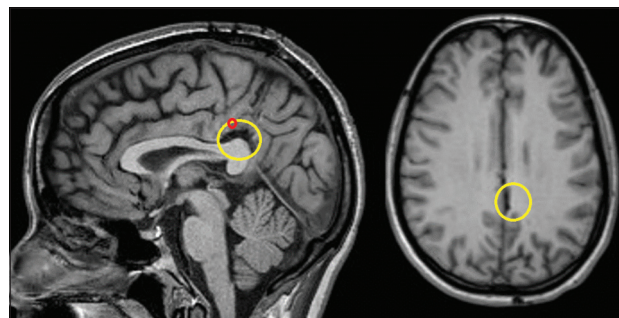


Figure 8. The second preoperative MRI. We retrospectively identified a discrete change on MRI (yellow circle). The position of seizure onsets is marked by red dots.

References

- Adcock JE, Wise RG, Oxbury JM, Oxbury SM, Matthews PM. Quantitative fMRI assessment of the differences in lateralization of language-related brain activation in patients with temporal lobe epilepsy. *Neuroimage* 2003; 18(2): 423-38.
- Alkawadri R, So NK, Van Ness PC, Alexopoulos AV. Cingulate epilepsy: report of 3 electroclinical subtypes with surgical outcomes. *JAMA Neurol* 2013; 70(8): 995-1002.
- Andermann F. Pseudotemporal vs neocortical temporal epilepsy: things aren't always where they seem to be. *Neurology* 2003; 61(6): 732-3.
- Barba C, Barbati G, Minotti L, Hoffmann D, Kahane P. Ictal clinical and scalp-EEG findings differentiating temporal lobe epilepsies from temporal 'plus' epilepsies. *Brain* 2007; 130(7): 1957-67.
- Bourdillon P, Isnard J, Catenox H, *et al.* Stereo electroencephalography-guided radiofrequency thermocoagulation (SEEG-guided RF-TC) in drug-resistant focal epilepsy: results from a 10-year experience. *Epilepsia* 2016. Ahead of print.
- Catenox H, Guenot M, Isnard J, Fischer C, Manguiere F, Ryvlin P. Intracranial EEG study of seizure-associated nose wiping. *Neurology* 2004; 63(6): 1127-9.
- Devinsky O, Morrell MJ, Vogt BA. Contributions of anterior cingulate cortex to behaviour. *Brain* 1995; 118(1): 279-306.
- Elwan SA, So NK, Enatsu R, Bingaman WE. Pseudotemporal ictal patterns compared with mesial and neocortical temporal ictal patterns. *J Clin Neurophysiol* 2013; 30(3): 238-46.
- Enatsu R, Bulacio J, Nair DR, *et al.* Posterior cingulate epilepsy: clinical and neurophysiological analysis. *J Neurol Neurosurg Psychiatry* 2014; 85(1): 44-50.
- Francione S, Liava A, Mai R, *et al.* Drug-resistant parietal epilepsy: polymorphic ictal semiology does not preclude good post-surgical outcome. *Epileptic Disord* 2015; 17(1): 32-46.
- Gillig P, Sackellares JC, Greenberg HS. Right hemisphere partial complex seizures: mania, hallucinations, and speech disturbances during ictal events. *Epilepsia* 1988; 29(1): 26-9.
- Hausser-Hauw C, Bancaud J. Gustatory hallucinations in epileptic seizures. Electrophysiological, clinical and anatomical correlates. *Brain* 1987; 110(2): 339-59.

Isnard J, Guenot M, Ostrowsky K, Sindou M, Mauguier F. The role of the insular cortex in temporal lobe epilepsy. *Ann Neurol* 2000;48(4): 614-23.

Kaiboriboon K, Parent JM, Barbaro NM, Walker JA, Garcia PA. Speech preservation during language-dominant, left temporal lobe seizures: report of a rare, potentially misleading finding. *Epilepsia* 2006;47(8): 1343-6.

Liava A, Mai R, Tassi L, et al. Paediatric epilepsy surgery in the posterior cortex: a study of 62 cases. *Epileptic Disord* 2014;16(2): 141-64.

Orsini DL, Satz P. A syndrome of pathological left-handedness. Correlates of early left hemisphere injury. *Arch Neurol* 1986;43(4): 333-7.

Palmini A, Andermann F, Dubeau F, et al. Occipitotemporal epilepsies: evaluation of selected patients requiring depth electrodes studies and rationale for surgical approaches. *Epilepsia* 1993;34(1): 84-96.

Remi J, Vollmar C, de Marinis A, Heinlin J, Peraud A, Noachtar S. Congruence and discrepancy of interictal and ictal EEG with MRI lesions in focal epilepsies. *Neurology* 2011;77(14): 1383-90.

Robillard A, Saint-Hilaire JM, Mercier M, Bouvier G. The lateralizing and localizing value of aversion in epileptic seizures. *Neurology* 1983;33(9): 1241-2.

Shihabuddin B, Abou-Khalil B, Delbeke D, Fakhoury T. Orbito-frontal epilepsy masquerading as temporal lobe epilepsy-a case report. *Seizure* 2001;10(2): 134-8.

Wieser HG, Blume WT, Fish G, et al. Proposal for a new classification of outcome with respect to epileptic seizures following epilepsy surgery. *Epilepsia* 2001;42(2): 282-6.

Williamson PD, Boon PA, Thadani VM, et al. Parietal lobe epilepsy: diagnostic considerations and results of surgery. *Ann Neurol* 1992;31(2): 193-201.

TEST YOURSELF



(1) In pseudotemporal epilepsy,

- A. do seizures always spread to mesio-temporal lobe structures?
- B. is seizure onset localized to the extra-temporal lobe structures?
- C. is the seizure semiology similar to that of temporal lobe seizures?
- D. is an extra-temporal lobe lesion always present on MRI?

(2) Which type of extra-temporal epilepsy can manifest as pseudotemporal epilepsy (more than one answer may be correct)?

- A. Occipital
- B. Parietal
- C. Frontal
- D. Insular

(3) Which of the following examinations is the most relevant in the diagnosis of non-lesional pseudo-temporal epilepsy?

- A. Video-EEG monitoring
- B. 18-FDG PET
- C. Neuropsychological evaluation
- D. Invasive EEG

Note: Reading the manuscript provides an answer to all questions. Correct answers may be accessed on the website, www.epilepticdisorders.com, under the section "The EpiCentre".