

# Recurrence of childhood absence epilepsy as pyknolepsy in adolescence

Elissa G. Yozawitz<sup>1</sup>, Morris H. Scantlebury<sup>1</sup>, Julie Robinson<sup>1</sup>, Rana Jehle<sup>1,2</sup>, Solomon L. Moshé<sup>1,2,3</sup>

<sup>1</sup> Saul R. Korey Department of Neurology and Montefiore/Einstein Epilepsy Management Center

<sup>2</sup> Department of Pediatrics, Albert Einstein College of Medicine

<sup>3</sup> Dominick P. Purpura Department Neuroscience, Bronx, New York

Received November 3, 2010; Accepted July 2, 2011

**ABSTRACT** – A developmentally normal adolescent boy with a history of childhood absence epilepsy presented with recurrence of pyknolepsy after a seven-year period of remission. The characteristics of his EEG showed the same 3-Hz generalised spike-wave discharge as in his previous EEG in childhood. To our knowledge, this is the first case report describing recurrence of childhood absence epilepsy as pyknolepsy in an adolescent. *[Published with video sequences]*

**Key words:** childhood absence epilepsy, recurrence, pyknolepsy, adolescence

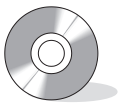Pyknolepsy was first defined by Adie in 1924 (Adie, 1924) as “a disease with explosive onset between the ages of four and 12 years, of frequent short... monotonous minor epileptiform seizures of uniform severity, which recur almost daily...”. Pyknolepsy (coming from the greek word “pyknos” signifying “dense” or “very frequent”) is not known to occur in adolescence or adulthood. Here, we report an unusual case of pyknolepsy re-emerging in an adolescent boy with CAE after a prolonged seizure-free period without medication.

frequent absence seizures (one every 10-15 minutes). The latter were characterised by staring, blinking, and occasional arm jerks. There was no provoking factor to this seizure flurry. He did not have a concurrent infection, head trauma, or other identifiable physical stress. CCTV-EEG confirmed pyknolepsy (figure 1A, B). Physical examination was normal. Routine laboratory studies, which included a urine toxicology screen, were also normal. Brain MRI revealed punctate T2/FLAIR hyperintensities, greater on the right side than left, in the subcortical parietal white matter (figure 2A, B).

Previously, at three years of age, the boy developed “myoclonic jerks” which were treated with valproate by another neurologist. There was neither EEG documentation nor

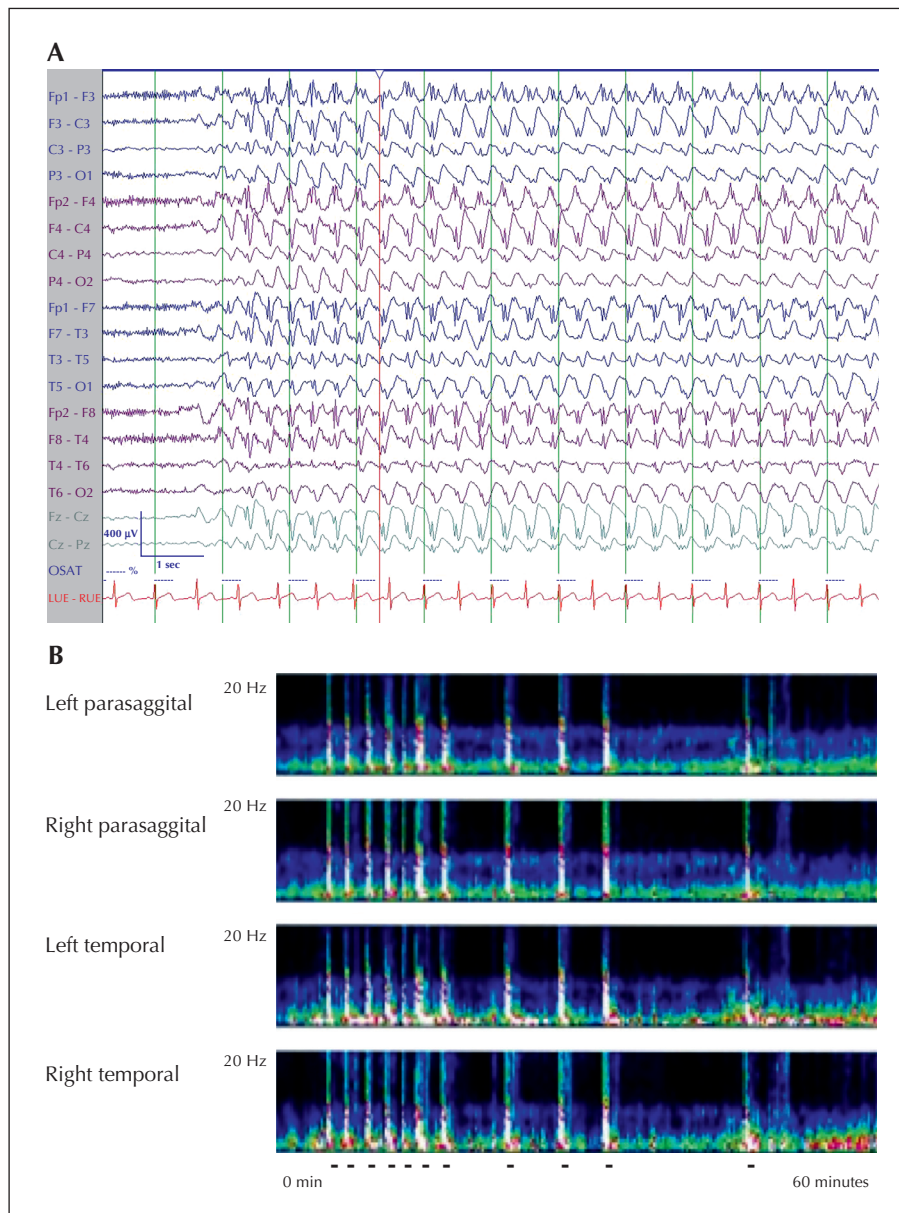
## Case study

A 14-year-old, post-pubescent boy presented with a generalised tonic-clonic seizure lasting several minutes, followed, an hour later, by very



## Correspondence:

E. Yozawitz MD  
Department of Neurology,  
Albert Einstein College of Medicine,  
Bronx, NY, USA  
<eyozawit@montefiore.org>

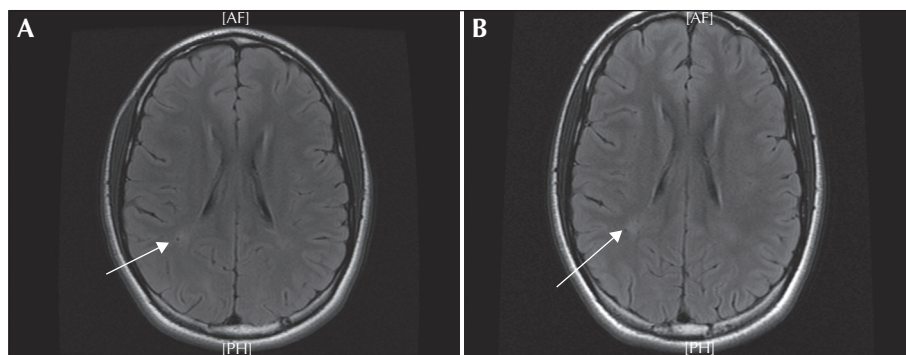


**Figure 1.** A) EEG during one absence seizure at 14 years of age with a 14-second burst of 3-Hz generalised spike-wave activity.

**B)** Depiction of several absence seizures over 60 minutes using compressed spectral analysis of the EEG (Fast Fourier Transform Spectrogram, Insight II software, Persyst Development Corporation, Prescott, Arizona). The x axis represents time and y axis frequency. Colour represents power, as depicted in the legend. The bars indicate an individual absence seizure depicted as increased power.

follow-up. At age six years, he presented with absence seizures which were several seconds long and occurred multiple times per day. The semiology consisted of behavioural arrest, eye blinking, and a few arm jerks. His EEG revealed a 3-Hz spike-and-wave pattern. He was treated with ethosuximide for two years with normalisation of his EEG. Subsequently, although the ethosuximide was discontinued, he remained seizure-free for seven years. His development was normal and there was no family history of epilepsy.

During the recurrence, his clinical seizures were effectively treated with 1,000 mg i.v. valproate, but the EEG continued to show a 3-Hz generalised spike-wave discharge (identical to that seen at six years of age). Ethosuximide, at 250 mg PO twice daily, was added to the valproate, and resolution of the EEG seizure pattern was achieved. One year later, the adolescent continued to excel in school and remained seizure-free. Follow-up CCTV-EEG monitoring did not show any 3-Hz generalised spike-wave discharge.



**Figure 2.** MRI brain reveals a subtle cystic lesion in the subcortical right parietal white matter and a punctate T2/FLAIR hyperintense focus of the subcortical right parietal lobe.

## Discussion

We describe the first reported case of CAE re-emerging as pyknolepsy in adolescence after a remission of many years without antiepileptic medication. Pyknolepsy normally is observed in childhood, with seizures disappearing by adolescence. Ethosuximide and valproic acid are more effective than lamotrigine for the treatment of CAE (Glauser *et al.*, 2010). Response to treatment is highly variable; between 21-89% (Bouma *et al.*, 1996; Wirrell *et al.*, 1996). This variability may depend on how strictly CAE is classified and on the duration of treatment (ILAE, 1989; Loiseau and Panayiotopoulos, 2005). CAE can progress to other epilepsy syndromes such as JME in 3-21% cases (Shian and Chi, 1994; Wirrell *et al.*, 1996) or other seizure types, such as generalised tonic-clonic seizures in 50% of patients (Bouma *et al.*, 1996; Wirrell *et al.*, 1996). Callenbach *et al.* (2009) investigated long-term outcome and the predictive value of baseline and EEG characteristics on seizure evolution in 47 children with newly diagnosed CAE. Half of the patients had relapses, but only 12 of 42 had relapses of absence seizures after a prolonged remission. However, the duration of the seizure-free period and the characteristics of the seizures were not clearly described. Pyknoleptic absence seizures, as exhibited by our patient, were not reported.

One might conjecture that our adolescent patient may have had a seizure syndrome other than CAE. Alternative differential diagnostic possibilities included: myoclonic absence epilepsy, absence epilepsy of early childhood, myoclonic astatic epilepsy, and GLUT 1 deficiency. *Myoclonic absence epilepsy* (Bureau and Tassinari, 2005) occurs at a later age of onset, and the prognosis is poor with persistence of myoclonic absences. A feature of this syndrome, which was not present in our patient, is the presence of rhythmic and bilateral jerks of limbs with severe intensity. *Absence*

*epilepsy of early childhood* (Chaix *et al.*, 2003) was considered, but our patient exhibited neither irregular 2-3-Hz spike-and-wave discharges nor poor neuropsychological outcome. His EEG features and clinical history were not consistent with *myoclonic astatic epilepsy* (MAE). Another possibility was glucose transporter type 1 (GLUT1) deficiency. Testing for GLUT1 was not performed, as there was no clinical necessity because: (1) seizures were well controlled, and (2) there was no family history of epilepsy. In the cases of GLUT1 mutation reported by Suls *et al.* (2009), recurrence of pyknolepsy, as reported here, was not observed. Thus, we concluded that our patient's symptomatology was best categorized by CAE.

It is not known why our patient developed pyknolepsy in adolescence. Risk factors proposed to be predictive of relapse and progression for other seizure types, such as prior cognitive difficulties, absence status at any time throughout the course of the disease, and family history of generalised seizures in first degree relatives (Bouma *et al.*, 1996; Wirrell *et al.*, 1996), were not present. However, subtle subcortical white matter abnormalities were observed on MRI for our patient. This is in line with previous case series showing that some patients with pyknolepsy may have subtle abnormalities such as focal microdysgenesis or volume asymmetries involving cortical or subcortical structures (Meencke and Janz, 1984; Caplan *et al.*, 2009). Unfortunately, our patient did not have MRI during childhood, so we were unable to compare his current imaging to his prior baseline. We can hypothesize that the recently observed MRI changes may depict a specific subpopulation resulting in recurrence, but additional studies are required to explore the validity of this notion. □

## Disclosure.

This work was supported, in part, by the Heffer Family Foundation.

None of the authors has any conflict of interest to disclose.

### Legend for video sequence

A 14-year-old boy with unprovoked absence seizure. Accompanying EEG shows a generalised burst of 3-Hz generalised spike-wave activity.

**Key words for video research on [www.epilepticdisorders.com](http://www.epilepticdisorders.com)**

*Etiology:* idiopathic

*Phenomenology:* absence seizure (typical); absence (dialeptic) seizure; status epilepticus (non convulsive)

*Localization:* –

*Syndrome:* childhood absence epilepsy (CAE)

### References

Adie W. Pyknolepsy: a form of epilepsy occurring in children with a good prognosis. *Brain* 1924; 47: 96-102.

Bouma PA, Westendorp RG, van Dijk JG, Peters AC, Brouwer OF. The outcome of absence epilepsy: a meta-analysis. *Neurology* 1996; 47: 802-8.

Bureau M, Tassinari CA. Epilepsy with myoclonic absences. *Brain & development* 2005; 27: 178-84.

Callenbach PM, Bouma PA, Geerts AT, et al. Long-term outcome of childhood absence epilepsy: Dutch Study of Epilepsy in Childhood. *Epilepsy Res* 2009; 83: 249-56.

Caplan R, Levitt J, Siddarth P, et al. Frontal and temporal volumes in Childhood Absence Epilepsy. *Epilepsia* 2009; 50: 2466-72.

Chaix Y, Daquin G, Monteiro F, et al. Absence epilepsy with onset before age three years: a heterogeneous and often severe condition. *Epilepsia* 2003; 44: 944-9.

Glauser TA, Cnaan A, Shinnar S, et al. Ethosuximide, valproic acid, and lamotrigine in childhood absence epilepsy. *N Engl J Med* 2010; 362: 790-9.

ILAE. Proposal for revised classification of epilepsies and epileptic syndromes. Commission on Classification and Terminology of the International League Against Epilepsy. *Epilepsia* 1989; 30: 389-9.

Loiseau P, Panayiotopoulos CP. Childhood Absence Epilepsy. 2005; from [http://www.ilae-epilepsy.org/Visitors/Centre/ctf/childhood\\_absence.cfm](http://www.ilae-epilepsy.org/Visitors/Centre/ctf/childhood_absence.cfm)

Meencke HJ, Janz D. Neuropathological findings in primary generalized epilepsy: a study of eight cases. *Epilepsia* 1984; 25: 8-21.

Shian WJ, Chi CS. Evolution of childhood absence epilepsy, juvenile myoclonic epilepsy and epilepsy with grand mal on awakening. *Zhonghua Min Guo Xiao Er Ke Yi Xue Hui Za Zhi* 1994; 35: 119-23.

Suls A, Mullen SA, Weber YG, et al. Early-onset absence epilepsy caused by mutations in the glucose transporter GLUT1. *Annals of neurology* 2009; 66: 415-9.

Wirrell EC, Camfield CS, Camfield PR, Gordon KE, Dooley JM. Long-term prognosis of typical childhood absence epilepsy: remission or progression to juvenile myoclonic epilepsy. *Neurology* 1996; 47: 912-8.