

# Non-convulsive status epilepticus of frontal origin as the first manifestation of Hashimoto's encephalopathy

Giulia Monti, Matteo Pugnaghi, Alessandra Ariatti, Laura Mirandola, Giada Giovannini, Silvia Scacchetti, Paolo Nichelli, Stefano Meletti

Division of Neurology, Department of Neurosciences, University of Modena and Reggio Emilia, Modena, Italy

Received February 21, 2011; Accepted July 21, 2011

**ABSTRACT** – Hashimoto's encephalopathy is an often misdiagnosed, life threatening, but treatable, condition which improves promptly with steroid therapy. Since clinical manifestations are heterogeneous and non-specific, the diagnosis is often difficult. Several case reports of Hashimoto's encephalopathy presenting with partial or generalised seizures are described, but only a few have focused on status epilepticus as the first clinical manifestation. We report two patients presenting with repetitive and prolonged seizures characterised by progressive reduction in contact and reactivity associated with frontal/diffuse polyspike-and-wave activities. This condition, which can be interpreted as a form of non-convulsive status epilepticus (NCSE) of frontal origin, was refractory to antiepileptic drugs but responded promptly to high doses of intravenous steroid treatment. In cases of unexplained encephalopathy with EEG documentation of NCSE, the early recognition and treatment of Hashimoto's encephalopathy may lead to a favourable prognosis. *[Published with video sequences]*

**Key words:** Hashimoto's encephalopathy, non-convulsive status epilepticus, anti-thyroid peroxidase antibodies, steroids



**Correspondence:**

S. Meletti  
Division of Neurology,  
Department of Neurosciences,  
University of Modena and Reggio Emilia,  
Modena, Italy  
<stefano.meletti@unimore.it>

Hashimoto's encephalopathy (HE) is a rare, life-threatening, condition associated with elevated levels of anti-thyroid antibodies (anti-thyroid peroxidase and anti-thyroglobulin). Thyroid function is not predictive of clinical symptoms and outcome. Clinical manifestations at onset, usually in otherwise healthy people, may be variable and include: tremor, myoclonic jerks, ataxia, stroke-like

episodes, neuropsychiatric symptoms (psychosis, behavioural changes, cognitive impairment), seizures and impairment of consciousness. Since symptoms are variable and non-specific, the diagnosis is complex and requires both the exclusion of other causes of encephalopathy and the demonstration of positive anti-thyroid antibody titre.

Differential diagnosis should include viral, paraneoplastic and non-paraneoplastic limbic encephalopathy, Creutzfeldt-Jakob disease, central nervous system vasculitis, and other autoimmune inflammatory encephalopathies. Seizures are the onset manifestation in 60-66% of cases of HE (Castillo *et al.*, 2006; Chong *et al.*, 2003), but only few cases of epileptic status associated with HE have been reported. Seven patients are described in different case reports: four presented with generalised convulsive status epilepticus (Duffey *et al.*, 2003; Ferlazzo *et al.*, 2006; McGinley *et al.*, 2000; Striano *et al.*, 2006), one had generalised absence status epilepticus (McKeon *et al.*, 2004), one had epilepsy partialis continua (Aydin-Ozemir *et al.*, 2006), and one had complex partial status epilepticus (Tsai *et al.*, 2007). Common features of reported cases are the poor responsiveness to antiepileptic drugs and the rapid clinical improvement after steroid administration.

We describe two new cases of Hashimoto's thyroiditis presenting with an electroclinical picture featuring non-convulsive status epilepticus with recurrent and prolonged episodes of catatonic stupor.

## Case reports

### Patient 1

A 51-year-old woman with chronic Hashimoto's thyroiditis came to our attention because of two tonic-clonic seizures over a few hours, followed by prolonged episodes of unresponsiveness with staring and fluctuating levels of consciousness. She had no previous seizures or history of epilepsy, nor neurological psychiatric diseases. Haematological tests, toxicology, complete rheumatological panel, and tumour markers (including paraneoplastic and non-paraneoplastic antibody panel; anti-HU Ab, anti-Yo Ab, anti-Ri Ab, anti Vgk Ab) were normal. Cerebrospinal fluid (CSF) analysis did not disclose abnormalities (including: cell count, oligoclonal bands, 14.3.3 protein, tau protein, and beta amyloid levels). Moreover, extensive microbiological and viral investigations on serum and CSF were negative. Gadolinium-enhanced brain MRI was normal.

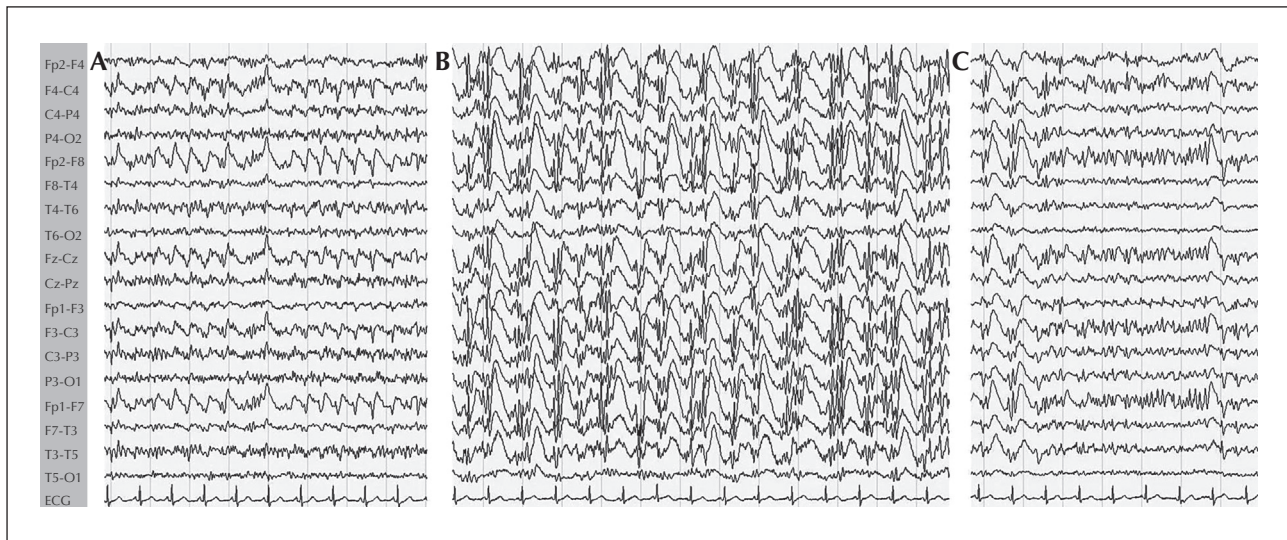
The patient was referred for video-EEG monitoring which demonstrated long-duration (10-12 minutes) seizures, recurring every 20-30 minutes (see *video sequences*). Ictal behaviour was characterised by an initial period (2-3 minutes) during which the patient was able to respond to simple questions. At this time, the ictal EEG was characterised by spike-and-wave activity localised over the bilateral frontal leads (*figure 1A*; see *video sequences 1, 2*). Subsequently, the patient became unresponsive and motionless. Ictal EEG

showed diffuse irregular 1-2 Hz spikes, polyspikes and waves (*figure 1B, C*; see *video sequence 3*). Between seizures, the patient was disoriented in space and time. She was initially treated with intravenous benzodiazepines (diazepam 10 mg bolus), without resolution of the status. Intravenous valproic acid (1,200 mg bolus followed by 2,400 mg in 24 hours for three days) was then used, but seizures persisted and visual/auditory hallucinations with paranoid ideations were observed. Valproic acid treatment was then stopped and intravenous phenytoin (750 mg in 24 hours) was administered. Seizures decreased in frequency and duration but did not disappear. Based on an hypothesis of acute encephalopathy related to Hashimoto's thyroiditis, endocrinological tests were performed disclosing higher levels of serum anti-thyroid antibodies: anti-thyroid peroxidase antibodies at 349.3 UI/ml (n.v. <50) and anti-thyroglobulin antibodies at >500 UI/ml (n.v. <35). Therefore, high doses of intravenous corticosteroid (1 gram of methylprednisolone for three days, and then 500 mg methylprednisolone for two days) were administered to the patient. After 24-48 hours, complete remission of seizures and hallucinations was obtained together with normalisation of EEG activity. The patient was asymptomatic and dismissed with oral steroid therapy which was continued for two months with marked decrease of serum anti-thyroid antibodies.

In December 2009 (after two years of follow-up), she was readmitted to our hospital for a new episode of NCSE, documented by video-EEG recordings. On this occasion, as well as in the first episode, she manifested prolonged ictal catatonic episodes followed by interictal psychotic symptoms. We again found increased levels of serum anti-thyroid antibodies: anti-thyroid peroxidase antibodies at >1,300 UI/mL and anti-thyroglobulin antibodies at >500 UI/mL. We repeated intravenous steroid treatment with clinical and EEG normalisation. At the last follow-up visit, one year after the previous status, the patient was healthy with a normal neurological examination and low plasma level of anti-thyroid antibodies. The patient is currently taking 300 mg phenytoin daily and no immunosuppressive therapy (Marshall and Doyle, 2006).

### Patient 2

A 66-year-old man without any pathological history came to our attention because of repeated episodes of loss of contact and confusion which started abruptly the day before hospital admission. He was unable to answer any questions or perform simple tasks and appeared confused with perseverations. Haematological tests, toxicology, complete rheumatological panel, tumour markers, as well as extensive microbiological tests on serum and cerebrospinal fluid analysis



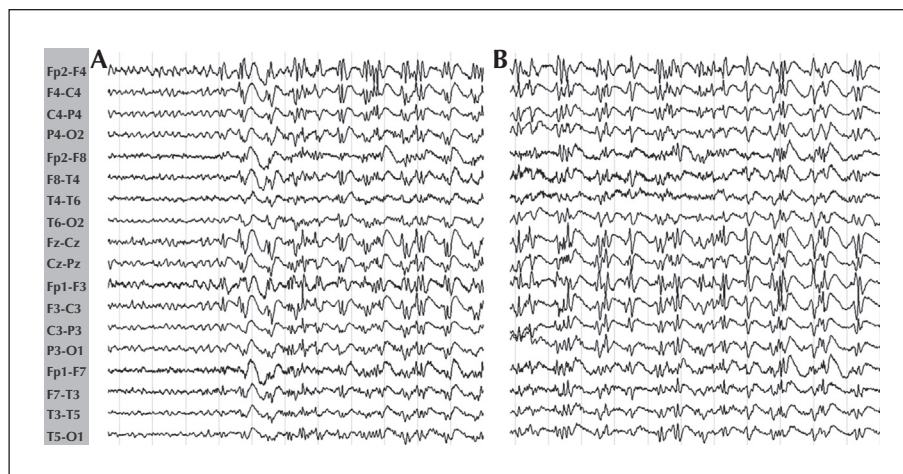
**Figure 1.** Ictal EEG in Patient 1.

- A)** Seizure onset: irregular rhythmic 1-2 Hz bi-frontal spike-and-waves. The patient is confused but responsive.  
**B)** Seizure evolves into a generalised spike-and-wave rhythmic activity. The patient is unresponsive.  
**C)** Seizure ends with clinical recovery and EEG spike-and-waves more evident in the frontal regions.

(including cell count, oligoclonal bands, 14.3.3 protein, tau protein, and beta-amyloid), were normal. A total-body CT scan was performed to rule out solid tumours while paraneoplastic antibodies in serum were not investigated. Gadolinium-enhanced brain MRI was also normal. The patient was referred for video-EEG monitoring which demonstrated long-duration seizures (5-10 minutes), recurring every 10-15 minutes, characterised by staring and motor arrest. Ictal EEG was characterised by generalised long runs of spikes and slow waves (1-2 Hz), more

evident in the frontal regions, bilaterally (*figure 2A, B*). The analysis of thyroid function revealed an increased level of serum TSH (6.86  $\mu$ IU/mL), anti-thyroglobulin antibodies (127.9 IU/mL), and anti-thyroid peroxidase antibodies (643.9 IU/mL). Thyroid ultrasound was suggestive of thyroiditis.

The patient's non-convulsive status was unresponsive to benzodiazepines (intravenous lorazepam) and antiepileptic drugs (*i.v.* valproic acid). Therefore, high doses of intravenous corticosteroid (1 gram methylprednisolone for three days, then 500 mg for two days)



**Figure 2.** Ictal EEG in Patient 2.

- A)** Seizure onset: irregular rhythmic 1-2 Hz bi-frontal spike-and-waves. The patient is confused and unresponsive.  
**B)** Ictal EEG shows generalised subcontinuous fronto-central spikes and waves. The patient is unresponsive.

were administered, in the suspicion of HE. A complete remission of seizures and confusion, as well as normalisation of EEG, was obtained in 24-48 hours. The patient was asymptomatic and discharged with oral steroid therapy which was discontinued after two months. At three months follow-up, normal levels of serum anti-thyroid antibodies were evident. At the last follow-up visit (two years), seizures had not recurred. At the present time, the patient is not taking any AED or immunosuppressive therapy.

## Discussion

We describe two patients with the following key-findings: (a) repeated and prolonged seizures featuring an episode of NCSE intermixed with confusion and psychotic symptoms, (b) a marked increase of anti-thyroid antibodies with evidence of autoimmune thyroiditis, and (c) a prompt clinical response to steroid treatment with normalisation of anti-thyroid antibodies. In addition, both patients showed poor response to acute AED treatments for recurrent seizures. Because of the characteristics noted above, a diagnosis of HE was made, although it should be noted that NMDAR antibodies were not investigated in either patient, and no anti-paraneoplastic studies were performed in Patient 2. Hence, the possibility that these entities were present cannot be categorically excluded even though the clinical features and evolution of these disorders are different from those presented by our patients.

HE is an heterogeneous condition that can manifest with various clinical symptoms. The pathogenesis of HE is unclear. Proposed mechanisms include autoimmune CNS vasculitis and an autoimmune reaction to antigens shared by the thyroid and CNS (Ferracci *et al.*, 2003; Tsai *et al.*, 2007). We know that anti-thyroid antibodies are essential in the diagnosis of HE, but their levels do not correlate with the severity of neurological deficits (Castillo *et al.*, 2006). The role of anti-thyroid antibodies in epileptic seizures in HE is unknown. For these reasons, some authors have proposed to change the term "Hashimoto's encephalopathy" to "Steroid-Responsive Encephalopathy associated with Autoimmune Thyroiditis" (SREAT), underlying the importance of immunosuppressive therapy.

Cases of status epilepticus in HE are reported in *table 1*. The patients presented with variable types of status epilepticus, but all patients had associated psychiatric symptoms or confusion. Also, the clinical prognosis was variable and often influenced by the timing of steroid therapy administration.

In our cases, video-EEG monitoring was mandatory in order to diagnose the presence of paroxysmal

episodes of altered consciousness featuring an episode of non-convulsive status epilepticus. It should be underlined that for all patients with seizures and confusion, a video-EEG recording should be recommended (Meierkord and Holtkamp, 2007). In particular, the EEG must be sufficiently long and detailed to record seizures from their onset and to record from anterior frontal regions in order to differentiate between partial and generalised NCSE, such as typical or atypical absence status (Thomas *et al.*, 1992; Kudo *et al.*, 1995; Thomas *et al.*, 1999). EEG features in our patients support a frontal origin of the seizures. Indeed, in both patients, ictal EEG at the onset of the episodes was characterised by bilateral spike-and-wave discharges with focal distribution on the frontal leads (Patient 1) or with frontal predominance (Patient 2). Later, during the evolution of seizures, spike-and-wave discharges showed a diffuse spreading to configure an episode of NCSE indistinguishable from absence status. The electroclinical picture of our patients is indeed very similar to cases of NCSE of frontal origin described by Thomas *et al.* (1999), characterised by progressive reduction in contact and reactivity. It should be noted that in our cases, as well as in other patients described in the literature, the differentiation of the focal origin of the status, with respect to generalised forms of non-convulsive status, is difficult. In this respect, several authors (Niedermeyer *et al.*, 1979; Kudo *et al.*, 1995; Thomas *et al.*, 1999) have emphasized the similarities between NCSE of frontal origin and absence status, especially when it occurs in patients without known epilepsy. In particular, the transformation from NCSE with frontal discharges to absence status with bilateral synchronous paroxysmal discharges has been reported. Secondary bilateral synchrony of frontal discharges that may originate in the fronto-polar or parasagittal areas of the frontal lobe is the most likely explanation. In conclusion, the presented patients underline that non-convulsive status epilepticus could be considered a special manifestation at the onset of HE. Screening of serum anti-thyroid antibodies in such cases is indicated since the early recognition and steroid treatment initiation may lead to a favourable prognosis, as reported in other conditions with recurrent seizures in which autoimmune mechanisms are thought to have a major role (such as paraneoplastic or non-paraneoplastic encephalopathy). More controversial is the necessity to continue the steroid treatment chronically. Indeed, some authors described recurrence of encephalopathy after the suspension of steroid therapy (Ferlazzo *et al.*, 2006), as in Patient 1. However, the necessity of long-term immuno-modulatory therapy is questionable because there is no evidence that it may prevent recurrence and it also has potential serious side effects (Marshall and Doyle, 2006). □

**Table 1.** Clinical features of status epilepticus in Hashimoto's Thyroiditis.

Reference	Age/Sex	Semiology	Other symptoms	EEG findings	MRI	CSF	Thyroid function	Ab anti-TPO	Ab anti-TG	Clinical evolution
Duffey P. <i>et al.</i> , 2003	40/m	GCSE	Tremor, confusion	Bi-frontal, generalized	n.a.	High protein level	Subclinical Hypo	Elevated	—	Death
McKeon A. <i>et al.</i> , 2004	61/f	GASE, myoclonus	Hallucination, confusion	Bi-frontal, generalized	Normal	Normal	Subclinical Hypo	Elevated	—	Remission
Aydin-Ozemir Z. <i>et al.</i> , 2006	37/f	EPC	n.a.	n.a.	Bilat TL	n.a	n.a.	Elevated	Elevated	Remission
Ferlazzo E. <i>et al.</i> , 2006	41/m	GCSE	Confusion, tremor	Bi-frontal, generalized	Normal	High protein level	Hypo	Elevated	Elevated	Recurrent
Striano P. <i>et al.</i> , 2006	27/f	GCSE, myoclonus	Psychosis	Bi-frontal	Normal	High protein level	Subclinical Hypo	Elevated	Elevated	Death
Tsai M. <i>et al.</i> , 2007	16/f	CPSE	Psychosis, confusion	Right temporal	Right TL	Normal	Mild Hyper	Elevated	Elevated	Remission
Monti G. <i>et al.</i> , 2011	51/f	NCSE	Psychosis, confusion	Bi-frontal, generalized	Normal	Normal	Normal with L-tyroxin therapy	Elevated	Elevated	Recurrent
Monti G. <i>et al.</i> , 2011	66/m	NCSE	Confusion	Bi-frontal, generalized	Normal	Normal	Subclinical Hypo	Elevated	Elevated	Remission

GCSE: generalized convulsive status epilepticus; GASE: generalized absence status epilepticus; EPC: epilepsy partialis continua; CPSE: complex partial status epilepticus; NCSE: non convulsive status epilepticus; TL: temporal lobe; Hypo: hypothyroidism; Hyper: hyperthyroidism.

**Disclosure.**

This work was supported by a grant of the Emilia-Romagna Region, Italy (project title: Mechanism, diagnosis and treatment of drug-resistant epilepsy; Area 1a Innovative Research). None of the authors has any conflict of interest to disclose.

**Legends for video sequences****Video sequence 1**

Beginning of seizure. The patient is feeling tired, but she is responsive. The examiner asks the patient to say her surname and to grasp her hand. The patient performs simple tasks correctly.

**Video sequence 2**

Three minutes from seizure onset. The patient is slow but responsive. She is staring but able to respond correctly to the examiner's questions ("How do you feel?", "Can you tell me your husband's name?", "Can you count aloud from one to ten?").

**Video sequence 3**

Seven minutes from seizure onset. The patient presents motionless staring and she is unresponsive to questions ("Do you feel asleep?", "Tell me your husband's name"). She is unable to name objects (the cues shown by the examiner) and to carry out orders ("Close your eyes", "Grasp my hand").

**Video sequence 4**

End of seizure (12 minutes from onset). The patient becomes responsive, she is able to denominate objects (a ball, a bottle of water) and she is oriented (she correctly says where she lives).

**Key words for video research on [www.epilepticdisorders.com](http://www.epilepticdisorders.com)**

*Etiology:* Hashimoto's thyroiditis

*Phenomenology:* status epilepticus (non convulsive), behavior (altered), hallucinations (visual)

*Localization:* —

*Syndrome:* epileptic encephalopathy not otherwise classified

**References**

- Aydin-Ozemir Z, Tuzun E, Baykan B, et al. Autoimmune thyroid encephalopathy presenting with epilepsy partialis continua. *Clin Electroencephalogr Neurosci* 2006; 37: 204-9.
- Castillo P, Woodruff B, Caselli R, et al. Steroid-responsive encephalopathy associated with autoimmune thyroiditis. *Arch Neurol* 2006; 63: 197-202.
- Chong J, Rowland L, Utiger R, et al. Hashimoto Encephalopathy. Syndrome or Myth? *Arch Neurol* 2003; 60: 164-171.
- Duffey P, Yee S, Reid IN, et al. Hashimoto's encephalopathy: postmortem findings after fatal status epilepticus. *Neurology* 2003; 61: 1124-6.
- Ferlazzo E, Raffaele M, Mazzu I, et al. Recurrent status epilepticus as the main feature of Hashimoto's encephalopathy. *Epilepsy Behav* 2006; 8: 328-30.
- Ferracci F, Moretto G, Candeago RM, et al. Antithyroid antibodies in the CSF. Their role in the pathogenesis of Hashimoto's encephalopathy. *Neurology* 2003; 60: 712-4.
- Kudo T, Sato K, Yagi K, Seno M. Can absence status epilepticus be of frontal lobe origin? *Acta Neurol Scand* 1995; 92: 472-7.
- Marshall GA, Doyle JJ. Long-term treatment of Hashimoto's encephalopathy. *J Neuropsychiatry Clin Neurosci* 2006; 18: 1.
- McGinley J, McCabe DJ, Fraser A, et al. Hashimoto's encephalopathy; an unusual cause of status epilepticus. *Irish Med J* 2000; 93: 118.
- McKeon A, McNamara B, Sweeney B. Hashimoto's encephalopathy presenting with psychosis and generalized absence status. *J Neurol* 2004; 251: 1025-7.
- Meierkord H, Holtkamp M. Non-convulsive status epilepticus in adults: clinical forms and treatment. *Lancet Neurol* 2007; 6: 329-39.
- Niedermeyer E, Fineyre F, Riley T, et al. Absence status (petit mal status) with focal characteristics. *Arch Neurol* 1979; 36: 417-21.
- Thomas P, Beaumanoir A, Genton P, et al. "De novo" absence status. *Neurology* 1992; 42: 104-10.
- Thomas P, Zifkin B, Migneco O, et al. Nonconvulsive status epilepticus of frontal origin. *Neurology* 1999; 52: 1174-83.
- Tsai M, Lee L, Chen S, et al. Complex partial status epilepticus as a manifestation of Hashimoto's encephalopathy. *Seizure* 2007; 16: 713-6.
- Striano P, Pagliuca M, Andreone V, et al. Unfavourable outcome of Hashimoto encephalopathy due to status epilepticus. One autopsy case. *J Neurol* 2006; 253: 248-9.