

Levetiracetam-induced thrombocytopenia in a patient with status epilepticus

Jonguk Kim, Jung-Won Shin

Department of Neurology, CHA Bundang Medical Center, CHA University, Seongnam, Korea

Received September 22, 2016; Accepted November 25, 2016

ABSTRACT – Levetiracetam has broad-spectrum activity in epilepsy. In contrast to phenytoin, levetiracetam has an ideal pharmacokinetic profile without any severe haemodynamic side effects and therefore intravenous loading of levetiracetam is commonly used in adult patients with status epilepticus, especially those who have medical problems. However, levetiracetam-induced serious adverse effects, such as thrombocytopenia and pancytopenia, have been reported in the literature. Here, we describe a case of status epilepticus after cardiac arrest treated with levetiracetam in which severe thrombocytopenia developed and was successfully managed by discontinuation of levetiracetam. Our report aims to increase awareness of this rare cause of thrombocytopenia among clinicians and provide a review of the literature.

Key words: levetiracetam, thrombocytopenia, status epilepticus

Levetiracetam (LEV) has broad-spectrum activity in epilepsy and is used to control generalized and focal seizures (Shorvon *et al.*, 2013). It has the characteristics ideally expected of an antiepileptic drug (AED); good bioavailability, rapid achievement of steady-state concentrations, linear kinetics, minimal protein binding, and minimal metabolism (Patsalos, 2000). Recent studies have suggested that intravenous LEV shows non-inferior efficacy when compared with intravenous valproic acid or phenytoin. In addition, it does not have any severe side effects, such as haemodynamic disturbances

or thrombocytopenia with hepatotoxicity in status epilepticus (Chakravarthi *et al.*, 2015; Lang *et al.*, 2015). Therefore, LEV is easy to use in clinical practice, especially in adult patients who take other drugs for medical problems. Hence, intravenous loading of LEV is commonly used as therapy in status epilepticus. However, LEV-induced serious adverse effects, such as thrombocytopenia and pancytopenia, have been reported. Here, we report a case of status epilepticus after cardiac arrest treated with levetiracetam in which severe thrombocytopenia developed.

Correspondence:

Jung-Won Shin
Department of Neurology,
CHA Bundang Medical Center,
CHA University, 59 Yatap-dong,
Bundang-gu, Seongnam-si,
Gyeonggi-do 463-712, Korea
<limitsum@gmail.com>

Case study

The patient was a 77-year-old female admitted to the hospital due to ischaemic colitis with haematochezia. She had a history of hypertension, stroke, cancer of the right lung (post-surgery status), asthma, and atrial fibrillation that was treated with rivaroxaban. After management of gastrointestinal problems, she underwent cardiac surgery for left atrial appendage closure, as she should have discontinued an anticoagulant due to recent bleeding. After perioperative infusion of midazolam, the heart rate decreased and progressed to asystole. Chest compressions with mask ventilation were immediately performed, along with repeated intravenous injection of atropine (total dose: 1.5 mg) and epinephrine (total dose: 3 mg). After 15 minutes of cardiopulmonary resuscitation, the cardiac rhythm returned to sinus rhythm, and the femoral pulse became palpable. After the operation, her consciousness did not recover, with stupor to semi-coma, however, spontaneous respiration recovered with intact brainstem function. The next day, she had a recurrent focal seizure with jerking movements of the left arm and legs, and there was no recovery of consciousness after resuscitation. Video-EEG monitoring was performed and showed frequent ictal discharge spreading to the right temporo-occipital

areas, consistent with a diagnosis of status epilepticus. Intravenous LEV was initially administered at a loading dose of 2,000 mg, followed by 1,000 mg administration twice daily, without complete resolution of EEG abnormalities. The estimated glomerular filtration rate (eGFR) was 73.9 ml/min/1.73 m², with 15.8 mg/dl BUN and 0.6 mg/dl creatinine at the time of initial loading of LEV. Topiramate (200 mg) and a 10-mg/kg loading dose of intravenous phenobarbital were added. Upon improvement of the ictal discharge on the EEG, and with recovered consciousness, the patient was treated with topiramate (100 mg) and LEV (750 mg), twice daily, and with phenobarbital (30 mg), thrice daily, as this was deemed more appropriate. Platelet count was $76 \times 10^3/\mu\text{l}$ (reference: $130\text{--}370 \times 10^3/\mu\text{l}$) at the time of LEV initiation and dropped to $14 \times 10^3/\mu\text{l}$ after two weeks. At that time, the patient was taking cilostazol (200 mg), lansoprazole, and acetylcysteine for one month, and a salbutamol nebulizer was also administered due to asthma. Vancomycin was administered for pneumonia, although this was discontinued due to its association with the induction of thrombocytopenia. However, the platelet count decreased continuously. Next, LEV treatment was stopped four days after the discontinuation of vancomycin, resulting in the rapid and complete resolution of thrombocytopenia within a few days (*figure 1*). The patient received a platelet

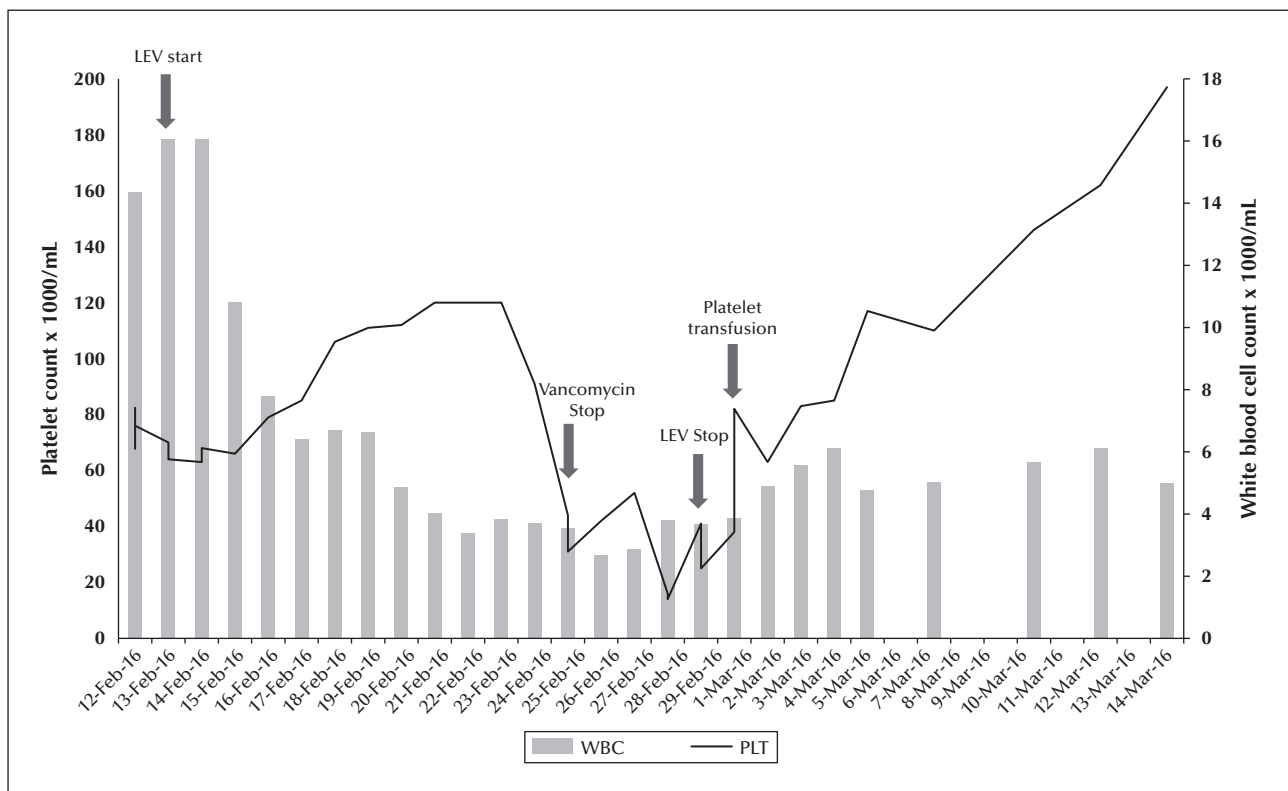


Figure 1. Graph depicting the relationship between platelet count and levetiracetam therapy. PLT: platelet; LEV: levetiracetam.

Table 1. Summary of levetiracetam-induced thrombocytopenia or pancytopenia reported in the literature.

Reference	Age	Sex	Underlying disease	Concomitant medication	Blood cell count prior to LEV	Time period thrombocytopenia noted after starting LEV	Nadir whole blood cell count	Adverse event related to LEV-induced thrombocytopenia or pancytopenia
Kimland <i>et al.</i> , 2004	49	M	Oligoastrocytoma, depression	Temozolomide, phenobarbital, phenytoin, sertraline, diazepam, oxazepam, betamethasone, vitamin B supplement, zolpidem	Pt: $314 \times 10^3/\mu\text{l}$ (measured the day after LEV was started)	20 days	Thrombocytopenia Pt: $7 \times 10^3/\mu\text{l}$	hematuria
Meschede <i>et al.</i> , 2008	64	F	Not described precisely, aetiology for symptomatic epilepsy	Levodopa, captopril, thiacid, rivastigmine, carbamazepine, valproic acid	Exact count not described Pt: $> 100 \times 10^3/\mu\text{l}$	3 days	Thrombocytopenia Pt: $5 \times 10^3/\mu\text{l}$	None
Peer Mohamed and Prabhakar, 2009	6	M	Cerebral venous thrombosis, mastoiditis	Phenytoin, heparin, warfarin	Exact count not described Pt: $> 100 \times 10^3/\mu\text{l}$	5 weeks	Thrombocytopenia Pt: $12 \times 10^3/\mu\text{l}$	Petechial rash on skin, mucosal hemorrhage
Oghladian <i>et al.</i> , 2010	50	F	Glioblastoma multiforme	Temozolomide, dexamethasone, ranitidine	Pt: $147 \times 10^3/\mu\text{l}$	30 days	Thrombocytopenia Pt: $27 \times 10^3/\mu\text{l}$	None
Sahaya <i>et al.</i> , 2010	35	M	AIDS, asthma, depression, MAC infection, hepatitis B virus infection	Clarithromycin, dapson, clonazepam, rifabutin, ritonavir, atazanavir, Truvada (emtricitabine/tenofovir), sertraline	Hb: 6.6-12.8 g/dl Pt: $69-230 \times 10^3/\mu\text{l}$ WBC: $1-6.3 \times 10^3/\text{ml}$	5 months	Thrombocytopenia Pt: $1 \times 10^3/\mu\text{l}$	Petechial rash in both lower extremities, hematuria, melena
Elouni <i>et al.</i> , 2009	76	F	Second ischaemic stroke	Clonazepam	Hb: 115 g/l Pt: $290 \times 10^3/\mu\text{l}$ WBC: $22.3 \times 10^3/\text{ml}$	2 days	Pancytopenia Hb: 7.8 g/dl Pt: $60 \times 10^3/\mu\text{l}$ WBC: $3 \times 10^3/\text{ml}$	None
Aydoğan <i>et al.</i> , 2012	16		Lafora disease (ICU care with the complaint of short breath)	Valproic acid	Hb: 8.4 g/dl Pt: $280 \times 10^3/\mu\text{l}$ WBC: $7.2 \times 10^3/\text{ml}$	4 days	Pancytopenia Hb: 6.2 g/dl Pt: $7 \times 10^3/\mu\text{l}$ WBC: $2.2 \times 10^3/\text{ml}$	None
Alzahrani <i>et al.</i> , 2015	79	F	Glioblastoma multiforme, hypertension, diabetes	Dexamethasone, pantoprazole, enoxaparin	Exact count not described; whole blood cell counts were within normal limits.	5 days	Pancytopenia Exact count not described	Melena

Pt: platelet; WBC: white blood cell; Hb: haemoglobin; MAC: Mycobacterium avium complex; ICU: intensive care unit.

transfusion (six pints) during the period of thrombocytopenia. Physical examination and general laboratory findings were stable and without any evidence of active bleeding during this time.

Discussion

LEV has proven to be a widely popular AED that is well tolerated via both the oral and intravenous routes in epilepsy and status epilepticus (Koubeissi *et al.*, 2008). In doses up to 3,000 mg/day, fatigue is seen in 6-27% of patients, somnolence in 11-40%, drowsiness in 12-25%, headache in 2-14%, dizziness in 2-15%, nausea in 6%, psychiatric side effects in 5-14%, diarrhoea in 4%, and imbalance in 1-7% in placebo-controlled and open-label studies (Abou-Khalil *et al.*, 2003). Owing to these mild side effects and the favourable pharmacokinetics of LEV, many clinicians choose this treatment for epilepsy and status epilepticus. However, since the 2000s, thrombocytopenia or pancytopenia related to LEV has been reported. In the case presented here, the temporal relationship between the onset of thrombocytopenia and LEV therapy was evident. Mild thrombocytopenia existed prior to LEV administration in our patient, but worsened under LEV therapy and resolved rapidly when LEV was discontinued. While pancytopenia or thrombocytopenia are less frequent than other adverse events, they can develop into severe medical problems. Therefore, caution is warranted with regards to such adverse events when using LEV.

When previously reported cases were reviewed (table 1), it was noted that almost all patients were in an immunocompromised state before LEV administration. Two cases, including the present case, showed haematological instability before LEV therapy. In the present case, the patient had mild thrombocytopenia in the range of $68-79 \times 10^3/\mu\text{l}$ following cardiac arrest. In previous case reports, including the present case, thrombocytopenia within a median of 12 days (range: 2-150 days) prior to the start of LEV was documented, and four out of eight cases (50%) had thrombocytopenia-related adverse events. Considering that almost all patients were in an immunocompromised state, bleeding events might therefore increase the rate of mortality and hospitalisation.

The mechanism of LEV-induced thrombocytopenia is unclear. Drug-induced thrombocytopenia is a well-known phenomenon that occurs due to either bone marrow suppression or immune-mediated peripheral destruction (Kenney and Stack, 2009). LEV-induced thrombocytopenia is suggested to occur due to immune-mediated peripheral destruction. In one report, a blood sample was analysed using the MAIPA (monoclonal antibody immobilization of platelet antigen) technique, which is used to screen for irregular

antibodies in the presence of LEV. Irregular antibodies reactive to platelets have been observed in the presence of LEV (Kimland *et al.*, 2004). Taking all of these cases into consideration, an immunocompromised state might heighten the risk of immune-mediated thrombocytopenia.

While LEV can induce severe thrombocytopenia, this has been shown to be reversible. Therefore, platelet counts should be checked within at least two weeks of starting administration, and clinicians should be aware of the possibility of LEV-induced blood dyscrasia. Closer observation of patients in an immunocompromised state is particularly warranted in order to check for alterations in whole blood cell count. □

Supplementary data.

Summary didactic slides are available on the www.epilepticdisorders.com website.

Disclosures.

The authors have no conflict of interest to declare.

References

- Abou-Khalil B, Hemdal P, Privitera M. An open-label study of levetiracetam at individualised doses between 1000 and 3000 mg day⁻¹ in adult patients with refractory epilepsy. *Seizure* 2003; 12(3): 141-9.
- Alzahrani T, Kay D, Alqahtani SA, Makke Y, Lesky L, Koubeissi MZ. Levetiracetam-induced pancytopenia. *Epilepsy Behav Case Rep* 2015; 4: 45-7.
- Aydoğan H, Yalçın S, Karahan MA, Büyükfrat E. Pancytopenia associated with levetiracetam treatment in Lafora's disease. *Blood Coagul Fibrinolysis* 2012; 23(2): 175.
- Chakravarthi S, Goyal MK, Modi M, Bhalla A, Singh P. Levetiracetam versus phenytoin in management of status epilepticus. *J Clin Neurosci* 2015; 22(6): 959-63.
- Elouni B, Ben Salem C, Biour M. Levetiracetam-induced pancytopenia. *Ann Pharmacother* 2009; 43(5): 985.
- Kenney B, Stack G. Drug-induced thrombocytopenia. *Arch Pathol Lab Med* 2009; 133: 309-14.
- Kimland E, Hojeberg B, von Euler M. Levetiracetam-induced thrombocytopenia. *Epilepsia* 2004; 45(7): 877-8.
- Koubeissi MZ, Amina S, Pita I, Bergey GK, Werz MA. Tolerability and efficacy of oral loading of levetiracetam. *Neurology* 2008; 70(22Pt2): 2166-70.
- Lang N, Esser W, Evers S, *et al.* Intravenous levetiracetam in clinical practice - results from an independent registry. *Seizure* 2015; 29: 109-13.
- Meschede A, Runge U, Sabolek M. Thrombocytopenia during levetiracetam therapy. *Epilepsy Res* 2008; 80(1): 91-2.
- Oghlakan R, Nock C, Koubeissi M. A case of levetiracetam-induced thrombocytopenia. *Epileptic Disord* 2010; 12(4): 335-7.

Patsalos PN. Pharmacokinetic profile of levetiracetam: toward ideal characteristics. *Pharmacol Ther* 2000; 85(2): 77-85.

Peer Mohamed B, Prabhakar P. Thrombocytopenia as an adverse effect of levetiracetam therapy in a child. *Neuropediatrics* 2009; 40(5): 243-4. Erratum in: *Neuropediatrics* 2009; 40(5): 244.

Sahaya K, Goyal MK, Sarwal A, Singh NN. Levetiracetam-induced thrombocytopenia among inpatients: a retrospective study. *Epilepsia* 2010; 51(12): 2492-5.

Shorvon S, Guerrini R, Cook M, Lhatoo SD. In: *Oxford Textbook of Epilepsy and Epileptic Seizures*. Kennard C. Oxford, 2013.