

Insight into the precuneus: a novel seizure semiology in a child with epilepsy arising from the right posterior precuneus

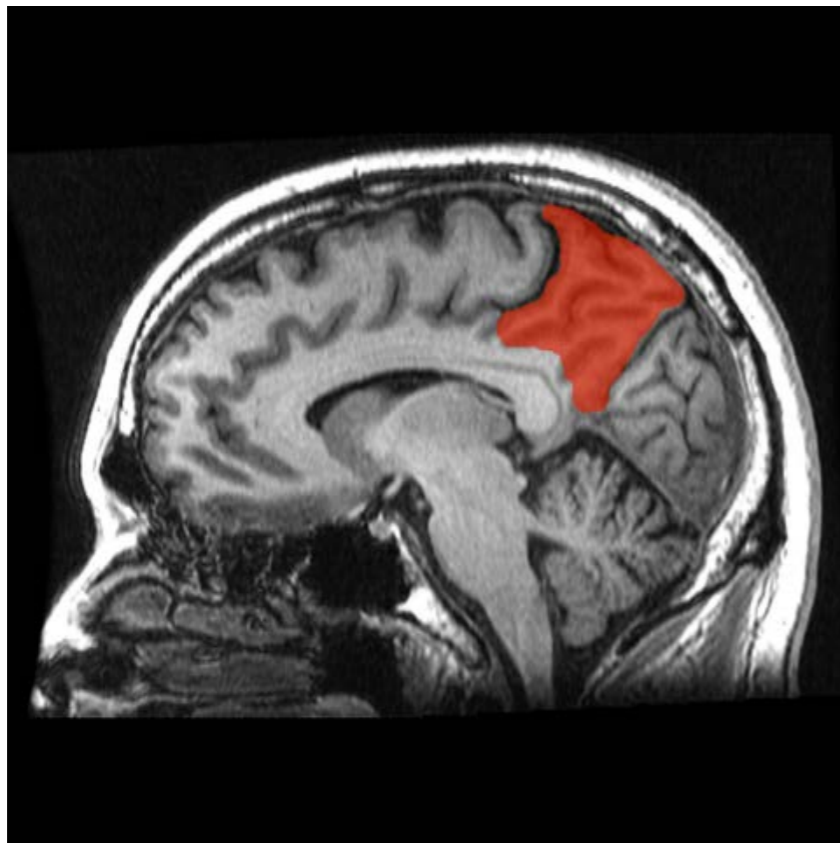
Janette Mailo, Richard Tang-Wai

Division of Pediatric Neurology, University of Alberta, Canada

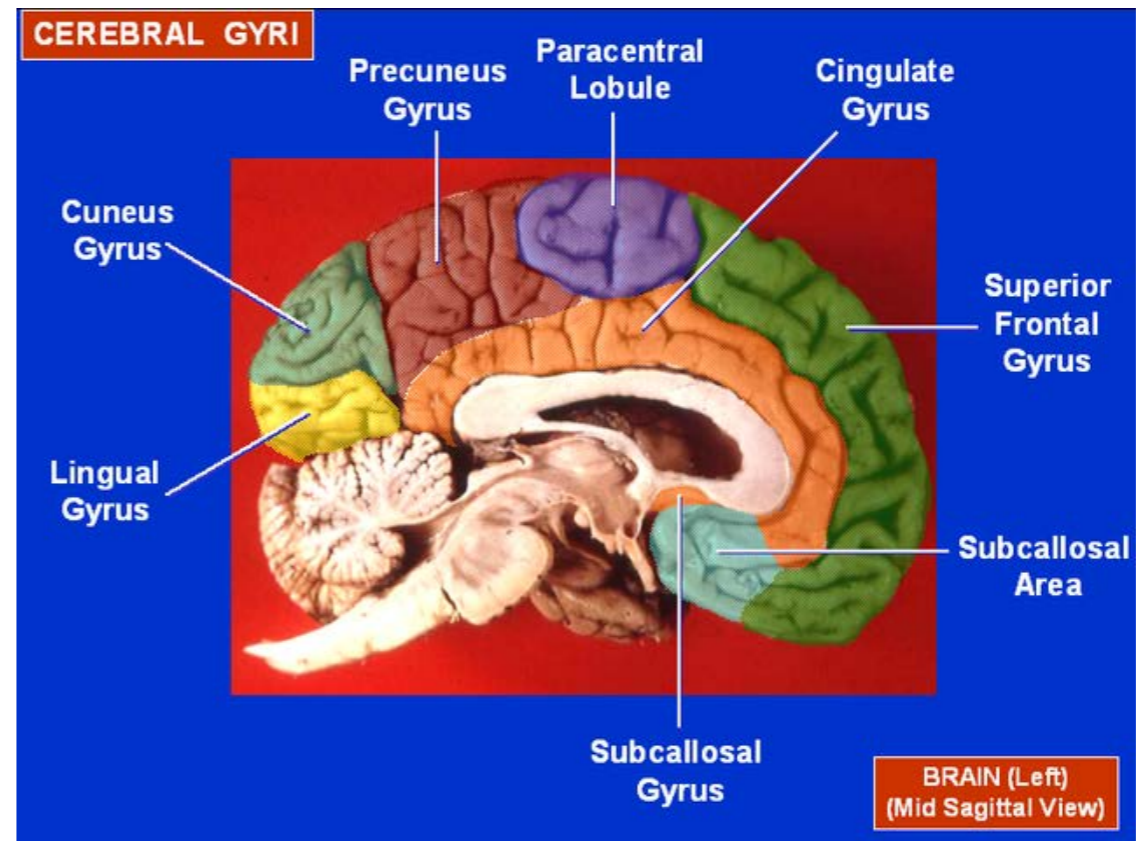
Received January 13, 2015; Accepted May 19, 2015

Insight into the precuneus: a novel seizure semiology in a child with epilepsy arising from right posterior precuneus

Precuneus: Anatomical location



- Sagittal MRI, precuneus in red. (Geoff B Hall)



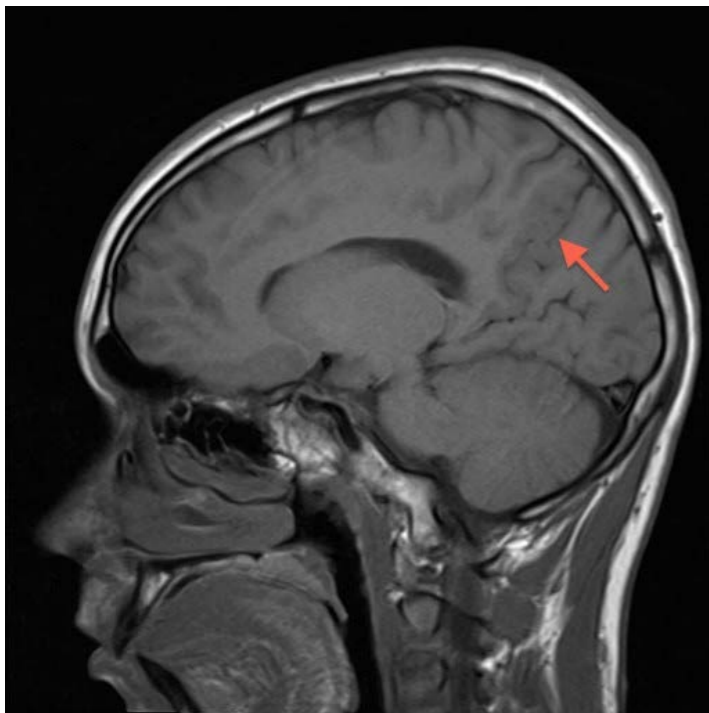
- Cerebral Gyri - Medial Surface (John A Beal, PhD)

Precuneus: Function

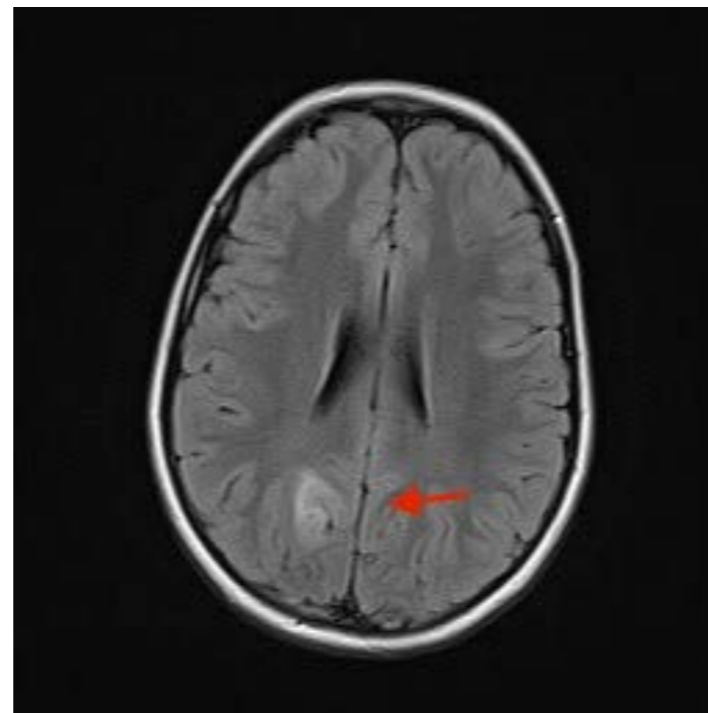
- Presumed role in wide spectrum of highly integrated tasks, including spatially-guided behaviour, visuo-spatial imagery and consciousness

Unusual seizure semiology arising from the posterior precuneus

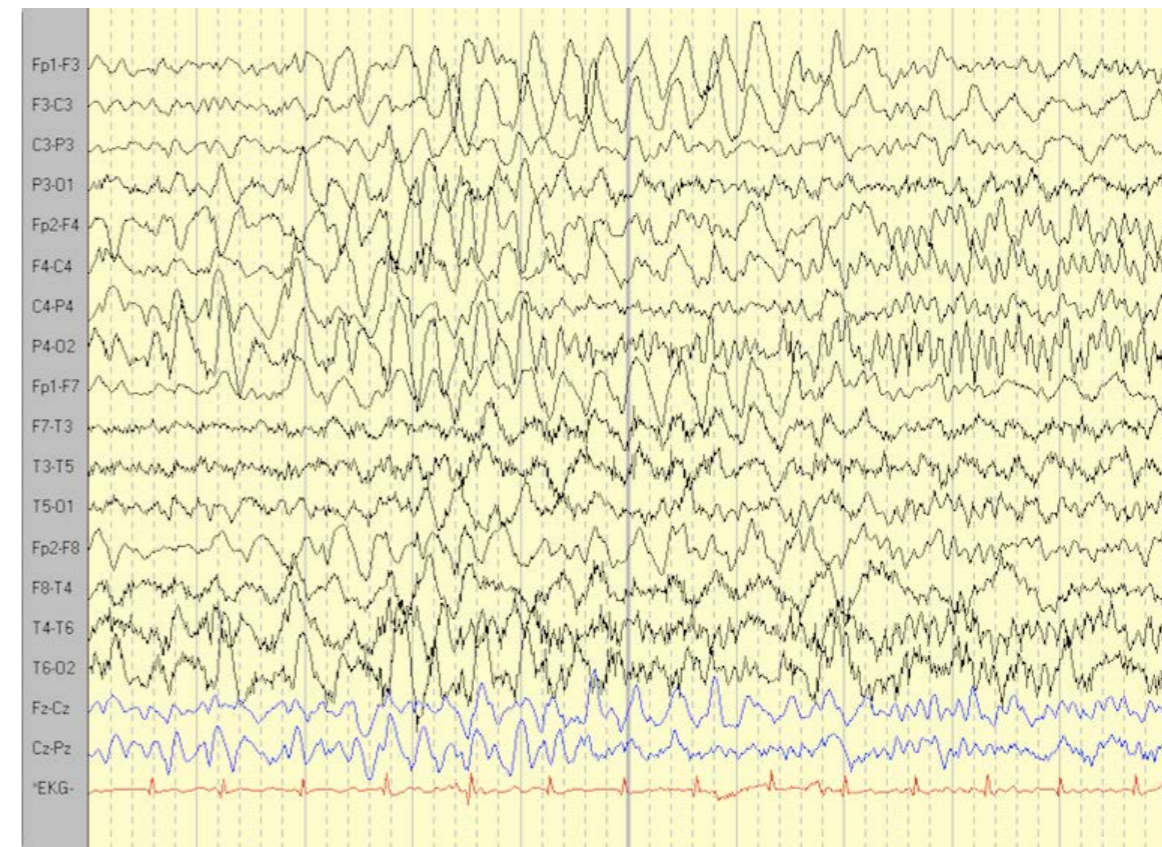
- Feeling of “wanting to move” and turning to the left with preserved awareness, and ability to answer the questions and turn to the right on command
- Reading-induced visual distortions with micropsia and macropsia



Sagittal T1 - lesion isointense with cortex and localized anterior to the parieto-occipital sulcus



Axial FLAIR - hyperintense heterogenous lesion in the mesial, right parietal region



Ictal EEG - polymorphic high-amplitude 3-4-Hz activity mixed with parieto-occipital spikes

Epilepsy arising from the posterior precuneus can improve our understanding of behavioural correlates of this under-investigated cortical region

- An ictal urge to move could represent the precuneus' role in
 - Motor imagery
 - Directing spatial information to be processed
 - Generating spatial information for imagined or planned body movement
 - Posterior precuneus' role in visual attention and visually-guided saccades
- Reading-induced visual distortion possibly represents the precuneus' role in multiple visual sensory integration systems
 - Oculomotor output processing
 - Smooth pursuit eye movements
 - Visuospatial imagery