

Ictal kissing: a release phenomenon in non-dominant temporal lobe epilepsy

Razi M. Rashid*, Katherine Eder*, Joshua Rosenow, Michael P. Macken, Stephan U. Schuele

Department of Neurology, Northwestern University, Chicago, IL, USA

Received June 3, 2010; Accepted September 21, 2010

ABSTRACT – *Background.* A variety of ictal automatisms with strong emotional elements have been described. Ictal kissing has not been well characterized and may provide useful clinical information and insight into the mechanisms of stereotyped ictal behaviour. *Methods.* Three of 220 patients (1.4%) admitted for video EEG monitoring between 7/2006 and 6/2009 with ictal kissing were identified. Clinical, neurophysiological and imaging data were reviewed and correlated. *Results.* All patients were right-handed women with a longstanding history and findings consistent with right temporal lobe epilepsy (TLE). Multiple habitual events were recorded for each patient, characterized by staring, oral automatisms and amnesia. In addition, partial preservation of responsiveness and speech were seen during seizures in all three patients. The first two patients showed kissing behaviour triggered by interactions during seizure testing. The last patient had six seizures overnight and developed spontaneous kissing behaviour in the ictal and post-ictal period of her later events, associated with hyperorality and sexual disinhibition. *Conclusion.* Our series supports the findings of two prior cases, of one male and one female, which reported IK behaviour associated with TLE and lateralizing to the non-dominant hemisphere. This behaviour has not been described in simple partial seizures or seen with electrical cortical stimulation suggesting that it represents a release phenomenon rather than activation of distinct symptomatogenic cortex. This is also supported by the fact that ictal kissing can occur within the spectrum of seizure-induced Kluver-Bucy syndrome and may extend into the post-ictal period. [Published with video sequences]

* These authors contributed equally to this work.

Key words: ictal emotions, ictal kissing, automatism, non-dominant hemisphere, temporal lobe epilepsy



Correspondence:

S. Schuele
Department of Neurology,
Northwestern University,
Abbott Hall # 1425,
710 North Lake Shore Drive,
Chicago, IL 60611, USA
<s-schuele@northwestern.edu>

Automatisms are defined as coordinated, repetitive motor activities, typically associated with impaired cognition and amnesia (Blume *et al.*, 2001). A variety of automatisms with strong emotional elements have been well-described during electrographic seizures, including sudden changes in facial expression seen with mimetic

automatisms, uncontrollable laughter in gelastic seizures, and crying in dacrycitic seizures (Arroyo *et al.*, 1993; Lenard, 1999; Meletti *et al.*, 2006). As ictal epileptic phenomena, gelastic and dacrycitic automatisms have high localizing value and are frequently associated with hypothalamic hamartomas (Kahane *et al.*, 2003).

doi: 10.1684/epd.2010.0337

In clinical practice, these peculiar phenomena should be distinguished from the more common emotional symptoms seen during non-epileptic psychogenic seizures (Bodde *et al.*, 2009). They should also be differentiated from the subjective emotional experiences reported during auras (Alvarez-Silva *et al.*, 2006; Aull-Watschinger *et al.*, 2008; Toth *et al.*, 2010), and from disturbances observed in the post-ictal period (Ito *et al.*, 2007; Kanner *et al.*, 2004).

Ictal kissing (IK) is a rare phenomenon during epileptic seizures which has been described in only two previous patients (Mikati *et al.*, 2005; Ozkara *et al.*, 2004). The clinical significance and neurophysiological mechanisms of IK remain poorly understood. We present a series of three patients with kissing as their prominent ictal manifestation.

Methods

Of 220 patients electively admitted to our Epilepsy Monitoring Unit (EMU) between 7/2006 and 6/2009, three (1.4%) were identified who had stereotypic kissing during electrographic seizure activity. Clinical, neurophysiological and imaging data were reviewed. All patients underwent video-EEG monitoring with a 64-channel scalp EEG recording system (Nihon Kohden, CA) using surface electrodes applied according to the International 10-20 system including additional anterior temporal electrodes. The topography and timing of electrographic seizure onset was determined by identification and localization of the initial ictal EEG change from baseline seen in association with a clinical event. Patients were tested during their seizures following a standardized protocol (Schuele *et al.*, 2009). All patients underwent a 1.5 T epilepsy protocol MRI with volume acquisition MPRAGE and coronal FLAIR sequences, fluoro-deoxyglucose positron-emission tomography (FDG-PPET) and neuropsychological testing as part of their presurgical workup. One patient who underwent surgical resection for non-lesional right TLE also had preoperative subtraction single photon emission computed tomography (SPECT) and magnetoencephalography (MEG). MEG data were acquired utilizing a 248-channel whole-head system (Magnes 3600, 4-D Neuroimaging®).

Results

Case 1

The first patient was a 39-year-old right-handed woman with a history of intractable partial seizures with secondary generalisation since the age of 33. Five antiepileptic treatments proved to be unsuccessful. A previous routine EEG and MRI showed no abnormalities. She had five

seizures while being monitored without anticonvulsant medication. The seizures began with an aura of nausea and tingling in her arms and legs bilaterally. This was followed by subtle change in responsiveness, chewing and lip-smacking. She was able to follow some commands and name objects during this time. All of her seizures lasted approximately one and a half minutes and were followed by post-ictal confusion and amnesia for the preceding event. She displayed ictal affectionate behaviour in two of her seizures.

In her second seizure she made a kissing motion towards the technician and then blew kisses repetitively at a phone that she was asked to identify. During her fourth seizure, while undergoing ictal SPECT injection, she held and kissed a technician's hand in an affectionate manner and then asked the technician to kiss her hand in return (*see video sequence 1*). Her ictal EEG was similar in all five events and showed fairly abrupt onset of rhythmic theta activity over the right temporal electrode chain, maximum at the midtemporal electrode, seen 5-10 seconds after the clinical seizure onset. Irregular delta slowing developed over the left hemisphere, 30 seconds after clinical onset. Post-ictal slowing was limited to the right hemisphere. Her affectionate behaviour started 50 seconds after seizure onset and ended abruptly 25 seconds later with the end of the electrographic seizure. Her inter-ictal EEG showed right anterior temporal sharp waves, on average, once every five minutes.

A repeat MRI with epilepsy protocol showed no intracranial abnormalities, with symmetric temporal lobes and hippocampi. FDG PET evaluation demonstrated hypometabolism in the right temporal region and subtraction SPECT revealed a congruent ictal hyperperfusion over the anterior temporal lobe on the right side. Magnetoencephalography localized the inter-ictal epileptiform activity to the right basal mid-temporal lobe (*figure 1*). She underwent a right temporal lobectomy in June 2009 with intraoperative electrocorticography demonstrating a very restricted irritative area over the anterior basal temporal lobe which was resected in its entirety. She is seizure-free during the 9 months of follow-up. Her surgical pathology showed cortical dysplasia type IIa (Palmini *et al.*, 2004).

Case 2

The second patient was a 46-year-old right-handed woman with a history of intractable epilepsy since the age of 26. She had partial seizures with secondary generalised convulsions, which persisted despite high doses of three antiepileptic medications. MRI showed increased T2/FLAIR signal involving the right hippocampus with mild associated volume loss, suggestive of right mesial temporal sclerosis (MTS). The patient was admitted for monitoring and experienced six of her typical seizures

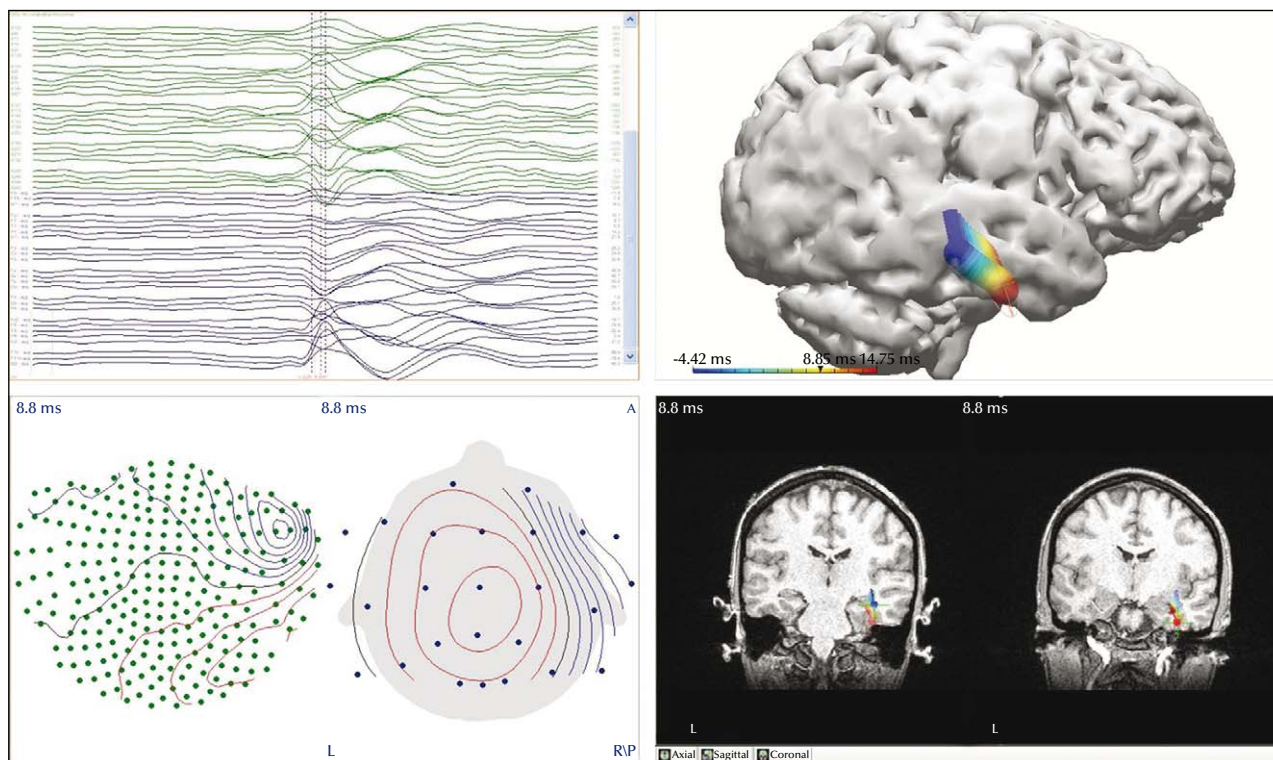


Figure 1. (Patient 1). MEG localized the inter-ictal epileptiform activity in the right basal mid-temporal lobe with anterior propagation. The left panels show the recorded MEG activity. Left upper panel: MEG channels; left lower panel: magnetic field distribution map. The right panels demonstrate the magnetic source co-registered to the patient's MRI. Right upper panel: three-dimensional head model; right lower panel: coronal high volume MRI acquisition. Note the anterior propagation of the magnetic field on the 3D model and the coronal MRI (courtesy of Dr John Ebersole).

lasting between 2.5–4 minutes each, while off medication. The events began with a facial expression of fear associated with whimpering, followed by automatisms of lip-smacking, picking at the bed sheets, fumbling with her right hand and left arm dystonic posturing. Her language was preserved during these events and she maintained a conversation with the staff testing her.

During her fourth seizure, she was noted to be markedly sexually disinhibited, hugging and attempting to kiss one of the male EEG technicians (see *video sequence 2*). The behaviour began after she was asked to raise her arms. She appeared to translate this motion into a request for a hug and pulled in the technician and hugged him, and then kissed him on the cheeks and tried to kiss him on the lips. She became very persistent, repeatedly requesting a kiss. The behaviour subsided abruptly with the end of the electrographic seizure two minutes later. Afterwards, she was slightly confused and amnesic for the event and her behaviour. The ictal EEG showed rhythmic theta activity over the right temporal region (*figure 2*) evolving into rhythmic delta activity which persisted for 2.5 minutes, associated with some irregular slowing over the left hemisphere. The display of affection started about

one minute after EEG seizure onset. Her inter-ictal EEG demonstrated intermittent runs of sharp waves over the right anterior temporal region activated by sleep. An ictal SPECT study during another of her events showed right anterior temporal hyperperfusion. She was offered a right anterior temporal resection but elected to continue medical therapy.

Case 3

The third patient was a 48-year-old right-handed woman with a history of right TLE since the age of 18 with predominantly complex partial seizures. Her seizures were intractable to fourteen different antiepileptic agents. At the time of admission she was maintained on high doses of three antiepileptic medications but continued to have breakthrough seizures three to five times per month. MRI showed right hippocampal volume loss and abnormal T2/FLAIR hyperintense signal, consistent with right MTS. During video EEG monitoring she had six complex partial seizures, each lasting about two minutes. Clinically, half of her events began with an aura consisting of a warm, rising sensation in her feet, followed by unresponsiveness and staring. This was followed by

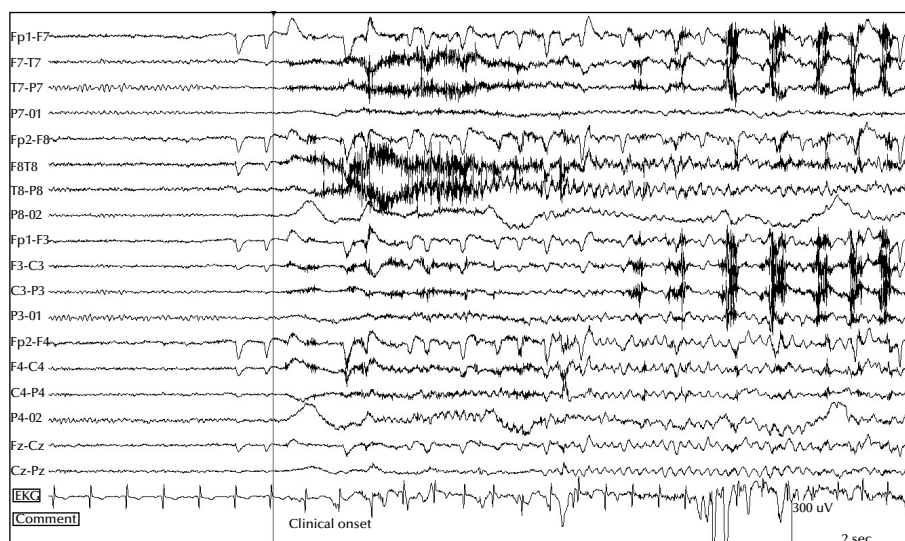


Figure 2. (Patient 2). A sudden arousal from drowsiness is seen, followed within two seconds by a rhythmic right temporal theta pattern. Ten seconds after onset, a repetitive EMG artefact is seen over the left hemispheric electrodes coinciding clinically with oral and manual automatisms. A similar electrographic onset was seen in all of her six recorded seizures.

repetitive leg movements and fumbling with her right hand, while her left arm maintained a fixed posture. She had prominent oral automatisms. She was intermittently able to follow some commands during the seizure and to speak in short sentences but would often revert to her native language. After the event, she appeared confused for a prolonged period of time and was amnesic for the event. She had urinary incontinence in two of the episodes. EEG in all six events demonstrated an abrupt onset of highly rhythmic theta activity over the right temporal region, which then spread to the left temporal area within 10 seconds, displaying a similar high voltage theta activity (*figure 3*), then gradually evolving into rhythmic generalised sharply contoured delta slowing. Six seizures were recorded, occurring overnight within a period of 14 hours. Ictal kissing was seen during seizures 3, 4 and 6 (*see video sequences 3*). Seizure 5 evolved into a brief secondary generalised convulsion. In seizures 3 and 4, the IK appeared to be triggered by environmental cues. She blew kisses in response to a command to stick out her tongue and also to blew a kiss towards a pen she was asked to identify. In seizure 4, she started to suck her thumb spontaneously and stopped interacting with the technician during that time. In seizure 6, the kissing behaviour was seen at the clinical onset, preceding the first EEG changes by 1.5 seconds. Later during this event, she blew a kiss towards a nurse, and blew kisses towards a technician two minutes after the end of the electrographic event. The technical staff reported that after the last event, she began blowing kisses at anyone who entered the room and repeatedly tried to pull the technicians towards her to kiss them. This behaviour slowly resolved over the next 24 hours as her medications

were restarted and she remained seizure free. The patient was unaware of her ictal and post-ictal behaviour. Her partner reported having witnessed similar episodes of affectionate behaviour with her seizures at home. She was offered a right anterior temporal resection but elected to continue medical therapy.

Discussion

We present three patients with ictal kissing (IK) and seizures arising from the non-dominant temporal lobe, characterized by partially preserved consciousness and speech but complete amnesia for the event. The affectionate behaviour was only seen in a subset of the recorded events and appeared to be triggered by environmental cues. Two of our patients demonstrated IK only after being given some form of external stimulus and the behaviour stopped abruptly with the end of the electrographic seizure activity. One patient, after having six seizures overnight and an electrographic pattern demonstrating rapid bilateral spread of the ictal discharge to both temporal lobes, developed self-initiated IK extending into the post-ictal period with hyperorality and sexual disinhibition consistent with post-ictal Kluver-Bucy syndrome.

Only two cases of kissing as an ictal phenomenon have been previously reported in the literature, both in the context of non-dominant TLE (Mikati *et al.*, 2005; Ozkara *et al.*, 2004). The first was published in 2004 and described a 25-year-old right-handed woman with a history of intractable partial epilepsy related to right MTS, who demonstrated affectionate kissing behaviour as well as repetitive religious speech during her right

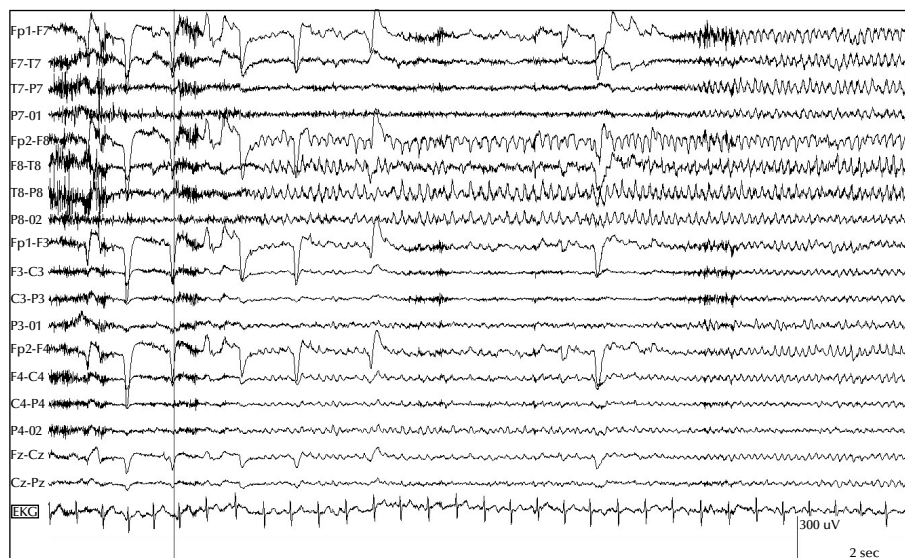


Figure 3. (Patient 3). Clinical onset consisted of a sudden kiss, followed by circular, semi-purposeful hand movements (see video sequence 3). The blue marker annotates the moment of the kiss with the associated EMG artefact. EEG seizure onset is seen over the right temporal region 1.5 seconds later. Evolution of ictal theta activity is noted 10 seconds later over the left temporal chain as well. This rapid spread of ictal activity to the left side was seen for all her six recorded seizures.

temporal seizures. After a period of religious exclamations, this patient was witnessed to compulsively kiss her own hand as well as the hands of other people around her. The second case was a 24-year-old right-handed man with a history of right TLE associated with a right temporal low grade glioma (Mikati *et al.*, 2005). His right temporal seizures were characterized by an abdominal aura followed by an altered level of awareness, spitting, and affectionate hugging and kissing behaviour mostly directed towards his mother but in some events also the medical staff. Both patients had preserved responsiveness and ictal speech despite the presence of automatisms and amnesia for the event. In our experience and in these previous cases, the preservation of responsiveness seemed necessary for patients with IK to interact sufficiently with the environment to perform these complex behaviours and lateralized the phenomenon to the non-dominant hemisphere (Ebner *et al.*, 1995).

The neurophysiological mechanisms of ictal automatisms in general are not uniform. Jasper (1964) speculated almost half a century ago that automatisms may represent either a reaction to internal stimuli, activation of a specific motor program, or release of behaviour by removal of inhibitory control. Examples for the first mechanism would include swallowing movements in response to excess salivation during oro-alimentary automatisms. The second mechanism refers to cortical activation of a functionally localized behaviour. Such behaviour can be seen in an awake and responsive patient as part of a motor seizure and can be reproduced by electrical cortical stimulation. Most of these motor phenomena consist of simple motor phenomena including clonic, tonic or

myoclonic movements. The complex, stereotyped and semi-purposeful behaviour consistent with automatisms is usually not seen in awake patients who are able to recall the behaviour. However, there are a few cases reported in which oral automatisms have been induced by electrical cortical stimulation of the insular operculum, the amygdala and hippocampus and more recently from the mesial frontal lobe while the patient was awake (Maestro *et al.*, 2008; Penfield and Jasper, 1954). These reports suggest that at least some oral automatisms could be related to a specific functional cortical representation similar to emotional automatisms, e.g. laughter and crying, which have a highly localizing value for the hypothalamic area and have been reproduced during electrical cortical stimulation and noted during the awake phase of a seizure (Arroyo *et al.*, 1993; Kahane *et al.*, 2003; Stefan *et al.*, 2004).

As a third mechanism, Jasper proposed that ictal automatisms may present as a release phenomenon. This is supported by the fact that similar behavioural stereotypies occur in a variety of neurological conditions associated with diminished inhibitory behavioural control, including mental retardation, schizophrenia and dementia. Similar to ictal stereotypies, they commonly present with chewing, lip smacking, fumbling, tapping, rubbing or other semi-purposeful, repetitive movements (Watts and Koller, 2004). Epileptic seizures cause dysfunction not only through excitation but also inhibition of neuronal activity which extends beyond the area directly involved in the electrographic seizure activity, leading to behavioural dysfunction or disinhibition. Inhibition of neuronal activity extends into the post-ictal period and

Table 1. Patient clinical data and two prior case reports.

	Patient 1	Patient 2	Patient 3	Case 1 (Ozkara <i>et al.</i> , 2004)	Case 2 (Mikati <i>et al.</i> , 2005)
Age (yrs)	39	46	48	25	24
Gender	F	F	F	F	M
Age at onset (yrs)	33	26	18	3.5	10
Handedness	R	R	R	R	R
Imaging findings	MRI: no abnormality FDG-PET: R temporal hypometabolism Subtraction SPECT: ictal hyperperfusion over R medial temporal lobe	MRI: R mesial temporal sclerosis	MRI: R mesial temporal sclerosis	MRI: R mesial sclerosis	MRI: R mesial temporal lesion Seizure free after second anterior temporal resection Pathology: low grade astrocytoma
Number of events recorded (number with IK)	5 (2)	6 (1)	6 (3)	4 (4)	13 (7)
EEG findings					
<i>Inter-ictal:</i>	SW, R temporal	SW, R temporal	SW, R > L temporal	SPK, R > L temporal	Unknown
<i>Ictal:</i>	Rhythmic theta activity maximum at F8-T8 and SP2, evolving into a high amplitude 7Hz rhythm maximum over the R temporal region	Rhythmic theta activity beginning in the R temporal region, spreading to the frontal lobes (R > L) and evolving into polymorphic slowing	Theta activity in the R frontotemporal region evolving into rhythmic generalised slowing	Semirhythmic theta activity over the right fronto-temporal region, evolving to bifrontotemporal slowing	Rhythmic theta activity maximum F8 and SP2, in some seizures evolving to bilateral frontotemporal slowing with right-sided predominance

Yrs: years; R: right; L: left; F: female; SW: sharp waves; SPK: spikes.

can cause ongoing release of behaviour control and, not uncommonly, post-ictal automatisms (Devinsky *et al.*, 1994; Rasonyi *et al.*, 2006). Disinhibited, sexual behaviour associated with epilepsy has been mostly described during the post-ictal state (Arnedo *et al.*, 2009; Blumer, 1970; Ellison, 1982).

Ictal kissing may be related to a combination of these mechanisms. It is unlikely to be a localizable phenomenon related to a specific cortical functional representation since it has not been described with electrical cortical stimulation studies or noted during seizures in fully awake patients. Subjective feelings of affection, elation and happiness, sexual arousal, and orgasm have been reported as epileptic auras, reproduced with electrical cortical stimulation and appear to localize to the non-dominant temporoparietal region (Asheim Hansen and Brodtkorb, 2003; Aull-Watschinger *et al.*, 2008; Heath, 1972; Janszky *et al.*, 2002; Janszky *et al.*, 2004). Positive emotional experiences are associated with the temporo-basal area and tend to lateralize to the right hemisphere (Fogarasi *et al.*, 2005; Fogarasi *et al.*, 2007; Holowka and Petitto, 2002; Stefan *et al.*, 2004). However, none of these reported cases show overt affectionate or sexual behaviour, confirming that a certain degree of behavioural disinhibition is necessary to act upon such an internal

stimulus. Patient 3 differs from our two other patients in that she demonstrated several episodes of self-initiated IK unrelated to environmental cues, which extended into the post-ictal period. In addition, she exhibited hyperorality with pronounced sexually disinhibited and compulsive behaviours, compatible with at least partial Kluver-Bucy syndrome (Janszky *et al.*, 2005; Kluver and Bucy, 1939). Her electrographic pattern showed early involvement of both temporal lobes in the epileptic activity which is consistent with the original description and later reports of peri-ictal Kluver-Bucy like behaviour, requiring extensive bitemporal lobe dysfunction for the behaviour to occur (Janszky *et al.*, 2005). None of the other four cases showed a similar early spread of the ictal discharge to the contralateral temporal lobe (*table 1*).

Our three cases suggest that IK may present as a combination of the discussed mechanisms leading to ictal automatisms. It may be related to an internal sexual stimulus due to right temporoparietal activation and/or triggered by an environmental cue in patients with non-dominant TLE. It seems to require at least partially preserved responsiveness and some degree of behavioural disinhibition. IK can also be seen as a self-triggered and more global ictal and post-ictal behavioural release phenomenon in the setting of Kluver-Bucy syndrome.

The main limitation of this study is its small sample size of only three patients. In addition, we could only surgically prove in patient 1 that the epileptogenic zone was limited to the anterior temporal lobe. The other two patients had imaging and EEG findings strongly suggestive of mesial temporal lobe epilepsy but declined surgery. Despite the small number, the characteristics of IK exhibited by the patients in our series are consistent with those described in the two previous case reports (Mikati *et al.*, 2005; Ozkara *et al.*, 2004). Each of our patients demonstrated distinctive IK behaviour, but the timing and the circumstances surrounding the behaviour varied among the patients as well as between events in the same patient. As discussed above, this may suggest that IK can result from more than one potential mechanism.

In conclusion, IK appears to represent a release phenomenon that localizes to the non-dominant temporal lobe. IK provides relevant clinical information and offers insight into the mechanism of automatisms and the role of the temporal lobe in mediating affectionate behaviour. □

Disclosure.

None of the authors has any conflict of interest or financial support to disclose.

References

- Alvarez-Silva S, Alvarez-Silva I, Alvarez-Rodriguez J, Perez-Echeverria MJ, Campayo-Martinez A, Rodriguez-Fernandez FL. Epileptic consciousness: Concept and meaning of aura. *Epilepsy Behav* 2006; 8: 527-33.
- Arnedo V, Parker-Menzer K, Devinsky O. Forced spousal intercourse after seizures. *Epilepsy Behav* 2009; 16: 563-4.
- Arroyo S, Lesser RP, Gordon B, Uematsu S, Hart J, Schwerdt P, *et al.* Mirth, laughter and gelastic seizures. *Brain* 1993; 116: 757-80.
- Asheim Hansen B, Brodtkorb E. Partial epilepsy with "ecstatic" seizures. *Epilepsy Behav* 2003; 4: 667-73.
- Aull-Watschinger S, Patariaia E, Baumgartner C. Sexual auras: Predominance of epileptic activity within the mesial temporal lobe. *Epilepsy Behav* 2008; 12: 124-7.
- Blume WT, Luders HO, Mizrahi E, Tassinari C, van Emde Boas W, Engel Jr J. Glossary of descriptive terminology for ictal semiology: Report of the ILAE task force on classification and terminology. *Epilepsia* 2001; 42: 1212-8.
- Blumer D. Hypersexual episodes in temporal lobe epilepsy. *Am J Psychiatry* 1970; 126: 1099-106.
- Bodde NM, Brooks JL, Baker GA, Boon PA, Hendriksen JG, Aldenkamp AP. Psychogenic non-epileptic seizures-diagnostic issues: A critical review. *Clin Neurol Neurosurg* 2009; 111: 1-9.

Legends for video sequences

Video sequence 1

Patient 1. The patient is shown during her ictal SPECT study. She reports a sudden aura and offers to push the button. EEG seizure onset is seen 10 seconds later coinciding with a behavioural arrest and oral automatisms and the tracer is injected. Half a minute later, the technician resumes testing and the patient is able to repeat the word "house" but shows diminished spontaneous movements and grasps the technician's hand. A minute into the event, she takes the technician's hand in an affectionate manner and kisses it and then requests a kiss from the technician. The patient returns quickly to baseline and is unaware of her preceding behaviour.

Video sequence 2

Patient 2 (anonymised). The patient's fourth seizure begins with vocalizing and fumbling with her right hand. The technician and nurse come in and she is responsive to commands. When asked to raise her arms and smile she appears to translate this motion into a request for a hug. She pulls the technician towards her and hugs him, then kisses him on the cheeks and tries to kiss him on the lips. She continues to try to pull him towards her, repeatedly verbally requesting a kiss. Her language remains intact but she is unresponsive to commands while fixated on requesting a kiss. The behaviour gradually subsides after approximately one minute and 30 seconds. Her seizure electrographic activity terminates 10 seconds later, after which she is confused and entirely amnesic for the event. She does not recognize that she had a seizure and does not recall the colour she was asked to remember at the beginning of the event.

Video sequence 3

Patient 3 (anonymised). Seventy seconds after the onset of her third seizure, the patient holds a technician's hands and blows a loud kiss in response to the command to stick out her tongue. She then blows a kiss towards a pen she is asked to identify. In the second segment she is shown sucking her thumb spontaneously during her fourth seizure. The third segment shows her blowing a kiss towards a nurse right at the onset of her sixth seizure. In the post-ictal period of the same seizure, she is blowing a kiss towards a technician who is asking her to stick out her tongue.

- Devinsky O, Kelley K, Yacubian EM, Sato S, Kufta CV, Theodore WH, *et al.* Postictal behavior. A clinical and subdural electroencephalographic study. *Arch Neurol* 1994; 51: 254-9.
- Ebner A, Dinner DS, Noachtar S, Luders H. Automatisms with preserved responsiveness: A lateralizing sign in psychomotor seizures. *Neurology* 1995; 45: 61-4.
- Ellison JM. Alterations of sexual behavior in temporal lobe epilepsy. *Psychosomatics* 1982; 23: 499-500, 505-9.
- Fogarasi A, Janszky J, Tuxhorn I. Ictal emotional expressions of children with partial epilepsy. *Epilepsia* 2007; 48: 120-3.
- Fogarasi A, Janszky J, Siegler Z, Tuxhorn I. Ictal smile lateralizes to the right hemisphere in childhood epilepsy. *Epilepsia* 2005; 46: 449-51.
- Heath RG. Pleasure and brain activity in man. deep and surface electroencephalograms during orgasm. *J Nerv Ment Dis* 1972; 154: 3-18.
- Holowka S, Petitto LA. Left hemisphere cerebral specialization for babies while babbling. *Science* 2002; 297: 1515.
- Ito M, Okazaki M, Takahashi S, Muramatsu R, Kato M, Onuma T. Subacute postictal aggression in patients with epilepsy. *Epilepsy Behav* 2007; 10: 611-4.
- Janszky J, Fogarasi A, Magalova V, Tuxhorn I, Ebner A. Hyperorality in epileptic seizures: Periictal incomplete klüver-bucy syndrome. *Epilepsia* 2005; 46: 1235-40.
- Janszky J, Ebner A, Szupera Z, Schulz R, Hollo A, Szucs A, *et al.* Orgasmic aura-a report of seven cases. *Seizure* 2004; 13: 441-4.
- Janszky J, Szucs A, Halasz P, Borbely C, Hollo A, Barsi P, *et al.* Orgasmic aura originates from the right hemisphere. *Neurology* 2002; 58: 302-4.
- Jasper HH. Some physiological mechanisms involved in epileptic automatisms. *Epilepsia* 1964; 5: 1-20.
- Kahane P, Ryvlin P, Hoffmann D, Minotti L, Benabid AL. From hypothalamic hamartoma to cortex: What can be learnt from depth recordings and stimulation? *Epileptic Disord* 2003; 5: 205-17.
- Kanner AM, Soto A, Gross-Kanner H. Prevalence and clinical characteristics of postictal psychiatric symptoms in partial epilepsy. *Neurology* 2004; 62: 708-13.
- Klüver H, Bucy PC. Preliminary analysis of functions of the temporal lobe. *Arch Neurol Psych* 1939; 42: 979-1000.
- Lenard HG. Dacrytic seizures reconsidered. *Neuropediatrics* 1999; 30: 107-8.
- Maestro I, Carreno M, Donaire A, Rumia J, Conesa G, Bargallo N, *et al.* Oroalimentary automatisms induced by electrical stimulation of the fronto-opercular cortex in a patient without automotor seizures. *Epilepsy Behav* 2008; 13: 410-2.
- Meletti S, Tassi L, Mai R, Fini N, Tassinari CA, Russo GL. Emotions induced by intracerebral electrical stimulation of the temporal lobe. *Epilepsia* 2006; 47 (Suppl 5): 47-51.
- Mikati MA, Comair YG, Shamseddine AN. Pattern-induced partial seizures with repetitive affectionate kissing: An unusual manifestation of right temporal lobe epilepsy. *Epilepsy Behav* 2005; 6: 447-51.
- Ozkara C, Sary H, Hanoglu L, Yeni N, Aydogdu I, Ozyurt E. Ictal kissing and religious speech in a patient with right temporal lobe epilepsy. *Epileptic Disord* 2004; 6: 241-5.
- Palmini A, Najm I, Avanzini G, *et al.* Terminology and classification of the cortical dysplasias. *Neurology* 2004; 62: S2-8.
- Penfield W, Jasper HH. *Automatisms, amnesia, and mental disturbance. Epilepsy and the functional anatomy of the human brain.* Boston: Little, Brown and Company, 1954; 497-539.
- Rasonyi G, Fogarasi A, Kelemen A, Janszky J, Halasz P. Lateralizing value of postictal automatisms in temporal lobe epilepsy. *Epilepsy Res* 2006; 70: 239-43.
- Schuele SU, Bermeo AC, Lüders HO. Seizure classification in epilepsy monitoring. In: Fisch BJ, ed. *Epilepsy and Intensive Care Monitoring.* New York: Demos Medical Publishing, 2009: 105-18.
- Stefan H, Schulze-Bonhage A, Pauli E, *et al.* Ictal pleasant sensations: Cerebral localization and lateralization. *Epilepsia* 2004; 45: 35-40.
- Toth V, Fogarasi A, Karadi K, Kovacs N, Ebner A, Janszky J. Ictal affective symptoms in temporal lobe epilepsy are related to gender and age. *Epilepsia* 2010; 51: 1126-32.
- Watts RL, Koller WC. *Movement disorders neurologic principles and practice.* New York: McGraw-Hill, 2004.