

# Euphoric (hedonic) theta hypersynchrony in early childhood

Michael Koutroumanidis

EEG Department, Guy's and St Thomas' Hospitals, London, United Kingdom

Received February 17, 2006; Accepted July 11, 2006

**ABSTRACT** – Euphoric or hedonic theta hypersynchrony appears to be an unusual finding in the electroencephalography of the child, and it has been rarely reported. This case report presents a 4-year-old child who responded to pleasurable stimulation with a robust, diffuse theta activity, and also samples some of the thoughts that such a response can generate.

*[Published with video sequences]*

**Keywords:** hedonic theta rhythm, euphoric theta hypersynchrony, video EEG, paediatric EEG

Diffuse rhythmic theta activity or theta hypersynchrony evoked by emotional stimuli in infants was first described in the 50s (Walter, 1950, Garsche, 1956, Lairy, 1956), and its last example was illustrated by Robert Mulsby in 1971 (Mulsby, 1971). This report documents with video-EEG, a similar response in a young boy with mild developmental delay.

## Case report

HL, a 4-year-old boy was referred for a routine EEG after five febrile convulsions (FC) between the age 18 and 26 months. He was born 25 weeks premature, suffered bilateral intraventricular haemorrhage, and was oxygen-dependent until 39 weeks. Subsequently, he made reasonable progress, but he is mildly developmentally delayed. Neurological examination is remarkable only for a mild left sided hemiparesis that was present since birth. He has had a number of respiratory infections with high fever, and it was in the course of these

illnesses that he had the five FC. Each lasted for less than 10 minutes, was always associated with high fever and was never repeated during the course of the same illness. All five FC were generalized and there were no lateralized or focal motor deficits postictally. The diagnosis of simple FC was made and the child was followed up. He received no antiepileptic treatment and had no further febrile or any afebrile seizures. A video EEG was recorded two months after his fifth episode.

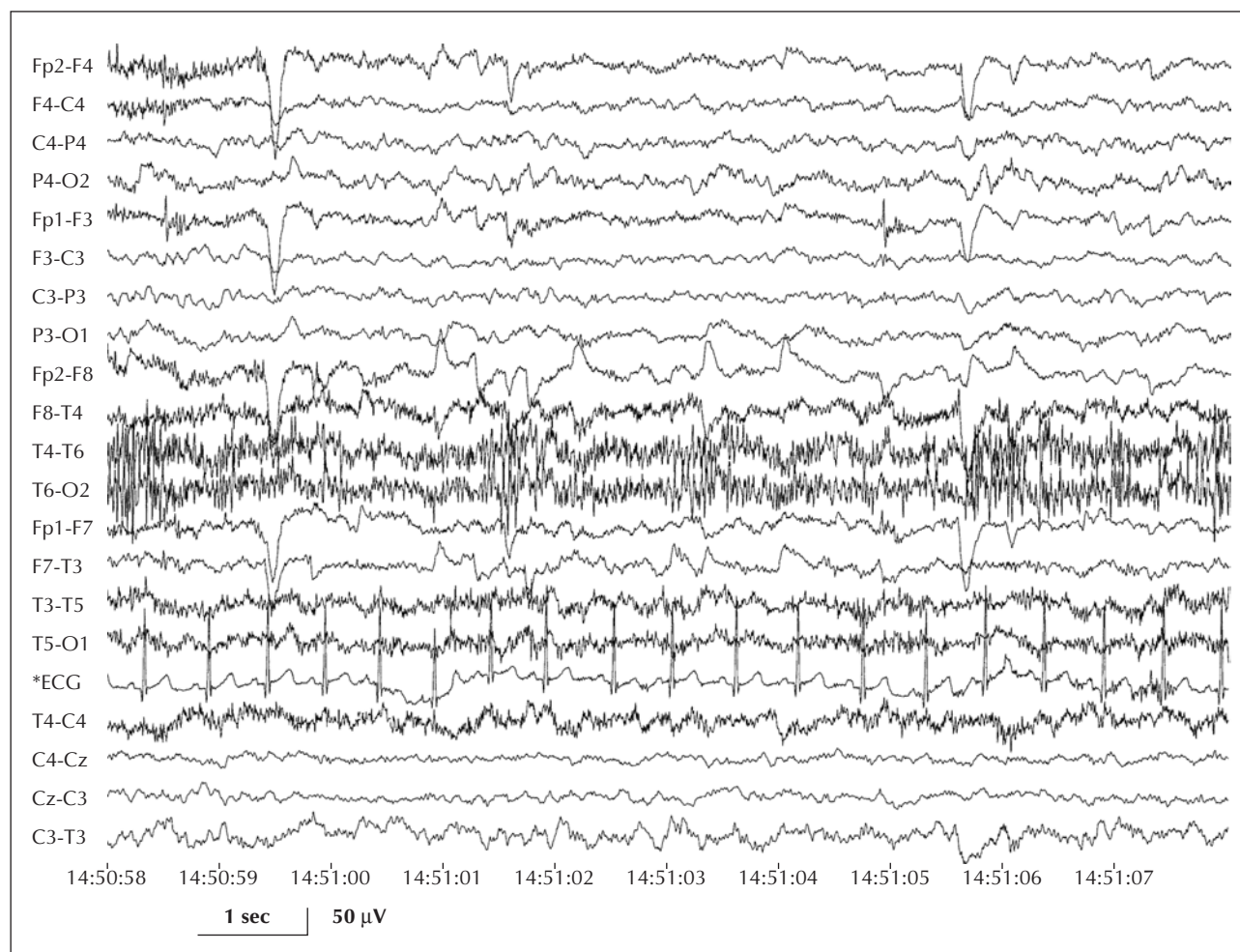
## Video-EEG findings

Due to the moderate developmental delay, co-operation was limited and the whole recording was performed with the boy sitting on his mother's lap with open eyes (*figure 1*). He remained quiet and calm throughout the recording, but became, at times, restless and rather dysthymic. Background activity was unremarkable without asymmetries. There were no electrographic or behavioural signs of



### Correspondence:

M. Koutroumanidis  
Department of Clinical Neurophysiology  
and Epilepsies  
Lambeth Wing, 3rd floor  
St Thomas' Hospital  
London SE1 7EH, UK  
Tel: (+00 44) 207188; fax: (+00 44) 207188  
<michael.koutroumanidis@gstt.nhs.uk>



**Figure 1.** Background activity when eyes were open. Bipolar “double banana” montage; high frequency filters = 70Hz; time constant = 0.3s. Even numbers indicate electrode locations over the right hemisphere.

drowsiness throughout the fifteen minute - recording, and the EEG was remarkable only for two events. The first was a brief, bilateral burst of high voltage delta activity with intermixed small spikes that appeared subclinical on careful video analysis. The second was a distinct electrographic event associated with excitement that occurred promptly after a pleasurable stimulus, continued for as long as the boy remained joyful and ceased immediately when the state of his cheerfulness ended spontaneously giving way to the habitually plain background (*figures 2A and 2B*, and video sequence).

This electrographic response occurs four seconds after his mother tells him rather casually “I love you H” (14:56:55, *figure 2A*, upper trace, arrow) to soothe him. The boy becomes immediately overjoyed, smiles and attempts to respond, his mum reassures him once more with genuine affection, and suddenly the EEG becomes overwhelmed by a diffuse 6Hz theta activity that reaches 100µV over the frontal areas (14:56:59). This theta hypersynchrony domi-

nates the record for almost a minute, during which time the boy remains exuberant looking at his mother, laughing and smiling with her (*figure 2A*, lower trace and *figure 2B*, upper trace) until 14:57:54 (*figure 2B* lower trace) after which he suddenly and apparently spontaneously loses interest and becomes sombre. This behavioural change coincides with the sudden, diffuse and irreversible disappearance of theta hypersynchrony that lingered for a second or two over the frontal areas before its total eclipse. There were no other changes and the EEG remained unremarkable until the end of the recording.

## Discussion

In this mildly retarded boy we recorded a distinctive electroclinical event of diffuse and unremitting regular theta activity associated with exuberant behaviour. Its appearance immediately after the verbal reassurance of maternal love and its disappearance upon the seemingly

spontaneous recurrence of sombreness, suggest that this theta hypersynchrony was the electrographic correlate of this boy's positive response to a very pleasurable stimulus.

The possibility of this theta hypersynchrony being hypnagogic (Gibbs and Gibbs, 1950) is negated by the lack of any concurrent behavioural signs of sudden drowsiness, and indeed no such clinical or electrographic signs were noted at any stage of the whole EEG recording. On the contrary, the boy remained alert and excitedly euphoric throughout the period of the EEG hypersynchrony (see video sequence). There was no crying or any evidence of breathing change either to suggest that theta hypersynchrony was a diffuse response to hyperventilation; besides, such responses are seldom so regular. The boy did not close his eyes, at least not persistently (and he didn't do so throughout the whole recording), ruling out the possibility of this diffuse hypersynchrony being a forward spread, slow for this age, alpha rhythm. To this end, the purist electroencephalographer would also add the somehow reluctant vanishing of the rhythm from the frontal areas (*figure 2B*, lower trace). Finally, diffuse theta activity of similar frequency but of higher amplitude (up to 200 $\mu$ V), may occur in children with Angelman syndrome (Boyd *et al.* 1988). In this condition however, it is usually sub-continuous and frequently associated with the so-called, high voltage notched delta pattern (Korff *et al.* 2005), and certainly with typical clinical features that are lacking here.

The purpose of this report is not to study the phenomenon of euphoric theta hypersynchrony. Thirty-five years ago, Robert Maulsby devoted many pages and photographs to illustrating a similar response in a physically healthy and well-developed 9-month-old girl, and called – to no avail – for studies on emotional development, both normal and pathological (Maulsby, 1971). This report does not bring any transcendent scientific information either; research groups with access to advanced recording techniques and divergent groups of volunteers (Lutz *et al.* 2004) are far better equipped to identify mentally-induced EEG changes and fathom the mechanisms through which external and internal environmental stimuli may influence neuronal growth and function. This paper is merely a reminder that theta hypersynchrony can occur as a result of pleasurable stimuli, and also in children with some psychomotor impairment. Our knowledge of its frequency and its precipitants and inhibitors, let alone its biological significance, is next to nothing. Robert Maulsby (1971) commented on the antidiametric experience of some of his most eminent colleagues on this rhythm (read his discussion in reference (Maulsby, 1971), and it may well be that bringing it up during recording may also depend on the physical setting and the use of toys or other material. The average EEG department is not meant to foster such events, but breakthroughs can occur, as in this boy. We

also suspect another reason: one usually sees what one knows or has heard of, and very seldom – if ever – does euphoric theta hypersynchrony features amongst the traditional teaching material of clinical electroencephalography. Our professional eyes are rightly trained to detect evidence of dysfunction in our attempt to understand diseases, but pursuing this we may overlook (or not be bothered at all by) physiological variability; time is short and anything not clearly pathological can be hurriedly discarded. Yet, it is the physiological variability and its multiple facets that can give us the measure and the dynamics of the boundaries between normality and abnormality.

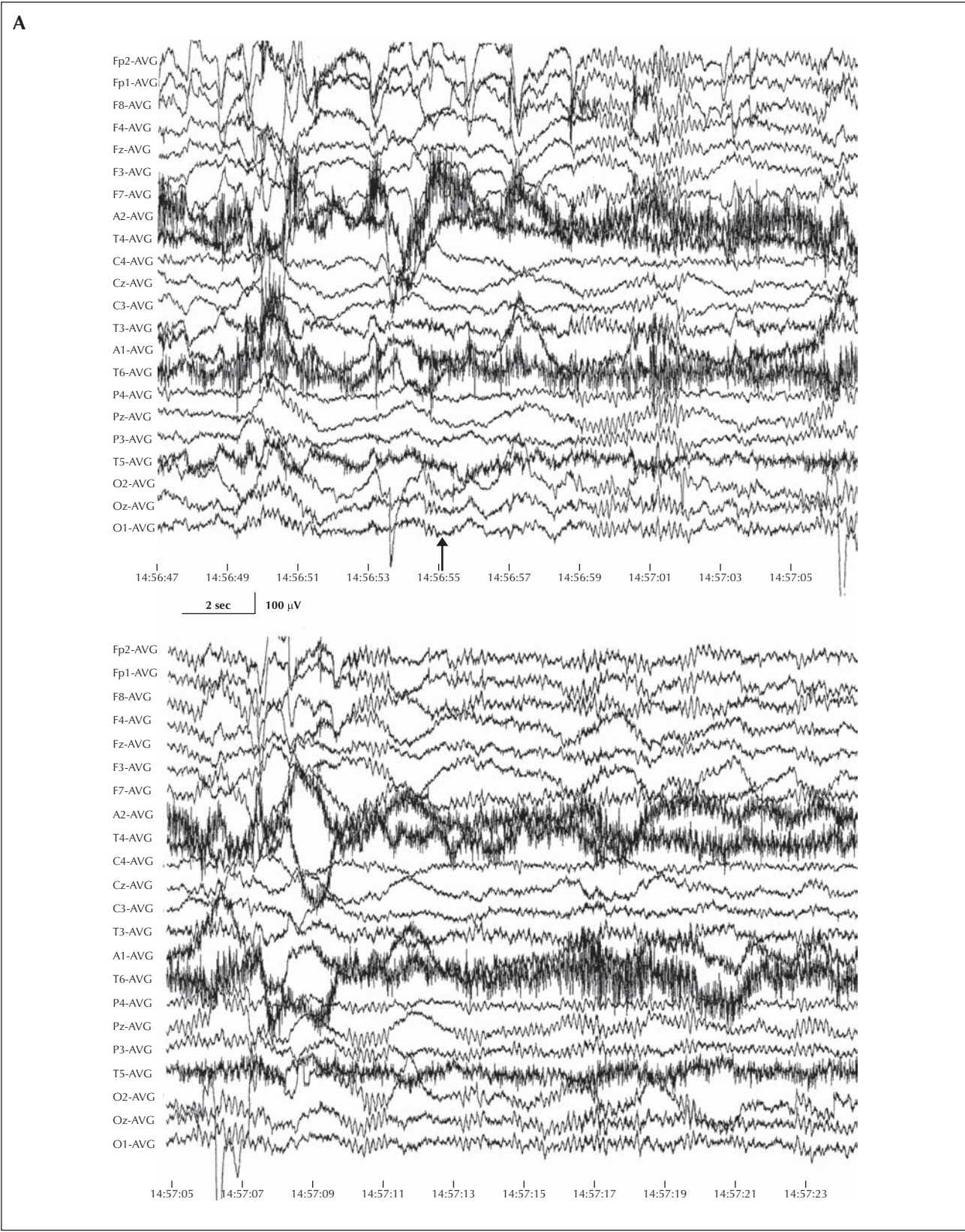
What do such observations have to offer to our boy and his equals? Euphoric theta hypersynchrony seems to be a privilege destined exclusively for small children; increased theta activity in adults was reported long time ago and only in extraordinary conditions, for example in astronauts during launch and the initial hours of space flight, and was attributed to either high level of psychoemotional reaction (Voskrenzenskiy *et al.* 1965) or heightened alertness and orientation (Adey *et al.* 1967). Recent studies have demonstrated that neuronal hypersynchrony within the gamma - band frequency range (30-70 Hz) occurs in adults, and is possibly involved in mental processes that include attention, learning, and conscious perception (Srinivasan *et al.* 1999, Rodriguez *et al.* 1999, Miltner *et al.* 1999). At odds with the swiftly responsive theta hypersynchrony in children however, gamma synchronization in adults, as a network phenomenon, seems to require time to develop, and is proportional to the size of the synchronised neuronal assembly (Lutz *et al.* 2004). Thus, it may (or may not) be analogous to theta hypersynchrony in children, whose brains may not yet be capable of generating faster neuronal oscillations, but with perhaps a similar role. Thalamo-cortical and cortico-cortical interactions may also be different between adults and children. One thing is for sure. Treating children (of normal and subnormal development) with affection (*and expressing it*) may have a perceptible, transient physiological effect with possible long-term consequences for their psychological development. Such robust electrographic response to pleasurable stimuli is hard to ignore or belittle, and is certainly easy to overemphasize, but we don't know and haven't heard of any adults who fared poorly in life because they received love and affection as children. □

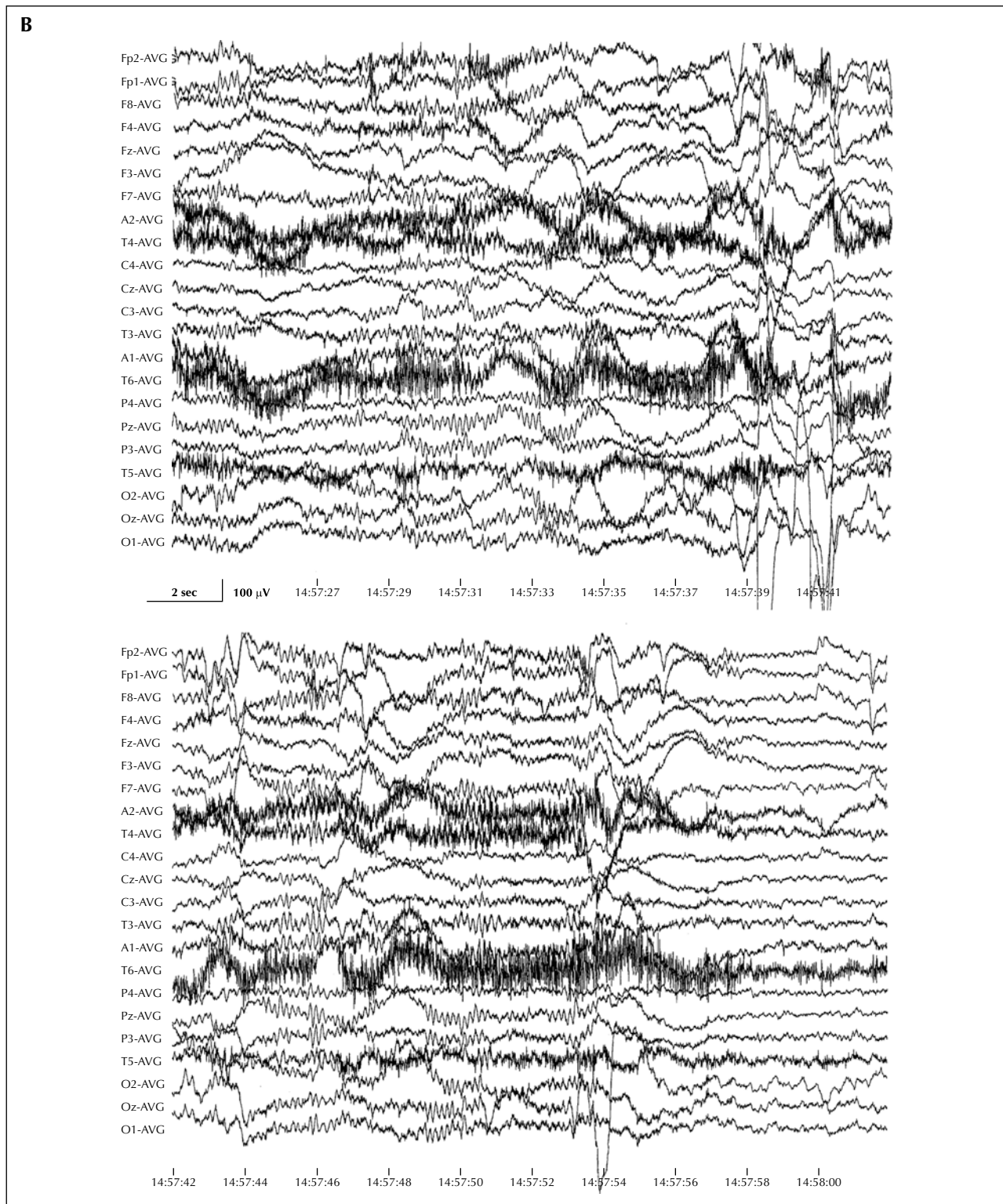
### Legends for video sequences

The video contains the whole episode of euphoric, theta hypersynchrony.

Note the close association between electrographic and behavioural changes. See the section on video-EEG findings for further details.







**Figure 2.** Episodic, diffuse theta hypersynchrony starts at 14:56:58, two seconds after mother showed affection (arrow in **A**, upper trace) and ceases spontaneously, when the boy becomes suddenly sober (14:57:55), lingering for a while over the bilateral frontal areas (**B**, lower trace on the right). Note also the abrupt attenuation of the muscle artefacts (from smiling) that coincides with the resolution of the theta hypersynchrony. For further details, see text and compare with video clip. Common average reference derivation; high frequency filters = 70Hz; time constant = 0.3s.



**Acknowledgements.** I am grateful to this little boy's mother for giving me permission to publish his case with the video clip, and to Dr John Jackman, consultant paediatrician, for providing me with the relevant clinical information.

## References

- Adey WR, Kado RT, Walter DO. Computer analysis of EEG data from Gemini flight GT-7. *Aerosp Med* 1967; 38: 345-59.
- Boyd SG, Harden A, Patton MA. The EEG in early diagnosis of the Angelman (happy puppet) syndrome. *Eur J Pediatr* 1988; 147: 508-13.
- Garsche R. Die B-Aktivität im EEG des Kindes. *Z. Kinderheilk* 1956; 78: 441-57.
- Gibbs FA, Gibbs EL. Atlas of electroencephalography, Vol 1: Normal controls. Cambridge M.A: Addison-Wesley, 1950.
- Korff CM, Kelley KR, Nordli DR. Notched delta, phenotype, and Angelman syndrome. *J Clin Neurophysiol* 2005; 22: 238-43.
- Lairy GC. L'organisation de l'électroencéphalogramme normale et pathologique. *Rev Neurol* 1956; 94: 749-801.
- Lutz A, Greischar LL, Rawlings NB, et al. Long-term meditators self induce high amplitude gamma synchrony during mental practice. *Proc Natl Acad Sci USA* 2004; 101: 16369-73.
- Maulsby RL. An illustration of emotionally evoked theta rhythm in infancy: Hedonic hypersynchrony. *Electroencephalogr Clin Neurophysiol* 1971; 31: 157-65.
- Miltner WHR, Braun C, Arnold M, et al. Coherence of gamma-band EEG activity as a basis for associative learning. *Nature* 1999; 397: 434-6.
- Rodriguez E, George N, Lachaux J-P, et al. Perception's shadow: long-distance synchronization of human brain activity. *Nature* 1999; 397: 430-3.
- Srinivasan R, Russell PD, Edelman GM, et al. Increased synchronization of neuromagnetic responses during conscious perception. *J Neurosci* 1999; 19: 5435-48.
- Voskrenzenskiy AD, Gagenko OG, Izosimov GV, et al. Working ability of cosmonauts during orbital flight. In: *Problems of space biology*. U.S.S.R: U.S. Library Congress, Aerospace Technology Division, 1965: 4-79.
- Walter WG. Normal rhythms – their development, distribution and significance. In: Hill D, Parr G, eds. *Electroencephalography: A symposium on its various aspects*. N.Y: Macmillan, 1950: 203-12.