

Epilepsia partialis continua triggered by traumatic hand injury: a peripheral tuning of brain excitability?

Eliseu Paglioli^{1,2,3}, William Alves Martins^{3,4},
Walter De la Cruz⁵, Victor Andrade^{3,4},
Vinicius Duval da Silva⁶, Rafael Menezes Nunes³,
André Palmiini^{3,4,7}

¹ Service of Neurosurgery, Hospital São Lucas, Porto Alegre

² Department of Surgery, Faculty of Medicine, Porto Alegre

³ Porto Alegre Epilepsy Surgery Program, Hospital São Lucas

⁴ Service of Neurology, Hospital São Lucas, Pontifícia Universidade Católica do Rio Grande do Sul (PUCRS), Porto Alegre

⁵ Department of Epilepsy, Instituto Nacional de Ciências Neurológicas, Lima, Peru

⁶ Department of Pathology, Hospital São Lucas, Pontifícia Universidade Católica do Rio Grande do Sul (PUCRS), Porto Alegre

⁷ Internal Medicine, Division of Neurology, Faculty of Medicine, Pontifícia Universidade Católica do Rio Grande do Sul (PUCRS), Porto Alegre, Brazil

Received September 22, 2014; Accepted December 07, 2015

ABSTRACT – Epilepsia partialis continua is often refractory to antiepileptic medication and its causal relation to peripheral sensory stimuli has only rarely been suggested. We report a man who received surgery for temporal lobe epilepsy 10 years ago, who presented “*de novo*” epilepsia partialis continua following mild traumatic injury of the left hand. Continuous myoclonus of the left upper limb started the day after injury and persisted unabated for several weeks. Non-invasive evaluation was inconclusive. Acute electrocorticography during surgery under local anaesthesia revealed continuous, rhythmic spiking over the right sensorimotor cortex. Tailored excision of the posterior bank of the motor and adjacent sensory cortex immediately stopped the continuous myoclonus. Histopathology showed abnormal radial lamination and was compatible with focal cortical dysplasia type IA. Epilepsia partialis continua did not recur for seven years. Afferent stimuli from peripheral injury can disinhibit hyperexcitable sensorimotor cortex leading to epilepsia partialis continua. [*Published with video sequences online*]

Key words: epilepsia partialis continua, focal cortical dysplasia, peripheral injury, disinhibition, epilepsy surgery



VIDEOS ONLINE

Correspondence:

Eliseu Paglioli
Serviço de Neurocirurgia,
Hospital São Lucas da PUCRS,
Avenida Ipiranga 6690,
CEP:90610-000,
Porto Alegre, RS, Brazil
<epaglioli@hotmail.com>

Epilepsia partialis continua (EPC) is characterized by continuous focal jerking of a body part, usually the hemiface or a limb, lasting hours, days or years (Guerrini, 2009). In the absence of a gross focal lesion, microscopic dysplasia should be suspected (Desbiens *et al.*, 1993). It is recognized that focal cortical dysplasia (FCD) in the rolandic cortex may remain dormant for decades, awaiting a trigger to generate EPC (Hemb *et al.*, 2014). Once triggered, however, the continuous jerking may never stop. Here, we address these issues reporting the case of a man who developed EPC following a peripheral hand injury.

Case study

A 50-year-old right-handed man presented with a three-week history of continuous myoclonic jerking of the left upper limb, starting less than 24 hours after a traumatic injury to his left hand. Myoclonus involved fingers, hand and arm and reached a plateau a few days following injury. Continuous jerking worsened with repetitive voluntary movements, but never disappeared, even during sleep (*video sequence 1*). Physical and neurological examinations were normal, except for a recent scar of a penetrating injury in the dorsal aspect of the left hand, and the continuous myoclonus in the left upper limb. High dosages of various antiepileptic medication regimens were ineffective. Following IV diazepam, jerking ceased for about 10 minutes, although voluntary movements could still elicit myoclonus, which then returned with higher intensity, unresponsive even to regional anaesthetic blockage. At a certain point, the patient said that he would rather have his arm amputated.

Ten years earlier, the patient had a right temporal resection for refractory complex partial seizures, starting at 8 years of age, without precipitating events. Attacks were consistently heralded by an unpleasant feeling of paresthesia in the left hand, followed by staring, disconnection and oral automatisms, with occasional secondary generalization. Interictal and ictal scalp EEG showed right anterior temporal discharges and MRI showed both increased signal in the right hippocampus and suprasylvian atrophy of the right hemisphere (*figure 1A*). Surgery significantly improved the complex partial seizures, but somatosensory auras persisted. Pathology of the resected tissue was not available. Occasional complex partial spells recurred at a rate of two to three per year, despite treatment with antiepileptic drugs. Functional status was very much improved and he resumed working as a locksmith.

Upon presentation with EPC, scalp EEG revealed occasional right temporal spikes, but no epileptic activity in the fronto-centro-parietal regions (*figure 2A*).

MRI showed right suprasylvian atrophy, unchanged in comparison with 10 years earlier (*figure 1B*). Functional MRI during EPC predominantly activated the somatosensory cortex bilaterally (*figure 1C*). Based upon the past medical history, transient response to IV diazepam, and right suprasylvian atrophy, we hypothesised that the myoclonus was cortically generated and proceeded to craniotomy under local anaesthesia. Acute ECoG revealed continuous, rhythmic spiking in the sensorimotor cortex, predominating in the bottom of the central sulcus (*figure 1D*). ECoG-guided excision of the epileptogenic sensory and posterior bank of the primary motor cortex immediately stopped EPC during surgery (*video sequence 2*). Histopathology showed abnormal radial lamination and neuronal distribution in micro-columns, which was compatible with FCD IA (*figures 1F, 1G*) (Blumcke *et al.*, 2011). Movements of the hand completely recovered after seven days. Two weeks after surgery, EEG showed runs of electrographic seizures in the right temporal lobe (*figure 2, B-D*), which had never been seen before rolandic resection.

The patient has been seizure-free for six years, taking carbamazepine at 1,200 mg/day, and has only slight proprioceptive deficits in his left hand.

Discussion

Despite understandable debate on the exact location of the epileptogenic zone in this man, the main point of this report is that a patient doing well for 10 years, following a right anterior temporal lobectomy (Engel class II outcome), suddenly started with refractory EPC in the left upper limb, 24 hours after an acute traumatic injury to this very body part. Despite recurrent simple partial seizures manifested as paresthesias in the left hand before and after temporal lobe surgery, he never had focal motor manifestations. Acute ECoG showed continuous spiking in a restricted area in the right rolandic region, a pattern often seen in FCD. Focal central resection led to complete cessation of the previously intractable EPC (*video sequence 2*) and histopathology showed a pattern of abnormal radial lamination that was compatible with FCD IA.

When the patient was first evaluated before temporal lobe surgery, MRI showed diffuse atrophy of the right hemisphere, particularly in the suprasylvian regions. Atrophic lesions without an obvious cause have been linked to low-grade FCD (Krsek *et al.*, 2008, 2010), which may well be the underlying histopathology we found in the resected tissue (*figure 1F and G*). The possibility that this man had Rasmussen's encephalitis as the cause of an atrophic hemisphere with EPC should be entertained, although he lacks subcortical typical imaging and histopathological features and showed no

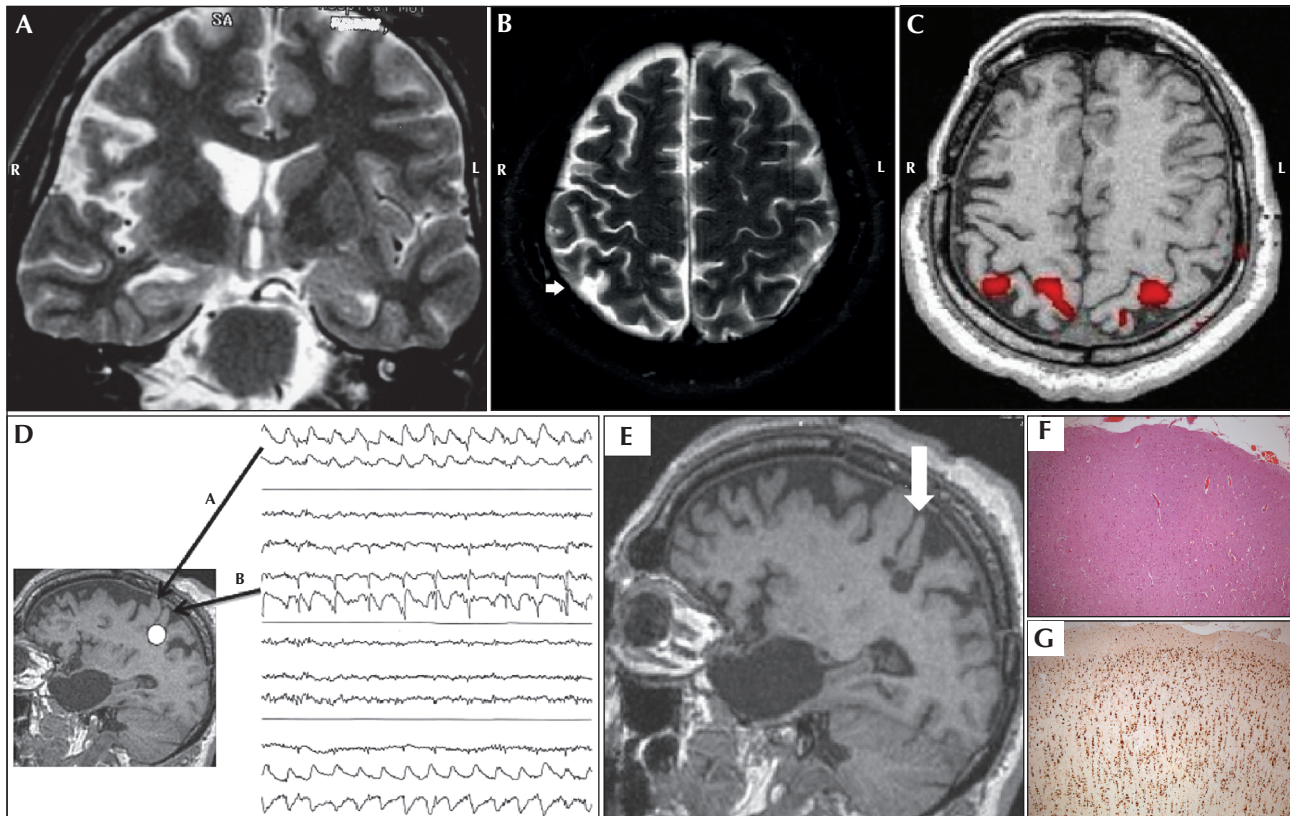


Figure 1. (A) MRI T2-weighted coronal image before the first surgery with right hippocampal hyperintensity convergent with interictal and ictal scalp EEG. Note the enlarged right lateral ventricle and prominence of right hemisphere sulci. (B) MRI T2-weighted axial image 10 years later, when EPC began. Note persistent right hemisphere atrophy, particularly of the parietal cortex (arrow). (C) Axial functional MRI during EPC demonstrating bilateral primary sensory cortex activation. (D) Elocorticography with continuous spike-wave activity over the right motor (arrow A) and sensory areas (arrow B), predominating on the depth of central sulcus (white circle). (E) Sagittal T1-weighted image post-resection of the depth of central sulcus (arrow). (F, G) Photomicrographs of H&E and NeuN staining, respectively, showing abnormal radial lamination and neuronal distribution in micro-columns at 50x magnification.

signs of progressive motor or cognitive deterioration over almost 17 years of follow-up (Varadkar *et al.*, 2014). Another way to conceptualize the complex case presented by this man is that he might have had FCD-related perisylvian epilepsy, partially treated by a right temporal lobectomy. This is an attractive possibility because temporal spikes posterior to the resection and sensory seizures continued after the first operation. Undiagnosed perisylvian or insular foci may mimic temporal or frontal lobe epilepsy due to extensive inter-connectivity (Isnard *et al.*, 2000; Nguyen *et al.*, 2009). This possibility should, however, be weighed against the good response to temporal lobectomy and the absence of any kind of recurrent seizures for more than six years following the focal central resection in the second surgery. Furthermore, the patient never had focal facial motor seizures, salivation or autonomic symptoms, or more typical manifestations of perisylvian or insular epilepsy. Finally, the recurrent sensory seizures were not only focal, distal and lateralized, but also completely controlled by a limited

resection around the sensory hand area (somewhat away from the insula and the perisylvian region). What has become clear from the evolution is that this patient had, from the start, a more diffuse right hemisphere disorder, which presented with distinct symptomatology at different times. Moreover, peripheral trauma was the “second hit” that triggered the medically intractable EPC.

That FCD was possibly the underlying pathology could be hinted at by the acute ECoG pattern (Palmini *et al.*, 1995; Palmini, 2010) and this case may add to an incipient literature suggesting that rolandic dysplasia may remain silent for decades and then suddenly “flare up” following a variety of triggers. For example, one patient in a series we recently reported with bilateral, sequential EPC had complex partial seizures which were well controlled by medication until she became pregnant, and after delivery (trigger 1) she suddenly started with intractable *left-sided* EPC. The day after *right* central resection (trigger 2), *right-sided* EPC unexpectedly started. Pathology was type II FCD (Hemb

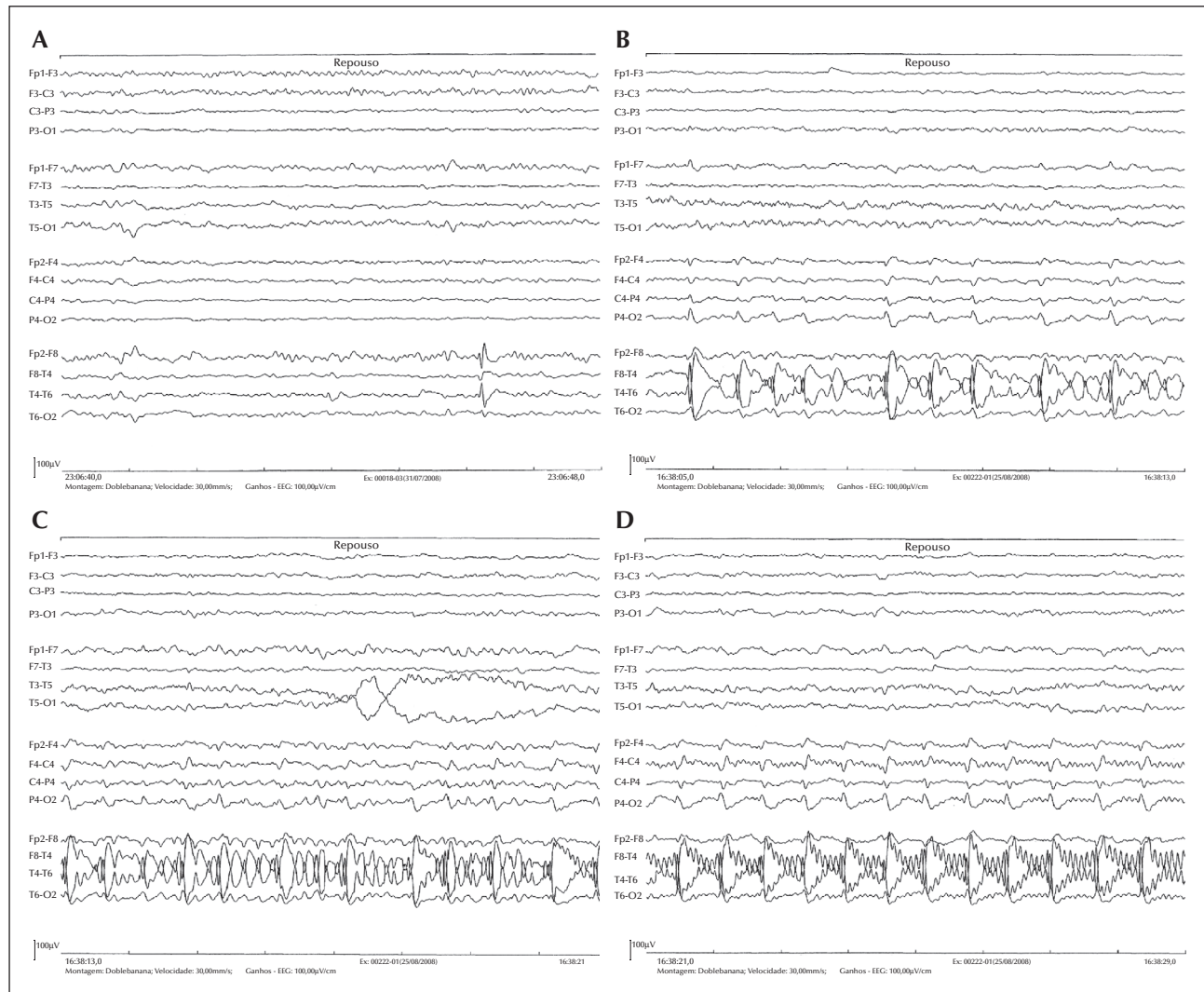


Figure 2. (A) Pre-resection scalp EEG at EPC presentation, with remaining interictal right temporal discharges. Note that rolandic regions are electrically silent. (B-D) Sequential sections of scalp EEG after rolandic resection and full control of the EPC. Electrographic seizures are seen in the right temporal lobe, without clinical symptoms. This abnormality was not present before resection.

et al., 2014) reinforcing the notion that EPC is an epileptic manifestation of type II FCD. As to whether FCD type IA is also a cause of EPC is open to a debate that will be hopefully kindled by this report. In a large series, a significant number of patients with type I FCD and status epilepticus were reported (Krsek *et al.*, 2008). Although in that study, EPC was combined with other types of status and the authors could not retrospectively retrieve that specific information (P. Krsek, M. Duchowny, personal communication), it is unlikely that no EPC was present in any of the patients with FCD type I and status epilepticus. Of much more relevance, the present case strengthens the perception suggested by our previous series (Hemb *et al.*, 2014) of latent epileptogenicity and suggests that peripheral trauma can provoke massive afferent volley and act as a disinhibiting trigger.

Reflex seizures following peripheral trauma in previously damaged brain have been rarely reported (Parsons-Smith, 1948; Rae, 1952; Spiller *et al.*, 2005). Whether augmented cortical hyperexcitability following peripheral injury occurs only in the presence of already abnormal cortex is not clear and the mechanisms by which peripheral injury would trigger continuous seizures are not understood. Most likely, massive afferent volleys disinhibit an already hyperexcitable cortex, which suggests that intrinsic inhibition is also operative in epileptogenic networks related to FCD (Palmini, 2010). The fact that in this patient EPC began only after peripheral injury allows us to hypothesize a delicate balance between intrinsic hyperexcitability and intrinsic inhibition in neuronal networks, such as those involved in FCD. This is also

suggested by a series of patients with bilateral, “mirror” EPC we reported recently (Hemb *et al.*, 2014), in whom we hypothesized that silent FCD lesions in the “normal” rolandic cortex were disinhibited by the initial resection on the dysplastic homologous contralateral region. Once disinhibited, re-entrant synaptic loops between motor and sensory neurons may play a major role and in the patient reported here even subtle sensory stimulation or movements led to immediate exacerbation of myoclonic jerks. Modulation of seizures by peripheral stimuli has been well established, and although commonly related to idiopathic epilepsy syndromes, seizure precipitation in patients with symptomatic epilepsies may occur, particularly when associated with malformations of cortical development (Palmini *et al.*, 2005).

Interestingly, EEGs after resection of the previously silent, dysplastic sensorimotor cortex unexpectedly showed recurrent electrographic seizures in the remaining parts of the ipsilateral, previously operated temporal lobe (*figure 2B-D*). This added complexity to the pattern of disinhibition, in that a peripheral injury disinhibited a likely rolandic FCD, the resection of which disinhibited the ipsilateral temporal neocortex - indeed supporting the view that inhibition plays a central role in the clinical presentation of FCD-related networks in epilepsy (Palmini, 2010). Despite the predominant view that FCD is a hyperexcitable lesion with impaired inhibition (Ferrer *et al.*, 1992), emerging basic science data support a role of inhibition in FCD circuits that could be disrupted by surgery or massive afferent volleys. For instance, significant increase in evoked and spontaneous inhibitory postsynaptic currents was found in human dysplastic tissue, likely reflecting a decrease in transporter-mediated GABA reuptake (Calcagnotto *et al.*, 2005).

In conclusion, this patient illustrates that peripheral injuries produce afferent stimuli that could trigger seizures in dormant cortical dysplasia. Coupled with recent evidence of “*de novo*” status following resection of dysplastic tissue (Hemb *et al.*, 2014), this observation suggests that excitation and inhibition act in tandem in dysplastic circuits being vulnerable to a number of interferences that, in turn, modulate epileptogenicity. □

Supplementary data.

Summary didactic slides are available on the www.epilepticdisorders.com website.

Acknowledgements and disclosures.

We thank Professor Albert Becker for the review of the histopathological sections. Dr. Palmini has received honoraria for talks and participation in advisory boards from Novartis, Abbott,

Eli Lilly and Janssen-Cilag, which do not bear upon this publication. Drs. Paglioli, De la Cruz, Martins, Andrade and Nunes have nothing to disclose. We confirm that we have read the Journal’s position on issues involved in ethical publication and affirm that this report is consistent with those guidelines.

Legends for video sequences

Video sequence 1

Video monitoring during EPC. Myoclonic jerks never abated, even during sleep. Repetitive movements and sensory stimuli exacerbated the myoclonus.

Video sequence 2

During awake craniotomy, there were continuous myoclonic jerks. After ECoG-guided excision of the sensory cortex and depth of the central sulcus, EPC immediately stopped.

Keywords for the video research on www.epilepticdisorders.com

Syndrome: reflex epilepsy

Aetiology: focal cortical dysplasia

Phenomenology: epilepsia partialis continua

Localization: sensorimotor cortex

References

- Blumcke I, Thom M, Aronica E, *et al.* The clinicopathologic spectrum of focal cortical dysplasias: a consensus classification proposed by an ad hoc Task Force of the ILAE Diagnostic Methods Commission. *Epilepsia* 2011; 52: 158-74.
- Calcagnotto ME, Paredes MF, Tihan T, *et al.* Dysfunction of synaptic inhibition in epilepsy associated with focal cortical dysplasia. *J Neurosci* 2005; 25(42): 9649-57.
- Desbiens R, Berkovic SF, Dubeau F, *et al.* Life-threatening focal status epilepticus due to occult cortical dysplasia. *Arch Neurol* 1993; 50(7): 695-700.
- Ferrer I, Pineda M, Tallada M, *et al.* Abnormal local-circuit neurons in epilepsia partialis continua associated with focal cortical dysplasia. *Acta Neuropathol* 1992; 83(6): 647-52.
- Guerrini R. Physiology of epilepsia partialis continua and subcortical mechanisms of status epilepticus. *Epilepsia* 2009; 50(12): 7-9.
- Hemb M, Paglioli E, Dubeau F, *et al.* “Mirror EPC”: epilepsia partialis continua shifting sides after rolandic resection in dysplasia. *Neurology* 2014; 83(16): 1439-43.
- Isnard J, Guénot M, Ostrowsky K, *et al.* The role of the insular cortex in temporal lobe epilepsy. *Ann Neurol* 2000; 48: 614-23.

Krsek P, Jahodova A, Maton B, et al. Low-grade focal cortical dysplasia is associated with prenatal and perinatal brain injury. *Epilepsia* 2010; 51(12): 2440-8.

Krsek P, Maton BB, Korman E, et al. Different features of histopathological subtypes of pediatric focal cortical dysplasia. *Ann Neurol* 2008; 63(6): 758-69.

Nguyen DK, Nguyen DB, Malak R, et al. Revisiting the role of the insula in refractory partial epilepsy. *Epilepsia* 2009; 50(3): 510-20.

Palmini A. Electrophysiology of the focal cortical dysplasias. *Epilepsia* 2010; 51(1): 23-6.

Palmini A, Gambardella A, Andermann F, et al. Intrinsic epileptogenicity of human dysplastic cortex as suggested by corticography and surgical results. *Ann Neurol* 1995; 37(4): 476-87.

Palmini A, Halasz P, Scheffer IE, et al. Reflex seizures in patients with malformations of cortical development and refractory epilepsy. *Epilepsia* 2005; 46(8): 1224-34.

Parsons-Smith G. Epileptic response to peripheral injury. *J Neurol Neurosurg Psychiatry* 1948; 11(4): 267-70.

Rae JW. Case report: reflex epilepsy and peripheral injury. *J Neurol Neurosurg Psychiatry* 1952; 15(2): 134-6.

Spiller AE, Guberman A, Bartolomei A, Zifkin B, Andermann F. Epileptogenesis due to peripheral injury as a cause of focal epilepsy. *Epilepsia* 2005; 46(8): 1252-5.

Varadkar S, Bien CG, Kruse CA, et al. Rasmussen's encephalitis: clinical features, pathobiology, and treatment advances. *Lancet Neurol* 2014; 13: 195-205.

TEST YOURSELF



(1) A 27-year-old woman presented with continuous myoclonic movements of the right upper extremity for 10 days, following injury with a kitchen knife. Myoclonus involved fingers, hand and arm and persisted during sleep. There is no history of epilepsy and neurological examination is otherwise unremarkable. MRI and EEG are both normal. Which of the following is the most likely syndromic/symptomatic diagnosis?

- A. Convulsive disorder
- B. Subcortical myoclonus
- C. Rasmussen's encephalitis
- D. Epilepsia partialis continua
- E. Post-traumatic peripheral nerve injury

(2) Which of the following statements about epilepsia partialis continua is not true?

- A. It is characterized by continuous focal jerking of a body part, usually the hemiface or a limb, lasting hours, days or years
- B. Most common aetiologies involve cerebrovascular events, Rasmussen's encephalitis and focal cortical dysplasia
- C. EPC may be the sole manifestation of a silent rolandic lesion, such as focal cortical dysplasia
- D. Even with negative EEG, EPC should be suspected in a patient with continuous myoclonic jerks
- E. Subcortical lesions often give rise to EPC

Note: Reading the manuscript provides an answer to all questions. Correct answers may be accessed on the website, www.epilepticdisorders.com, under the section "The EpiCentre".