

Definition of the neurological phenotype associated with dup (X)(p11.22-p11.23)

Marcella Broli¹, Francesca Bisulli¹, Massimo Mastrangelo², Elena Fontana³, Isabella Fiocchi², Claudio Zucca⁴, Maria Clara Bonaglia⁵, Serafino Buono⁶, Sebastiano Antonino Musumeci⁶, Corrado Romano⁶, Santina Reitano⁶, Maria Savio⁶, Girolamo Aurelio Vitello⁶, Bruno Bernardi⁷, Daniela Cevolani⁸, Raffaele Agati⁸, Roberto Poda¹, Roberto Gallassi¹, Roberto Giorda⁹, Orsetta Zuffardi¹⁰, Bernardo Dalla Bernardina³, Marco Seri¹¹, Paolo Tinuper¹

¹ Department of Neurological Sciences, University of Bologna, Bologna

² V. Buzzi Children's Hospital, Milan

³ Neuropsychiatry, G.B. Rossi Hospital, University of Verona, Verona

⁴ Clinical Neurophysiology, E. Medea Scientific Institute, Bosisio Parini, Lecco

⁵ Cytogenetics, E. Medea Scientific Institute, Bosisio Parini, Lecco

⁶ Department for Mental Retardation, I.R.C.C.S. Oasi Maria Santissima Association, Troina, Enna

⁷ Neuroradiology, Imaging Department, Pediatric Hospital Bambino Gesù, Rome

⁸ Neuroradiology Unit, Bellaria Hospital, Bologna

⁹ Molecular Biology, E. Medea Scientific Institute, Bosisio Parini, Lecco

¹⁰ Medical Genetics I.R.C.C.S. C. Mondino, Pavia

¹¹ Medical Genetics, Department of Gynecological, Obstetric and Pediatric Sciences, Sant'Orsola Malpighi Hospital, University of Bologna, Bologna, Italy

Received May 2, 2011; Accepted August 5, 2011

ABSTRACT – The aim of this study was to describe in detail the neurological features of nine patients carrying the recently reported microduplication at Xp11.22-11.23. Clinical and neurological examination, brain magnetic resonance imaging (except for two patients), electroencephalography and a neuropsychological assessment specific for language disturbances were performed in nine patients with microduplication at Xp11.22-11.23, disclosed by comparative genomic hybridisation array. Six patients were familial cases belonging to three unrelated pedigrees and three were sporadic cases. The patients had the following characteristics: mild dysmorphic facial features (except for two patients), mental retardation with moderate to severe global language deterioration, electroencephalographic epileptiform discharges during wakefulness and especially during sleep

Correspondence:

P. Tinuper
Department of Neurological Sciences,
University of Bologna,
Via Ugo Foscolo 7,
40123 Bologna, Italy
<paolo.tinuper@unibo.it>

This work was presented during the last American Epilepsy Society poster session (San Antonio, USA, December 2010).

or electrical status epilepticus during slow sleep in younger cases, and negative brain magnetic resonance imaging. The main clinical features of this new microduplication syndrome were mild facial dysmorphisms, from increased electroencephalogram abnormalities during sleep to electrical status epilepticus during slow sleep, and mental retardation mainly involving language function in the absence of detectable brain lesions. In the absence of detectable brain lesions, speech delay may be associated with electrical status epilepticus during slow sleep or, alternatively, related to abnormal brain expression of a dosage-sensitive gene contained within the duplication region.

Key words: Xp11.22-11.23, mental retardation, speech impairment

Giorda *et al.* (2009) recently identified a group of subjects with a microduplication at Xp11.22-11.23 during a diagnostic genome array screen (comparative genomic hybridisation array) (CGH array) of 2,400 subjects with mental retardation (MR), either isolated or associated with a more complex phenotype. The duplication was either familial or sporadic. The aim of this paper was to better define the neurological phenotype of this new syndrome.

Materials and methods

We directly studied nine patients belonging to a group of subjects with a microduplication at Xp11.22-11.23, identified by Giorda *et al.* (2009). A neurologist reconstructed the patients' family and personal histories by telephoning or visiting relatives. All patients underwent neurological evaluation, electroencephalography (EEG) (during the awake and sleep state, especially afternoon naps and sometimes overnight) and, except for two patients (Cases I.1 and II.3 of Family 1), morphological brain magnetic resonance imaging. Brain functional MRI (fMRI) was performed only in one patient (Case II.1 of Family 2) to explore receptive and expressive language functions (for details of fMRI stimulation paradigm, image acquisition, and image analysis (Appendix A see *appendix*). Electroneurography was also performed in two patients (Cases II.1 and II.3 of Family 2). All patients underwent neuropsychological evaluation but both intellectual and language difficulties precluded extensive neuropsychological assessment. A language analysis was also performed but only a qualitative evaluation was possible.

Results

Clinical and instrumental features of the nine patients are summarised in *table 1*; details of electrical status epilepticus during slow sleep (ESES) are summarised in *table 2*. Of these nine patients, six belonged to three families and three were sporadic cases. None

of the patients who underwent brain MRI (seven of nine patients) showed structural abnormalities. The genealogical trees and further information of all familial and sporadic cases was previously published by Giorda *et al.* (2009).

Family 1 (the follow-up of this family is incomplete due to loss of patient compliance)

Patient I.1 (female of 39 years)

Clinical history. The patient was the only child born to non-consanguineous parents with a second degree cousin affected by MR. Infancy was reported as normal except for speech delay and menarche at nine years. She reached primary school level education. She married and had five pregnancies. Her first child died at birth during a dystocic delivery. Of the others, two carry the microduplication and two are disease-free. She never had overt clinical seizures.

Neuropsychological assessment. Raven's Coloured Progressive Matrices revealed borderline intellectual functioning. Results showed impaired abilities in logical and abstract thought. Verbal language was characterised by complete sentence structure, although the content of speech was poor and expressed in simple language. The vocabulary was limited, related to semantic categories in common use and often revealed phonological and syntactic errors. Adaptive behaviour was not inappropriate.

EEG. Infrequent single sharp waves and spike-waves were observed at temporal-parietal areas of both hemispheres and vertex.

Patient II.1 (female of 14 years)

Clinical history. The patient was the second child born at 40 weeks by eutocic delivery after an uneventful pregnancy. Psychomotor milestones were reported as normal. Language delay with speech (dyslalia) and relationship disorders were diagnosed at the age of six years. At eight years, early puberty appeared and was treated with gonadotropin-releasing hormone therapy. She never had overt clinical seizures.

Table 1. Summary of clinical and instrumental features.

Case	Family 1	Family 2	Family 3	Sporadic case 1	Sporadic case 2	Sporadic case 3
	I.1 ♀39 y	II.1 ♀14 y	II.3 ♀9 y	II.1 ♂35 y	II.3 ♀38 y	♂11y
Facial dysmorphisms	Absent	Absent	Present ¹	Present ²	Present ³	Present ⁴
Clinical examination	Bilateral 5 th toes hypoplasia	Hypermetropic astigmatism and visus 6/10 in the right eye, pes cavus nodular goiter	Hypermetropic astigmatism,tapering fingers with Dubois sign and pes plano valgus	Pes cavus and hammer toe	Dolicocephaly	Thoracic and lumbar spine scoliosis, knock knees and pes planus valgus
						Early puberty signs
						Synophrys, arched palate, diffuse hypertri-chosis, partial 2/3 syndactylia of feet, stubby short hands and feet
Neurological examination	Negative	Abdominal muscles hypotonia	Negative	Severe dysarthria, difficulty understanding simple tasks and speech deficits (he pronounces single words); absent leg osteotendi-nous reflexes	Mild dysarthria, difficulty understanding complex tasks and speech deficits (she pronounces short sentences); absent leg osteotendi-nous reflexes	Dyspraxia and a mildly impaired coordination
						Dyspraxia, dysphasia, difficulty understanding simple tasks, hypomimic face, osteo-tendinous hyporeflexia
						Left-handed, walking with extrarotation of the feet, mildly impaired coordination, dyspraxia, dysarthria, hypomimic face

Table 1. (Continued)

Case	Family 1	Family 2	Family 3	Sporadic case 1	Sporadic case 2	Sporadic case 3
	I.1 ♀39 y	II.1 ♀14 y	II.3 ♀9 y	II.1 ♂35 y	II.3 ♀38 y	♂11 y
EEG	SWs on temporal-parietal areas of both hemispheres and vertex	Frequent SWs, single or organized in short sequences on temporal-parietal areas of both hemispheres and vertex	Frequent SWs, single or organized in short sequences on temporal-parietal areas of both hemispheres and vertex	During sleep (up to phase 2 of NREM sleep), bursts of diffuse epileptiform activity	During wake, anterior dominant fast activity; rare bisynchronous anterior dominant SWs complexes on drowsiness	SWs, usually single or organized in short sequences on temporal areas of both hemispheres. During sleep, epileptiform activity became continuous with a significant disorganization of sleep structure
						Generalized polyspikes and slow waves during wakefulness increased by sleep
						Spikes and slow waves over the centro-parietal region of both hemispheres. During sleep, bilateral and diffuse slow spikes and waves
Brain MRI	Not performed	Negative	Not performed	Negative	Negative	Lateral ventricles and sub-arachnoid spaces dilation
Defined epileptic seizures	-	-	-	-	-	-

Presence: +; absence: -.

¹Bitemporal narrowing, hypoplastic nostrils, large nasal root, hypoplastic filtrum, small mouth.

²Bushy eyebrows and synophrys, high nasal root, hypoplastic alae nasi, short and flat philtrum, thin lips, midface hypoplasia.

³Bushy eyebrows and synophrys, high nasal root, hypoplastic alae nasi, short and flat philtrum, thin lips, midface hypoplasia, small ears with prominent antihelix.

⁴High bossing forehead with high frontal hairline, deep nasal root, flat philtrum, prominent upper lip, micrognathia.

⁵Full eyebrow, hypotelorism, slightly downslanting palpebral fessures, high nasal root, slightly posteriorly rotated ears, short phyltrum and thin lips, arched palate, absence of upper incisor.

⁶Mild, not better specified.

⁷High bossing forehead with high frontal hairline, deep nasal root, flat phyltrum, prominent upper lip, micrognathia.

Table 2. Summary of ESES features.

Patient	Case 1	Case 2	Case 3	II.1	II.3
ESES age onset	7 years	7 years	7 years	10 years	5 years
ESES age resolution	13 years	8 years	12 years	No follow-up	No follow-up
ESES therapy (AEDs)	LTG + CLB	ESM + VPA LEV + VPA	VPA ESM LEV ESM + VPA	Not done	Not done
Response to treatment	Yes	Yes	Yes	–	–

AEDs: antiepileptic drugs; LTG: lamotrigine; CLB: clobazam; ESM: ethosuximide; VPA: valproic acid; LEV: levetiracetam.

Neuropsychological assessment. Cognitive tests and an adaptive behaviour scale (Wechsler Intelligence Scale for Children revised, Leiter-R, Raven's Coloured Progressive Matrices, and Vineland Adaptive Behavior Scales) disclosed mild intellectual disability with a moderately dysharmonic profile in cognitive functioning. The delay in cognitive functions was higher in verbal (vocabulary and comprehension), visuo-spatial, and constructive skills (Block Design task) and attention/concentration. The analysis of the adaptive behaviour showed a global low score without any significant difference between communication, socialisation and daily living skills.

EEG. Many spike-waves, usually single or organised in short sequences, were observed at temporal-parietal areas of both hemispheres and vertex.

Patient II.3 (female of 9 years)

Clinical history. The patient was the fourth child born at 37 weeks by Caesarean section after a pregnancy complicated by poor foetal movement and threatened by miscarriage. Psychomotor milestones were unreported. She showed language delay. She never had overt clinical seizures.

Neuropsychological assessment. The administration of cognitive tests and an adaptive behaviour scale (Leiter-R, Raven's Coloured Progressive Matrices, and Vineland Adaptive Behavior Scales) disclosed a mild MR/intellectual disability and a receptive and expressive language disorder. The analysis of the adaptive behaviour showed a global low score. Impulsiveness, inattention, oppositional and aggressive behaviours were observed.

EEG. Many spike-waves, usually single or organised in short sequences, were observed at temporal-parietal areas of both hemispheres and vertex.

Family 2

II.1 and II.3 siblings belonged to a family in which both parents presented MR. The 60-year-old mother

(Case I.1 of Family 2) had diabetes and, like her offspring, showed microduplication at Xp11.22-11.23, identified by CGH array. The 65-year-old father, with mild, unspecified MR, had a history of alcohol abuse. He refused clinical examination and genetic analysis. History taking was difficult for the two siblings of this family because they were institutionalised and had an impaired ability to communicate (MR and speech disturbances). Information was therefore gathered from available clinical documentation and interviewing the patients' caregivers.

Patient II.1 (male of 35 years)

Clinical history. At age 20 years, the patient was institutionalised due to a deprived family setting and maltreatment. There was no information about his birth or possible pre-, peri-, or postnatal complications. Caregivers and relatives reported severe speech delay. He currently works as carpenter. He has ulcerative rectocolitis. He never had overt clinical seizures.

Neuropsychological assessment. All tests (Mini Mental Examination, Coloured Raven's Progressive Matrices '47, and immediate visual memory) were markedly impaired. Spontaneous speech was characterised only by very limited verbal production, such that phonemic and syntactic structure could not be assessed. The Token listening comprehension test showed random answers, even though the patient was able to understand simple verbal orders. Repetition was impaired for sounds, phonemes, syllables and words. The patient was able to read only letter by letter and write only his name.

EEG. Bursts of diffuse epileptiform activities were observed during sleep (up to phase 2 NREM sleep) (figure 1).

Electroneurography. Normal nerve conduction velocities and amplitudes in the nerves examined were observed using surface electrodes on the right median, left ulnar, right peroneal, right and left tibial, and right and left sural nerves. This examination

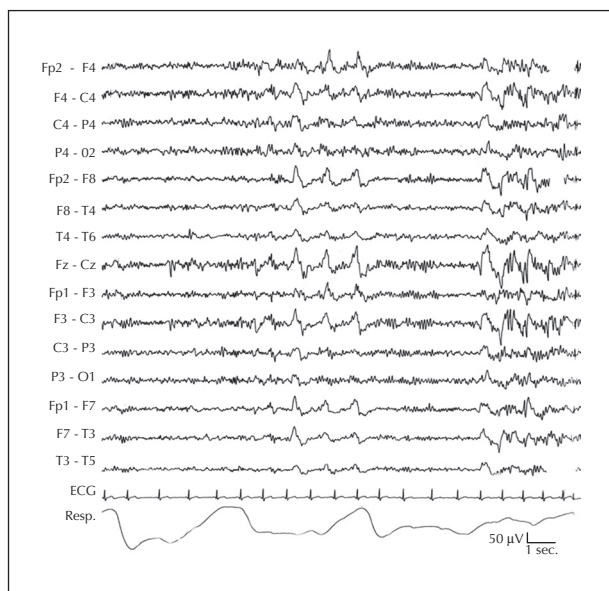


Figure 1. EEG of Case II.1 (family 2) during sleep deprivation. During sleep (up to phase 2 NREM), high amplitude bisynchronous anterior dominant spike-wave complexes are evident.

was performed due to absence of leg osteotendinous reflexes with *pes cavus* and hammer toe.

Brain fMRI. Asymmetries were disclosed in the eloquent language areas indicating left hemispheric dominance (*appendix*). The smaller width of the eloquent language areas in this patient could be a sign of reduced brain function and represent one of the neurological correlates of the clinical characteristics of this pathology (*figure 2*).

Patient II.3 (female of 38 years)

Clinical history. At age 23 years, the patient was institutionalised due to a deprived family setting and maltreatment. There was no information about her birth or possible pre-, peri-, or postnatal complications. Her caregivers and relatives reported severe speech delay. She works in a factory. She has Wegener granulomatosis and, in the past, suffered from recurrent uveitis. She never had overt clinical seizures.

Neuropsychological assessment. All tests (Mini Mental Examination, Coloured Raven's Progressive Matrices "47" and immediate visual memory) indicated marked impairment. Spontaneous speech was characterised by limited verbal production, sometimes unintelligible, with articulatory difficulties and phonemic errors with neologisms; prosody was impaired with monotonous intonation and without inflections. There was also a frequent lack of grammatical functors and phonemic inflections. Repetition was impaired for both words and phrases. The Token listening

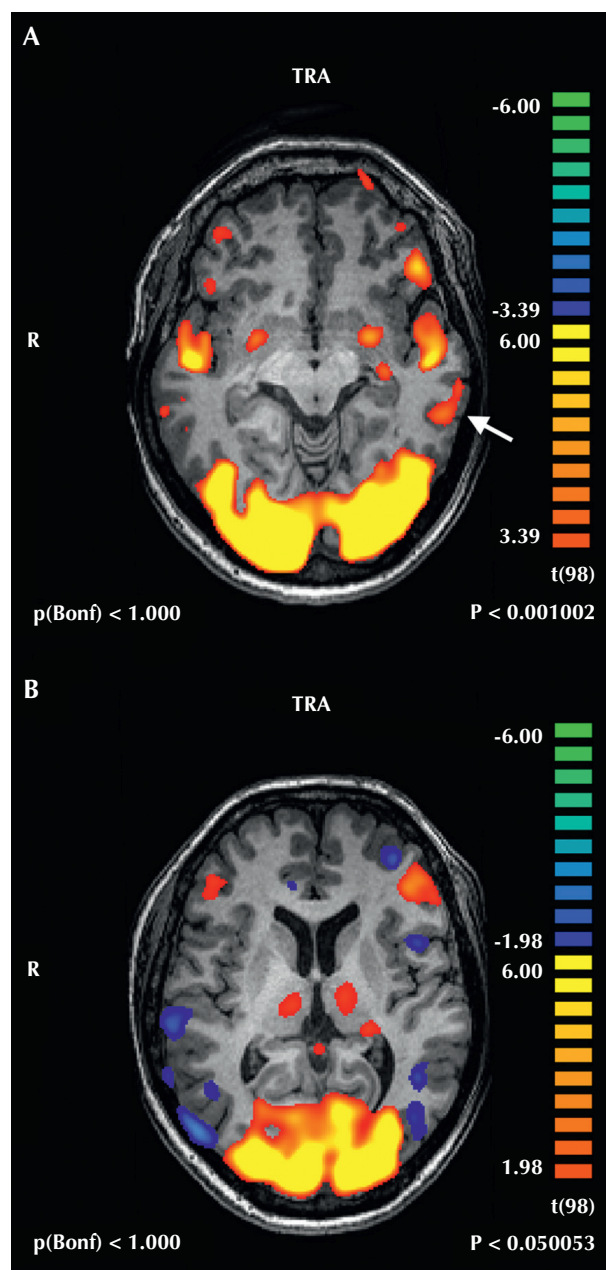


Figure 2. fMRI of Case II.1 (family 2); axial representation of the eloquent areas was evoked by two language paradigms. **A)** Text listening ($p < 0.001$). Besides the wide occipital bilateral activations, bilateral temporal activations are appreciable; on the left side, an additional posterolateral eloquent area (arrow) is evident. **B)** Image naming ($p < 0.05$). Wide bilateral occipital activations are appreciable together with smaller frontal opercular eloquent areas prevailing on the left side. Note the threshold had to be lowered ($p < 0.05$ vs $p < 0.001$ in **A**) to disclose eloquent areas. Asymmetries can be seen in the language eloquent areas indicating a left hemispheric dominance and a smaller width of the language eloquent areas.

comprehension test was markedly poor (and was discontinued at the 27th item due to apparently random responses). Nevertheless, the patient was able to

understand simple verbal orders and could read letter by letter but not whole words. She was capable of writing only her name.

EEG. An anterior dominant fast activity was observed when EEG was performed at sleep deprivation during wakefulness; drowsiness evoked rare bisynchronous anterior dominant spike-wave complexes.

Electroneurography. Normal nerve conduction velocities and amplitudes in the nerves examined were observed using surface electrodes on the right median, left ulnar, right peroneal, right and left tibial, and right and left sural nerves. This examination was performed due to absence of leg osteotendinous reflexes with *pes cavus* and hammer toe.

Family 3

Patient II.3 (male of 11 years)

Clinical history. The patient was the third child of non-consanguineous parents with two sisters in good health. Family history for MR was negative. He was born at term by Caesarean section for podalic presentation after a pregnancy complicated by threatened premature delivery from the seventh month. No perinatal disease was present. The proband, his mother and one uncle of maternal lineage presented previous episodes of cyanosis and staring blankly. At the age of six months, he had a seizure characterised by clonic movements of the limbs and a stare lasting for one minute with spontaneous termination. He was under magnesium valproate therapy up to the age of five years. Motor milestones were slightly delayed. Blood test revealed a beta-thalassaemic trait.

Neuropsychological assessment. The administration of cognitive tests and adaptive behaviour scales (Leiter-R, Raven's Coloured Progressive Matrices, and Vineland Adaptive Behavior Scales) defined a mild mental retardation/intellectual disability, impairment of motor skills and expressive language disorder. The subject had difficulties in tasks requiring attention and specific logical skills. His language was poor with sentences structured in an elementary way. Omissions, substitutions and dyslalia were also shown. His adaptive skills were generally poor.

EEG. Spikes and waves were observed, usually single or organised in short sequences at temporal areas of both hemispheres.

Sporadic cases

Case 1 (female of 14 years)

(Case 4 of Giorda et al. [2009])

Clinical History. The patient was the first born child at 34 weeks by Caesarean section due to premature membrane rupture. At the age of three years, she

presented febrile convulsions and delayed language development was diagnosed. Significant inhibition in relational attitude and emotional coercion were also noticed. Since the age of nine, it was reported that her EEG recordings showed discharges of bilateral diffuse epileptiform abnormalities mainly during sleepiness, hyperpnoea and intermittent light stimulation. Epilepsy started at the age of 12 years with generalised tonic-clonic seizures during sleep. Satisfactory seizure control was achieved with lamotrigine (LTG) monotherapy. She is overweight and also presents hypothyroidism, hyperinsulinaemia and oligomenorrhoea.

Neuropsychological assessment. Moderate mental retardation (total IQ: 49) with elective language impairment in both aspects of verbal production and comprehension was identified.

EEG. Normal background activity during wakefulness was observed, as well as abnormal epileptiform discharges over the left frontal-temporal areas. During sleep, epileptiform activity became continuous with a significant disorganisation of the sleep structure (*figures 3, 4*); antiepileptic treatment with LTG had partially reduced the intensity and diffusion of the discharges during sleep. After treatment with clobazam (CLB) and LTG, epileptiform abnormalities during sleep significantly decreased.

Case 2 (female of 13 years)

(Case 5 of Giorda et al. [2009])

Clinical history. Neonatal hypotonia was reported without specific pre-, peri-, or postnatal complications. A delay in psychomotor development, especially language ability, became evident at the age of four. She suffered cyclic vomiting and, because of this, many blood tests and instrumental analysis were performed: an esophago-gastro-duodenoscopic examination showed an erosive esophagitis with hiatal hernia. Also, plasmatic and urinary amino acids were tested and shown to be negative. At seven years, the patient presented early puberty and absence-like seizures, thus valproic acid (VPA) was started. After six months, an EEG pattern specific for ESES appeared and, because of this, ethosuximide (ESM) was introduced. After one year, due to the persistence of ESES, levacetametam (LEV) was introduced replacing VPA with resolution of ESES. Seizures also disappeared after adding LEV to ESM; she is currently seizure-free.

Neuropsychological assessment. Only a global description from available documents was possible. After four years of rehabilitation, the patient showed motor improvement, whereas language abilities were deficient and she could only pronounce simple sentences and understand simple orders.

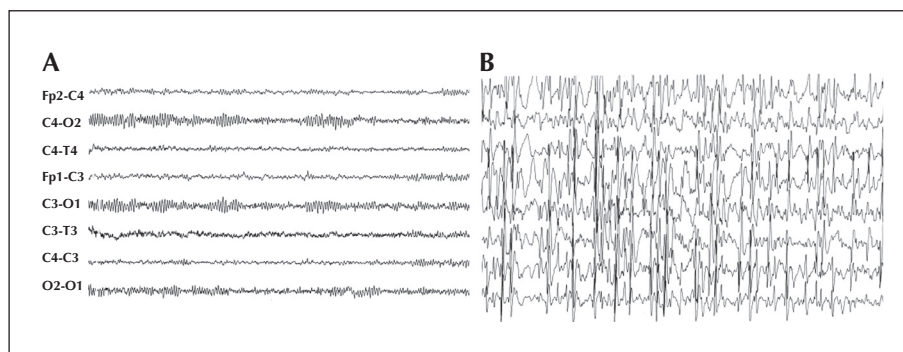


Figure 3. EEG of sporadic Case 1. During the awake state (A) specific discharges were not present, whereas during sleep (B) generalised epileptiform discharges became subcontinuous and ESES was determined.

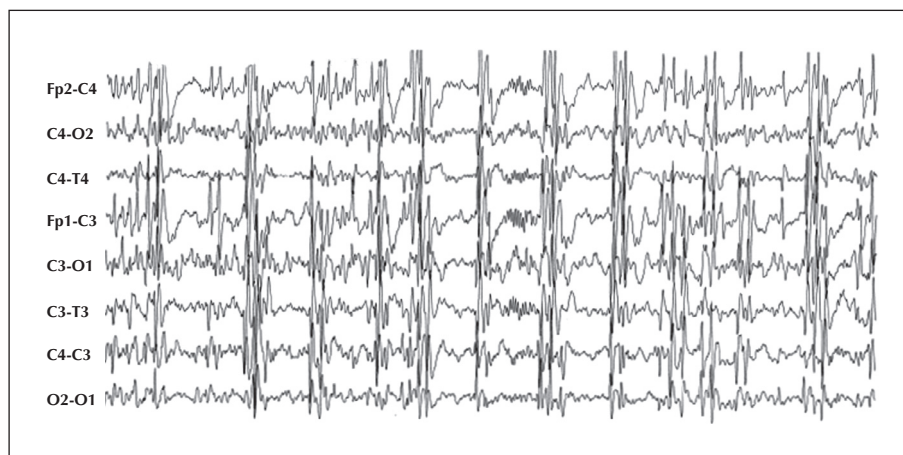


Figure 4. EEG of sporadic Case 1. As in figure 3, the EEG recording shows the persistence of sporadic spindles.

EEG (at age ten years). Generalised polyspikes and slow waves during wakefulness were observed to increase upon sleep (*figure 5*).

Case 3 (female of 11 years)

(Case 6 of Giorda et al. [2009])

Clinical history. Normal delivery at term. Family history was unremarkable. Independent walking was reached at the age of 14 months. By three years of age, she had a significant delay in language ability and sleep disturbances with frequent nocturnal awakenings. She presented attention deficit with emotional instability and recurrent episodes of compulsive eating. At eight years, early puberty was diagnosed; menarche at nine years. She presented diffuse hypertrichosis and was overweight. At the age of seven years, EEG revealed spike and wave activity related to secondary bilateral synchrony without clinical seizures. VPA was used, and subsequently ESM and LEV, without efficacy. After the first EEG (at the age of four years), ESM

was combined with VPA with a major improvement in behaviour and attention and a significant reduction of paroxysmal activity during sleep. She never had overt clinical seizures.

Neuropsychological assessment. She presented moderate mental retardation, severe attention deficit, comprehension disorder and expressive disorder characterised by poor vocabulary, dysarthria with unintelligible speech. She was able to produce only phrases of five to six words.

EEG. An activity during wakefulness, characterized by spikes and slow waves over the centro-parietal region of both hemispheres, was observed. In addition, photosensitivity without clinical symptoms was evident. During sleep, bilateral diffuse slow spikes and waves appeared, persisting throughout all slow sleep stages, forming a typical picture of ESES. During REM sleep, paroxysmal activity became fragmented, whereas focal spikes predominated in the centro-parietal area.

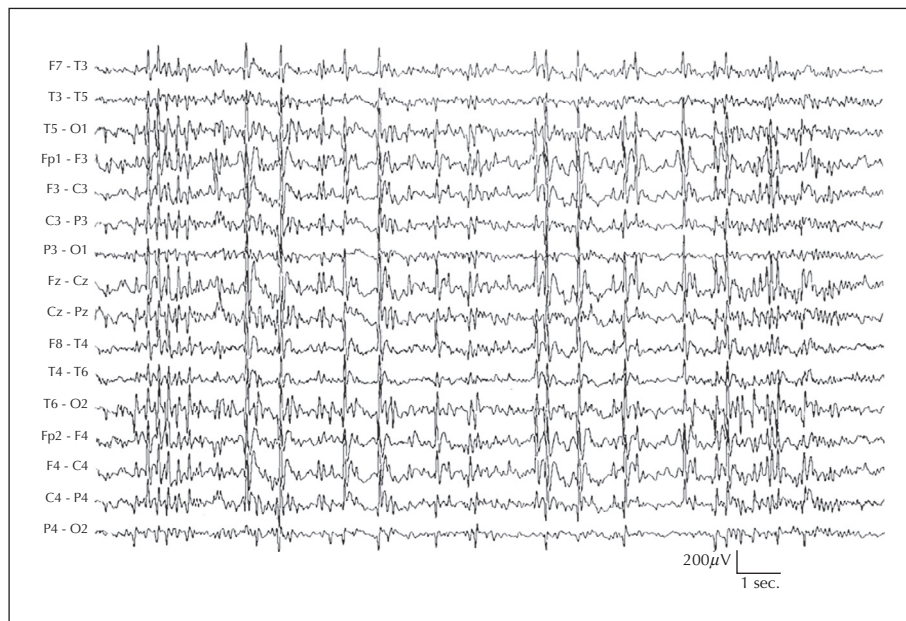


Figure 5. EEG of sporadic Case 2. During drowsiness and slow sleep, generalised epileptiform discharges, such as polyspikes and slow waves, became subcontinuous and ESES was determined.

Discussion

Giorda *et al.* (2009) recently reported a microduplication at Xp 11.22-11.23 associated with mild dysmorphic features, MR, speech delay and EEG features, from increased abnormalities during sleep to ESES. The present study aimed to describe the neurological phenotype of the new syndrome following the hypothesis that some peculiar features, such as ESES, speech delay and MR, may be related to a common underlying pathogenetic mechanism. Epilepsy was also reported in three of nine patients but this condition had a benign course and was so rare that we could not speculate on its pathogenetic implications.

ESES was observed in five of nine patients (with only amnesic data for patients II.1 and II.3 of Family 1). Patry *et al.* (1971) introduced the term “electrical status epilepticus during slow sleep” (ESES) to indicate a specific EEG pattern with a certain percentage of epileptiform activity during sleep (expressed as a spike-wave index), characterised by nearly continuous activation beginning with sleep onset, persisting throughout the night, and resolving when the child awoke. The term ESES was subsequently converted to “status epilepticus during sleep” (SES) (Tassinari *et al.*, 2000), an electroencephalographic hallmark of a condition that when prolonged in children results in disorders collectively referred to as “encephalopathy related to SES” (ESES) (Tassinari

and Rubboli, 2006). Even though the ESES EEG pattern disappears spontaneously by the mid-teen years, ESES gives rise to permanent language deficits, and other neuropsychological sequelae can persist. From a broader prospective, this condition may be responsible for acquired aphasia and other dysfunctions, such as behavioural disturbances and motor impairment (Tassinari *et al.*, 2009). ESES was only evident in younger patients in our series (Cases 4, 5 and 6 and II.1 and II.3 of Family 1). The data from the literature indicates that ESES is never observed in adults. Unfortunately, EEGs performed in childhood were not available for our adult patients; the fact that their epileptiform discharges were especially activated during sleep cannot be interpreted as an evolution of a previous ESES.

Another point of interest is the relationship between ESES and speech delay which are hallmarks of Xp11.22-11.23 microduplication. Although our neuropsychological assessment was limited by a non-standardised nature of evaluation due to both language difficulties and the different ages of our patients, ESES and speech delay were reported in all cases. Speech delay may be a symptom of many disorders, but its relationship with ESES is intriguing. If the epileptiform activity during sleep persists for more than two years, language seldom recovers completely and such patients continue to have lifelong language dysfunction (Deonna, 1991). The pathophysiological relationship between

ESES and the peculiar patterns of neuropsychological derangement remains unknown. Some evidence indicates that the duration of ESES and the localisation of interictal foci influence the degree and type of cognitive dysfunction (Tassinari and Rubboli, 2006). In addition, Tononi and Cirelli (2003) investigated the effects of a learning task involving specific brain regions on sleep homeostasis, demonstrating a local increment of EEG slow-wave activity (SWA) during sleep in the cortical regions involved in task performance. This would imply that prolonged focal epileptic activity during sleep (as occurs in ESES) interferes with local SWA at the site of the epileptic focus, impairing neural processes and, possibly, the local plastic changes associated with learning and other cognitive functions. Hence, ESES might be considered a clinical model for localised EEG disruption during sleep caused by long-lasting sleep-related focal epileptic activity (Tassinari and Rubboli, 2006; Tassinari *et al.*, 2009). In the absence of detectable brain lesions, the speech delay in our patients may have resulted from or been related to a previous ESES, no longer evident in adulthood as in our familial cases, but nonetheless able to cause local SWA damage, impairing the plastic changes associated with language learning.

Alternatively, speech delay in our patients could be related to abnormal brain expression of a dosage-sensitive gene contained within the duplication region. Xp 11.2 is a gene-rich, rearrangement-prone region within the critical linkage interval for several neurogenetic disorders harbouring X-linked MR, and many genes contained within the duplication region are involved in brain development, neurogenesis and neuronal migration (for more details, see table S6 of Giorda *et al.* [2009]).

Another hypothesis is that speech delay may be the result of global language regression in a child with MR who lived in a deprived home lacking the child-mother interactions necessary for correct language development. There is growing evidence that exposure to highly responsive parenting styles, namely the maternal response, plays a key role in the development of children with intellectual disabilities (Warren and Brady, 2007). Moreover, some investigations suggest that the children of mentally retarded parents are at risk of language and cognitive delay, MR, and maltreatment, as retarded mothers interact less positively with their children during play and can be taught to improve their child-rearing skills (Feldman, 1986). This is probably the case for our adult patients of Family 2 who lived in a deprived family setting.

Another point of interest is the association between dupXp11.22-11.23 and facial dysmorphic features. The

dysmorphisms were described in almost all cases (except two) but they differed from patient to patient. For this reason, a larger sample of subjects is needed to establish whether the dysmorphism is a distinctive feature of the syndrome or is due to a random association.

Finally, an association between dupXp11.22-p11.23 syndrome and early puberty/excess weight (seven of nine patients) and autoimmune disease (adult cases of Family 2 and sporadic Case 1) was evident. Early puberty (and the excess weight that may be a symptom of this) may be the manifestation of a genetic disorder involving a sex chromosome, whereas the association with autoimmune disease could be either a chance occurrence or related to sex chromosome impairment. Clinical and experimental evidence has strengthened the link between sex chromosomes and immunity (Selmi, 2008).

To our knowledge, only three patients have been described with a similar syndrome, due to deletions in 16p13 and characterised by intellectual disability (including a speech disturbance), various dysmorphic features, and seizure disorders involving the rolandic region (including ESES) (Reutlinger *et al.*, 2010). Therefore, similar phenotypes can be the result of different genetic disorders which are likely to be disclosed by performing CGH array in patients with normal karyotype analysis.

In conclusion, we describe the clinical and neurological phenotype of a new syndrome related to Xp microduplication, characterised by mild facial dysmorphisms (in almost all patients), MR, ESES during childhood, EEG abnormalities activated during sleep in adults, and language impairment in the absence of structural brain abnormalities. Minor characteristics include: epilepsy (usually with a good prognosis), behavioural disturbances, autoimmune disorders, early puberty, and excess weight.

We suggest that in the presence of MR, speech delay and ESES, the CGH array will serve to disclose additional cases of Xp11.22-11.23 microduplication in selected patients, thereby demonstrating that the frequency of this syndrome could be currently underestimated. □

Acknowledgments.

We thank Anne Collins and Daniel Barron for editing the English text and Elena Zoni for help in manuscript editing. We thank Dr Federico Oppi for help in Neuropsychological evaluation, Drs Cesa Scaglione and Sara Marconi for electroneurography and Drs Emanuela Avola and Pinella Failla for following Families 1 and 3.

Disclosure.

None of the authors has any conflict of interest or financial support to disclose.

References

- Deonna TW. Acquired epileptiform aphasia in children (Landau-Kleffner syndrome). *J Clin Neurophysiol* 1991;8: 288-98.
- Feldman MA. Research on parenting by mentally retarded persons. *Psychiatr Clin North Am* 1986;9:777-96.
- Giorda R, Bonaglia MC, Beri S, et al. Complex segmental duplications mediate a recurrent dup(X)(p11.22-p11.23) associated with mental retardation, speech delay, and EEG anomalies in males and females. *Am J Hum Genet* 2009;85:394-400.
- Patry G, Lyagoubi S, Tassinari CA. Subclinical "electrical status epilepticus" induced by sleep in children. *Arch Neurol* 1971;24: 242-52.
- Reutlinger C, Helbig I, Gawelczyk B, et al. Deletions in 16p13 including GRIN2A in patients with intellectual disability, various dysmorphic features, and seizure disorders of the rolandic region. *Epilepsia* 2010;51: 1870-3.
- Selmi C. The X in sex: how autoimmune diseases revolve around sex chromosomes. *Best Pract Res Clin Rheumatol* 2008;22: 913-22.
- Tassinari CA, Rubboli G. Cognition and paroxysmal EEG activities: from a single spike to electrical status epilepticus during sleep. *Epilepsia* 2006;47: 40-3.
- Tassinari CA, Rubboli G, Volpi L, et al. Encephalopathy with electrical status epilepticus during slow sleep or ESES syndrome including the acquired aphasia. *Clin Neurophysiol* 2000;111: S94-102.
- Tassinari CA, Cantalupo G, Rios-Pohl L, Giustina ED, Rubboli G. Encephalopathy with status epilepticus during slow sleep: "the Penelope syndrome". *Epilepsia* 2009;50: 4-8.
- Tononi G, Cirelli C. Sleep and synaptic homeostasis: a hypothesis. *Brain Res Bull* 2003;62: 143-50.
- Warren SF, Brady NC. The role of maternal responsivity in the development of children with intellectual disabilities. *Ment Retard Dev Disabil Res Rev* 2007;13: 330-8.

Appendix

fMRI: stimulation paradigm

A classical block paradigm consisting of 30-second stimulations alternating with 30-second periods of rest for a total of 5 minutes was used in all tasks. Owing to the patients' impaired mental faculties, very simple tasks were performed. The first task (auditory task) consisted of listening to a voice narrating five of Aesop's fables, each completed in 30 seconds ("The hare and the turtle", "The fox and the grapes", "The lion and the mouse", "The frogs desiring a king", and "The ant and the cicada") followed by 30 seconds of silence. The second task (visual task) was silent (covert) image naming: simple images (a flower, house, car, etc), each persisting for five seconds on the screen, were shown to the patient in sequence for 30 seconds, followed by a 30-second period of black screen. The patient had simply to think of the name of each image.

fMRI: image acquisition

A General Electric 3 Tesla Signa Excite system and an eight channel "phased array" coil were used to acquire fMRI and morphological sequences. fMRI acquisition consisted of the whole brain, 29 interleaved slices, and an axial (bicommissural AC-PC plane), single-shot, gradient-echo echo-planar sequence (GE-EPI), which was continuously acquired during the stimulation paradigm. *Structural MRI* consisted of whole brain coverage (162 slides), and sagittal, T1-weighted, high definition fast spoiled inversion recovery 3D gradient echo (FSPGR-IR) BRAin Volume (BRAVO) imaging which affords isotropic whole-brain coverage with $1 \times 1 \times 1$ mm resolution. Non-magnetic goggles and headphones (Visual Stim XGA and Digital Stereo Commander XG, Resonance Technology) were used to give subjects visual and auditory stimuli. Moreover, another morphological axial T2-weighted fast spin-echo (FSE) sequence was acquired.

fMRI: image analysis

Image analysis was performed by using BrainVoyager v. 2.08 (Brain Innovation®, Maastricht, The Netherlands). fMRI acquisitions were pre-processed (default slice scan time correction, 3D motion correction and temporal filtering correction, 8 mm smoothing, 108 voxel clustering), co-registered to the segmented morphological sequence and converted into three-dimensional volume time courses.

fMRI: results

The first task (text listening vs silence) evoked eloquent areas in the superior part of the temporal region bilaterally, with a weak prevalence on the left side, where they appeared discontinuous and showed a further small activation in the postero-medial part of the superior temporal gyrus, which anatomically corresponded to the postero-medial part of the Wernicke area. Moreover, other activated areas were appreciable in the frontal opercular zone bilaterally, but prevailing on the left side. The anatomical localisation of these eloquent areas corresponded to the anatomical localisation of Broca's area. A wide bilateral occipital activation was also evident, due to the PC desktop shown in the goggles the patient wore. Because of the patient's movements, this task resulted in other smaller activations, which were only partially corrected by the software. The second task (image naming vs black screen) was repeated twice because of the absence of any activation in the real-time processing. In the repeated task, besides the wide bilateral occipital eloquent areas evoked by the visual stimulation, a smaller activation in the frontal operculum was also evident: it appeared bilateral, but clearly prevalent on the left side. Again, the anatomical localisation of the aforesaid activations corresponded to Broca's area. It should be pointed out that the threshold in this trial was very low ($p < 0.05$) compared to the threshold of the first task ($p < 0.001$).

In this case, fMRI showed asymmetries in the language eloquent areas pointing to a left hemispherical dominance. In our experience, the normal population showed larger responses (wider eloquent areas) evoked by the same kinds of stimulation in both the receptive and expressive language trials. The smaller width we found in the language eloquent areas in our patient could be one of the signs of hypo/poor function of the brain and could represent one of the neurological correlates of the clinical characteristics of this pathology (figure 2).