

# **Atlas of Electroencephalography**

**Ali A. Asadi-Pooya, M.D., Dennis J. Dlugos, M.D.,**

**Christopher T. Skidmore, M.D., Michael R. Sperling, M.D.**

**Thomas Jefferson University, Philadelphia, PA, USA**

# Authors

**Ali A. Asadi-Pooya, M.D.**

Jefferson Comprehensive Epilepsy Center, Thomas Jefferson University, Philadelphia, USA  
Department of Neurology, Shiraz University of Medical Sciences, Shiraz, Iran

**Dennis J. Dlugos, M.D.**

The Children's Hospital of Philadelphia, University of Pennsylvania, Philadelphia, USA

**Christopher T. Skidmore, M.D.**

Jefferson Comprehensive Epilepsy Center, Thomas Jefferson University, Philadelphia, USA

**Michael R. Sperling, M.D.**

Jefferson Comprehensive Epilepsy Center, Thomas Jefferson University, Philadelphia, USA

# Table of Contents

## Title

## Chapter

■ Title and Table of Contents	
■ EEG Techniques	1
■ Background Rhythms in EEG	2
■ Normal EEG in Wakefulness and Sleep	3
■ Activation Methods	4
■ Artifacts	5
■ Normal EEG Variants	6
■ Epileptiform EEG Abnormalities	7
■ Non-epileptiform EEG Abnormalities	8
■ Unclassified EEG Findings	9
■ References	

# What Is New in This Edition?

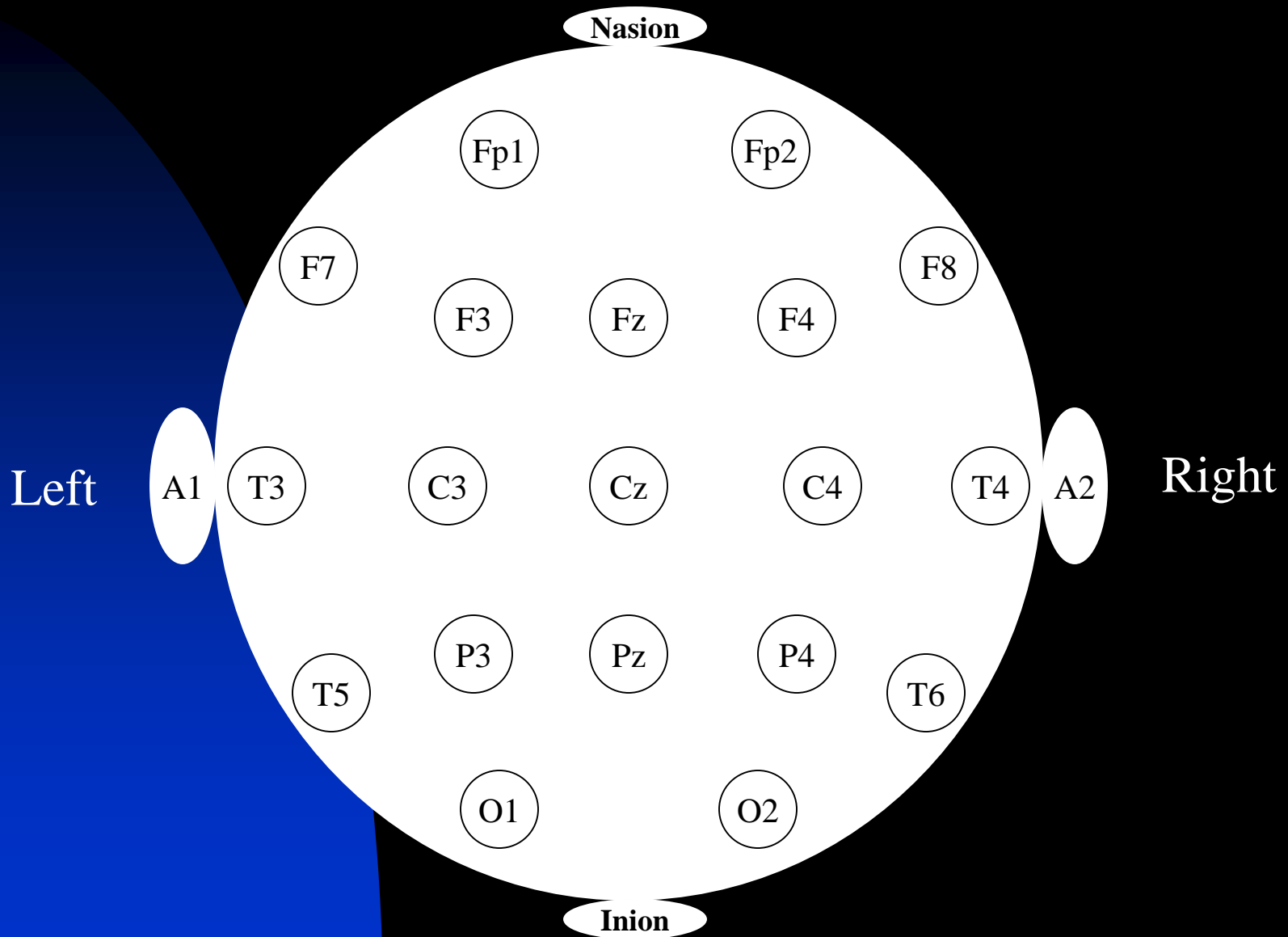
- Updated with the new definitions and terminologies (e.g., on status epilepticus, periodic discharges, etc.)
- Slides on “How to Report” various EEG findings are added
- All slides are reviewed and revised
- New and up-to-date references are reviewed and included



# **Chapter 1**

## **EEG Techniques**

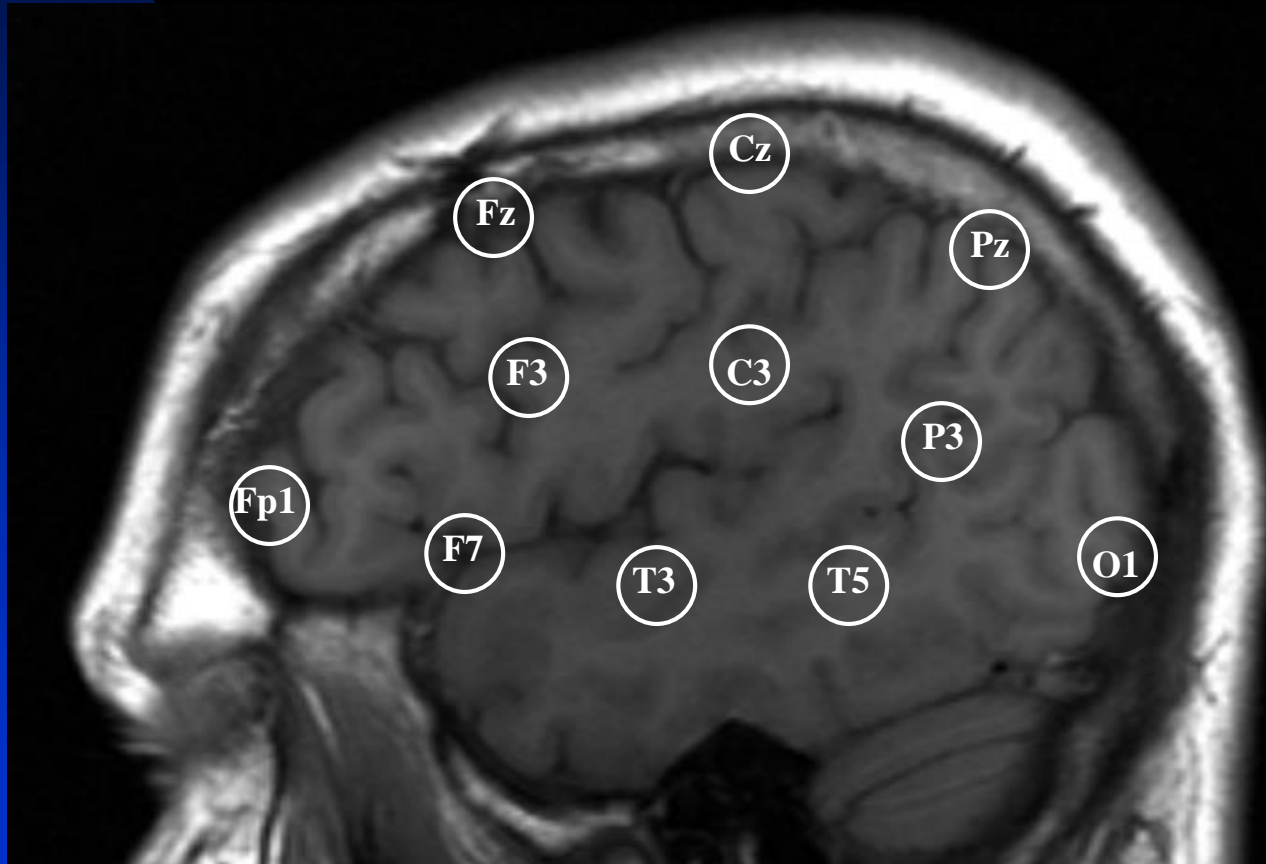
# Electrode Placement in International 10-20 System



# Alphanumeric Nomenclature of Electrodes in 10-20 system

- Fp1, Fp2: frontopolar
- F3, F4: mid-frontal
- F7, F8: fronto-temporal
- Fz: midline frontal
- T3 (T7), T4 (T8): mid-temporal
- T5 (P7), T6 (P8): posterior temporal
- A1, A2: ear
- C3, C4: central
- Cz: vertex
- P3, P4: parietal
- Pz: midline parietal
- O1, O2: occipital

# Brain Regions Underlying the Scalp EEG Electrodes



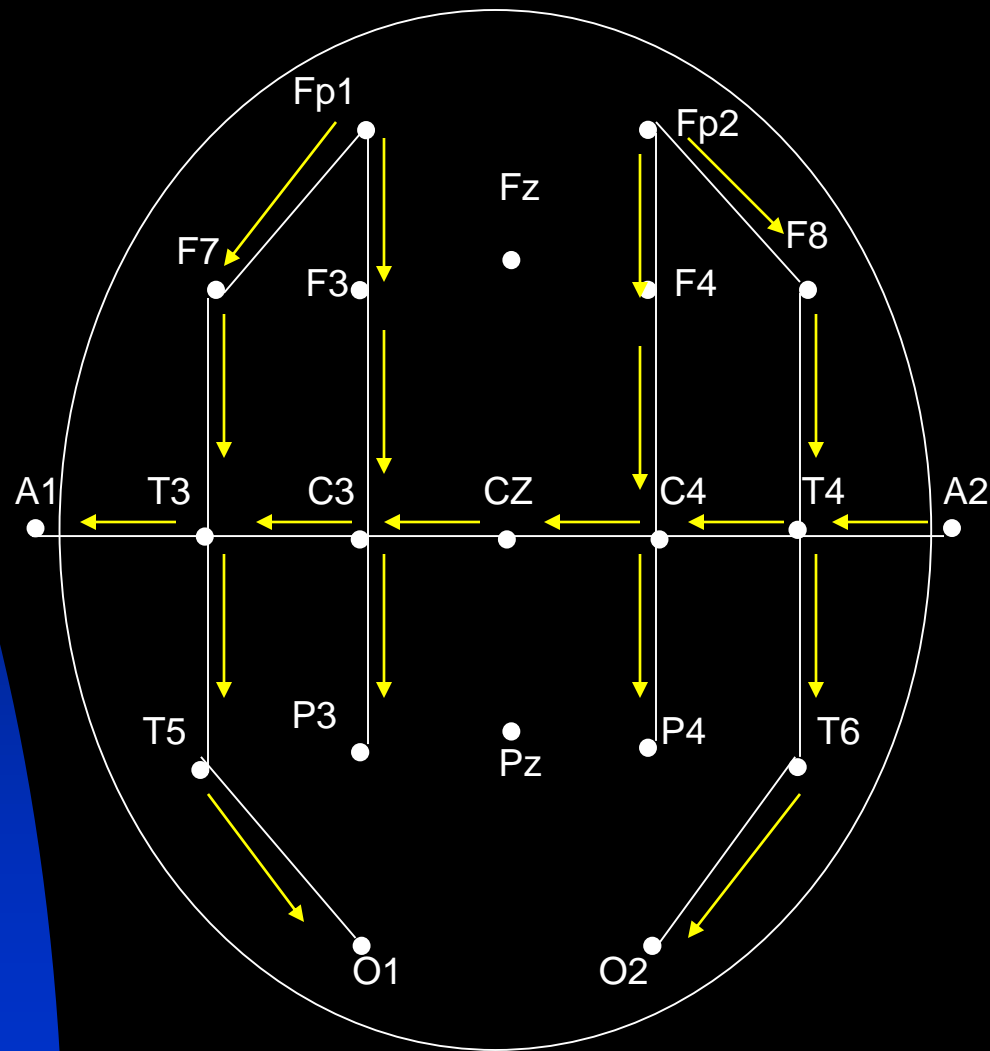
# Montage Design Guidelines

- A good montage can be easily imagined and remembered
- Record at least 16 channels
- Use all the 21 electrodes
- Use both bipolar and referential montages
- Use simple montages
- Label each montage in the recording
- Organize the montage: anterior first, posterior later; right above left or vice versa

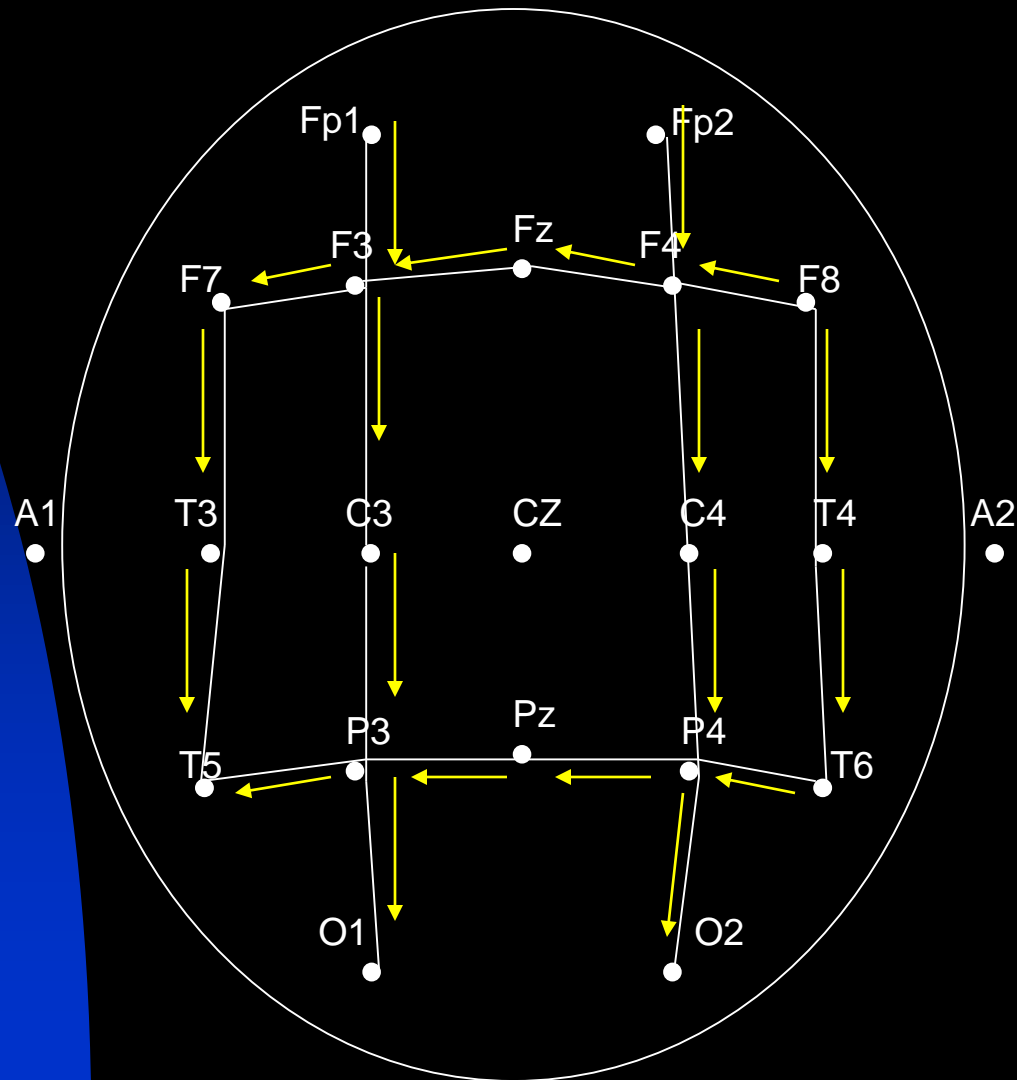
# Montage Design at Thomas Jefferson University

- Montages are created to give a clear picture of the spatial distribution of EEG across the cortex
- Bidirectional montages with orthogonal chains to facilitate localization
- Major bipolar EEG Montages:
  - ★ Temporal longitudinal bipolar montage: evaluates the temporal regions more clearly
  - ★ Parasagittal longitudinal bipolar montage: evaluates the parasagittal regions more clearly
  - ★ Circular bipolar montage: evaluates prefrontal and occipital regions
  - ★ Temporal (T1-T2) montage: evaluates the temporal regions very clearly
- Major referential EEG Montages:
  - ★ Ear referential montage
  - ★ Cz referential montage

# Temporal Longitudinal Bipolar Montage

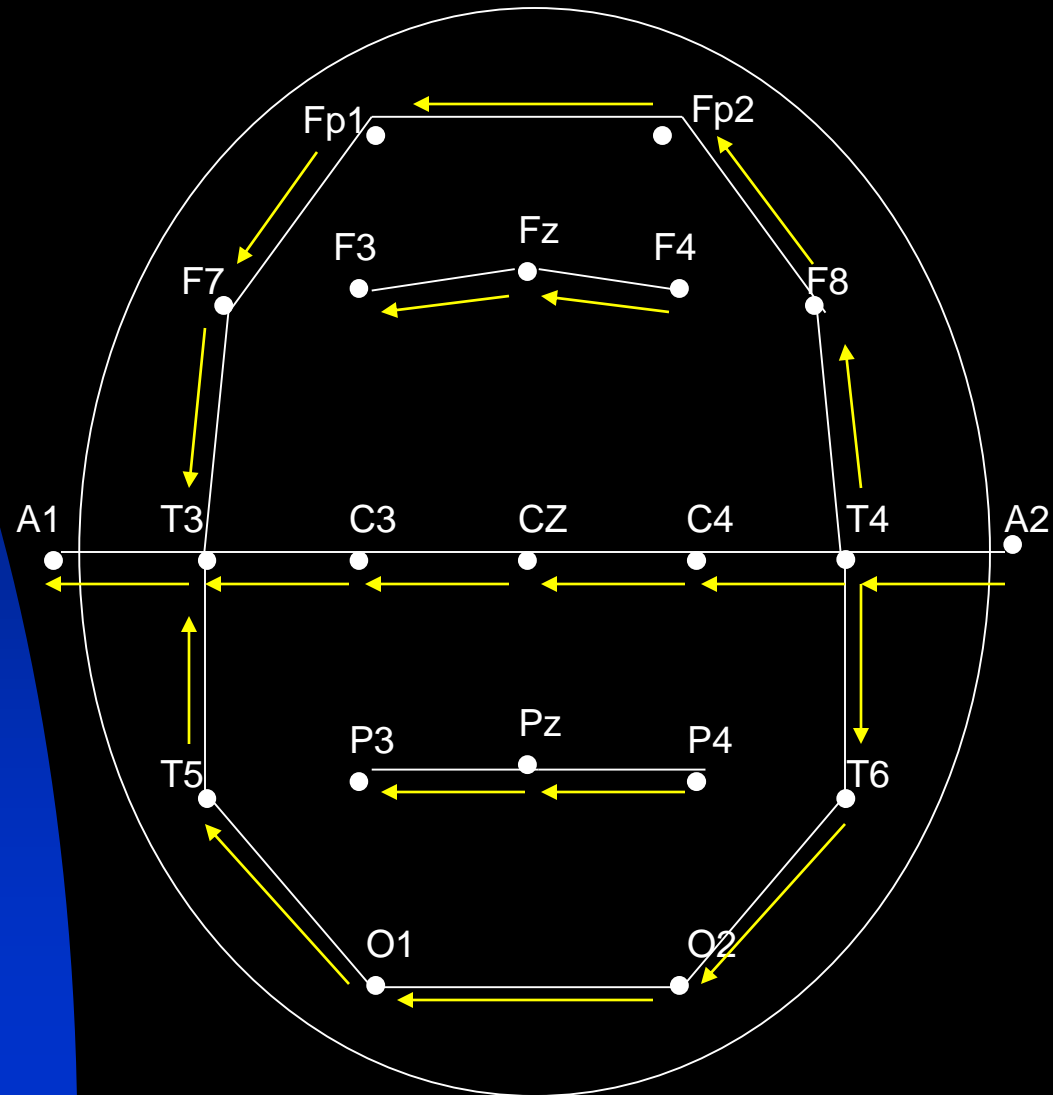


# Parasagittal Bipolar Montage



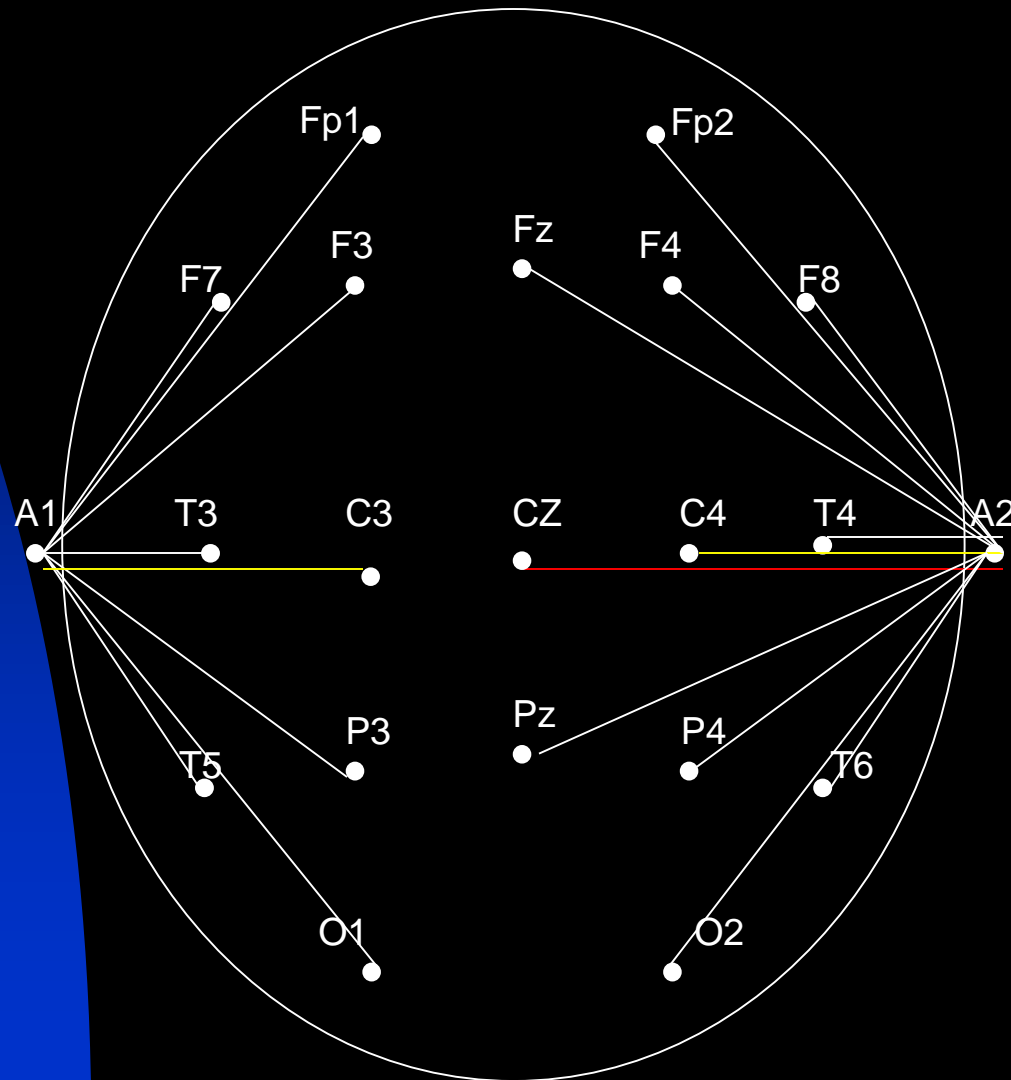


# Circular Bipolar Montage



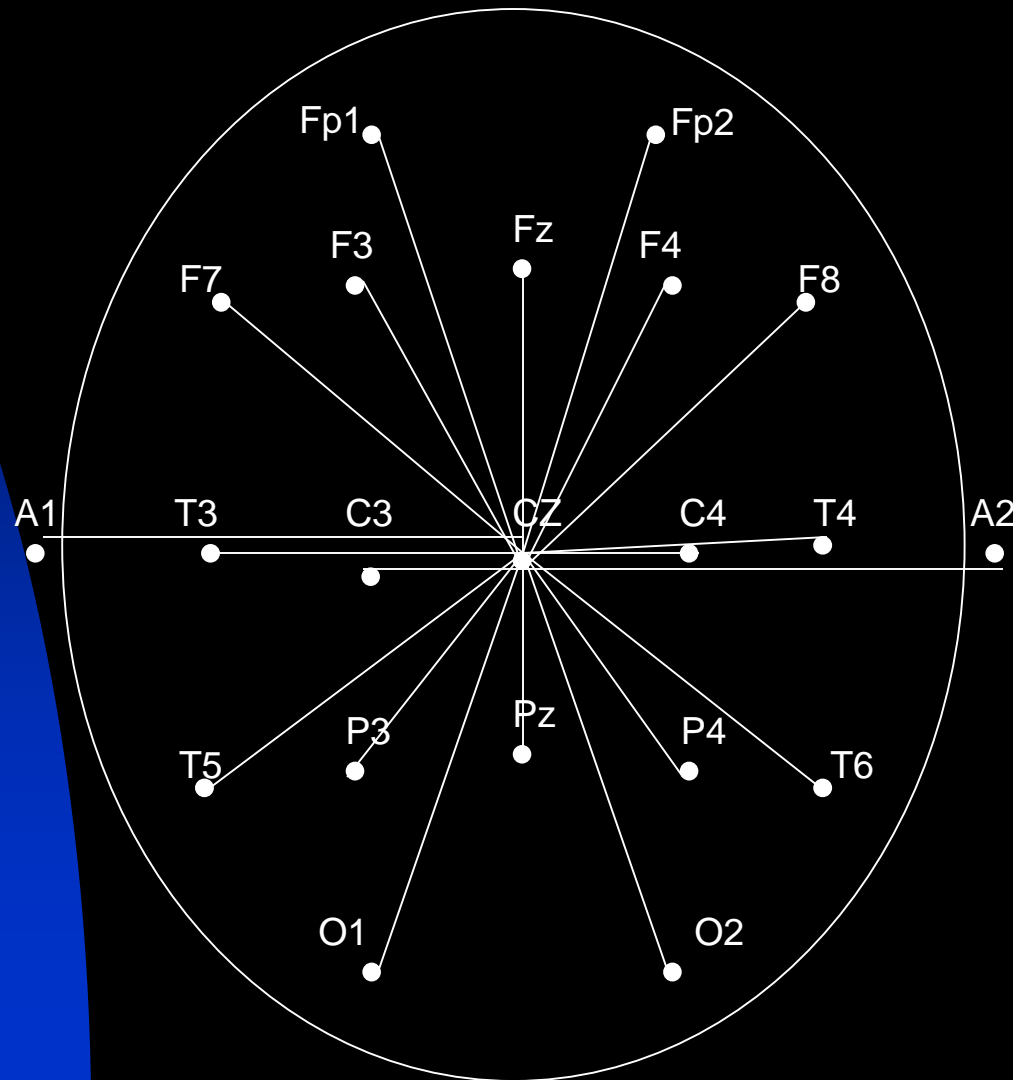
# Ear Reference Montage:

## An Ear Electrode is the Second Input for All Channels

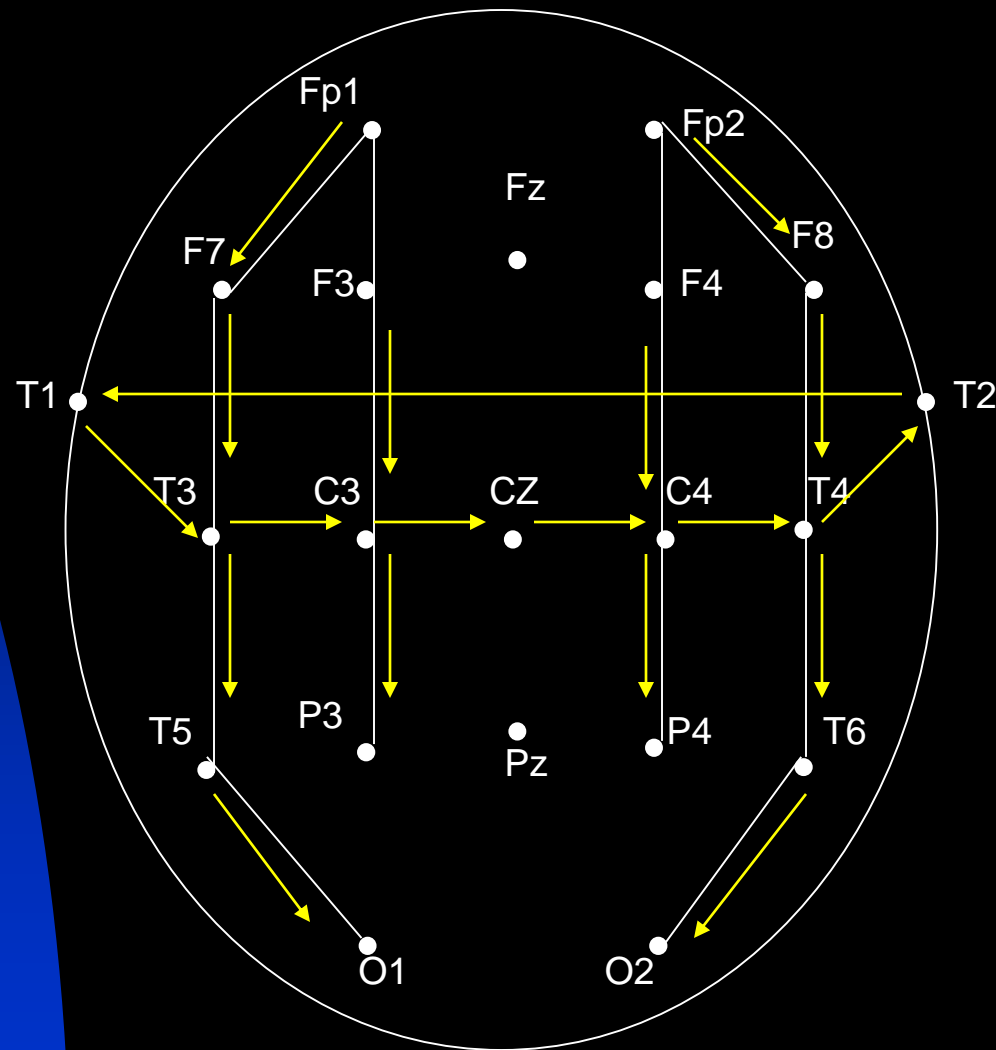


# Cz Reference Montage:

## Cz Electrode is the Second Input for All Channels



# Temporal (T1-T2) Bipolar Montage



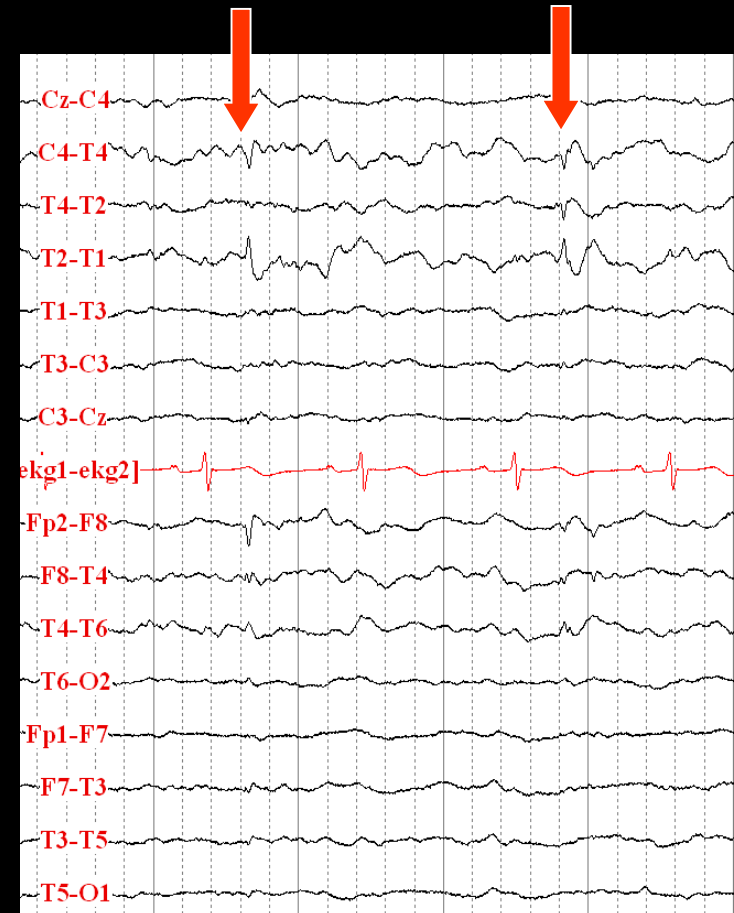
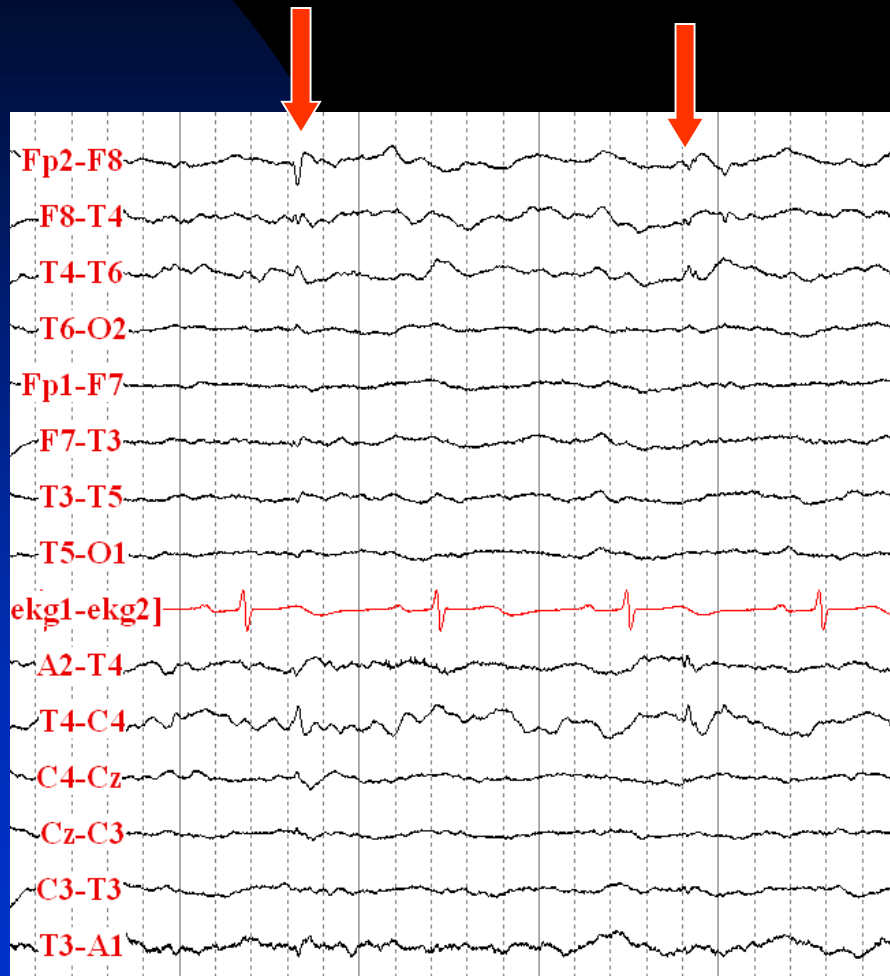
See the next image for explanation

# Temporal (T1-T2) Bipolar Montage

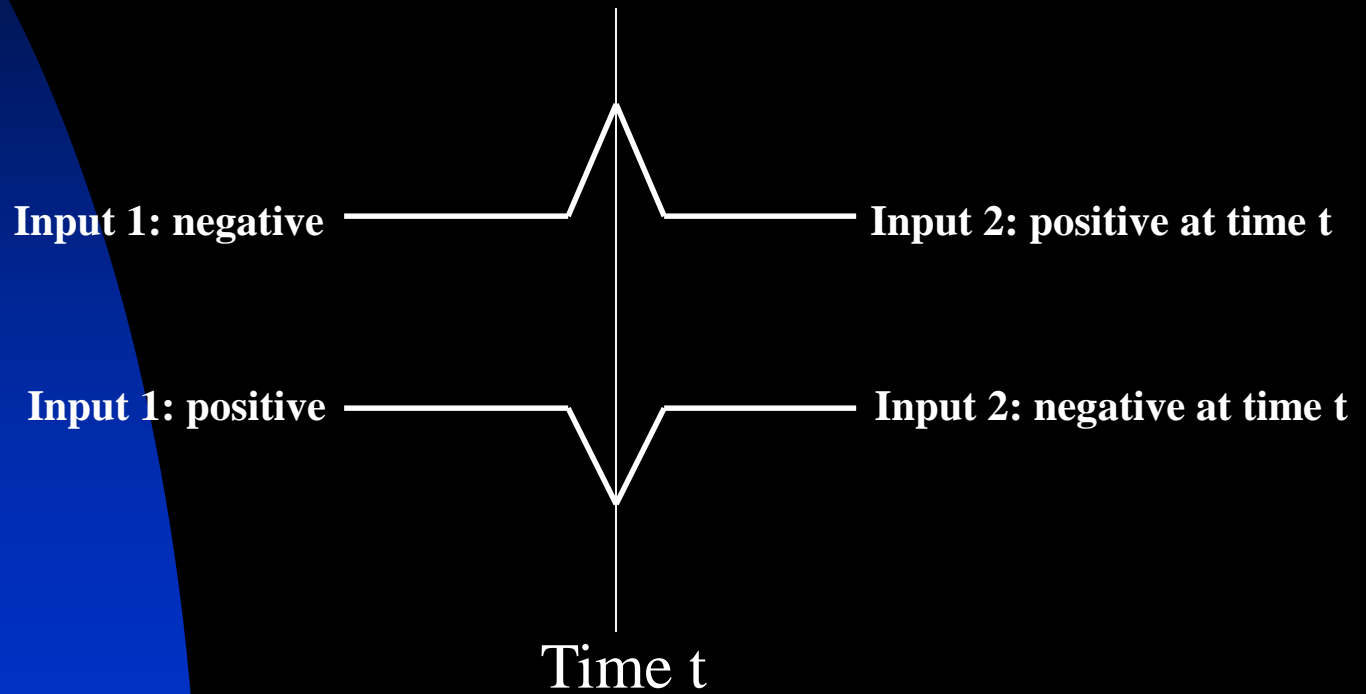
- This montage is very good for patients with suspected temporal lobe epilepsy
- It shows the temporal changes in both anteroposterior and transverse chains and increases the possibility of detecting any abnormalities in this area
- During ictal recordings it may show the seizure onset earlier and more obviously

Next image shows an example

# Right Temporal Spikes Are More Easily Seen in the Temporal Bipolar Montage




# Rules of Polarity

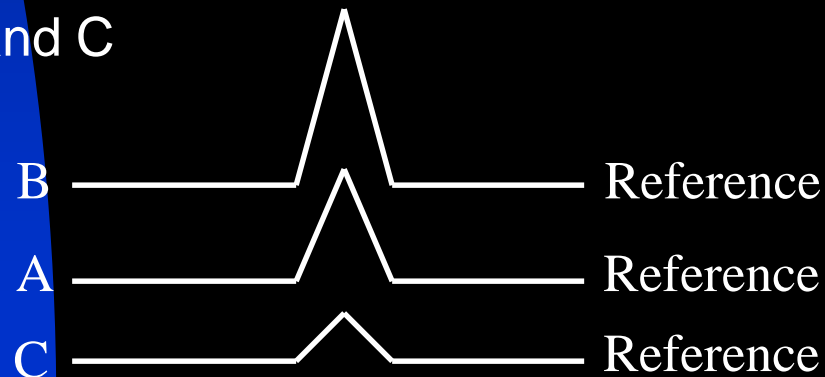


# Interpretation of Findings in Different Montages

- Negative phase reversal in bipolar montage represents the region with maximum potential (field maximum): B is more negative than A and C



- Electrode with highest amplitude in a referential montage represents the region with maximum activity among sampled electrodes: B is more negative than A and C

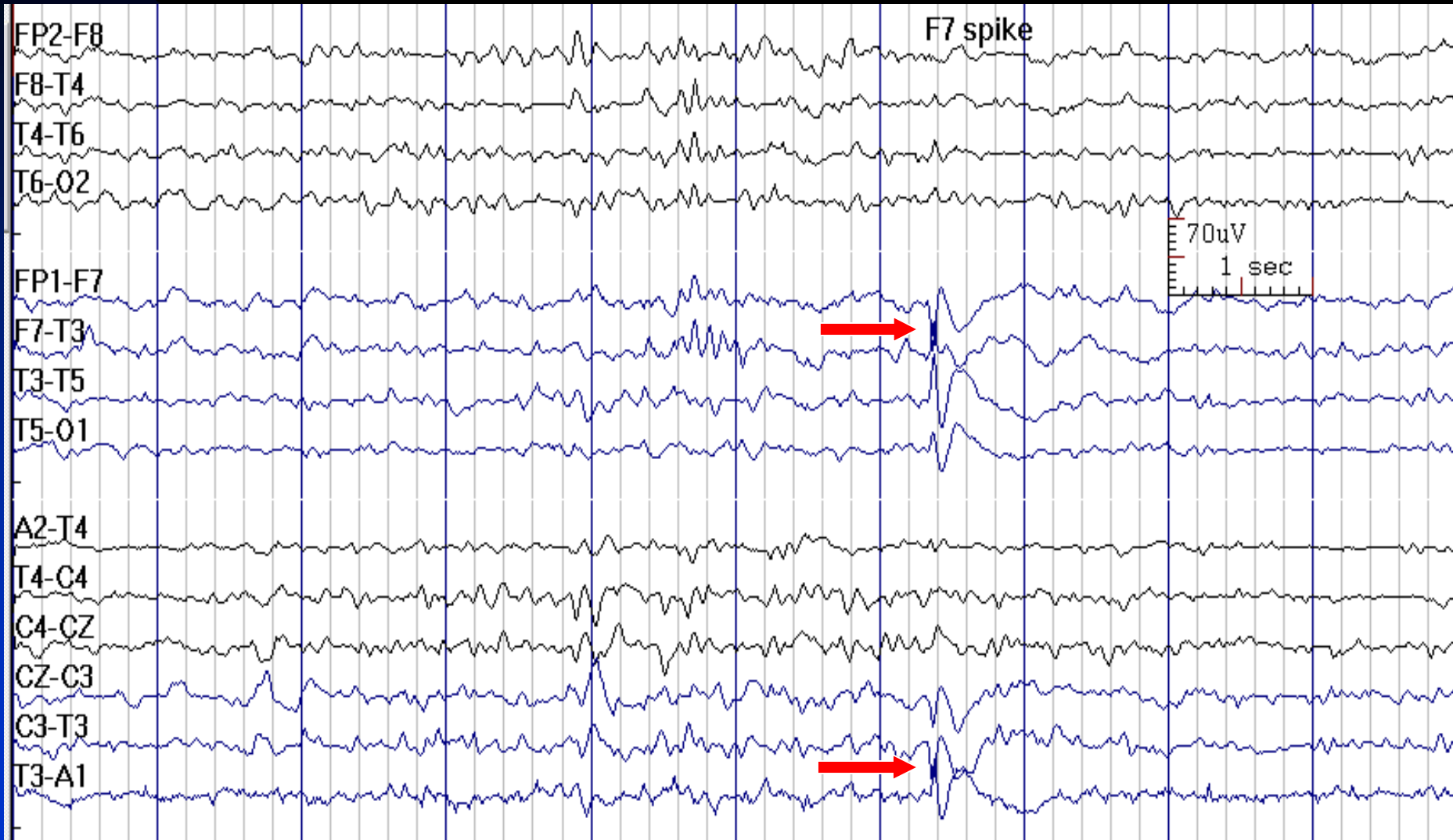




# Use of Reference Montage

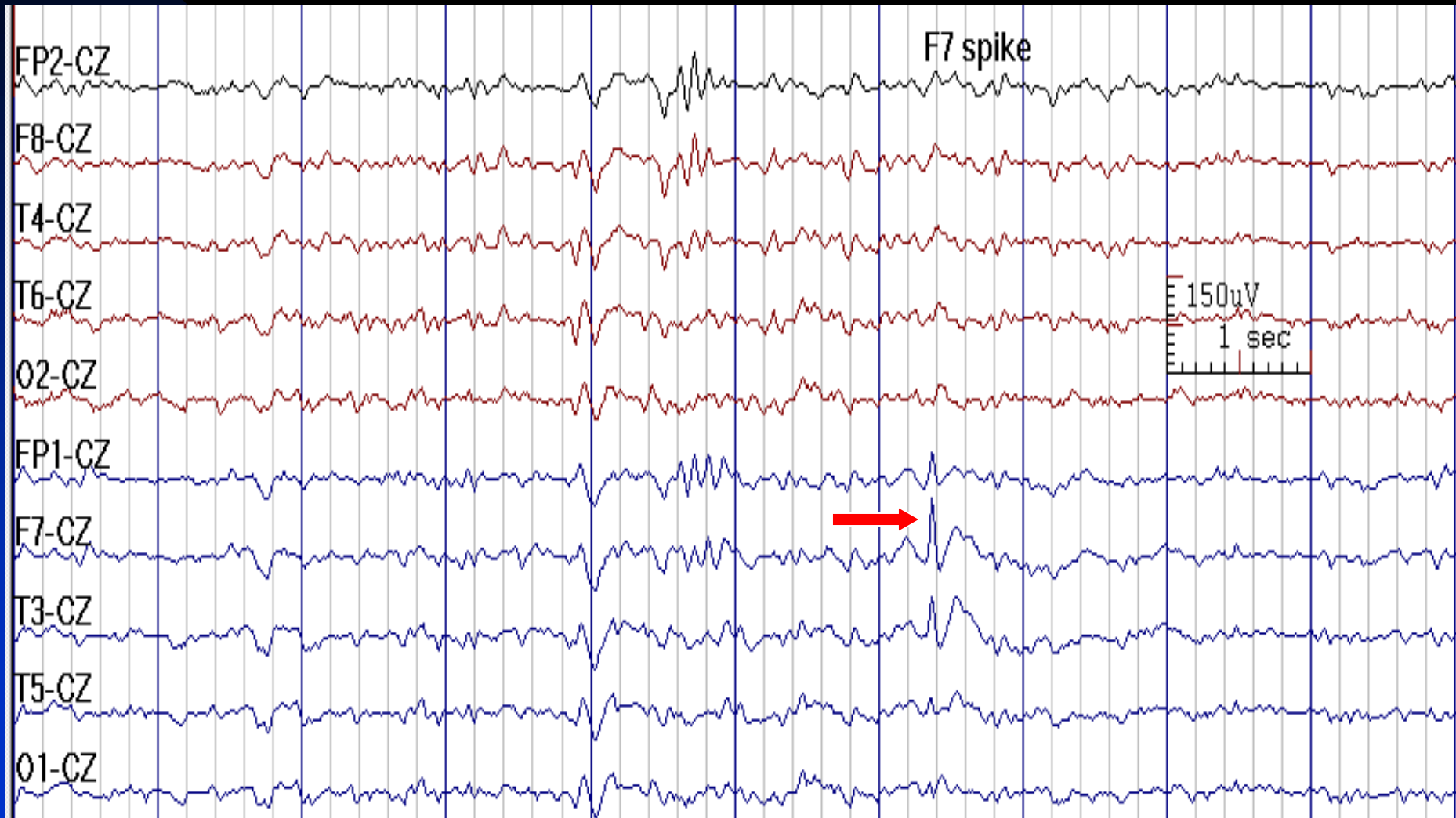
- Reference Montages are good for determining the true amplitude and morphology of a waveform
- Reference electrode ideally should be out of field
- For temporal electrodes (F7/F8, T3/T4, T5/T6), Cz is usually a good scalp reference. However, Cz may not be a good reference choice during sleep, because normal sleep activities are maximal at Cz
- For parasagittal and midline electrodes (F3/F4, C3/C4, P3/P4), generalized discharges (generalized spike-wave complexes, triphasic waves, FIRDA, etc.), or occipital abnormalities, ear is usually a good scalp reference

# F7 Sharp Wave: Negative Phase Reversal in Bipolar montage



See the next image for the same finding in reference montage

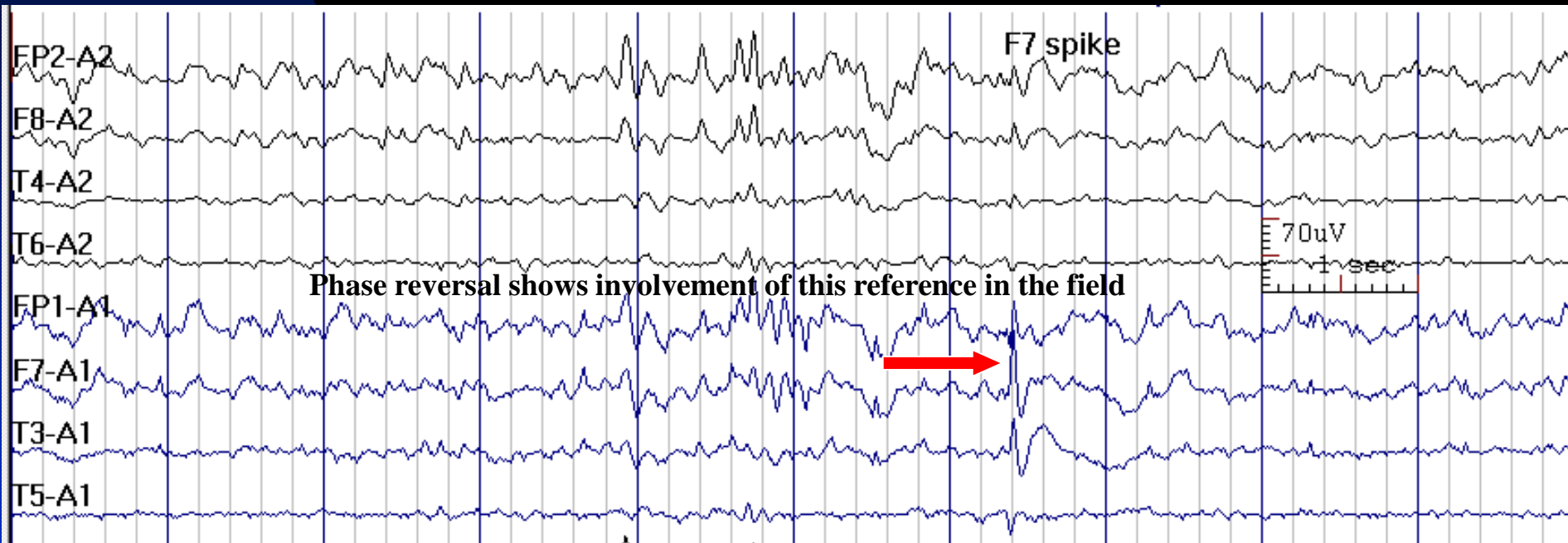
# F7 Sharp Wave: Highest Amplitude in Cz Reference



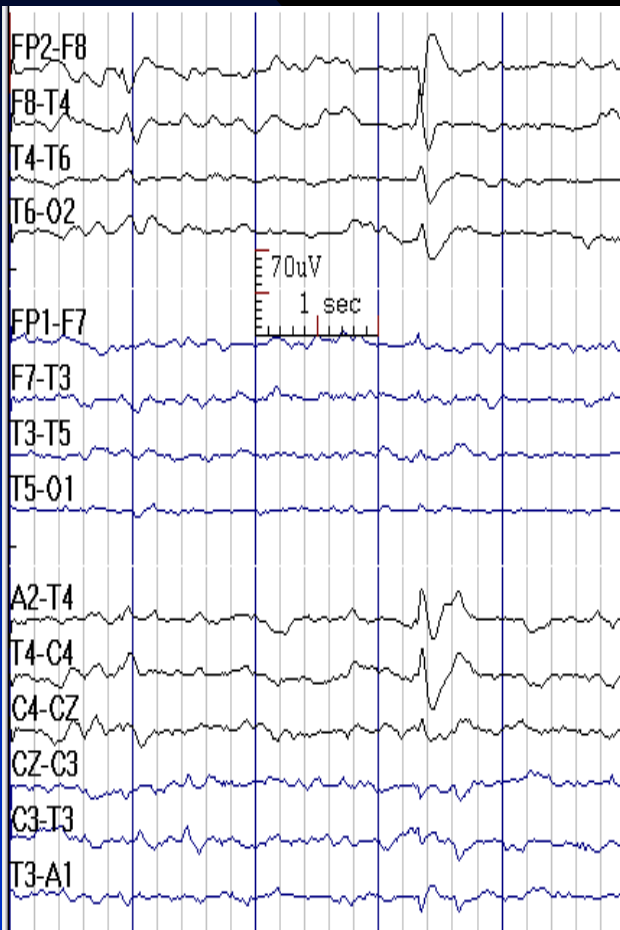
See the previous image for the same finding in temporal longitudinal montage

# Ear is not a Good Reference for Temporal Chain: It Is Involved in the Field

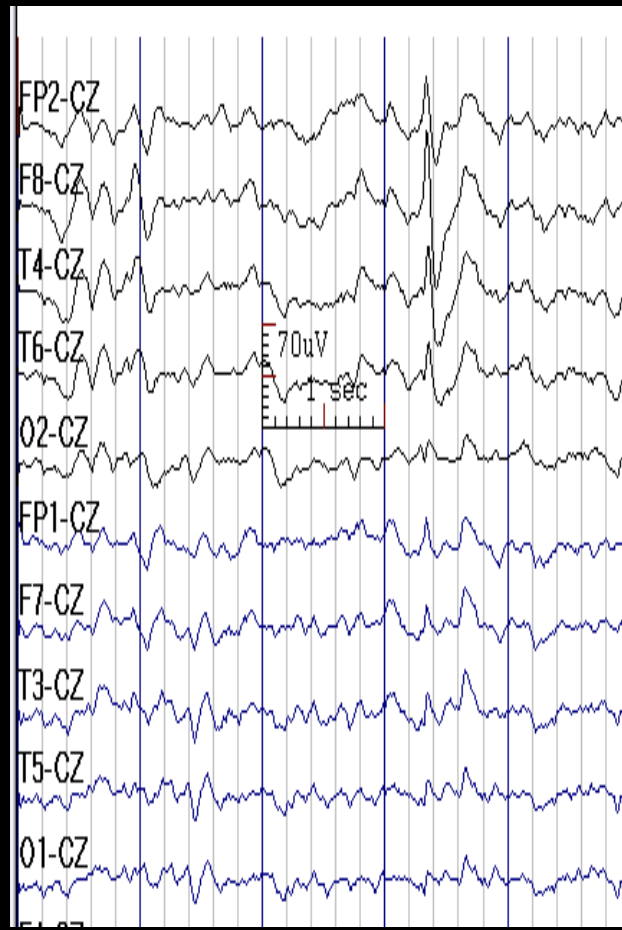
(Same Discharge as in Previous Image)



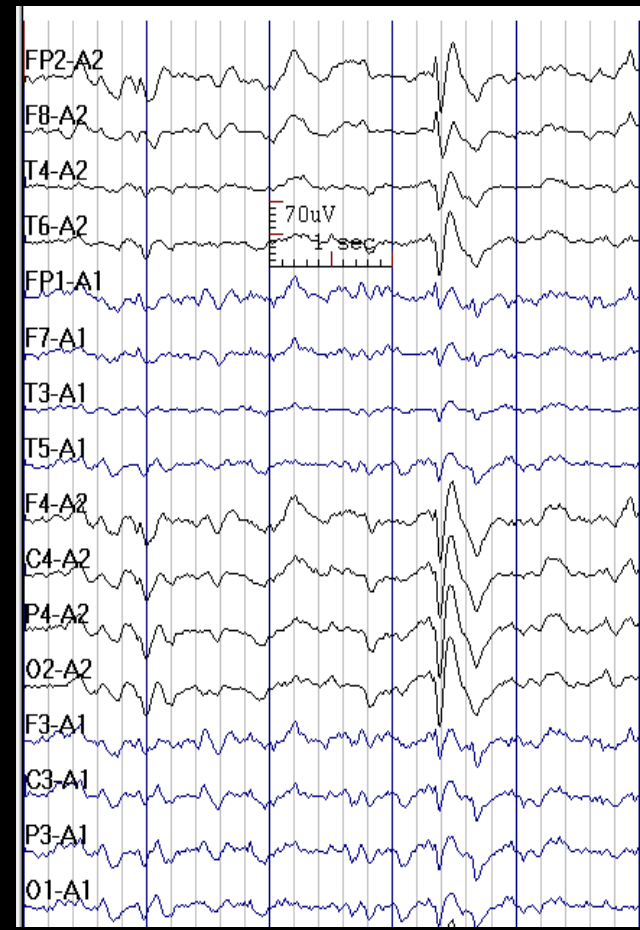
**F8 Spike in Bipolar Montage**



**F8 Spike in Cz Reference Montage**



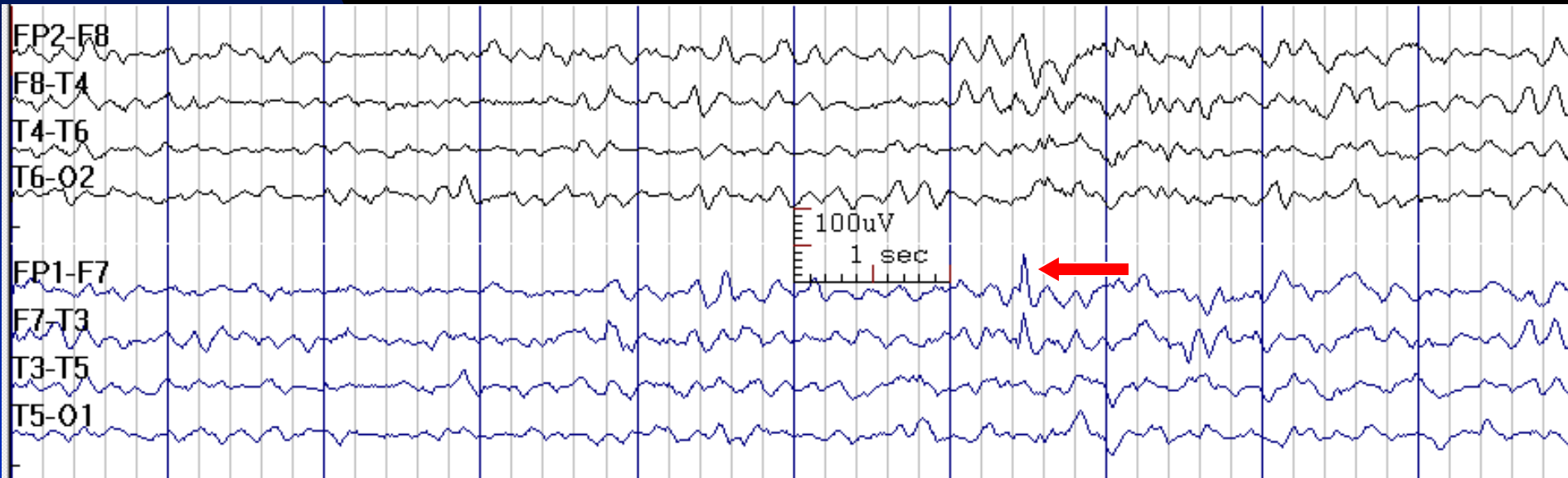
**F8 Spike in Ear Reference Montage**



# Analyzing End of the Chain Electrodes

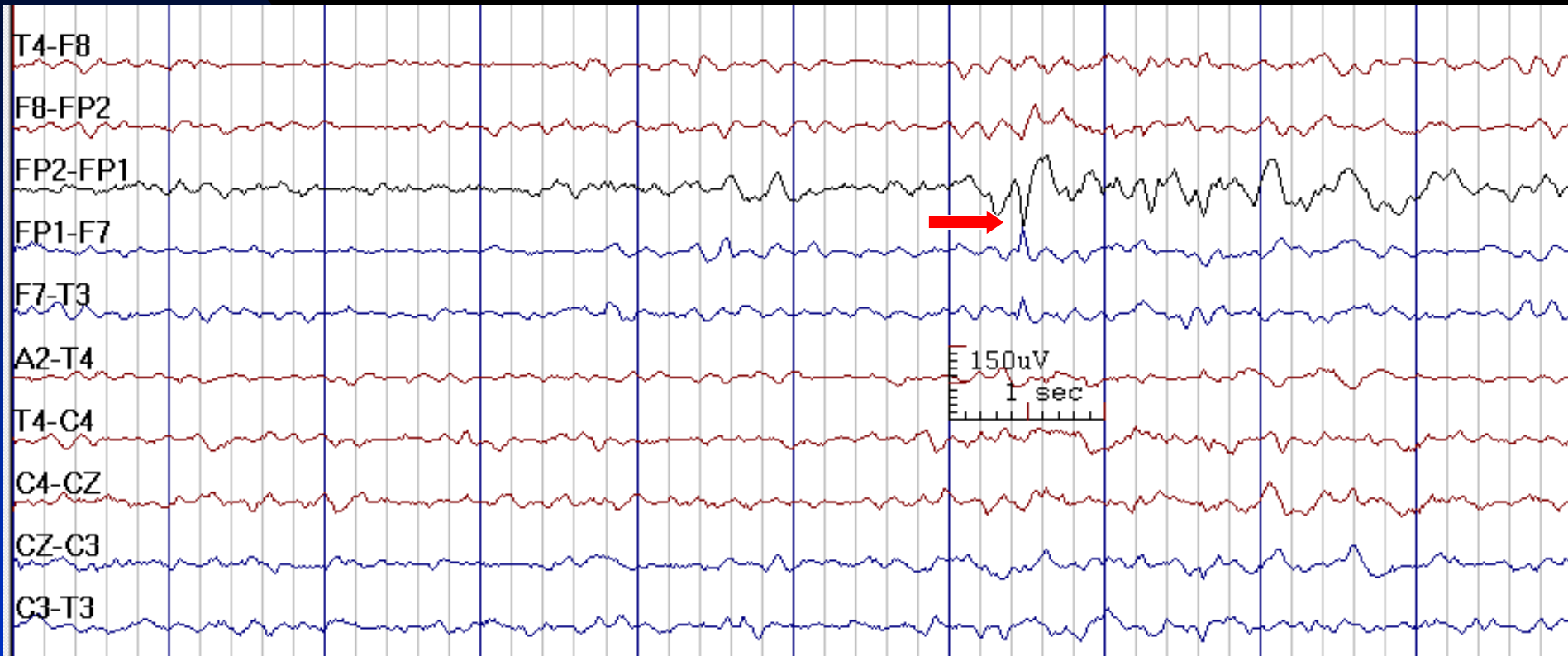
- Fp1 and Fp2 electrodes are end of the chain of electrodes in anterior-posterior bipolar montages; therefore, when there is a suspicious finding in these electrodes, it is useful to employ a bipolar montage in which they are linked (e.g., hatband, circle montage) to evaluate the region with maximum potential (negative phase reversal)
- This is also true for O1 and O2 electrodes

# Fp1 Spike in a 35-Year-Old Man with Focal Epilepsy



Next image shows the same finding in circular montage


# Fp1 Spike in Bipolar Circular Montage



See the previous image for the same finding in temporal longitudinal montage




# Field Determination Based on Anteroposterior and Transverse Planes


A-C: 

C-N: 

N-E: 

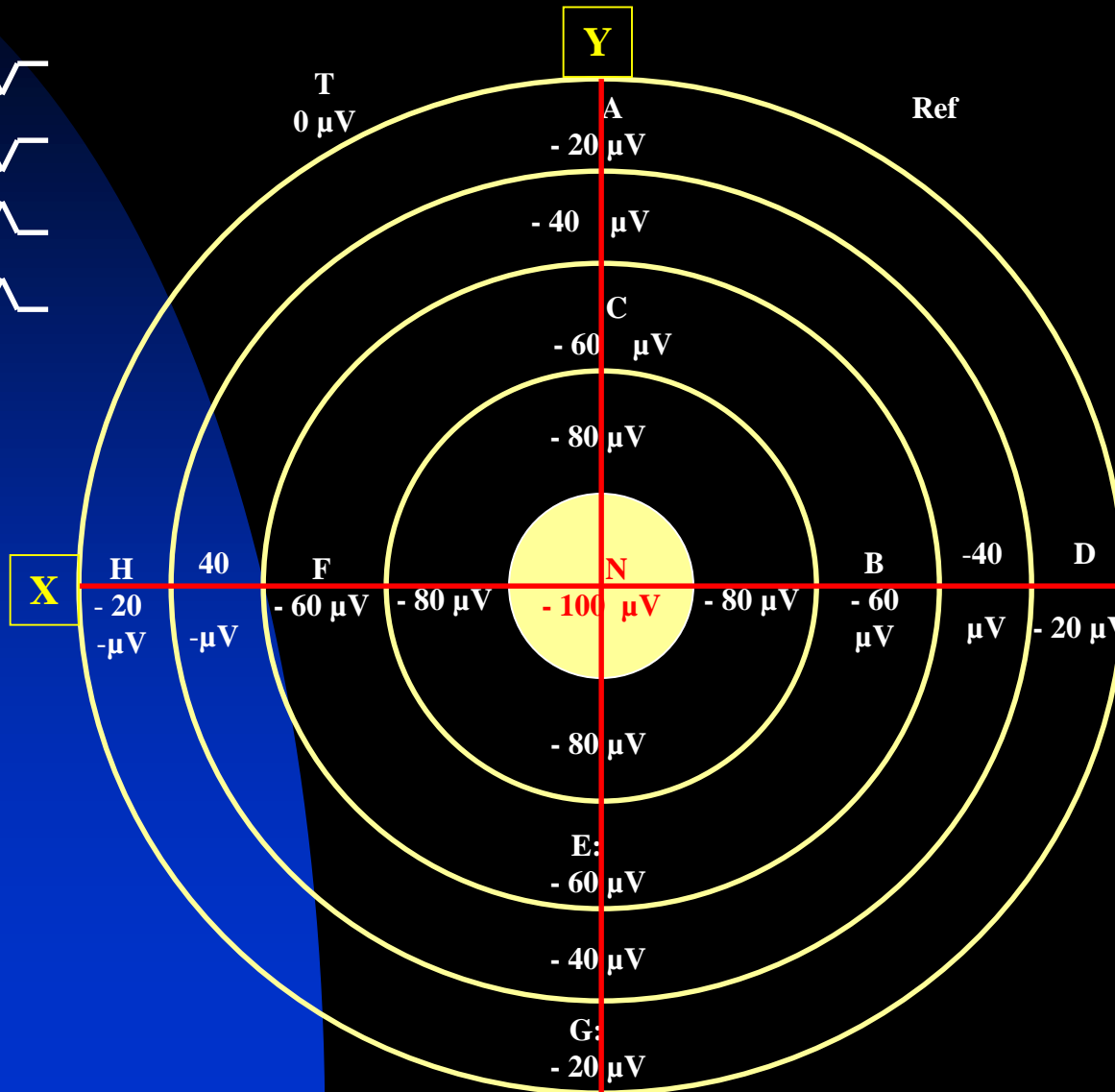
E-G: 

D-B: 

B-N: 

N-F: 

F-H: 



NOTE: Negative phase reversal in bipolar montage represents the region with maximum potential: in this slide **N** is the point of maximum potential in AP (Y) and transverse (X) planes

# Field Determination Based on Anteroposterior and Transverse Planes


A-C: 

C-G: 

G-I: 

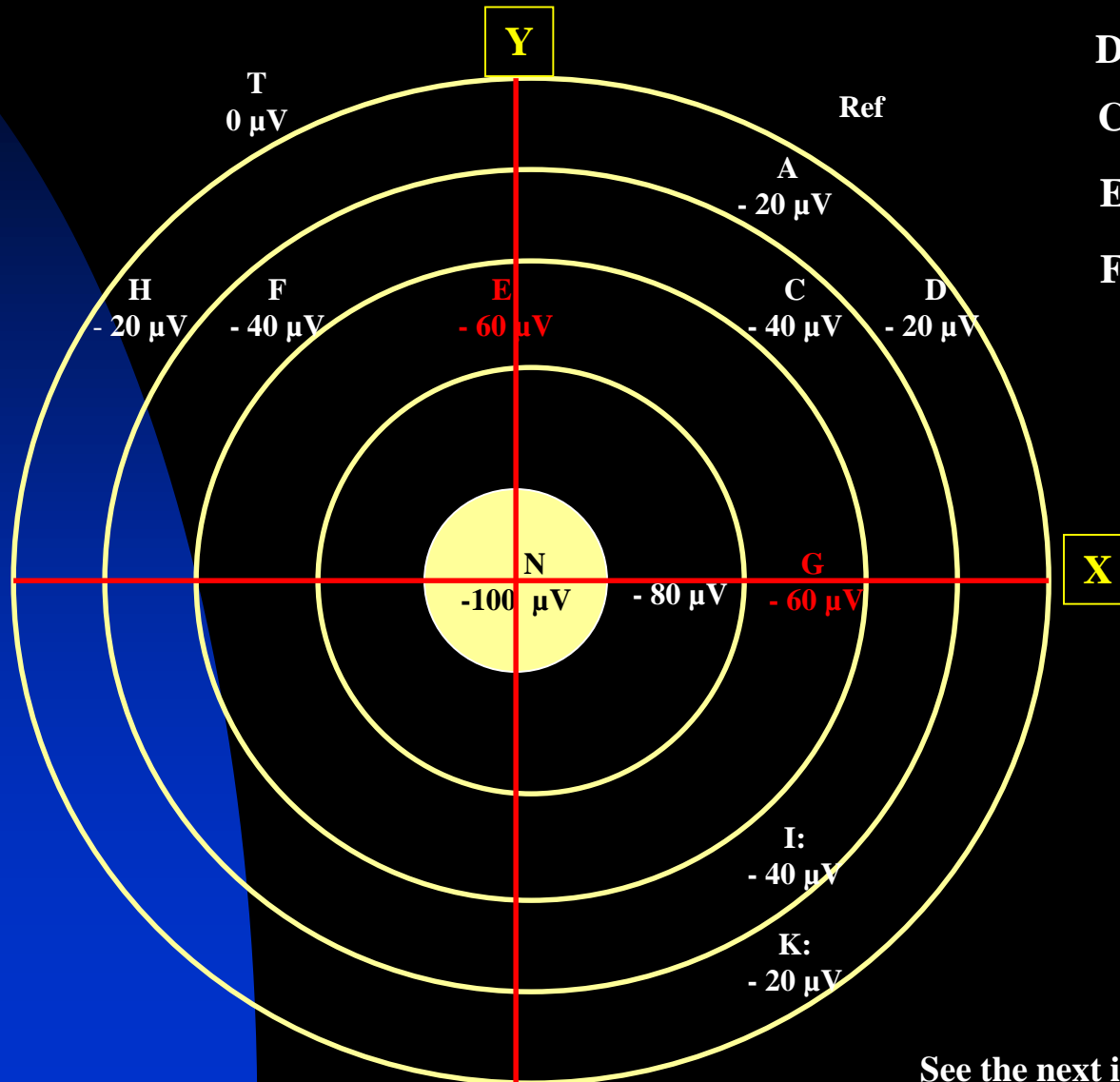
I-K: 

D-C: 

C-E: 

E-F: 

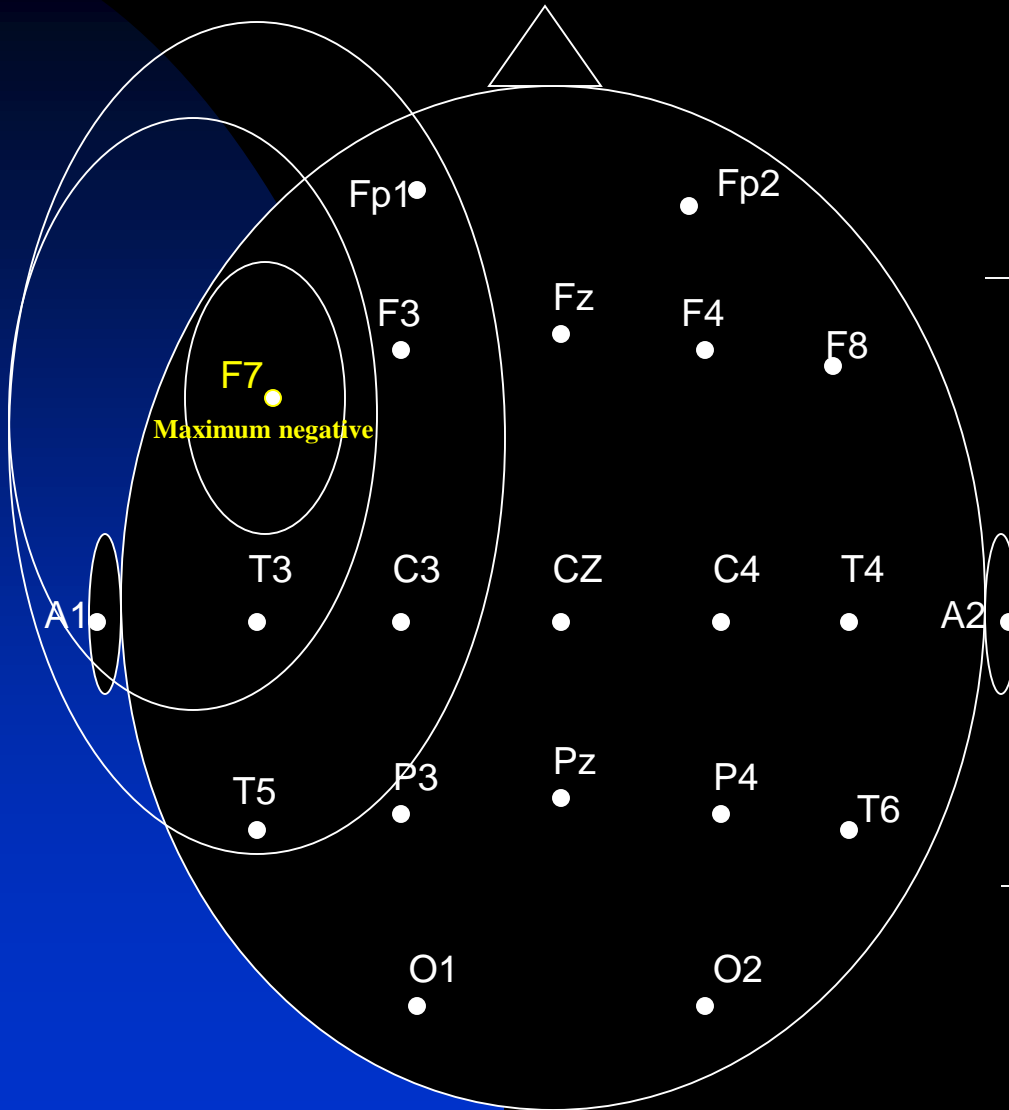
F-H: 



See the next image for explanation

- In the anteroposterior plane, **G** is the point of maximum negativity. The line labeled **X** indicates the axis showing the plane of maximum negativity. The source of the negativity could be located anywhere on this plane.
- In the transverse plane, **E** is point of maximum negativity: The line labeled **Y** indicates the axis showing the plane of maximum negativity. The source of the negativity could be located anywhere on this plane.
- The point where planes **Y** and **X** intersect is the location of maximum negativity: **N**
- Therefore, assuming a radial field distribution, one can localize a field source even when an electrode is not placed on that source.

# EEG Localization



FP1- F7

V

Temporal

F7-T3

^

A-P

T3-T5

^

T5-O1

^

A1-T3

—

T3-C3

^

Temporal-

Central

C3-Cz

^

Transverse

Cz-C4

—

FP1-F3

—

Frontal-

F3-C3

—

Parietal

C3-P3

^

A-P

F7-F3

^

F3-Fz

^

Frontal

Transverse

Fz-F4

—

# **Chapter 2**

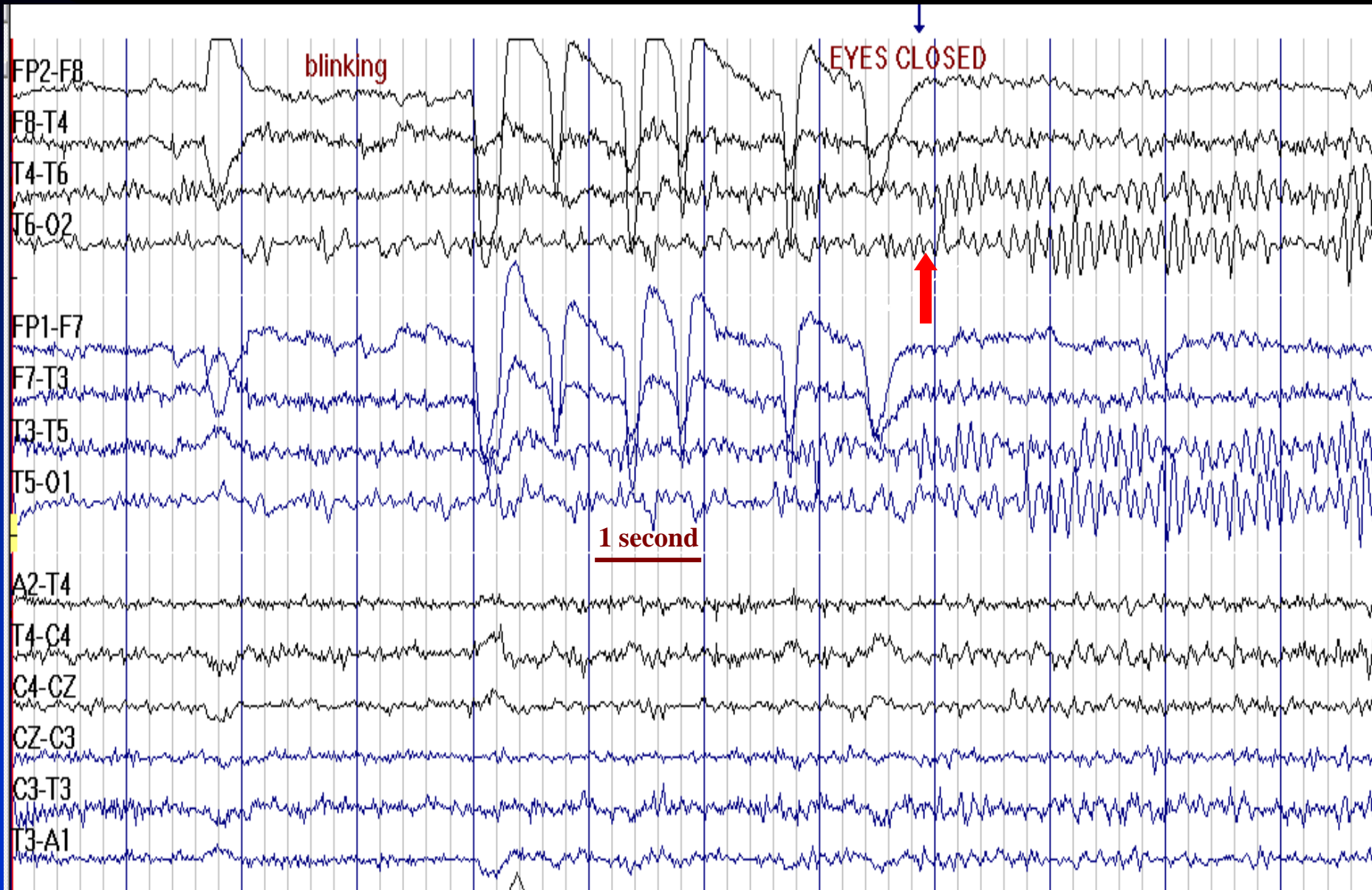
## **Background Rhythms in EEG**

- **Alpha Frequency**
- **Beta Activity**
- **Theta Activity**
- **Delta Activity**

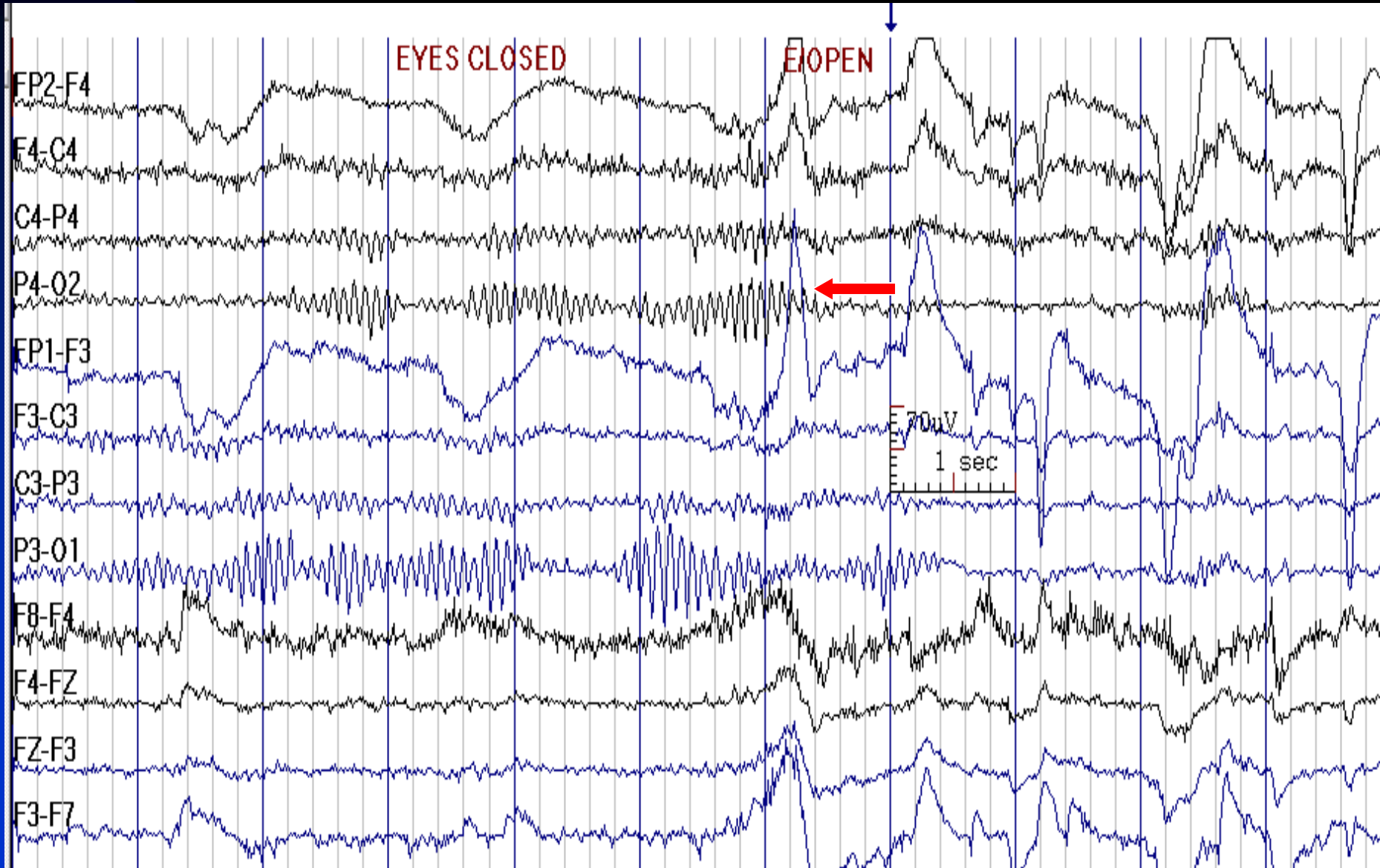
# Normal Alpha Rhythm (Posterior Dominant Rhythm)

- **Frequency:** 8.5 - 12 Hz in older children and adults ( 4 Hz at 4 months, 6 Hz at 12 months, 8 Hz at 3 years of age)
- **State:** relaxed wakefulness (eyes closed)
- **Distribution:** posterior scalp regions, often spread to parietal, temporal or central regions
- **Characteristics:** sinusoidal, waxes and wanes, spiky variant
- **Amplitude:** 15 - 45  $\mu$ V, higher amplitudes in children; should be measured in reference montage
- **Reactivity (Blocking):** eye opening, alerting stimuli, and drowsiness attenuate the alpha rhythm
- **Prevalence:** present in 90% of normal individuals. Absence is not a definite abnormality if every thing else is normal

# Normal Alpha Rhythm

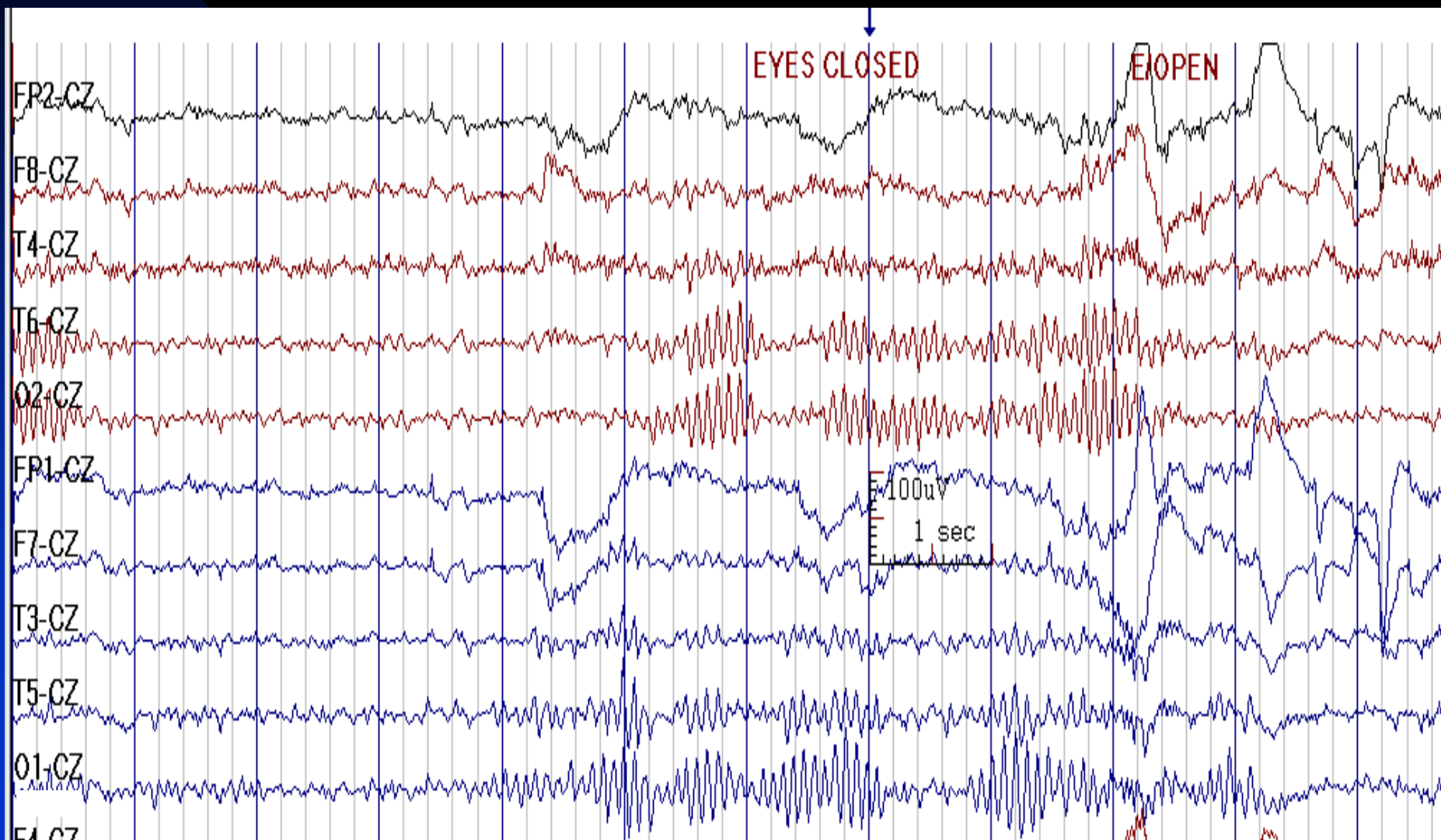


# Alpha Reactivity to Eye Opening

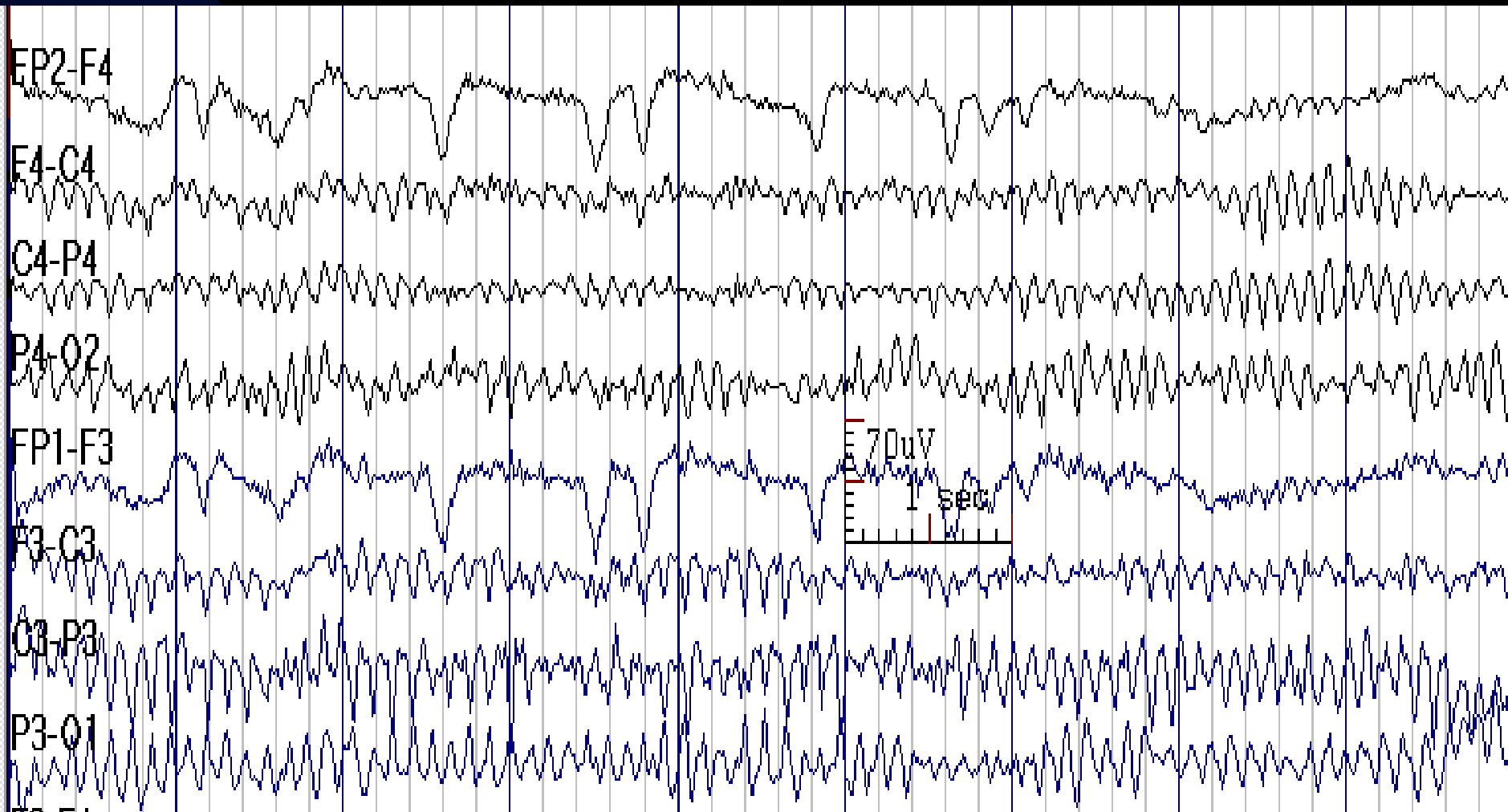




# Alpha Rhythm Field of Distribution

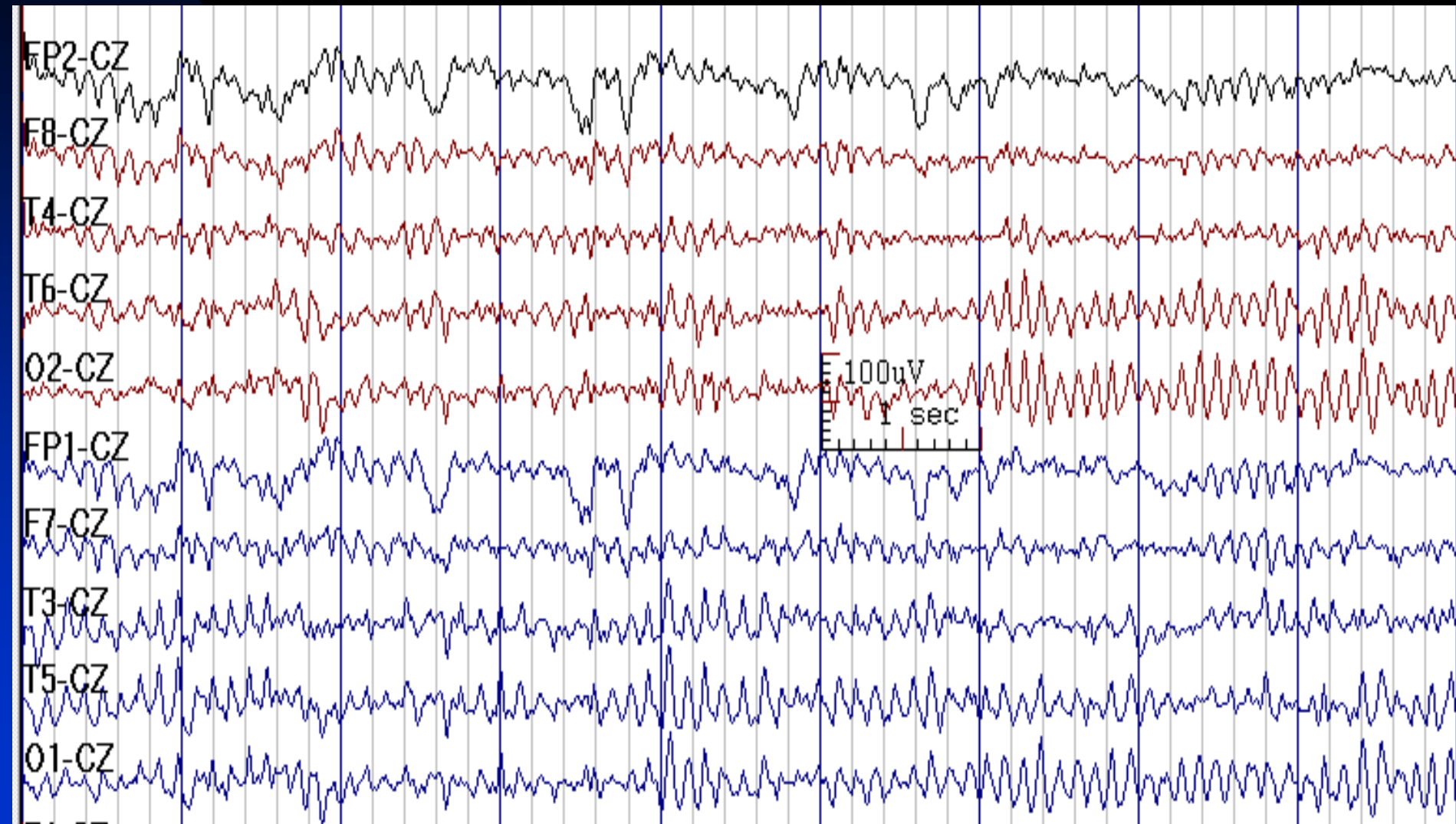


# Alpha Amplitude Asymmetry (Left Higher than Right) in Bipolar Montage



See the next image for the same finding in reference montage

# Alpha Amplitude is not Abnormally Asymmetric in Reference Montage (Previous Image)

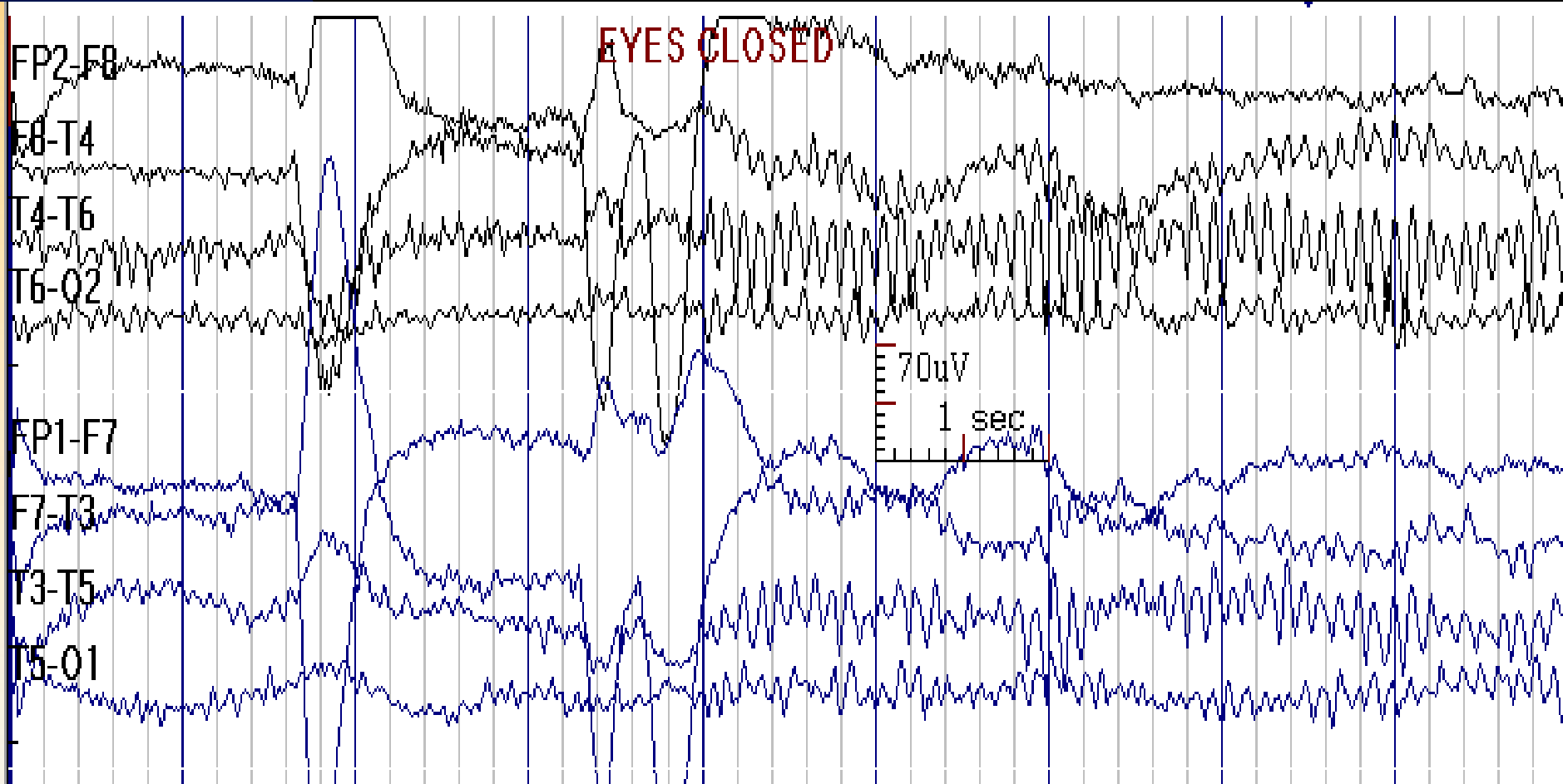


See the previous image for the same finding in bipolar montage

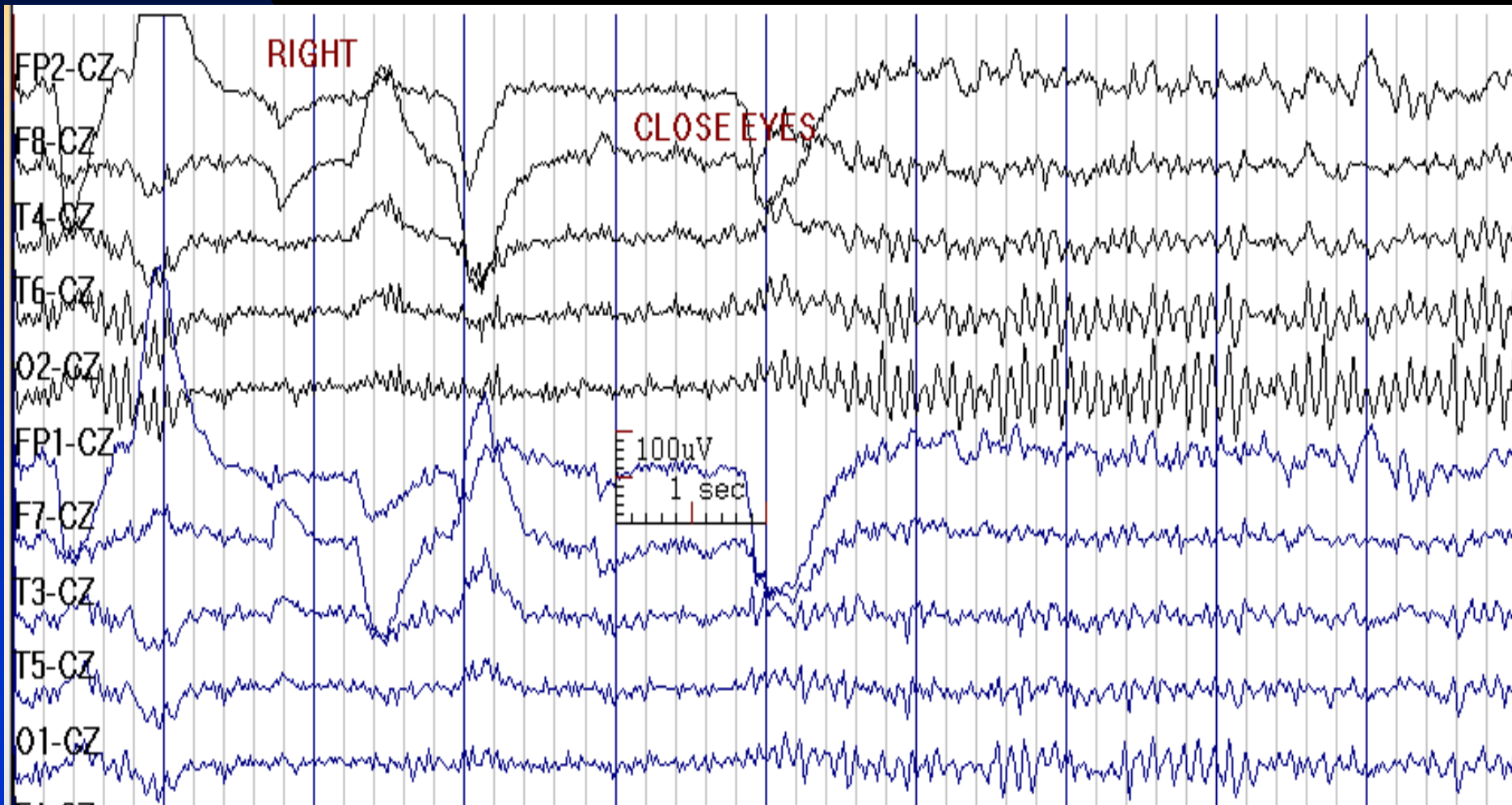
# Alpha Rhythm

- Since Cz is usually out of the alpha rhythm field, a Cz reference is often good for evaluating its amplitude and distribution; if the alpha rhythm spreads to Cz, an Fz reference may be used
- If in a bipolar montage, the alpha rhythm is asymmetric, it could result from greater in-phase cancellation on one side. This should be verified with a reference montage

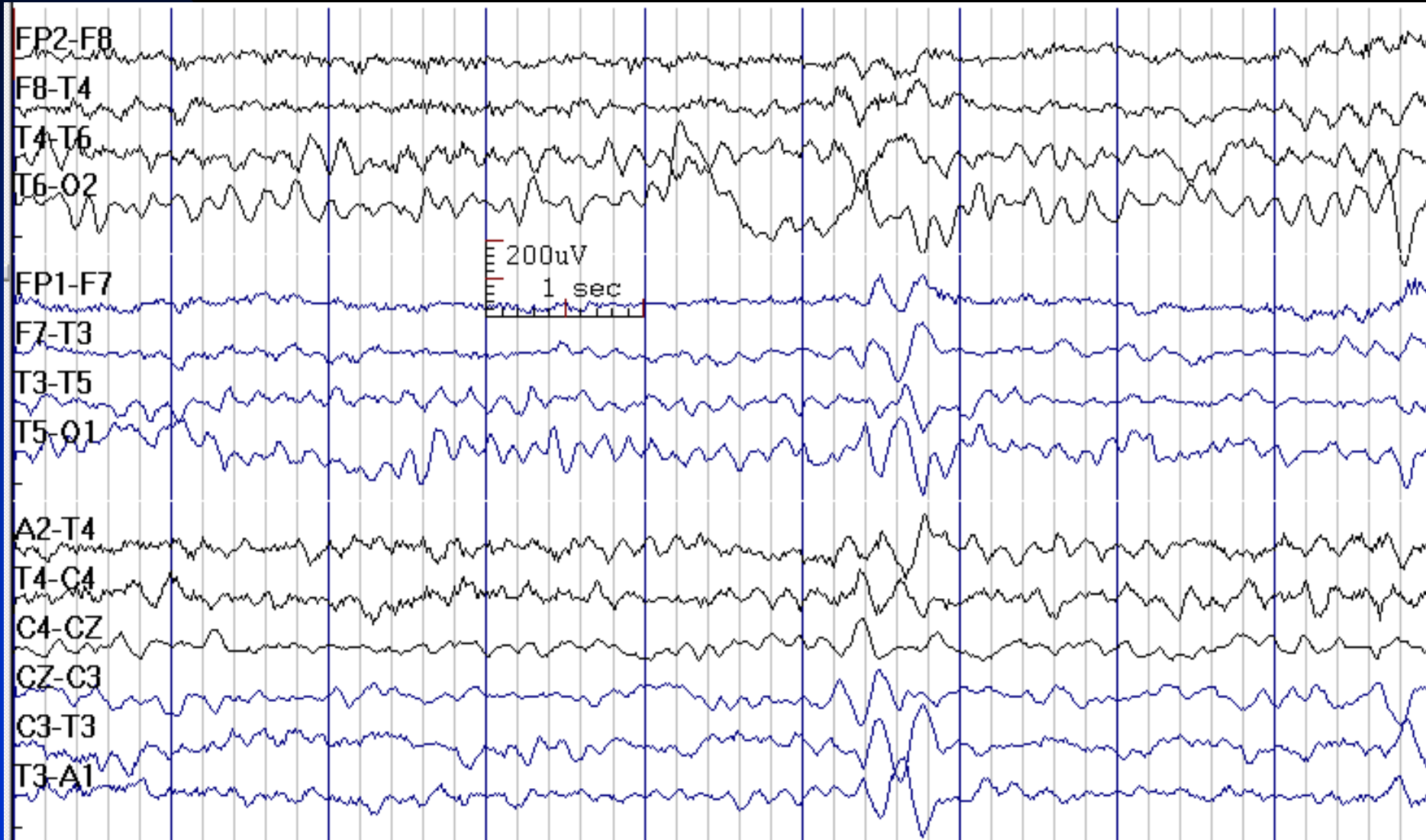
# Spiky Variant of Alpha Rhythm (Normal)



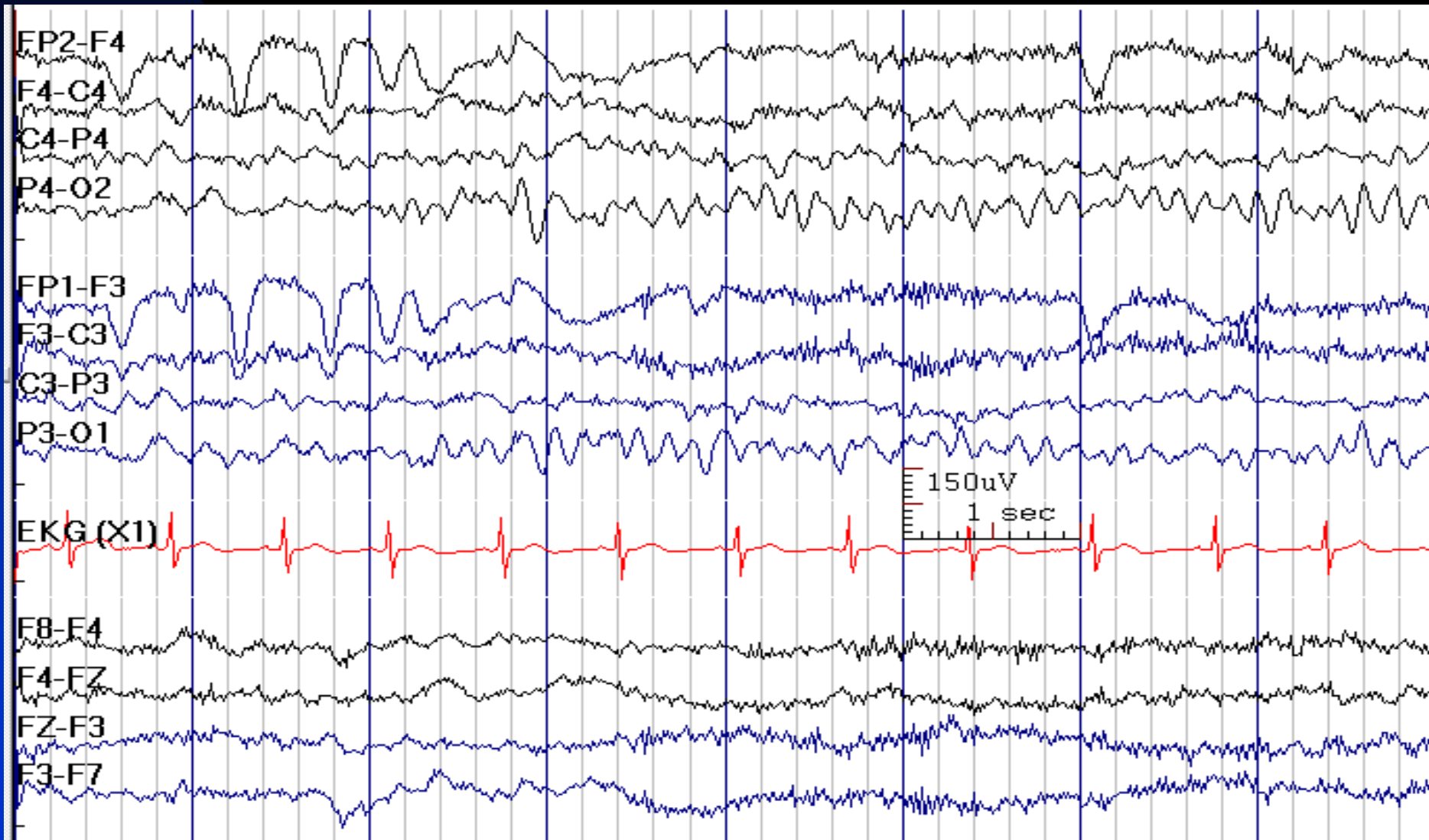
# Spiky Variant of Alpha Rhythm



# 7 Hz Normal Posterior Dominant Rhythm in a 2-Year-Old Boy



# 7 Hz Normal Posterior Dominant Rhythm in a 15-Month-Old Girl

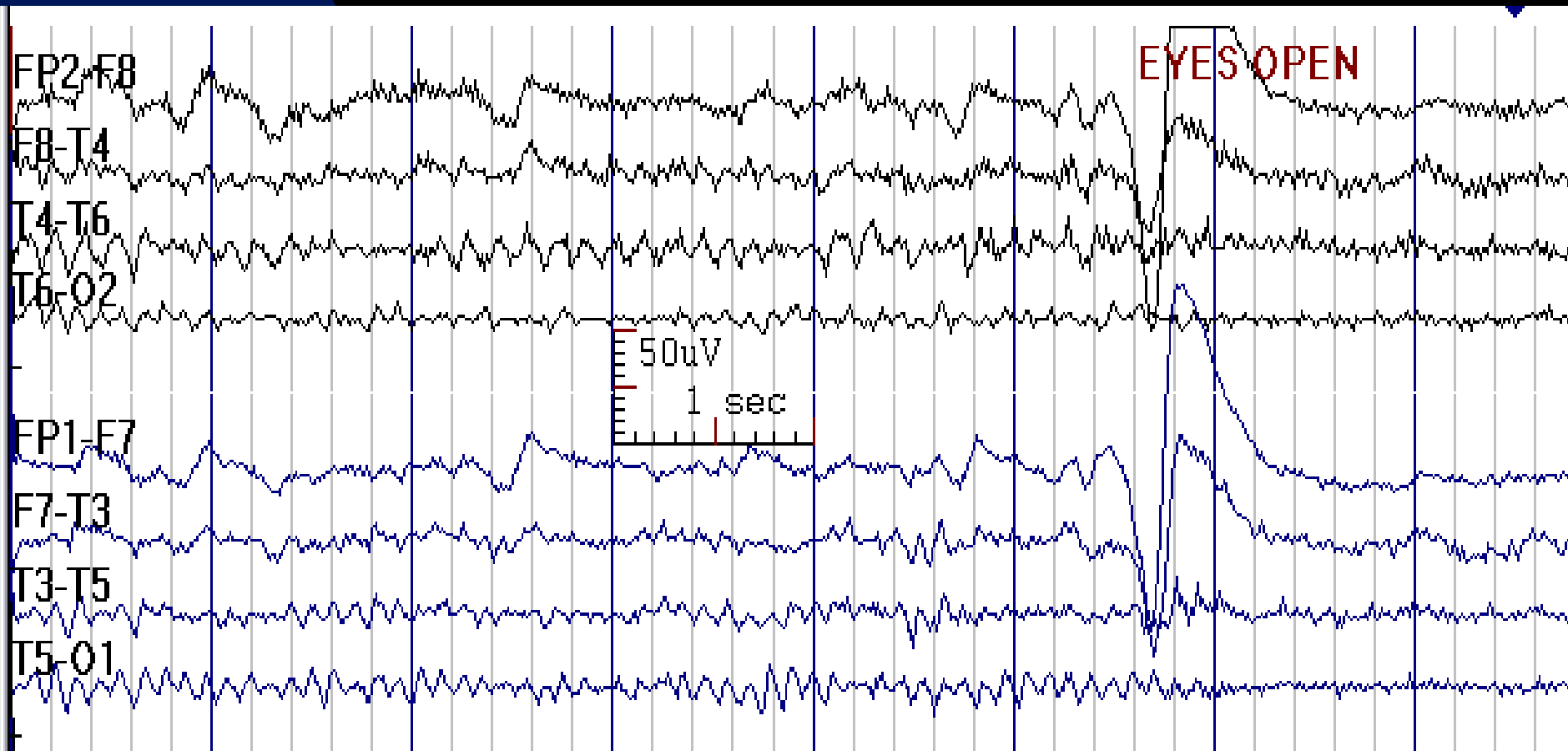




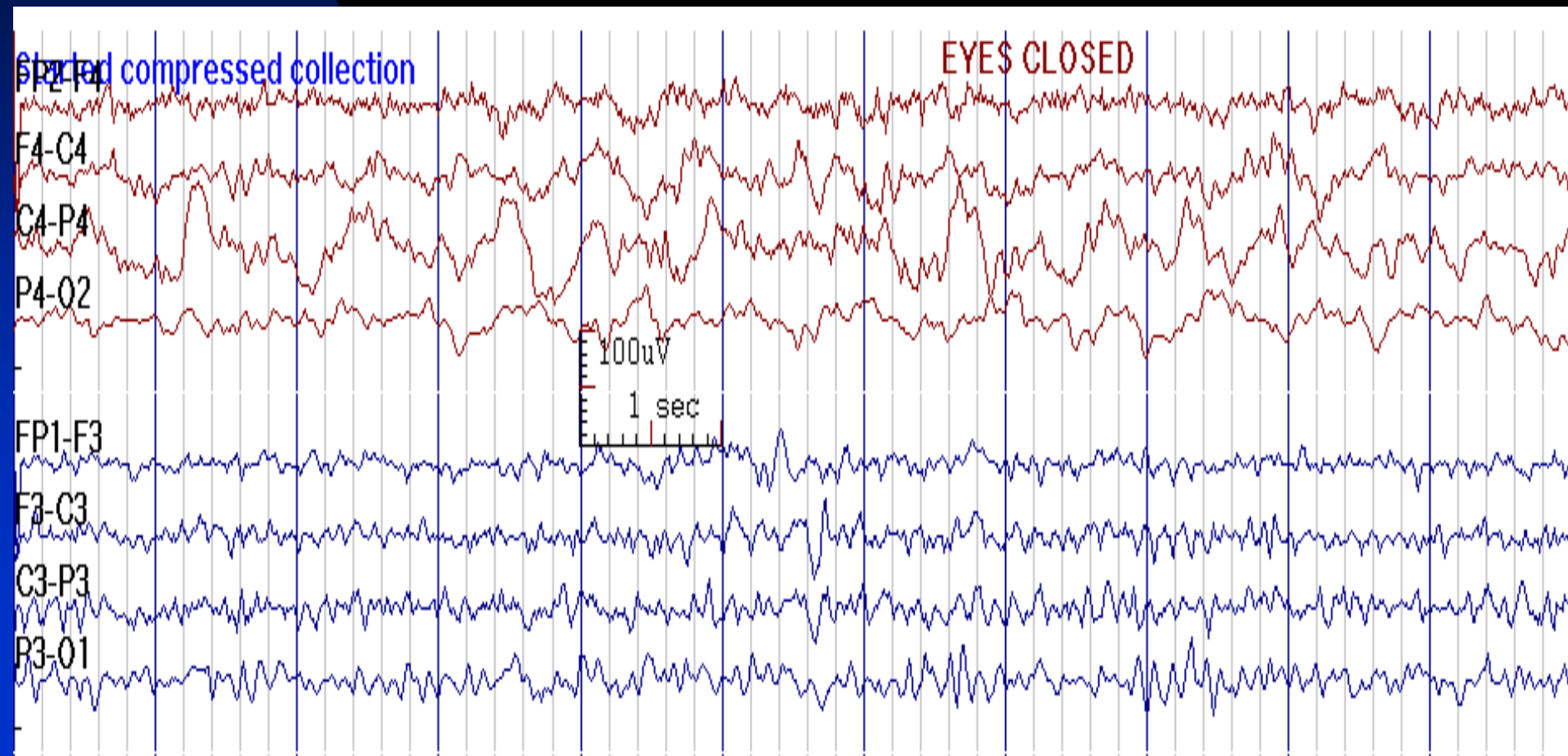
# Abnormal Alpha Rhythm

- **Frequency:**  $< 8.5$  Hz above 6 years of age
- **Interhemispheric amplitude asymmetry:** right  $>50\%$  more than left or left  $>35\%$  more than right (if there is no associated frequency asymmetry, this finding is of uncertain significance)
- **Reactivity:** unilateral failure of attenuation of alpha rhythm with eye opening or alerting stimuli (Bancaud's phenomenon), indicates ipsilateral occipital lesion

Alpha Rhythm is 9.5 Hz on Left Side  
but 8 Hz on the Right Side in  
a 43-Year-Old Man with a Right Occipital CVA



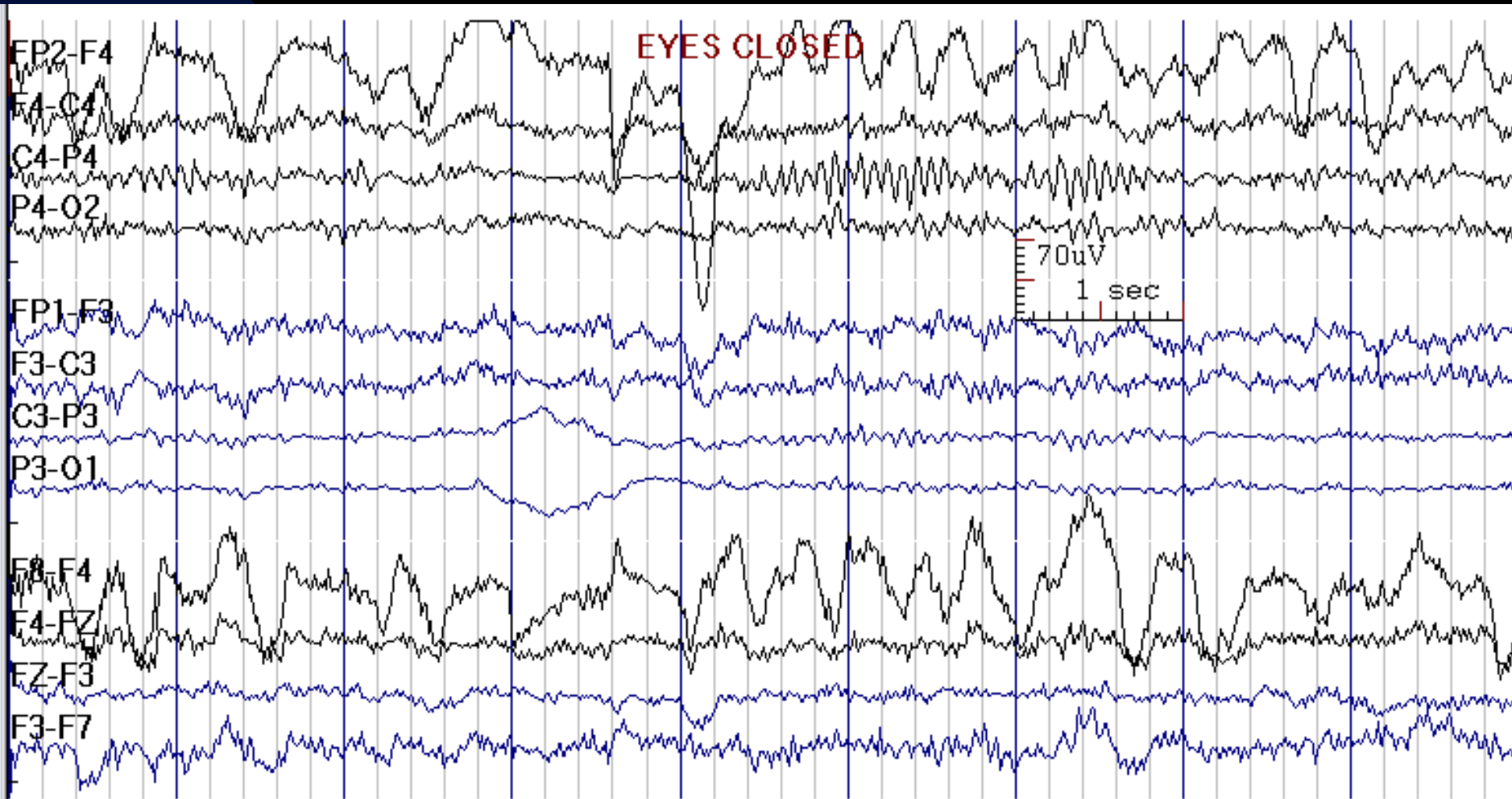
# Alpha Rhythm is Absent on the Right Side in a 73-Year-Old Woman with Right Hemorrhagic CVA; Note Continuous Delta Waves in the Right Parieto-Occipital Regions



# Asymmetric Alpha Rhythm

(Lower Amplitude on the Left)

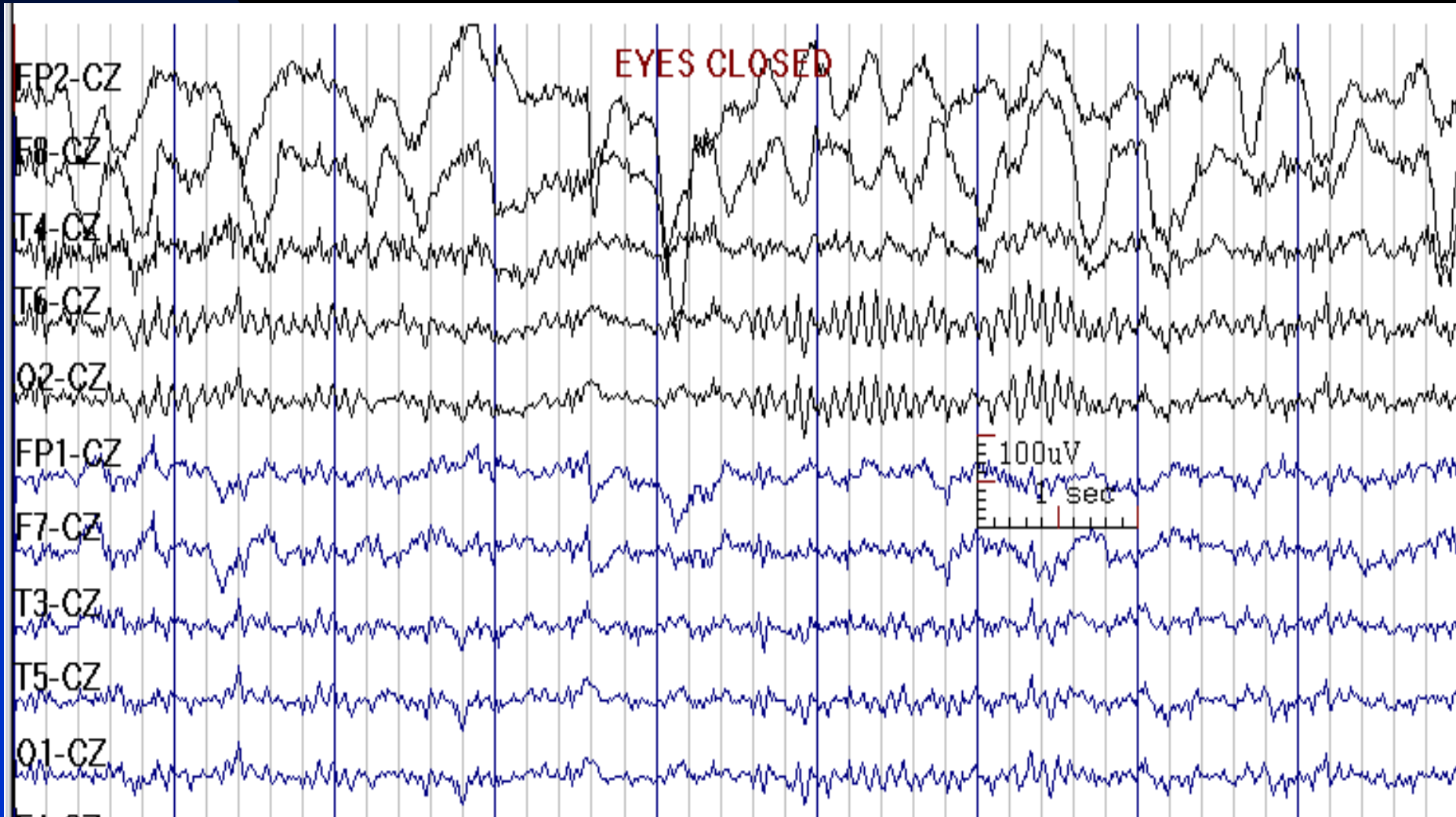
19-Year-Old Woman with Left Hemisphere Traumatic Brain Injury



See the next image for the same finding in reference montage

# Previous Image in Cz Reference Montage

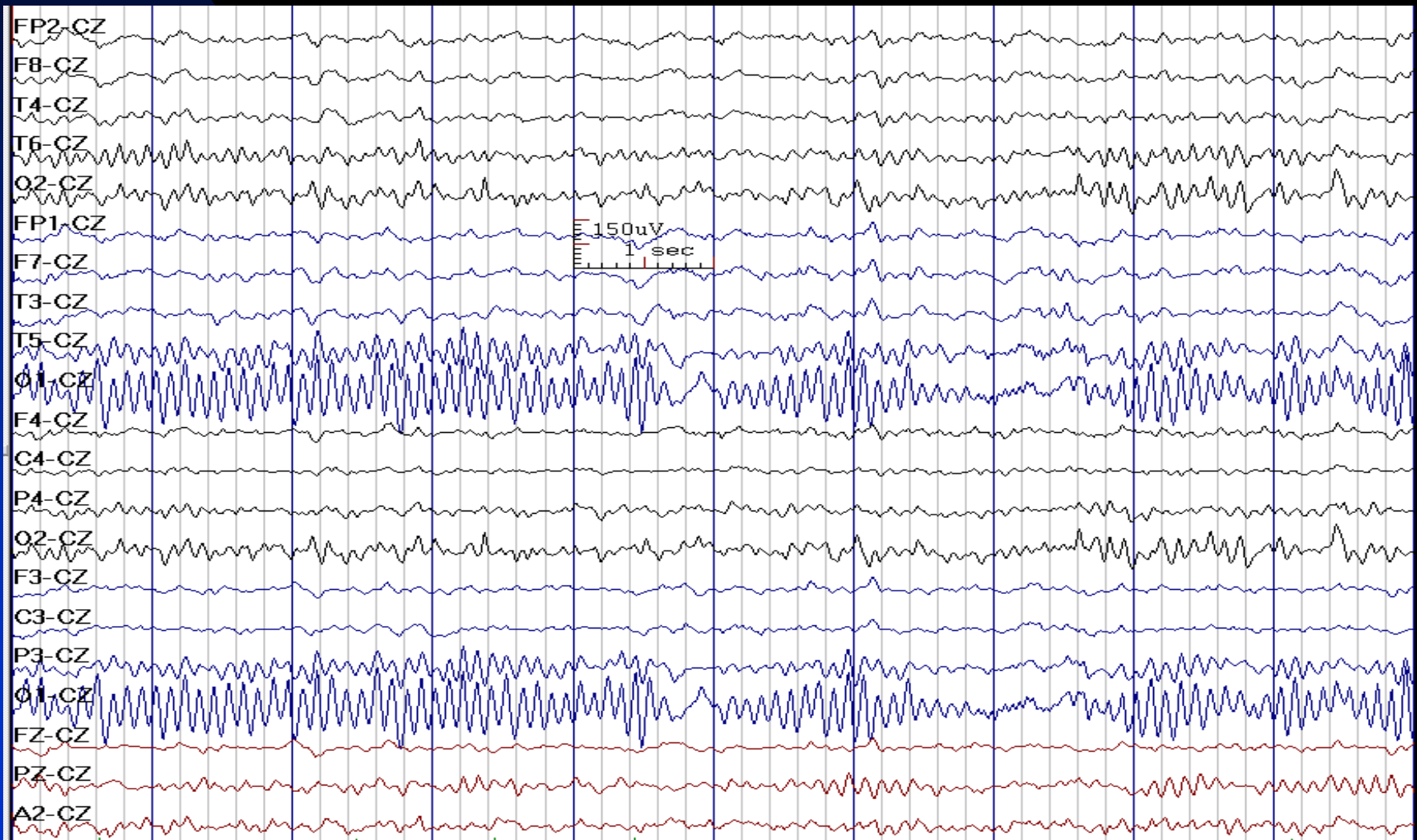
(Note Absent Eye Movement Artifacts on the Left Side Due to Left Eye Enucleation)



# Asymmetric Alpha Rhythm

(Lower Amplitude on the Right)

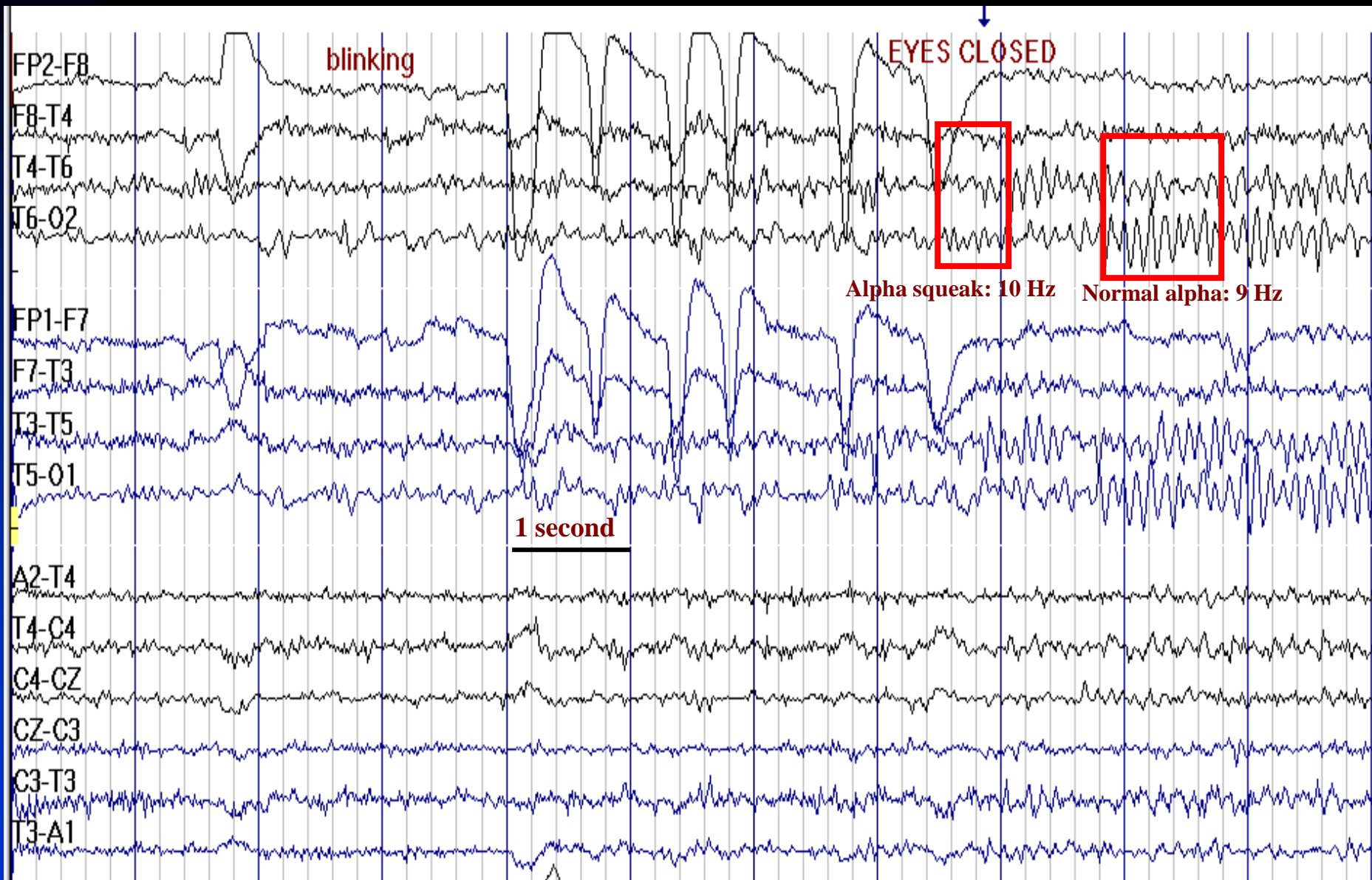
12-Year-Old Boy with Right Posterior Hemispheric Infarct



# Alpha Squeak

- Brief increase in frequency of the alpha rhythm immediately upon eye closure (for 0.5 - 1 seconds)
- Frequency is usually 1 - 2 Hz faster than alpha in the same individual

# Alpha Squeak

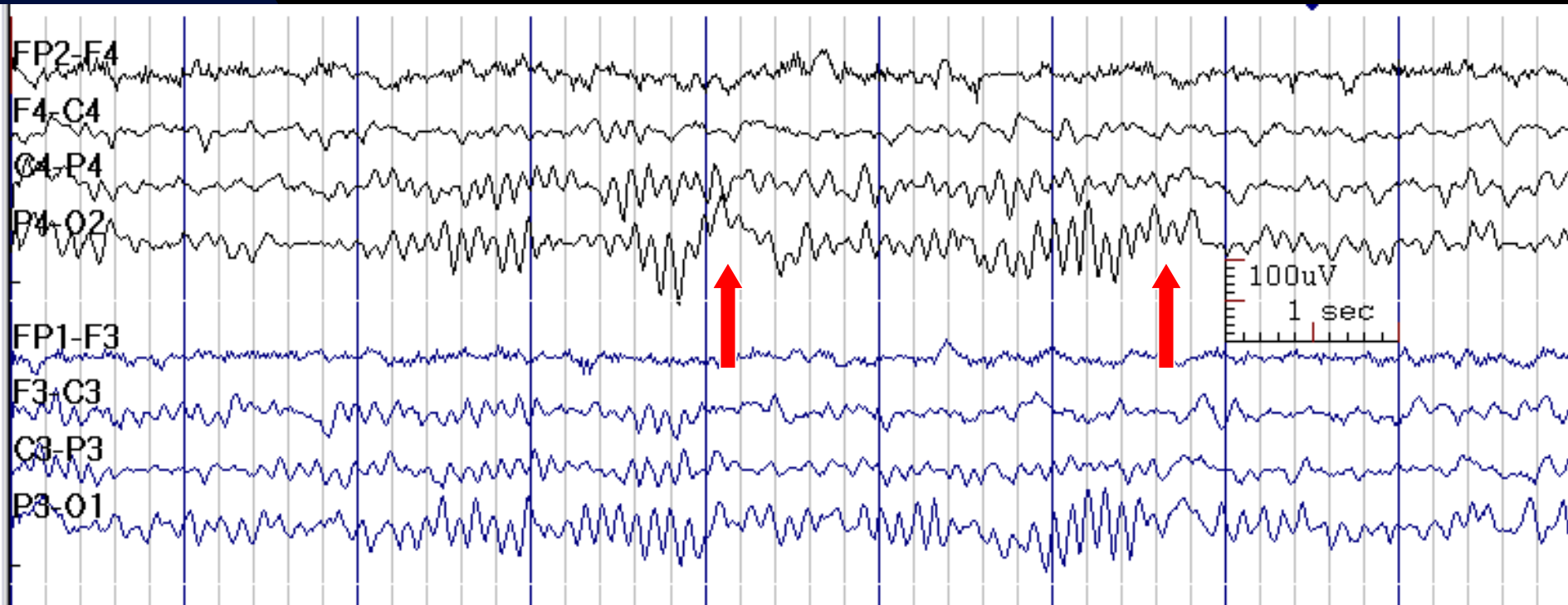




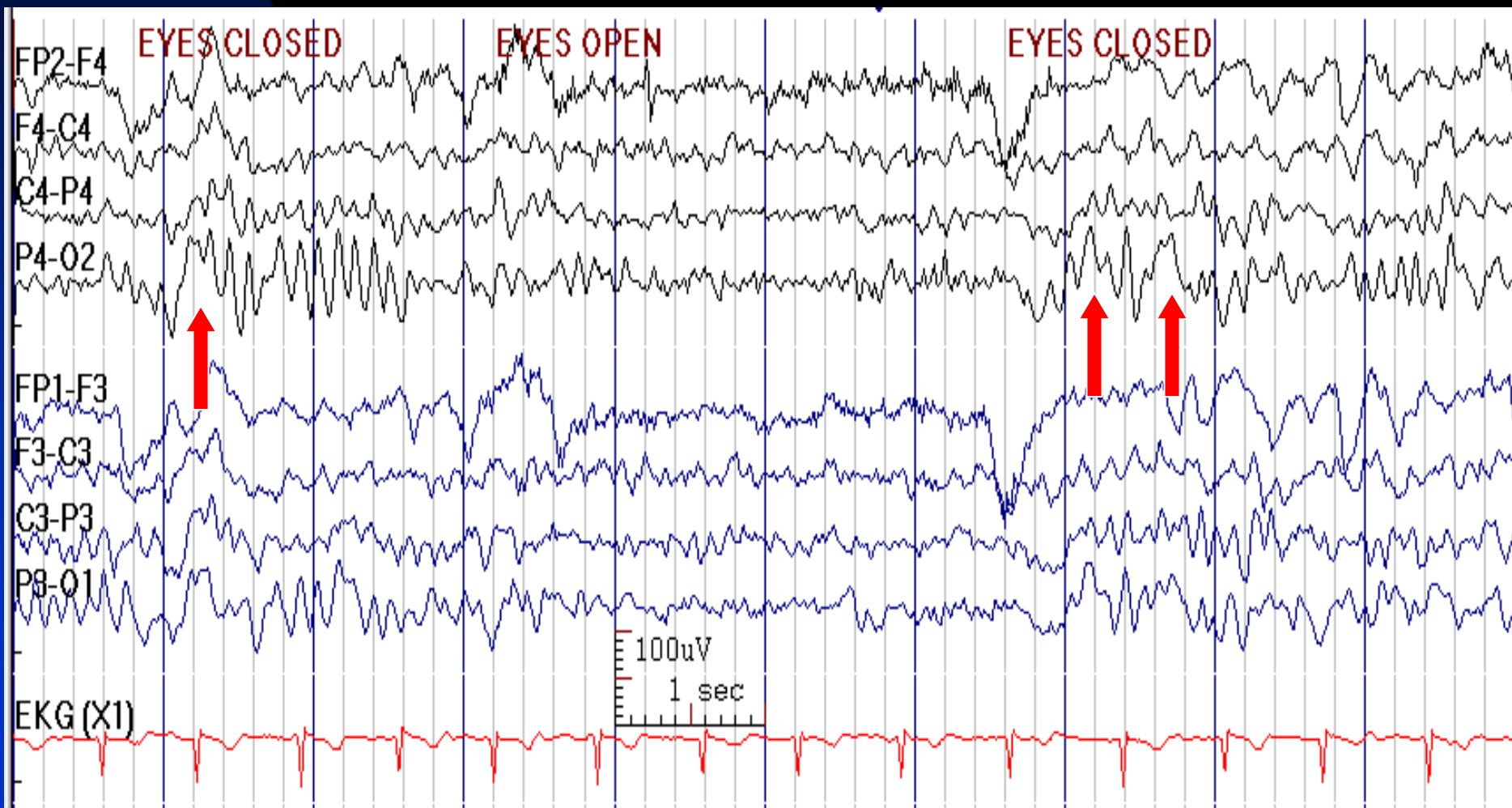# Posterior Slow Waves of Youth

- **Frequency:** delta and theta range
- **State:** relaxed wakefulness (eyes closed), accentuated by hyperventilation
- **Distribution:** posterior scalp regions, often spread to parietal, temporal, or central regions
- **Characteristics:** arrhythmical fused waves intermixed with alpha rhythm (alpha is often superimposed)
- **Amplitude:** moderate voltage (no more than 120% of the maximum alpha rhythm voltage); often asymmetrical (often maximal on the right) and asynchronous
- **Reactivity (Blocking):** eye opening, alerting stimuli, and drowsiness attenuate them (similar to the alpha rhythm)
- **Prevalence:** present in childhood, usually disappears by age 21

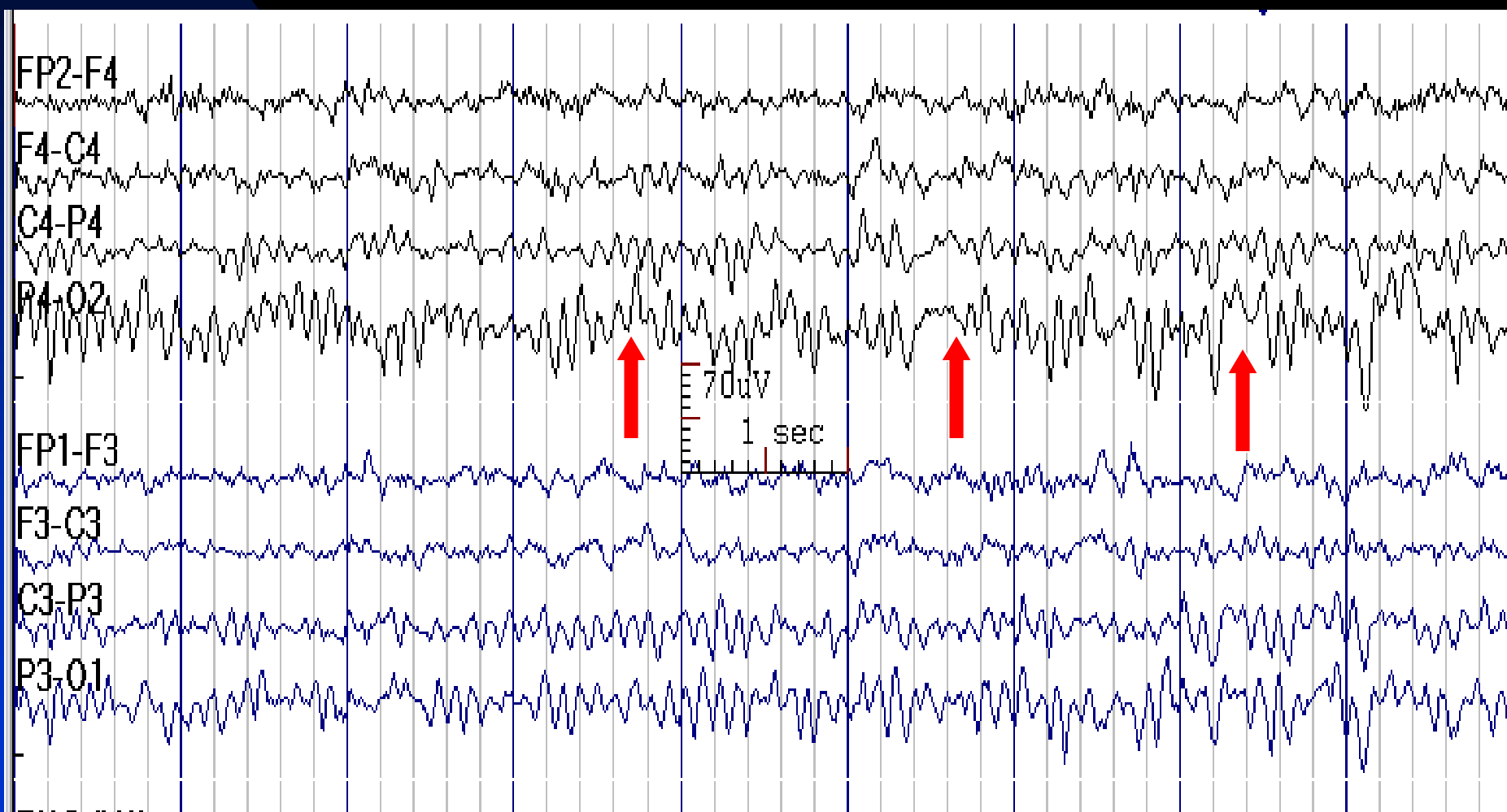
# Posterior Slow Waves of Youth



# Posterior Slow Waves of Youth: Reactivity to Eye Opening



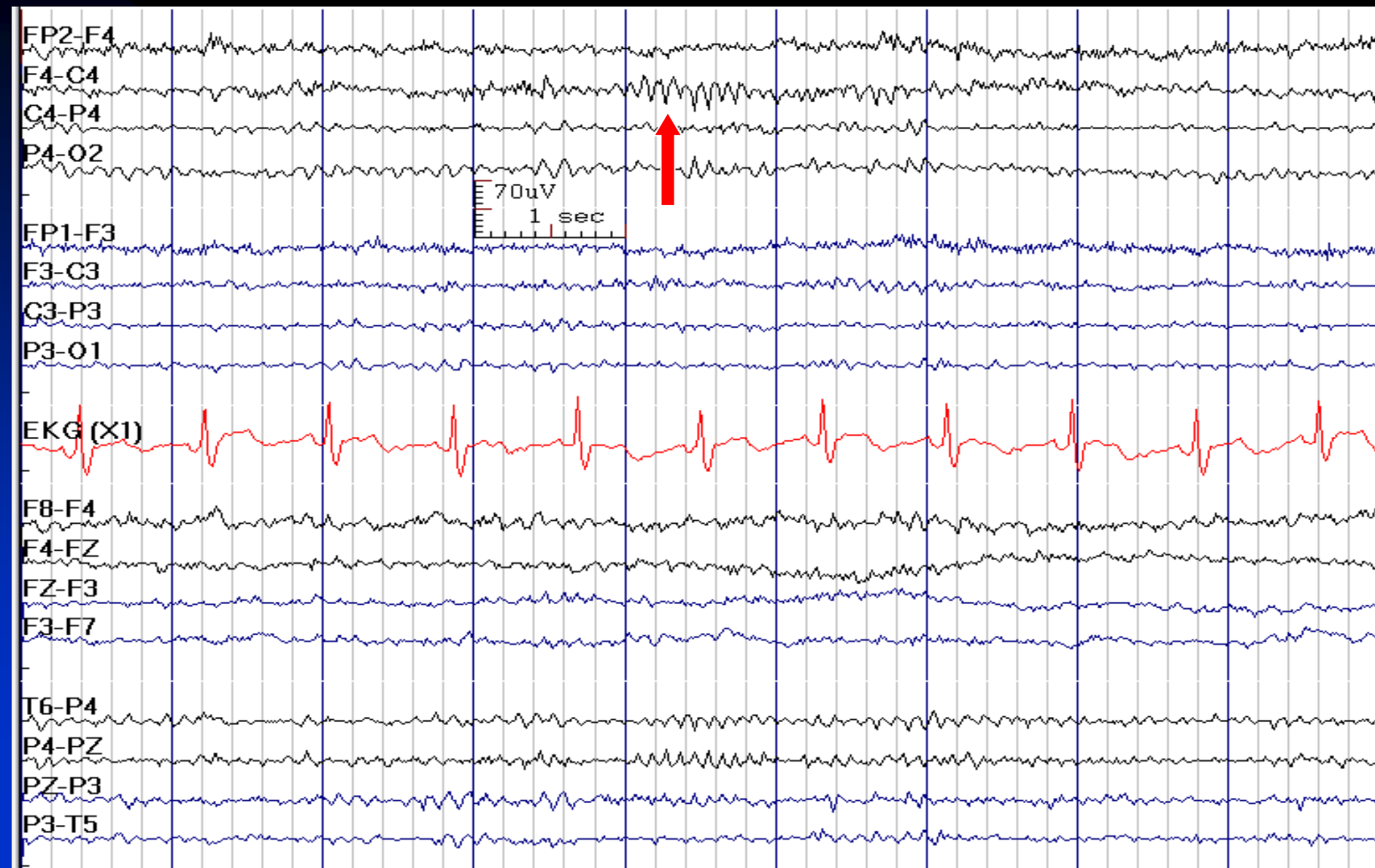
# Posterior Slow Waves of Youth Accentuated by Hyperventilation



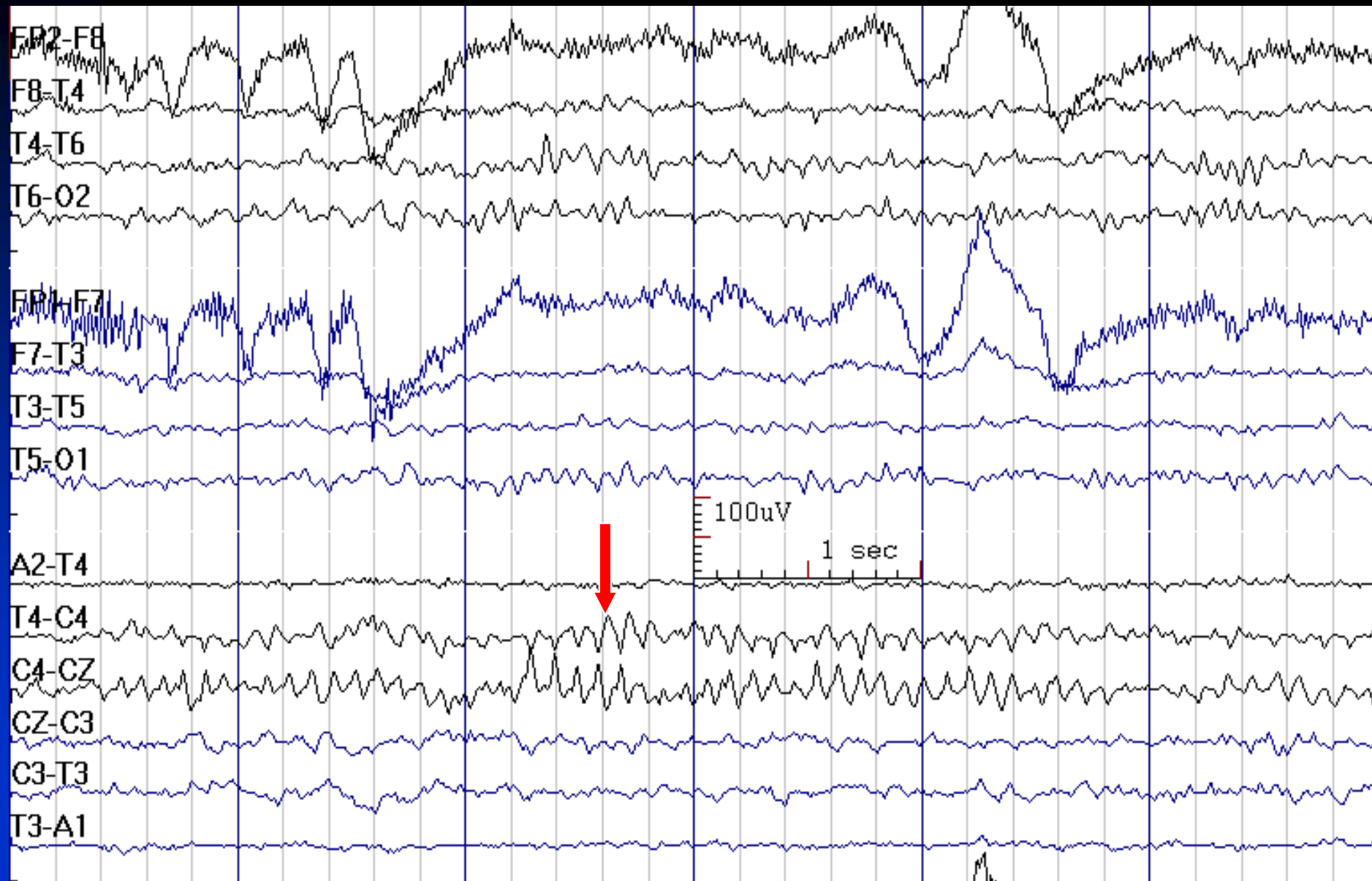
# Mu Rhythm (Precentral Alpha, Rolandic Alpha)

- **Activity:** usually 1 Hz slower than the patient's alpha activity (usually 8 - 10 Hz)
- **State:** relaxed wakefulness, enhanced by immobility and hyperventilation
- **Distribution:** central unilateral or bilateral
- **Characteristics:** arch-shaped waves
- **Amplitude:** 20-60  $\mu$ V, asymmetry between hemispheres is common
- **Reactivity:** attenuated by contralateral (and occasionally ipsilateral) limb movement, thought of movement or tactile stimulation
- It is the rhythm of the sensorimotor cortex at rest

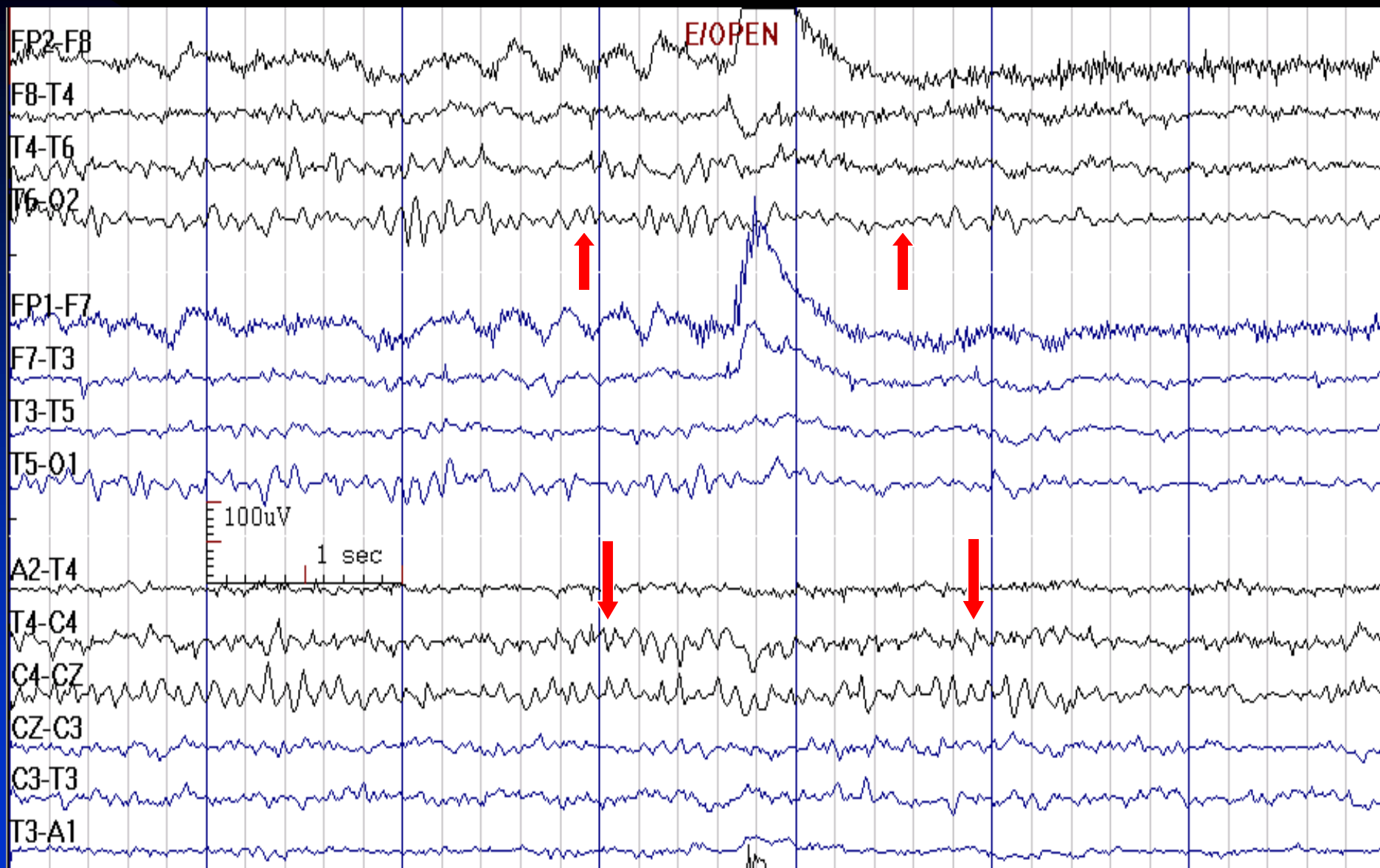
# Mu Rhythm



# Mu Rhythm is Sometimes Unilateral

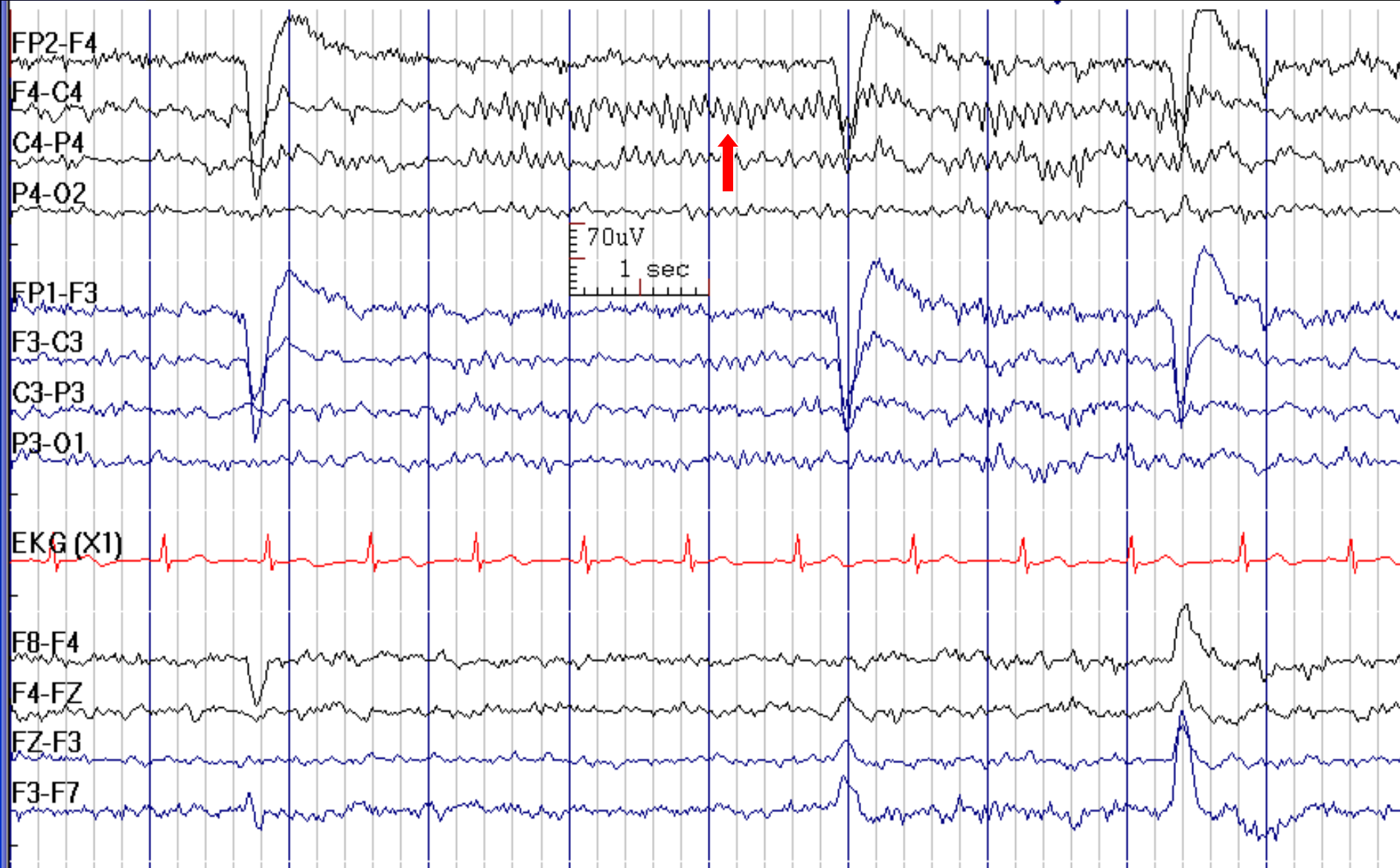


# Mu is not Reactive to Eye Opening, but Alpha is





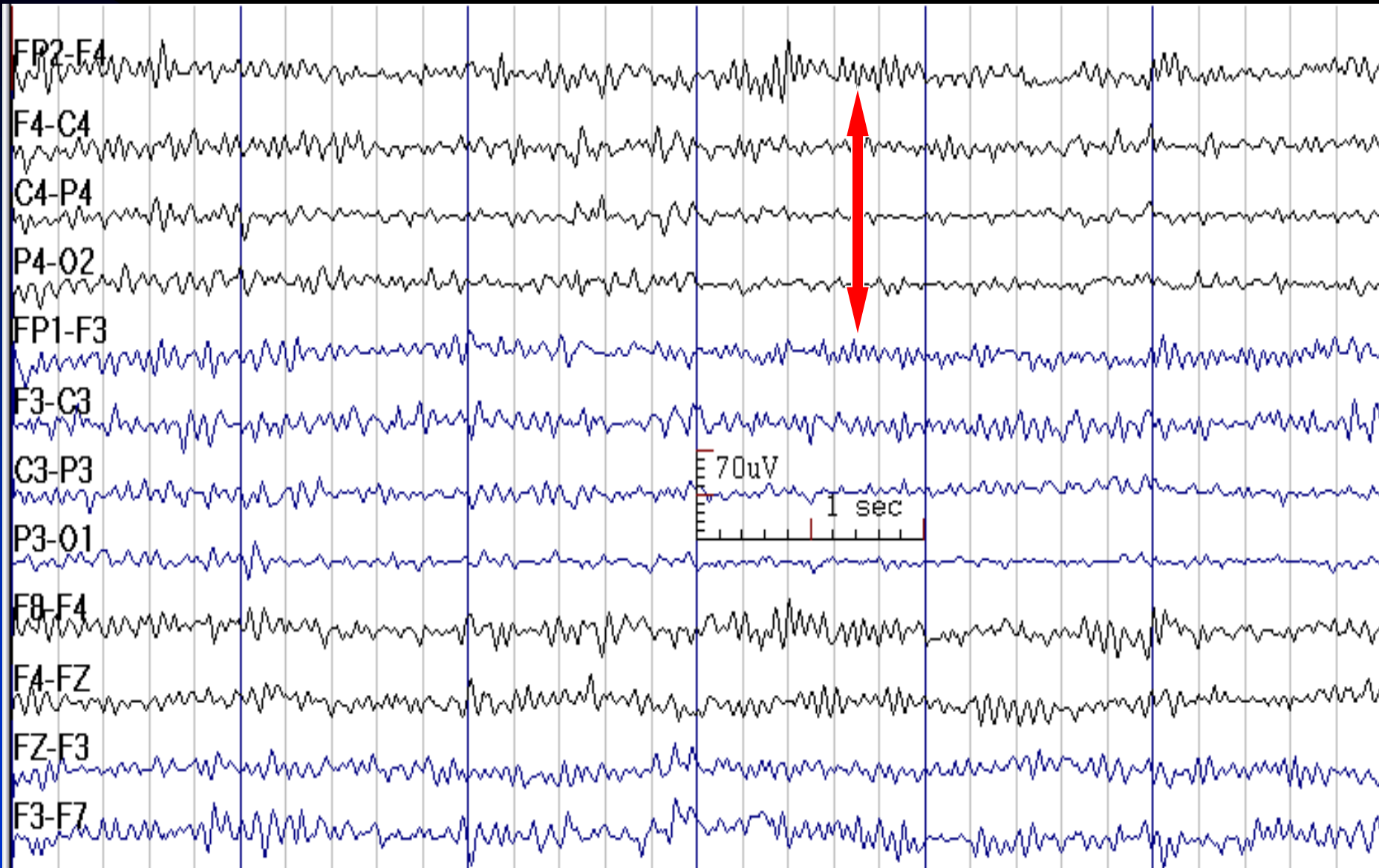
# Mu Rhythm



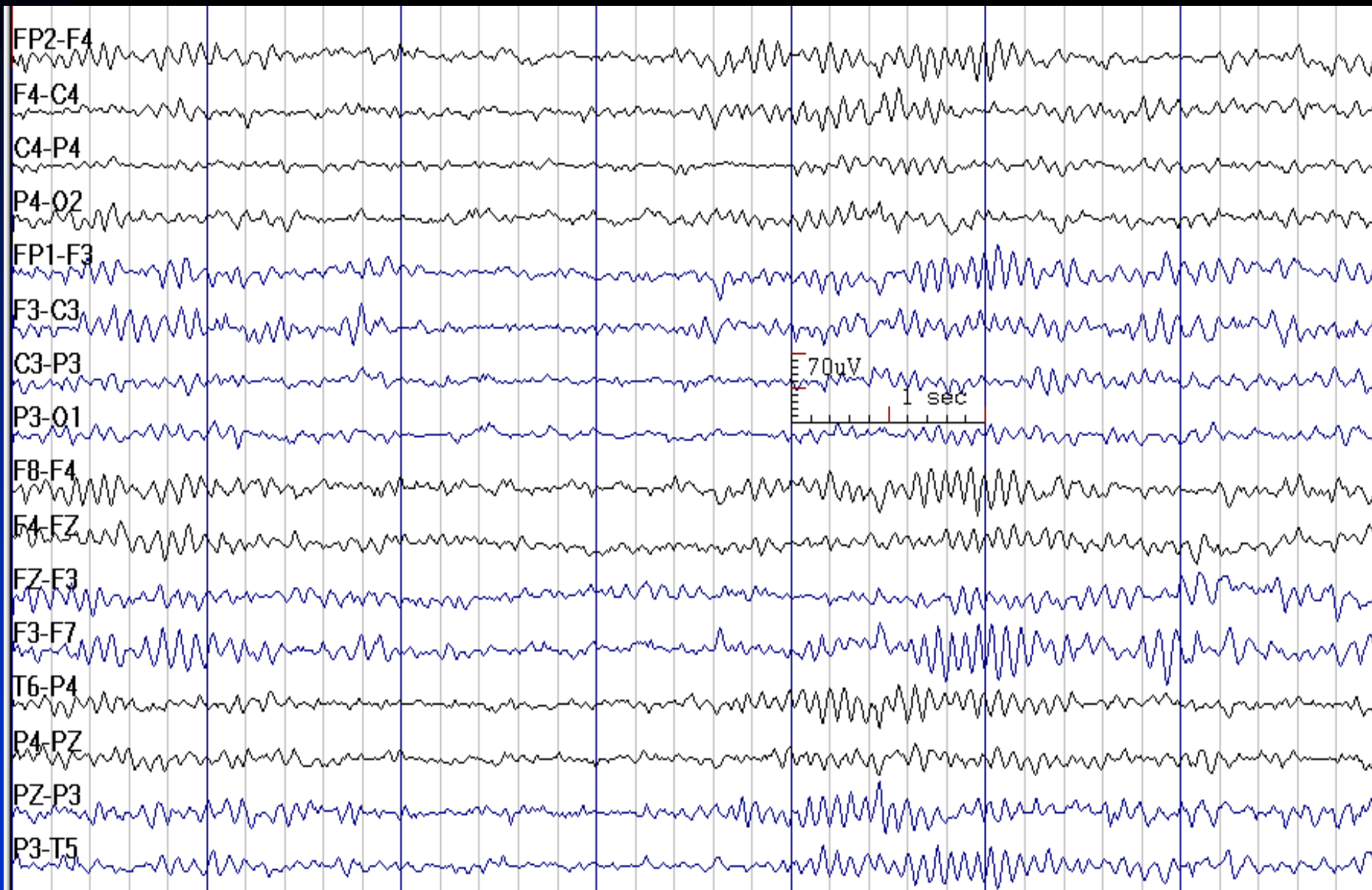
# Beta Activity

- **Frequency:** 13 - 30 Hz, commonly 18 - 25 Hz
- **State:** all states, greater amplitude in sleep stages 1, 2 and REM, may appear as central spindles (beta spindles) in early stage 1 sleep
- **Distribution:** usually fronto-central, in some individuals may be widespread
- **Characteristics:** sinusoidal
- **Amplitude:** < 20  $\mu\text{V}$  after the age of 6 years, higher in infants (up to 60  $\mu\text{V}$ )
- Increased by barbiturates, benzodiazepines, zolpidem, thyrotoxic state

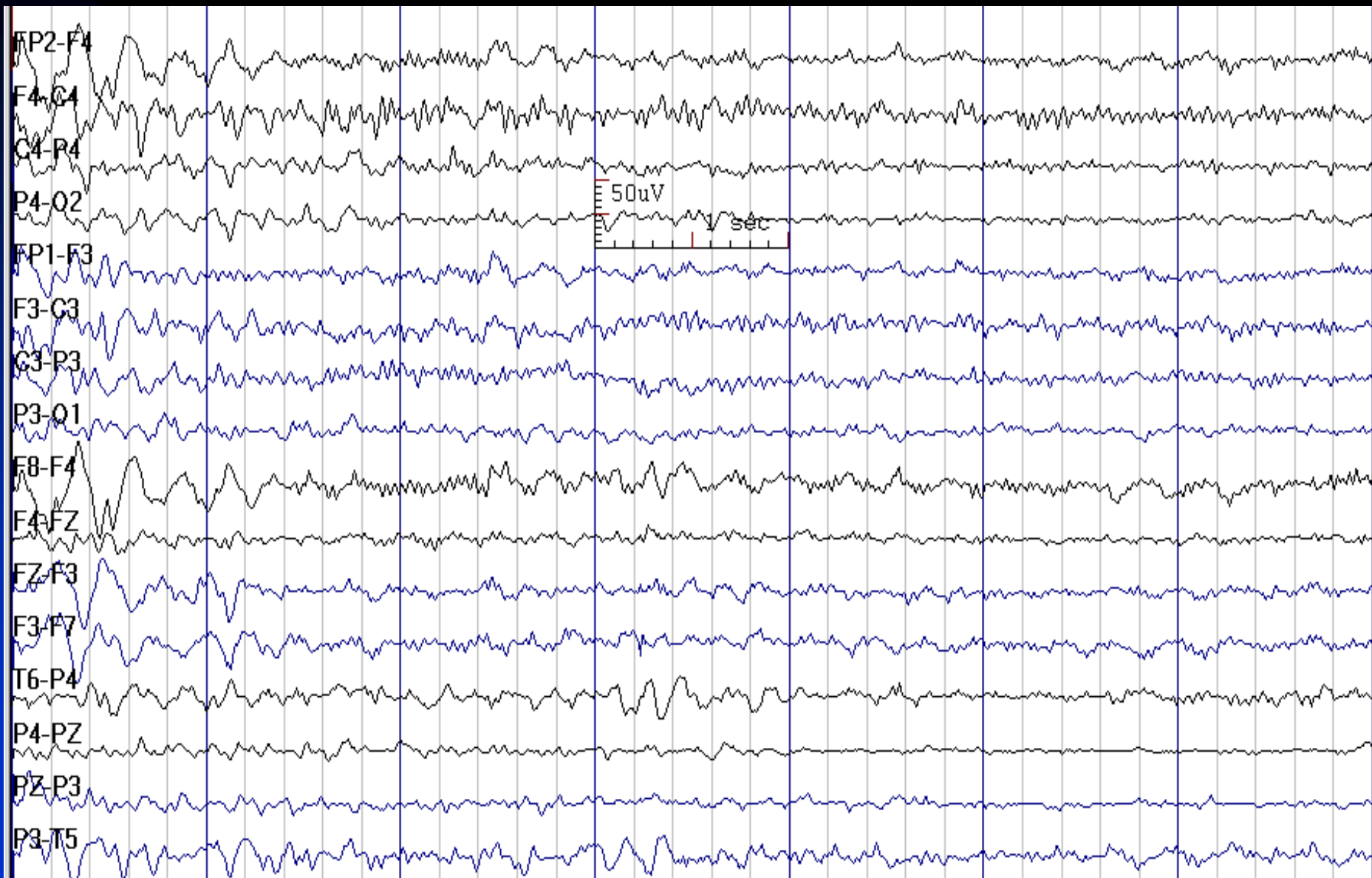
# Beta Activity



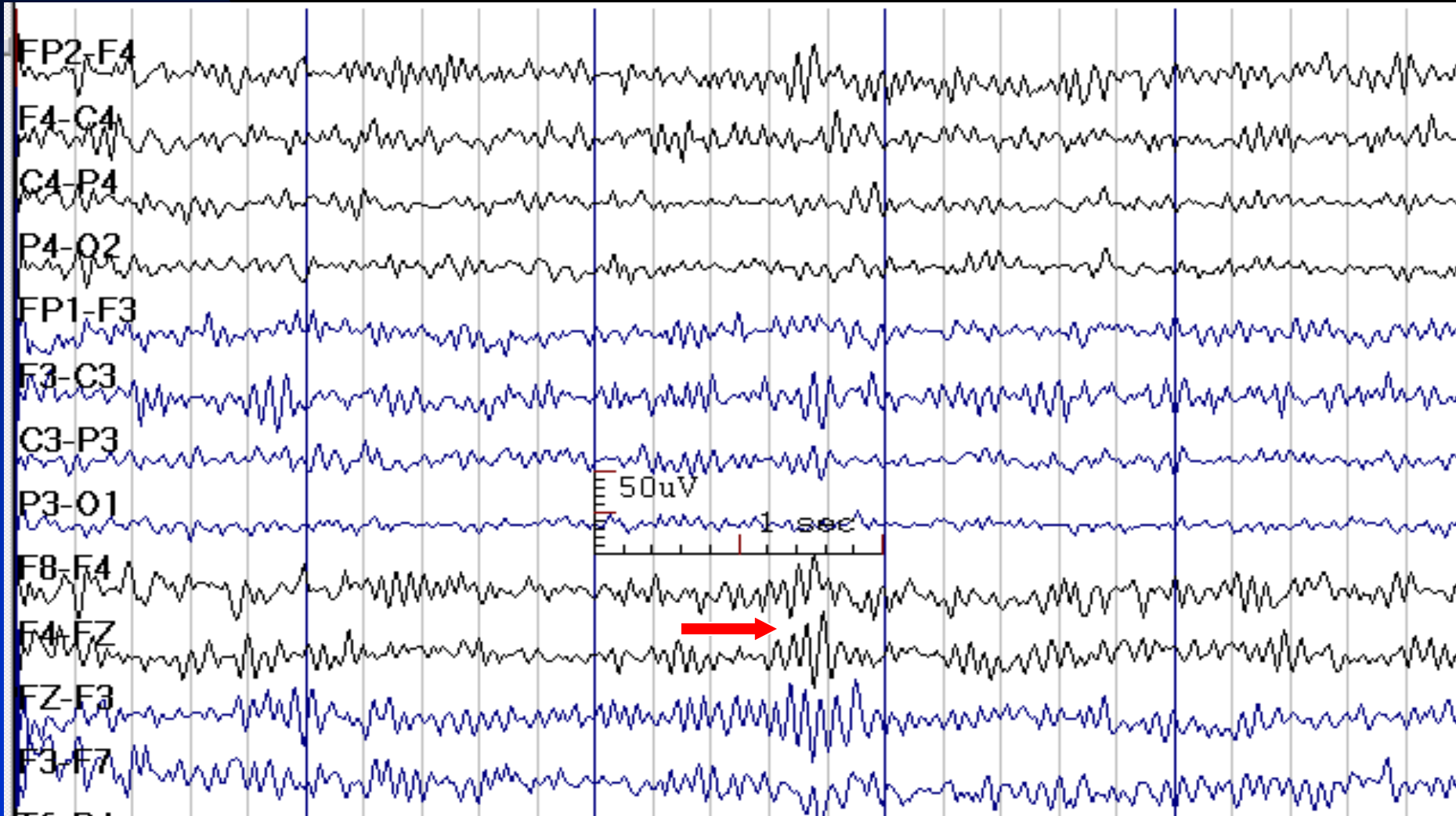
# Beta Activity in Drowsiness



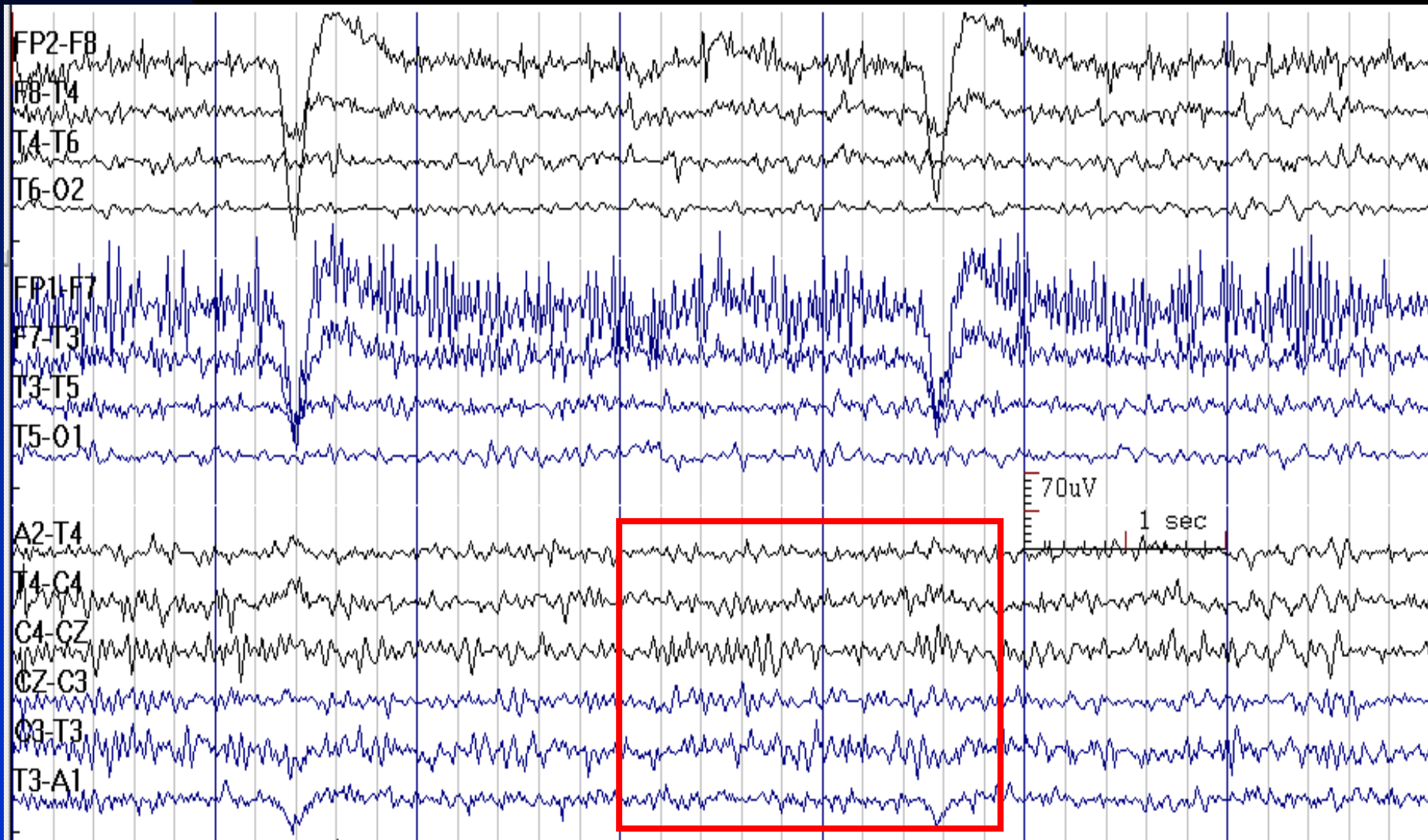
# Beta Activity in Drowsiness



# Beta Spindles in Stage 1 Sleep

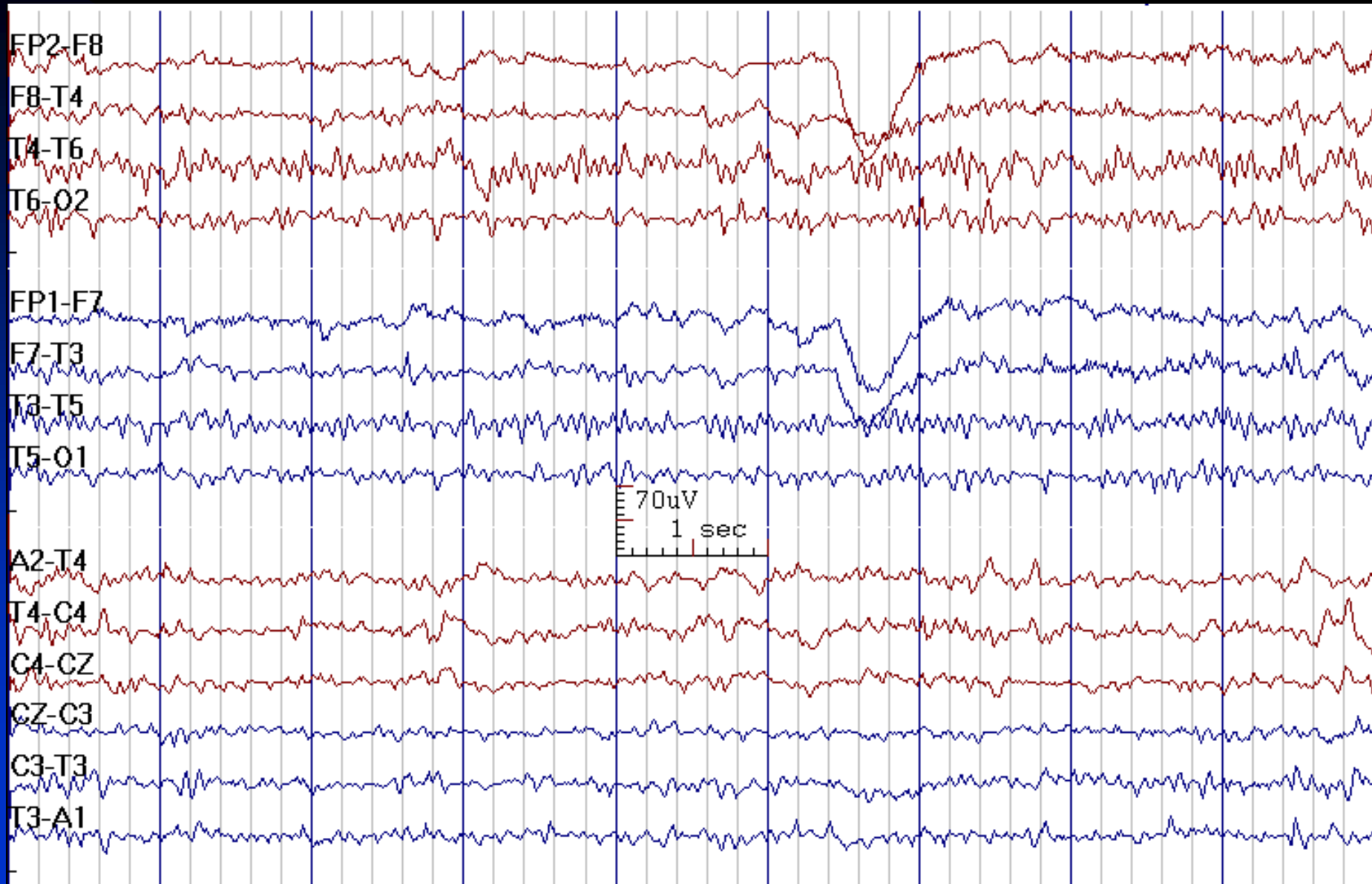


# Increased Beta Activity in a 40-year-Old Man Receiving Lorazepam





# Increased Beta Activity





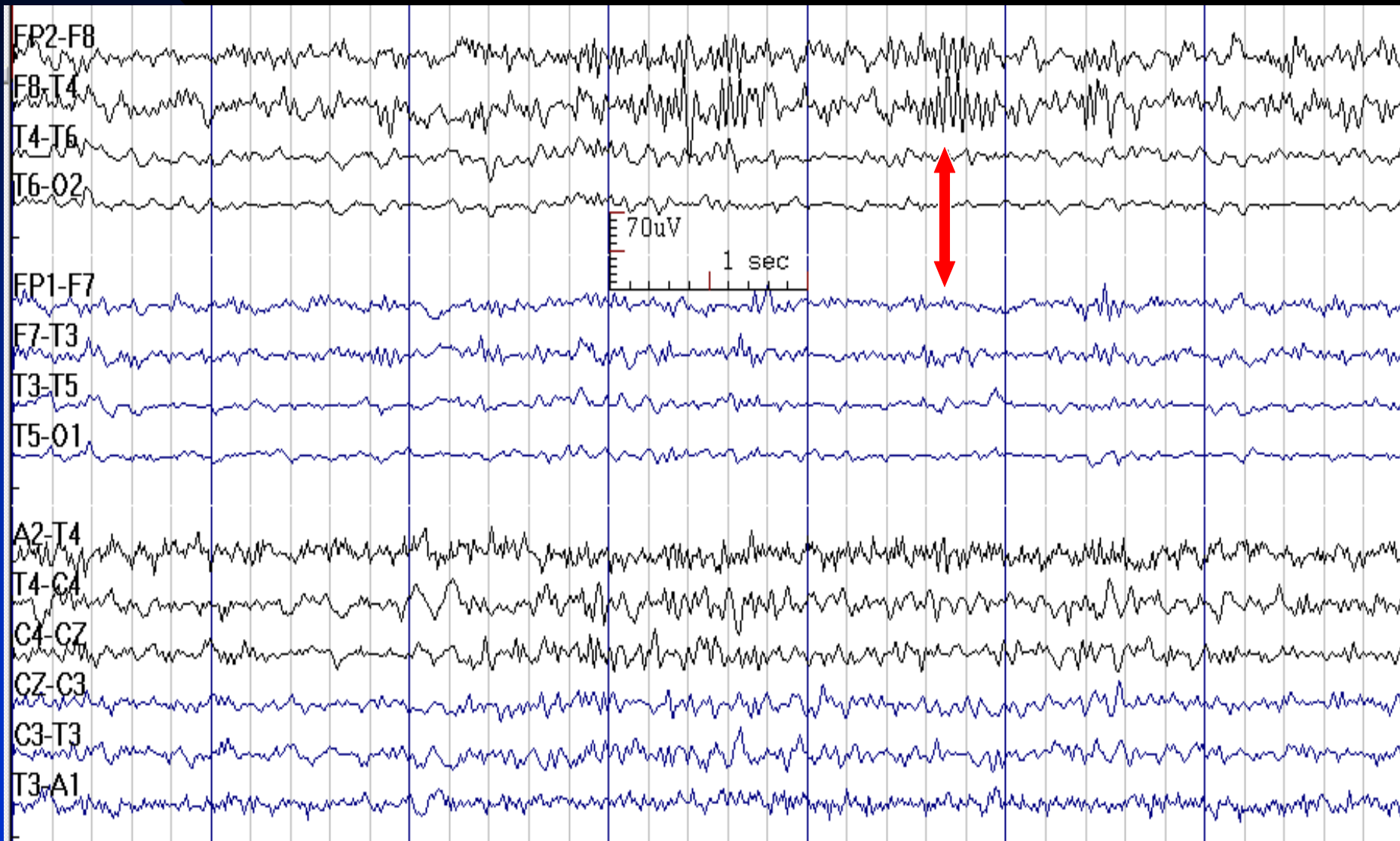
# Abnormal Beta Activity

## ■ Asymmetry:

- ◆ Decreased amplitude and amount (greater than 35%): may be due to cortical injury, fluid collection (scalp edema, subdural hematoma)
- ◆ Increased amplitude and amount: may be due to skull defect (post-operative, bone disease)

# Beta Asymmetry:

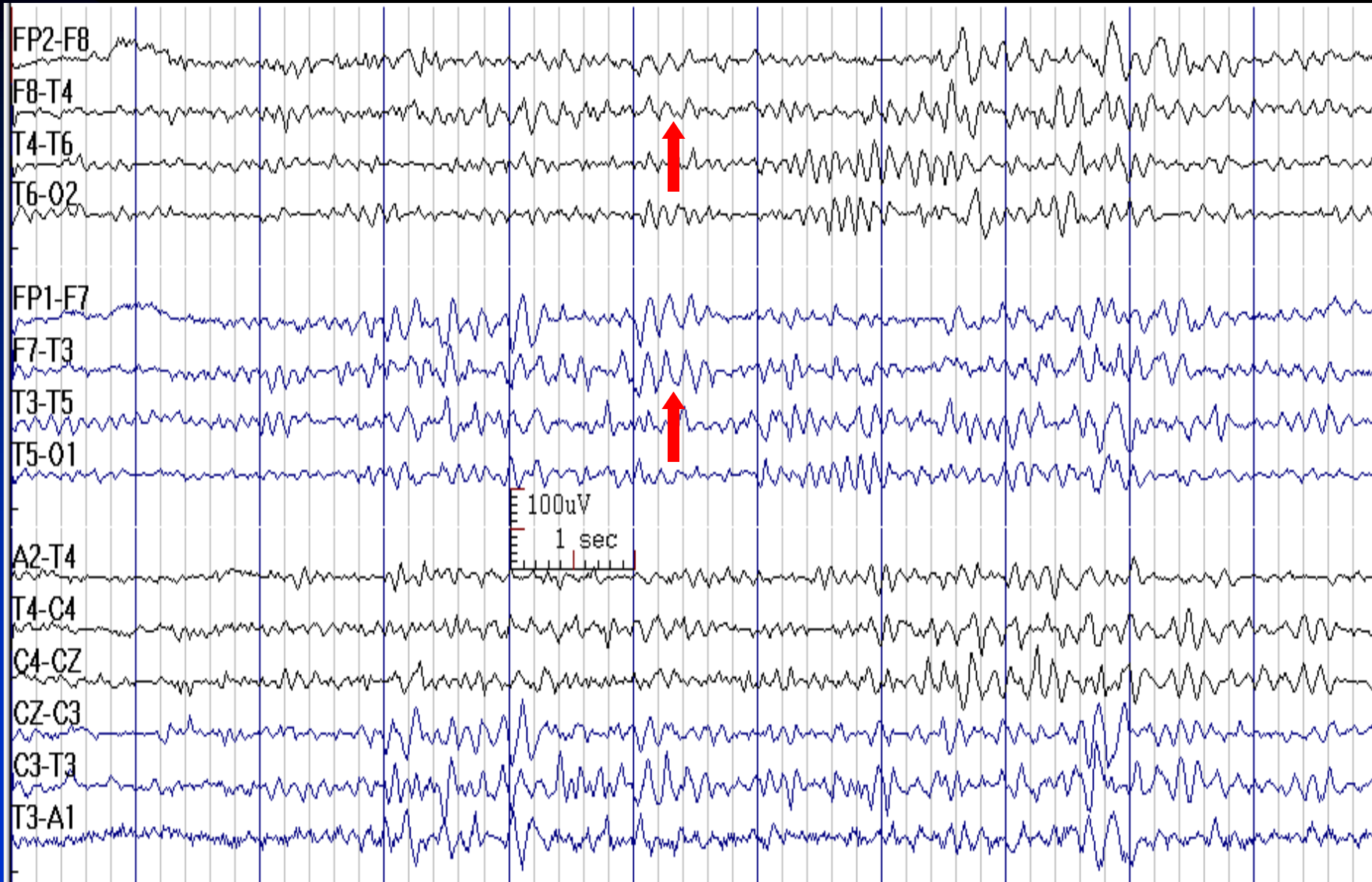
## Increased in Right Hemisphere after Craniotomy



# Theta Activity

- **Frequency:** 4 - 7.5 Hz
- **State:** wakefulness and drowsiness
- **Distribution:** fronto-central regions
- **Characteristics:** irregular or sinusoidal
- **Amplitude:** usually less than 45  $\mu\text{V}$
- **Reactivity:** state dependent
- **Ontogeny:** present in large amount in children in midline regions, reaches a peak at 5-6 years, largely disappears by adulthood
- Random 6-7 Hz low amplitude ( $<15 \mu\text{V}$ ) activity in fronto-central regions in non-drowsy adult is normal

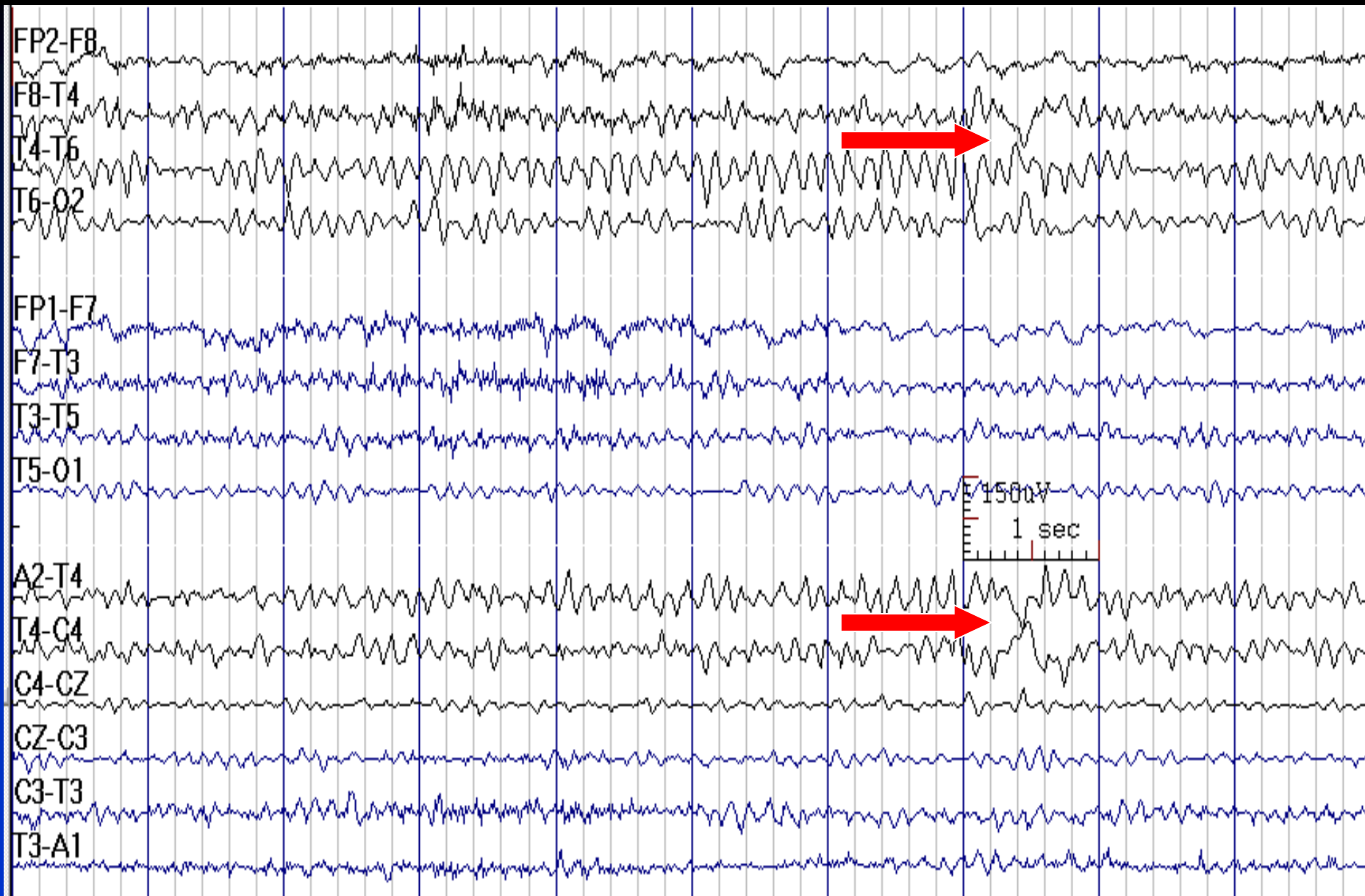
# Theta Activity in Sleep



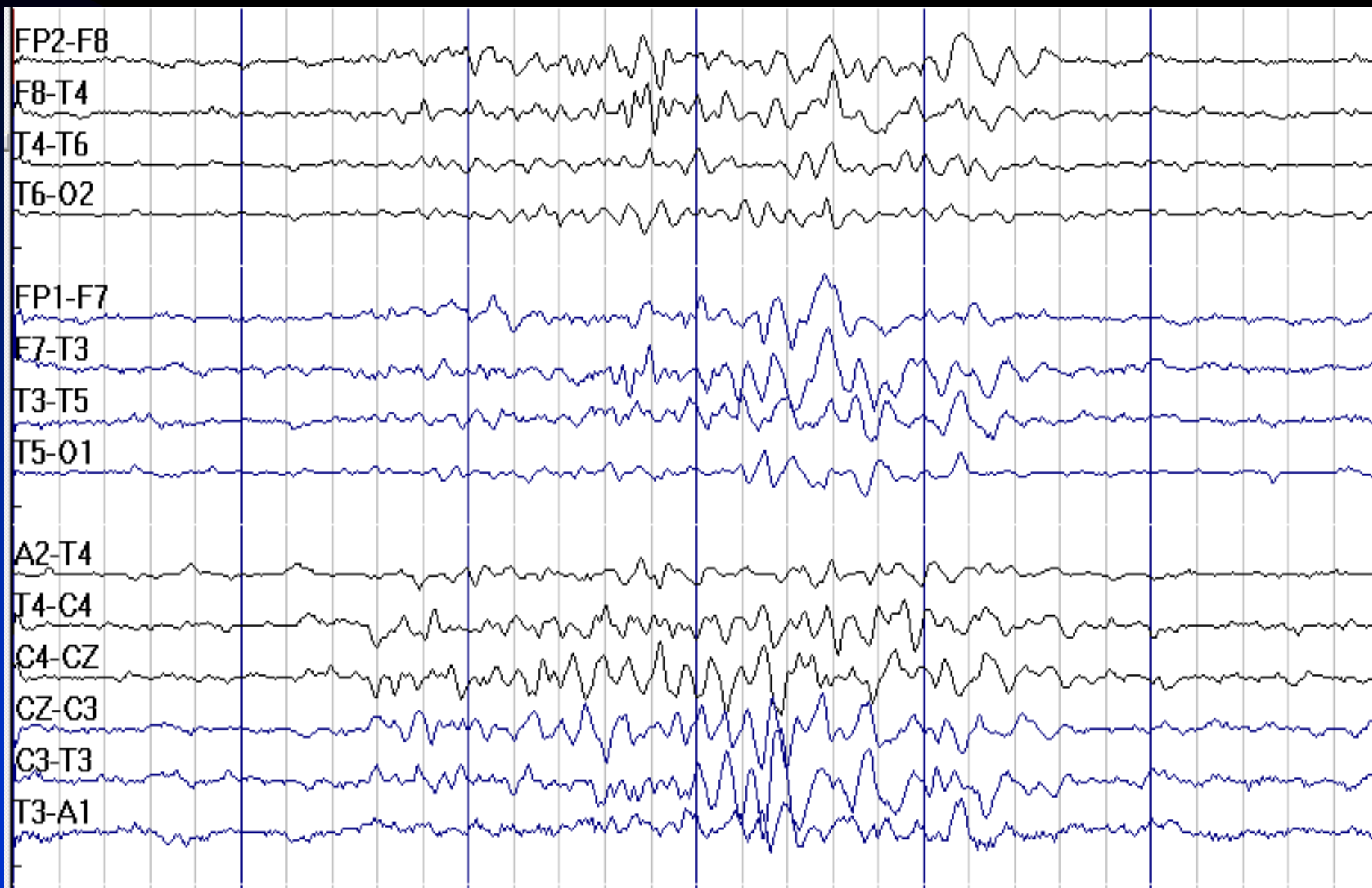
# Delta Activity

- **Frequency:** less than 4 Hz, may have overriding theta, alpha, or beta waves
- **Duration of one waveform:** more than 250 msec
- **Ontogeny:** seen in wakefulness in newborns and infants and dominates in the first year of life, disappears in awake EEG after 6 years of age
- Normally, common in **sleep** stages 3 & 4; may be seen in small amounts in sleep stages 1 & 2 and **hyperventilation**
- When normal, it is usually **symmetric** in frequency and amplitude

# Delta Wave



# Normal Delta and Theta Activity in Sleep



# **Chapter 3**

## **Normal EEG in**

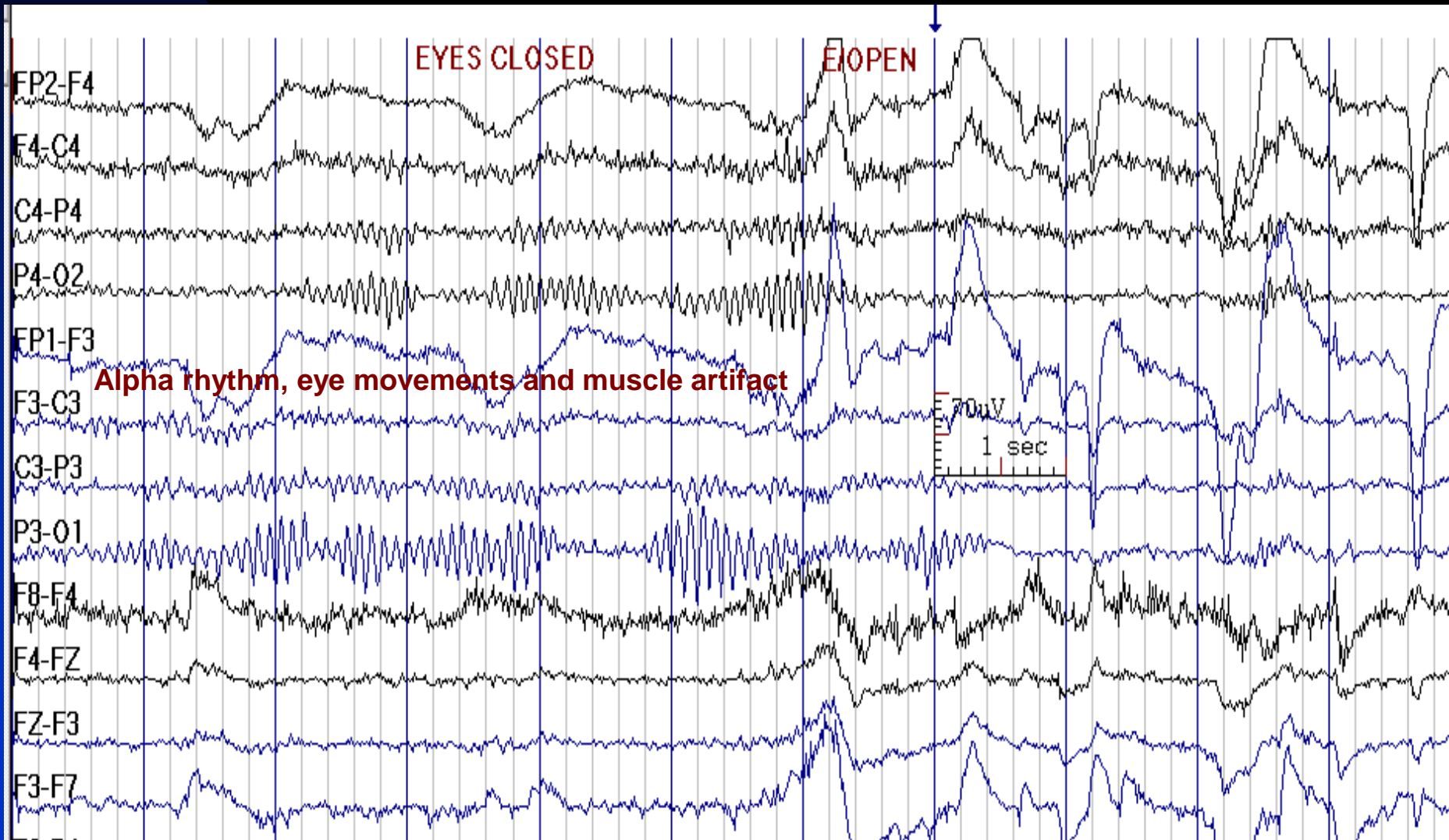
### **Wakefulness and Sleep**



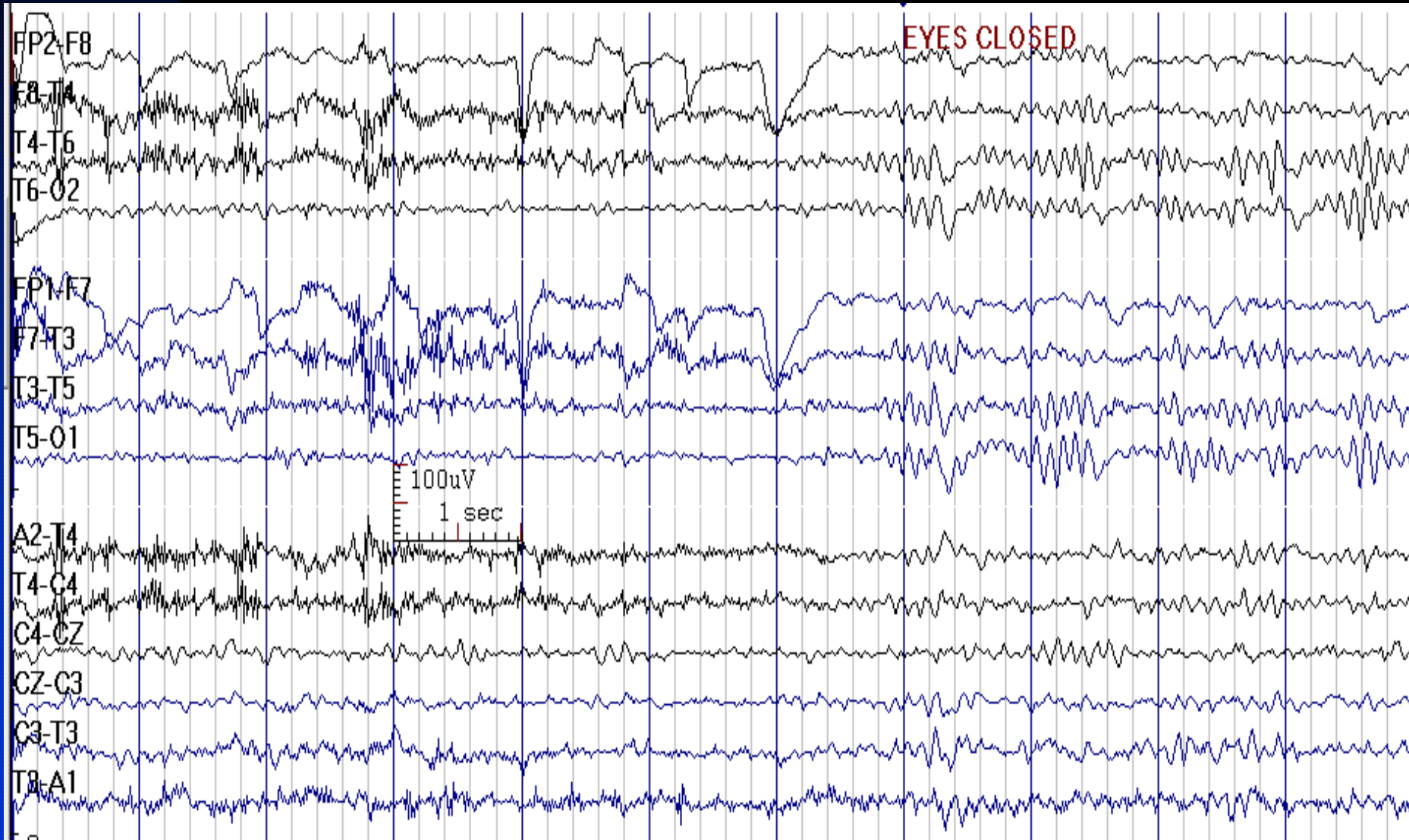
# Awake State

- Fast frequencies ( $> 13$  Hz) predominate in frontal regions
- Posterior dominant rhythm (alpha rhythm) is best displayed with eyes closed
- Eye movement and muscle artifacts are frequent

# EEG in Wakefulness



# EEG in Wakefulness



# Drowsiness (Stage 1 Sleep)

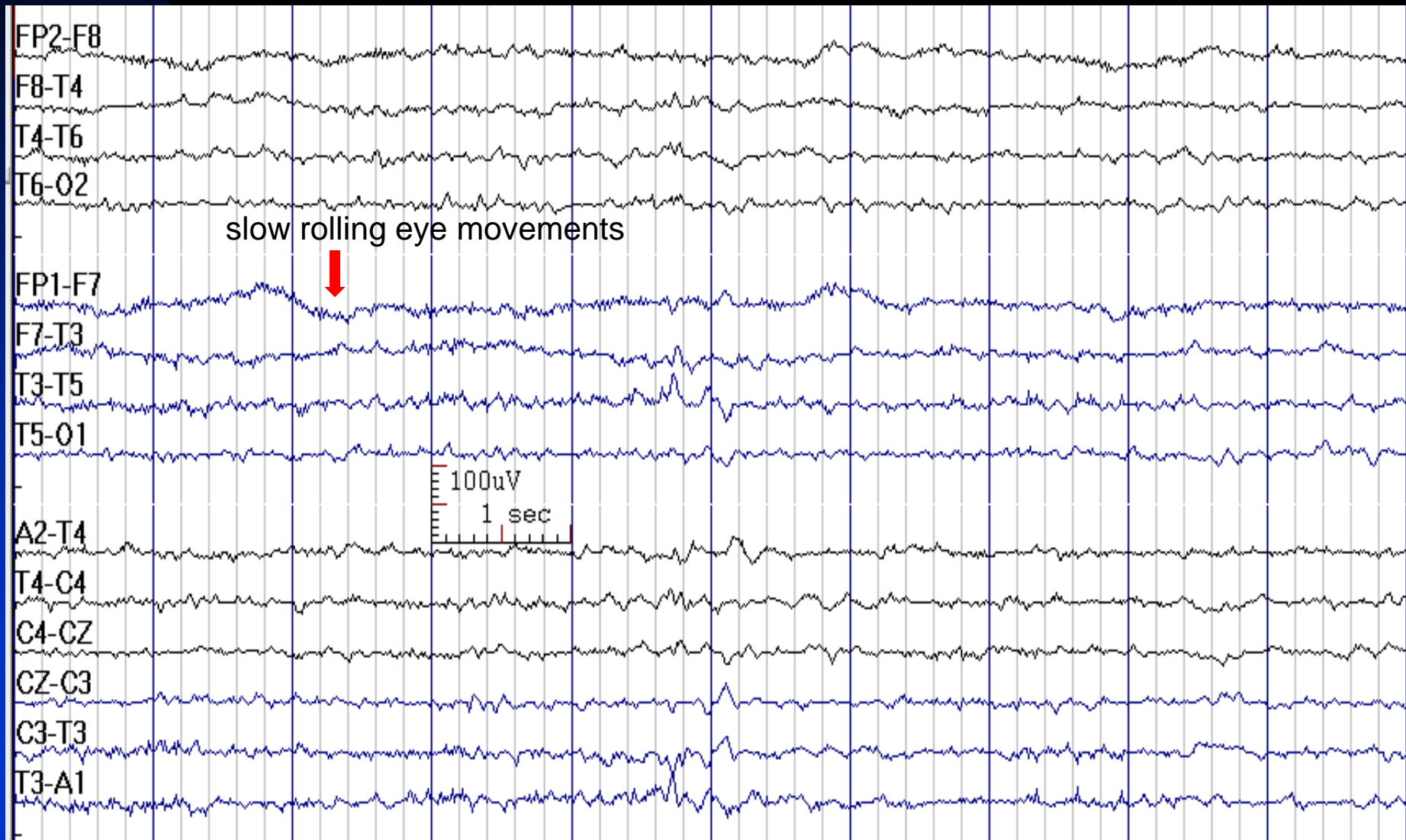
## ■ Physiological clues

- Decreased muscle activity
- Disappearance of eye blinks
- Slow rolling eye movements or rapid horizontal eye movements (infrequent)

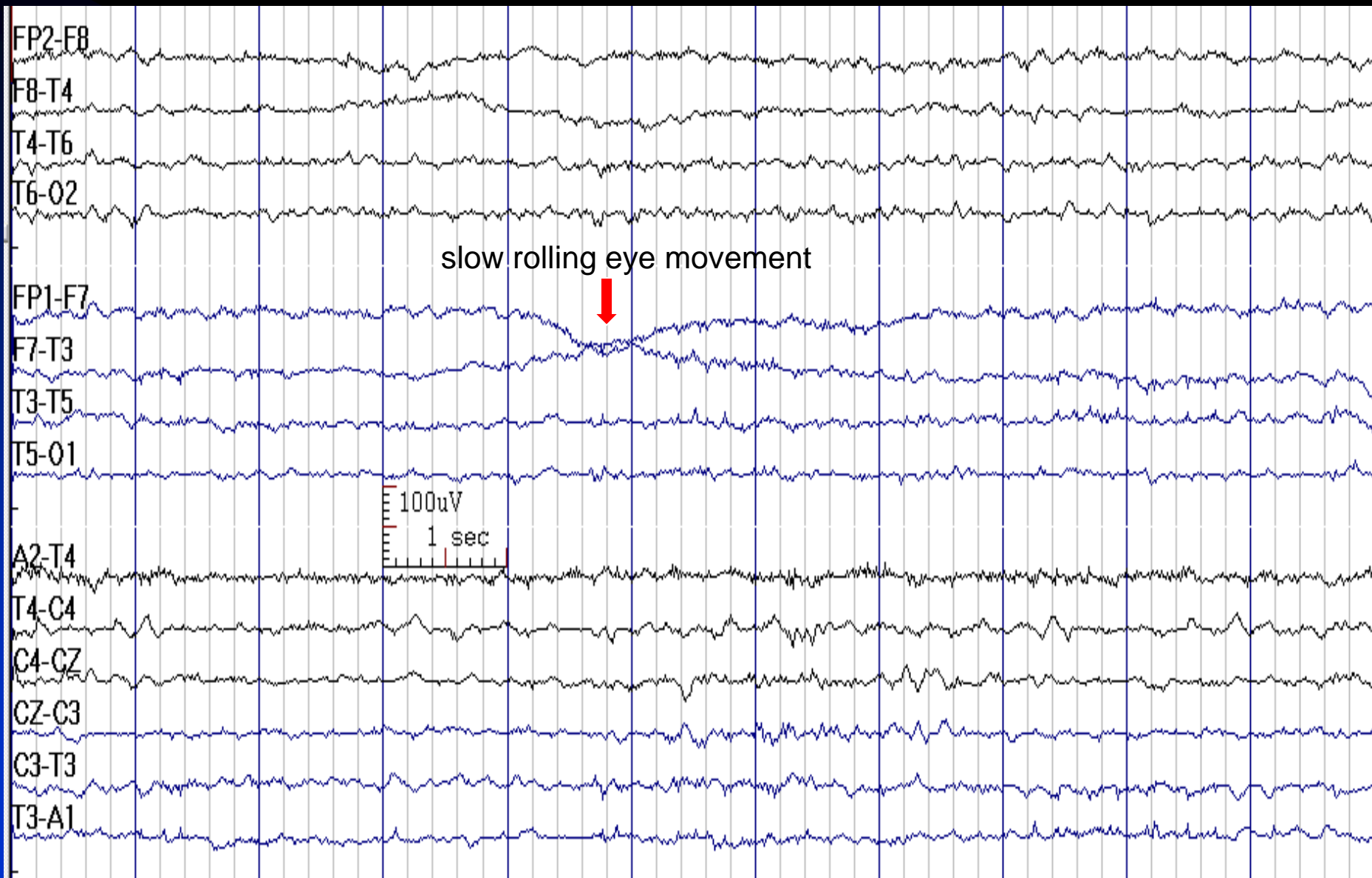
## ■ EEG clues

- Alpha rhythm slowed (1-2 Hz from baseline) and decreased (to less than 20% of the background) with anterior spread
- Increased fronto-central beta activity, occasional central beta spindles
- Increased fronto-central theta activity
- Vertex waves (later in drowsiness)
- Positive Occipital Sharp Transients of Sleep (POSTS)

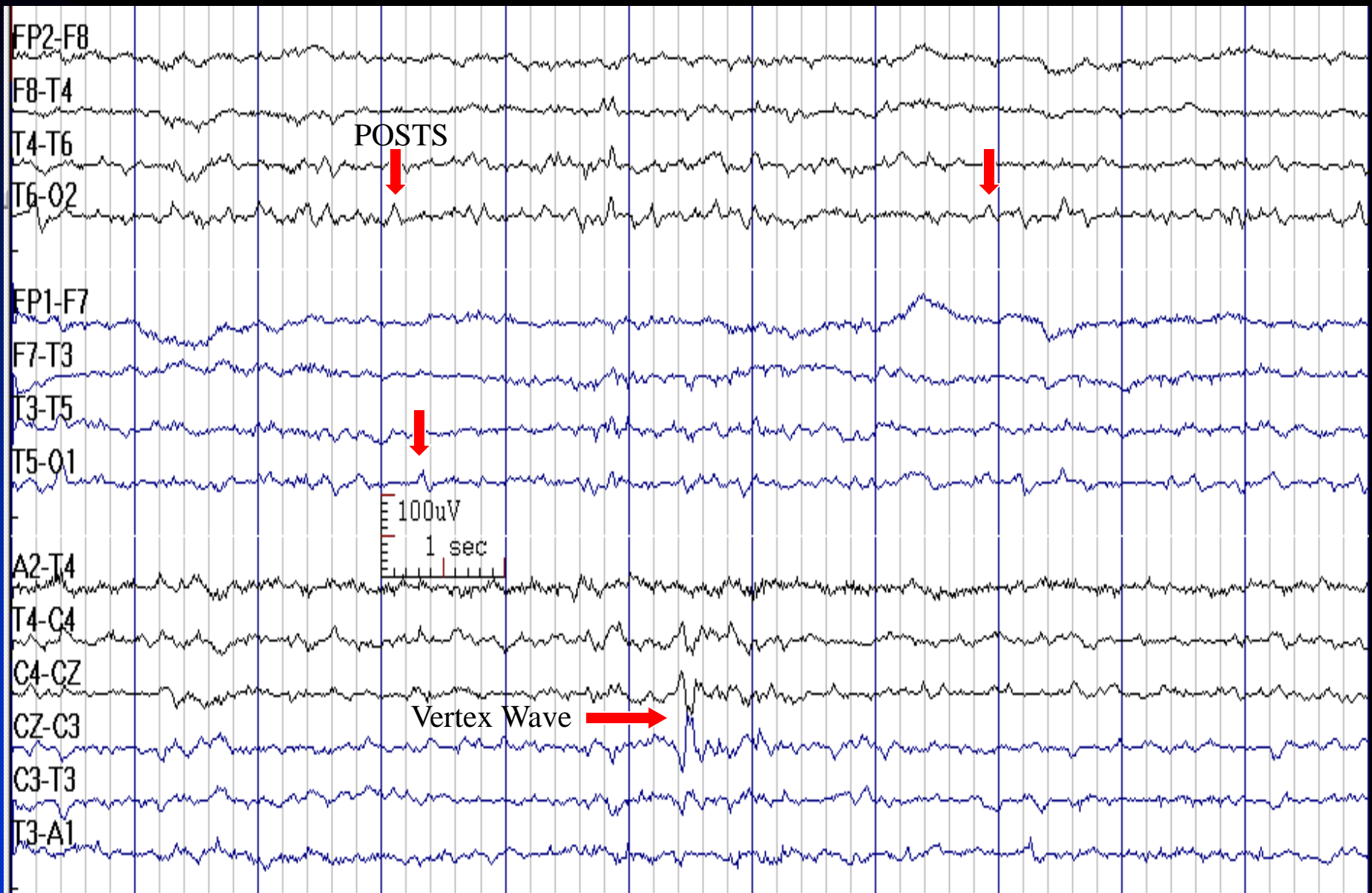
# EEG in Drowsiness (↓ Muscle Artifact, No Eye Blinks, Slow Rolling Eye Movements, Decreased Alpha, Increased Theta)



# EEG in Drowsiness (Slow Rolling Eye Movement)

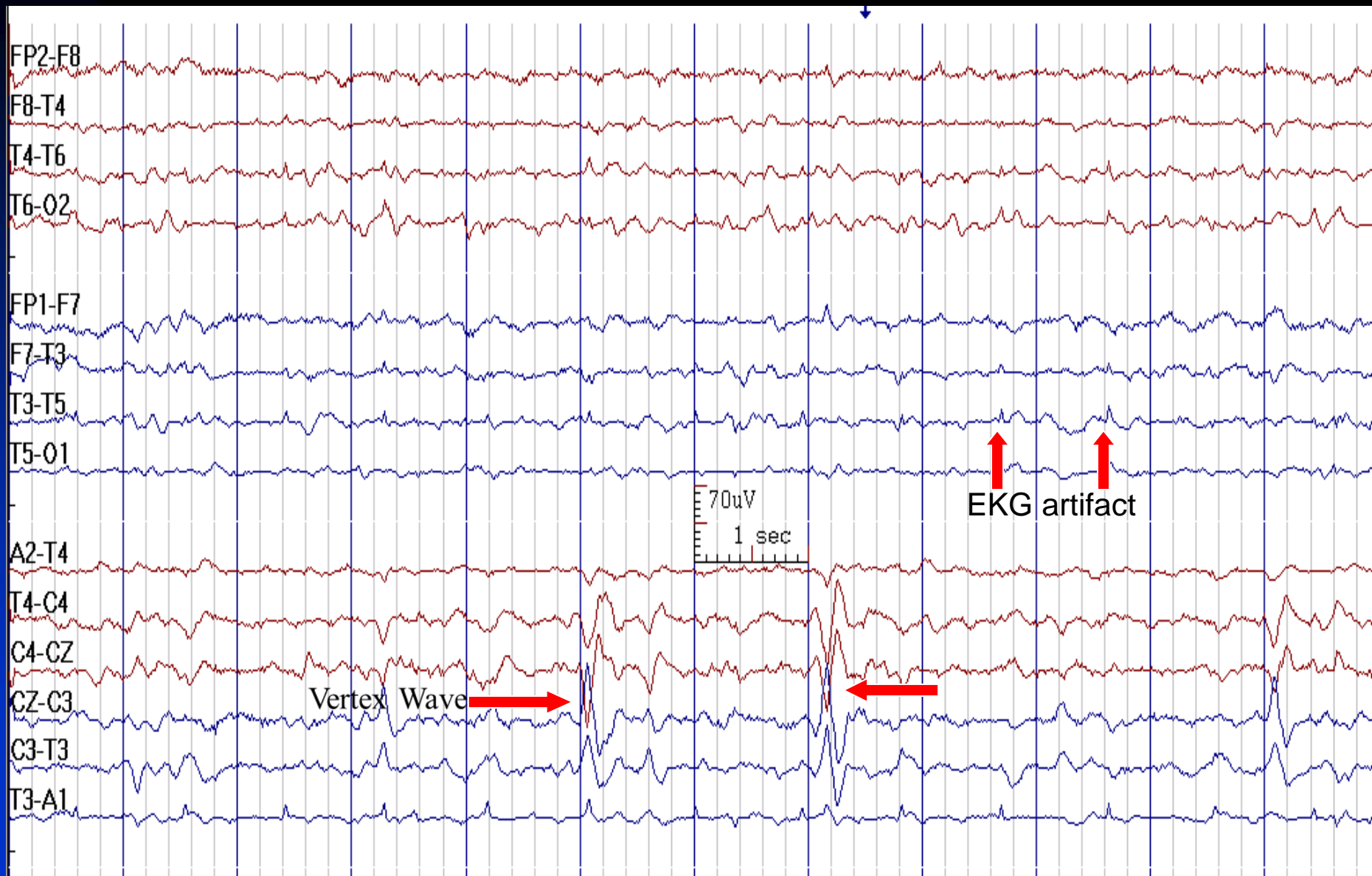


# EEG in Drowsiness (Vertex Wave and POSTS)





# EEG in Drowsiness (V waves)

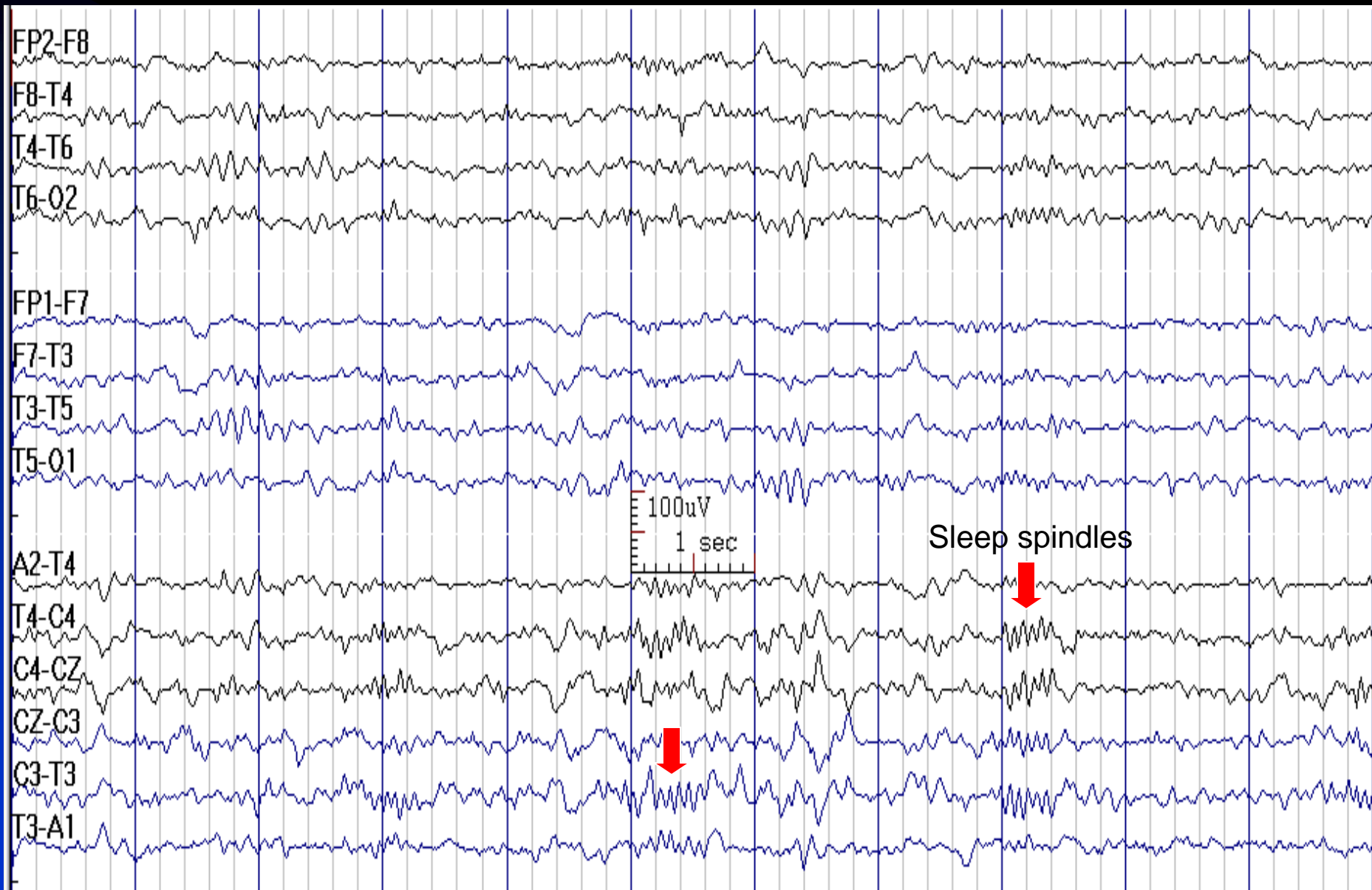




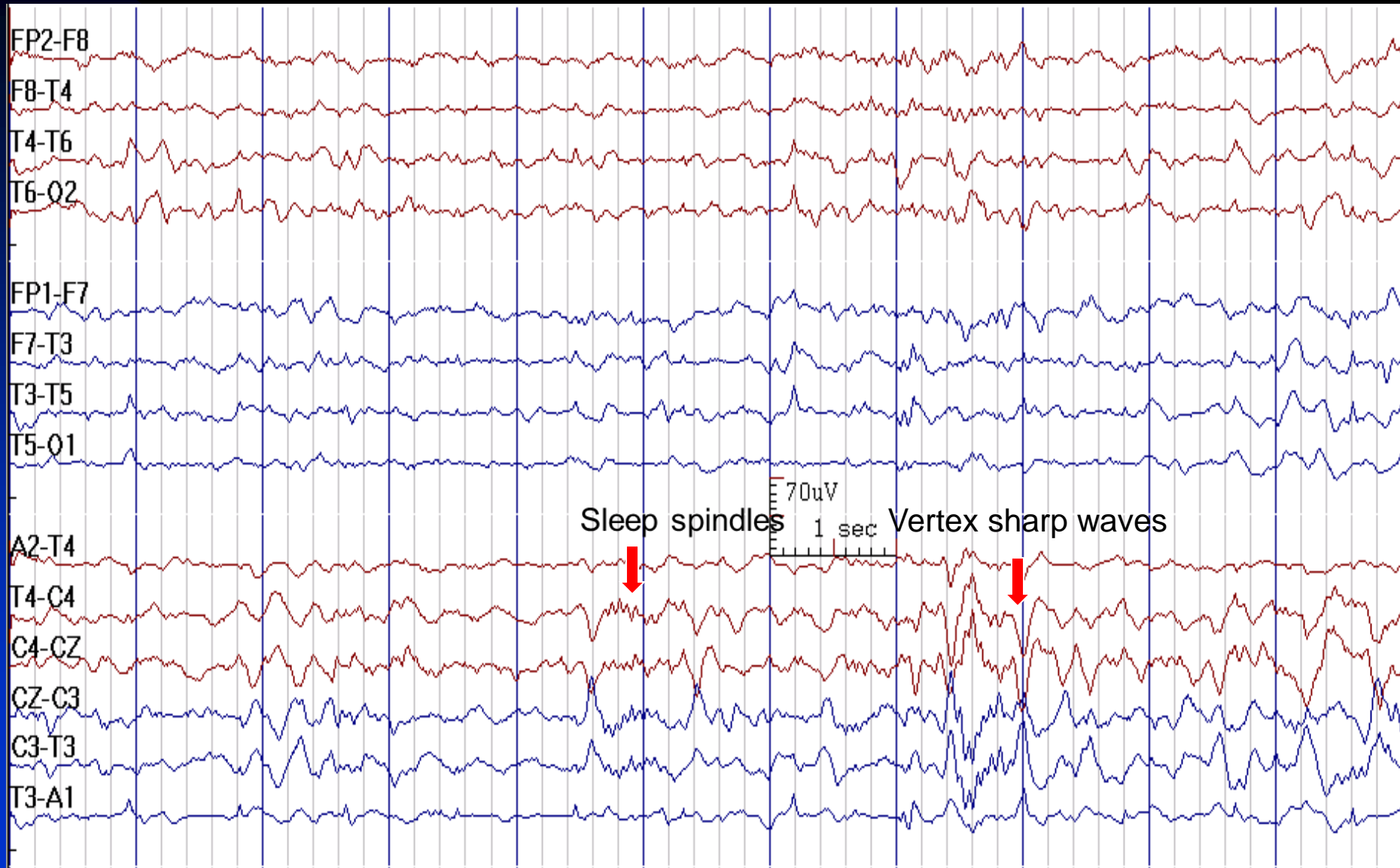
# Stage 2 Sleep

- **Primary differentiating features:** sleep spindles and K-complex
- **Other waves:** vertex waves, POSTS, increased theta, appearance of delta (less than 20% of the record)
- There is no posterior dominant alpha rhythm

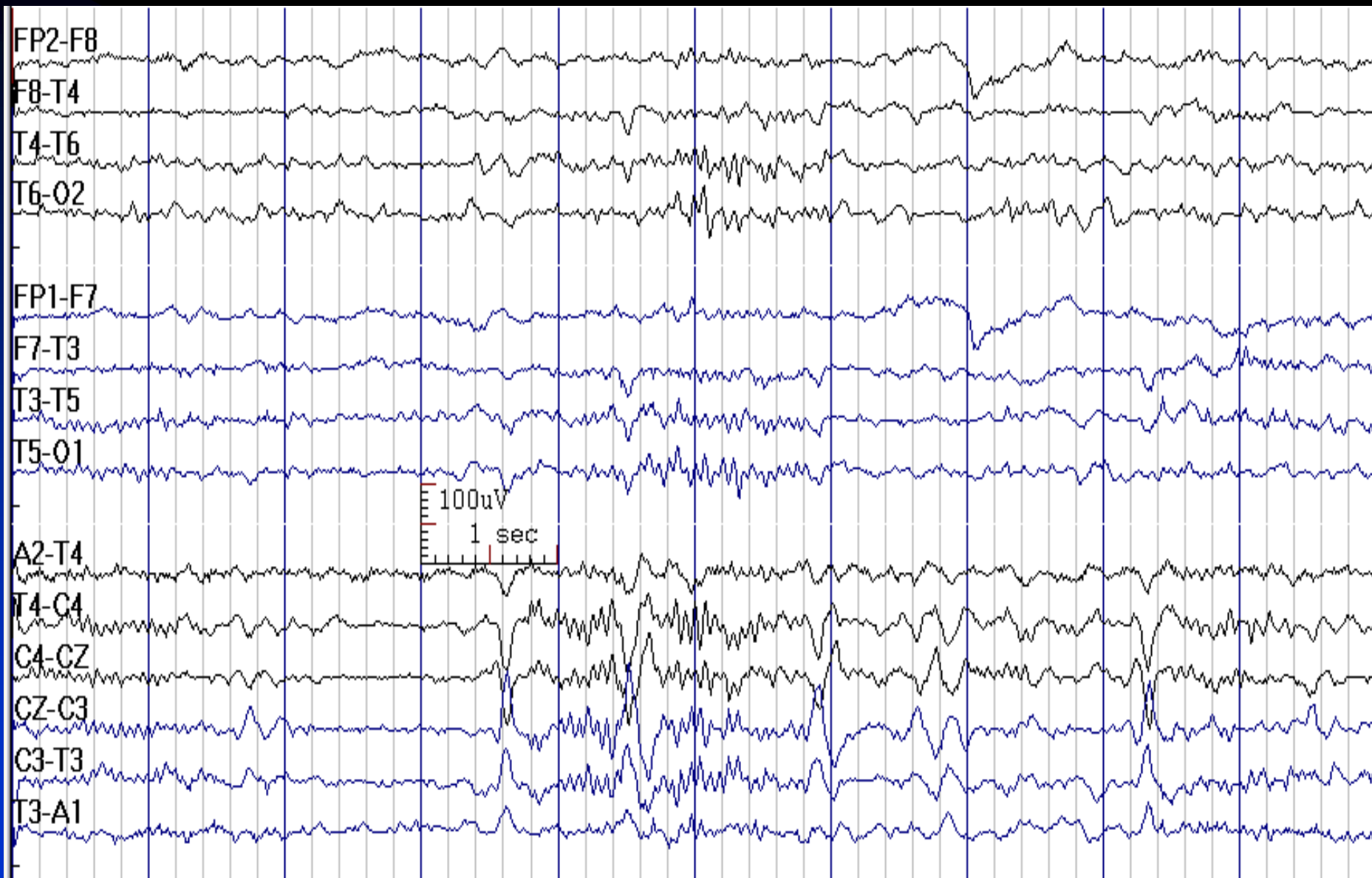
# Stage 2 Sleep



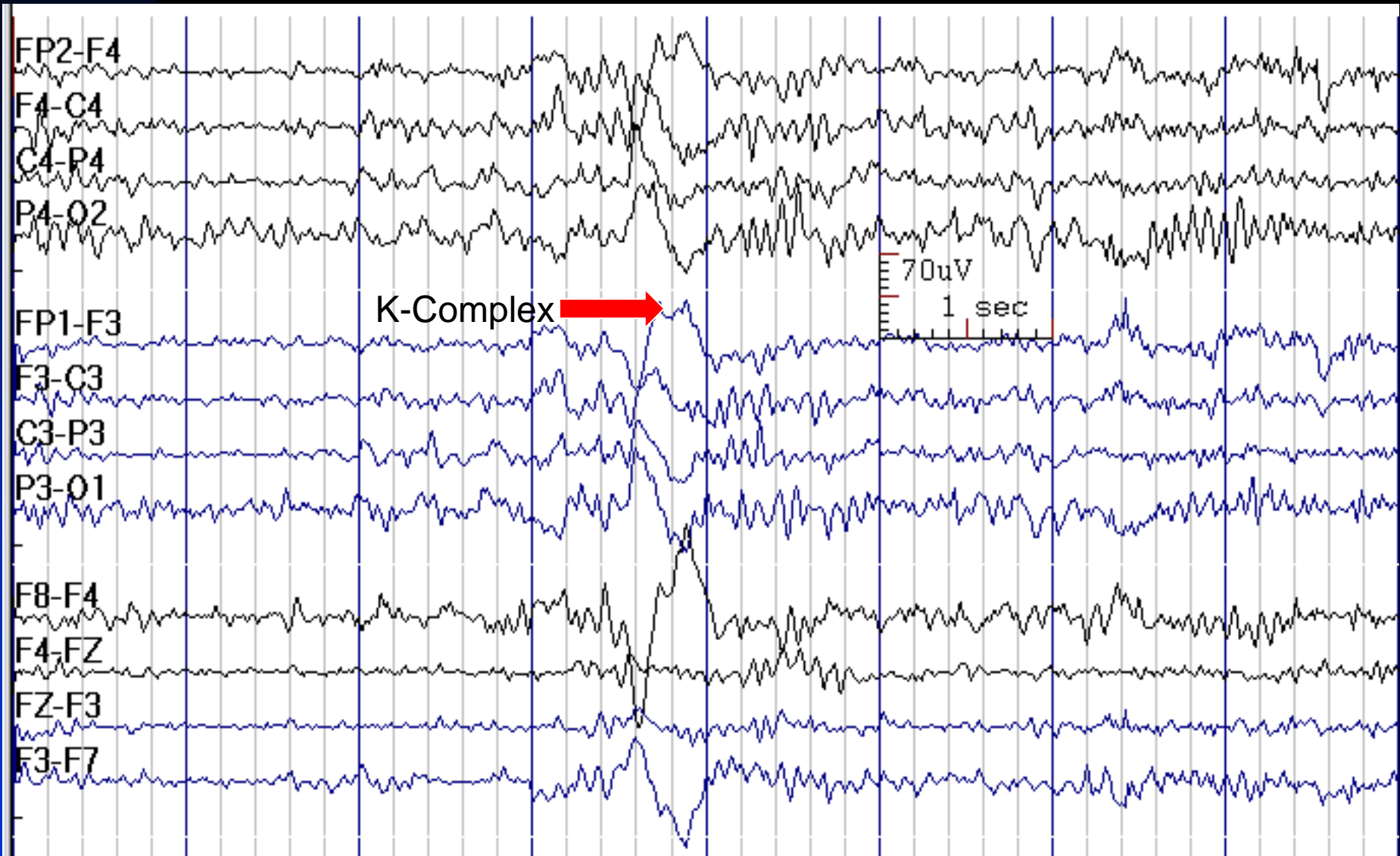
# Stage 2 Sleep



# Stage 2 Sleep



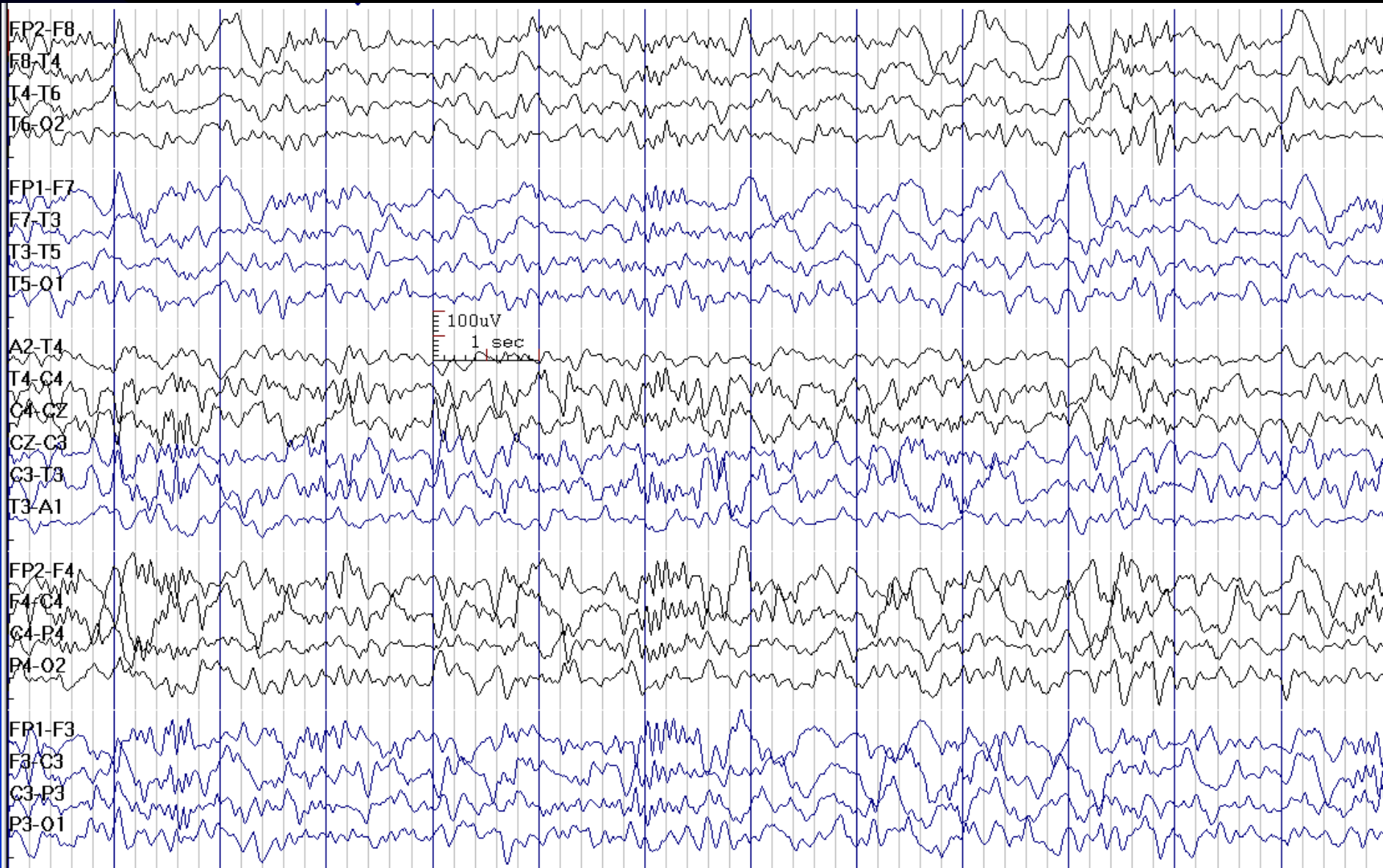
# Stage 2 Sleep



# Slow Wave Sleep (Stages 3 & 4)

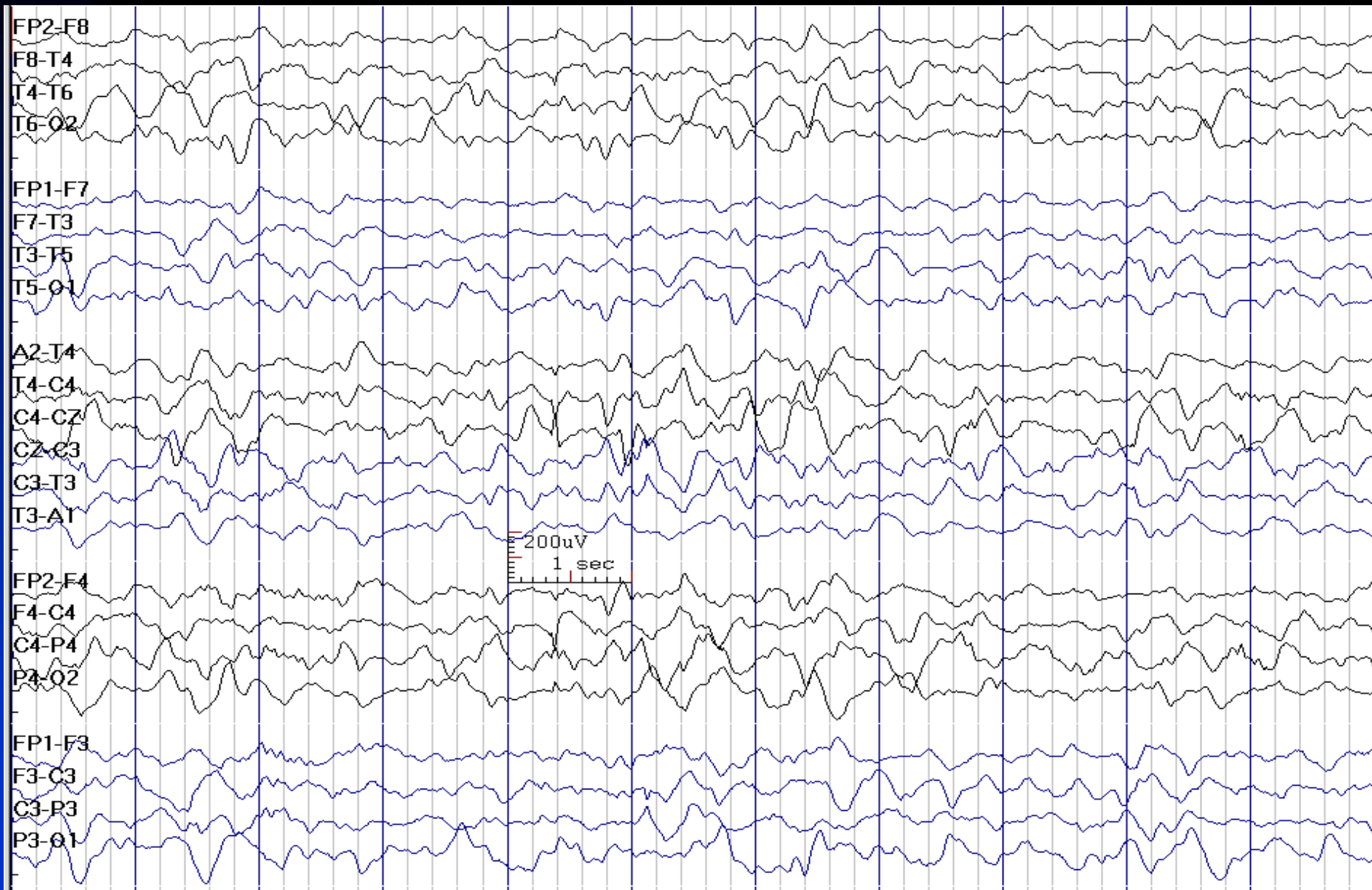
- **Stage 3** : 20-50% high amplitude delta activity
- **Stage 4**: more than 50% delta activity
- **May still be present**: spindles & K-complexes in Stage 3; these disappear in Stage 4
- **Absent**: vertex waves & POSTS
- It is uncommon to record SWS in routine EEG laboratory studies

# Slow Wave Sleep (Stage 3)





# Slow Wave Sleep (Stage 4)

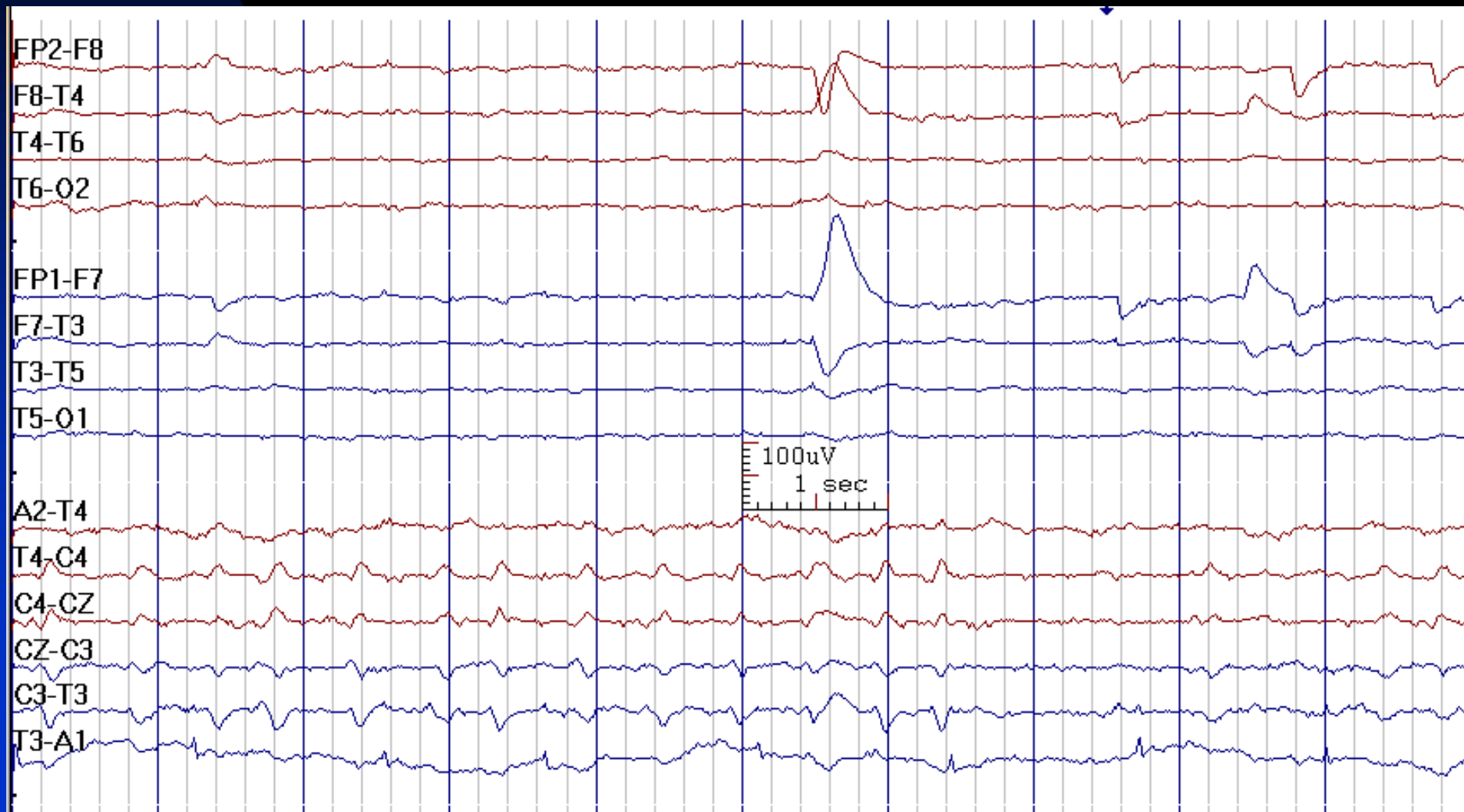




# REM Sleep

- **Stage defining:** rapid eye movements, vertex saw-tooth waves (monomorphic saw-shaped) at onset, lower amplitude mixed frequency alpha-theta background
- **May be present:** variable heart rate & respiration, posteriorly dominant alpha-like activity (slower than alpha)
- **Absent:** Vertex waves, POSTS, K-complexes, sleep spindles
- REM sleep is rarely recorded in routine clinical EEG laboratory studies

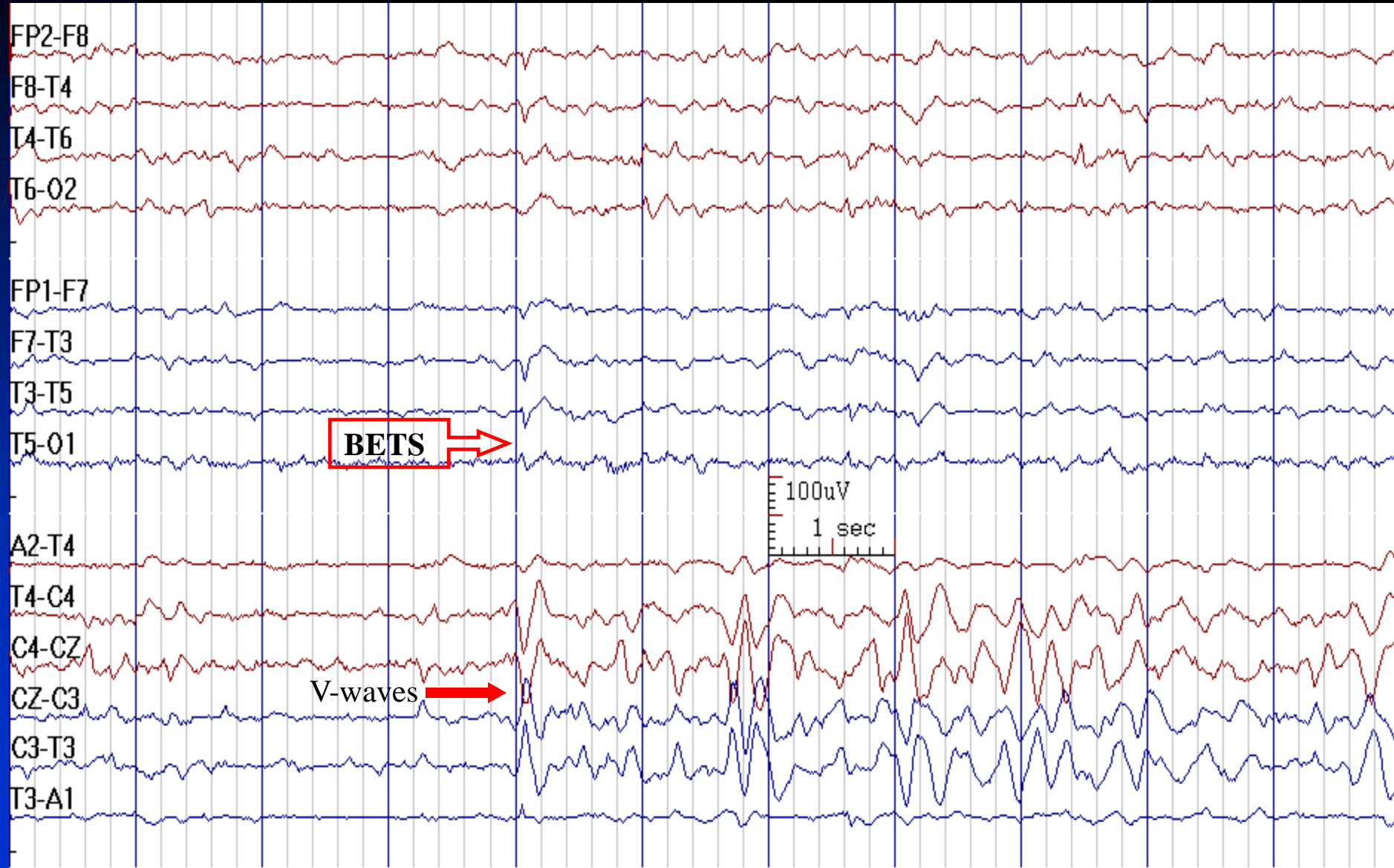
# REM Sleep: Rapid Eye Movements and Vertex Saw-tooth Waves



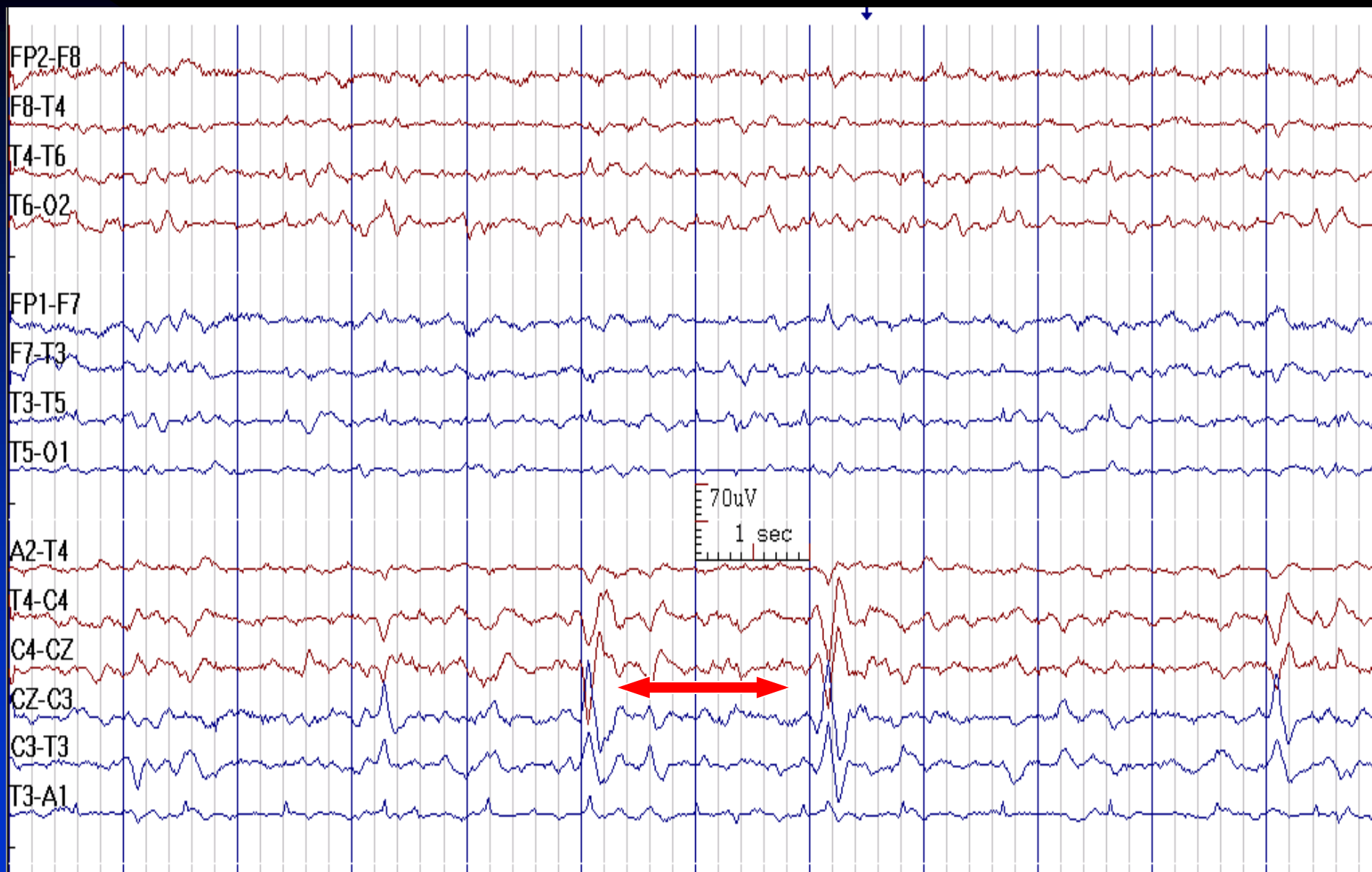
# Vertex Sharp Waves (V waves)

- **Distribution:** central (Cz, C3, C4) maximum, may be off-center
- **Duration:** 100-200 msec (sharper in youth)
- **Amplitude:** 40-100  $\mu\text{V}$
- **Characteristics:** biphasic, initial surface negative, then low voltage positive phases
- **State:** stages 1 & 2 sleep
- Bilaterally synchronous and symmetric

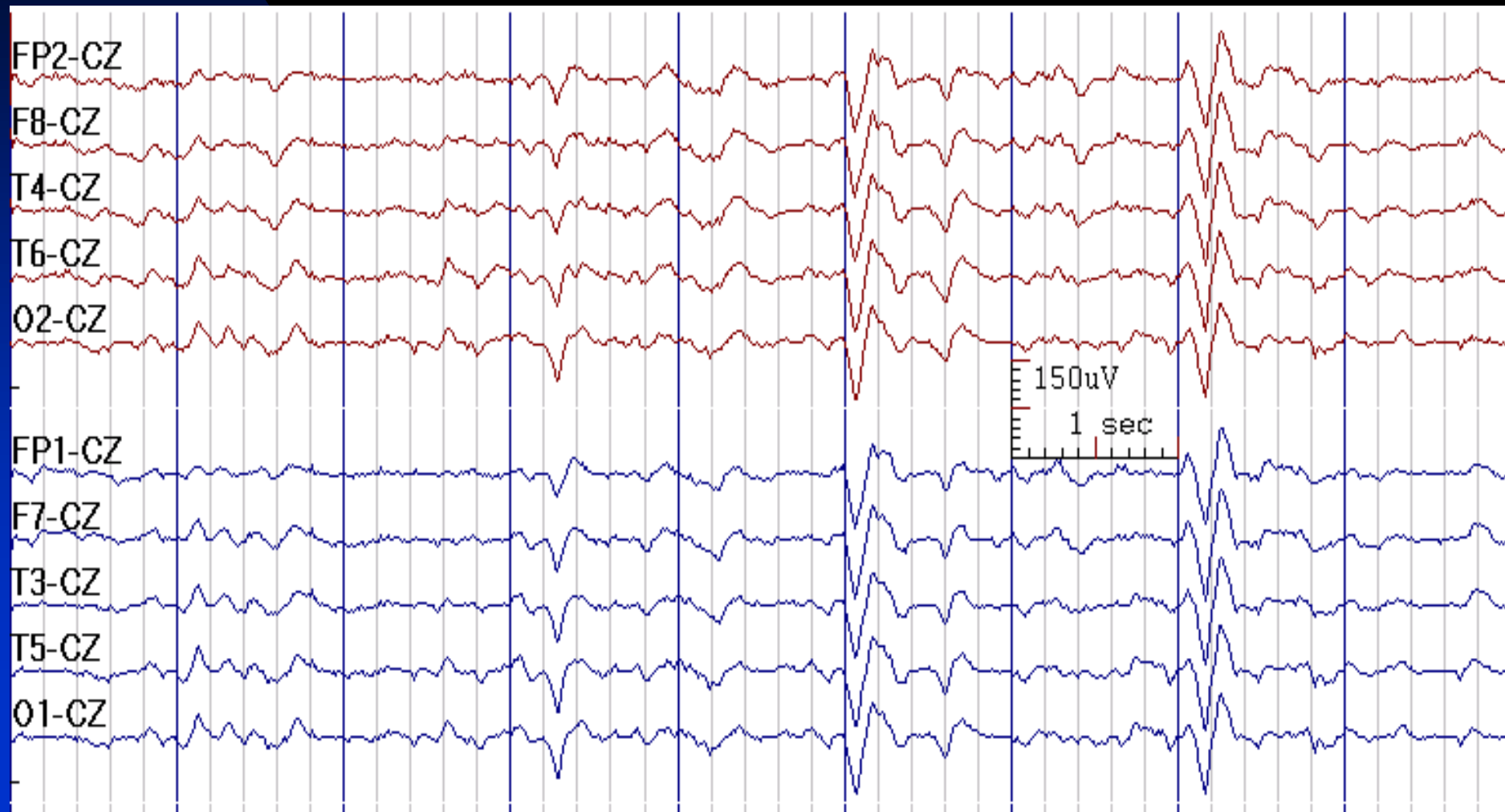
# Run of V-waves in Stage 1 Sleep



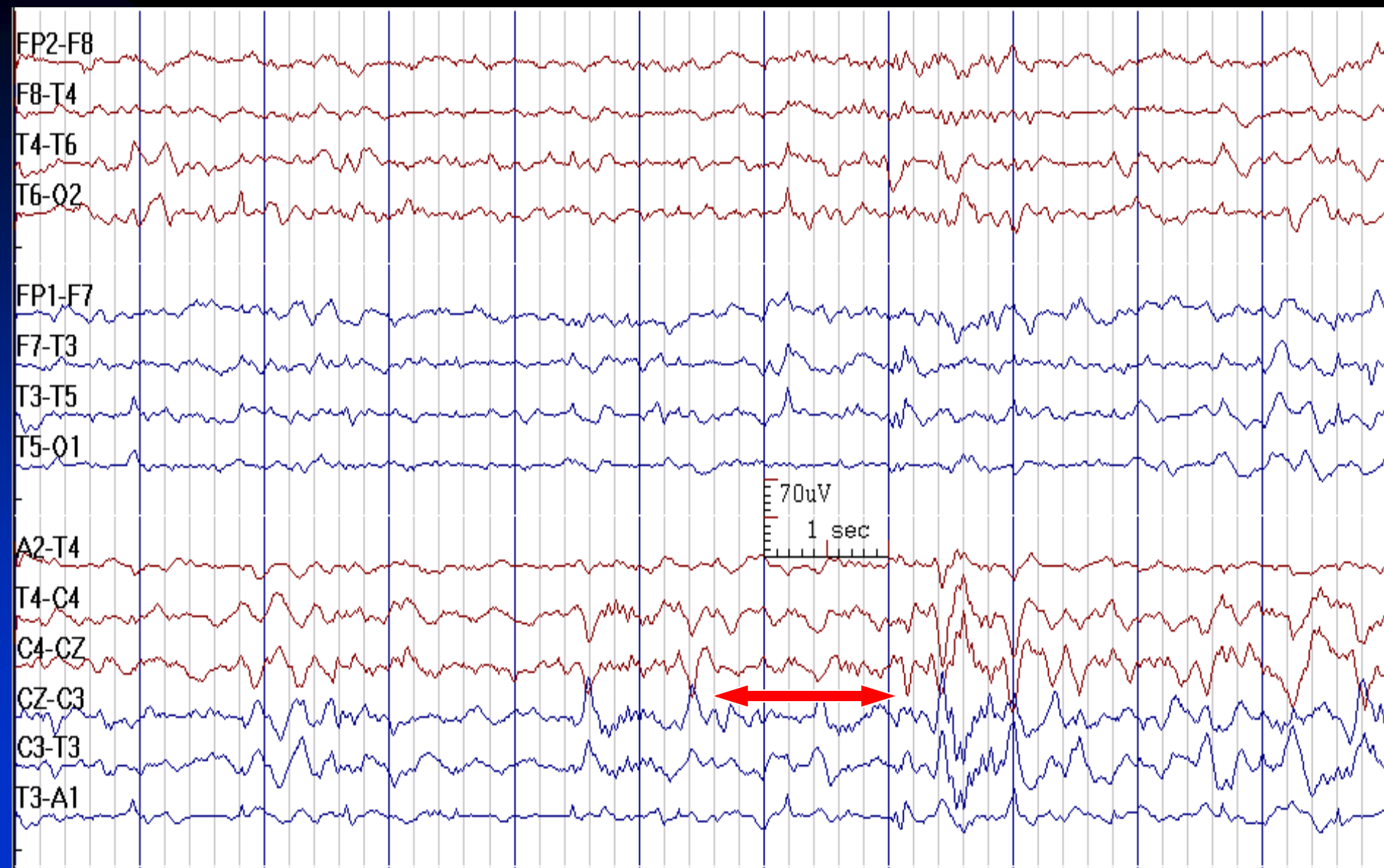
# V-Waves in Stage 1 Sleep



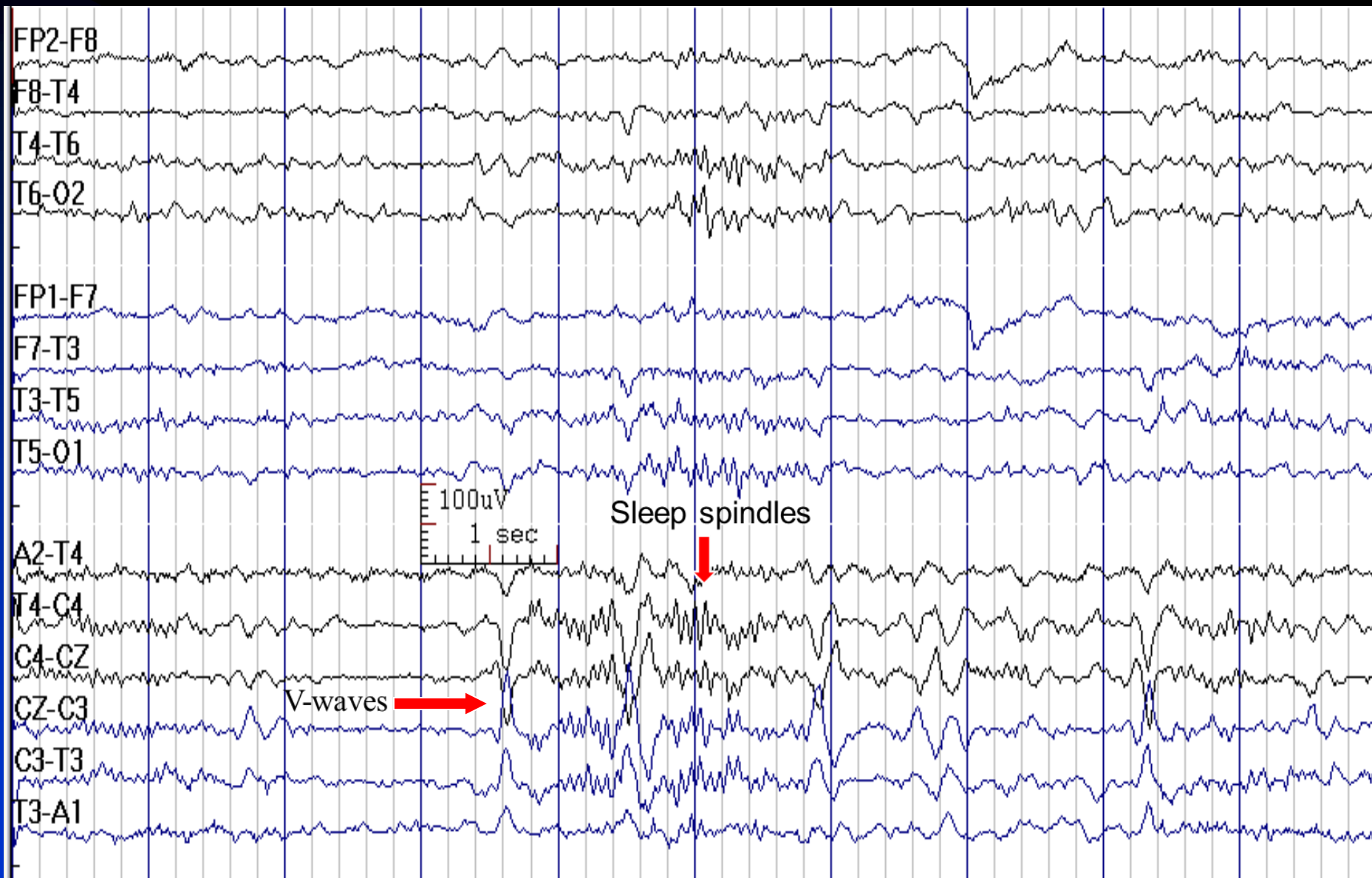
# Vertex Reference Montage Is Not Appropriate to Display Vertex Waves (Contaminated Reference)



# V-Waves in Stage 2 Sleep

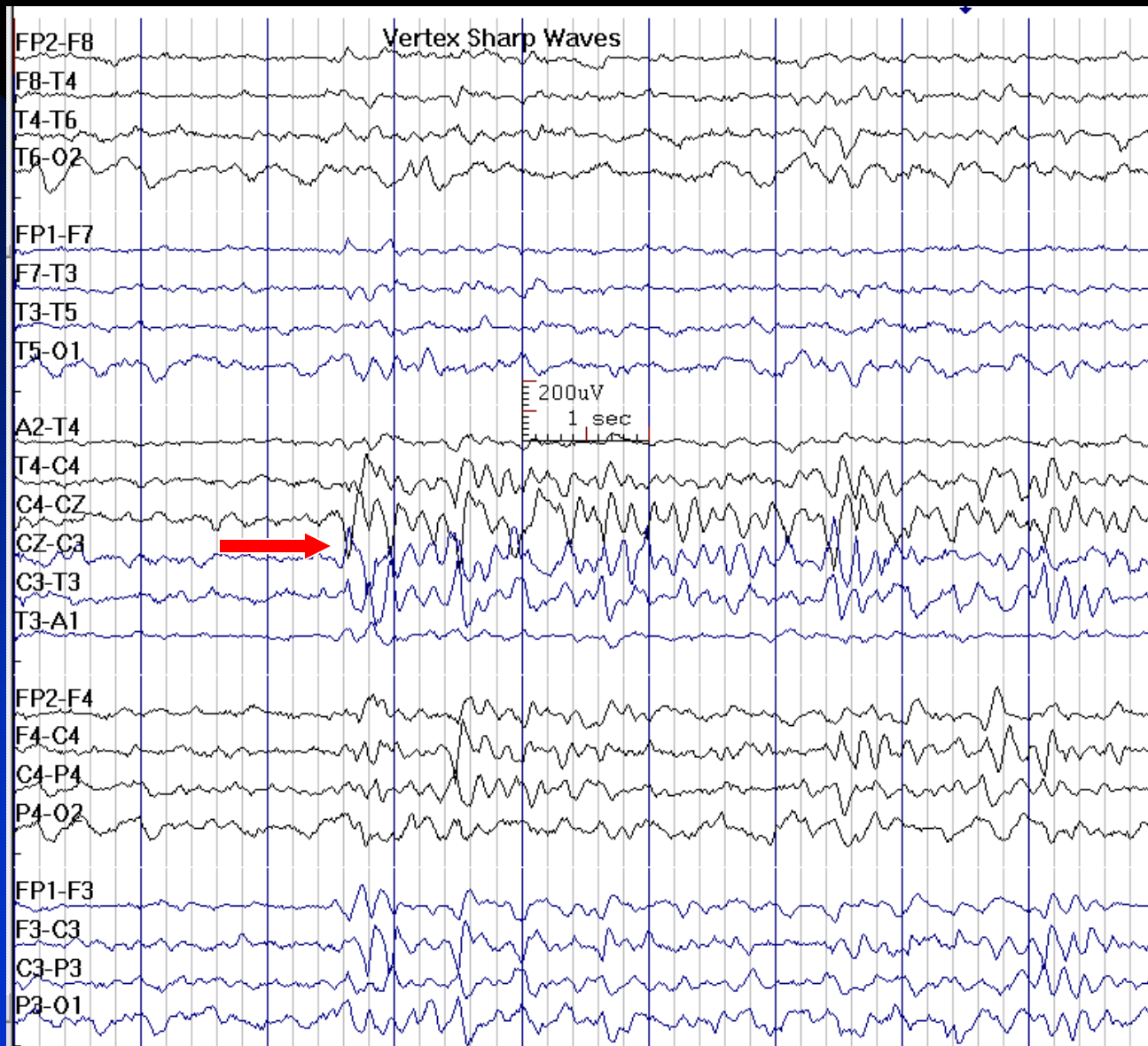


# V-Waves in Stage 2 Sleep

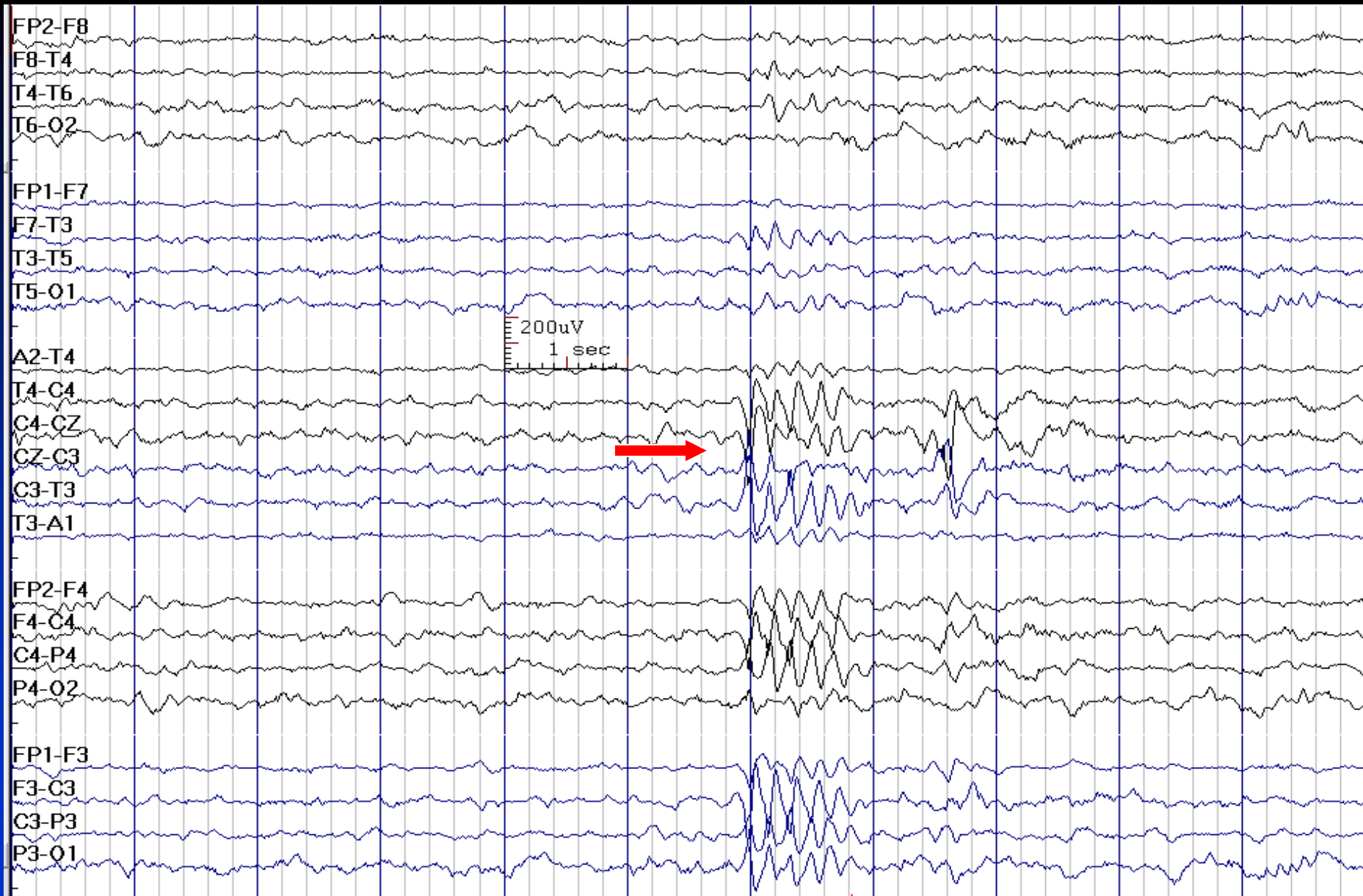




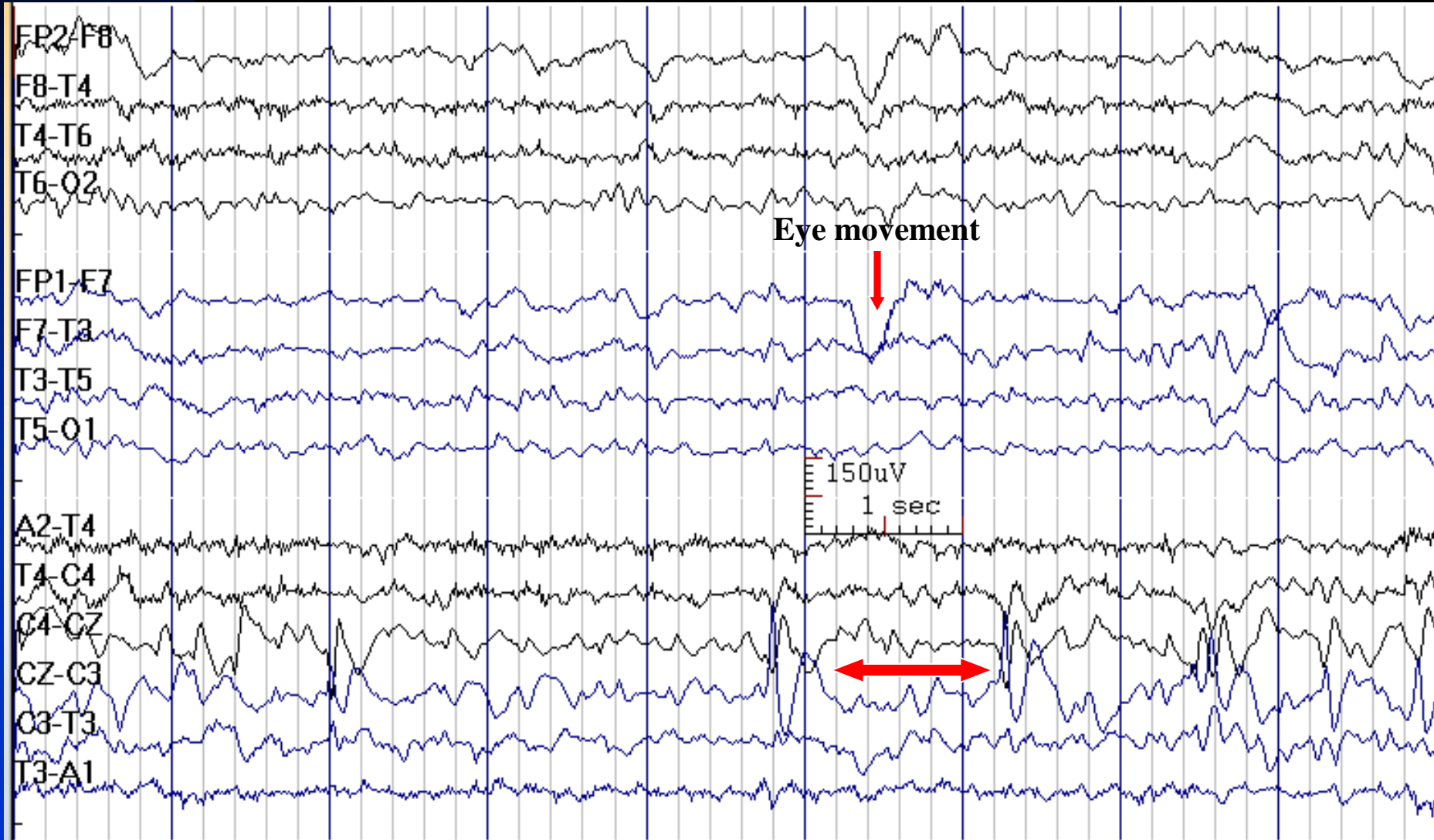
# Run of Vertex Waves



# Run of Vertex Waves in a 7-Year-Old Normal Boy



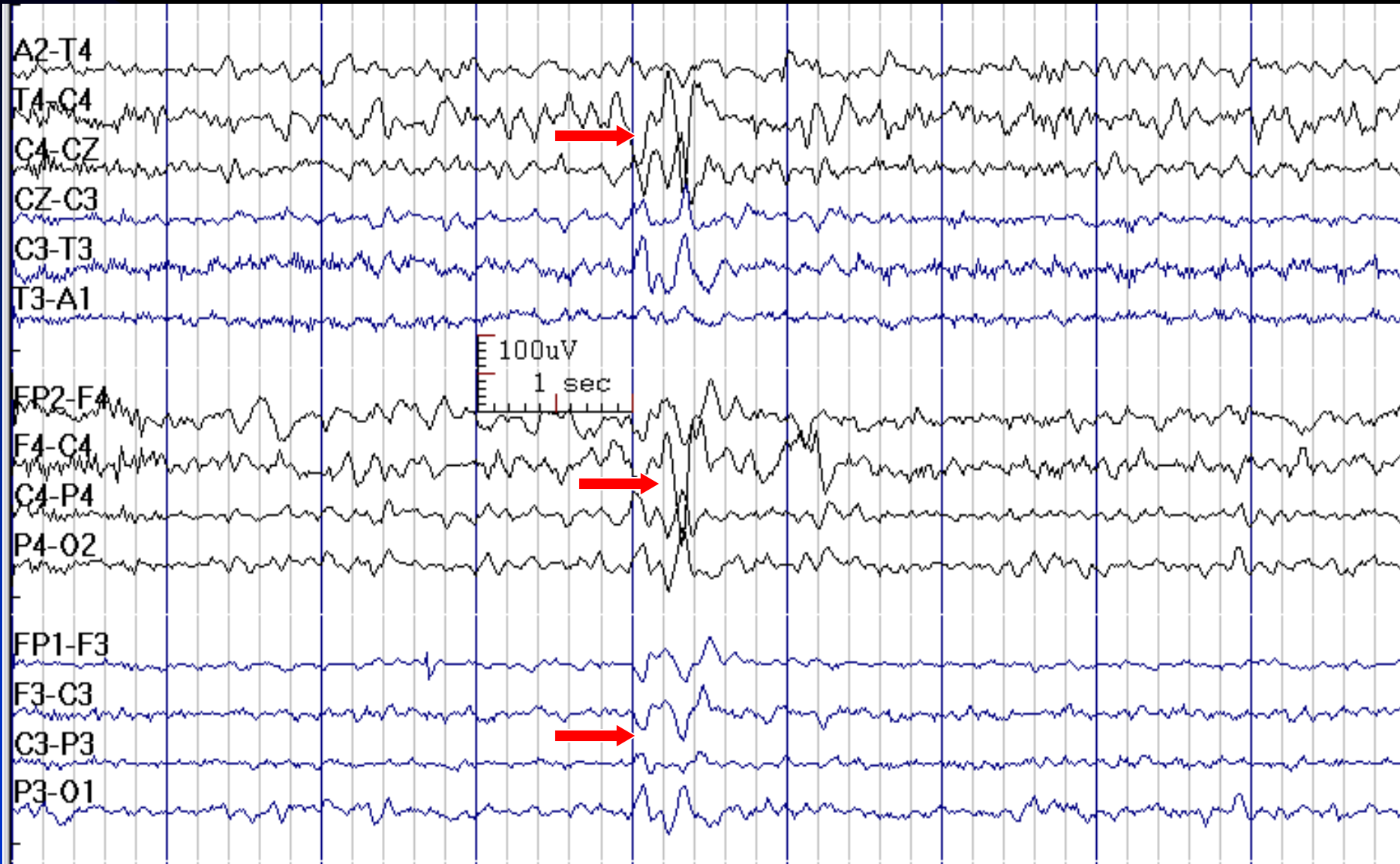
# These Cz Sharp Waves are Abnormal: They Appear in Wakefulness (8-Year-Old Boy with Epilepsy)



# Abnormal V-Waves

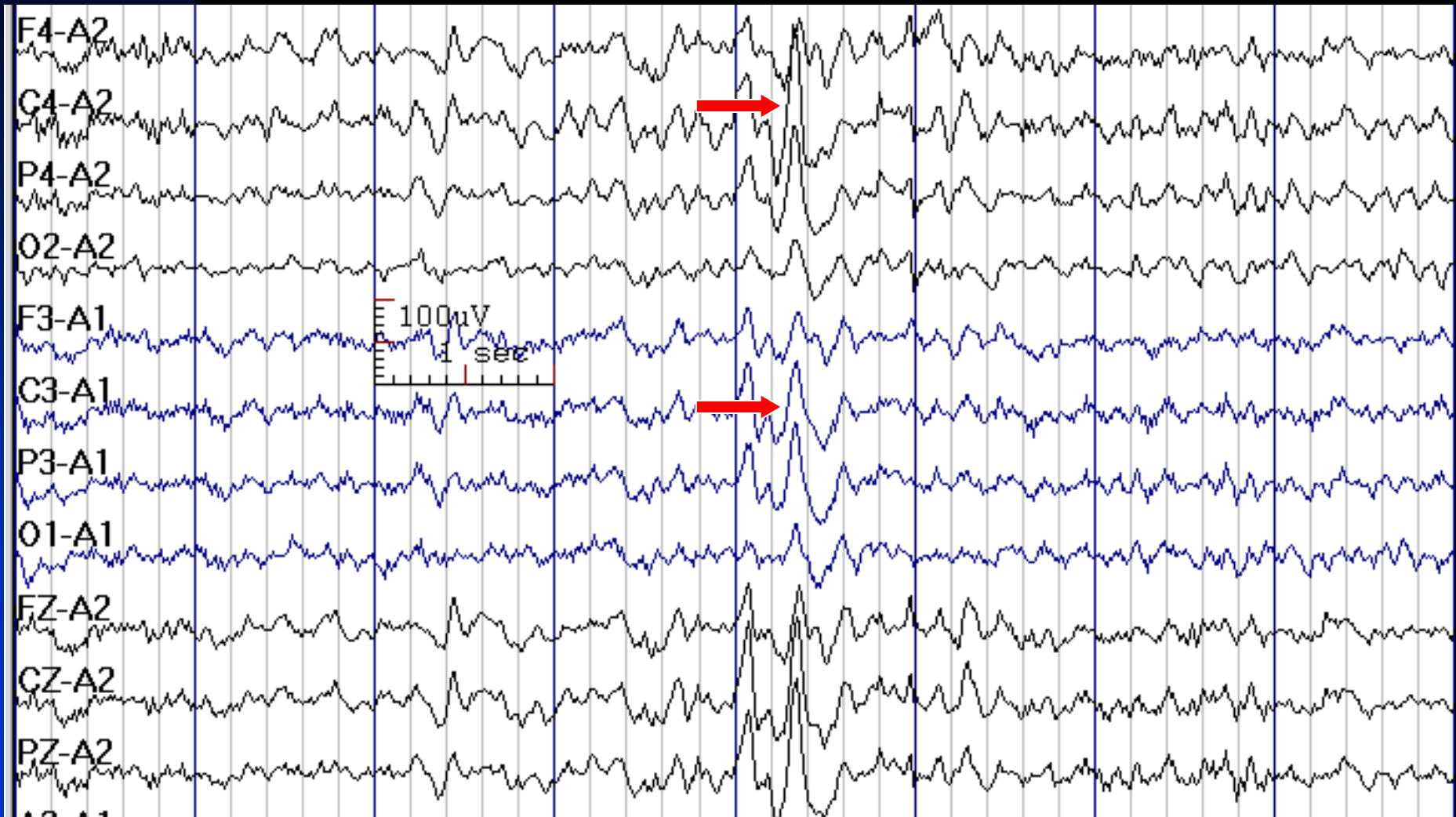
- **Persistent asymmetry of more than 20%:** a lesion on the side with lower amplitude or skull defect on the side with higher amplitude
- **Asynchrony:** obstructive hydrocephalus

# Asymmetric V-Wave (higher amplitude on the right): Due to Skull Defect on Right Side



see the next slide in reference montage

# Previous Slide in Ear Reference Montage (Asymmetric V-Wave)

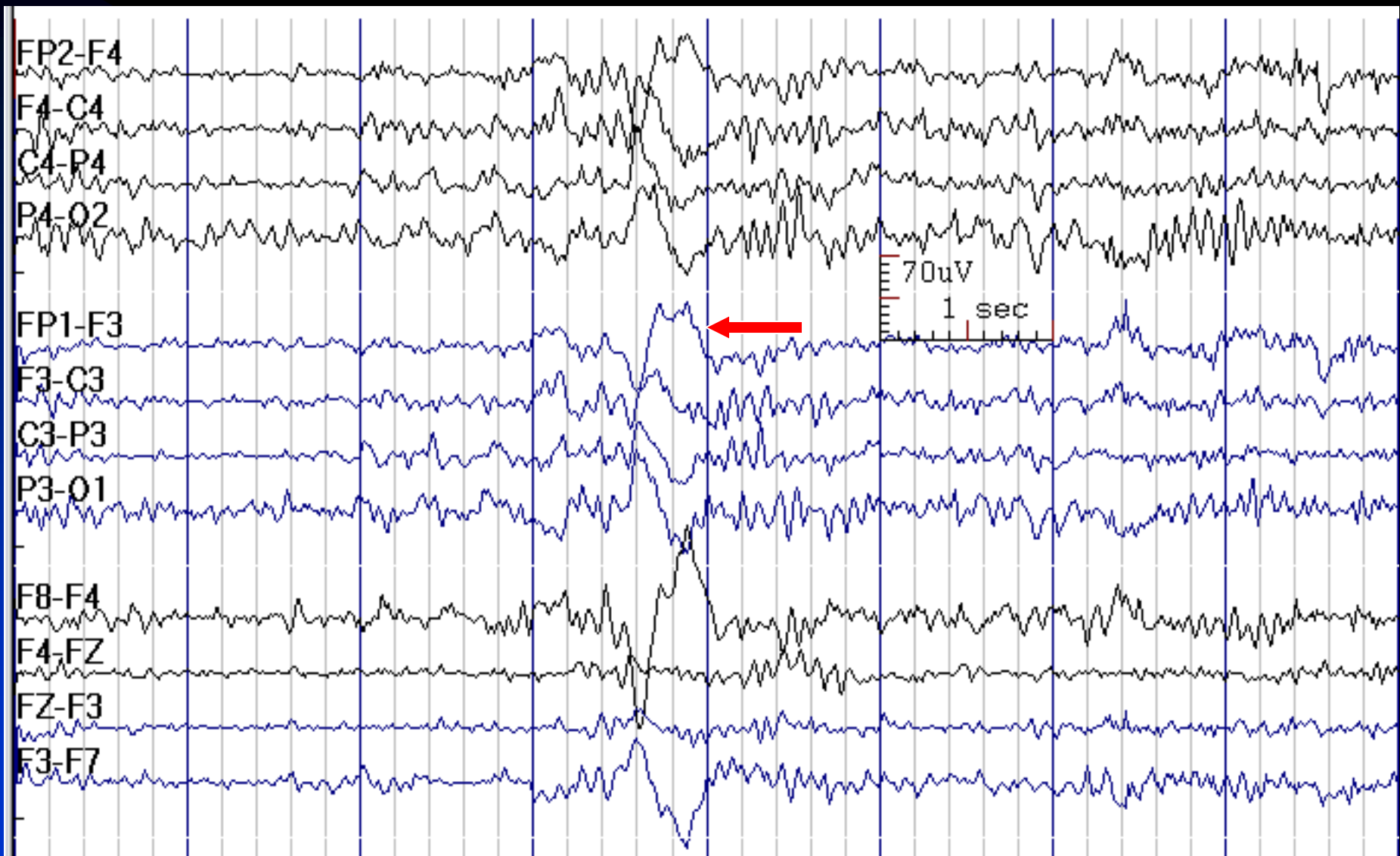


# K-Complex

- **Definition:** biphasic frontal slow waves in sleep, often associated with sleep spindles
- **Distribution:** bilateral, maximum anteriorly
- **Duration:** > 500 msec
- **Amplitude:** usually > 100  $\mu\text{V}$
- **State:** in stages 2 or 3 sleep
- Evoked by auditory or other sensory stimuli



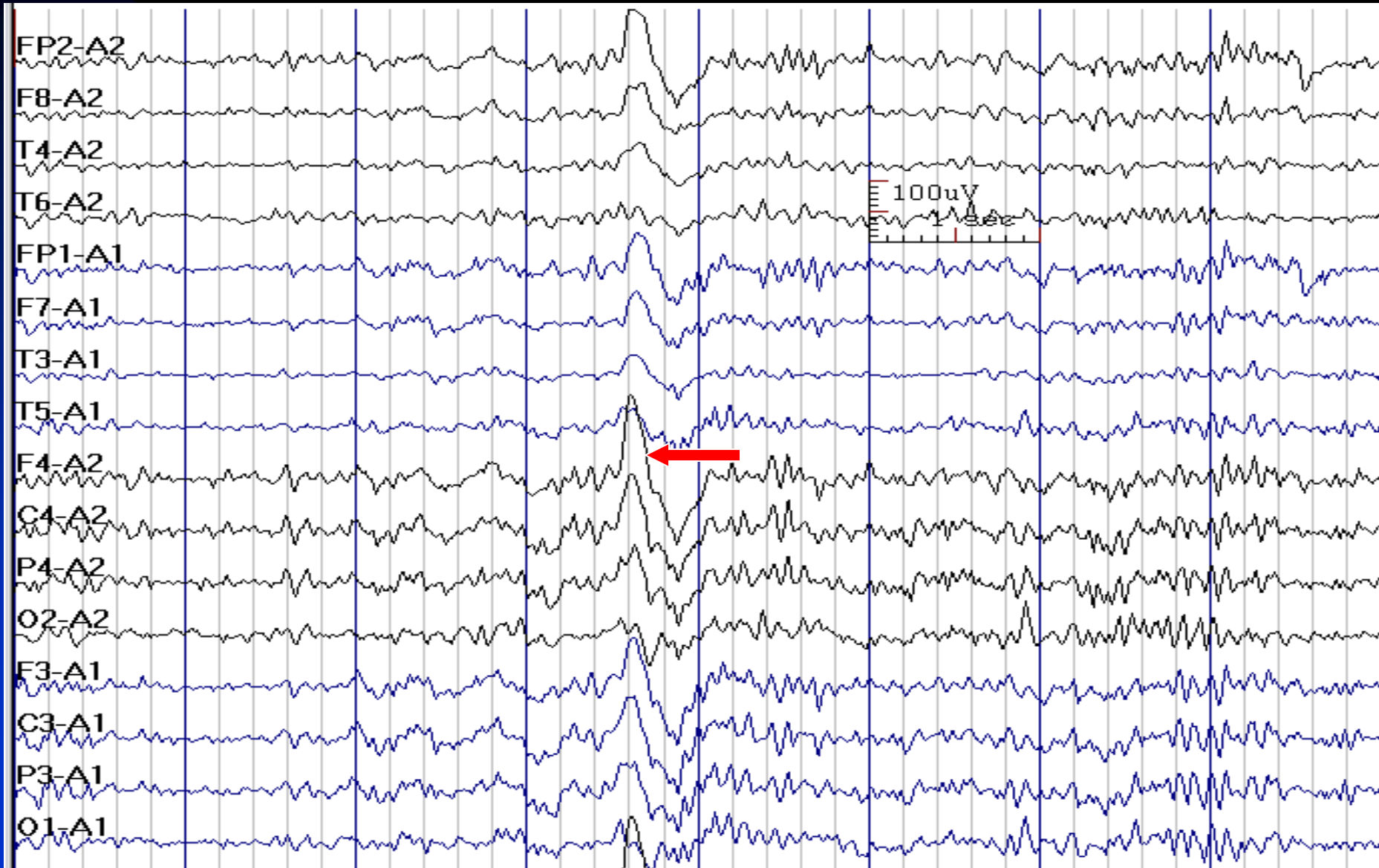
# K-Complex



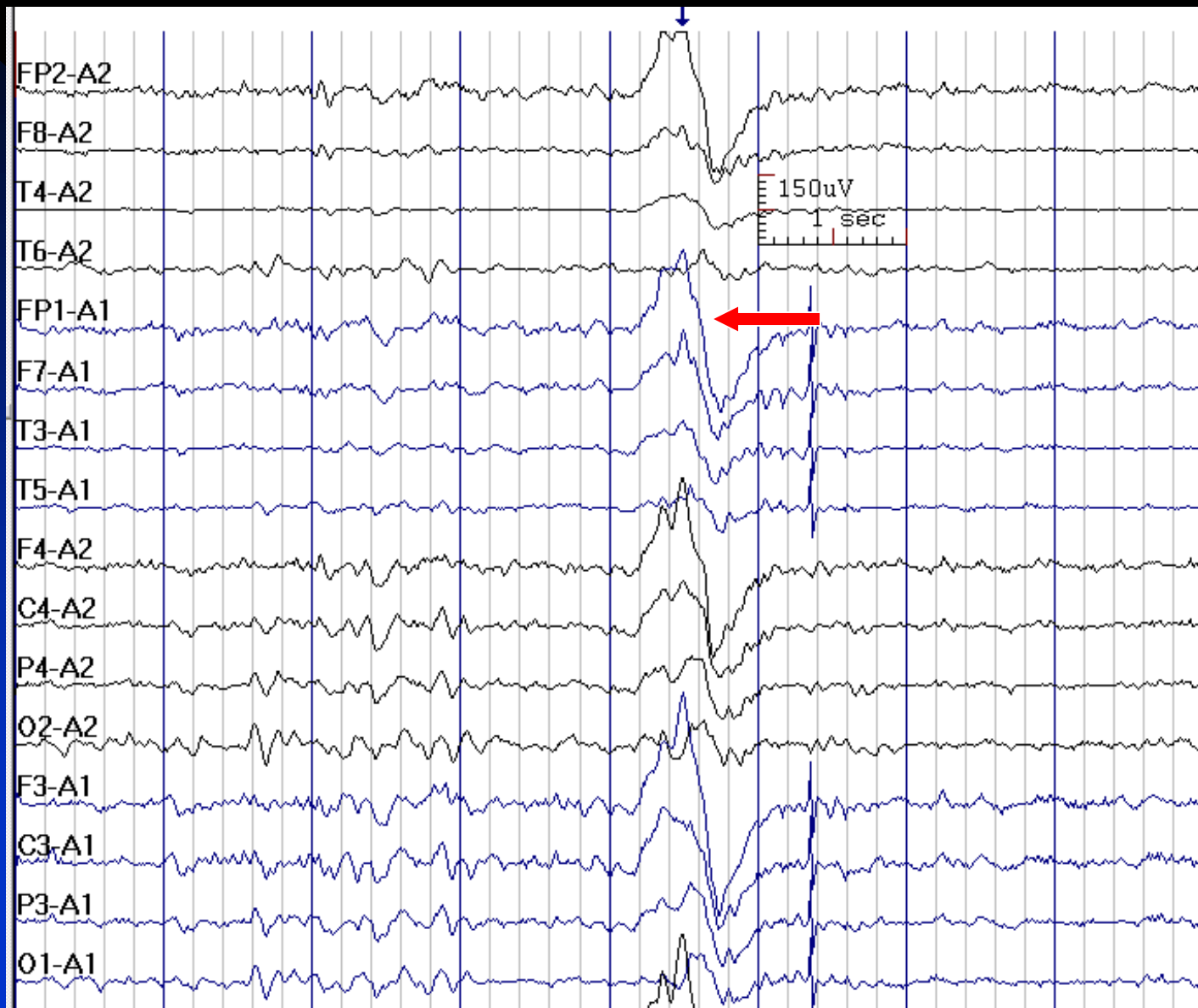
see the next slide in reference montage



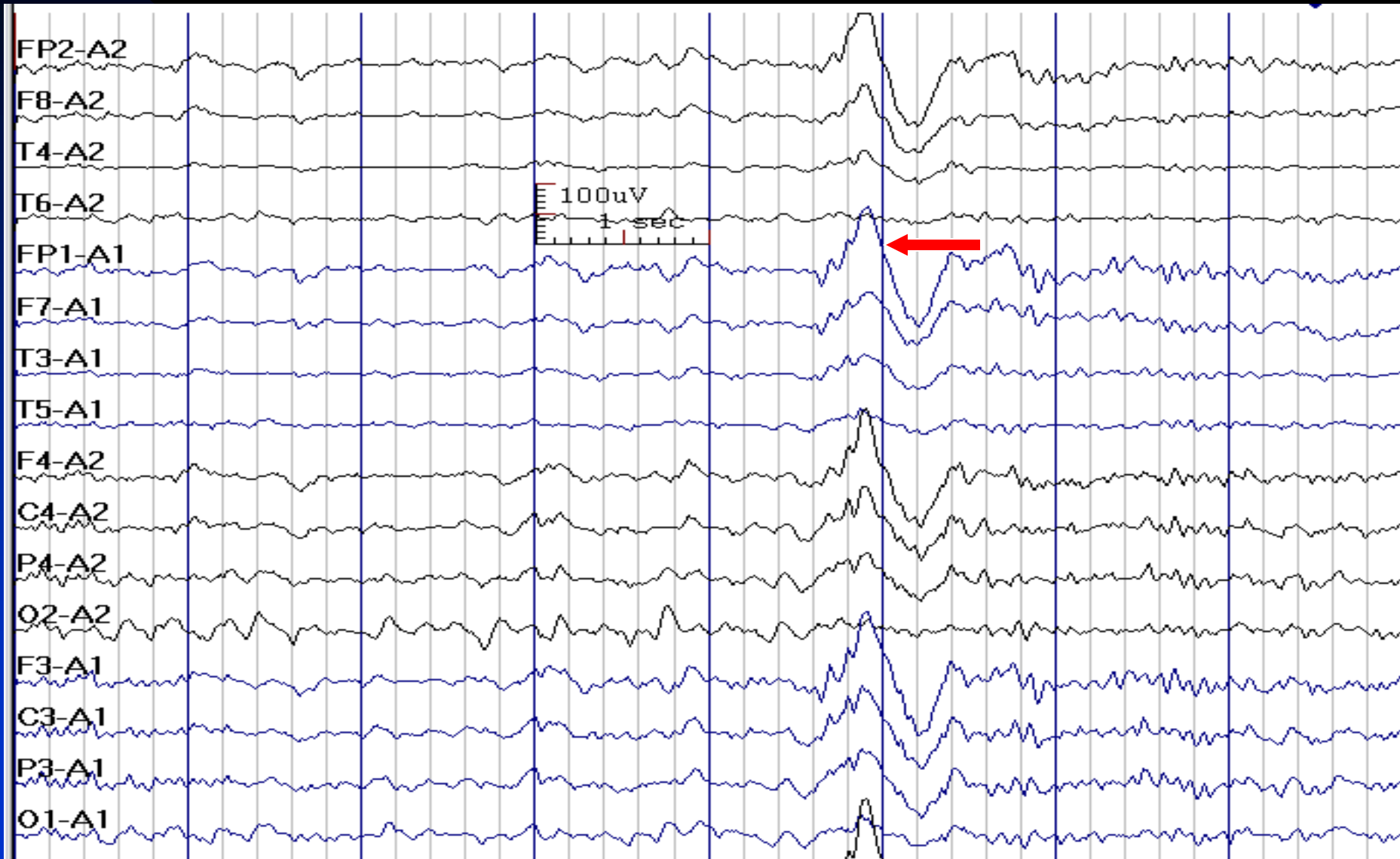
# K-Complex in Reference Montage (Ipsilateral Ear)



# K-Complex in Reference Montage



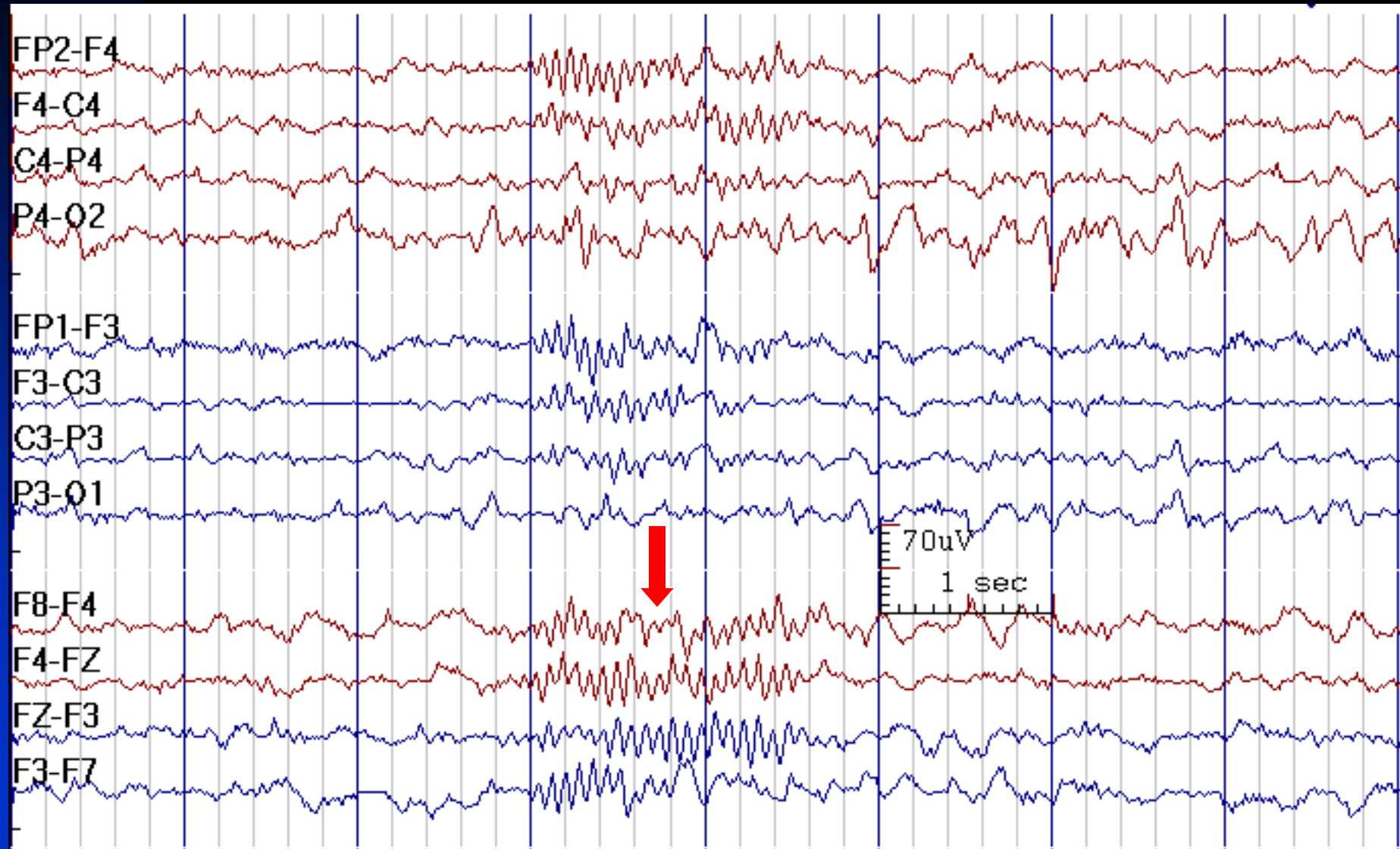
# K-Complex in Reference Montage



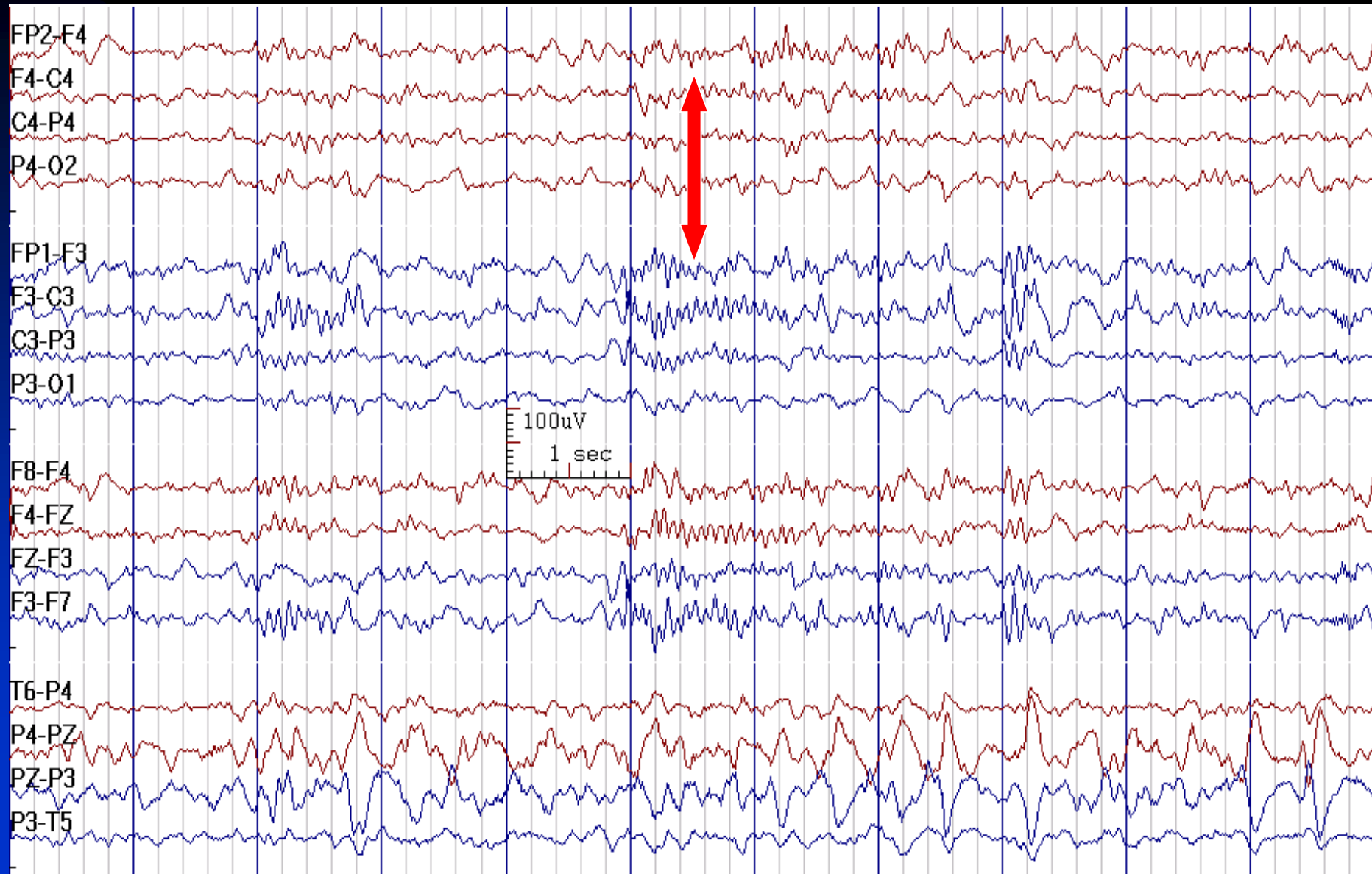
# Sleep Spindles

- **Activity:** 12-15 Hz, rhythmic (may be 10-12 Hz frontally)
- **Distribution:** bilateral central (C3, C4) regions
- **Duration:** 1 sec trains at 5-15 sec intervals. Spindle length is greater at ages 3-9 months than later
- **Characteristics:** bilaterally symmetric and synchronous after 2 years of age
- **State:** stages 2 & 3 of sleep
- **Ontogeny:** appear at 6-8 weeks post term with prolonged comb-like morphology, initially asynchronous, becoming increasingly more synchronous during the first year of life; rare in second year of life; appear in mature form at age 2

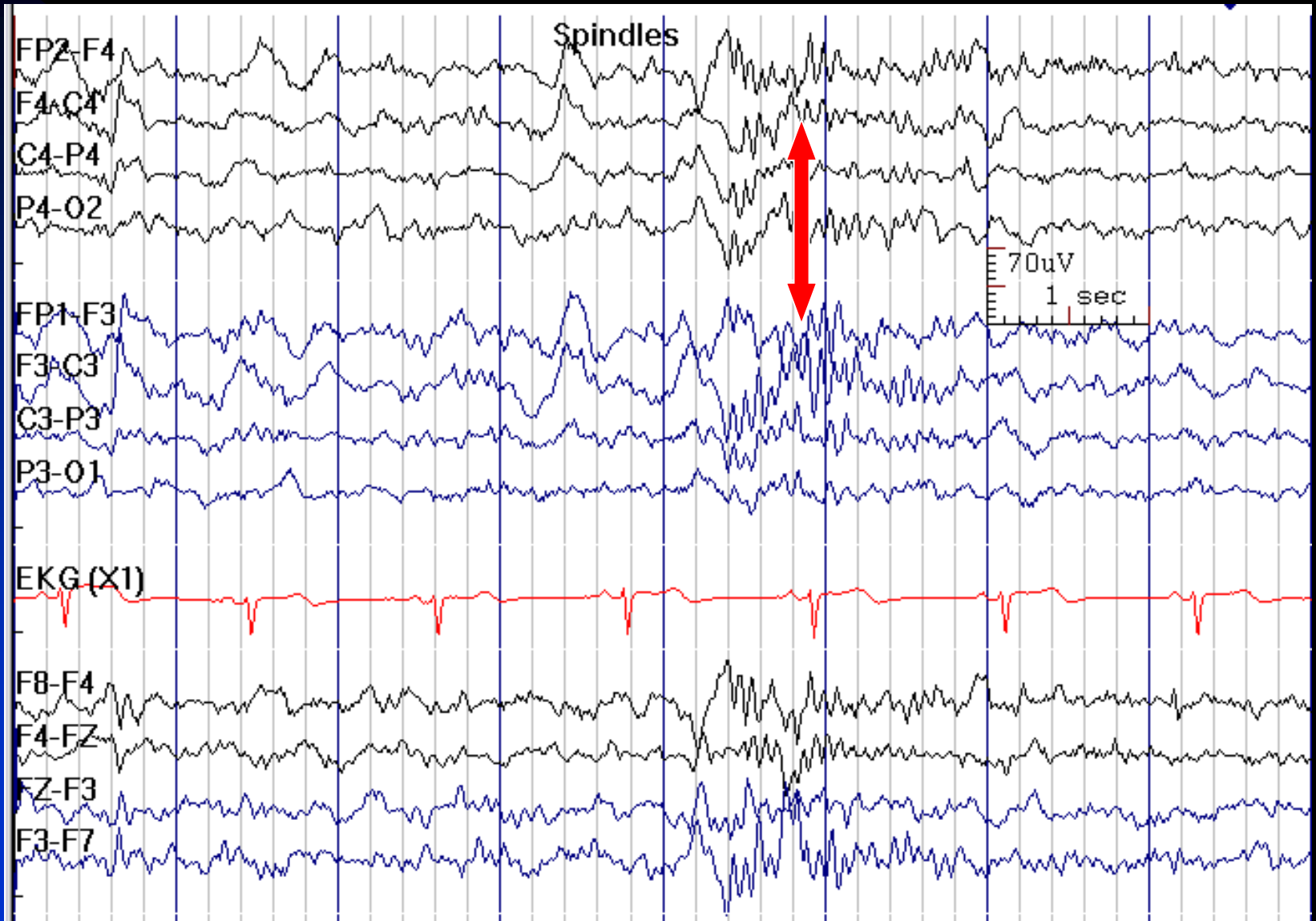
# Sleep Spindles



# Sleep Spindles

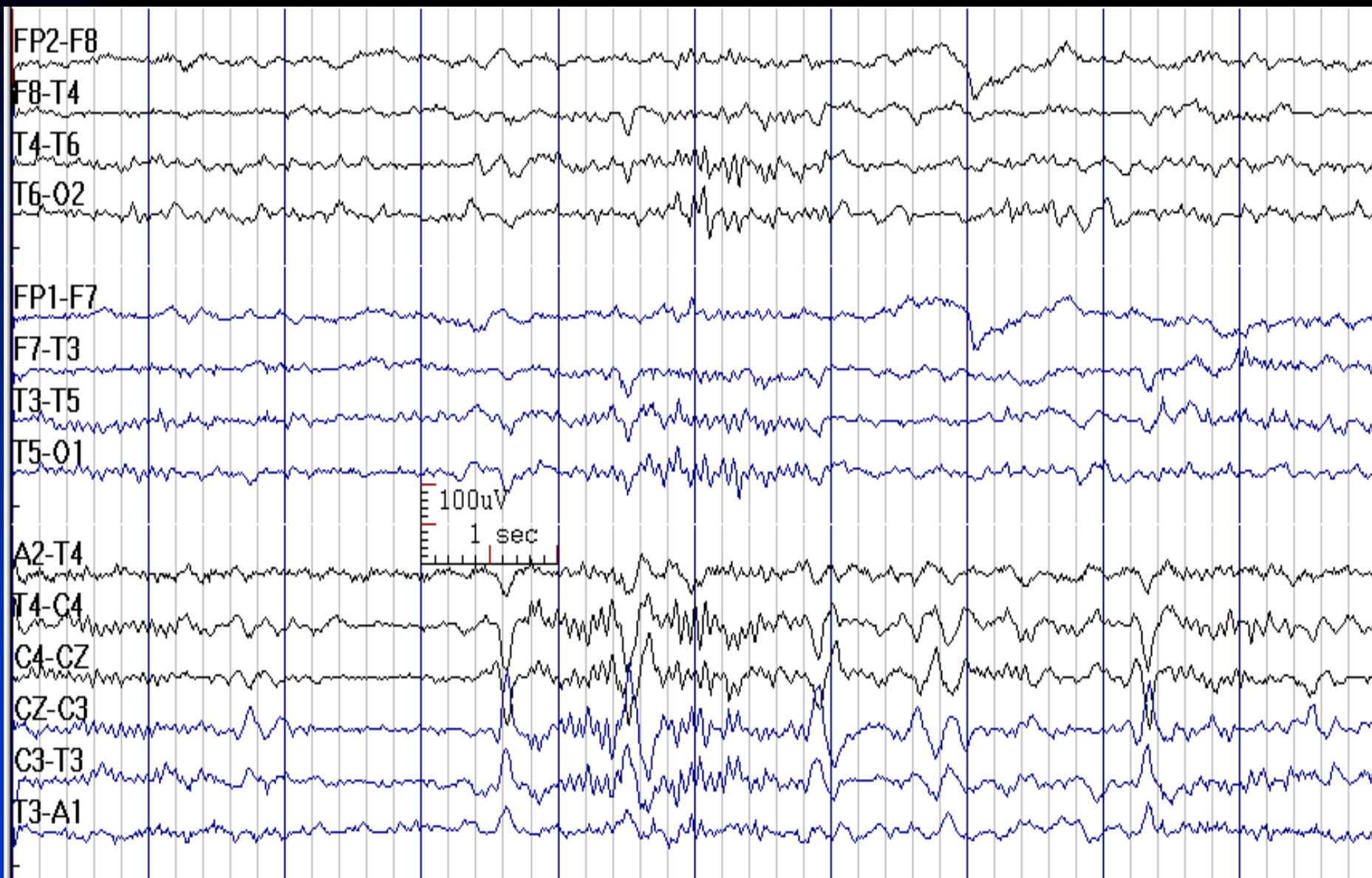


# Sleep Spindles



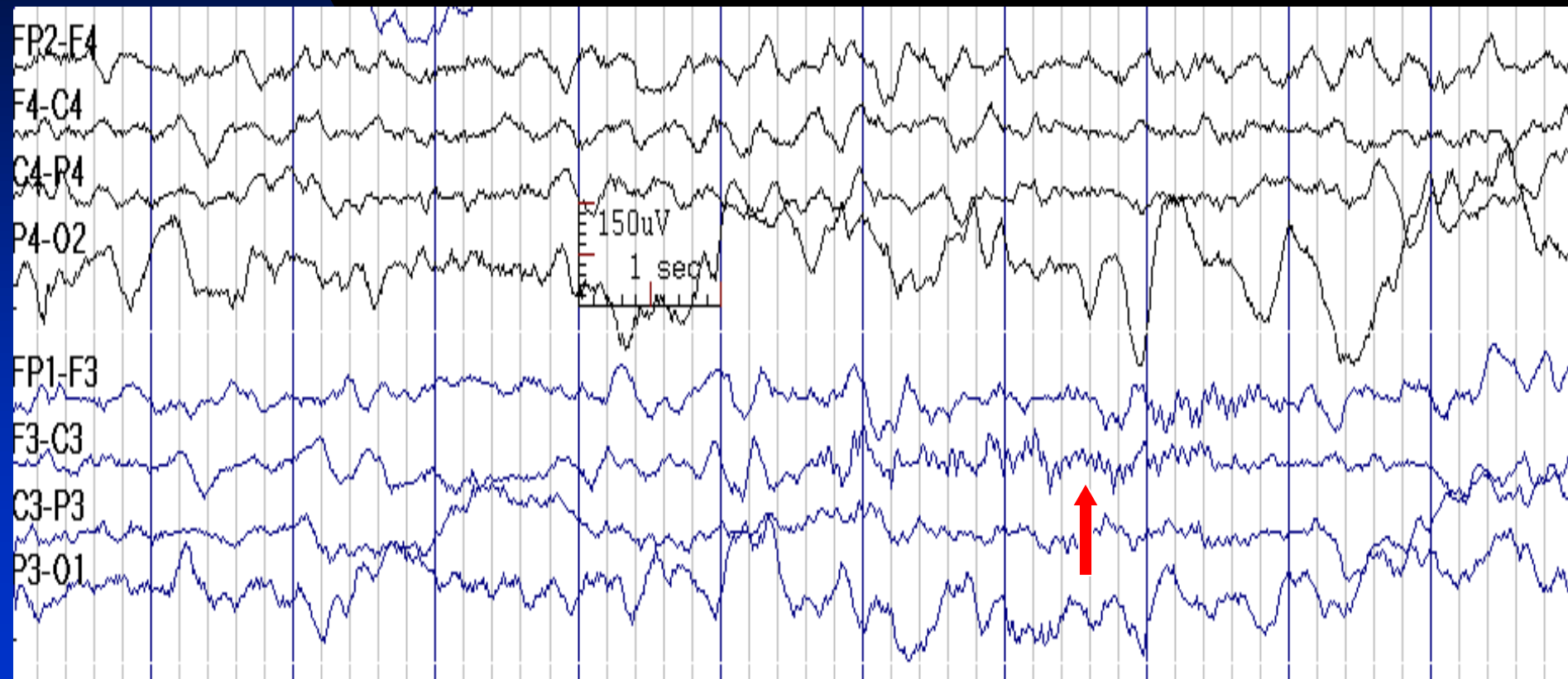


# Sleep Spindles

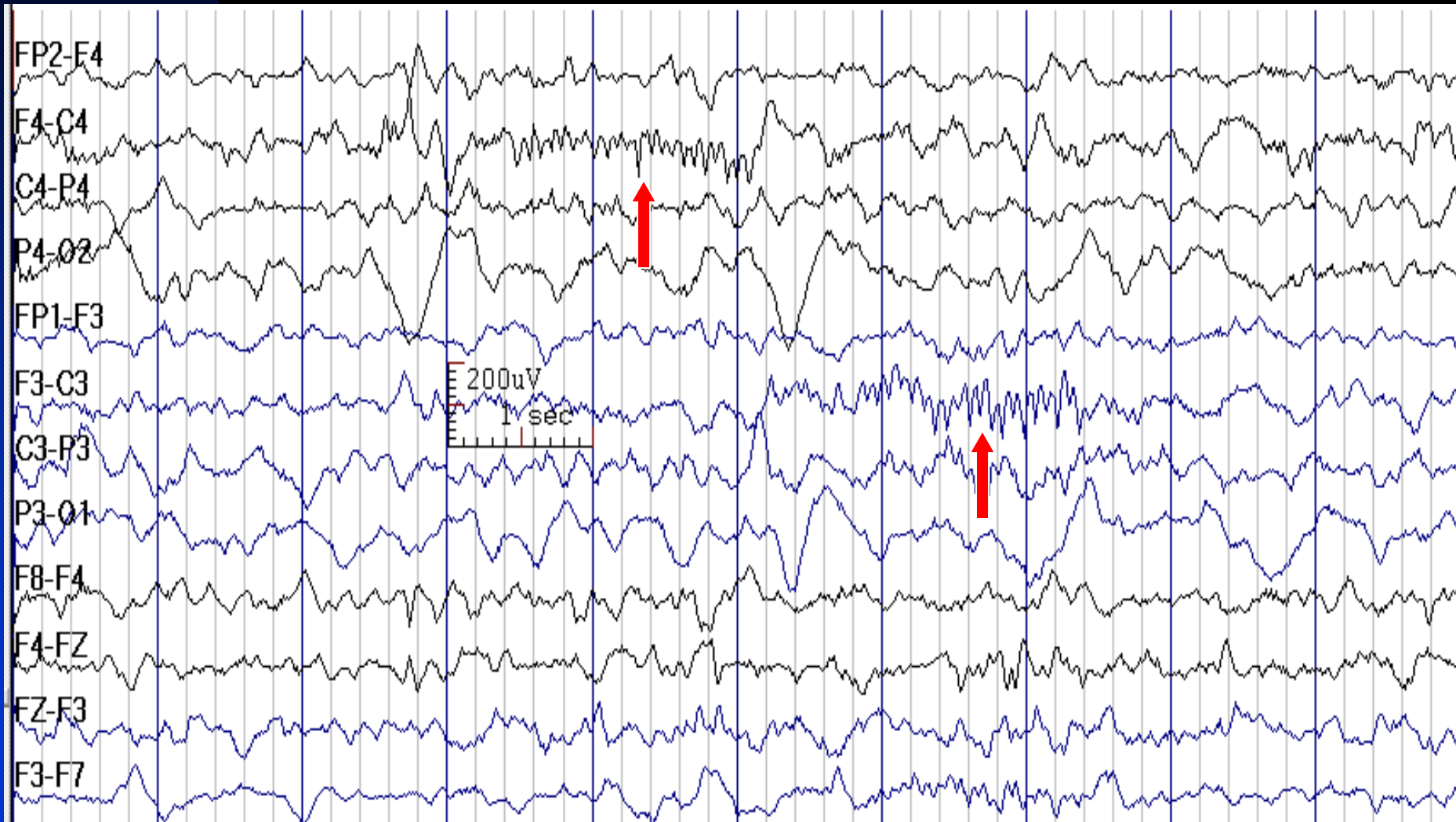




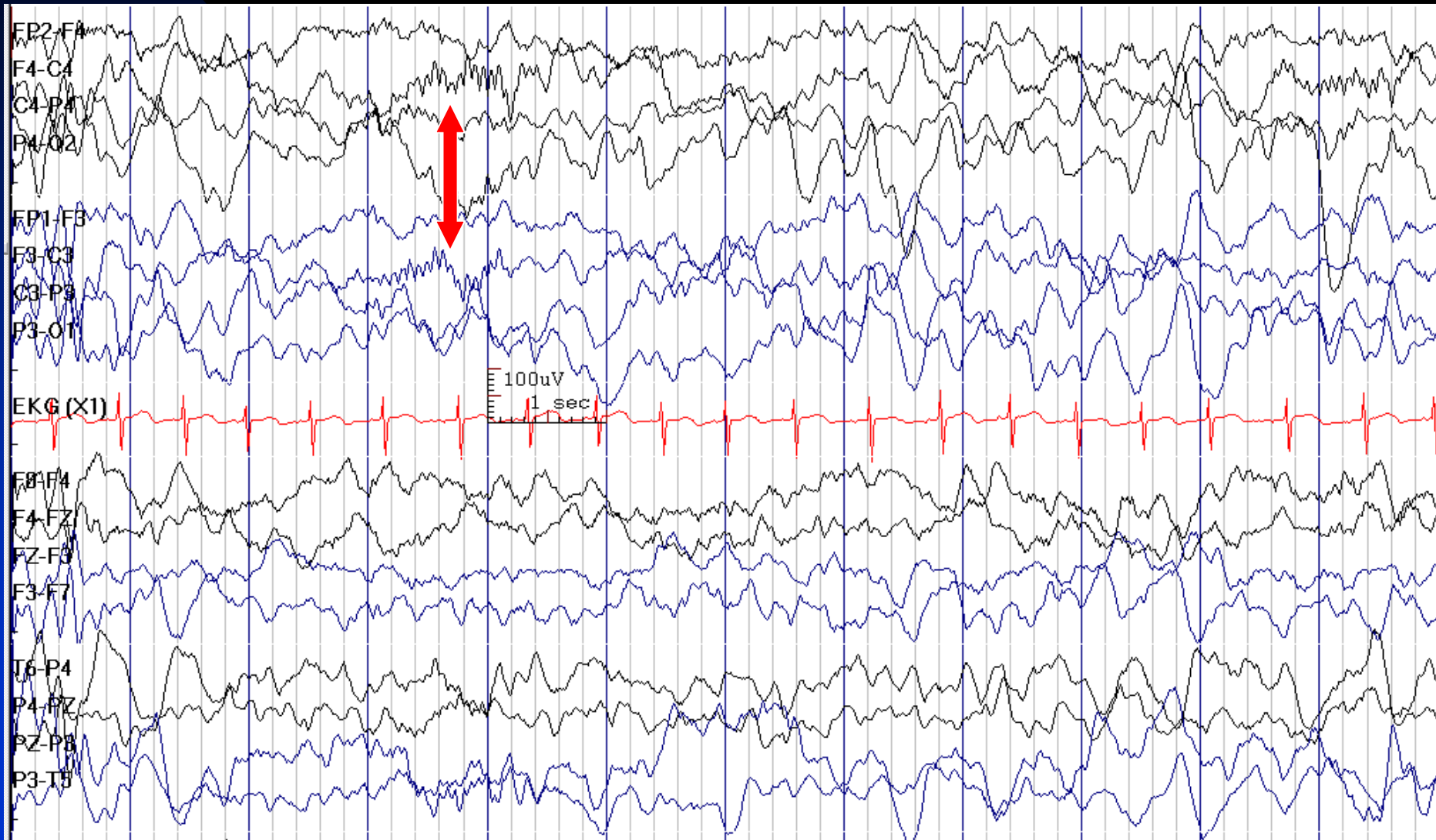
# Unilateral Sleep Spindles in a 6-Month-Old Boy



# Bilateral Asynchronous Sleep Spindles in a 7-Month-Old Girl



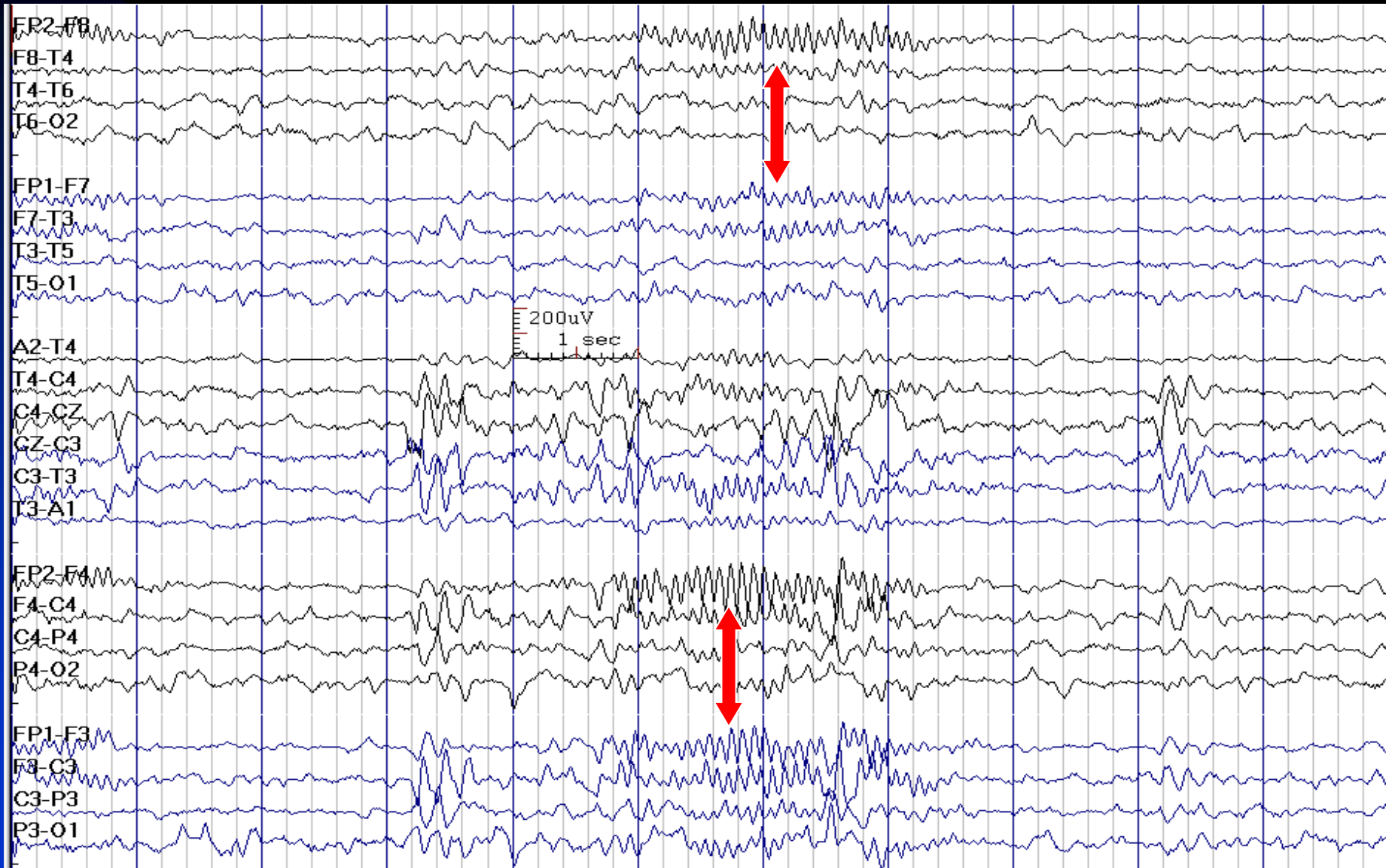
# Bilateral Synchronous Sleep Spindles in a 2-Year-Old Boy



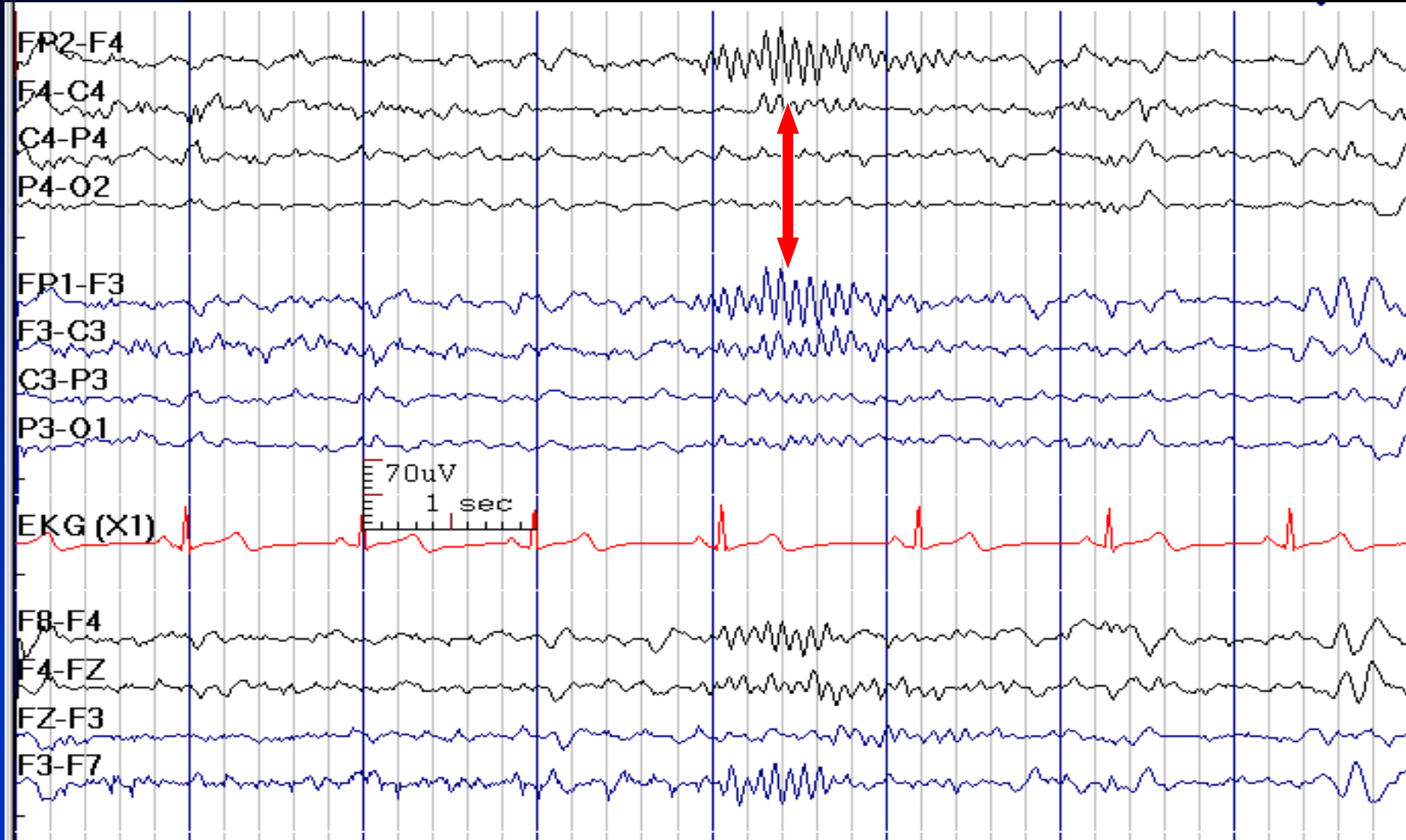
# Frontal Spindles

- **Activity:** 12-15 Hz in stage 2; 10-12 Hz in stage 3
- **Distribution:** frontal regions, bilateral
- **Duration:** less than 3 seconds
- Occurs in 5% of normal children and adults

# Frontal Sleep Spindles



# Frontal Sleep Spindles

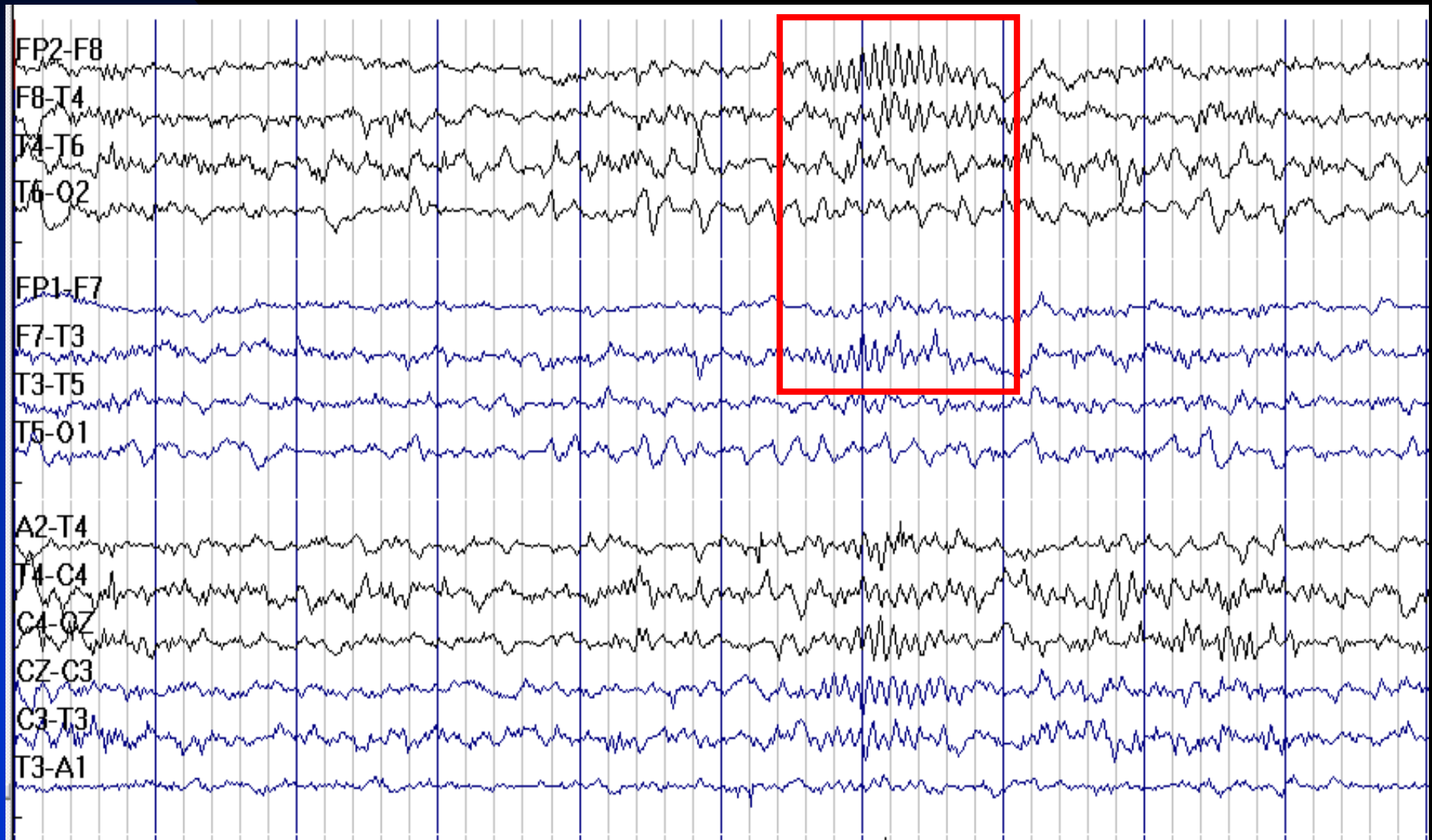


# Abnormal Sleep Spindles

- **Asynchrony:** after the age of 2 years is abnormal
- **Unilateral slowing:** ipsilateral hemispheric lesion
- **Asymmetry:** consistent voltage difference of more than 30% suggests an abnormality on the low voltage side or skull defect over the high voltage side

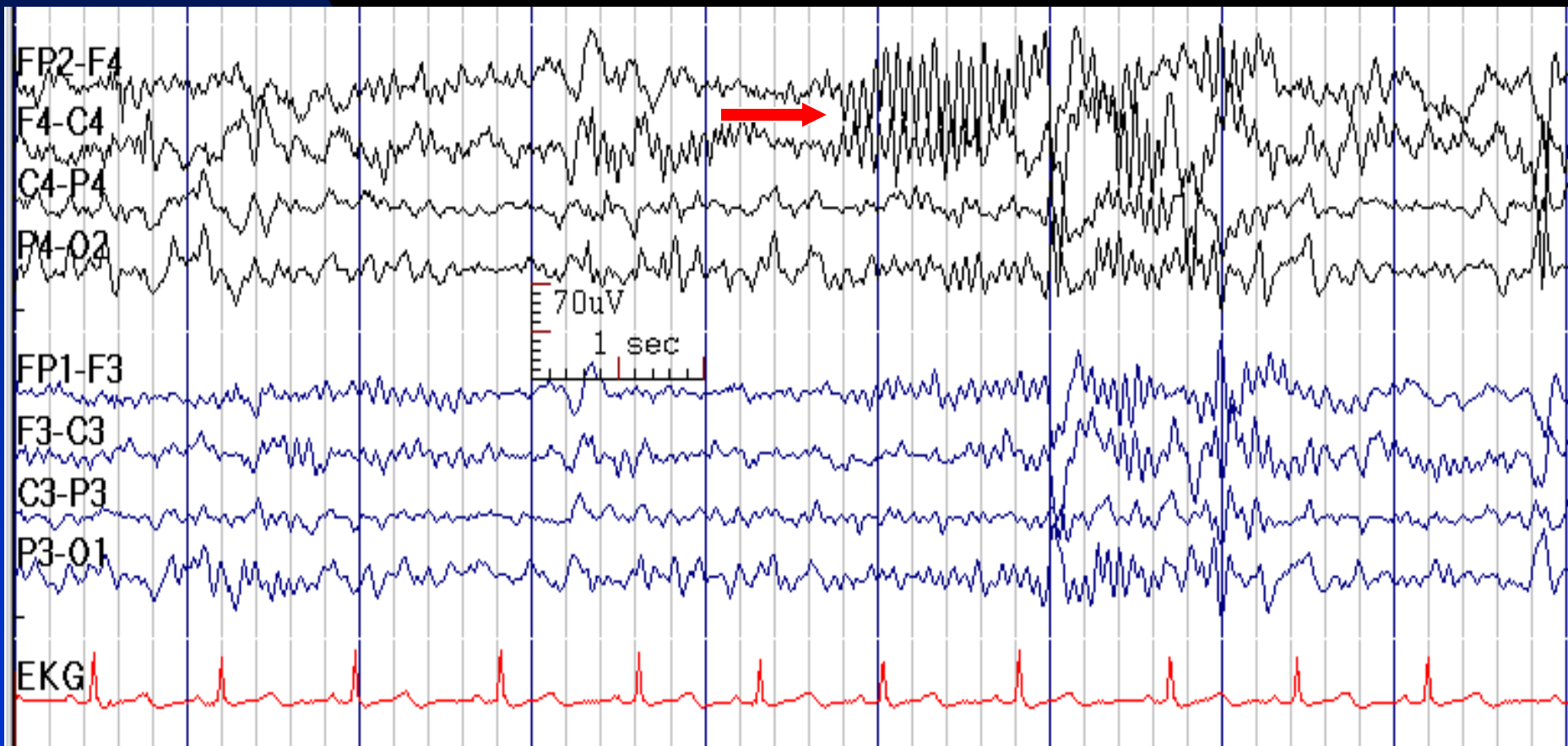


# Sleep Spindles are Higher in Amplitude in the Right Frontal Region due to Skull Defect (Breach Rhythm)

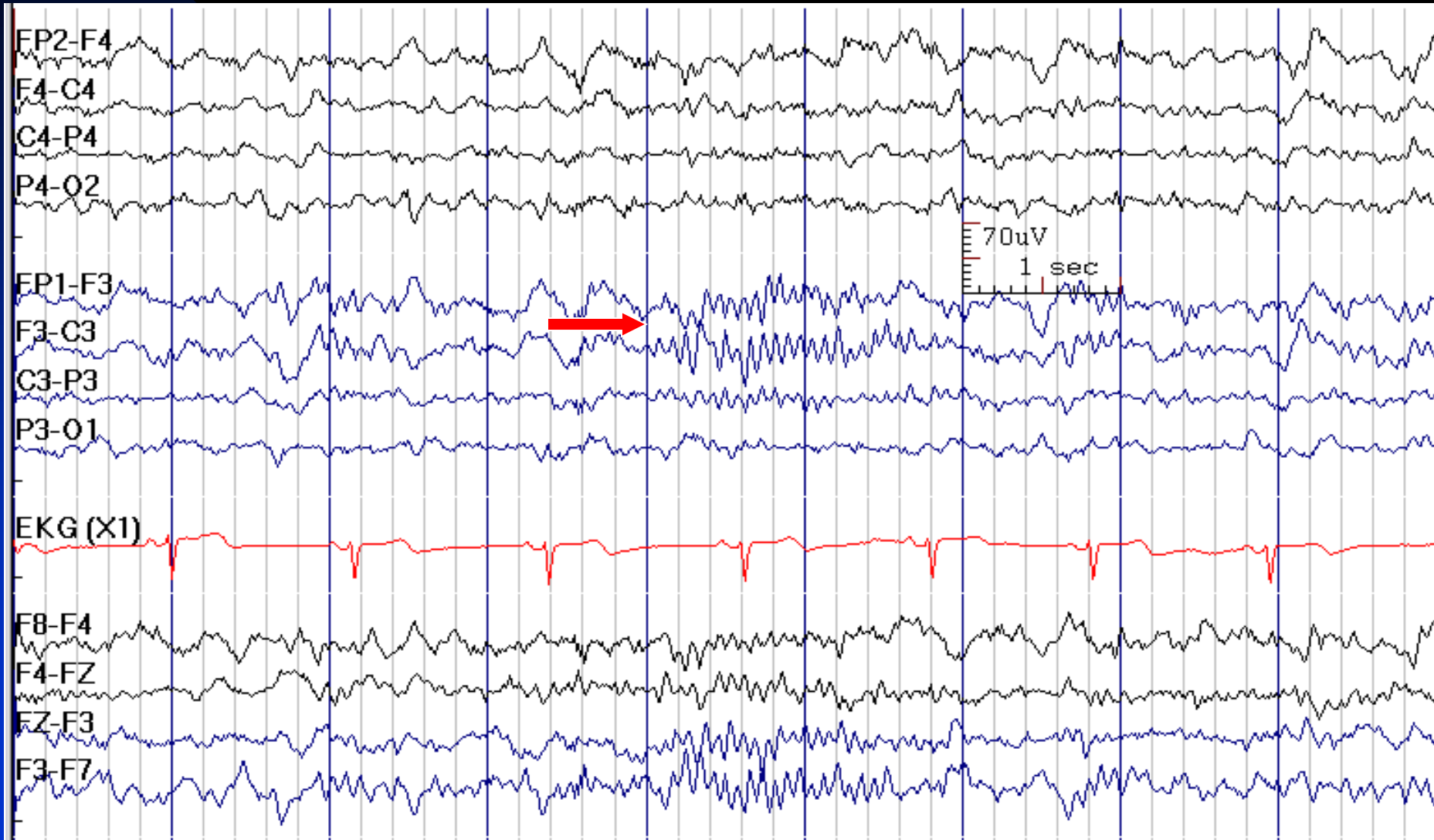




# Sleep Spindles are Higher in Amplitude in the Right Frontal Region due to Skull Defect



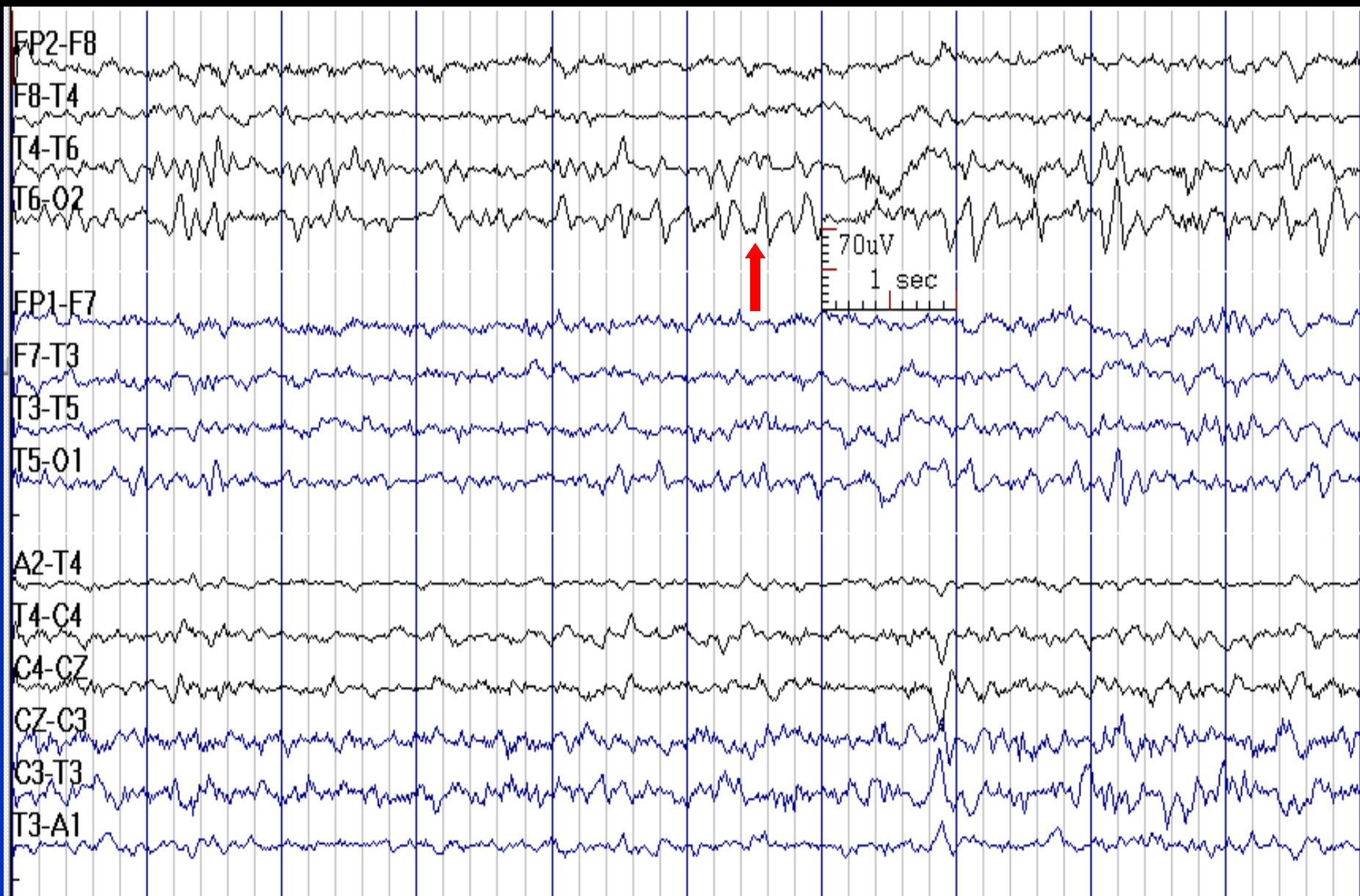
# Sleep Spindles are Higher in Amplitude in the Left Frontal Region due to Skull Defect



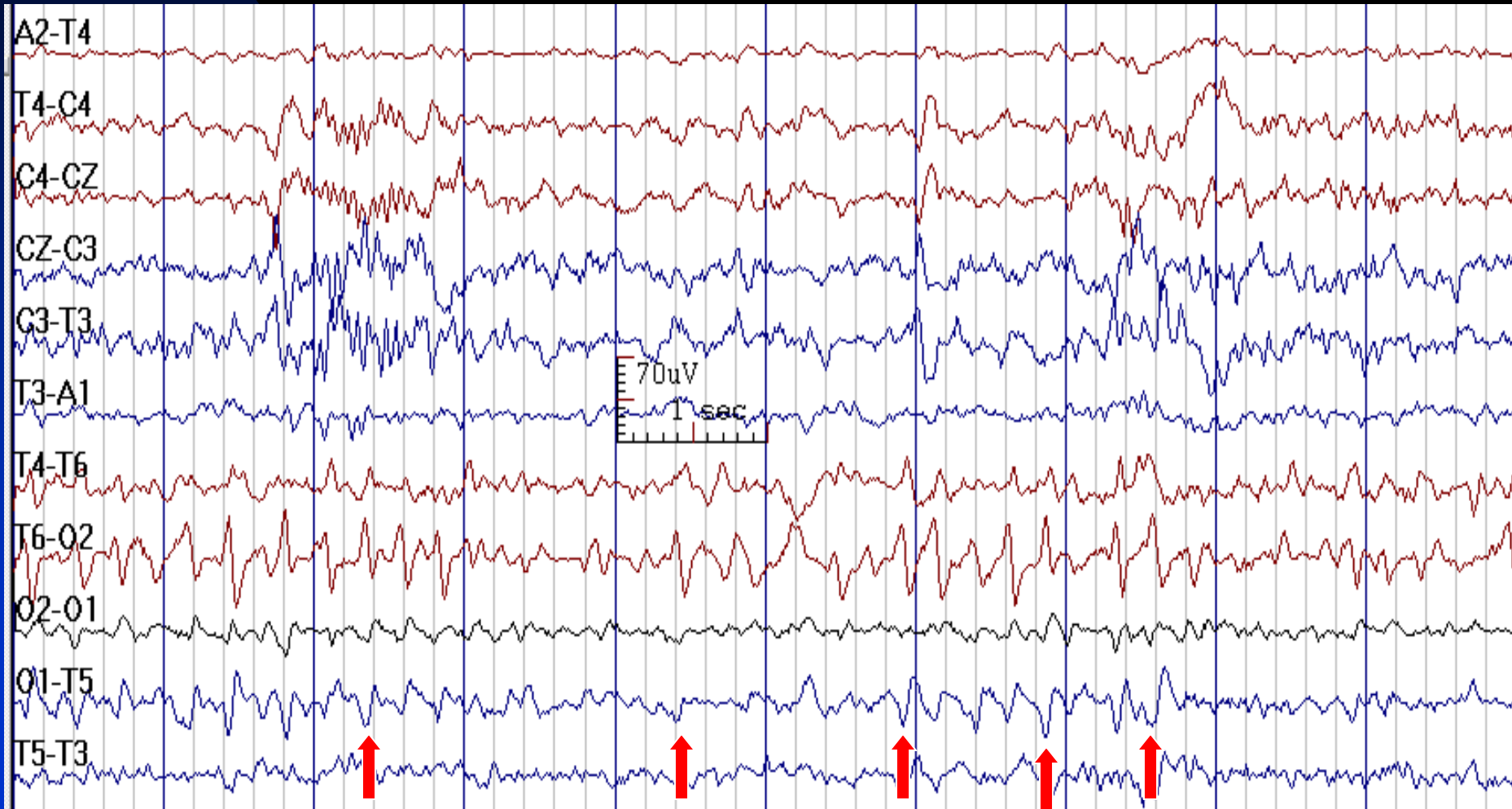
# Positive Occipital Sharp Transients of Sleep (POSTS)

- **Activity:** occurs singly or in trains, positive in occipital regions
- **State:** sleep stages 1 & 2
- **Distribution:** bioccipital, but asymmetrical (up to 60%), often with posterior temporal field spread
- **Amplitude:** 20-70  $\mu\text{V}$
- **Characteristics:** sharply-contoured, monophasic, and surface positive.  
The initial deflection has a slower time course than the ascending phase (check mark like shape)

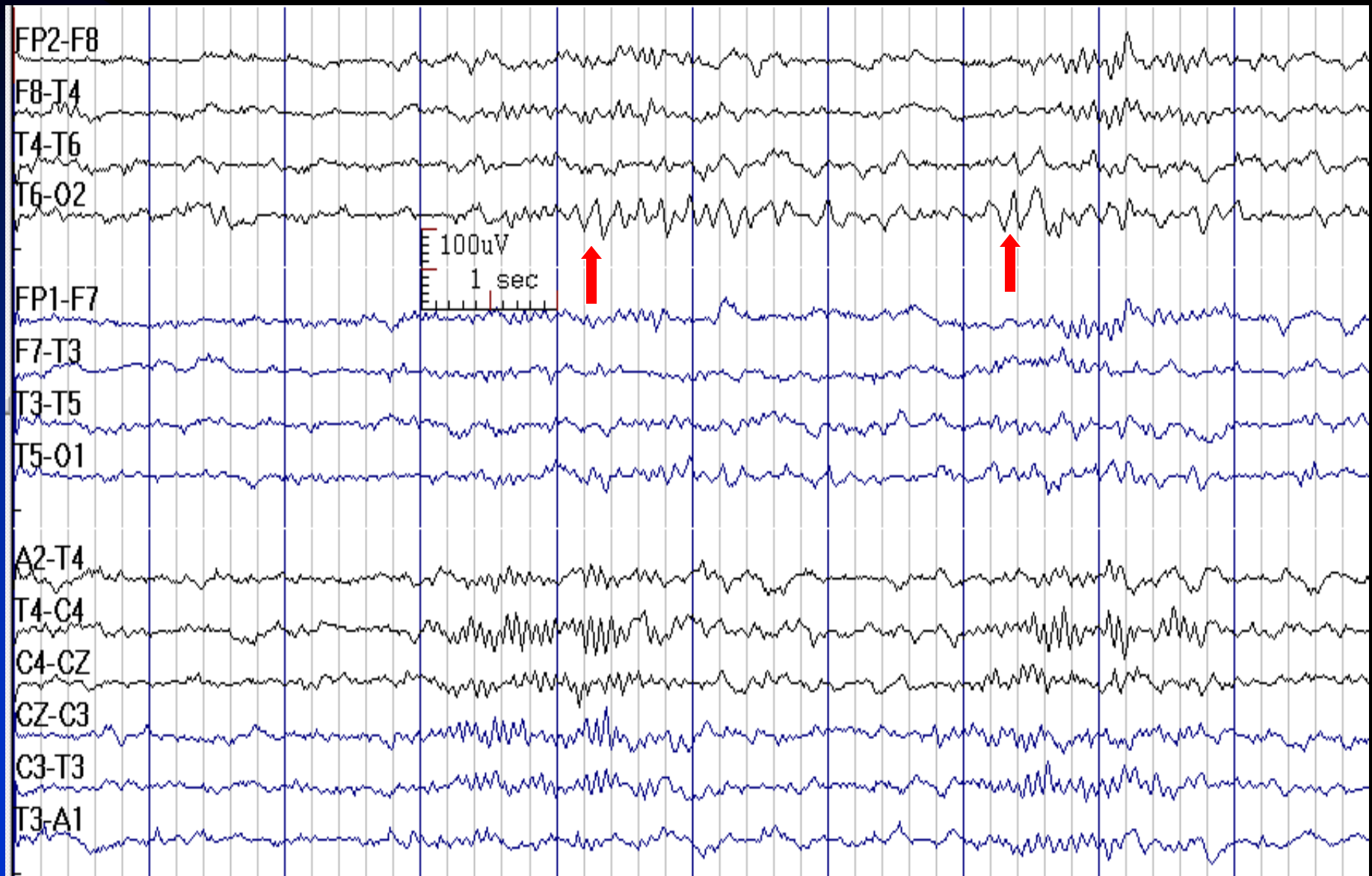
# POSTS



# POSTS (Circular Bipolar Montage)



# POSTS in Stage 2 Sleep

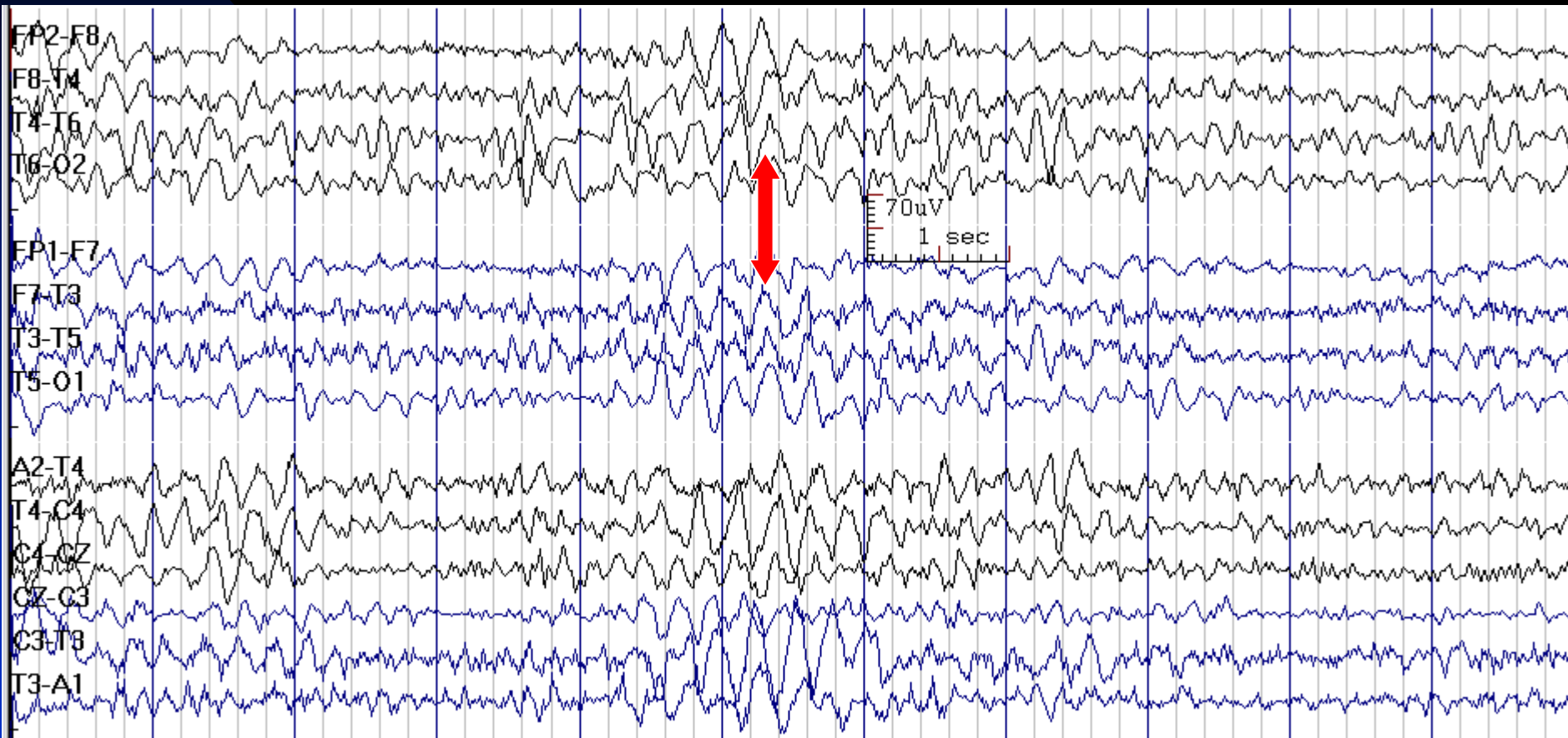


# Hypnagogic Hypersynchrony

- **Activity:** high amplitude sinusoidal theta-delta activity with occasional notching (specially in youth)
- **State:** at wake-sleep transition
- **Distribution:** generalized, maximum fronto-central
- **Characteristics:** synchronous and rhythmic

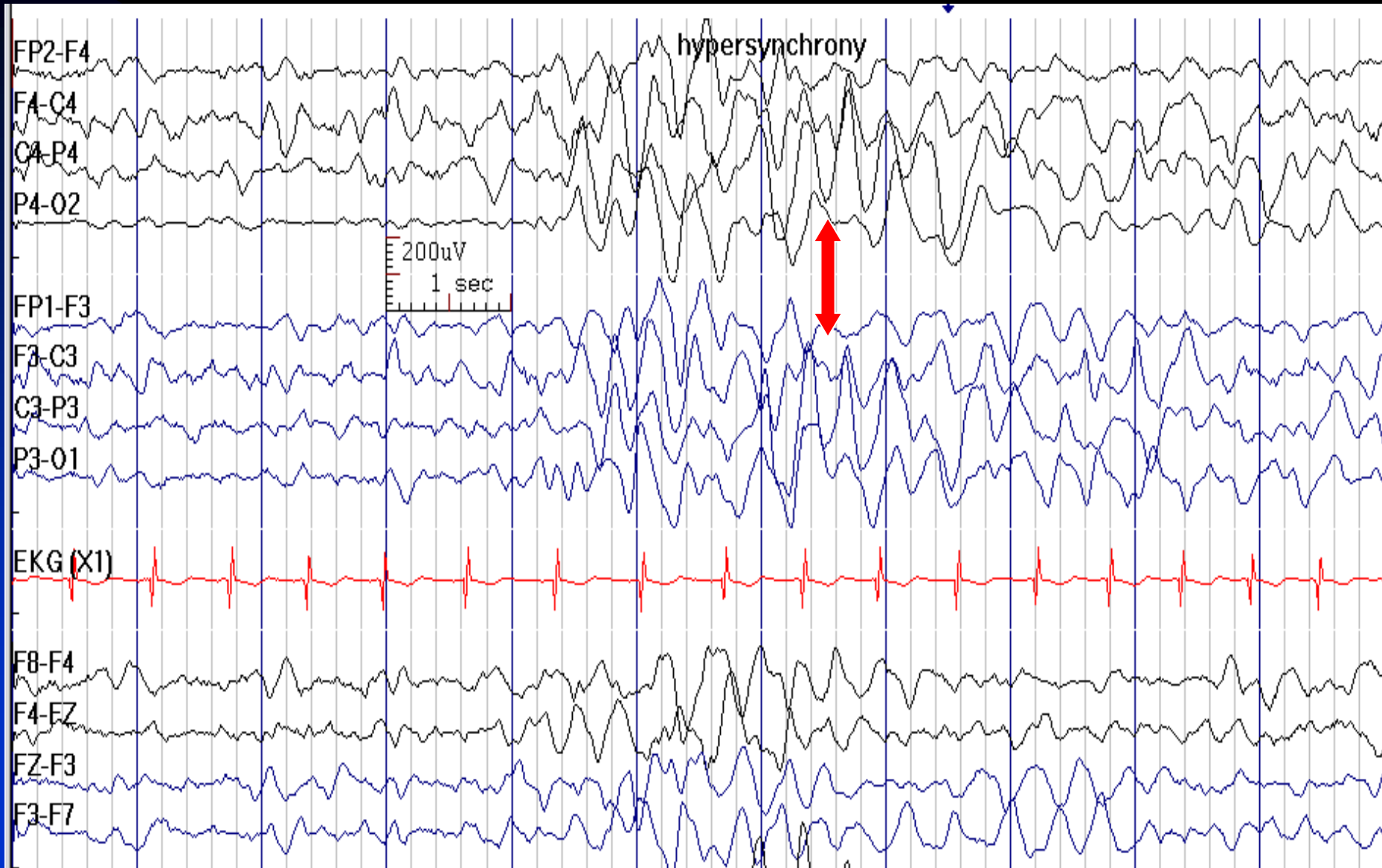


# Hypnagogic Hypersynchrony in a 10-Year-Old Boy





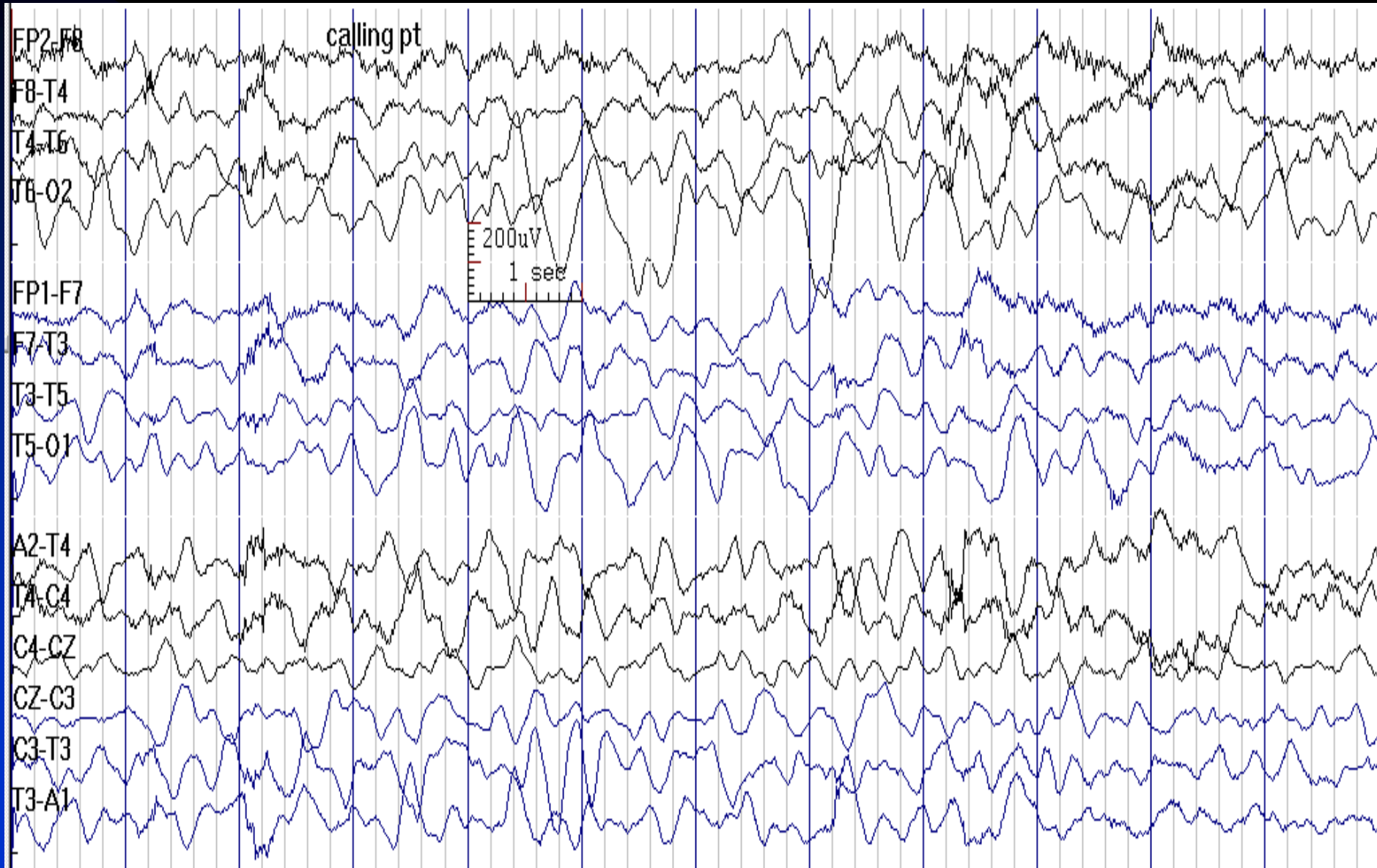
# Hypnagogic Hypersynchrony in a 25-Year-Old Man



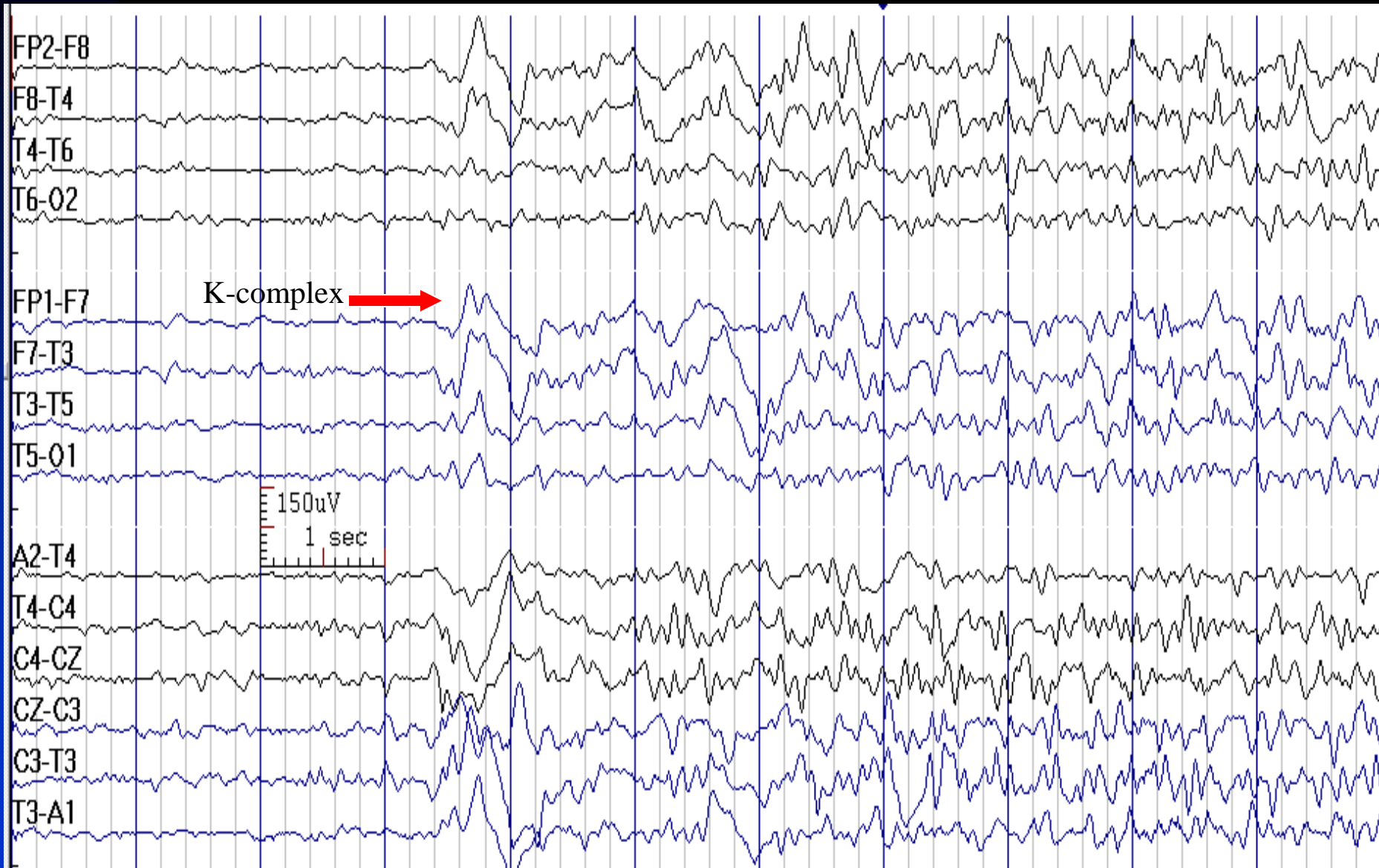
# Arousal

- **First phase:** change in the background frequencies
- **Second phase:** generalized rhythmic monomorphic delta activity frontally and less rhythmic activity posteriorly, perhaps with muscle and movement artifact (hypnopompic hypersynchrony)
- **Last phase:** posterior semirhythmic delta activity
- Arousal may be aborted at any of these phases, with a reversion to sleep

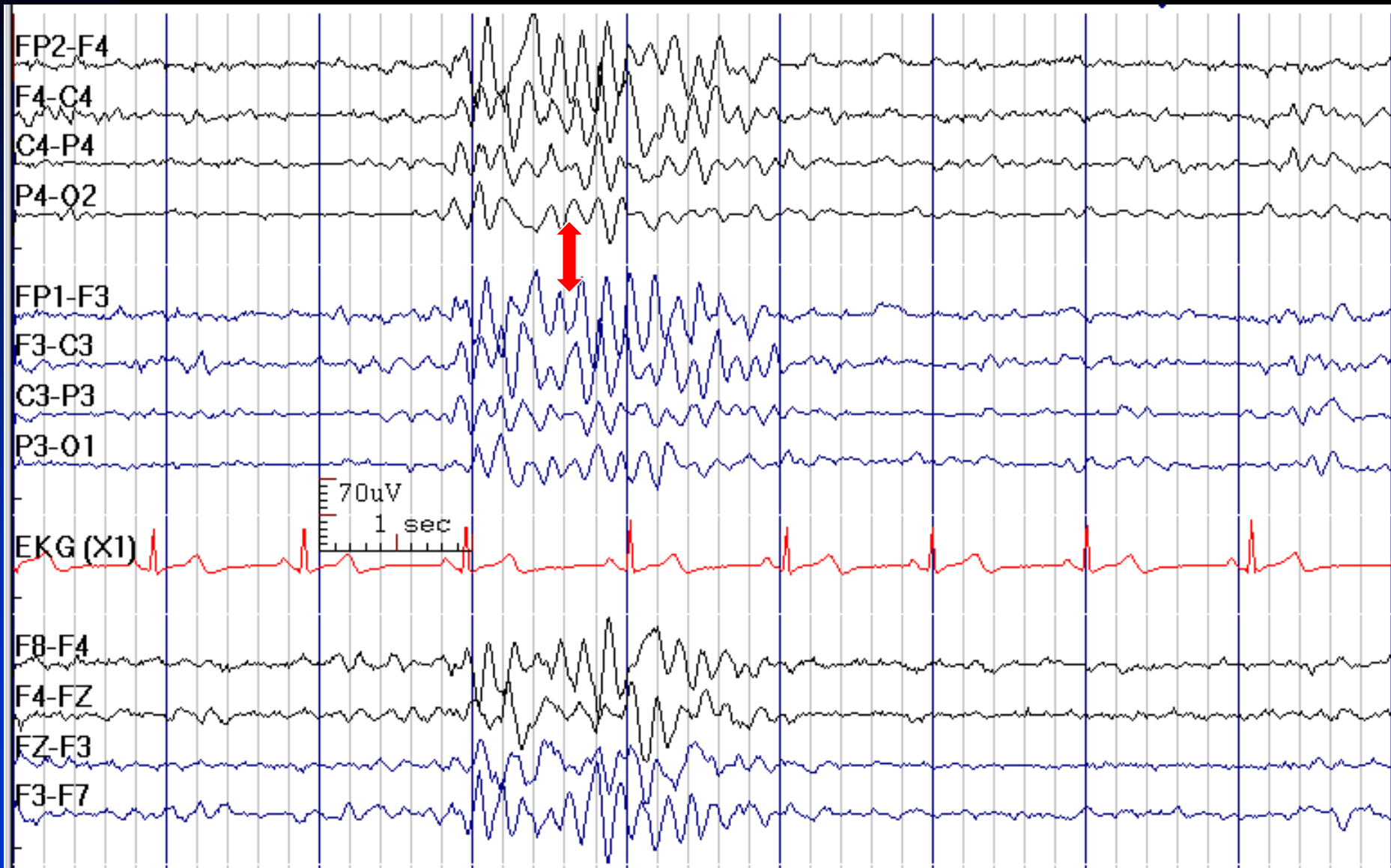
# Arousal in a 2-Year-Old Boy



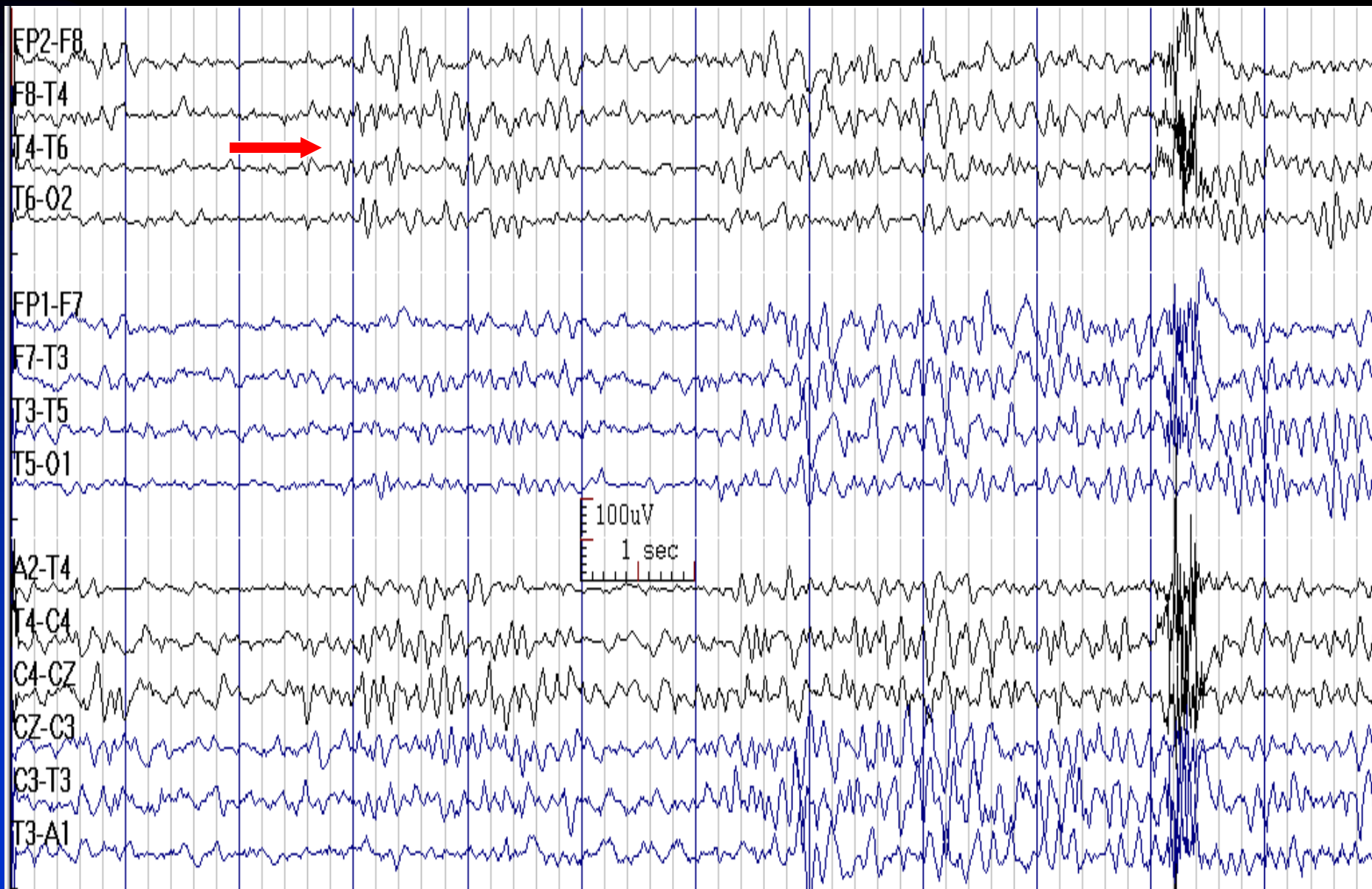
# K-complex and then Hypnopompic Hypersynchrony



# Hypnopompic Hypersynchrony in a 15-Year-Old Boy



# Arousal



# **Chapter 4**

## **Activation Methods**

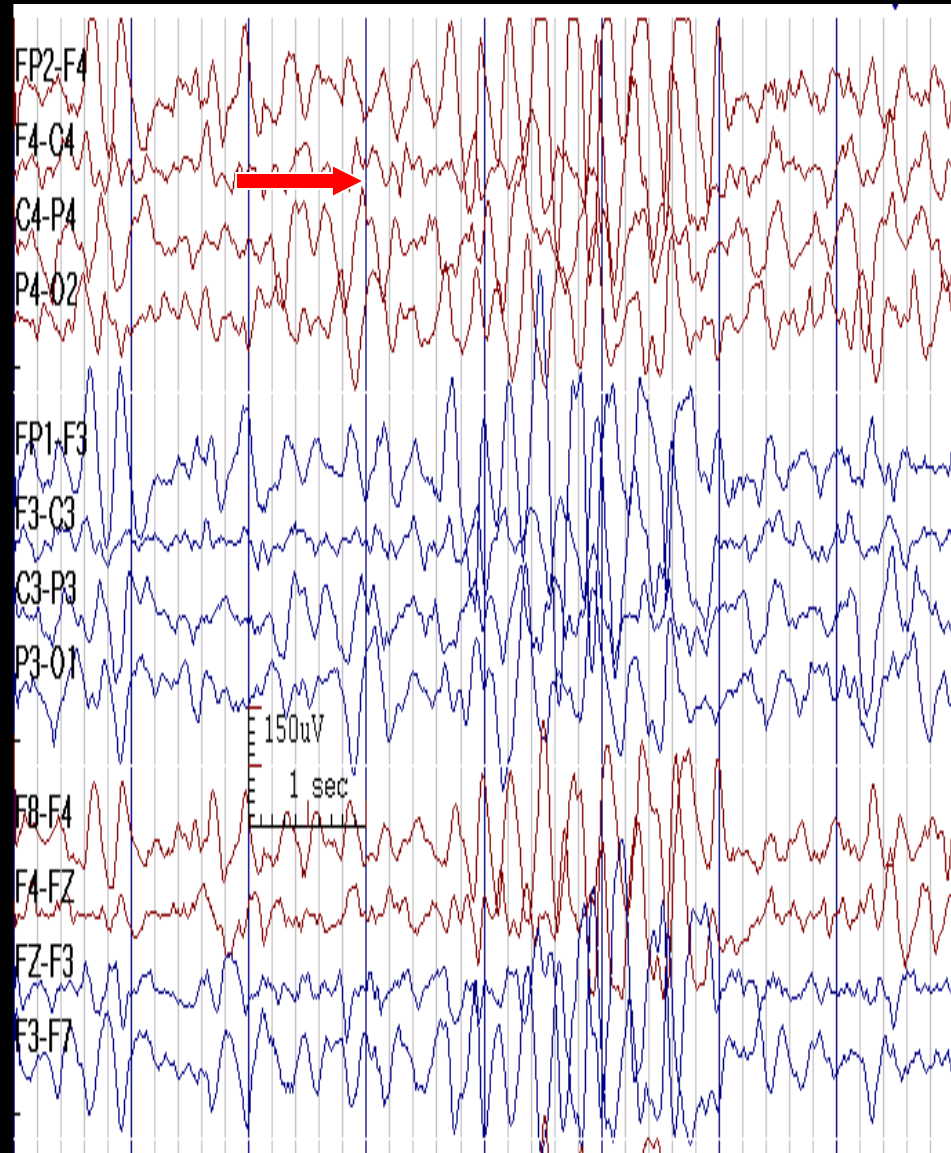
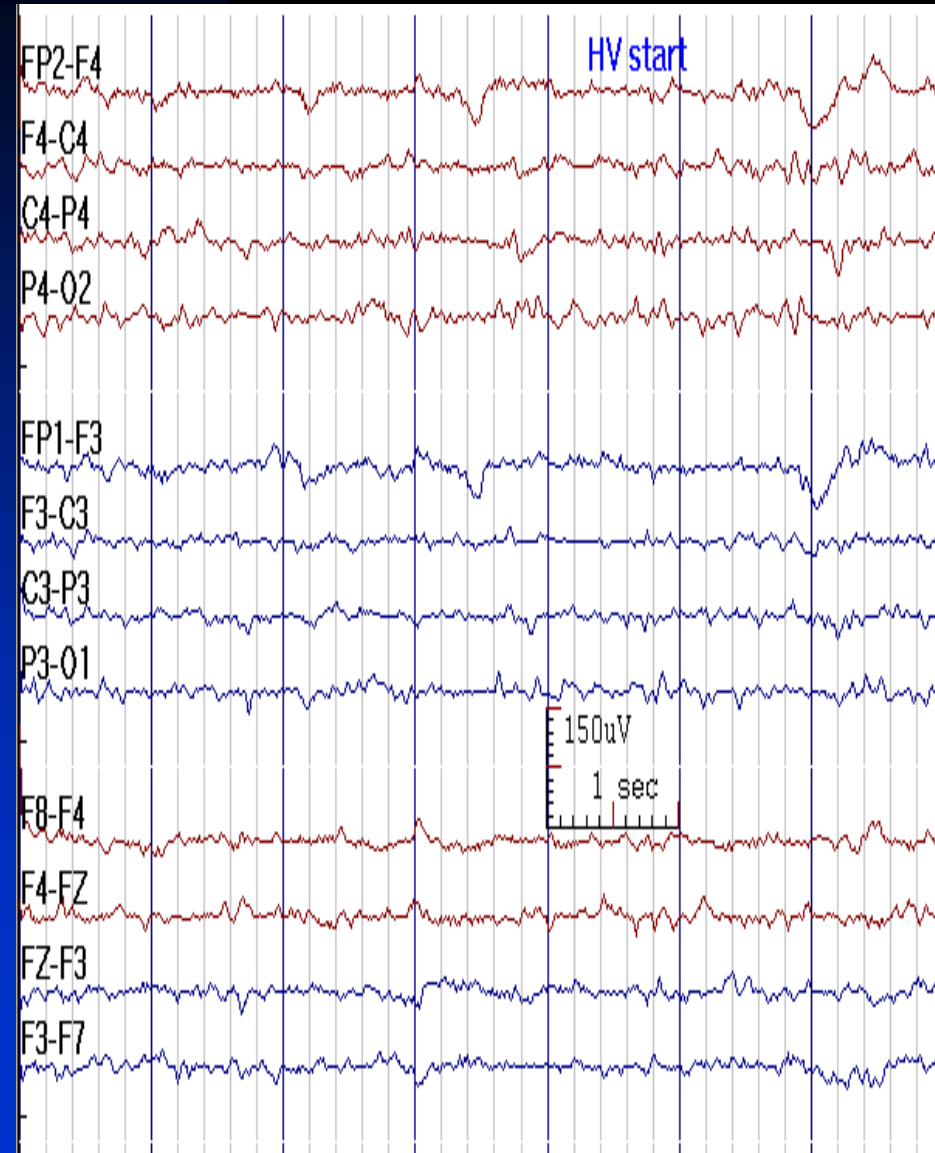
- **Definition:** any procedure designed to enhance or elicit normal or abnormal EEG activities, especially epileptiform abnormalities
- **Common activation methods:**
  - ◆ Hyperventilation (HV)
  - ◆ Photic stimulation
  - ◆ Sleep
  - ◆ Sleep deprivation



# Hyperventilation

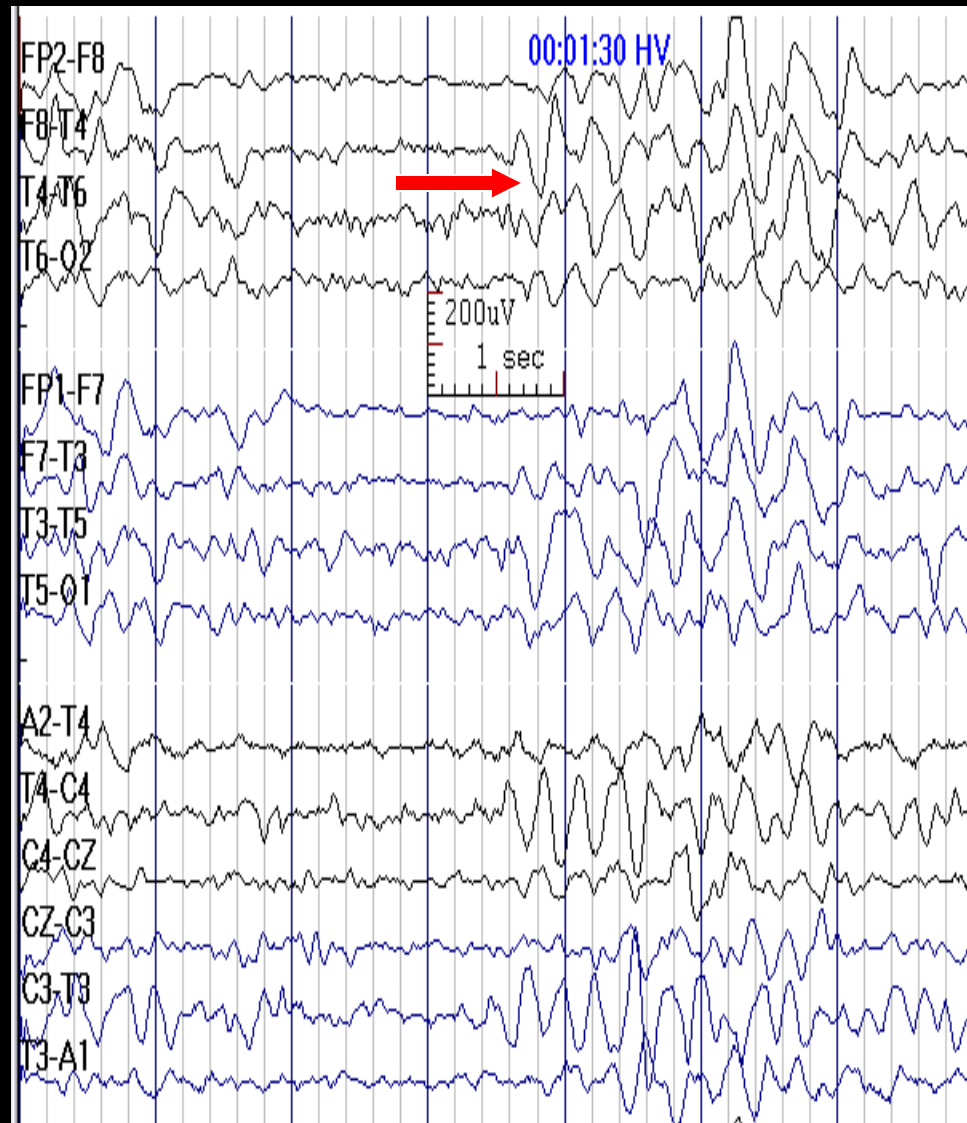
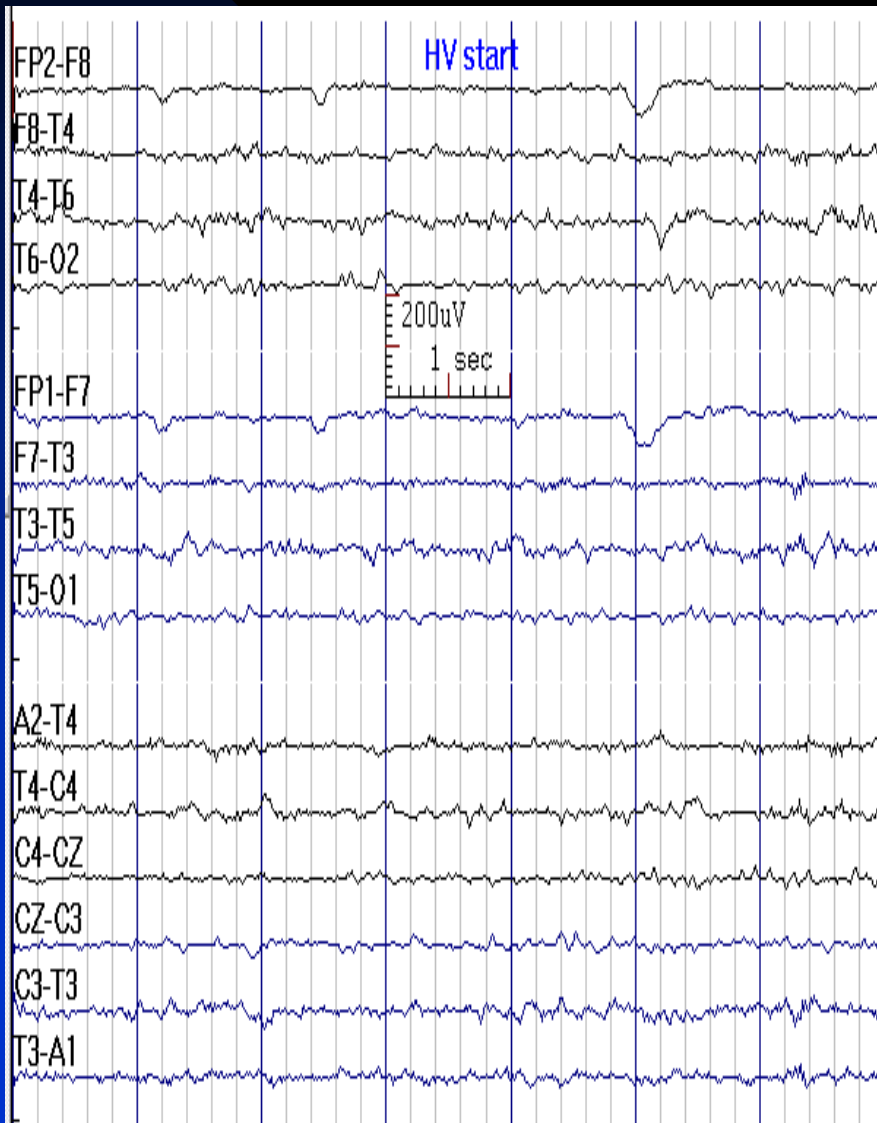
- Development of medium to high amplitude, bilaterally synchronous rhythmic theta-delta waves
- Anterior dominant in adults (occasionally FIRDA), anterior or posterior dominant in children (occasionally OIRDA)
- Prominent changes in children, usually diminishing intensity as adult age, rare in elderly
- Enhanced by fasting
- Usual return of EEG to baseline in 1-2 minutes after HV ends
- **Contraindicated in:** severe cardiorespiratory diseases, sickle cell disease or trait, cystic fibrosis, acute stroke, recent intracranial hemorrhage, moyamoya disease

# HV Response in a 10-Year-Old Boy

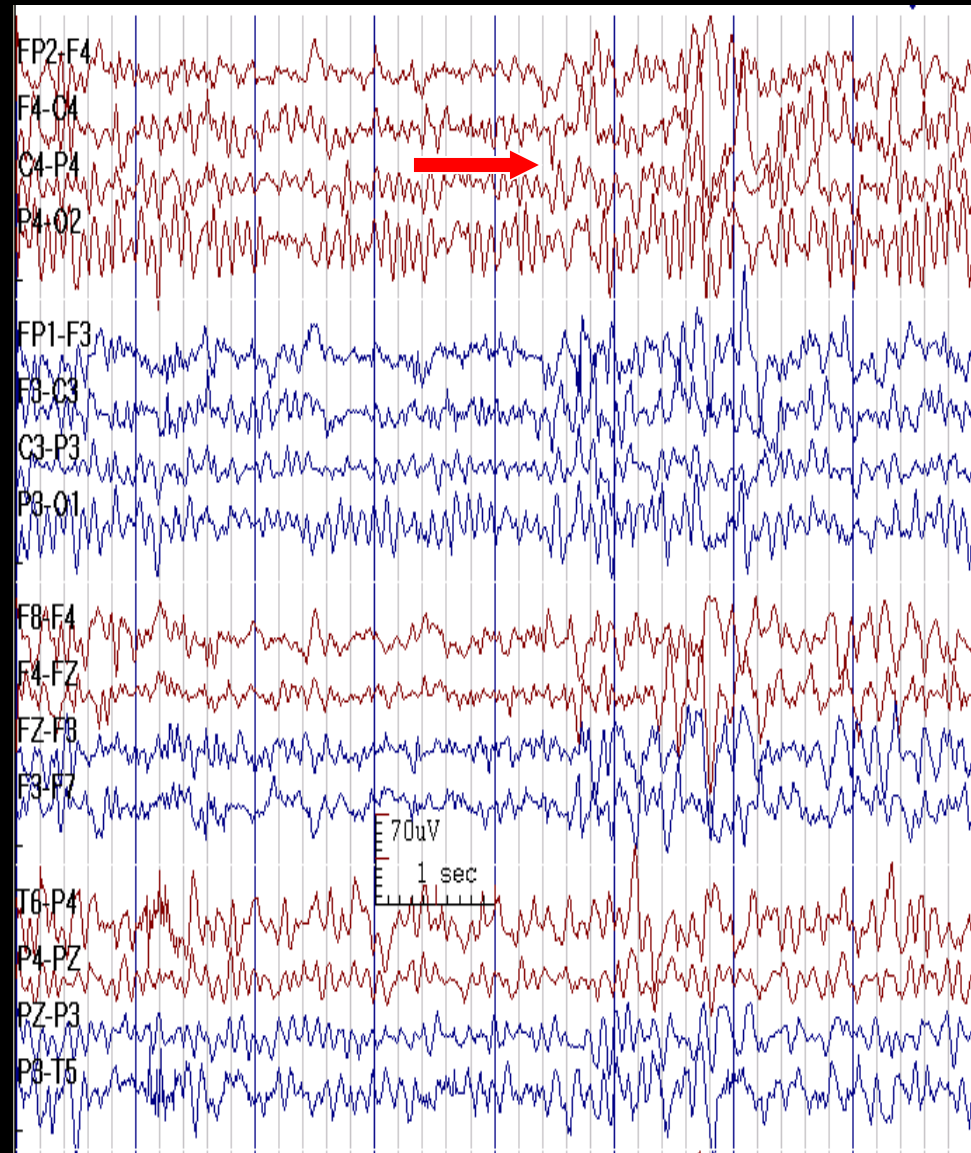
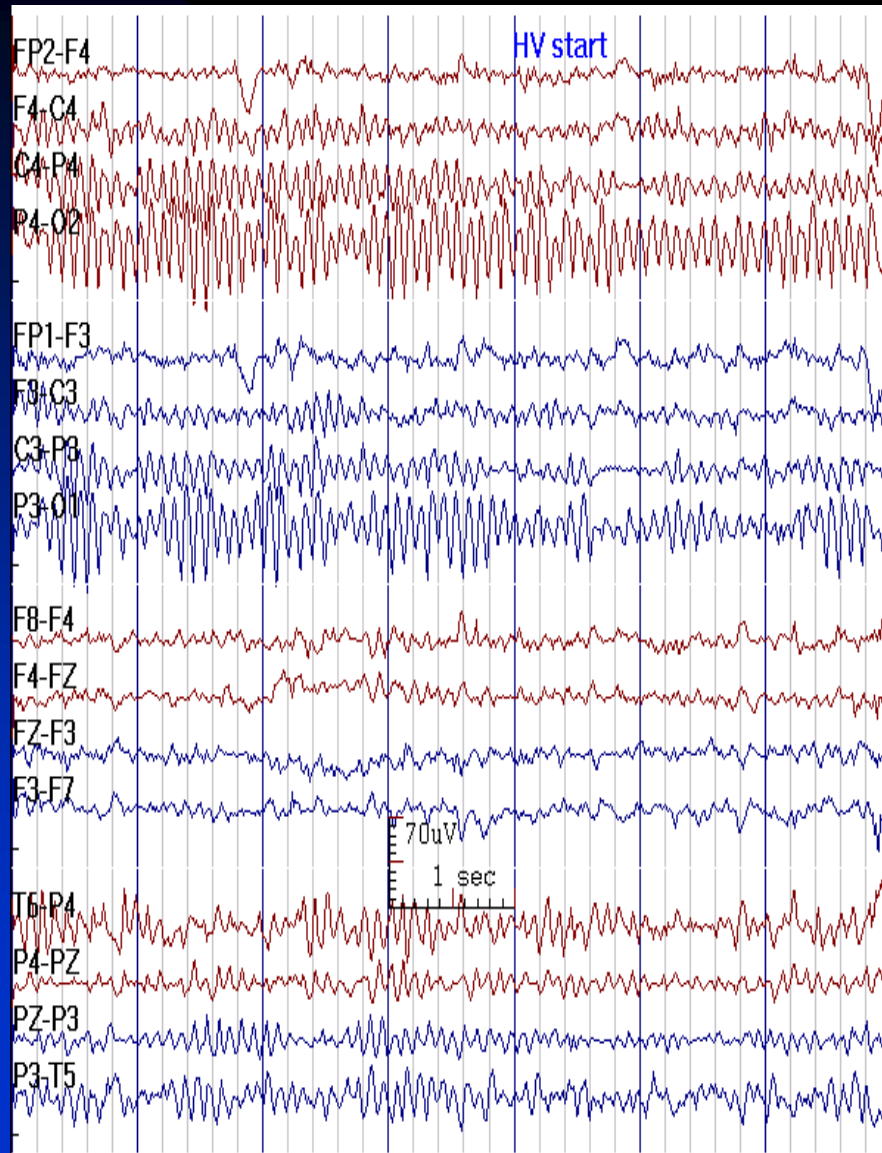


# HV Response in a 10-Year-Old Boy

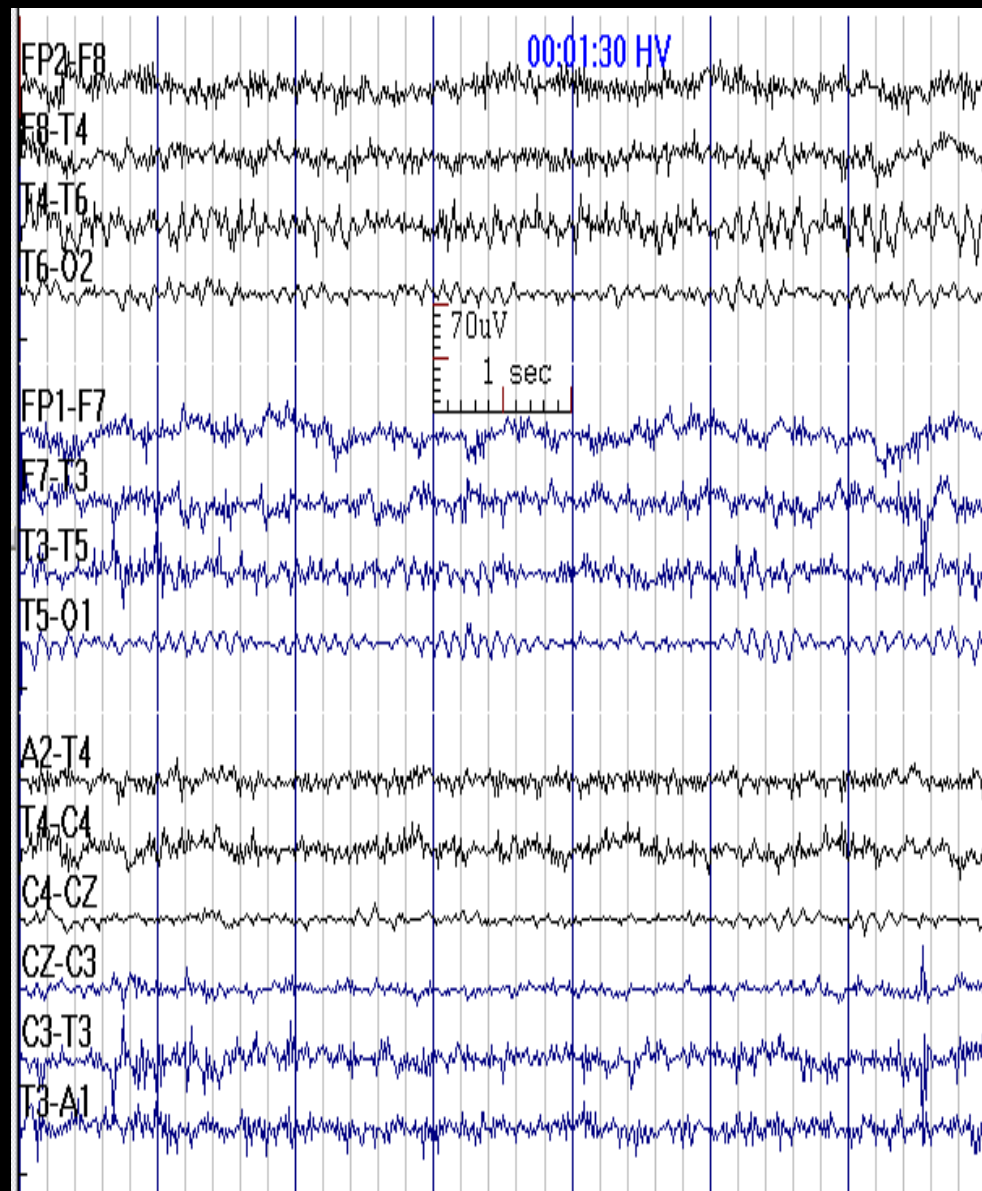
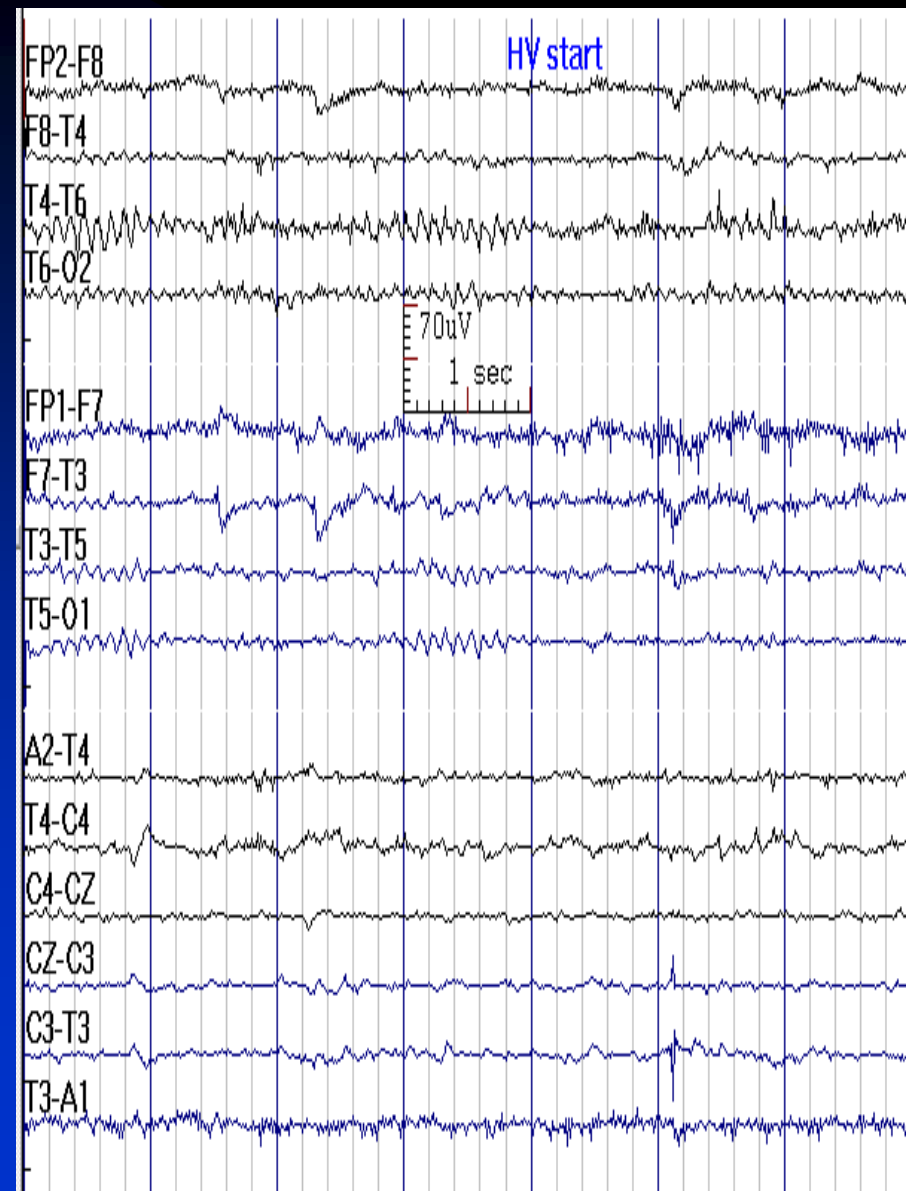
(Reduced Sensitivity; One Benefit of Digital EEG)



# HV Response in an Adult



# HV Response in an Adult

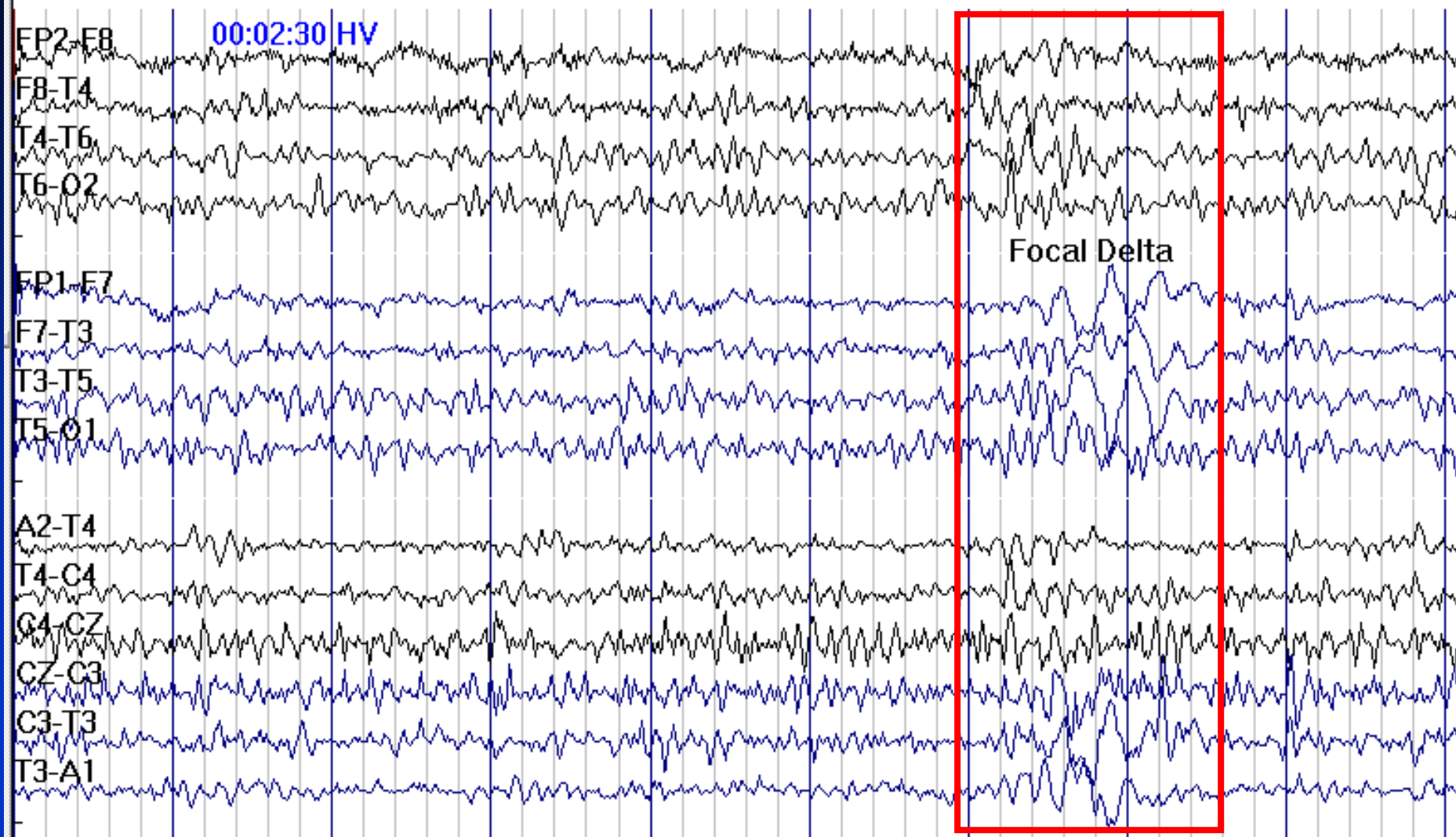


# Abnormal HV Responses

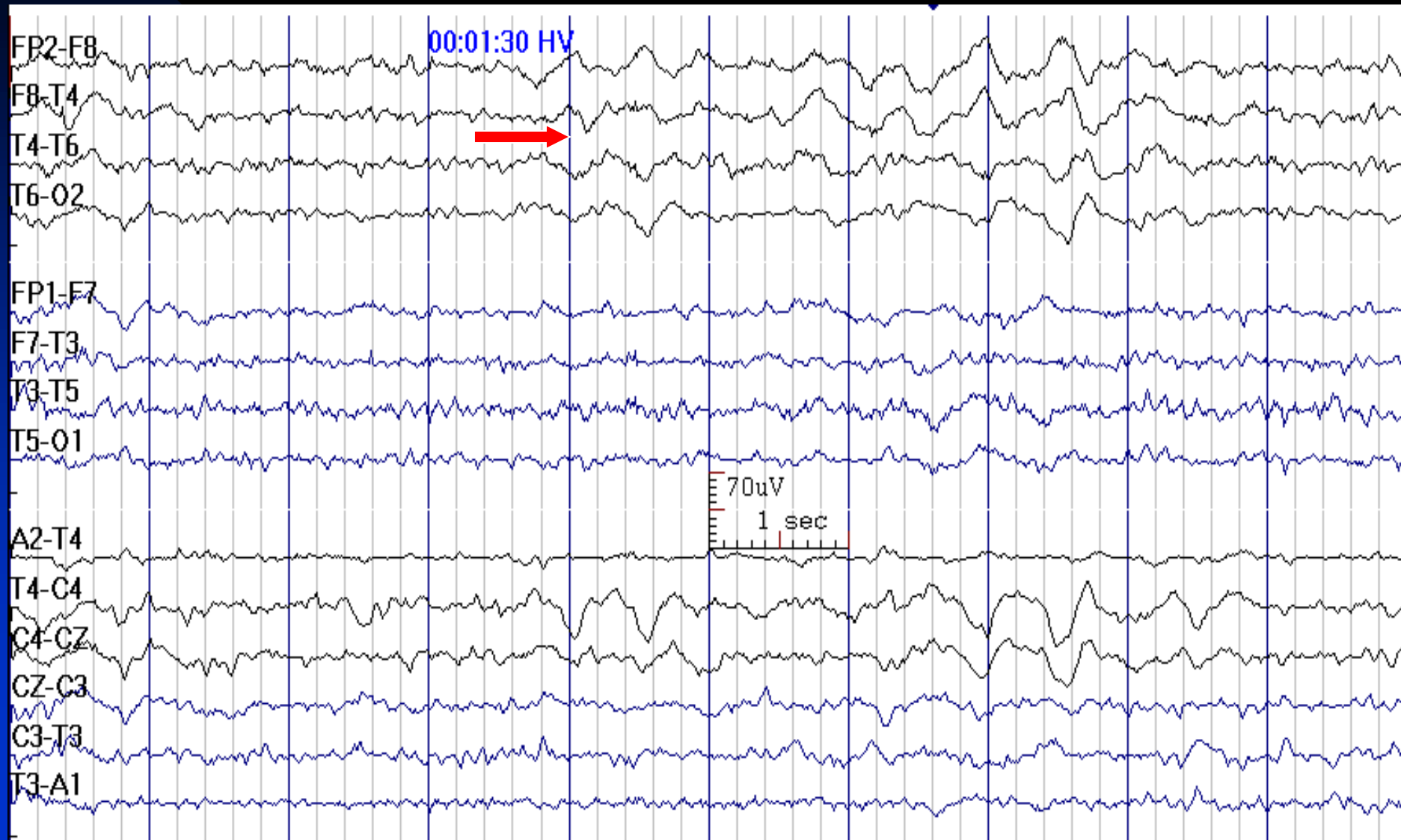
- **Lateralized or localized slowing:** however, initial response to hyperventilation may be normally asymmetrical with a greater build-up over one hemisphere, usually the left
- **Epileptiform discharges:** however, sometimes HV creates sharply contoured wave forms. It is better to read HV response as normal unless clear identification of spikes can be made
- **Seizures:**  $\geq 80\%$  of untreated children with absence seizures, 50% of patients with slow spike-and-wave pattern and rarely in partial seizures
- **Delayed (5 minutes or more) slowing:** suggestive of Moyamoya disease
  - ◆ However, many patients inadvertently hyperventilate beyond the recommended time; therefore prolonged slowing can not be termed pathologic unless  $p\text{CO}_2$  is measured to confirm cessation of HV



# Focal Delta (F7) during HV in a 35-Year-Old Man with Temporal Lobe Epilepsy

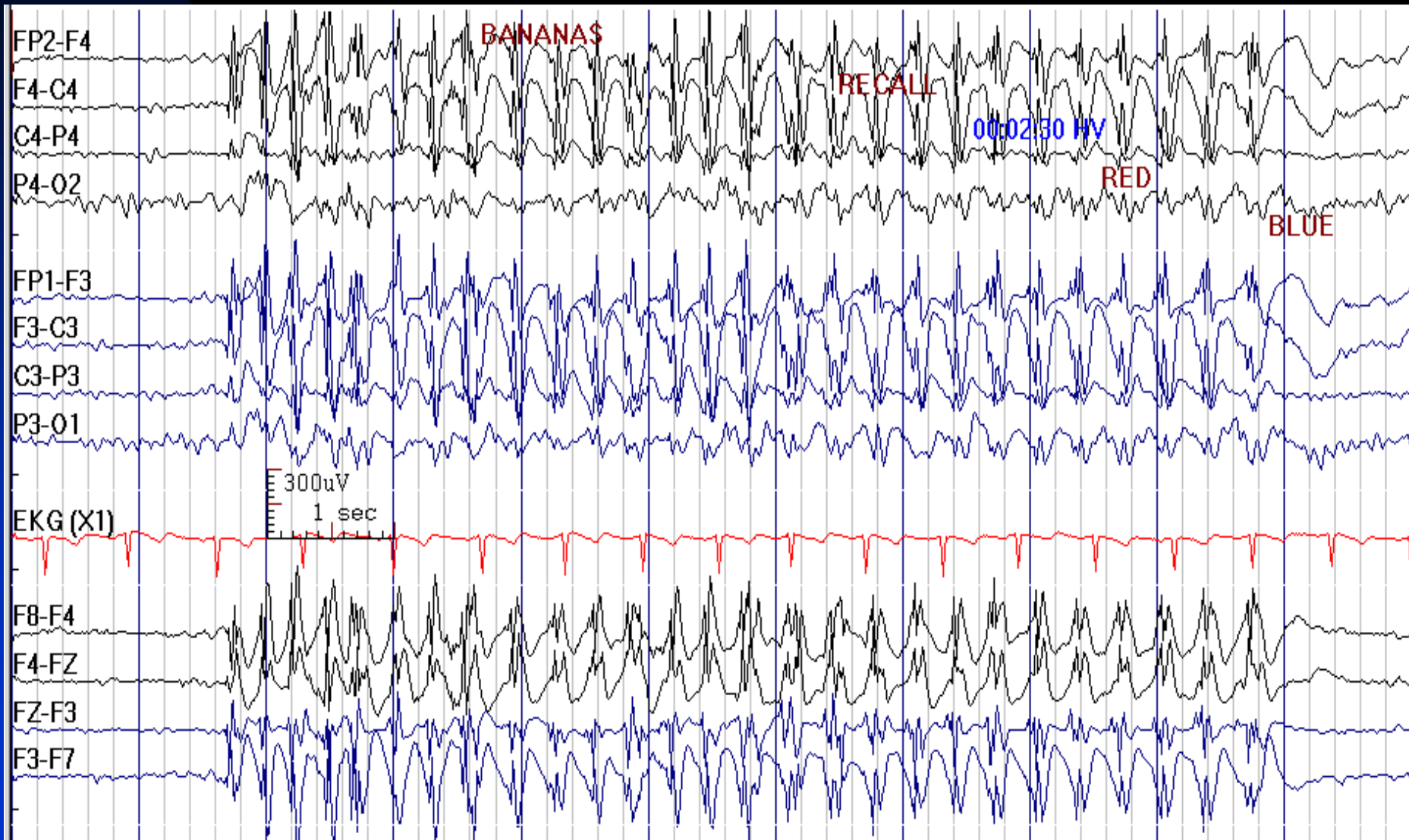


# Unilateral Delta Activity (T4) during HV in a 44-Year-Old Man with Epilepsy





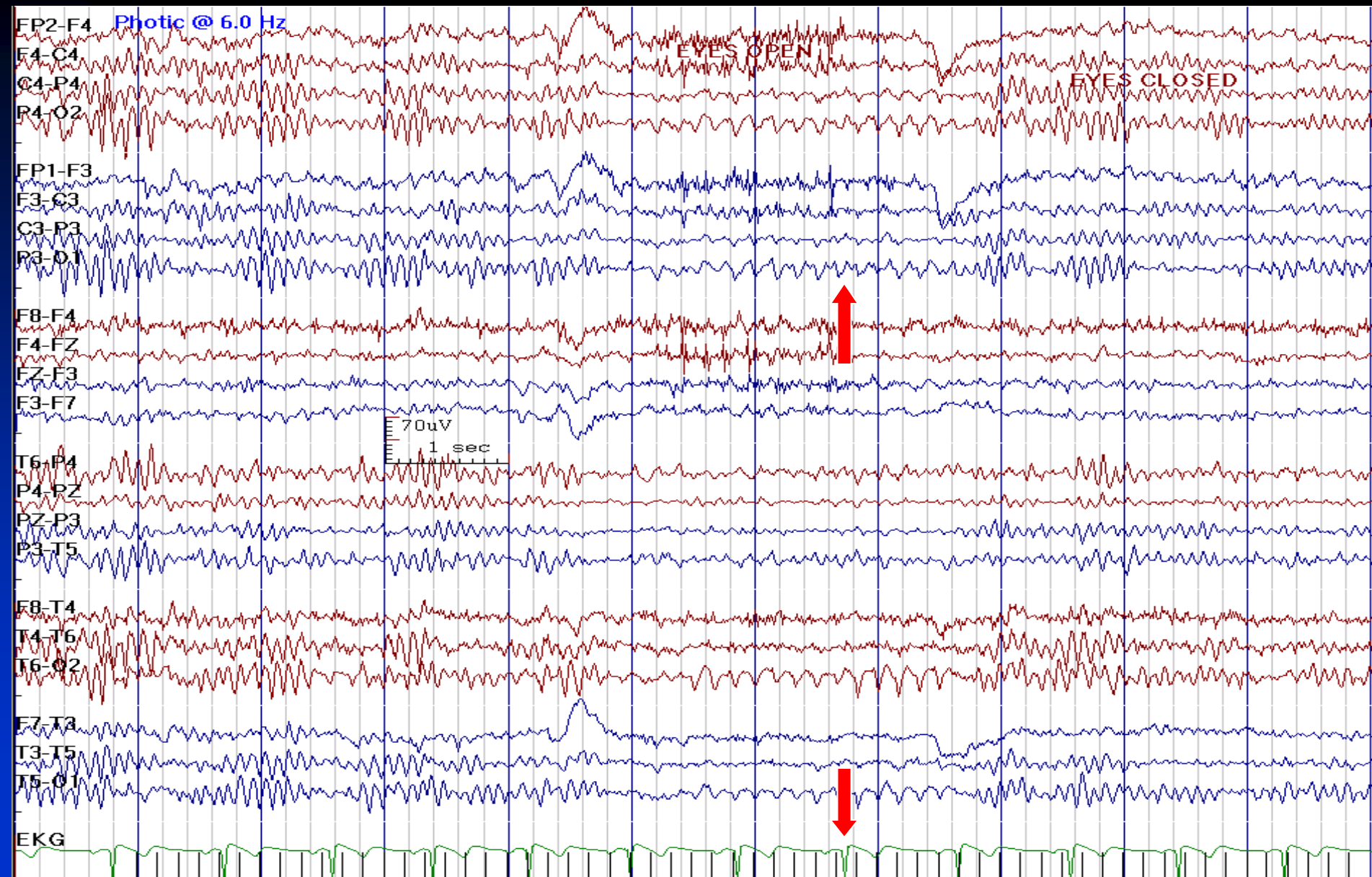
# Absence Seizure Provoked by HV



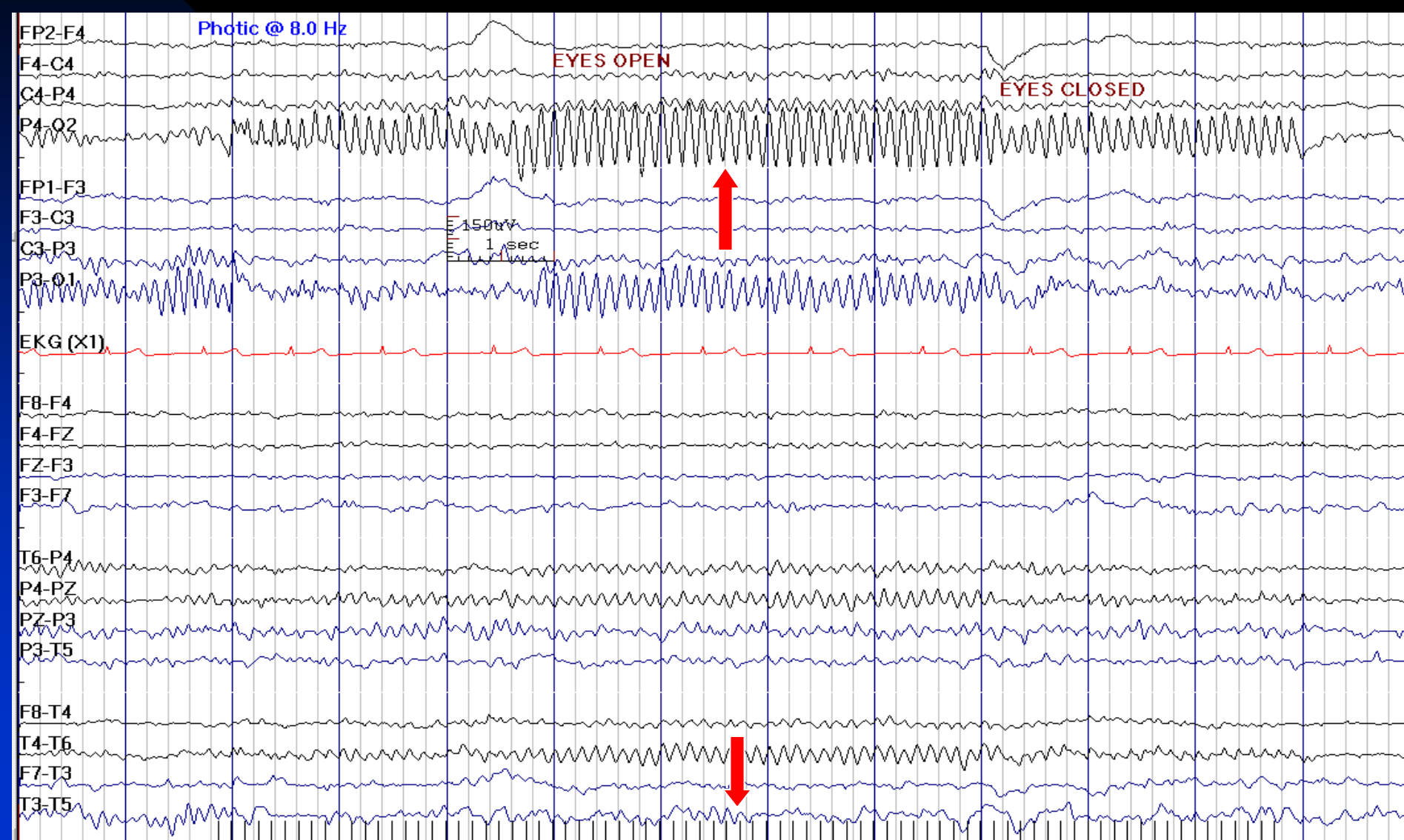
# Normal Responses to Photic Stimulation

- **Photic driving:** rhythmic waveforms in posterior head regions, time- locked (with a 70-150 msec delay), and stimulus dependent, may be sub- or supra-harmonic to stimulus frequency
- **Photomyoclonic response:** synchronous or asynchronous frontalis contractions in response to flashing lights

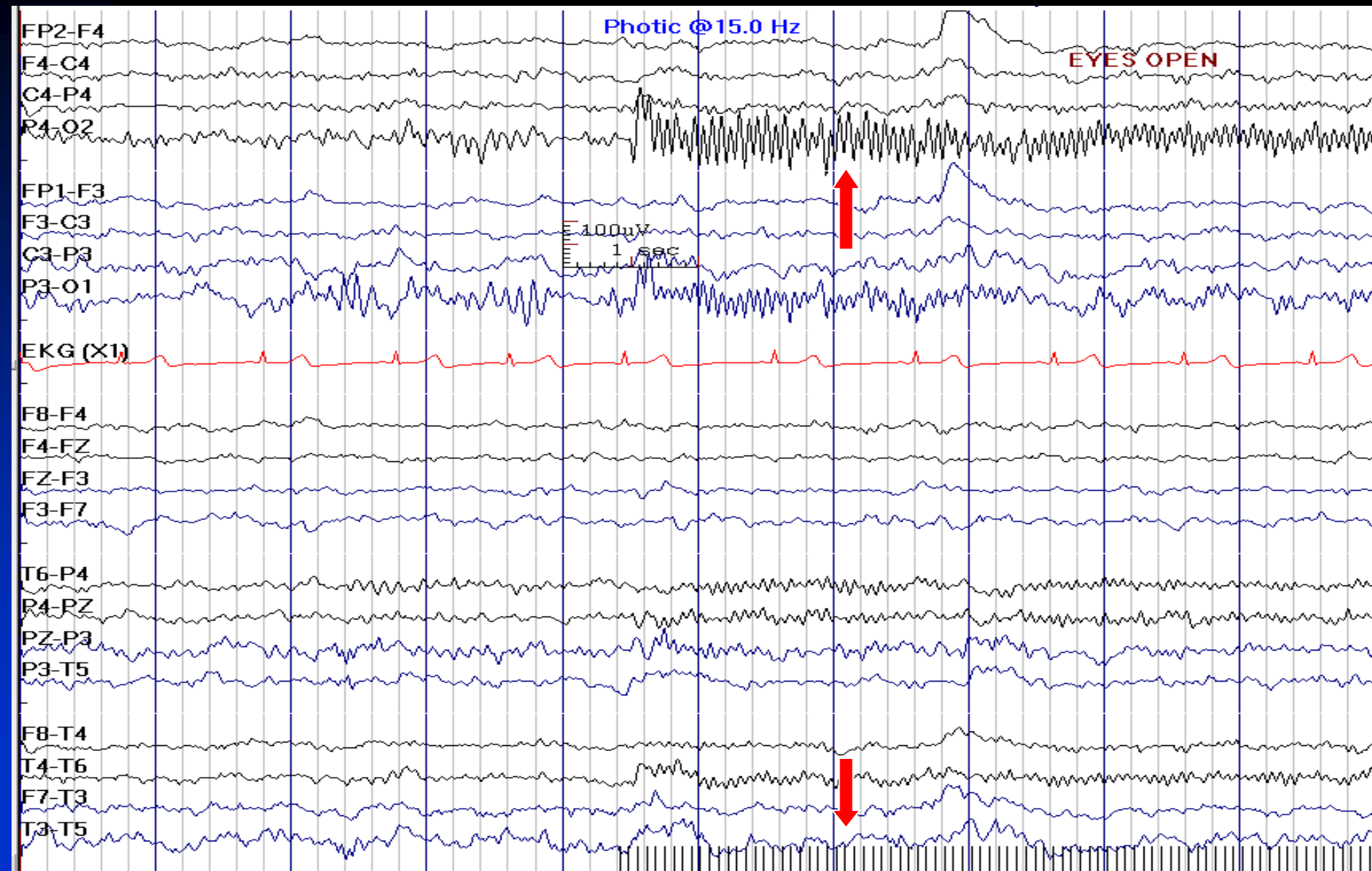
# Photic Driving; 6 Hz



# Photic Driving; 8 Hz

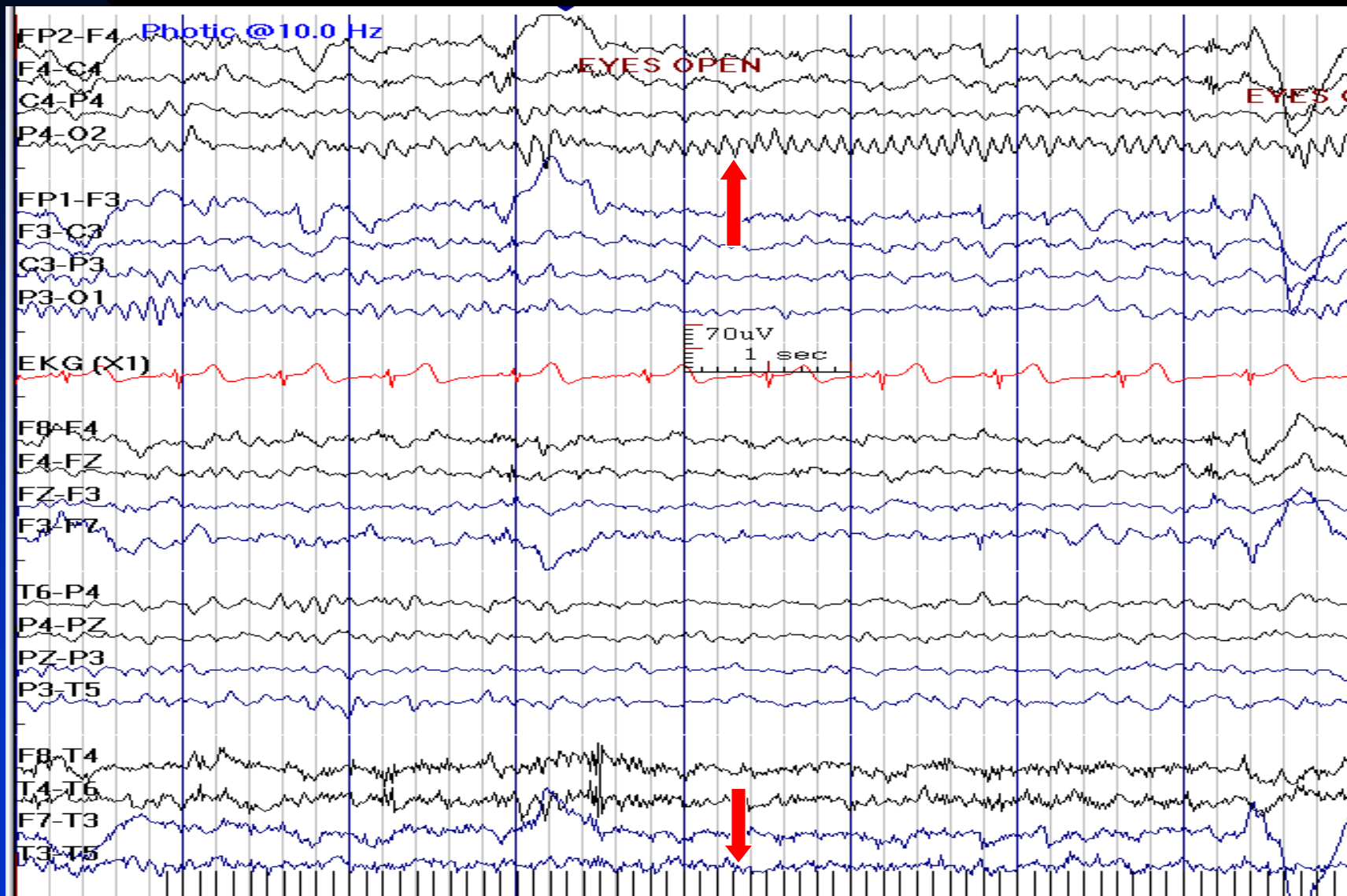


# Photic Driving; 15 Hz



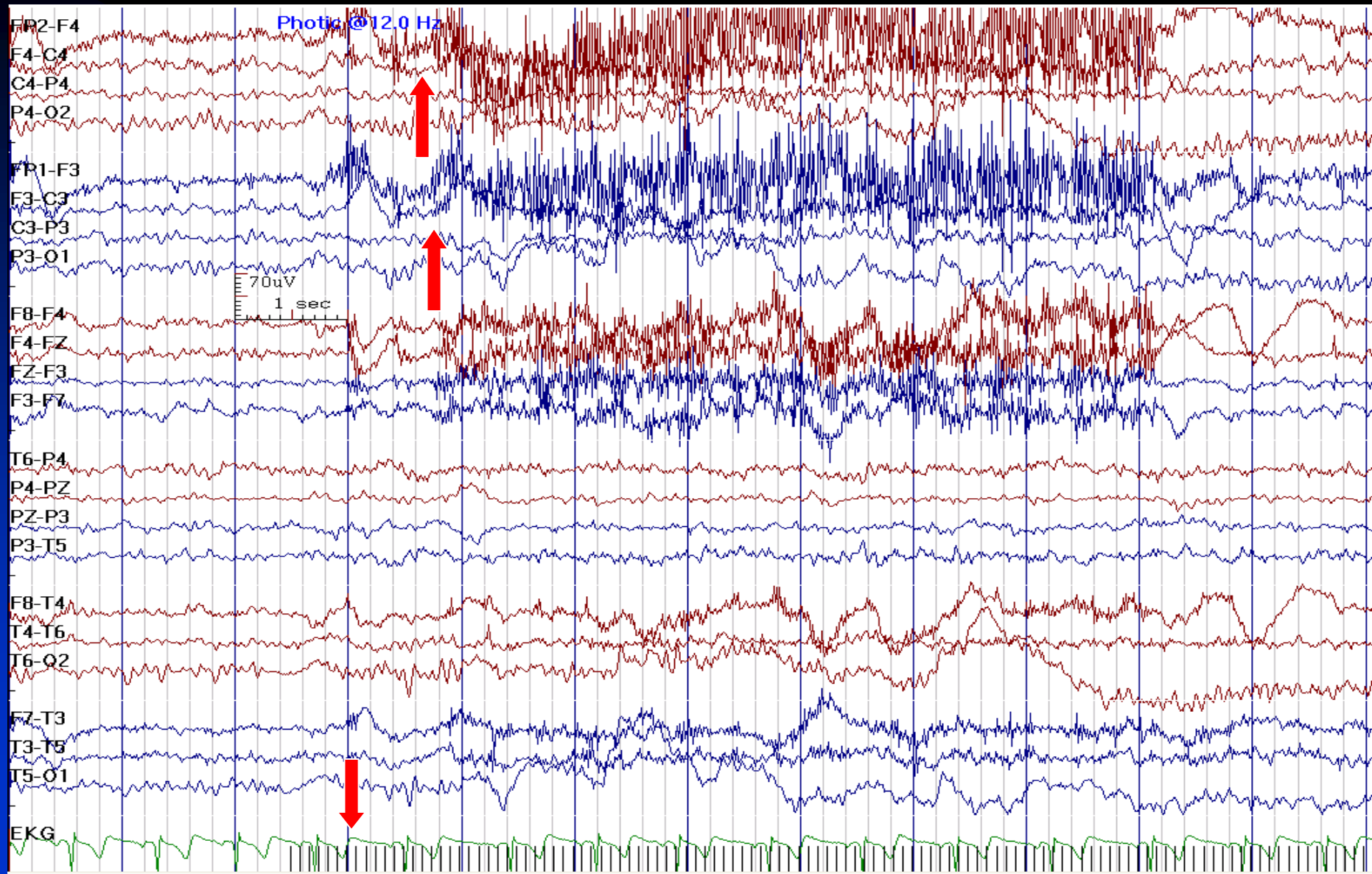
# Unilateral Photic Driving:

## If the Rest of EEG is Normal, This Is a Normal Finding





# Photomyoclonic Response



# Abnormal Responses to Photic Stimulation

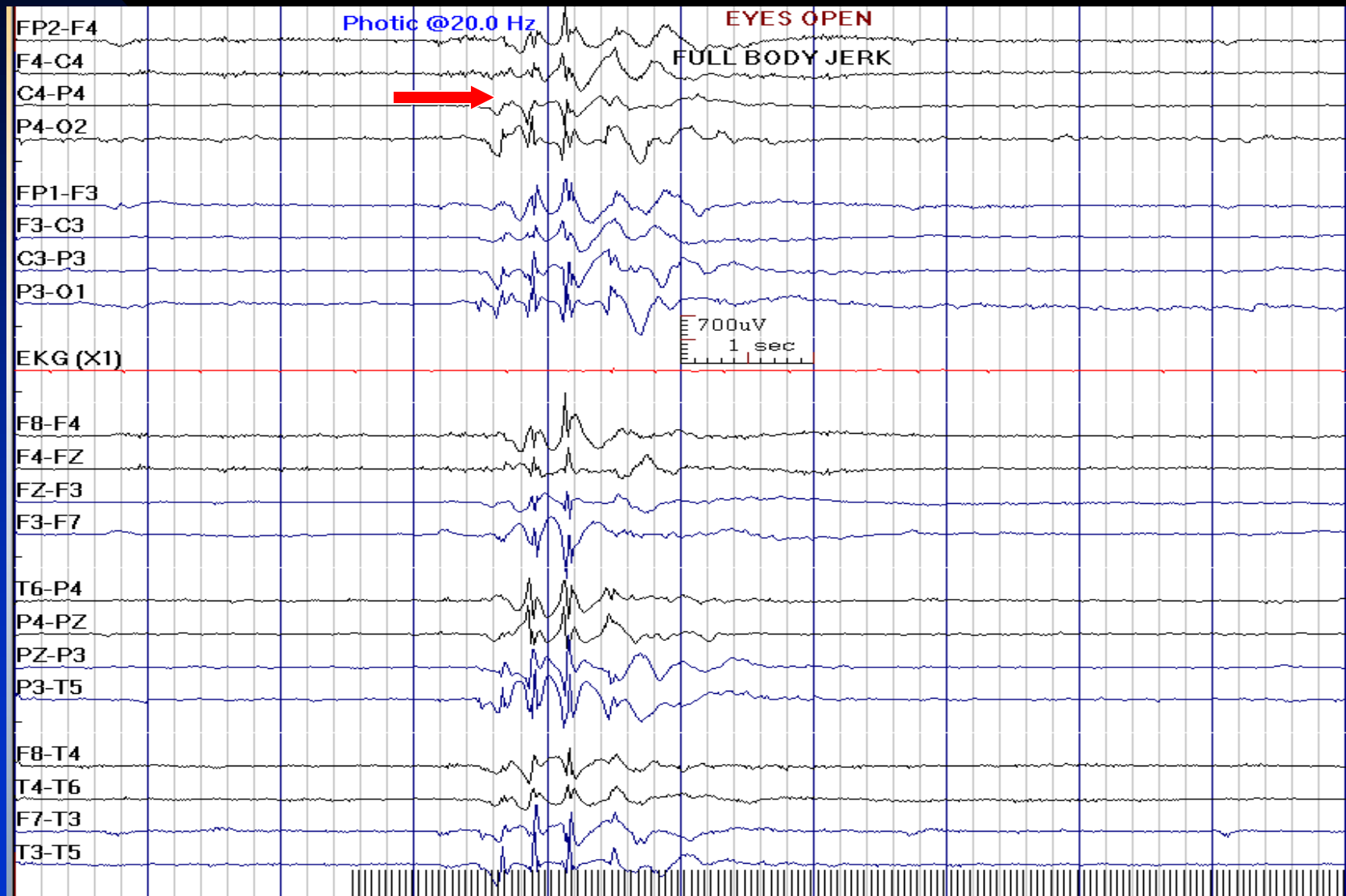
- **Photoparoxysmal response (PPR):**
  - ◆ Any generalized paroxysmal response to photic stimulation, containing either slow waves or epileptiform discharges
  - ◆ Any anterior or posterior dominant, bisynchronous and symmetrical epileptiform pattern



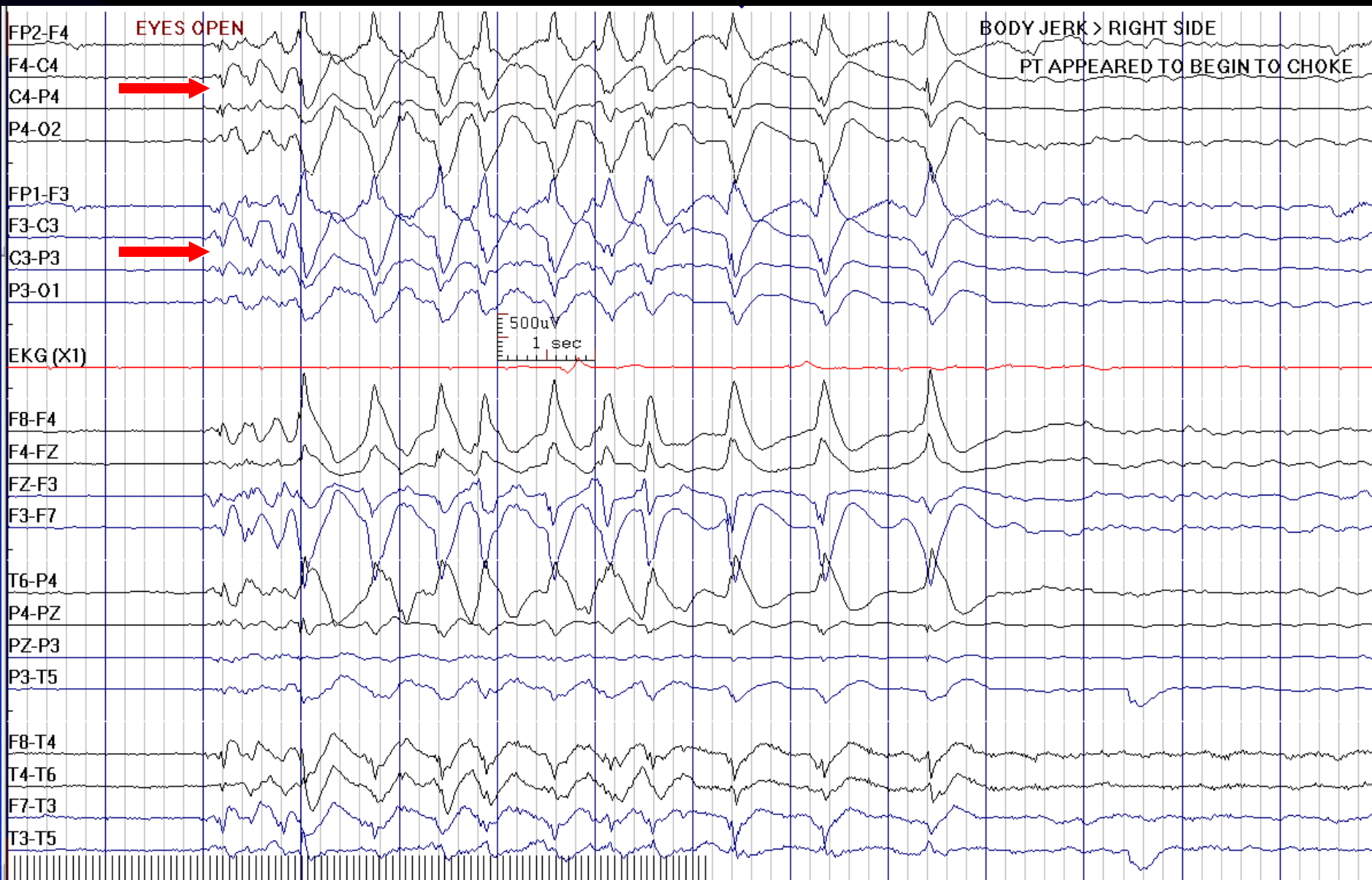
# Photoparoxysmal Response Characteristics

- Usual duration of one or more seconds
- Maximum response and the lowest threshold at 16 Hz photic stimulation and upon eye closure
- May persist more than 200 milliseconds beyond the termination of the flash stimulation (sustained response)
- Response to single flash may indicate progressive myoclonic epilepsy

# Photoparoxysmal Response in a 2-Year-Old Boy with Myoclonic Epilepsy (Reduced Sensitivity)



# Sustained Photoparoxysmal Response



# **Chapter 5**

## **Artifacts**

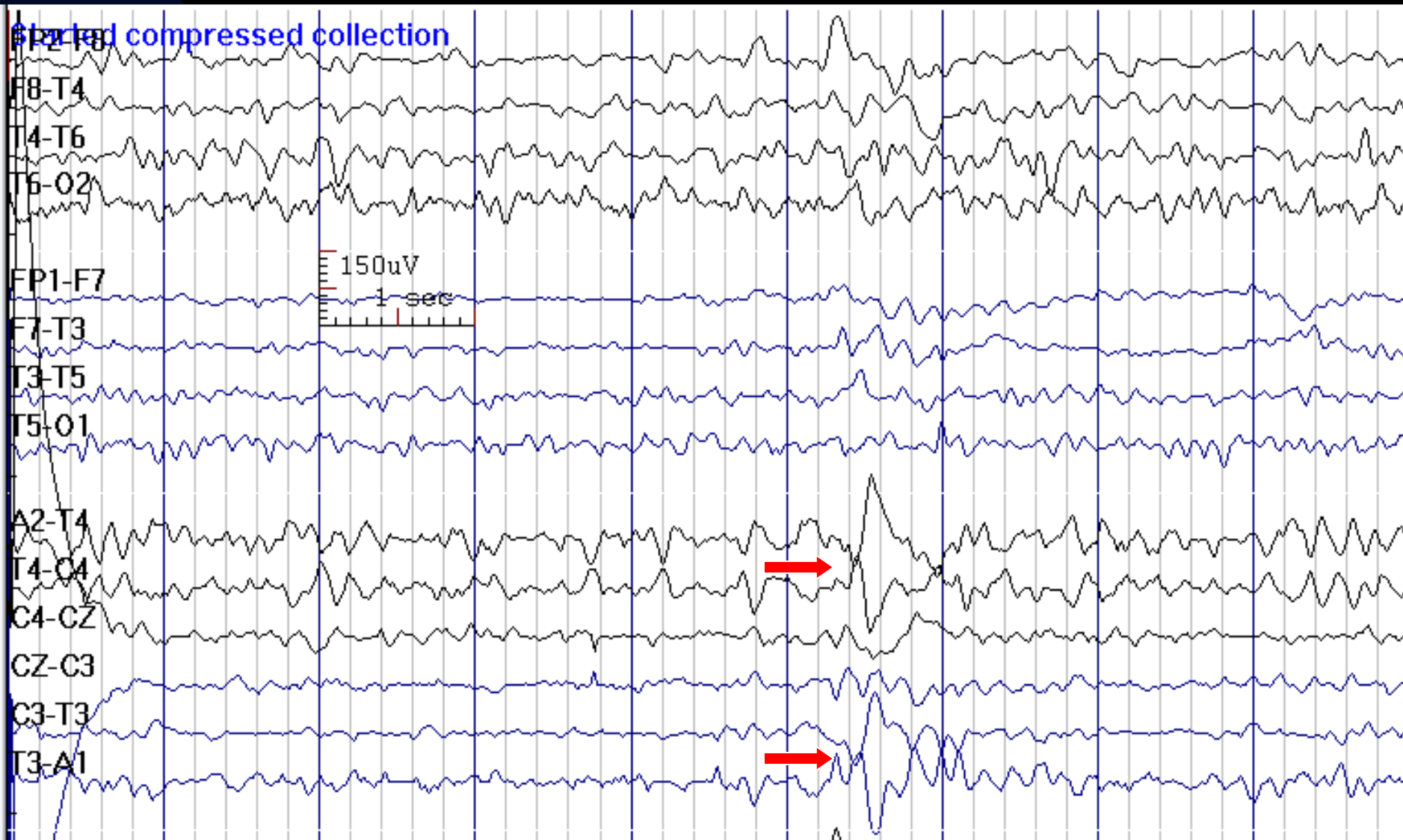
- **Definition:** artifacts are signals of extra-cerebral origin which may obscure or be confused with EEG activity
- **Physiological:** eye movements, EKG, EMG, tongue movements (glossokinetic), galvanic skin response (sweating, salt bridge), and movements (tremor, jerk)
- **Non-physiological:** instrumental, electrode, and environmental

# Artifacts: Basic Rules

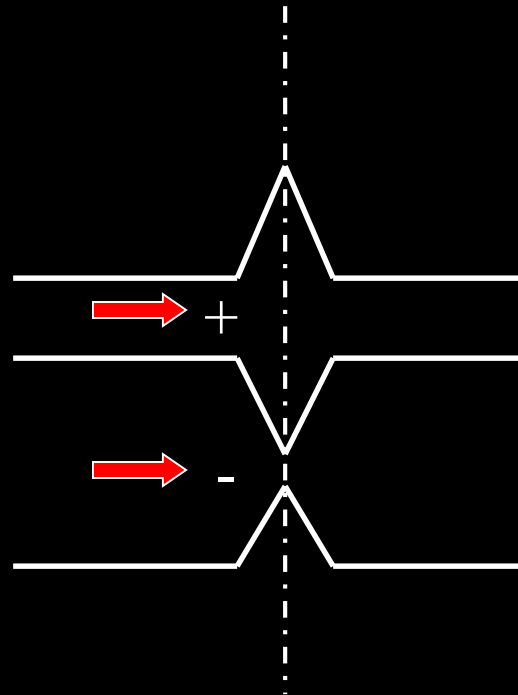
- Fits known field of physiological artifact
- Field of distribution is not logical – field maximum in multiple non-contiguous locations
- Atypical patterns of positivity or negativity
- Double or triple phase reversals
- Mirror image in adjacent channels

# Mirror Image and Absence of Physiological Field

## Indicate T4 and T3 Artifacts

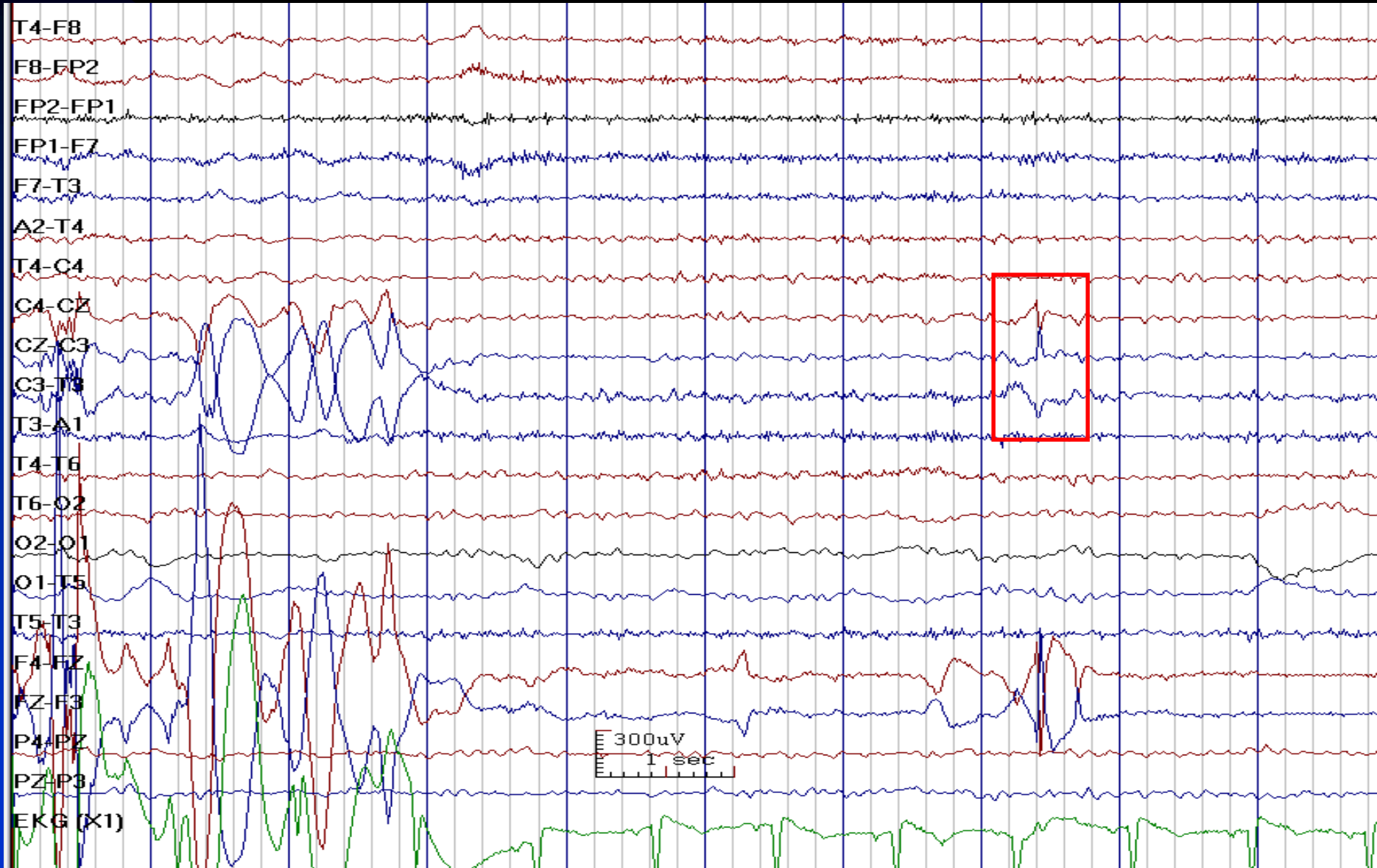


# Double Phase Reversal Characteristic for Artifact

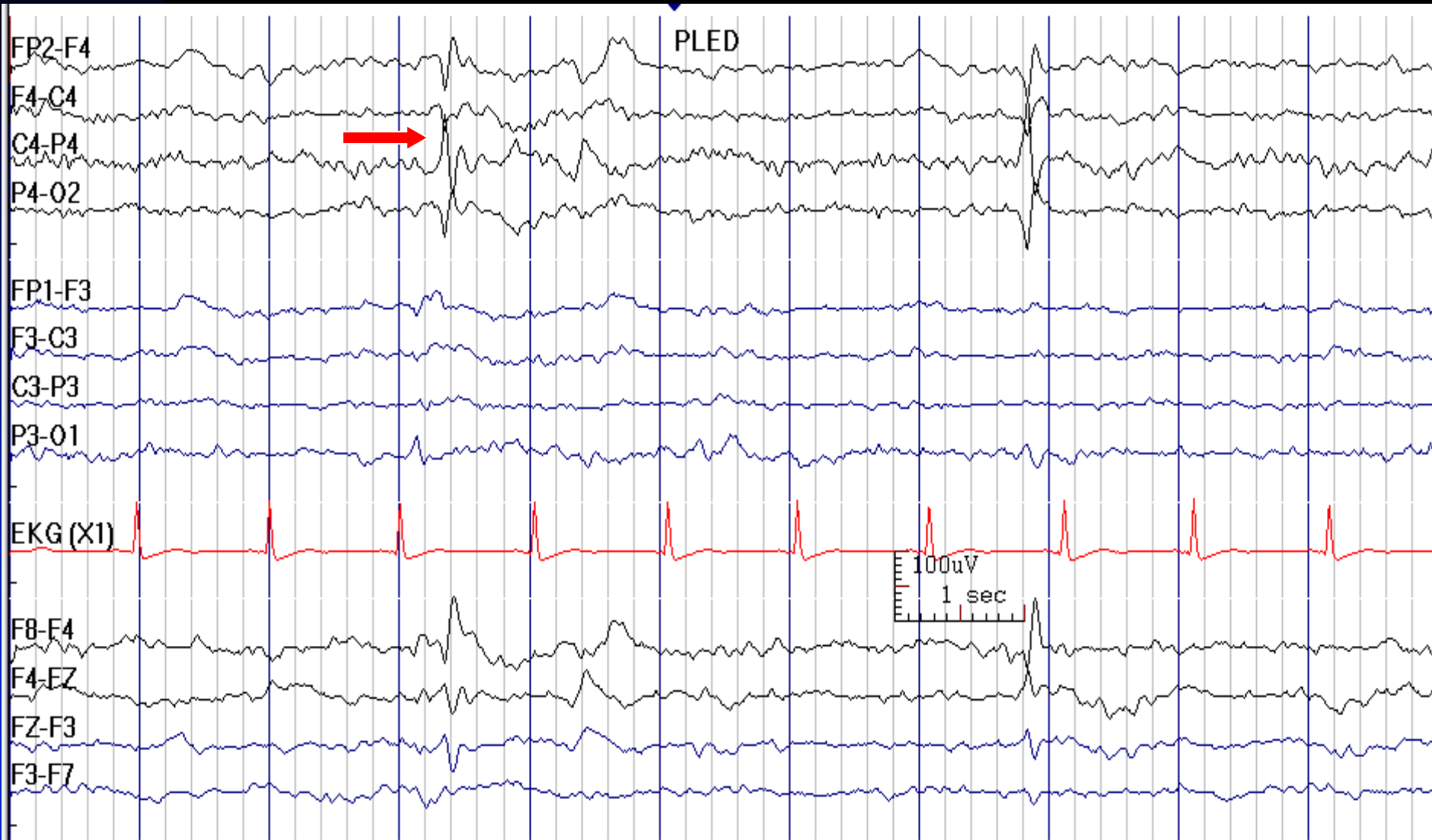




# Double Phase Reversal is Usually an Artifact

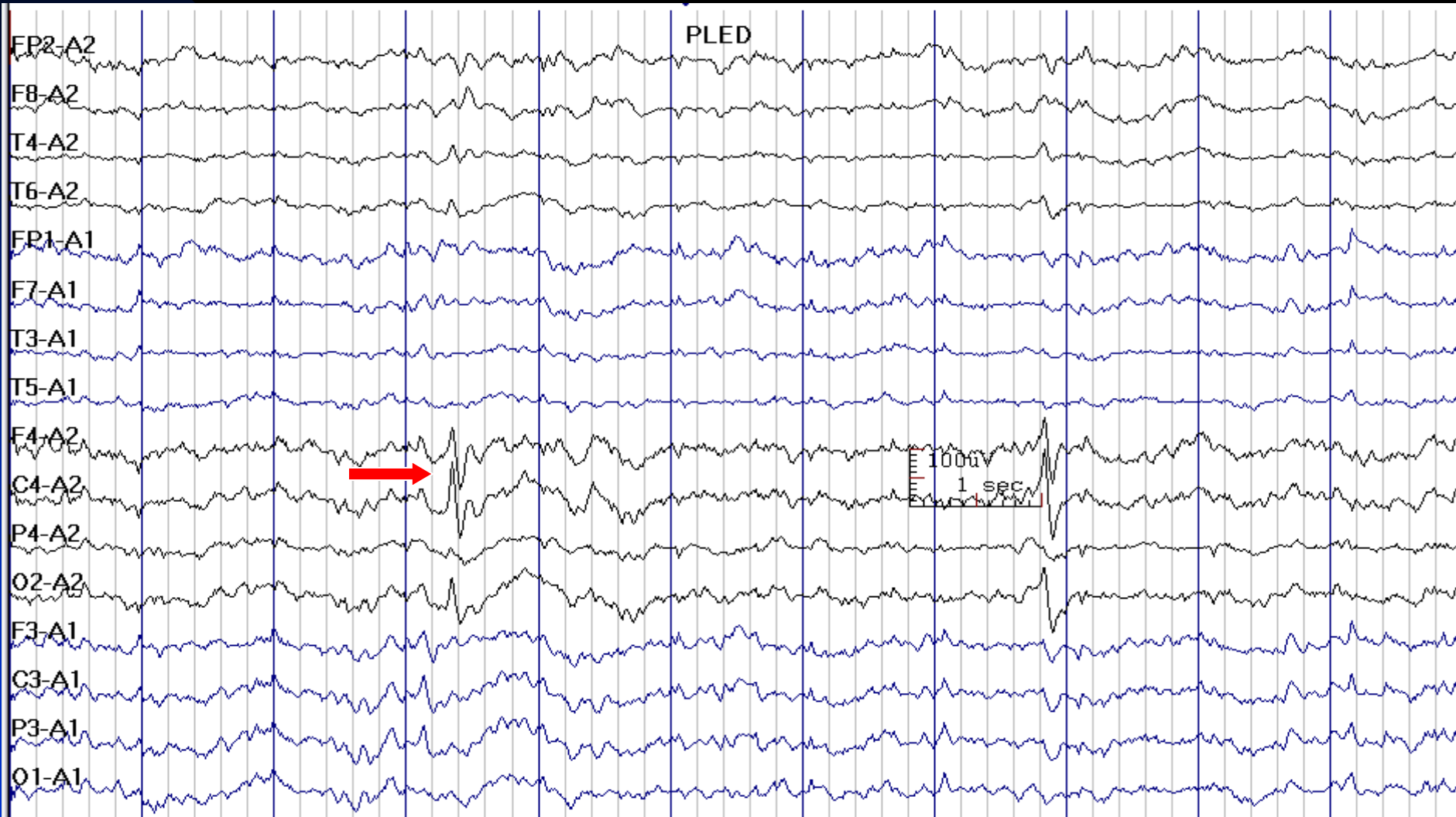


# Double Phase Reversal May Be Due to Jack Box Plug-in Error



See the next image for the same finding in reference montage

# Previous Image in Reference Montage; The Field Dose Not Make Sense (C4 > O2 > P4)



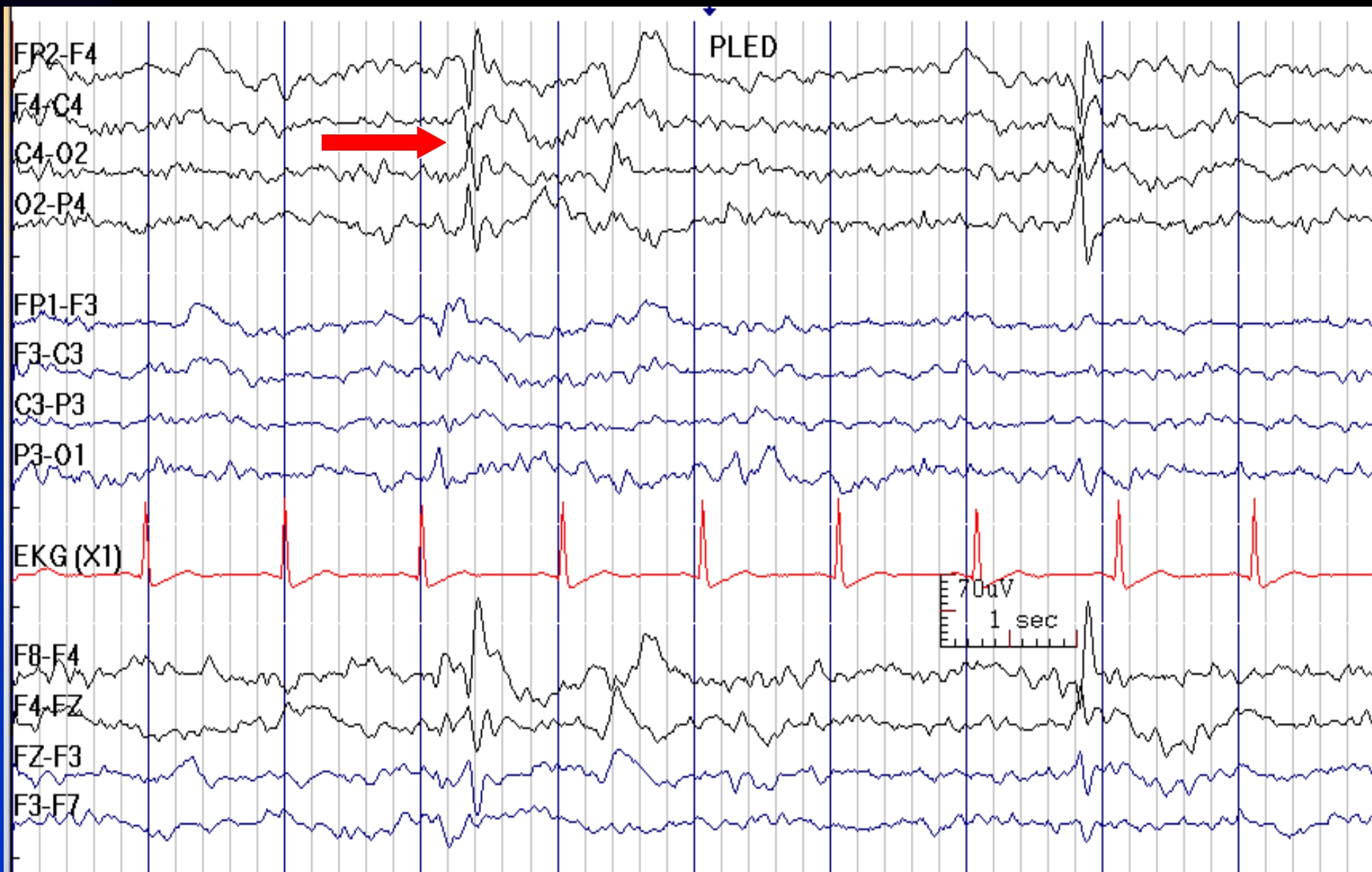
See the next image for explanation

# Double Phase Reversal May Be Due to Jack Box Plug-in Error

- In the 2 previous slides, the observed double phase reversal was due to error in plug-in the electrodes (P4 and O2)
- When we changed the electrode on the montage, it looked as a real brain activity, which was C4 PLEDs (next slide, the same page; pay attention to switched P4 and O2 electrodes)
- When the field of activity of the suspicious finding dose not make sense, it is better to consider plug-in error

Go to the next image to see the finding after correction of electrodes

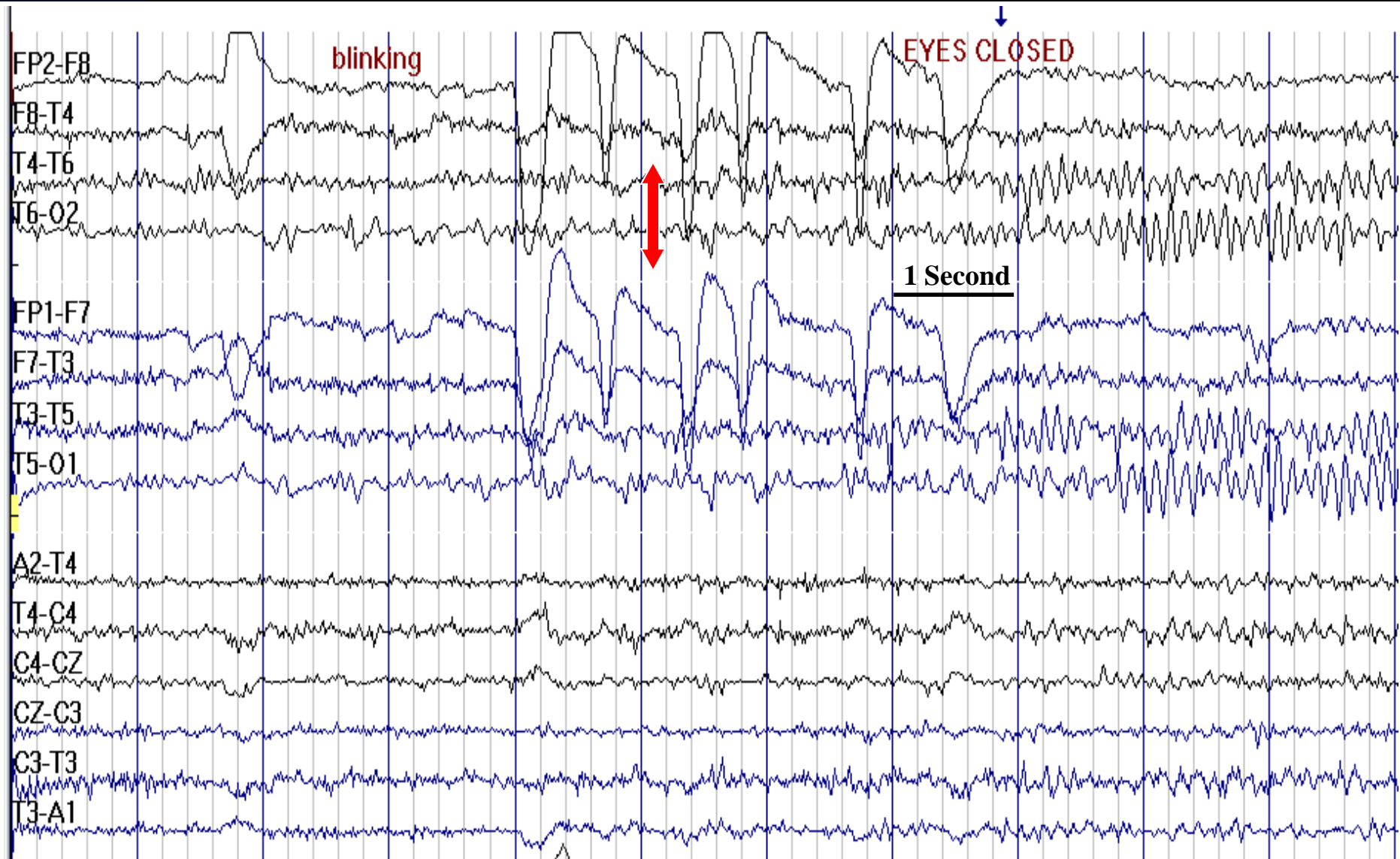
# C4 PLEDs: Previous Image after Switching the Electrodes



# Eye Movement Artifacts

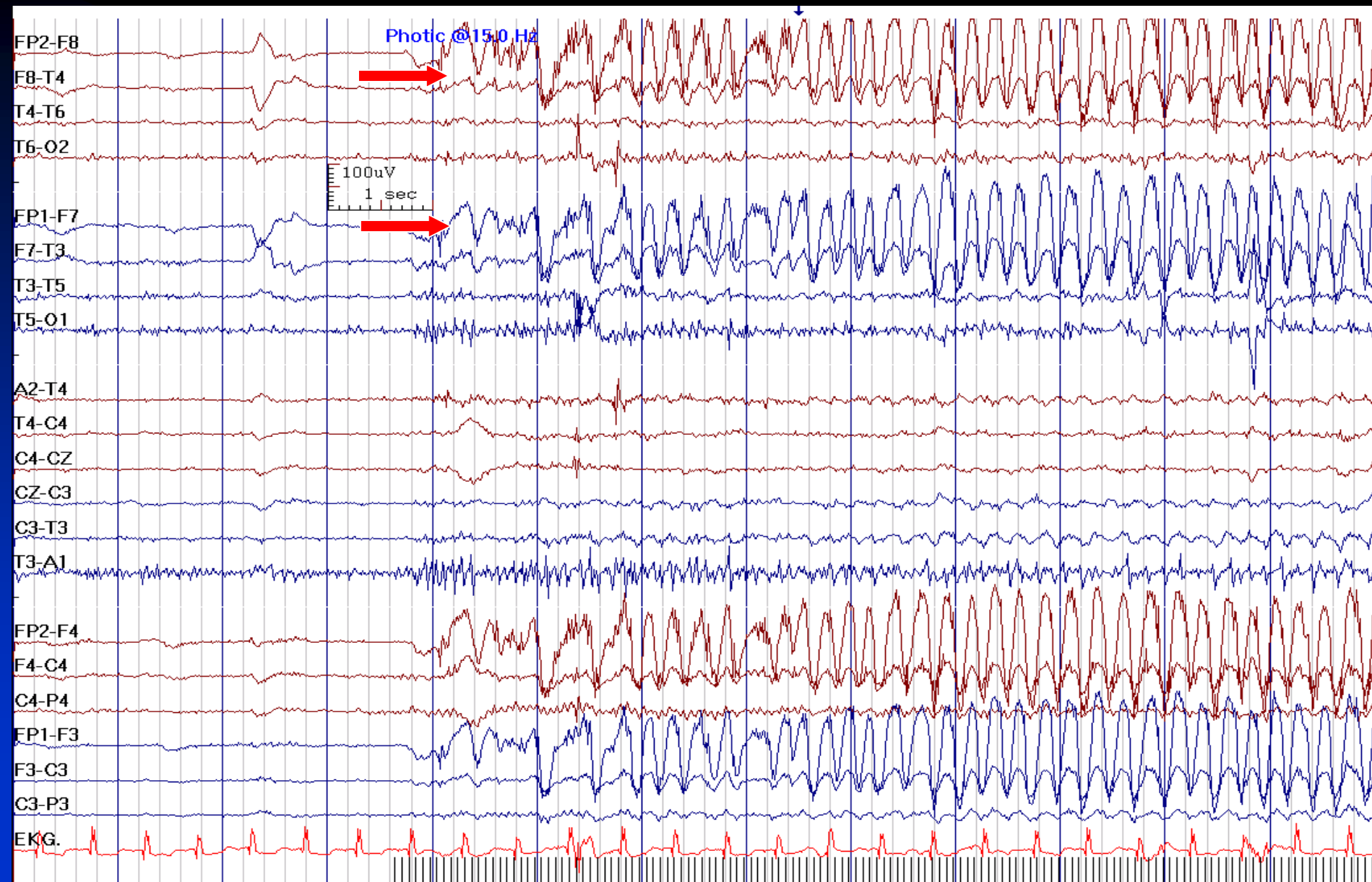
- **Generated by corneoretinal potential:** cornea is relatively positive and retina is relatively negative
- **Involved electrodes:** Fp1 and Fp2 in vertical eye movements (F4, F3 to a lesser extent); F7 and F8 in horizontal eye movements

# Blinking Artifacts



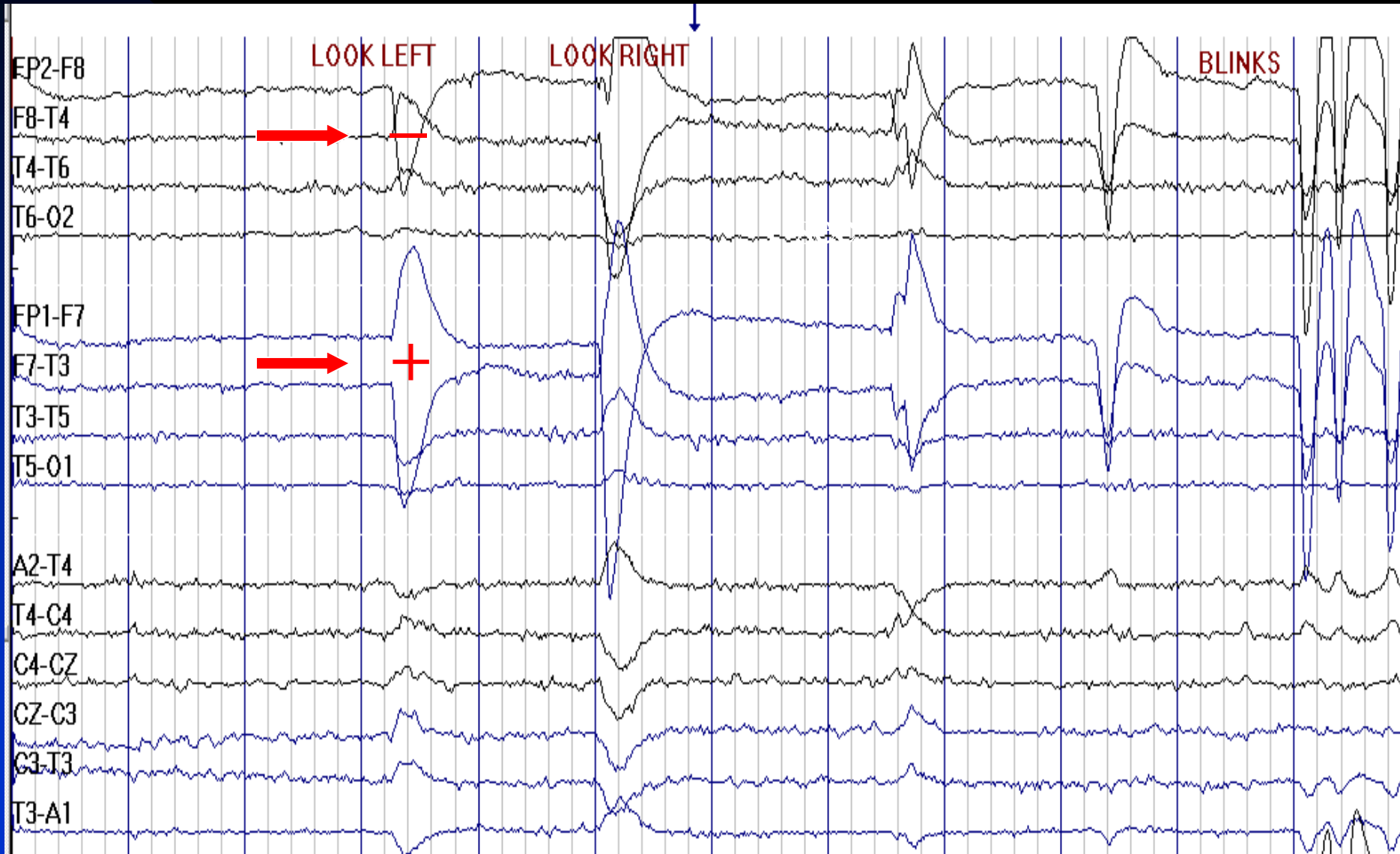


# Eye Blinking in Response to Photic Stimulation

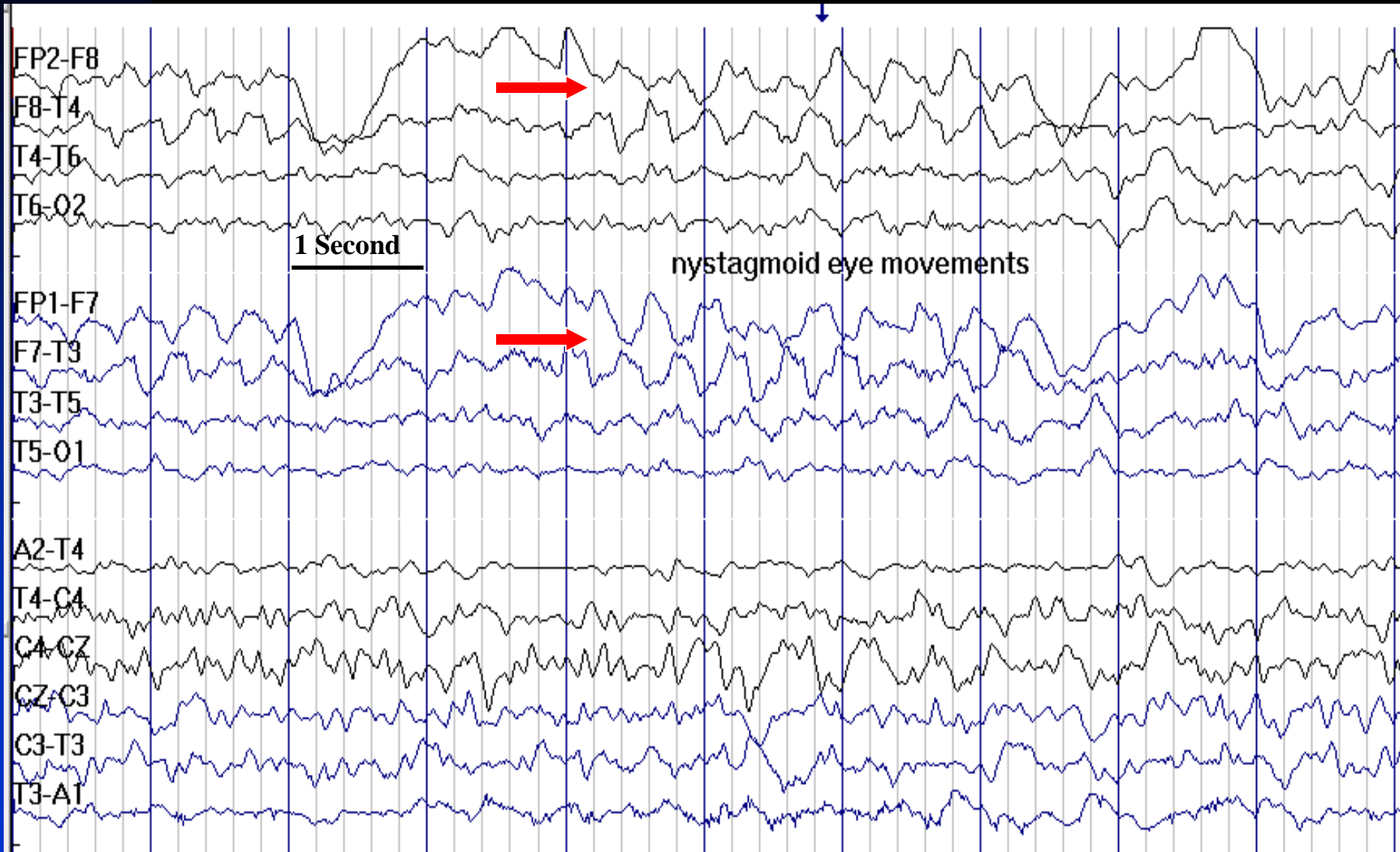




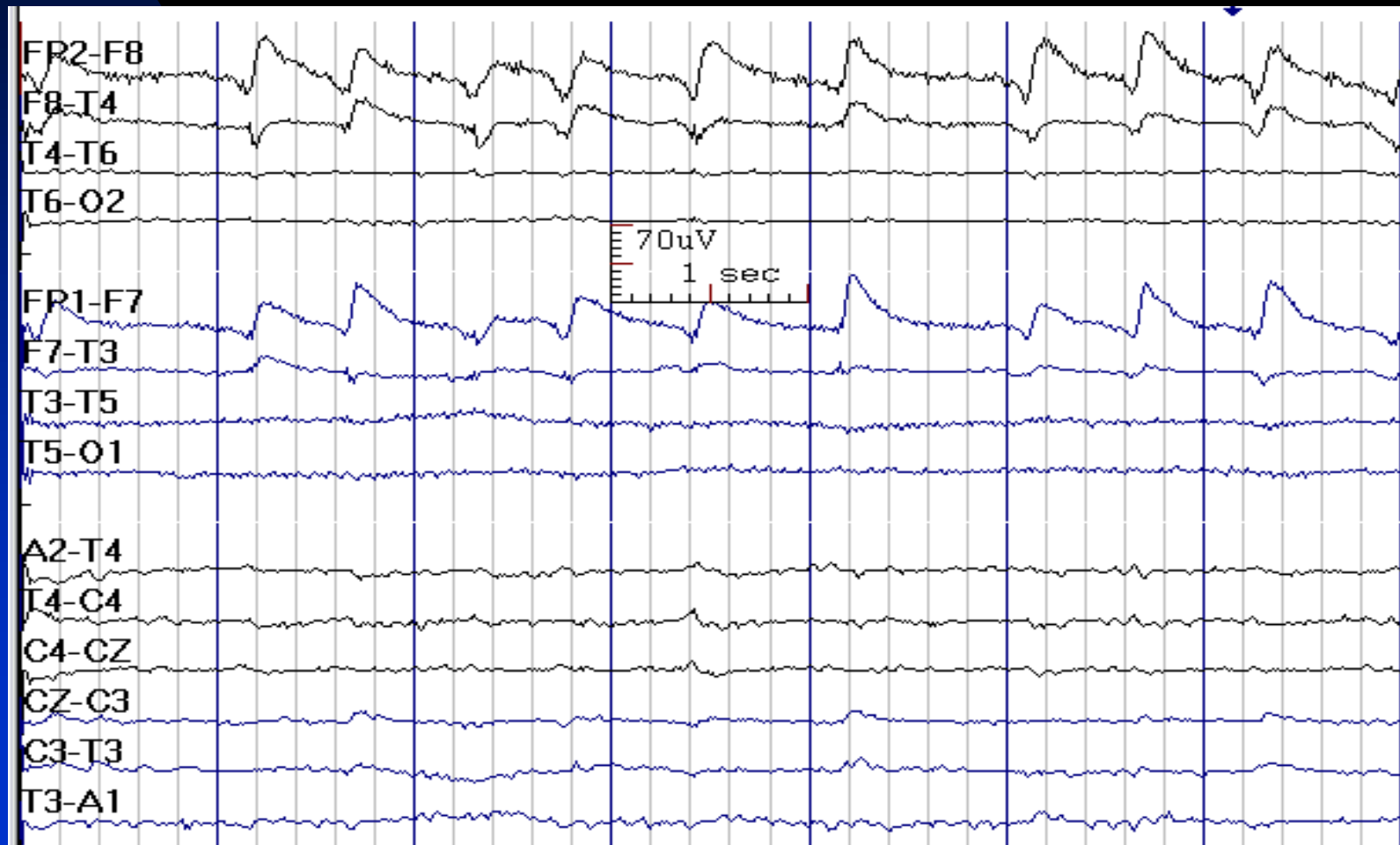
# Horizontal Eye Movements



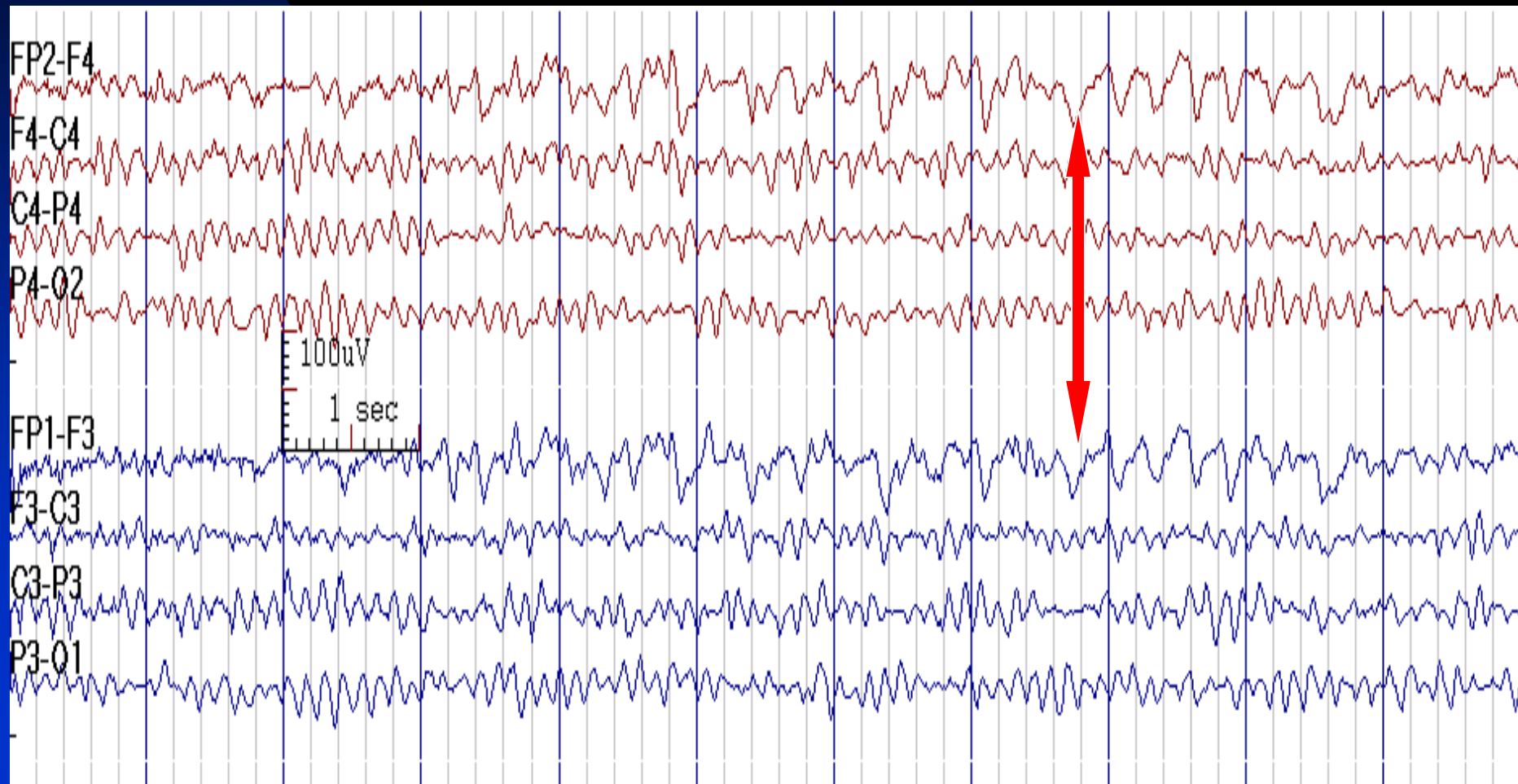
# Nystagmoid Eye Movements



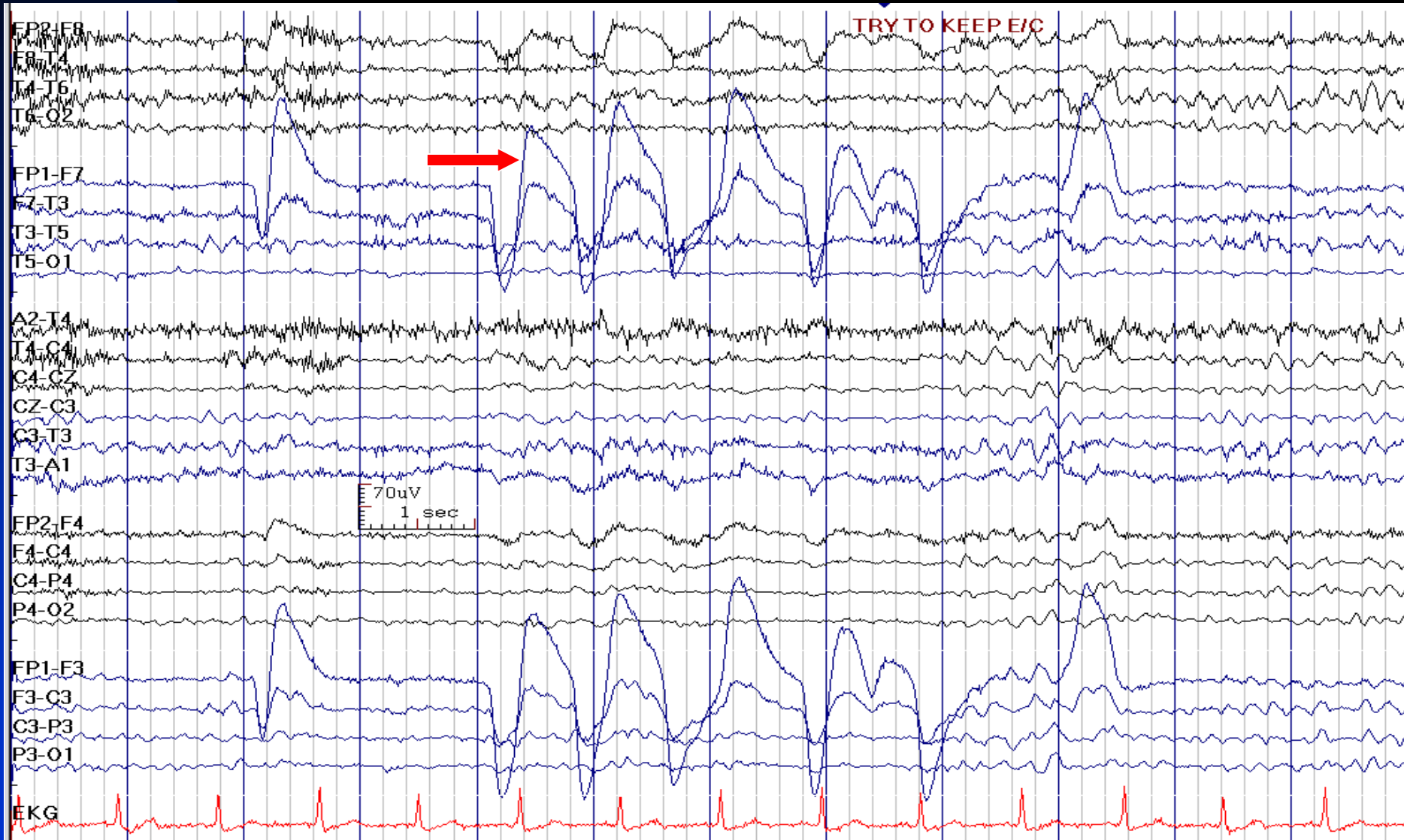
# Downbeat (with Rightward Component) Nystagmus (Fp1 & Fp2 are Negative)



# Eye Flutter



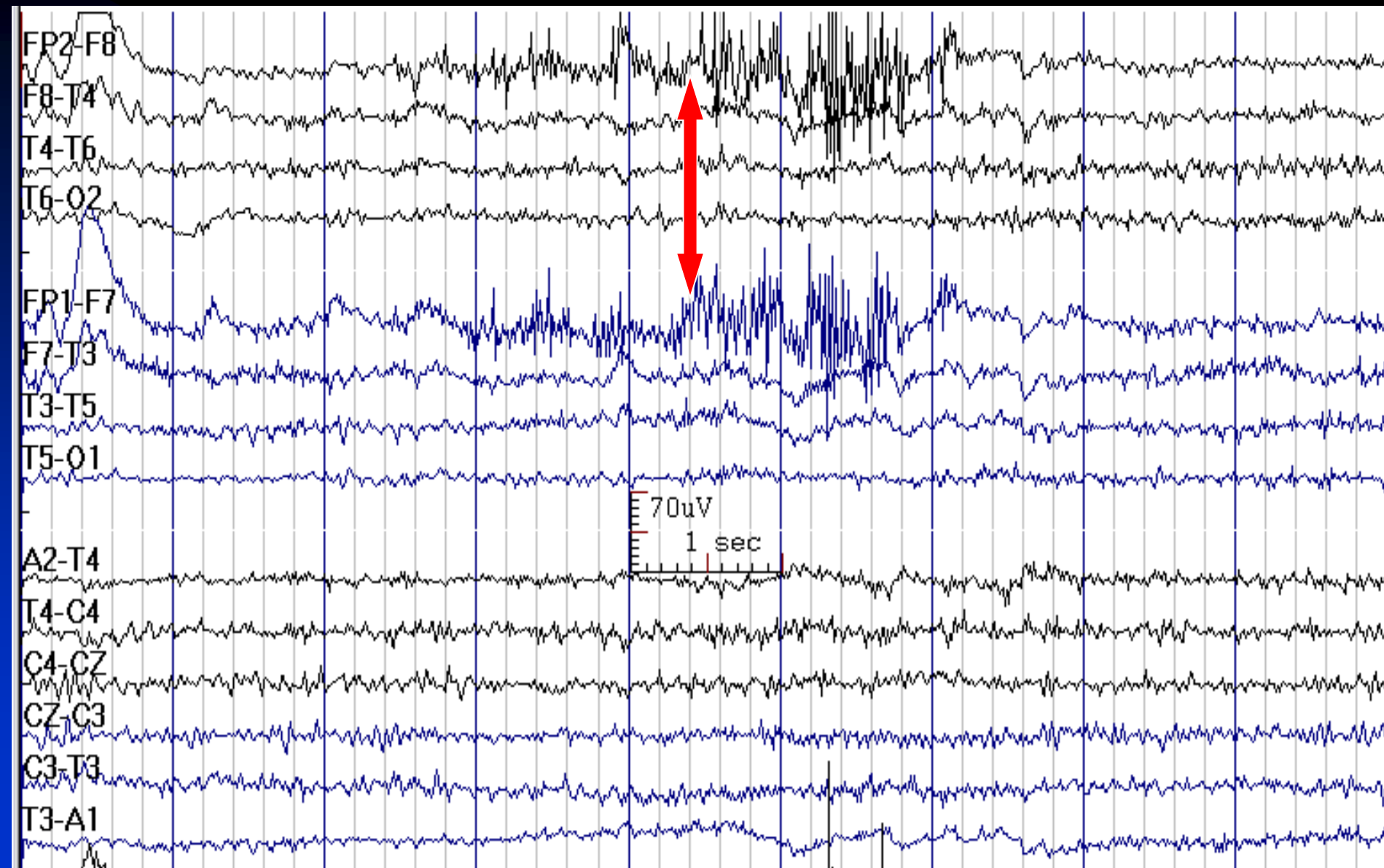
# Unilateral Eye Movement Artifact (Right Eye is Enucleated)



# Muscle (EMG) and Glossokinetic Artifacts

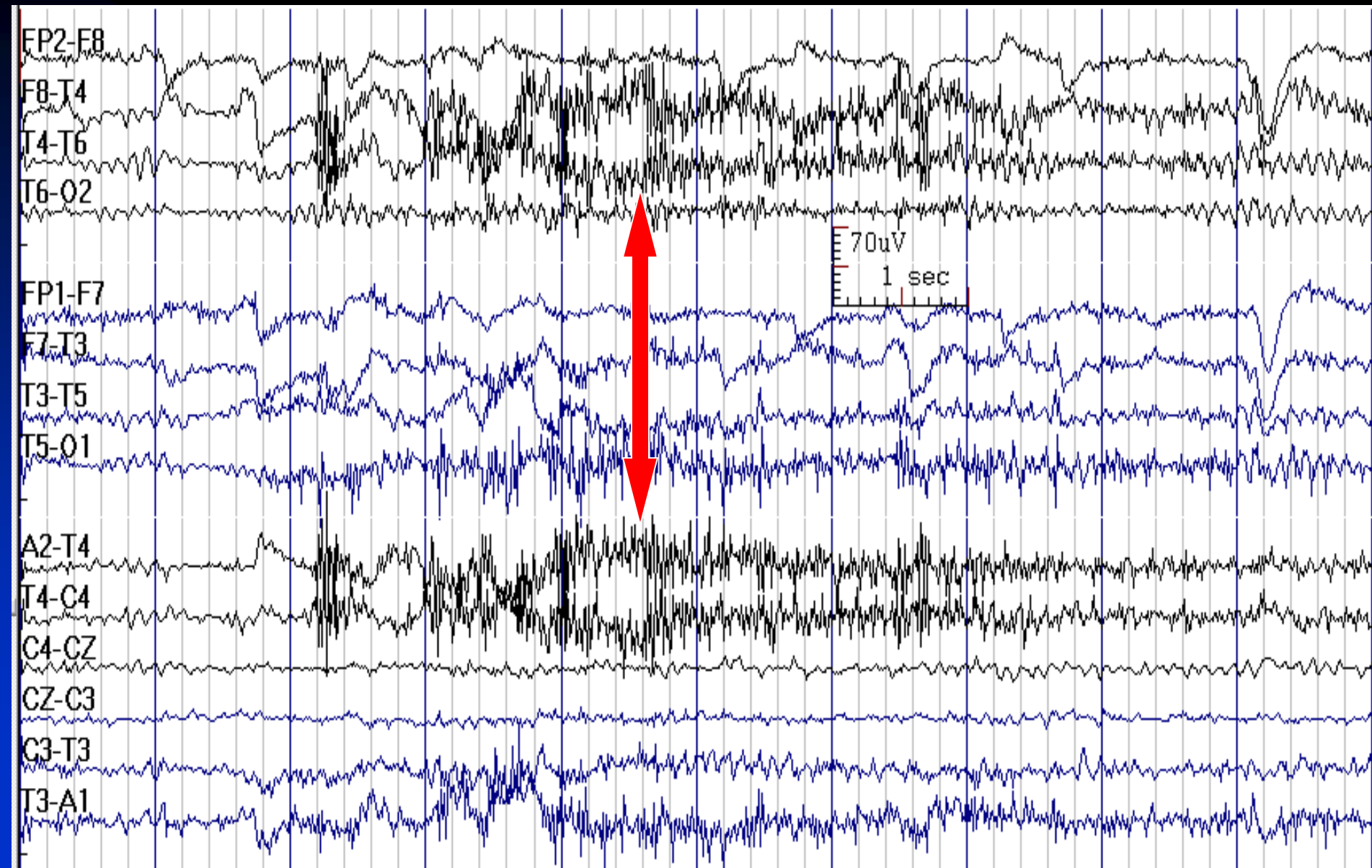
- **EMG:** muscle contraction usually produces very high frequency (>50 Hz) variable amplitude artifact in overlying or adjacent electrodes in scalp EEG
  - ◆ Duration less than 15 msec
  - ◆ Maximal amplitude in electrode contacts over muscles, may display field spread to adjacent contacts
- **Glossokinetic:** due to tongue movement (dipole: tip of the tongue is more negative than base), low frequency, maximal in temporal leads, unilateral or bilateral, may be associated with muscle artifact

# Muscle (EMG) Artifact (Frontalis Muscle)



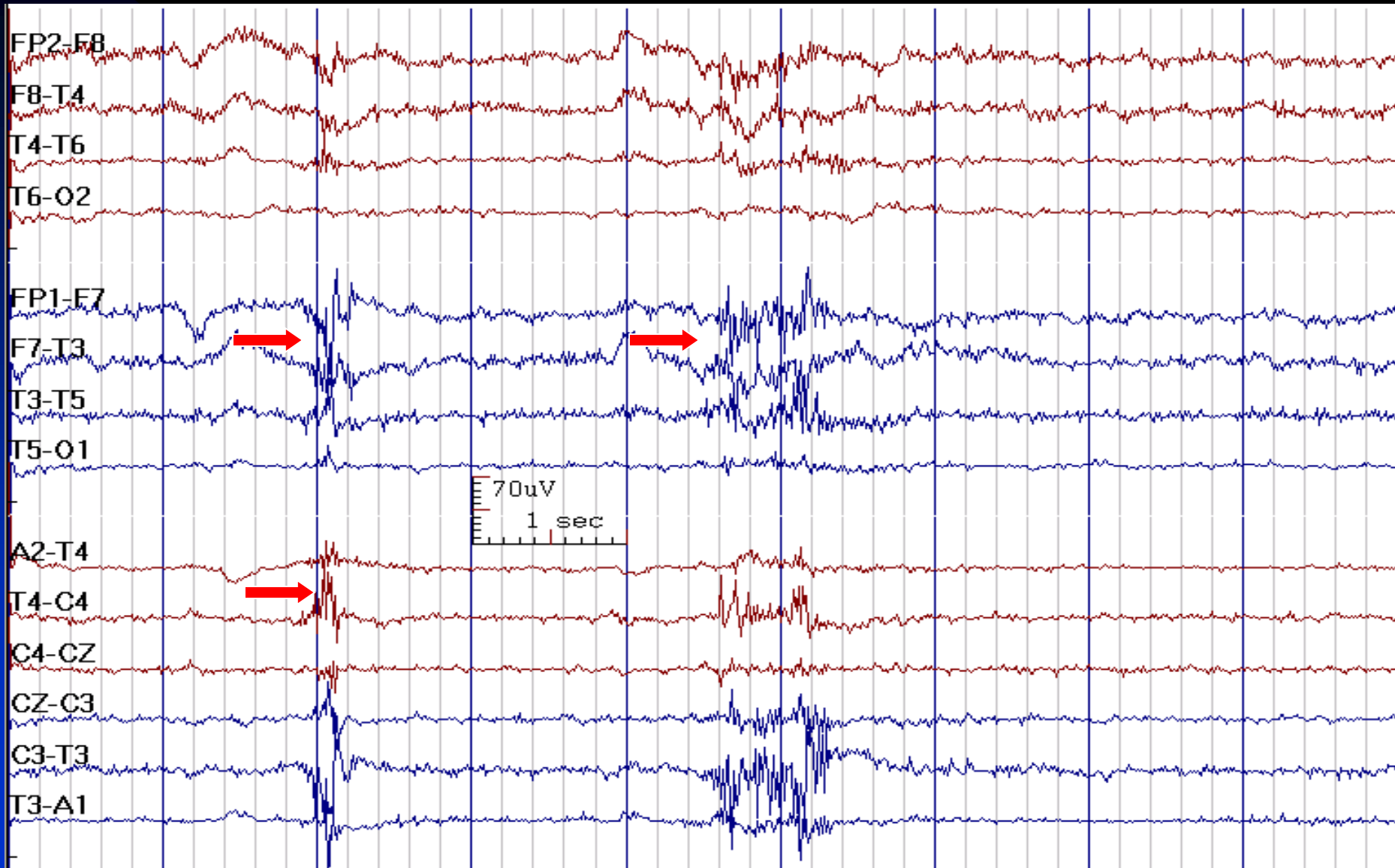


# Muscle (EMG) Artifact (Temporalis Muscle)

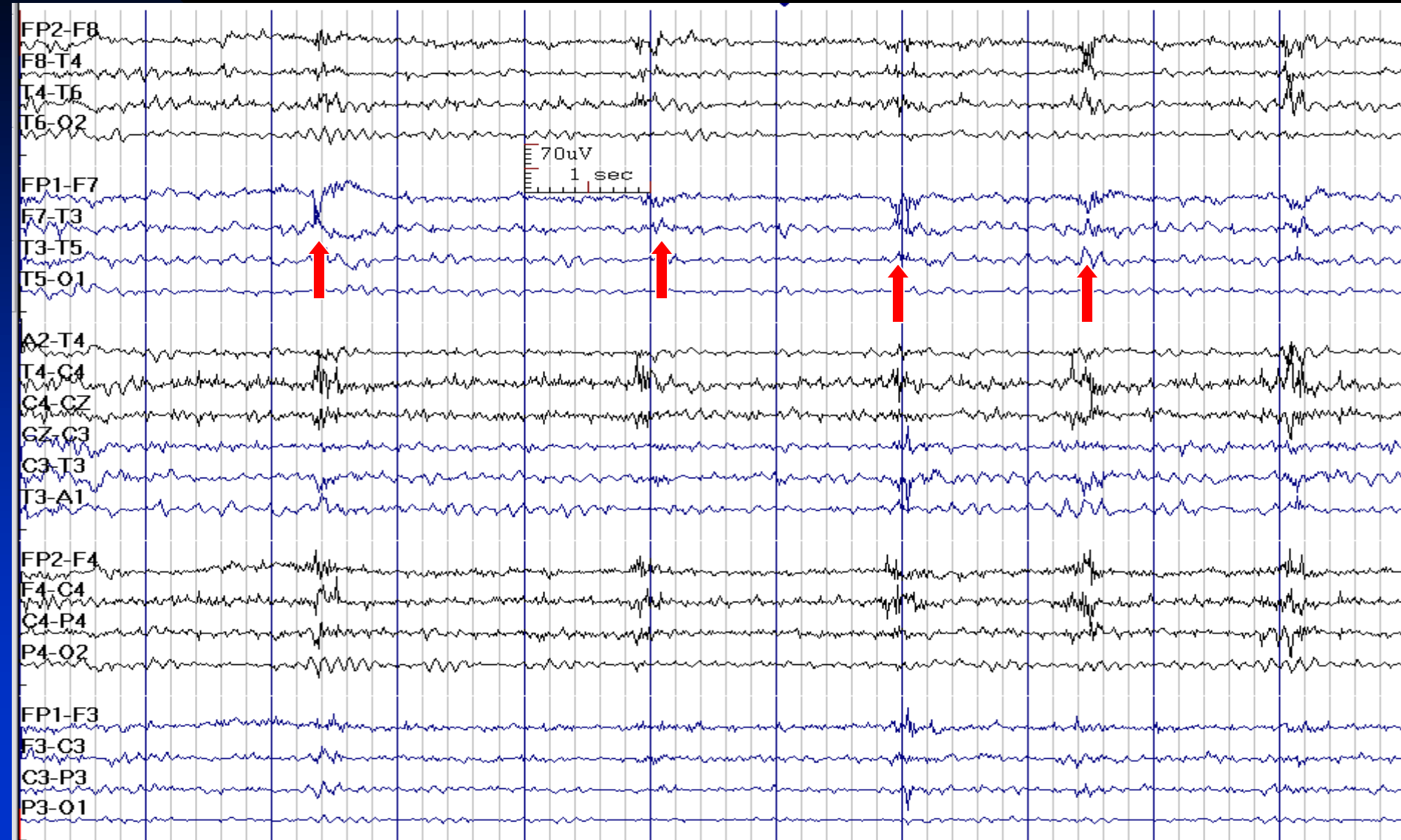




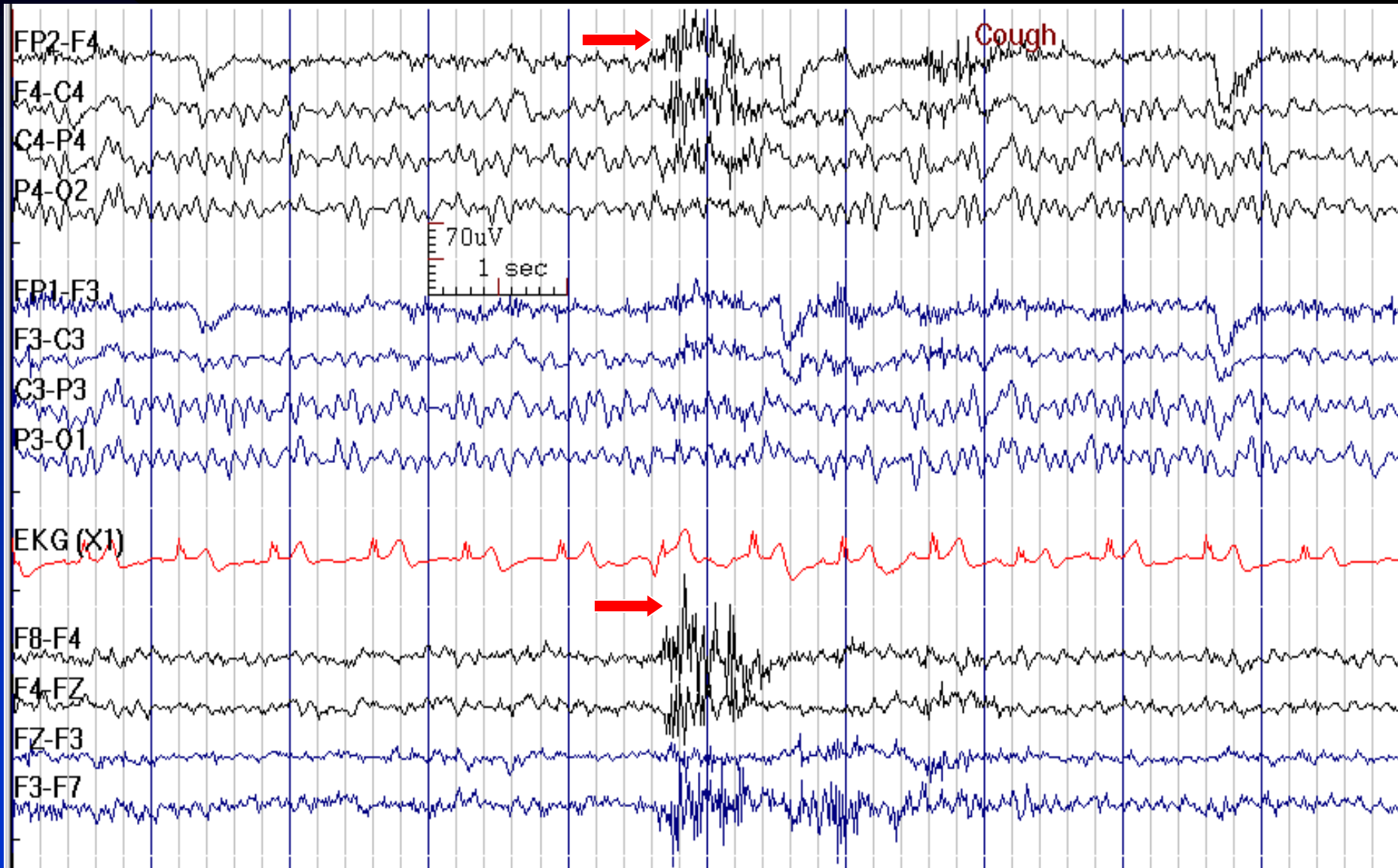
# Muscle (EMG) and Glossokinetic Artifacts



# Repeated Glossokinetic Artifacts in a 81-Year-Old Woman



# Cough with Glossokinetic Artifact

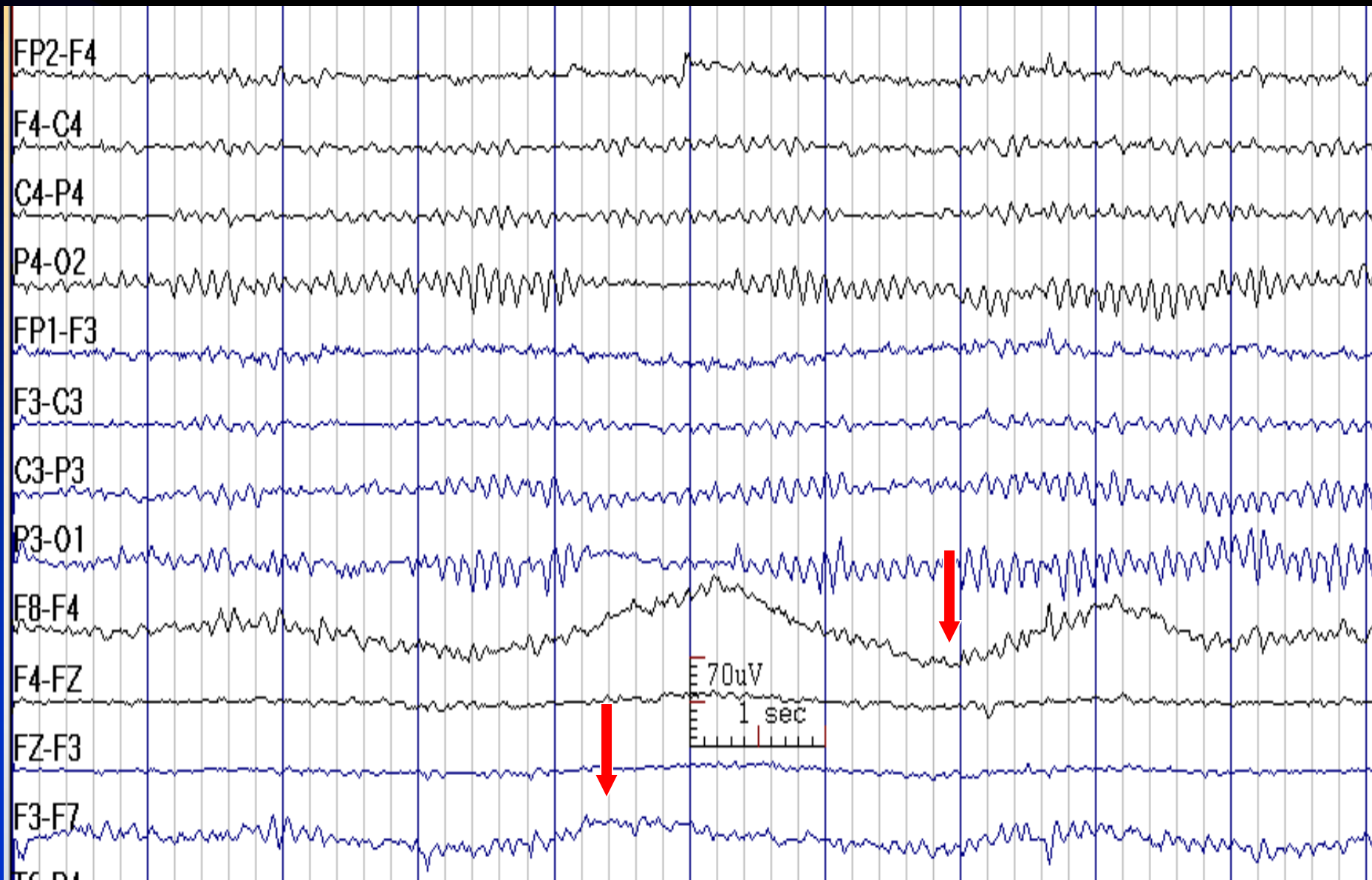


# Sweat Artifact

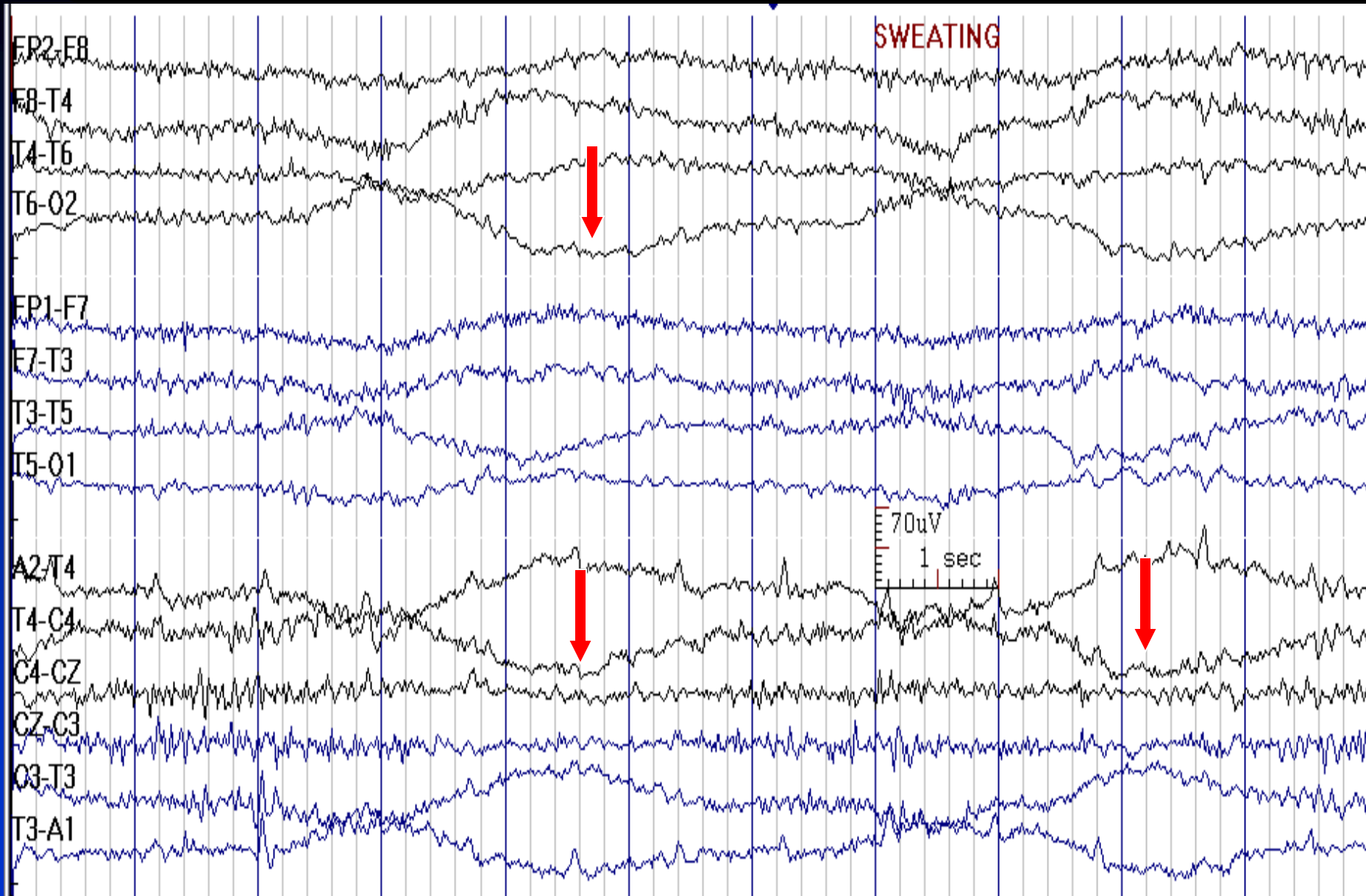
## (Galvanic Skin Response)

- Sweating during the EEG produces large and very slow ( $< 0.5$  Hz) potential shifts with bizarre fields inconsistent with cerebral activity
- They may be similar to eye rolling artifact, but are not maximum at F7/F8 and do not show the right-left phase reversal characteristic of horizontal eye movements

# Sweat Artifact

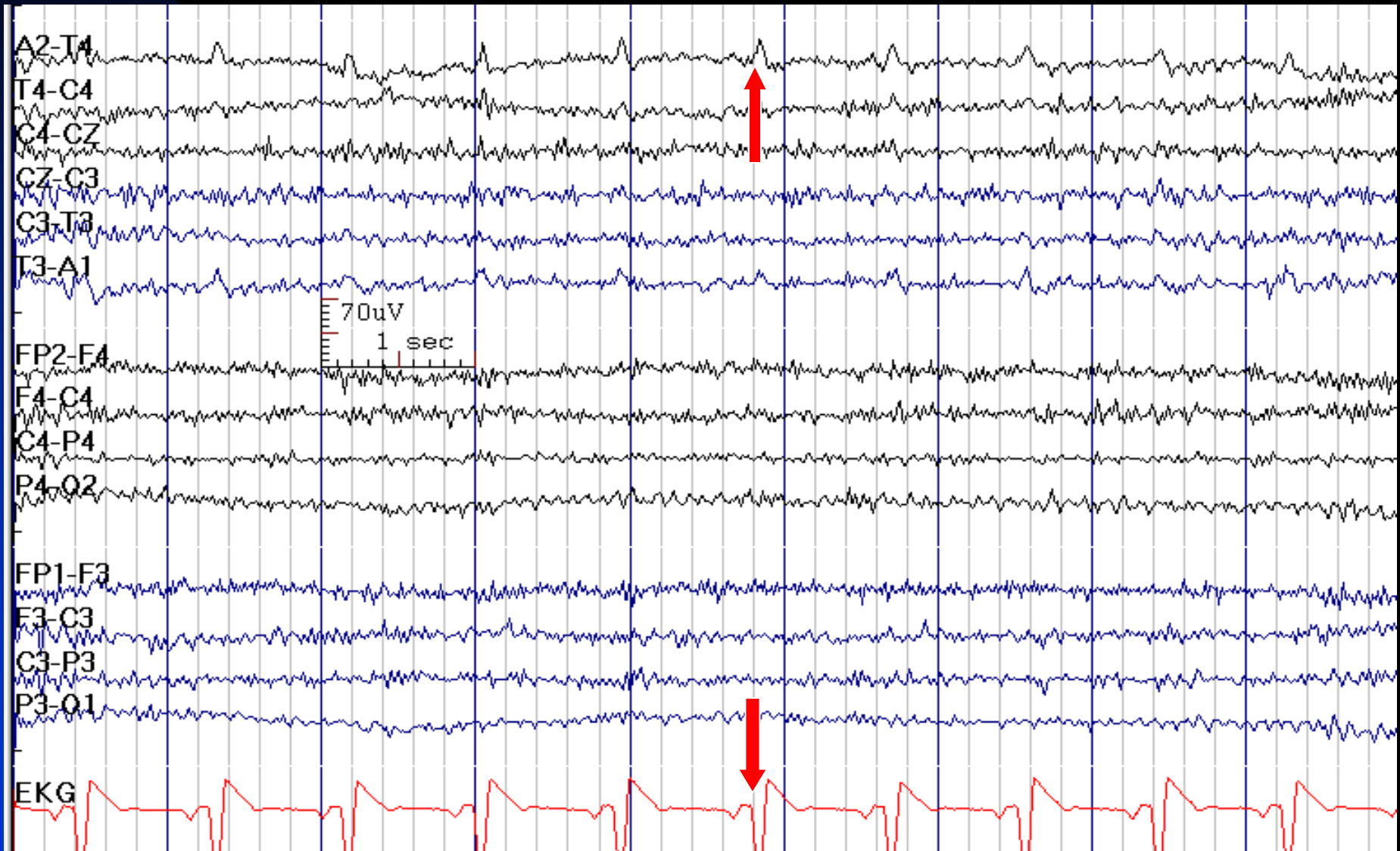


# Sweat Artifact

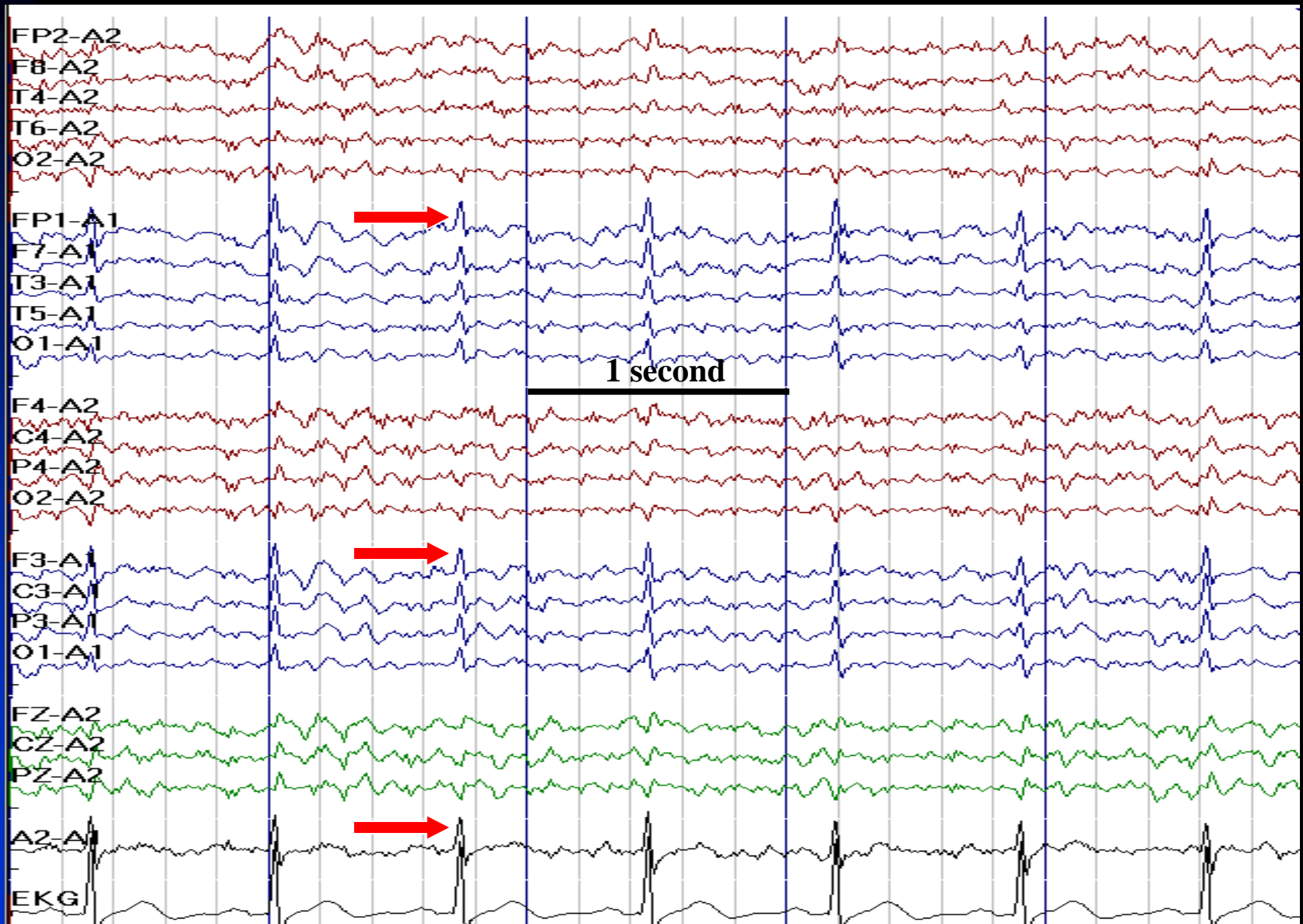




# EKG Artifact is Usually Most Apparent in the Ear Electrodes

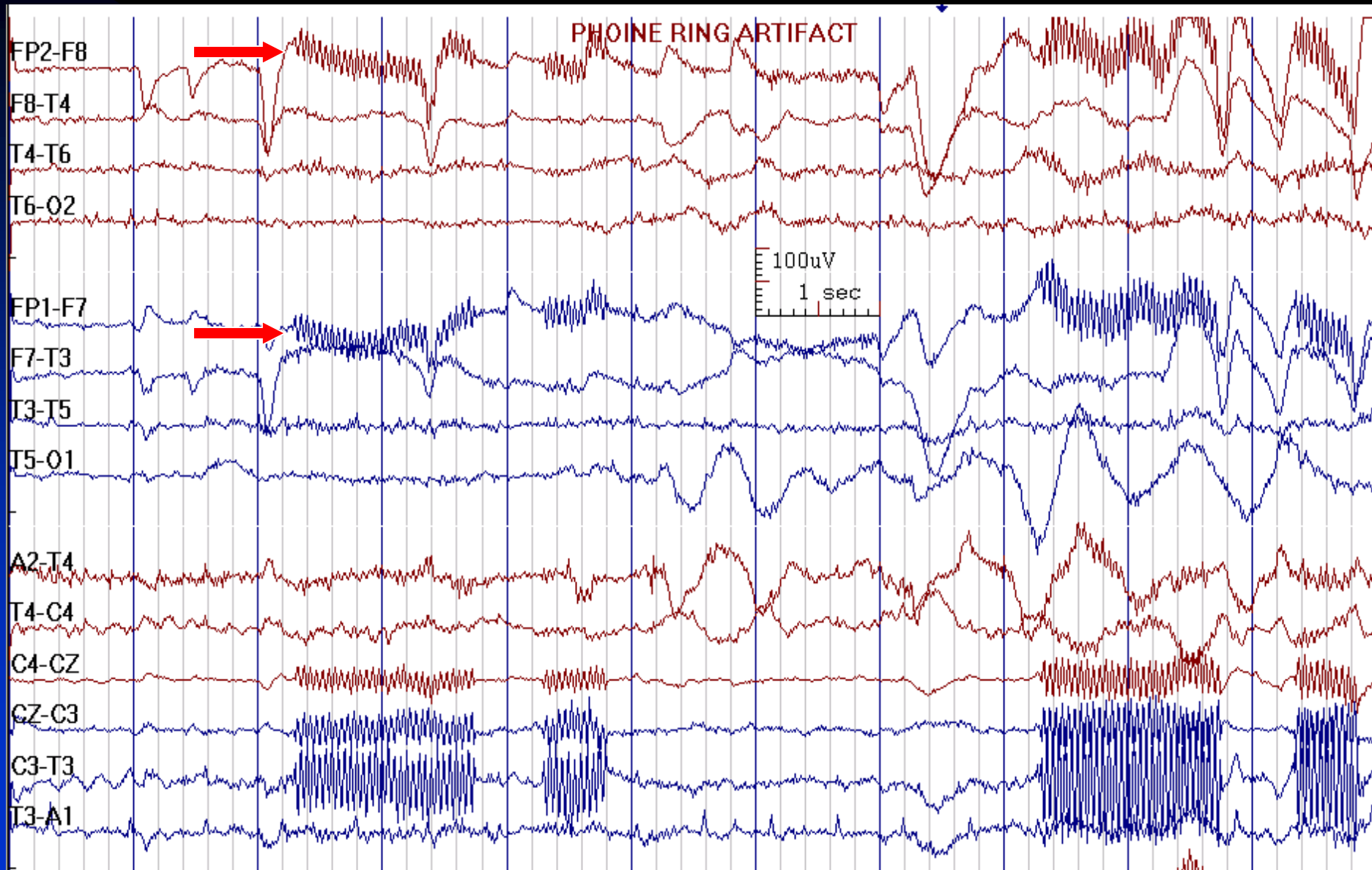


# EKG Artifact Looks Like Sharp Waves





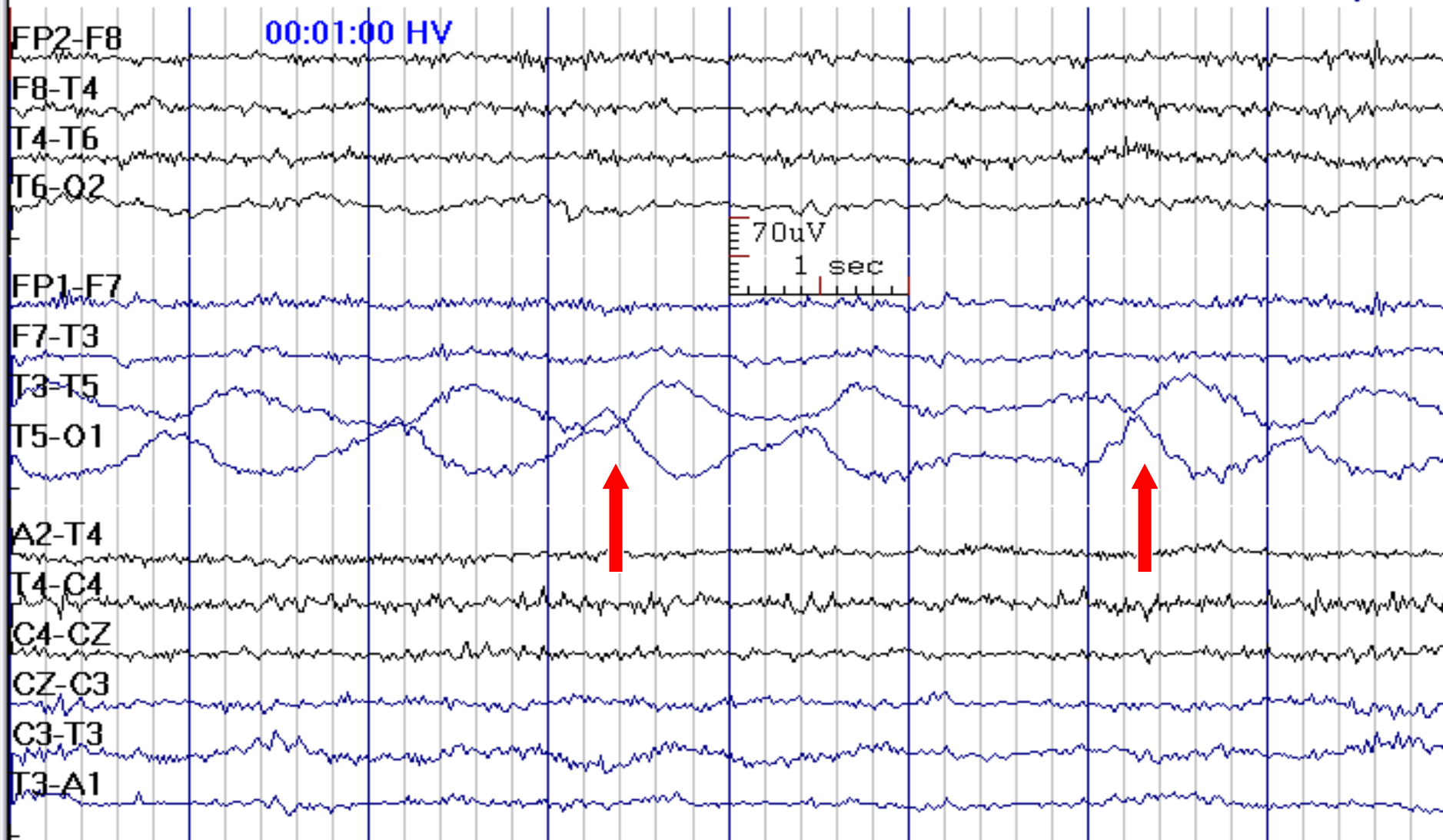
# Phone Ring Artifact (Prominent 20 Hz Artifact)



# Electrode Artifacts

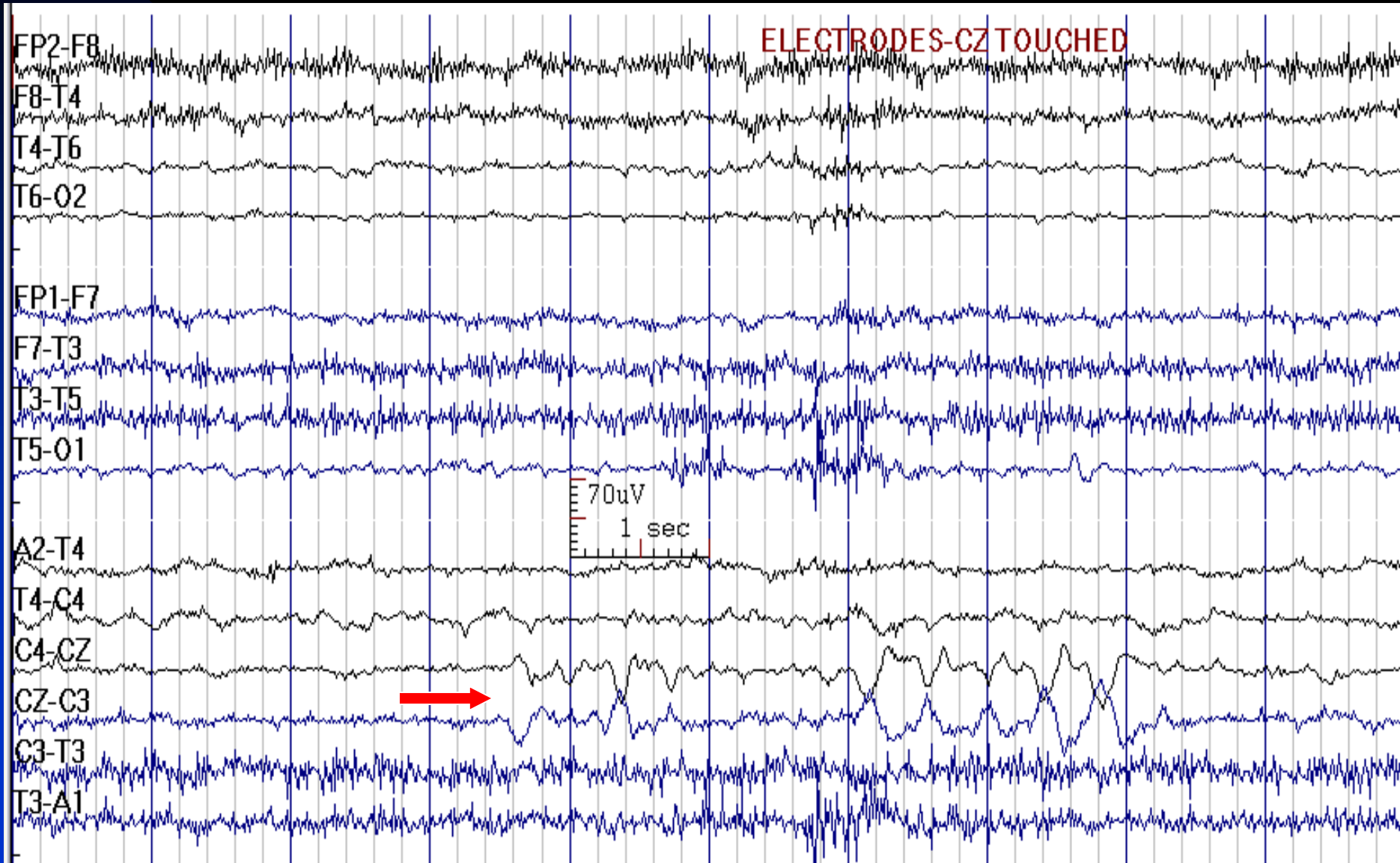
- Any unusual event that is confined to a single or common electrode must be considered artifactual when reading scalp EEG
- Note the electrode artifact the first time it occurs, try to fix it the second time and replace the electrode if it recurs

# Head Movements Artifact Looks Like Rhythmic Delta in Left Posterior Quadrant

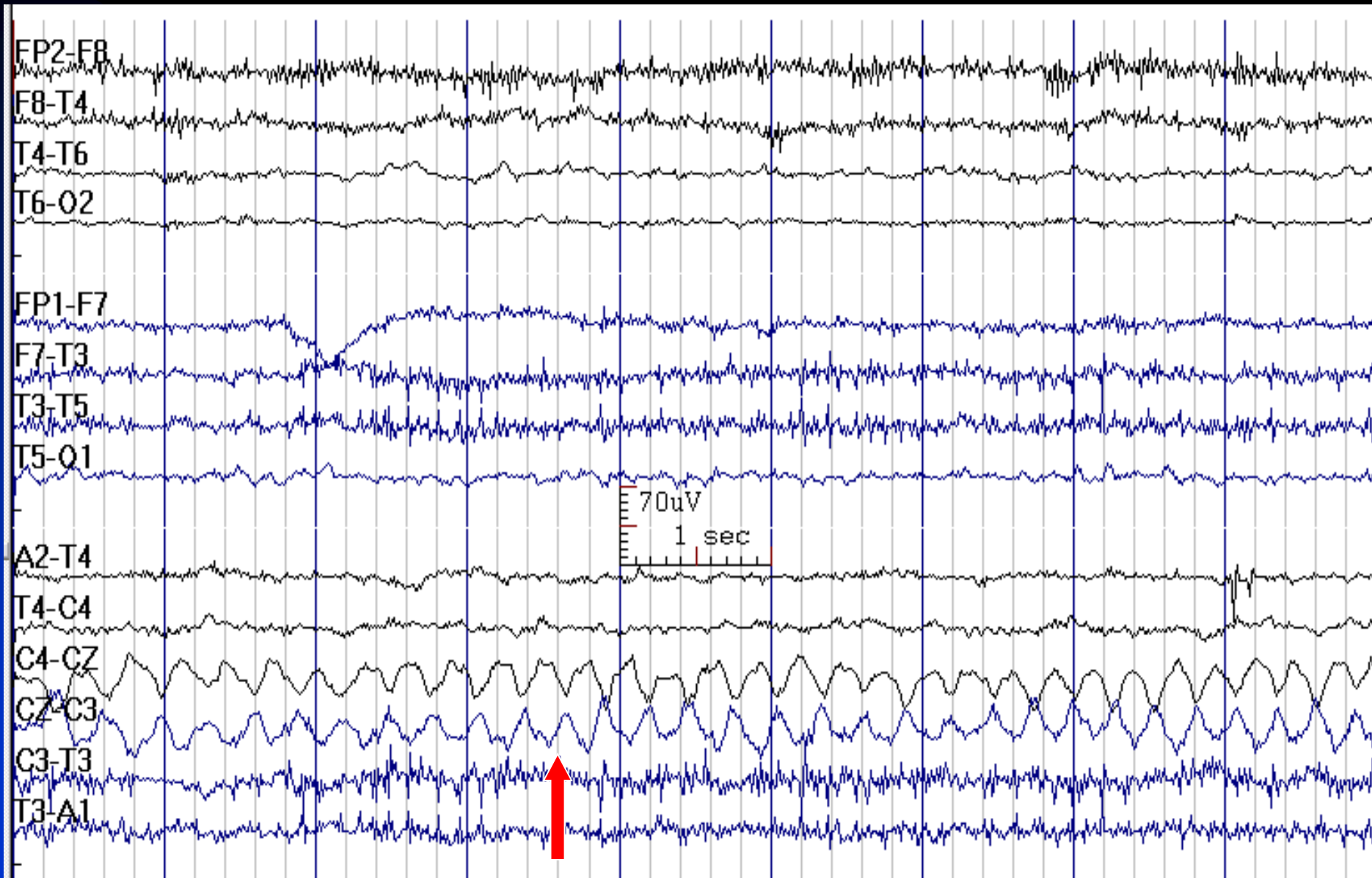


# Electrode Artifact at Cz: Electrode Touched

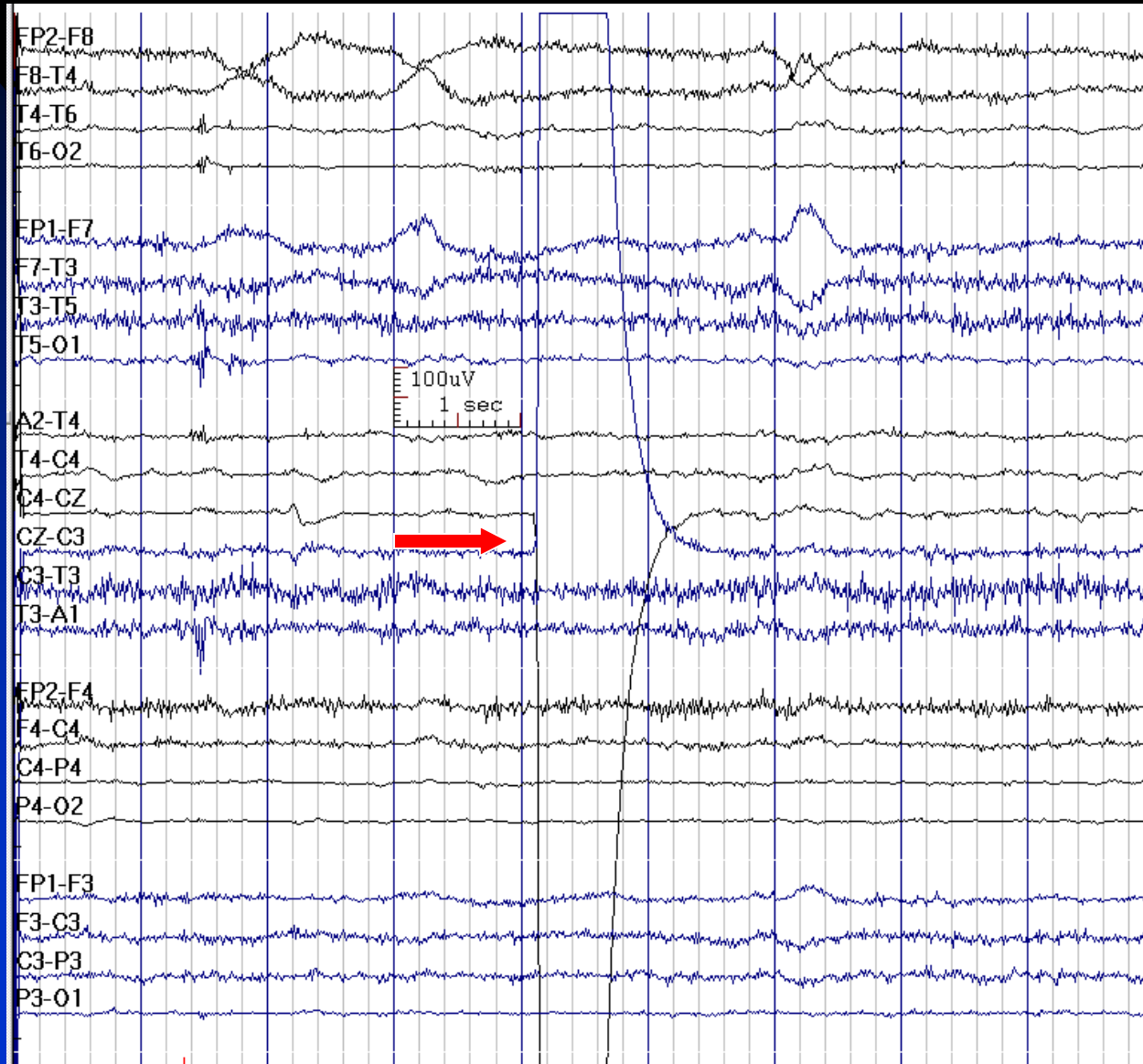
(Could be Mistaken for Vertex Waves)




# Cz Wire Swinging, Mimicking a Seizure



# Cz Electrode Pop Artifact (Capacitance Discharge)



# Jack Box Unplugged



# **Chapter 6**

## **Normal EEG Variants**



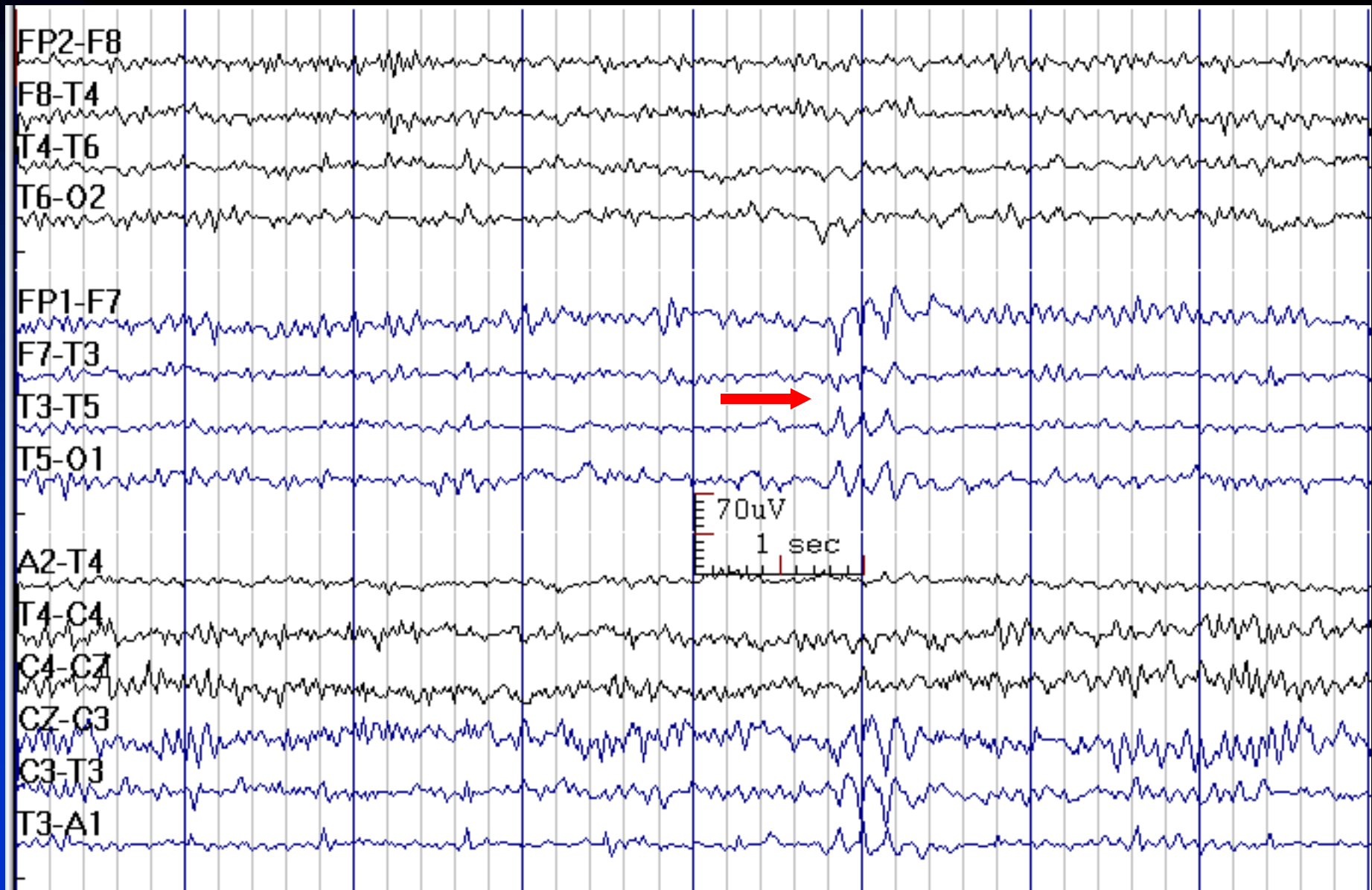
# Benign EEG Patterns

- Rhythmic mid-temporal theta of drowsiness (RMTD)
- Wicket rhythm & spike
- Benign epileptiform transients of sleep (BETS)
- Lambda Waves
- Midline theta
- Temporal slow waves in the elderly
- Alpha variants

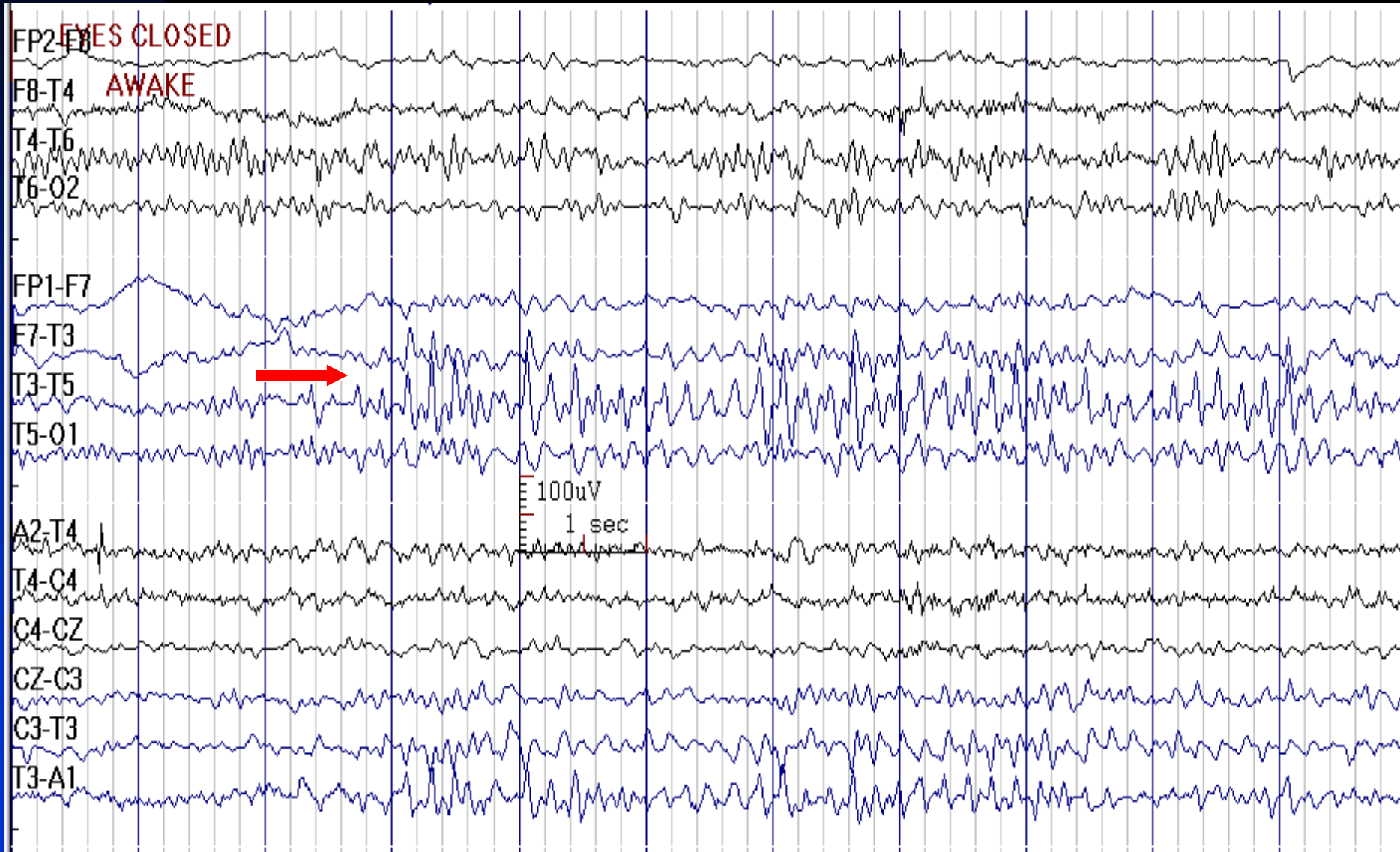
# Rhythmic Mid-Temporal Theta of Drowsiness (RMTD)

- **Frequency:** 5-7 Hz
- **Distribution:** bilateral temporal, independently, field may include parasagittal regions
- **Characteristics:** intermittent monorhythmic and monomorphic theta in trains (lasting up to 10 seconds), frequently notched or flat-topped (arceaux)
- **State:** relaxed wakefulness, drowsiness
- **Age:** adolescents, adults
- **Other names:** Psychomotor variant, Rhythmic Mid-Temporal Discharge

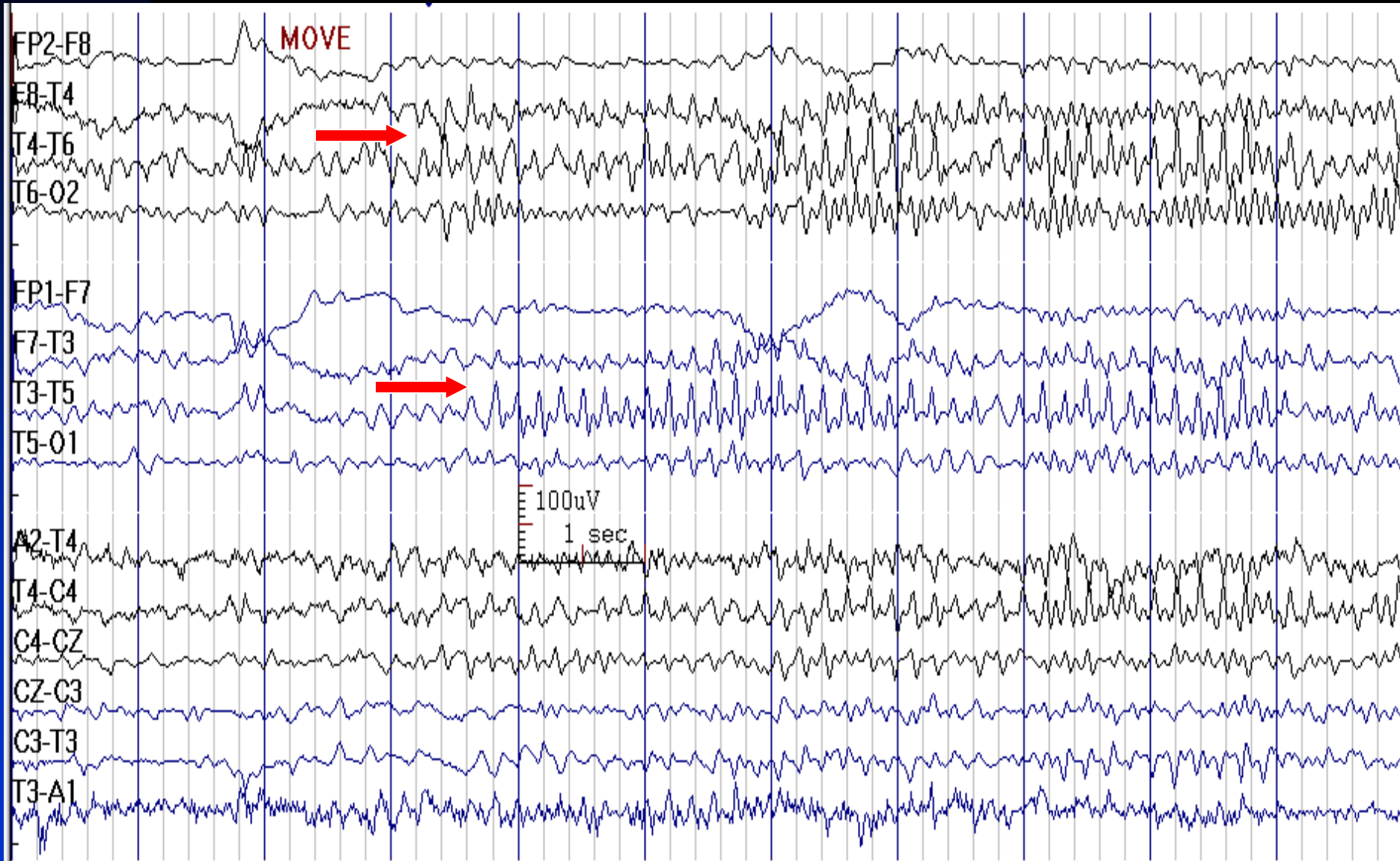
# Rhythmic Mid-Temporal Theta of Drowsiness



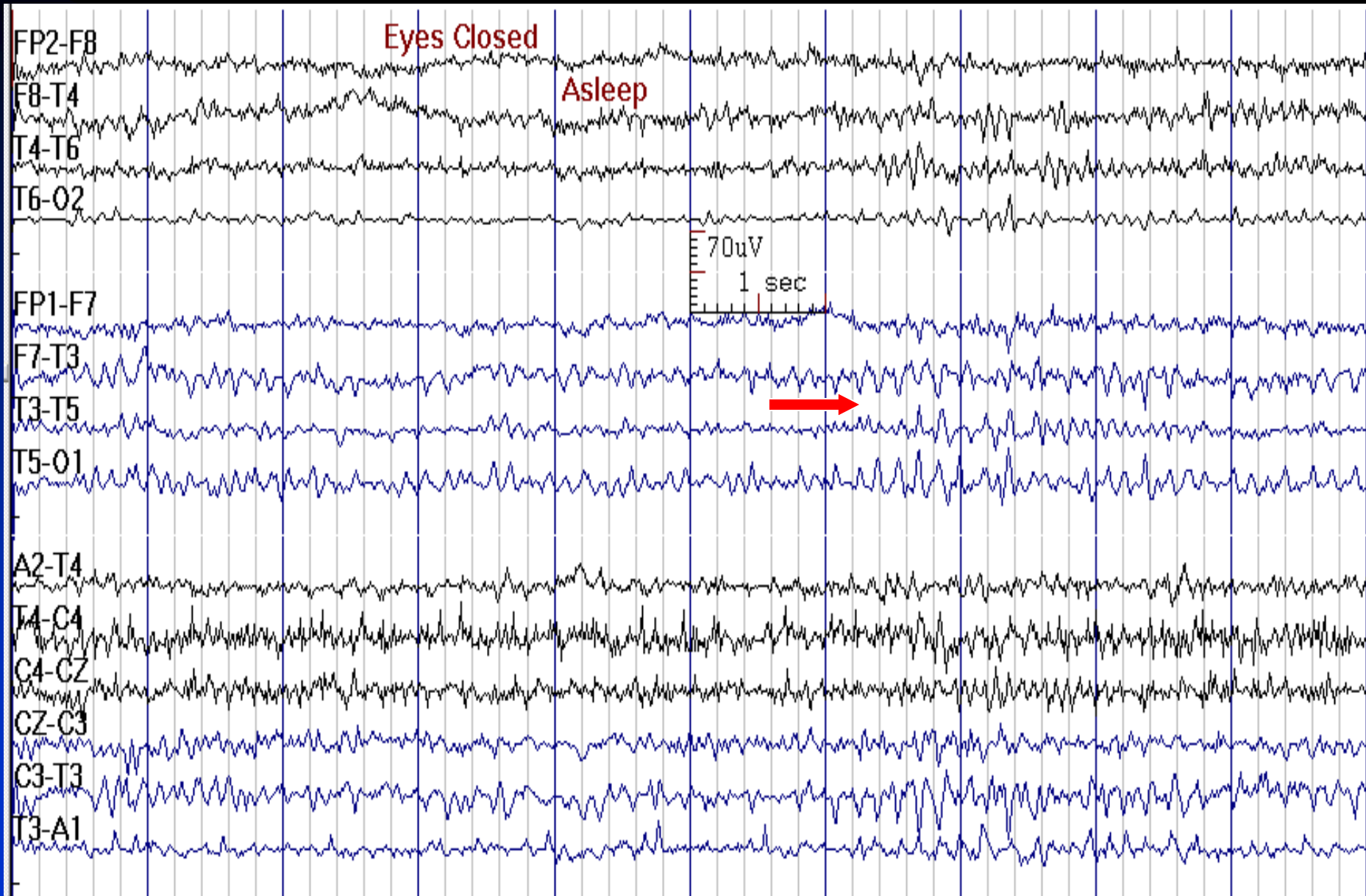
# Rhythmic Mid-Temporal Theta of Drowsiness



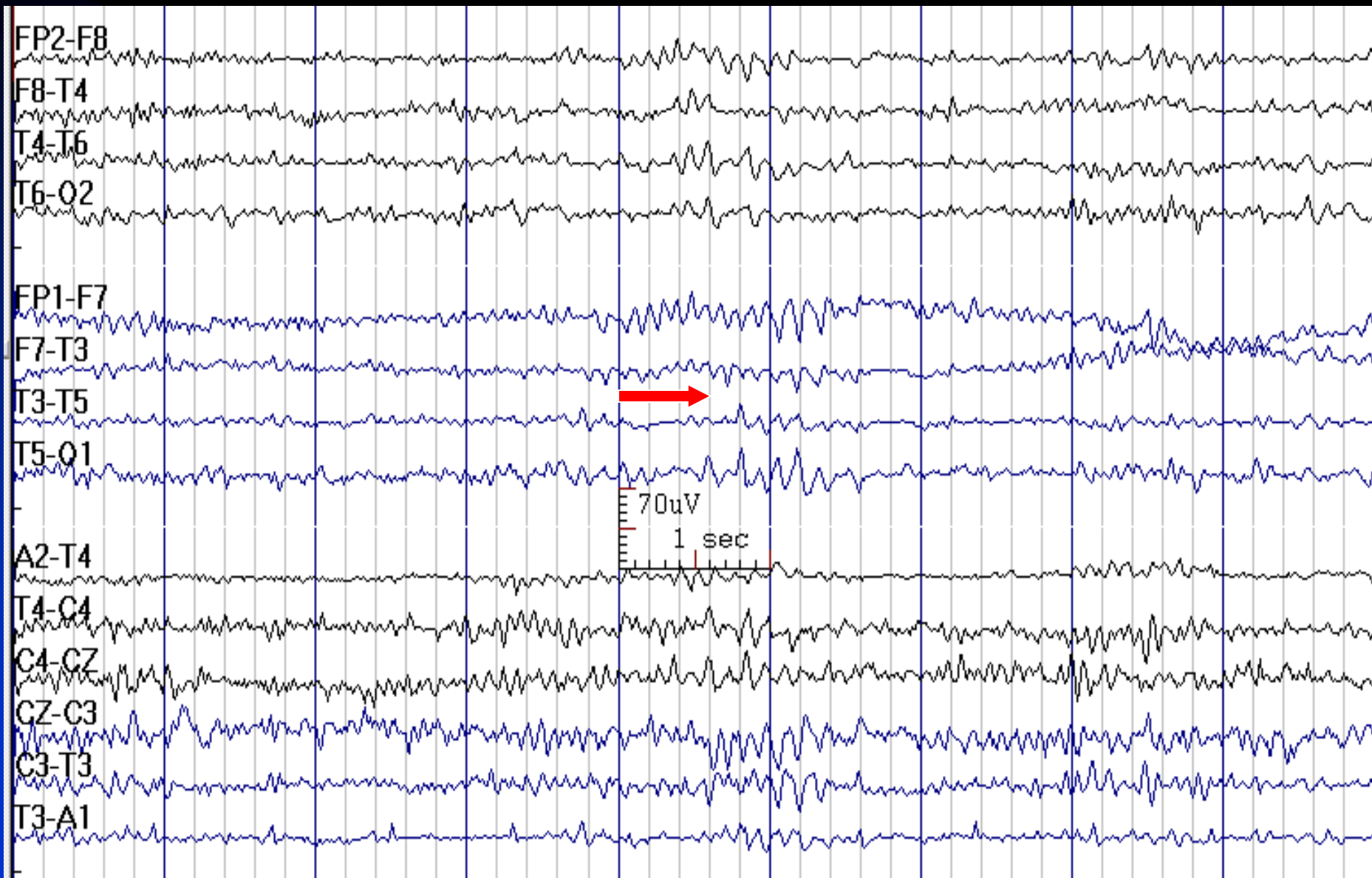
# Rhythmic Mid-Temporal Theta of Drowsiness



# Rhythmic Mid-Temporal Theta of Drowsiness

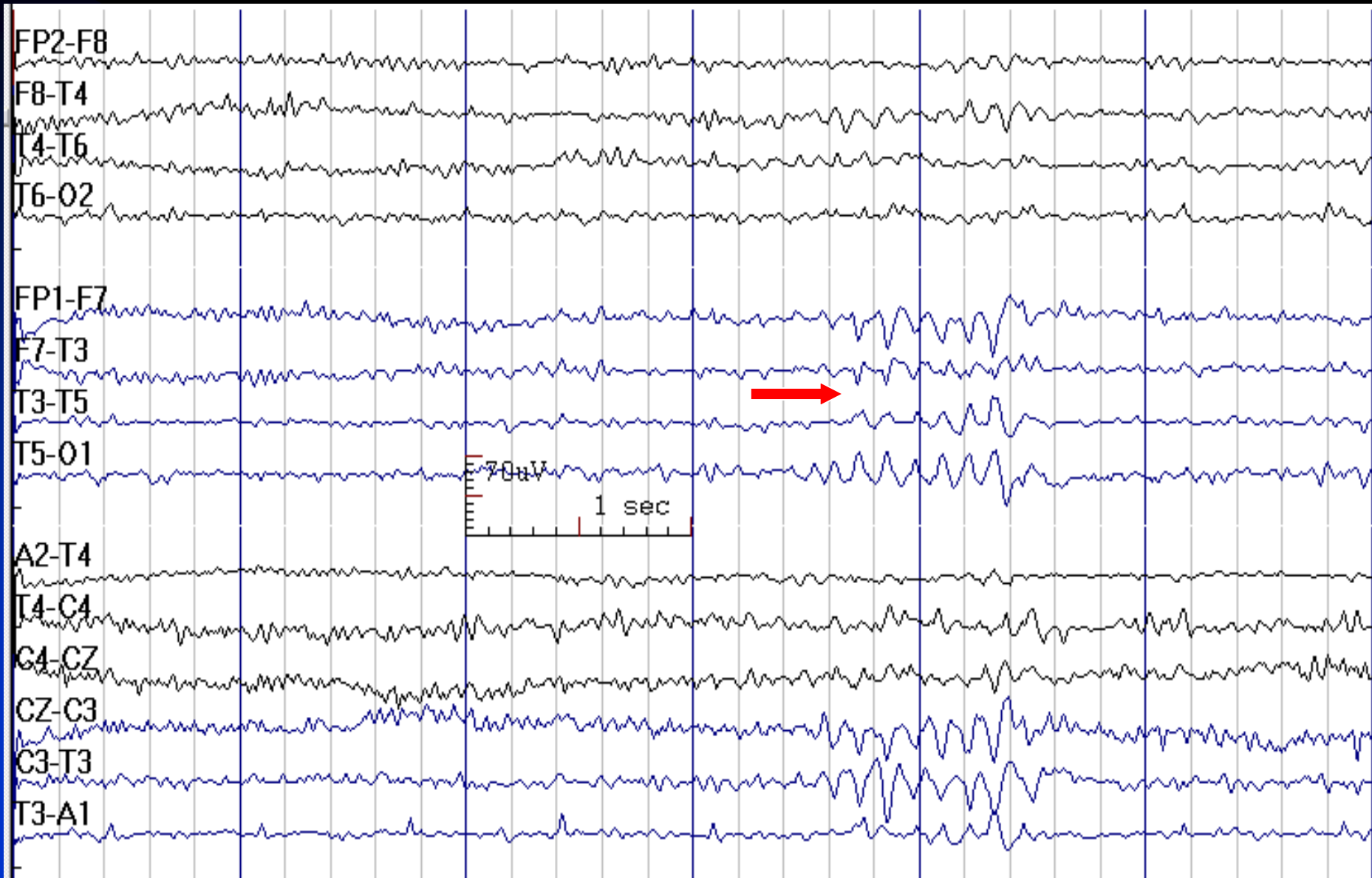


# Rhythmic Mid-Temporal Theta of Drowsiness





# Rhythmic Mid-Temporal Theta of Drowsiness

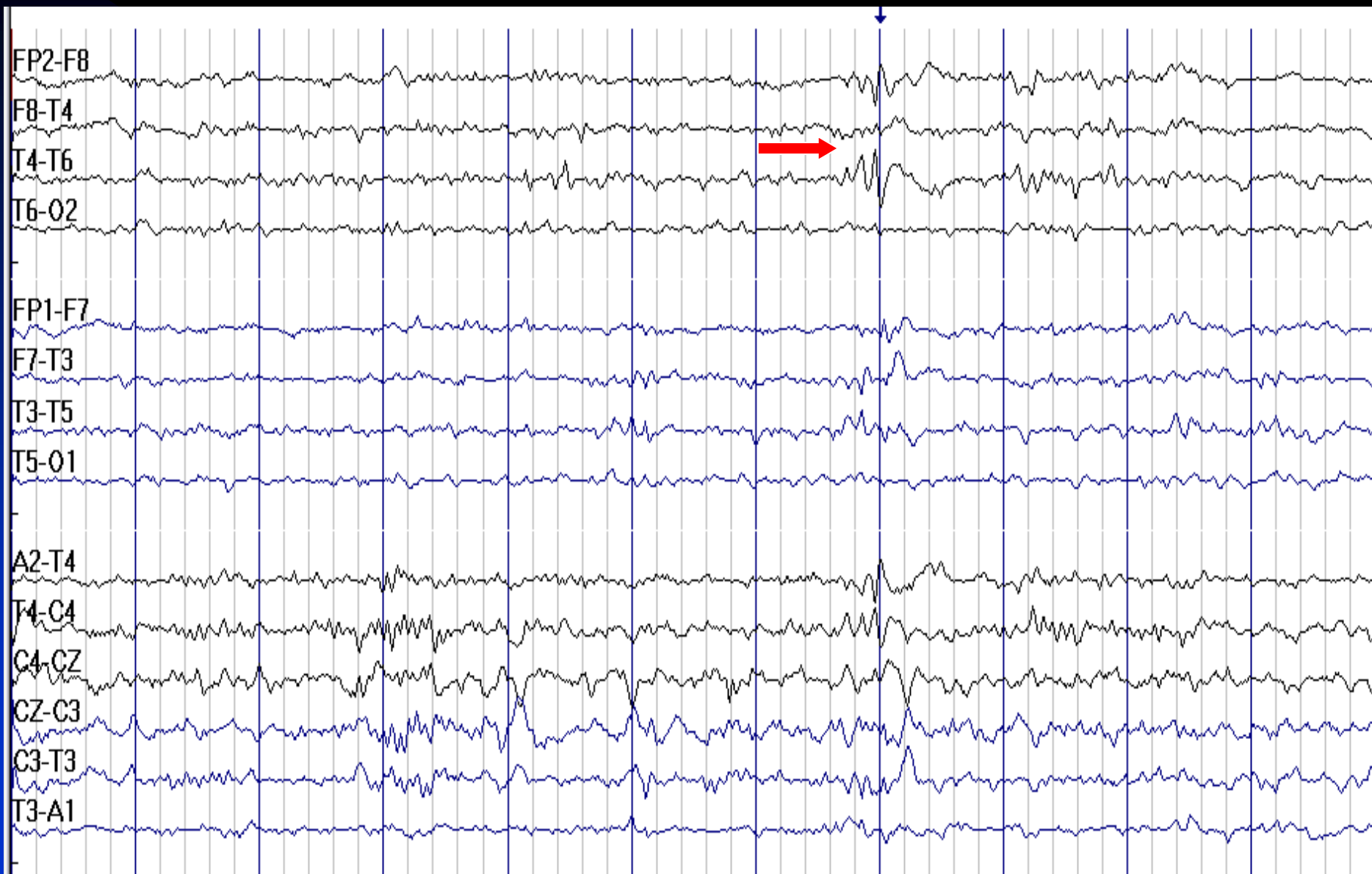




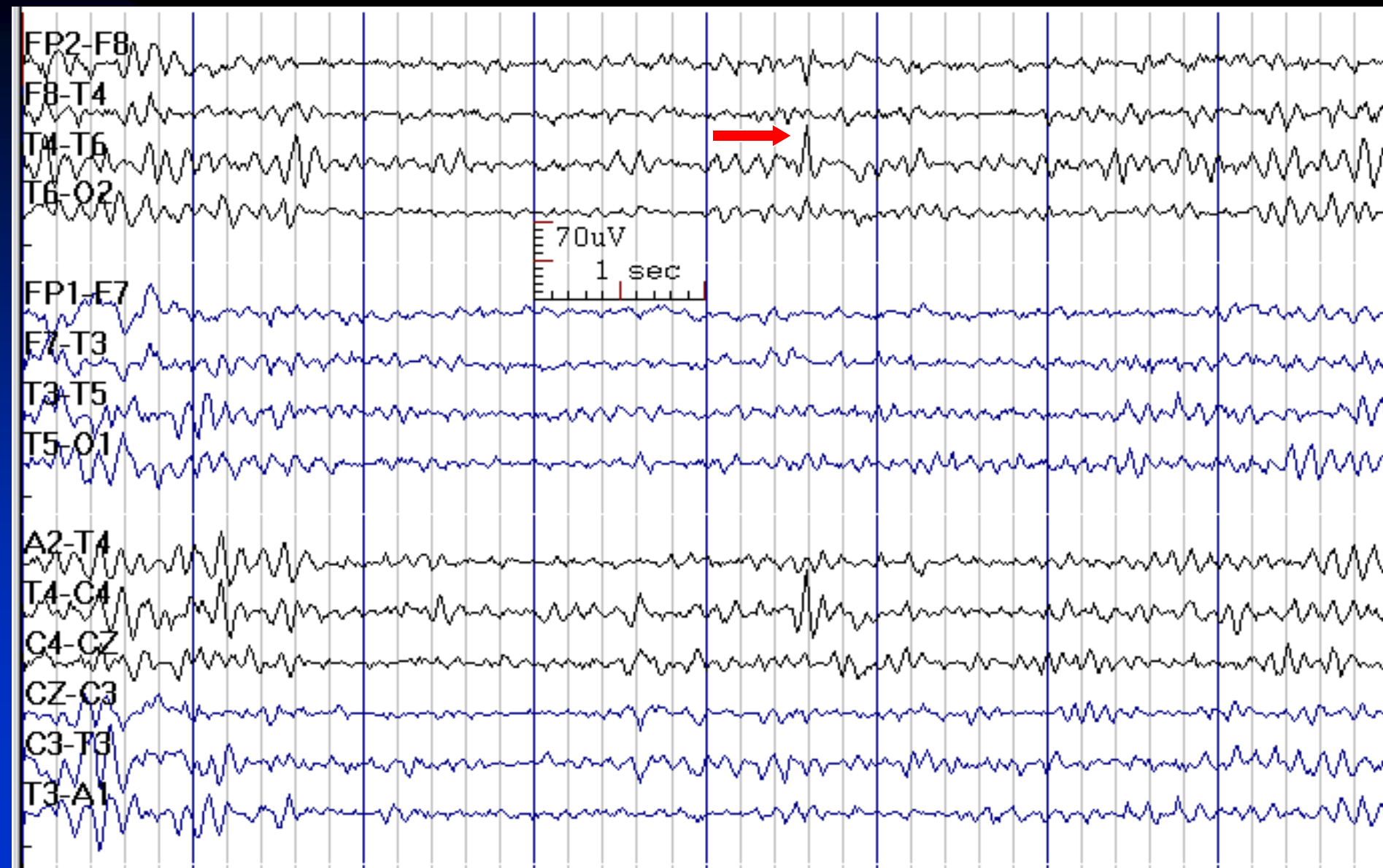
# Wicket Rhythm / Spike

- **Activity:** 8-11 Hz, 60-200  $\mu$ V
- **Distribution:** bilateral temporal, independently
- **Characteristics:** monomorphic and monophasic trains or a single spike-like or arc-like transient, without distortion of background
- **State:** drowsiness, light sleep, rarely REM
- **Age:** adults older than 30 years

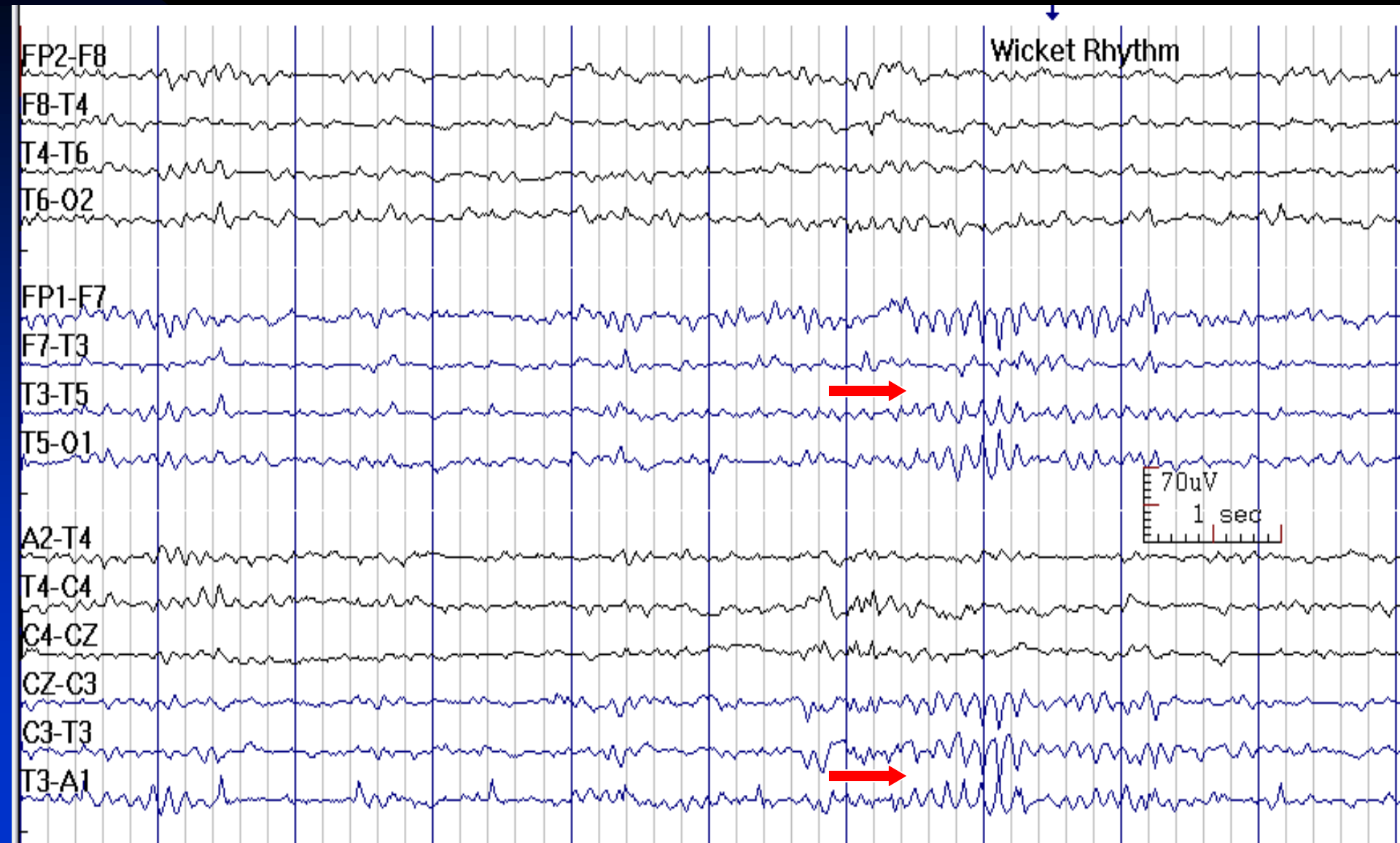
# Wicket Rhythm and Spike



# Wicket Spike at T4



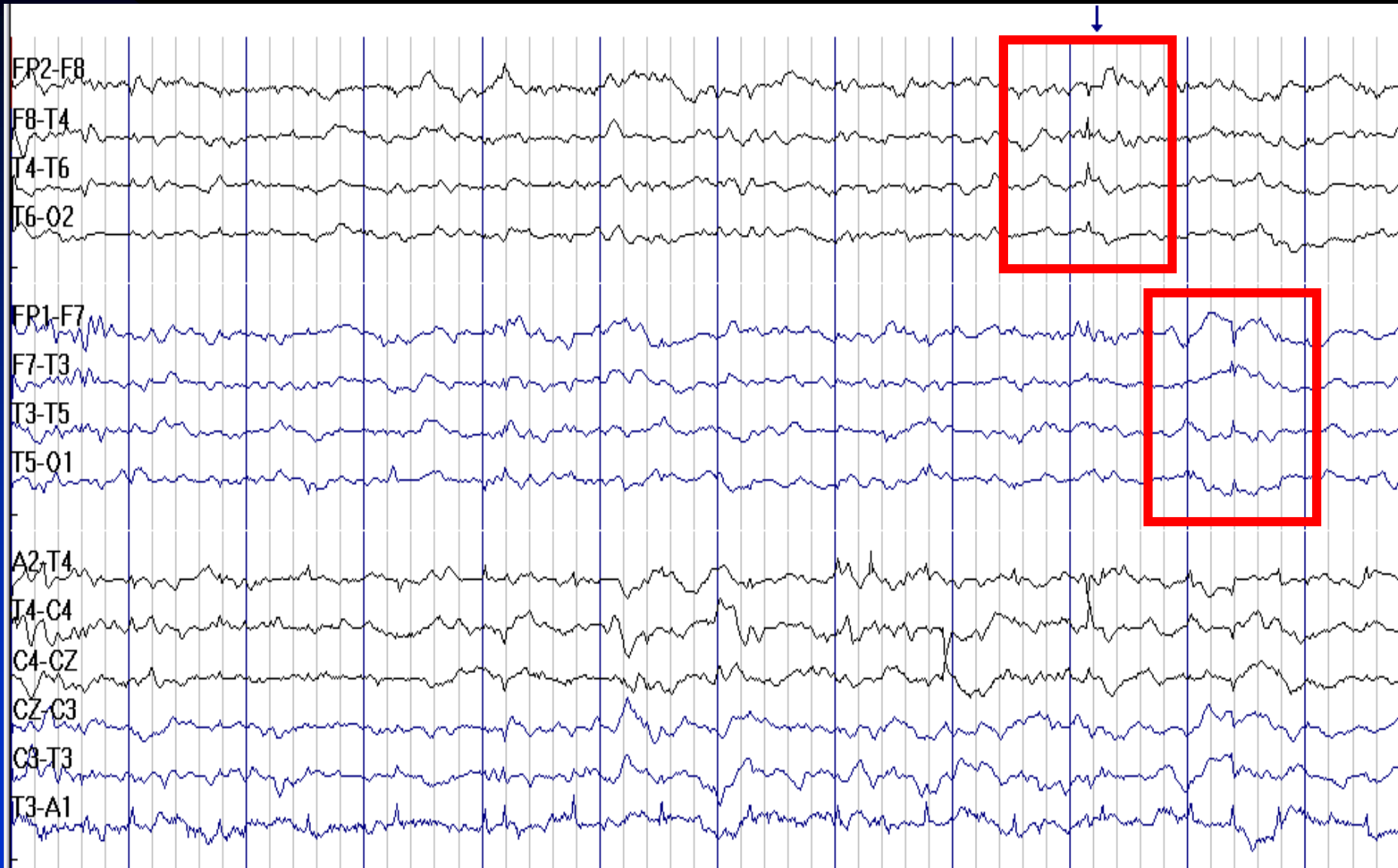
# Wicket Rhythm



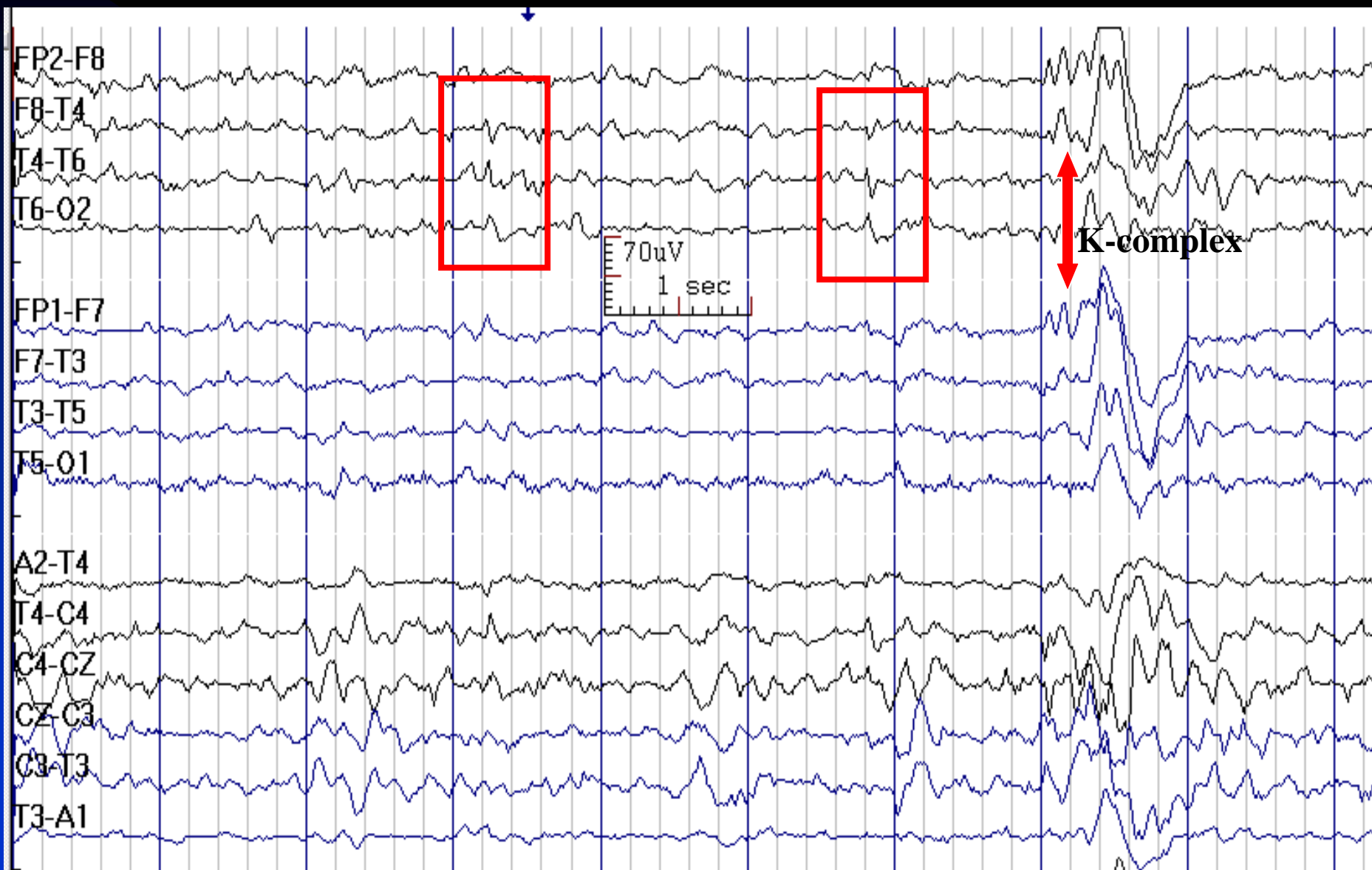# Benign Epileptiform Transients of Sleep (BETS)

- **Activity:** duration < 50 msec., amplitude usually < 50  $\mu$ V (may be higher in nasopharyngeal or sphenoidal leads)
- **Distribution:** bilateral temporal regions, independently with a broad field extending to occipital and frontal regions
- **Characteristics:** mono- or diphasic single small spike with a smaller following slow wave
- **State:** drowsiness, sleep stages 1 and 2
- **Age:** adults
- **Other names:** small sharp spikes, benign sporadic spikes of sleep

# Benign Epileptiform Transients of Sleep



# Benign Epileptiform Transients of Sleep (BETS)

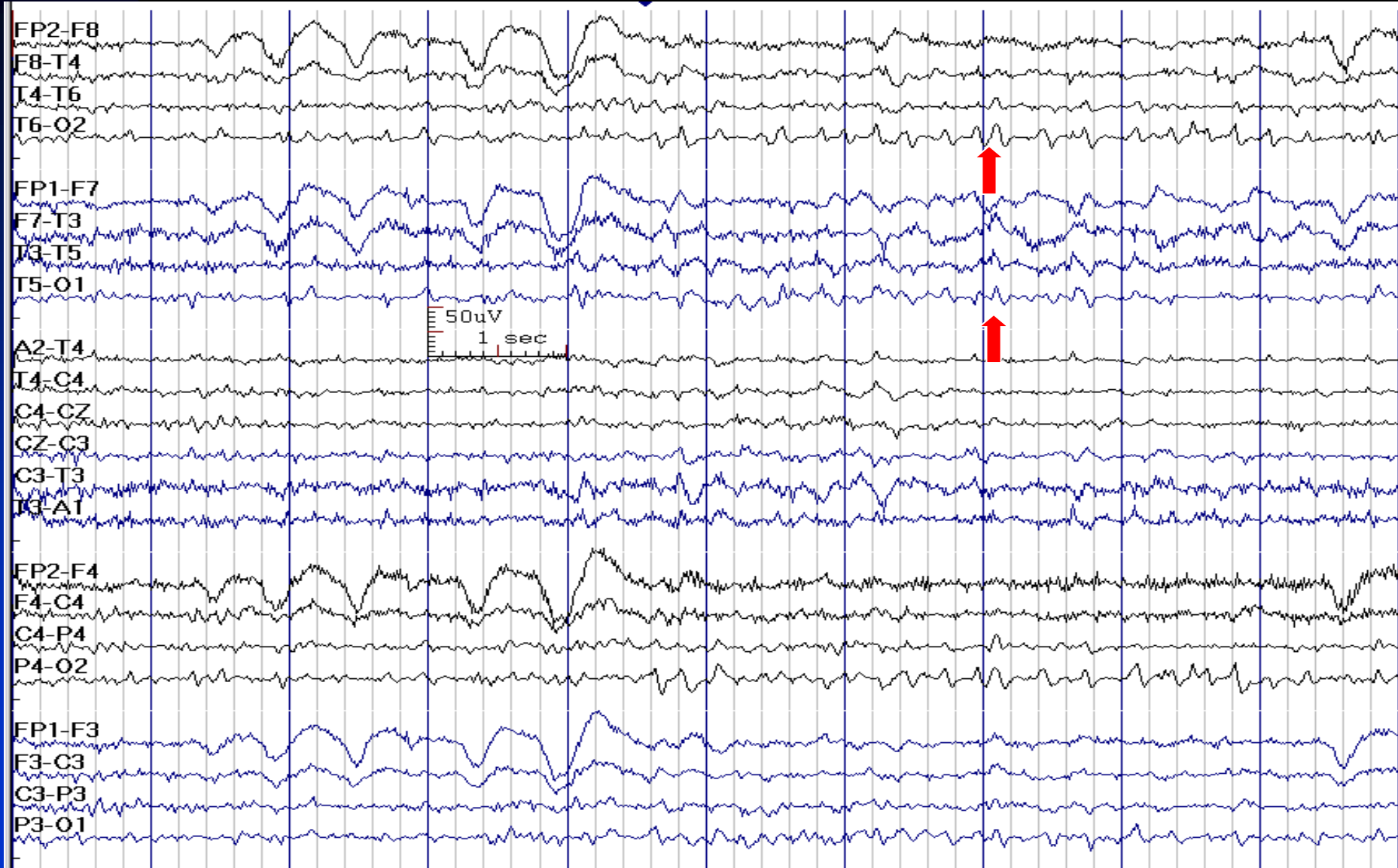


# Lambda Waves

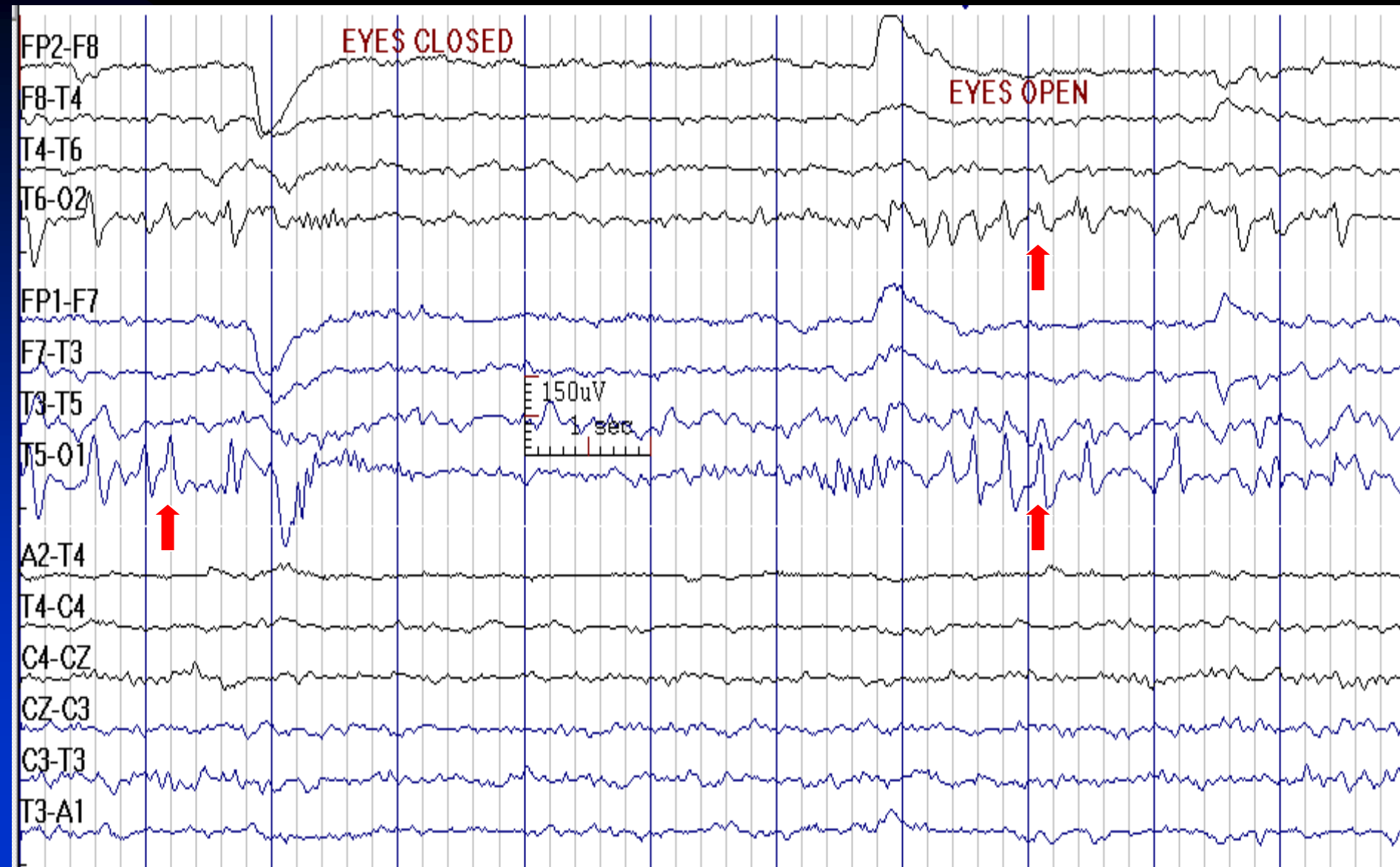
- **Duration:** 160-250 msec
- **Distribution:** bilateral occipital regions, could be asymmetric and unilateral
- **Characteristics:** biphasic or triphasic sharp transients with a small initial positive and a prominent subsequent negative phase
- **State:** awake, eyes open, scanning a complex picture, occurs with saccadic eye movements
- **Age:** children



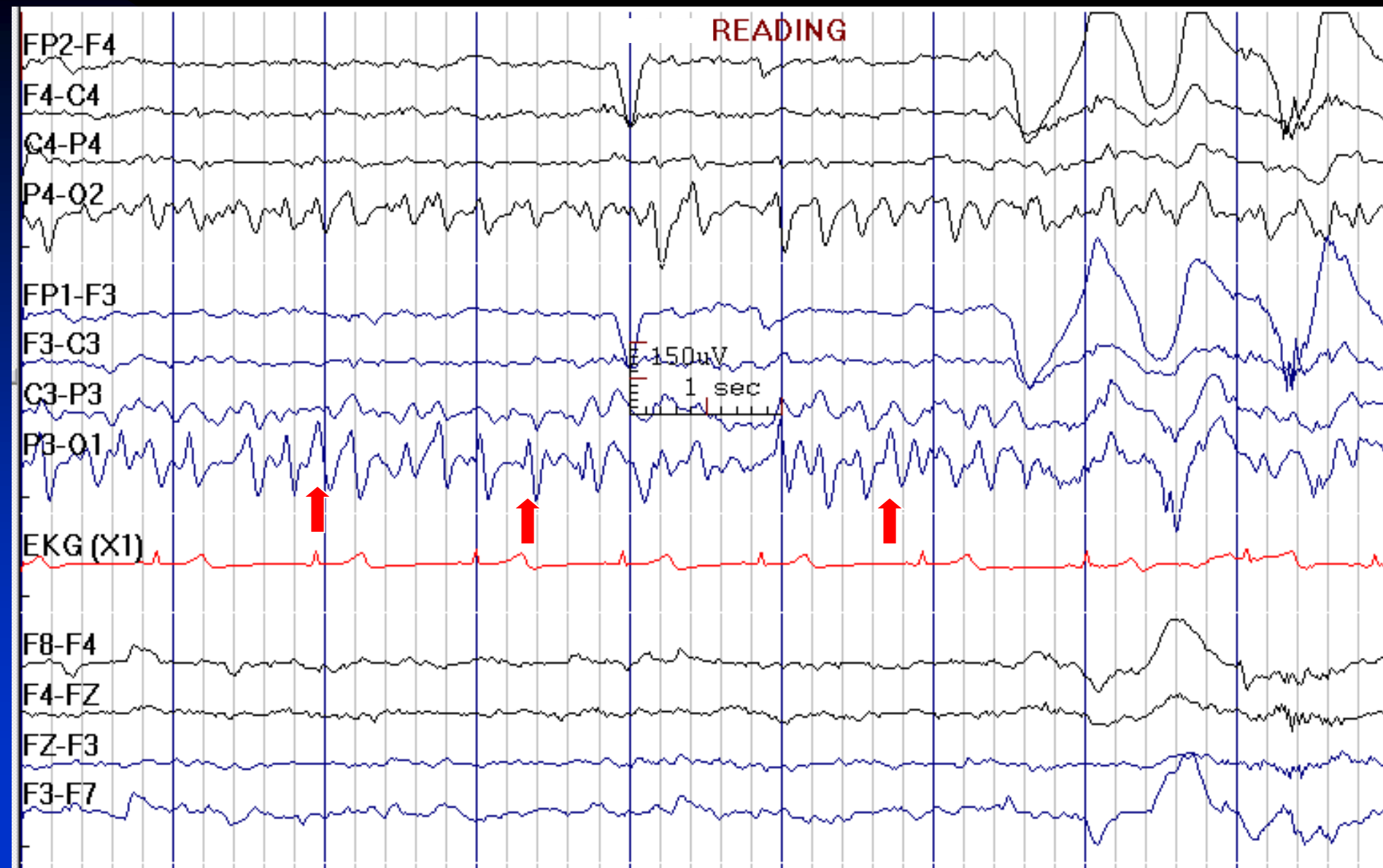# Lambda Waves



# Lambda Waves



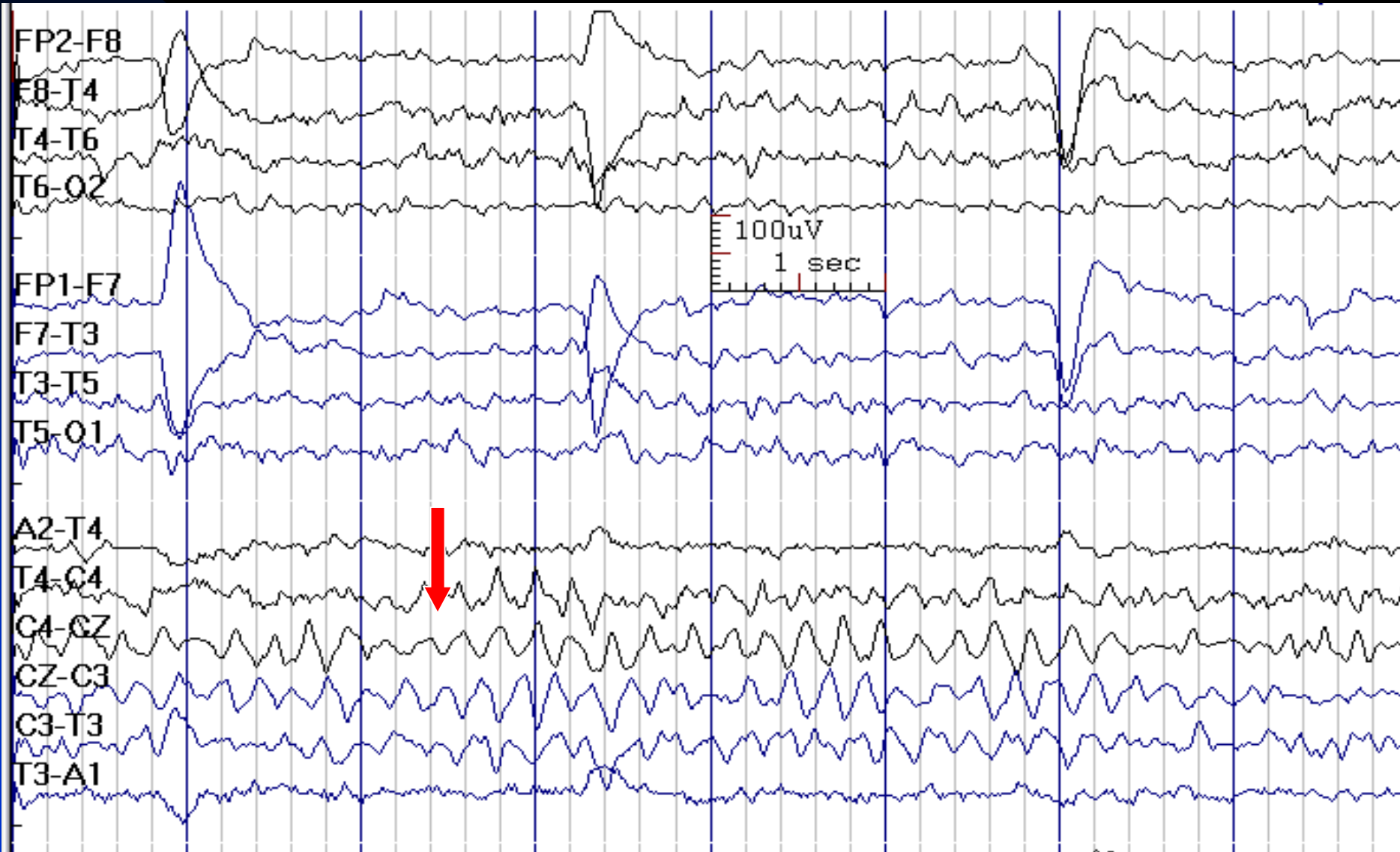# Lambda Waves



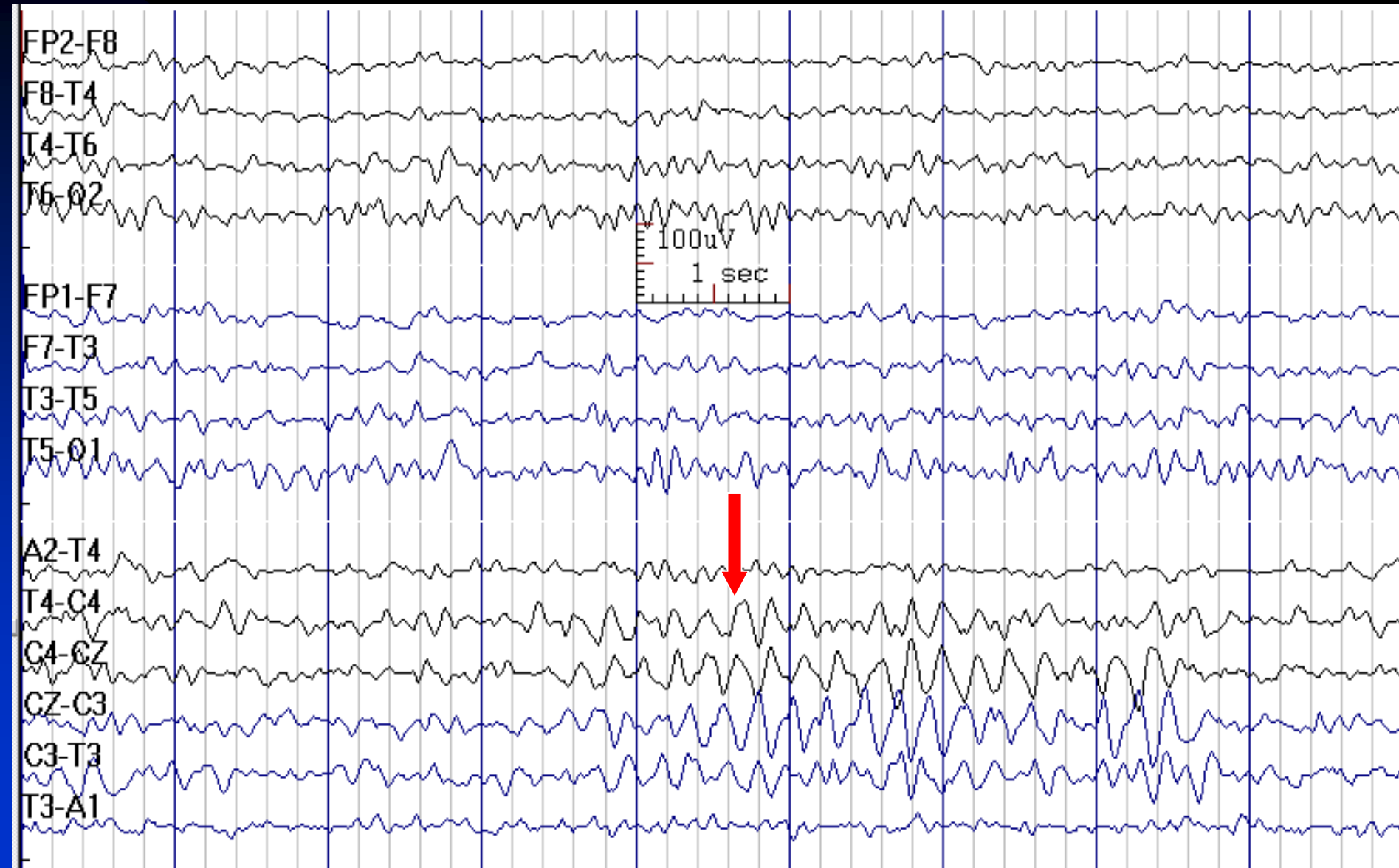# Midline Theta

- **Activity:** 5-7 Hz
- **Distribution:** vertex, maximum at Cz
- **Characteristics:** sinusoidal, arciform or Mu-like, waxes and wanes
- **State:** wakefulness, drowsiness
- **Age:** adults
- **Other names:** theta of Ciganek

# Midline Theta in Wakefulness



# Midline Theta in Drowsiness



# Temporal Slow Waves in the Elderly

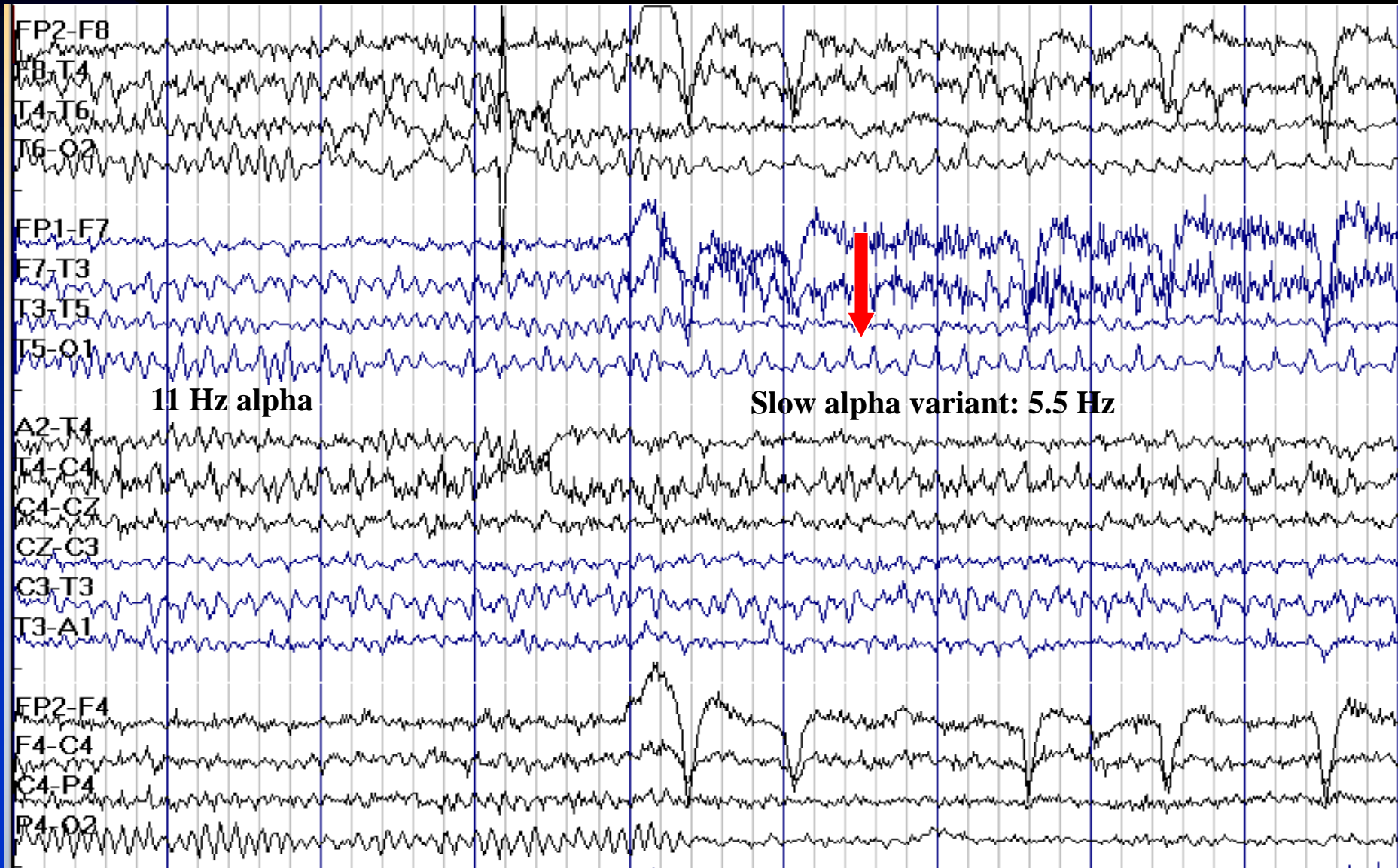
- **Activity:** 4-5 Hz, low to medium voltage
- **Distribution:** bilateral temporal, usually left predominance
- **Characteristics:** mixed frequency in runs of 2-6 waves, enhanced by HV, considered normal if occurs less than once per 2-3 minutes
- **State:** wakefulness
- **Age:** adults older than 50 years

# Alpha Variants

- **Frequency:** harmonics and subharmonics of normal alpha activity with similar reactivity and distribution
  - ◆ **Fast alpha variant:** double alpha frequency
  - ◆ **Slow alpha variant:** half normal alpha frequency (4-5 Hz), usually sinusoidal or notched
- **State:** relaxed wakefulness
- **Age:** adults



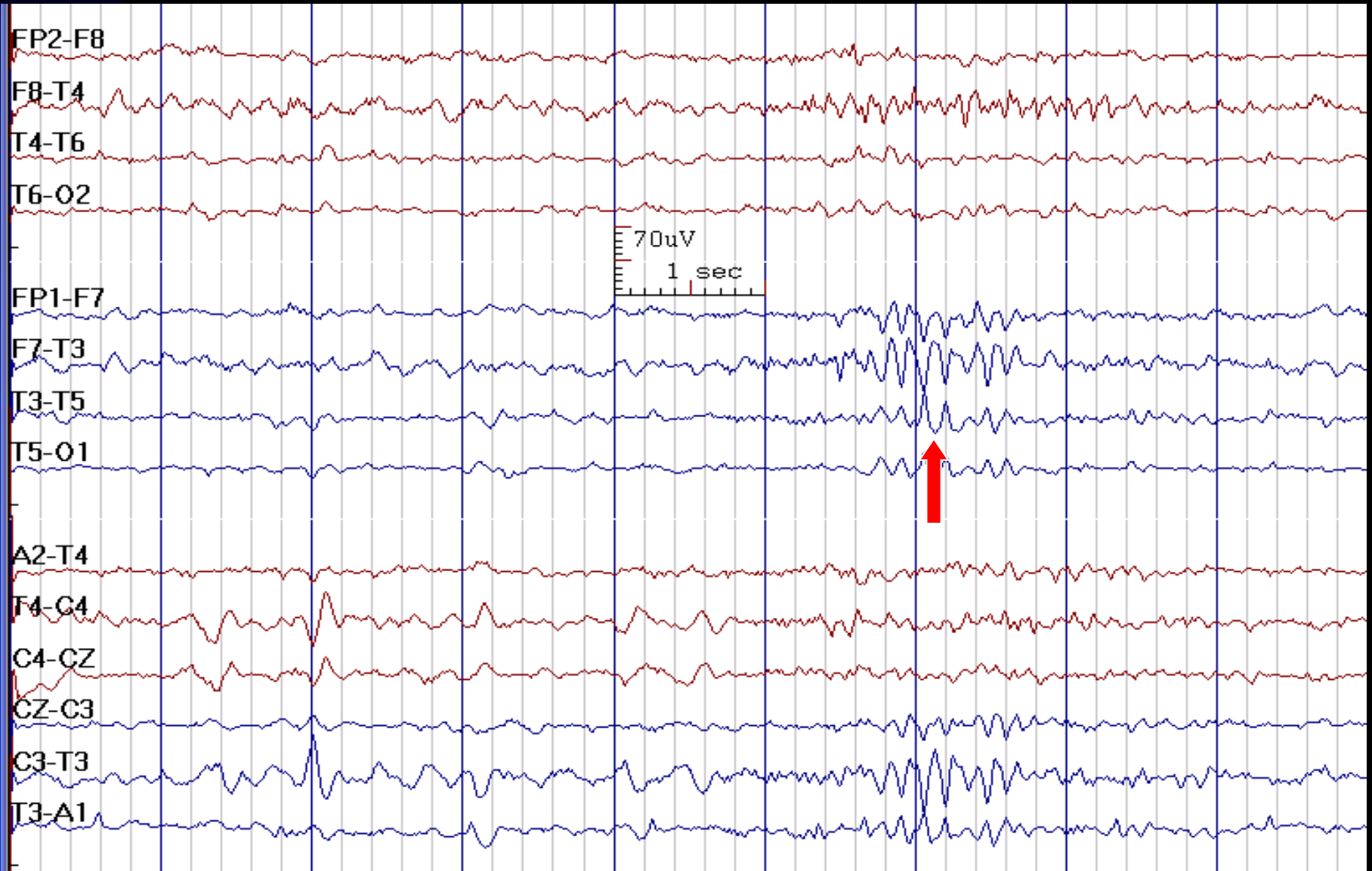
# Slow Alpha Variant



# Breach Rhythm

- **Activity:** high voltage spiky activity
- **Distribution:** in the region of a skull defect
- **Characteristics:** sharply contoured waveforms without an aftergoing slow wave
- **Note:** in the setting of breach rhythm, be cautious when interpreting sharply appearing waveforms as pathological

# Left Temporal Breach Rhythm After Craniotomy



## Other Normal Variants

- Positive bursts of 14 and 6 Hz (originally called 14 and 6 Hz positive spikes) have also been called ctenoids
- Spike-and-wave discharges at 6 Hz also referred to as “phantom spike-and-wave”

# Chapter 7

## Epileptiform EEG Abnormalities

- Interictal epileptiform discharges (IEDs)
- Ictal epileptiform discharges (Seizures)

# Interictal Epileptiform Discharges

## ■ Essential criteria:

1. **Paroxysmal**: clearly set apart from ongoing background activity and not simply a sharply contoured component of a sequence of waves
2. **Abrupt change in polarity**: results in the sharp contour or spikiness
3. **Spikes**: duration 20-80 msec
4. **Sharp waves**: duration 80-200 msec
5. **Polyspikes**: polyphasic (greater than 5 phases), repetitive (more than one) spikes
6. **Presence of a physiological field**
7. **Not an artifact or a normal sharp transient**

# Common Characteristics of IEDs

- The majority of IEDs are of **negative polarity**
- Most IEDs are followed by a **slow wave**
- IEDs may be of any amplitude, **no minimum voltage requirement or maximum limit**

# Ictal Scalp EEG

## ■ Isomorphic seizure pattern:

- ★ Ends similar to the way in which it begins, without progression through multiple phases into a postictal phase
- ★ Ictal morphology is similar to interictal epileptiform patterns and differs only in greater rhythmicity, duration, spatial extent and amplitude
- ★ Characteristic for generalized seizures (e.g., absence seizures)

## ■ Metamorphic seizure pattern:


- ★ Ends quite differently from its beginning, commonly progressing through different ictal phases into a postictal state
- ★ Seen both in generalized and partial seizures



# Focal Interictal Epileptiform Discharges (IEDs)

- Negative phase reversal in bipolar montage represents the region with maximum potential (field maximum)
- Electrode with highest amplitude in a referential montage represents the region with maximum activity among sampled electrodes
- **Note:** Reference electrode should be out of field or least involved


# Field Determination Based on Anteroposterior and Transverse Planes


A-C: 

C-N: 

N-E: 

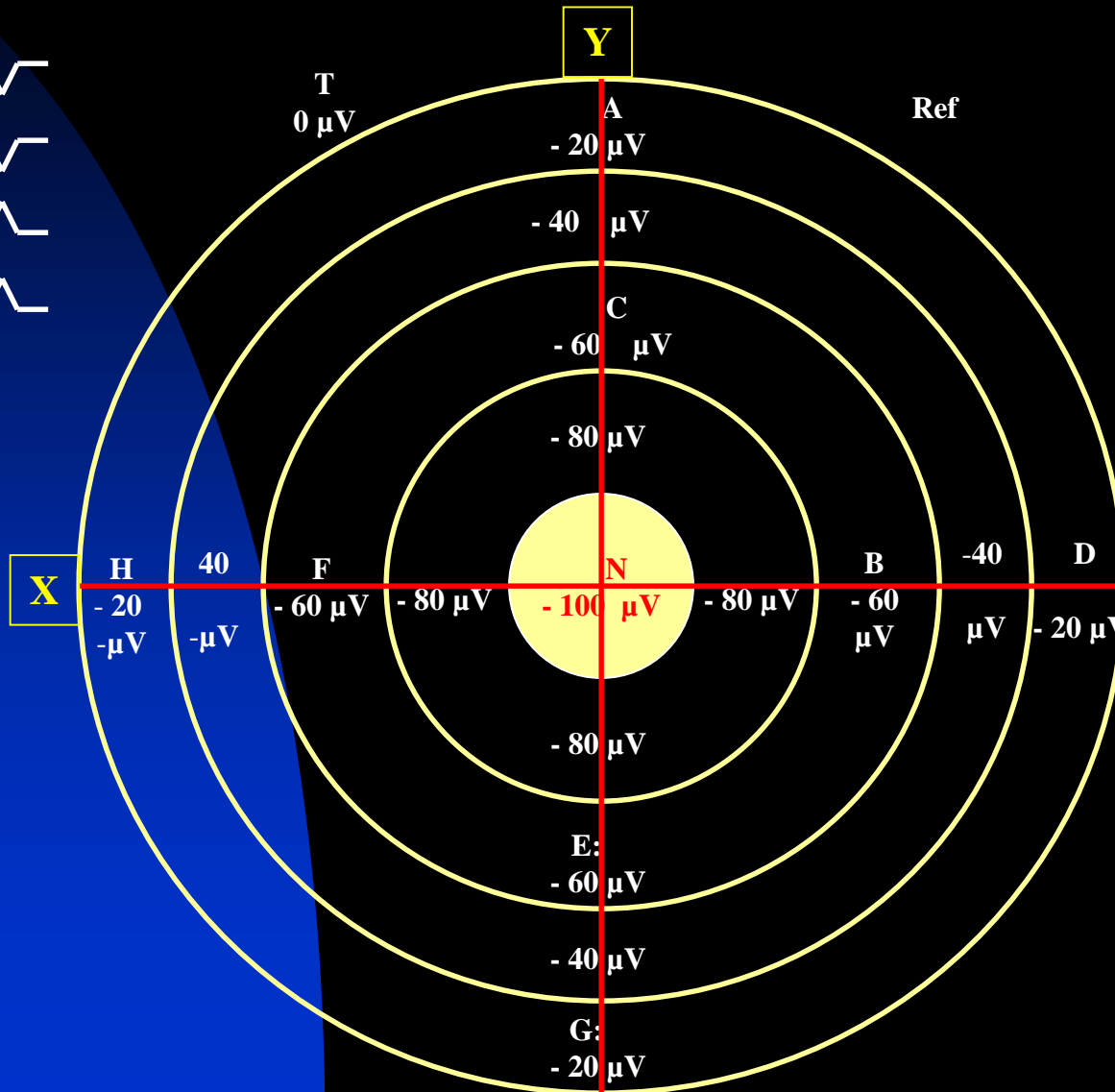
E-G: 

D-B: 

B-N: 


N-F: 

F-H: 



NOTE: Negative phase reversal in bipolar montage represents the region with maximum potential; in this slide **N** is the point of maximum potential in AP (Y) and transverse (X) planes.


# Field Determination Based on Anteroposterior and Transverse Planes


A-C: 

C-G: 

G-I: 

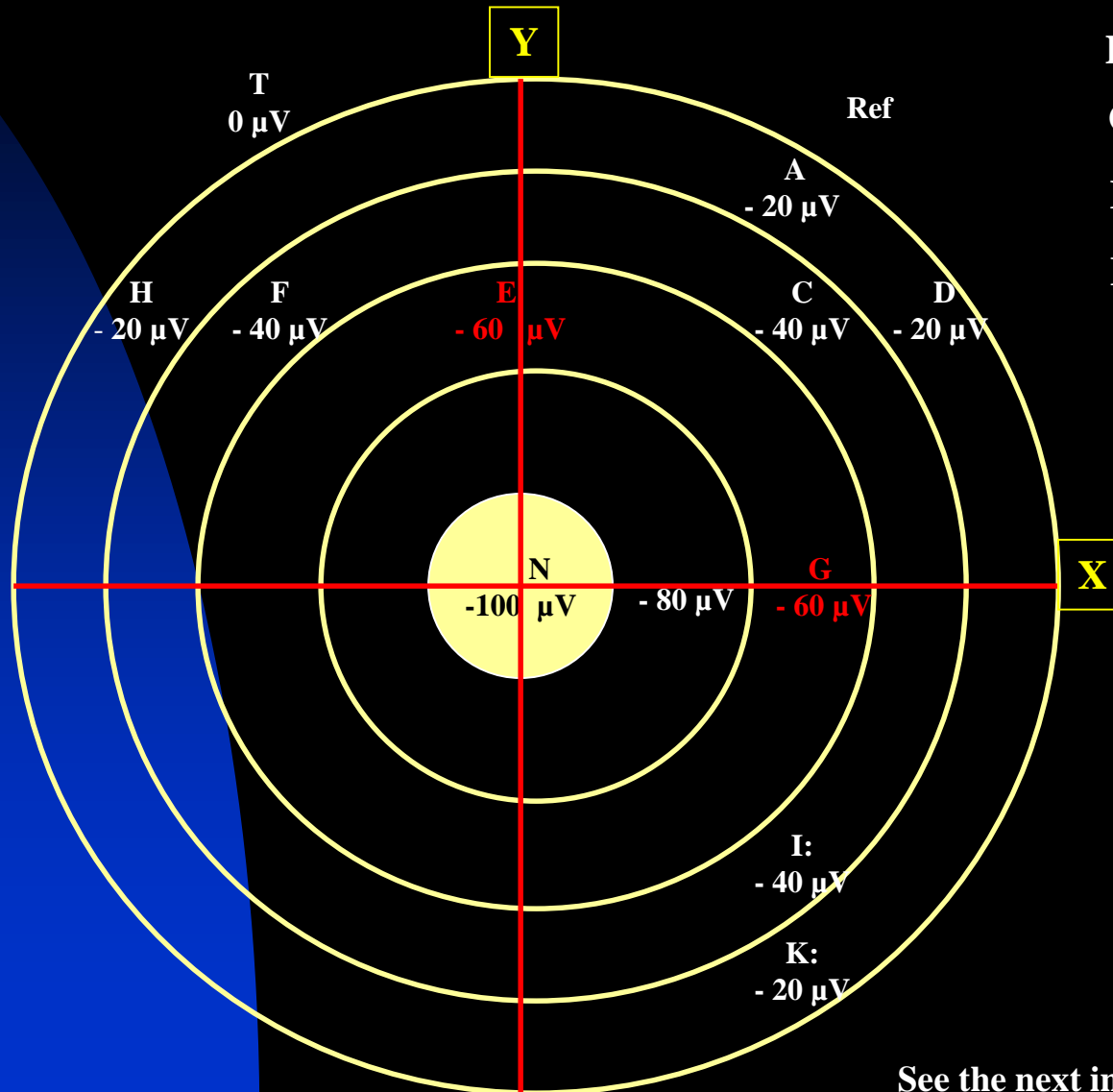
I-K: 

D-C: 

C-E: 

E-F: 

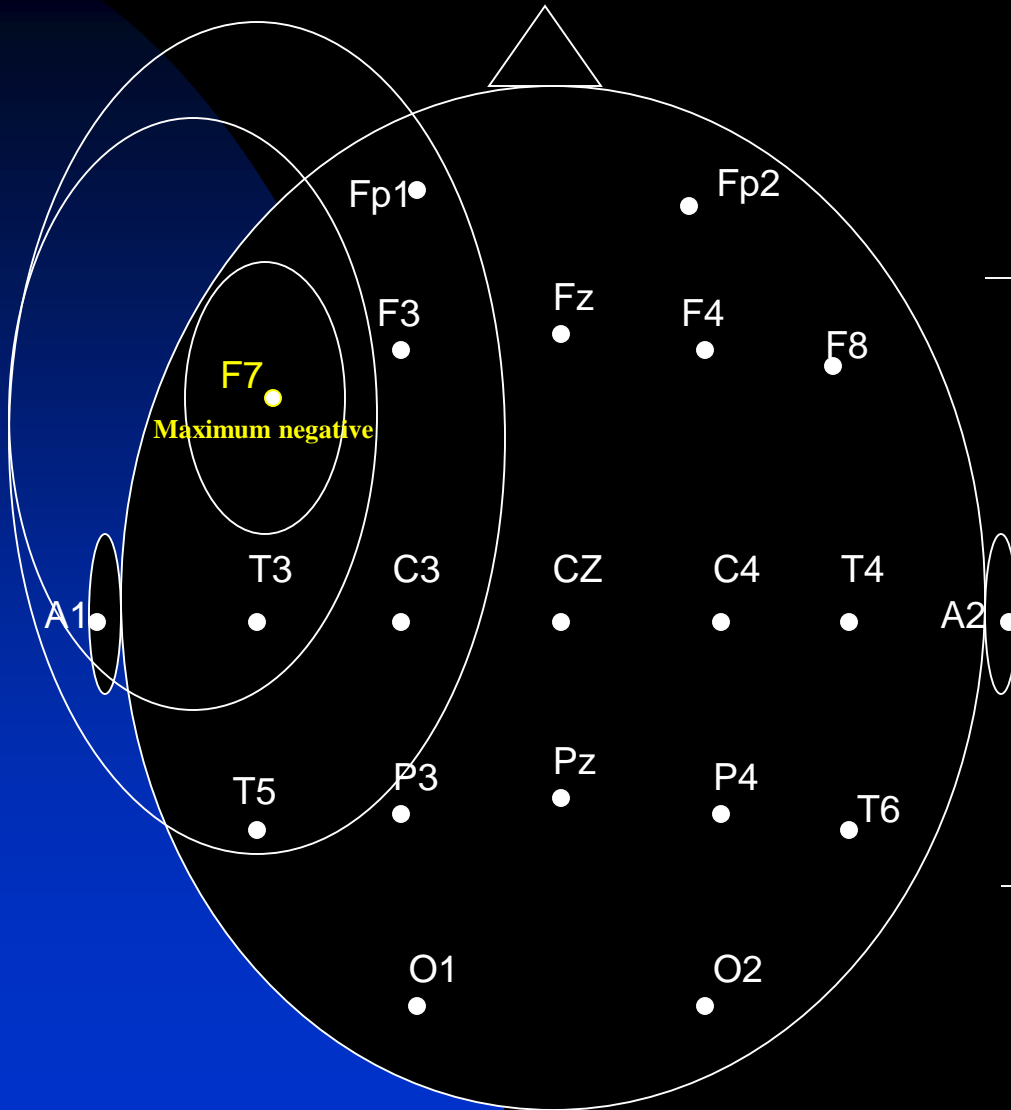
F-H: 



See the next image for explanation

- In the anteroposterior plane, **G** is the point of maximum negativity. The line labeled **X** indicates the axis showing the plane of maximum negativity. The source of the negativity could be located anywhere on this plane.
- In the transverse plane, **E** is point of maximum negativity: The line labeled **Y** indicates the axis showing the plane of maximum negativity. The source of the negativity could be located anywhere on this plane.
- The point where planes **Y** and **X** intersect is the location of maximum negativity: **N**.
- Therefore, assuming a radial field distribution, one can localize a field source even when an electrode is not placed on that source.

# EEG Localization



FP1- F7

V

Temporal

F7-T3

^

A-P

T3-T5

^

T5-O1

^

A1-T3

—

T3-C3

^

Temporal-

C3-Cz

^

Central

Cz-C4

—

Transverse

FP1-F3

—

Frontal-

F3-C3

—

Parietal

C3-P3

^

A-P

F7-F3

^

F3-Fz

^

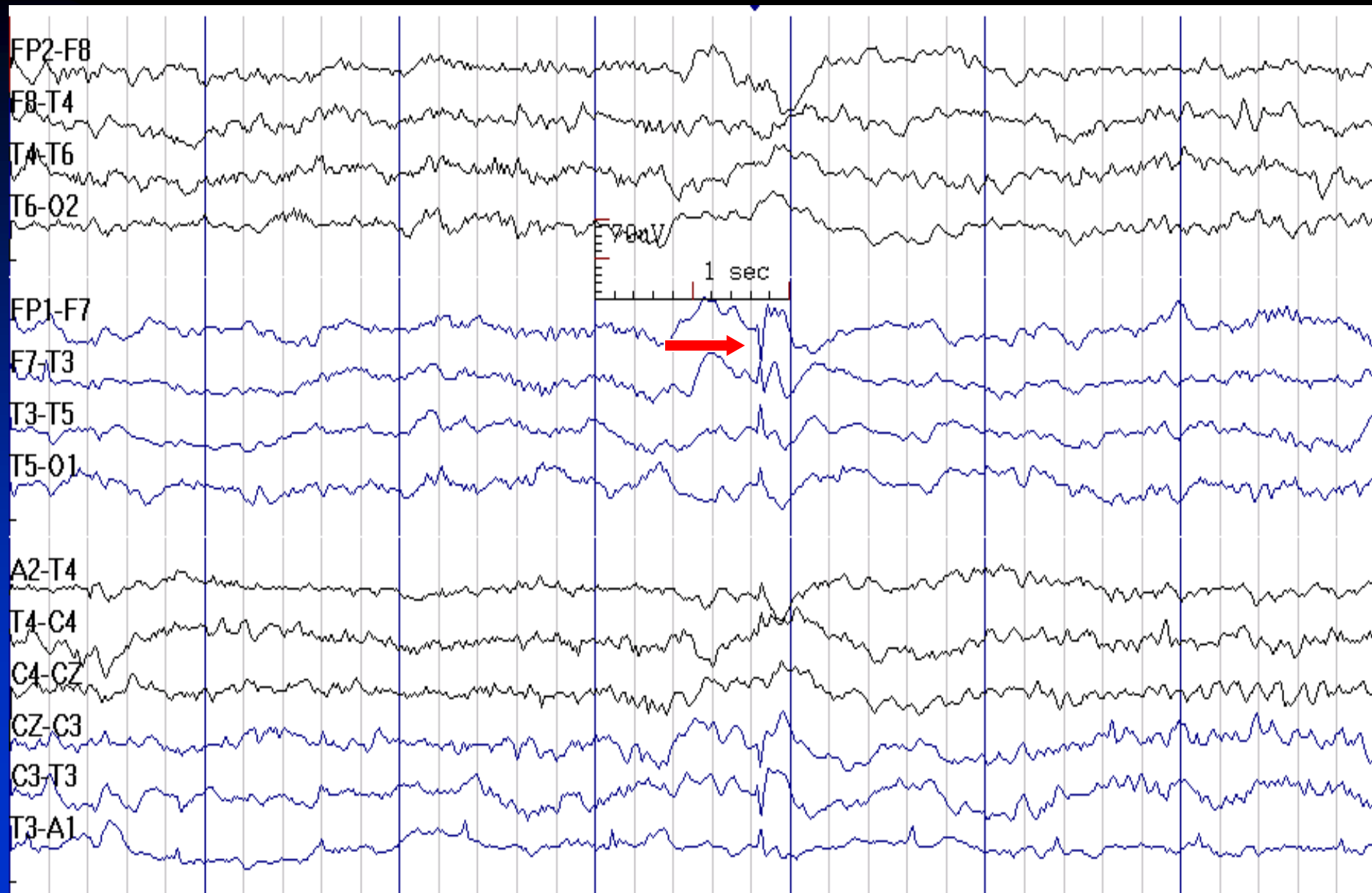
Frontal

Fz-F4

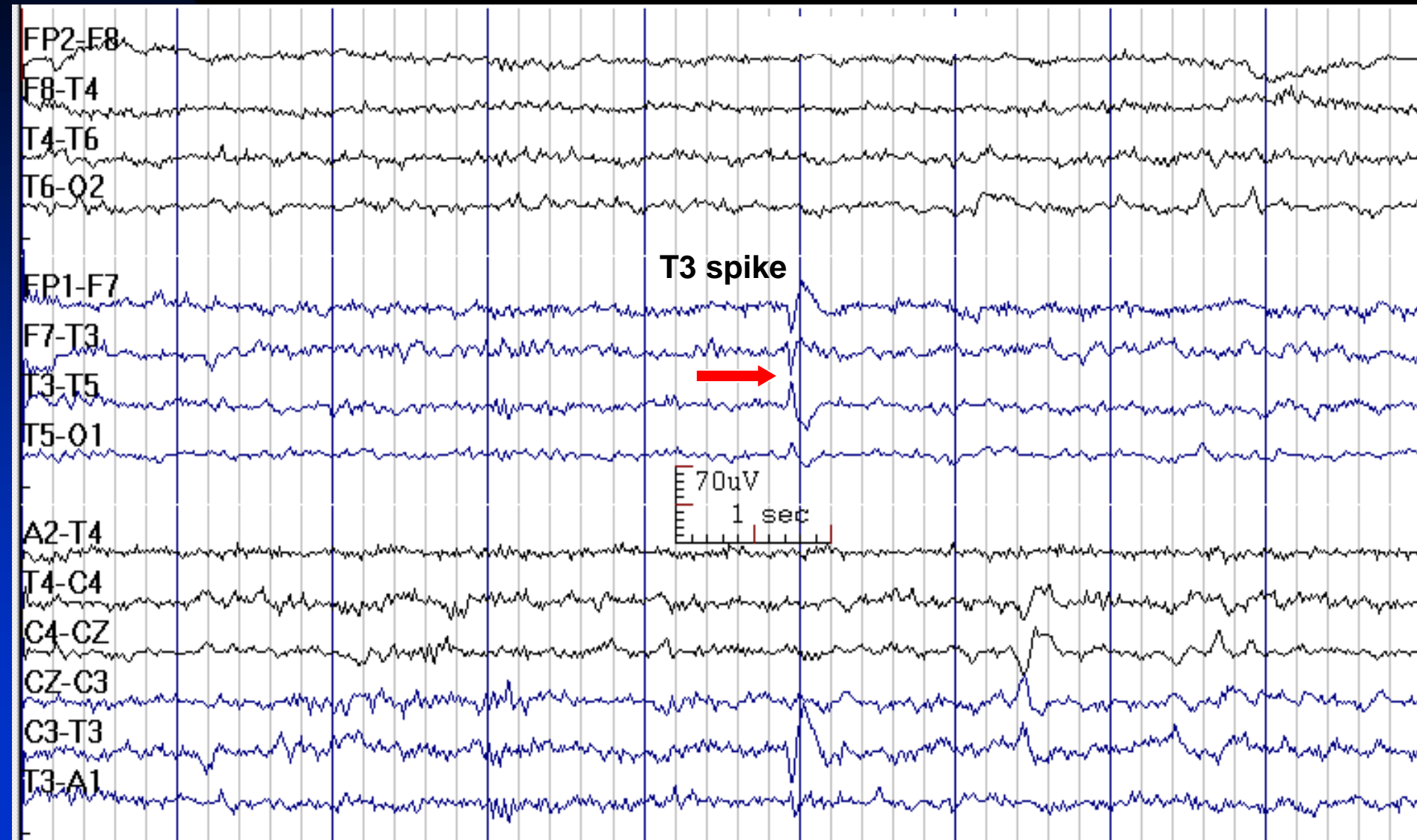
—

Transverse

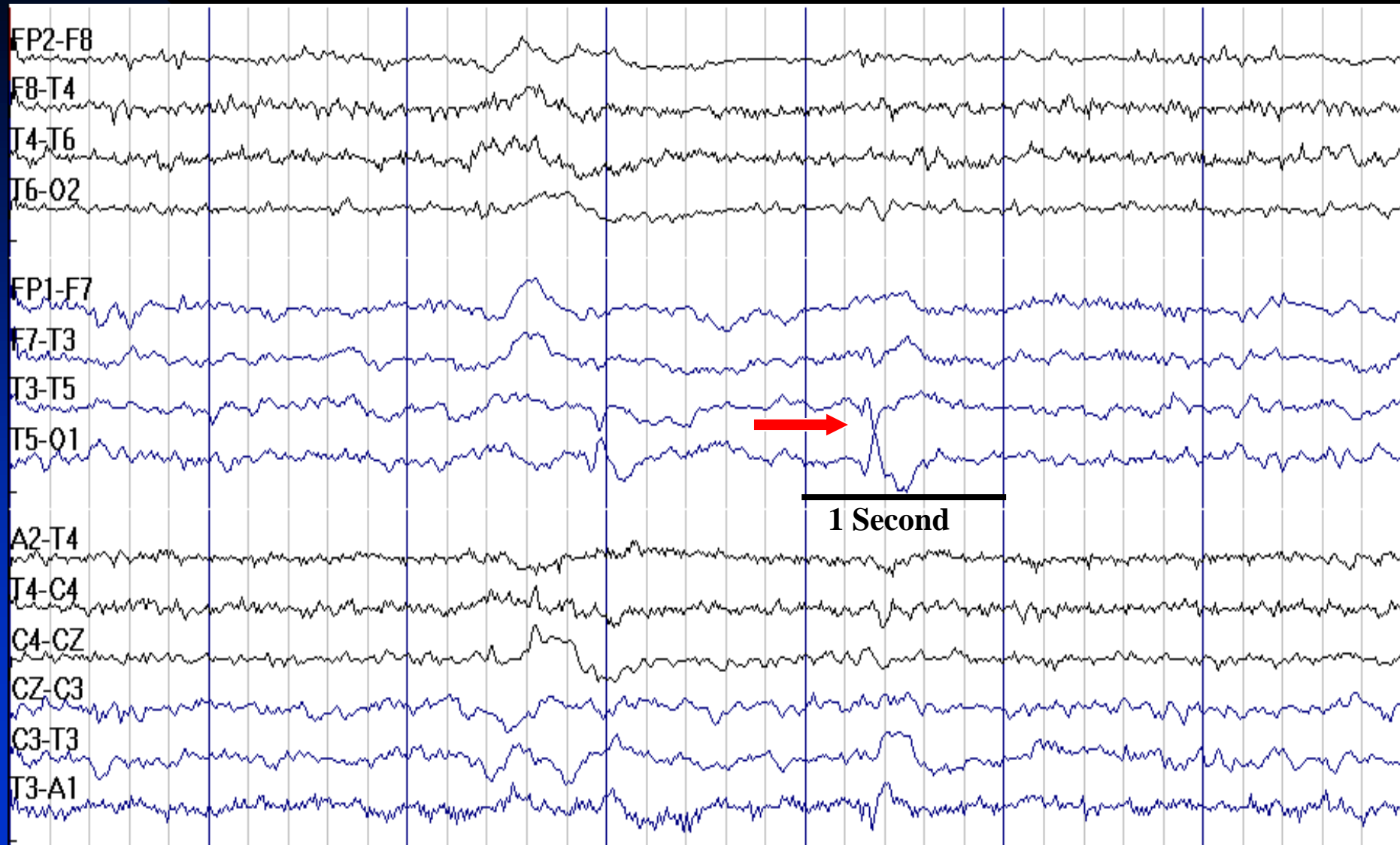
# F7 Spike: Duration < 80 msec



# T3 Spike/Sharp wave: Duration is ~ 80 msec



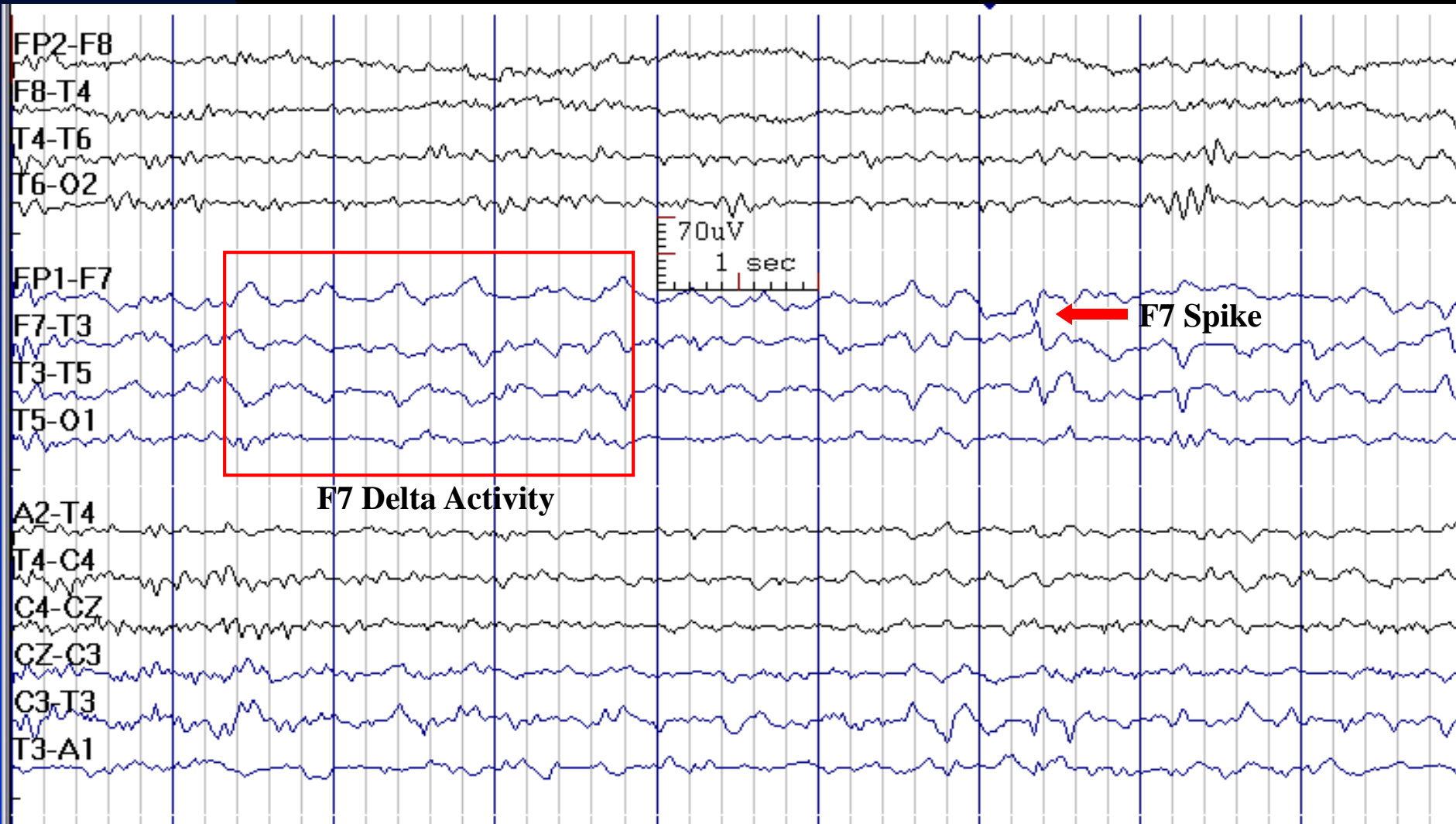
# T5 Sharp Wave





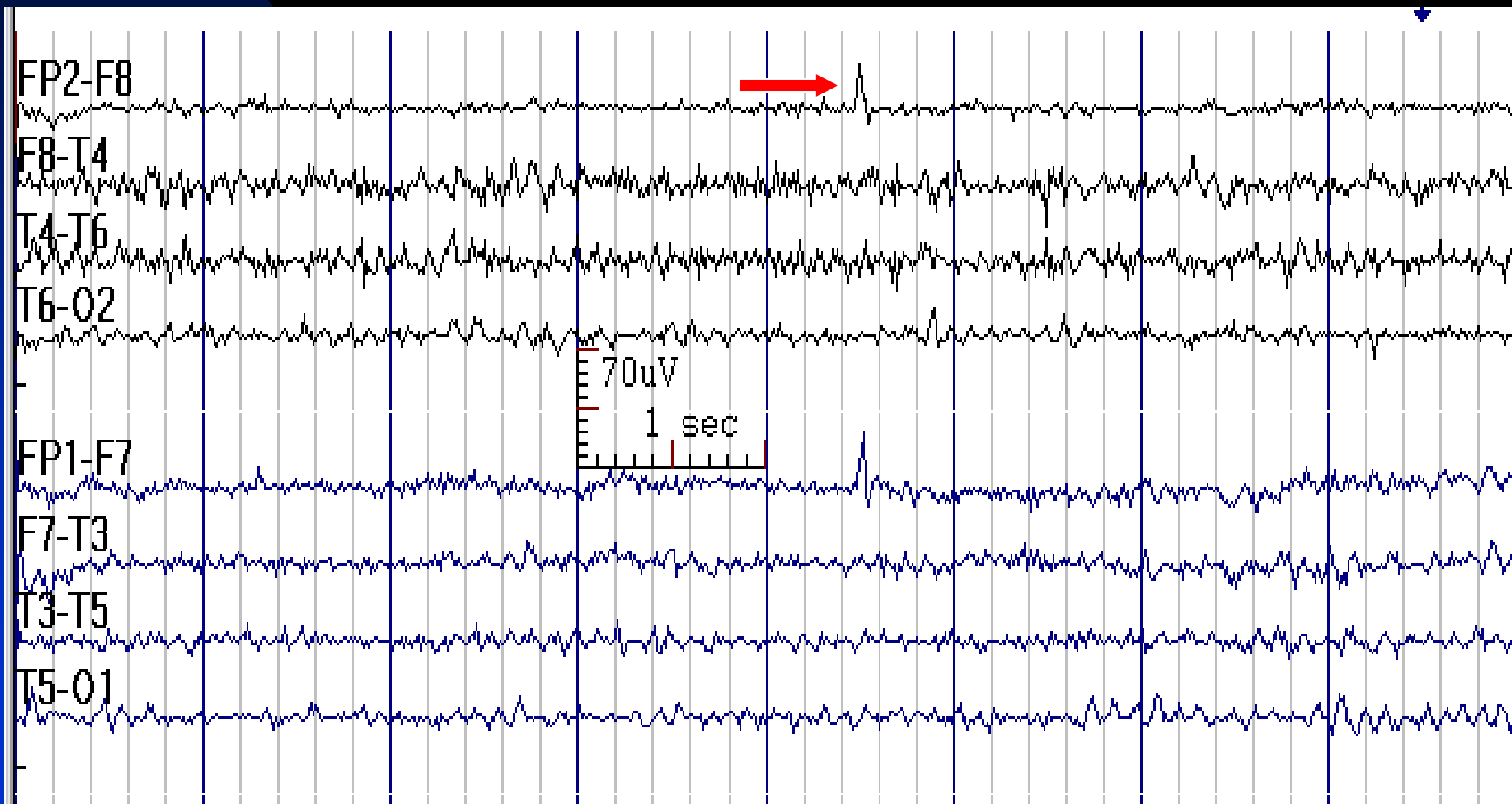
# Amplitude is not a Determining Factor for Being an Epileptiform Discharge

## F7 Spike and F7 Delta Activity in Temporal Lobe Epilepsy



# Artifact Resembling a Spike in Anterior Channels

There is no physiological field, no disruption of the background,  
and no aftergoing slow wave



# Localization in Focal Interictal Epileptiform Discharges (IEDs)

- Frontal IEDs
- Temporal IEDs
- Parietal IEDs
- Occipital IEDs
- Multi-focal IEDs ( $\geq 3$  regions, in both hemispheres)
- IEDs with secondary bilateral synchrony

# Frontal Interictal Epileptiform Discharges

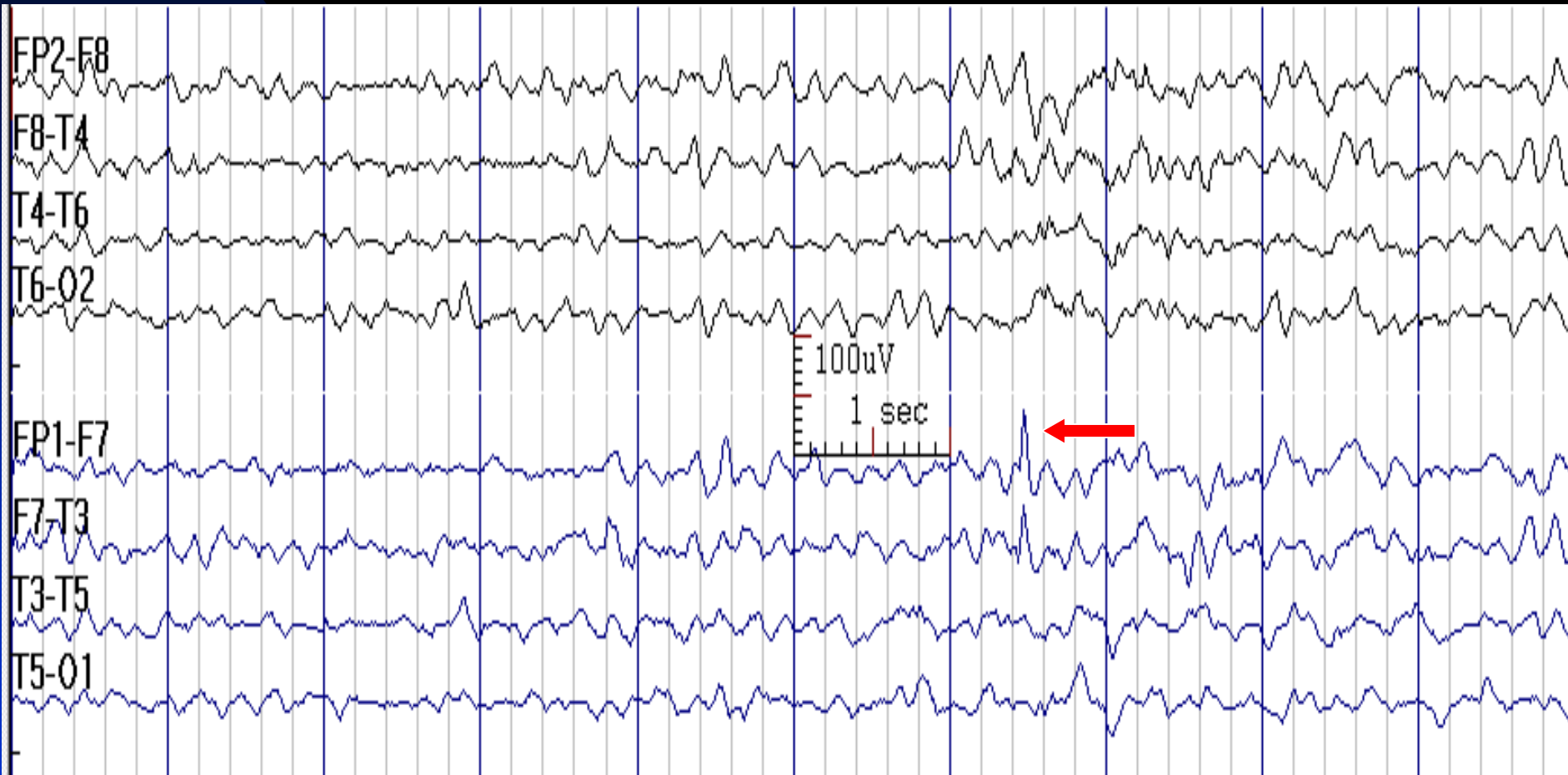
## Localization Based on Maximum Potential

- Fp1/Fp2: Frontopolar cortex
- F3/F4 or C3/C4: Dorsolateral frontal cortex (rarely mesial frontal cortex)
- F7/F8: Frontal (orbital or dorsolateral) or anterior temporal cortex
- Fz, Cz: Mesial frontal cortex
- In frontal lobe epilepsy, interictal EEG is frequently normal

# Analyzing Fp1 and Fp2 Electrodes

- These electrodes are end of the chain of electrodes in anterior-posterior bipolar montages; therefore, when there is a suspicious finding in these electrodes, it is useful to employ a bipolar montage in which they are linked (e.g., hatband or circle montage)
- This is also true for O1 and O2 electrodes

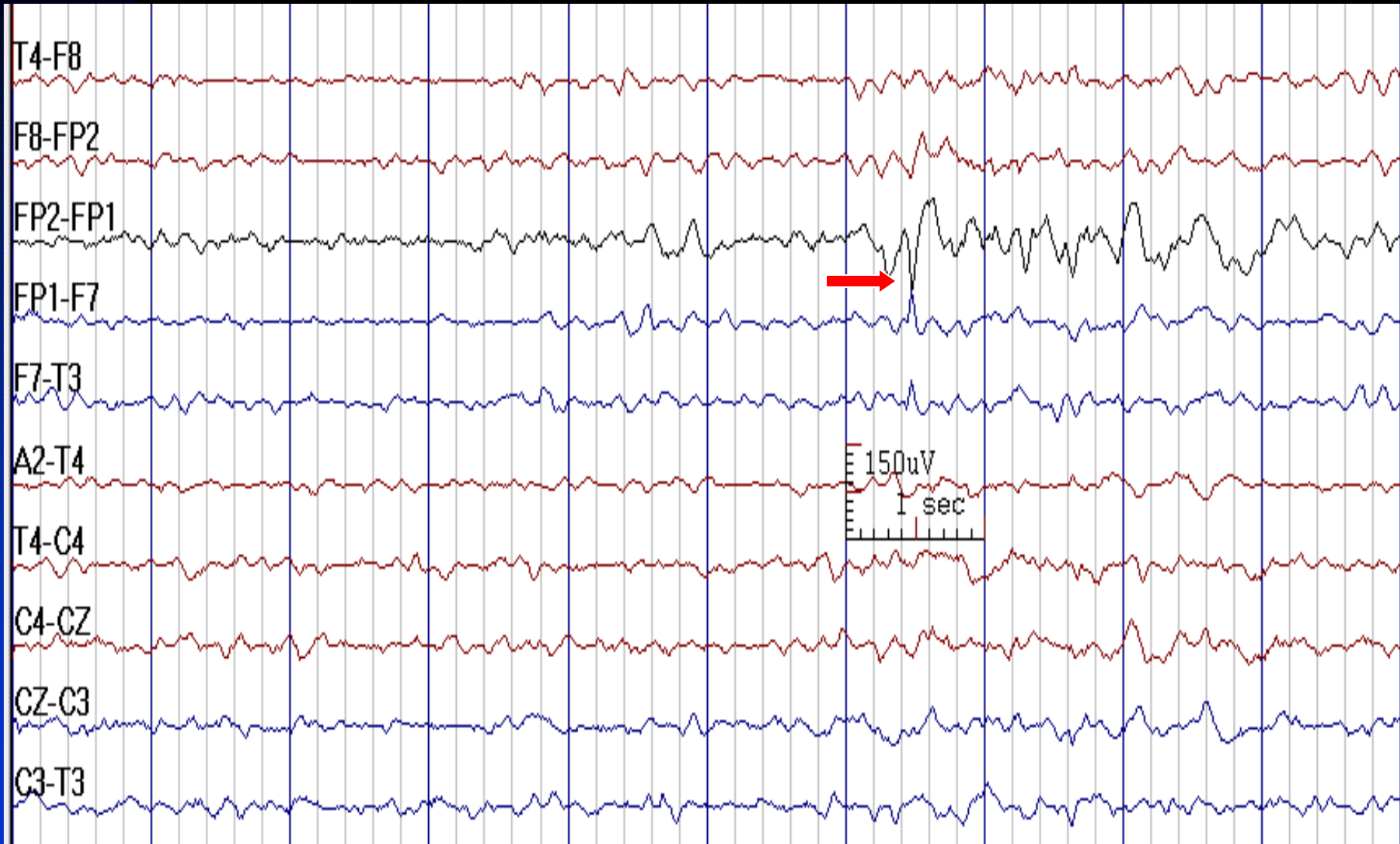
# Fp1 Spike in a 35-Year-Old Man with Focal Epilepsy (End of Chain in This Montage)



See the next image for the same finding in circular montage

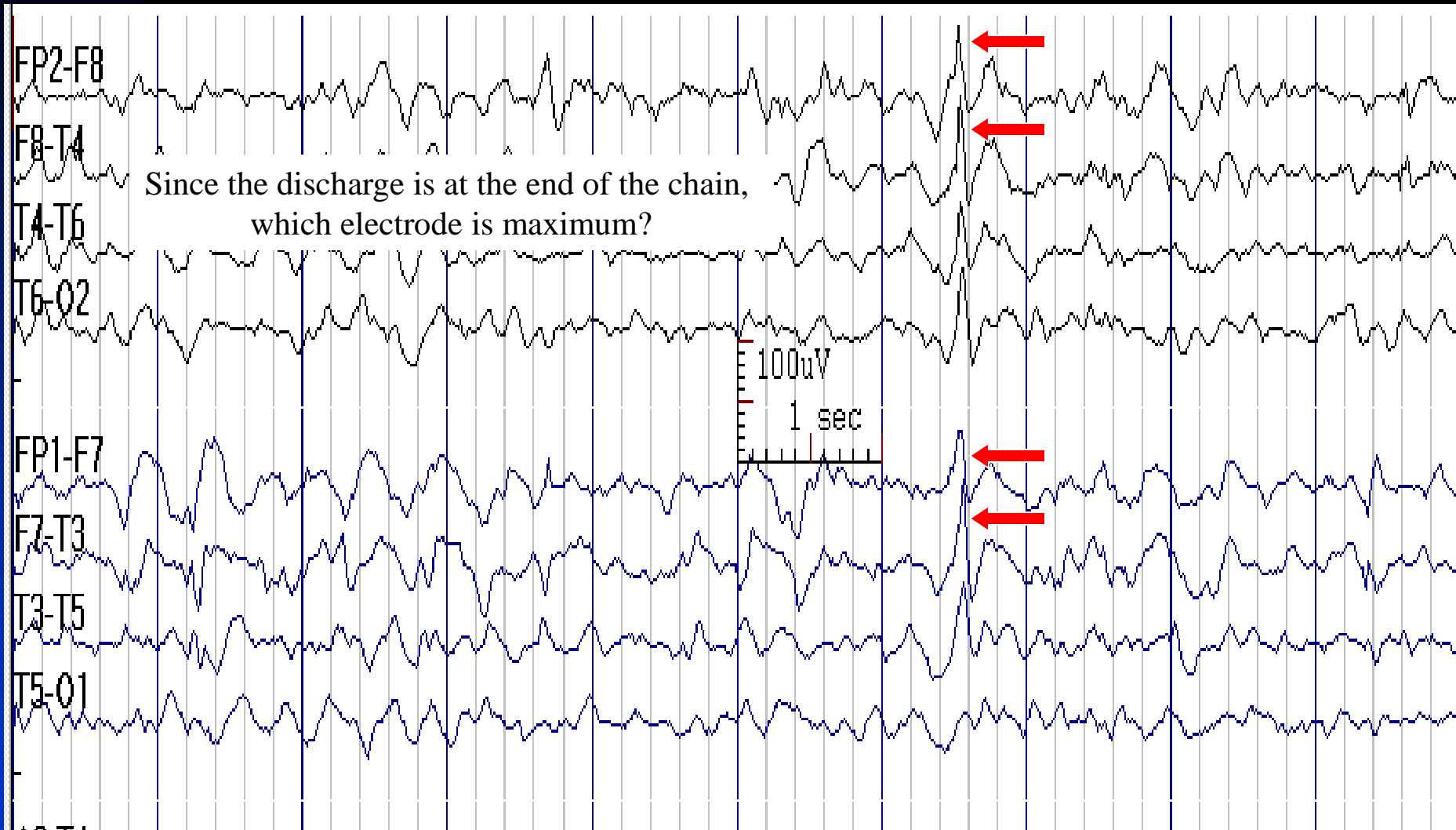# Fp1 Spike in Bipolar Circular Montage

(Not End of Chain in This Montage)



See the previous image for the same finding in temporal longitudinal montage

# Fp2 Spike Could be Mistaken for a Bifrontal Spike in this Montage

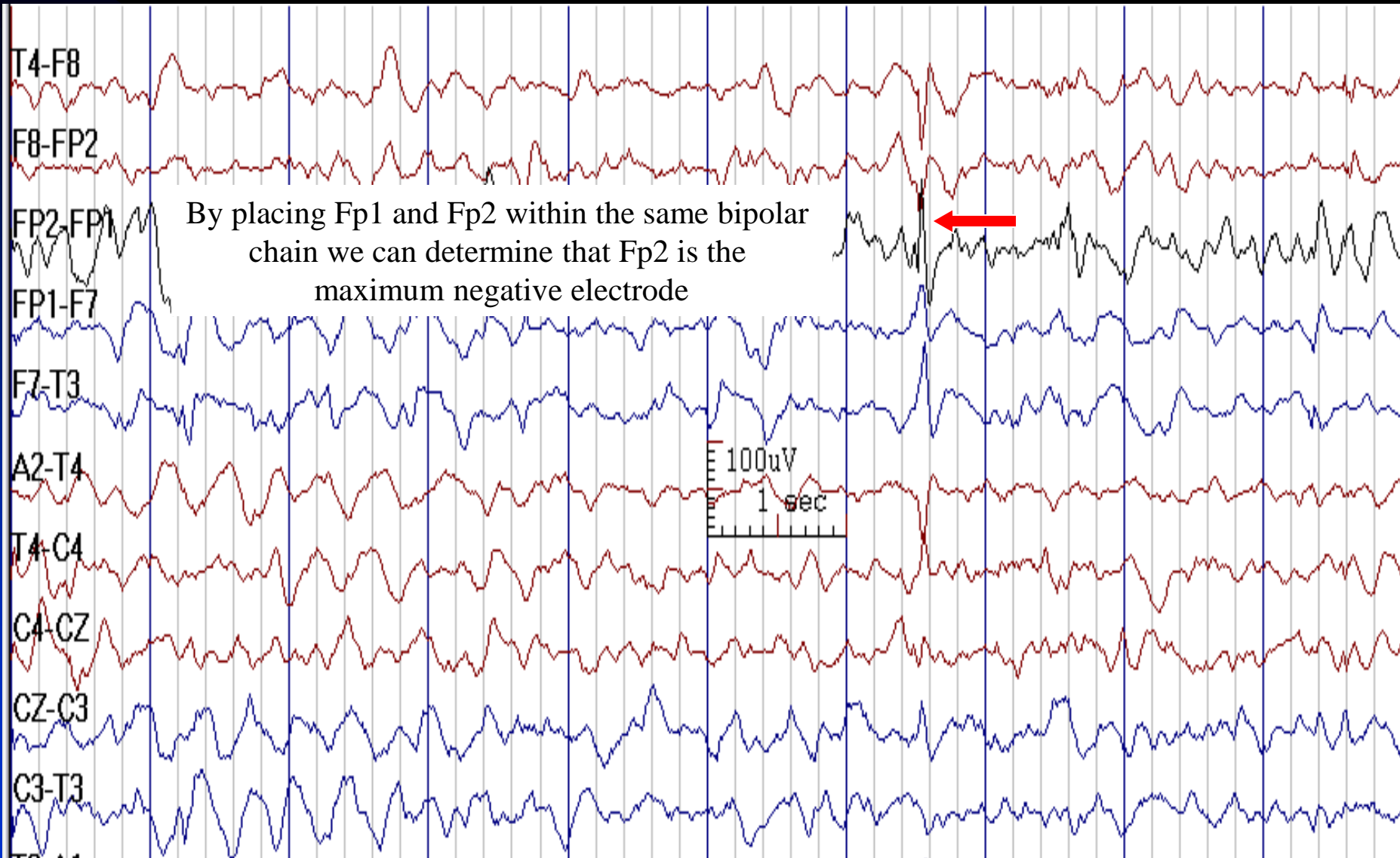


See the next image for the same finding in circular montage



# Fp2 Spike

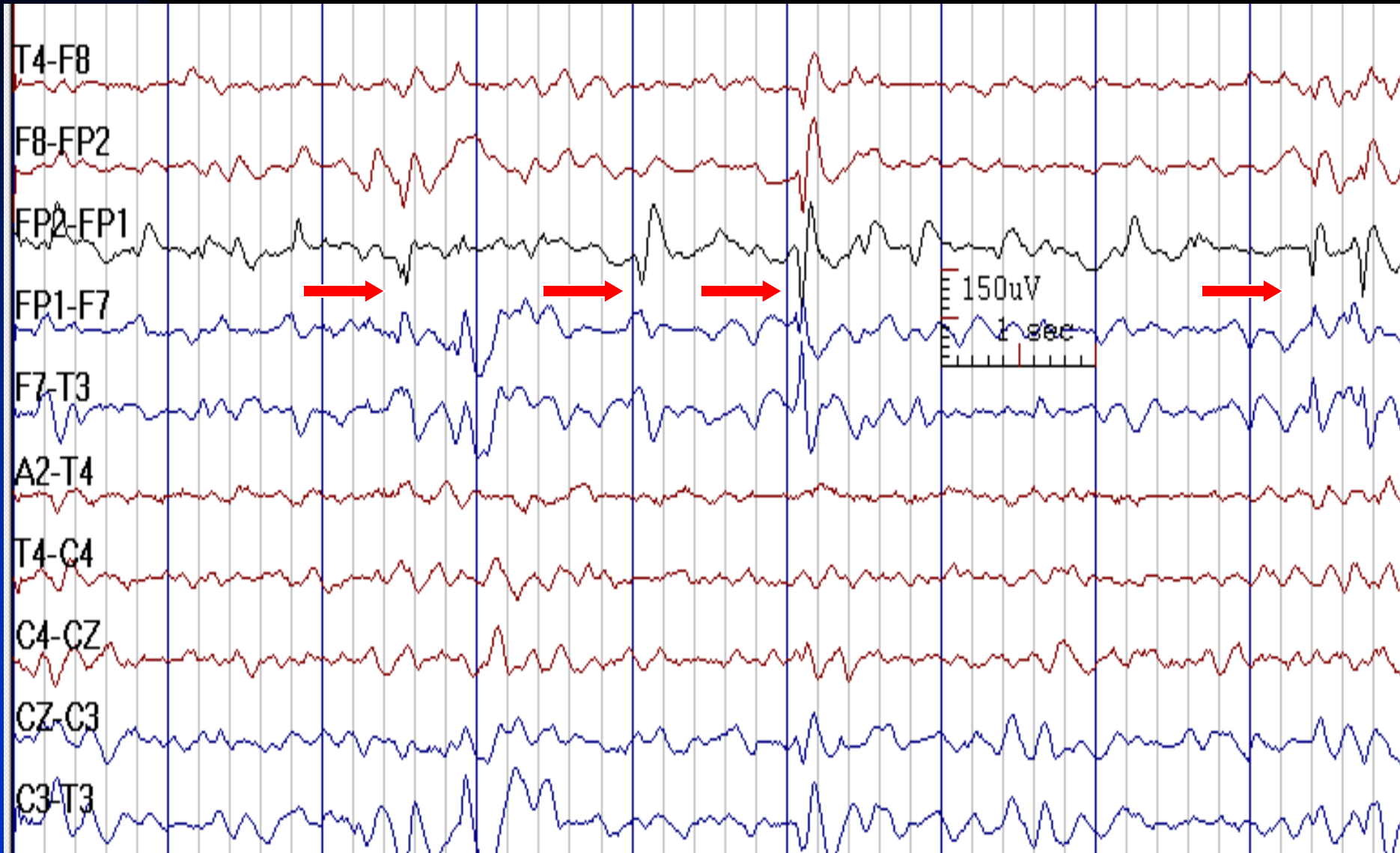
(Middle of the Chain in Circle Montage, Previous Image)



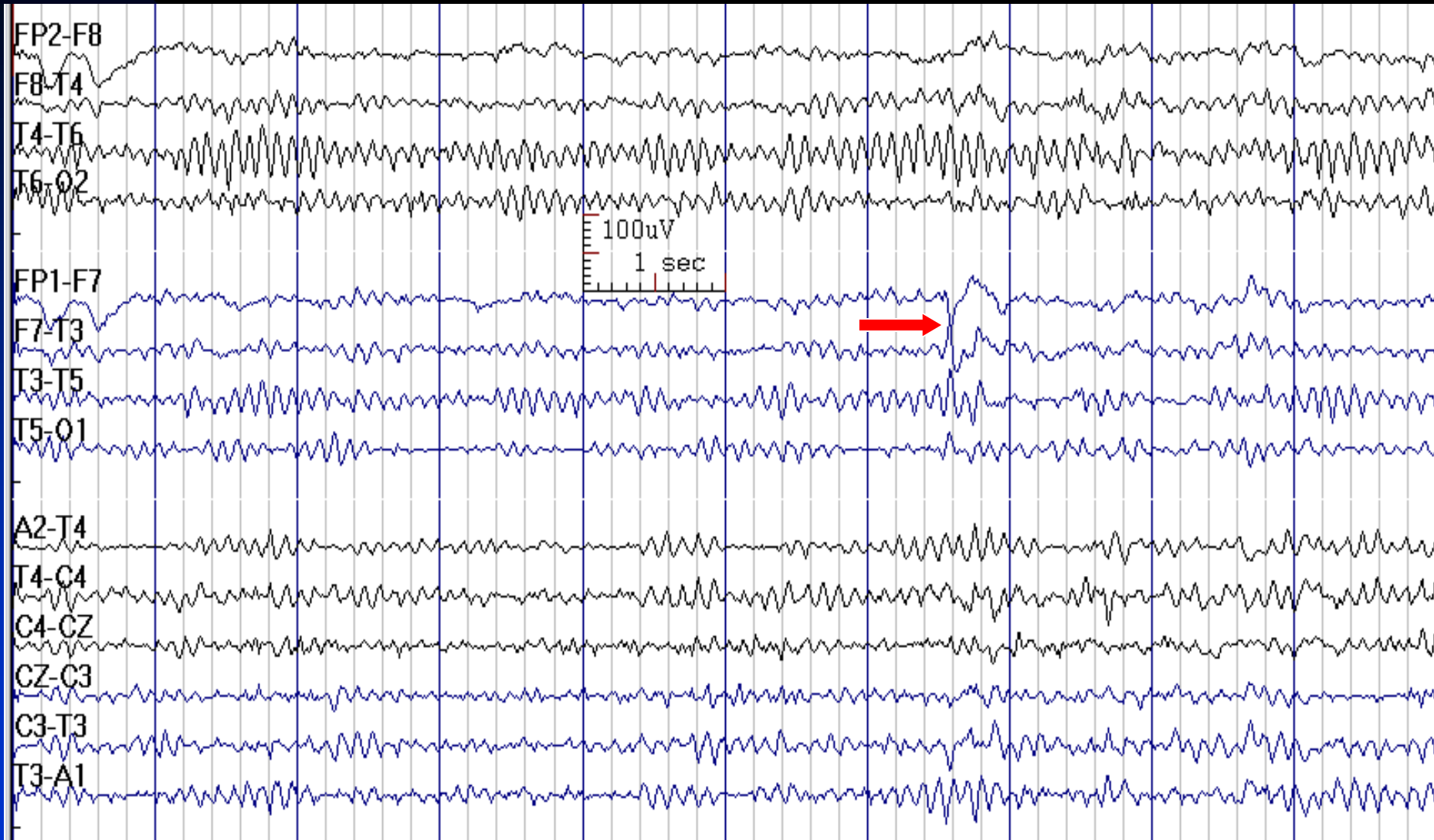
See the previous image for the same finding in temporal longitudinal montage

# Fp1 Spikes and Sharp Waves

Note Varying Morphology

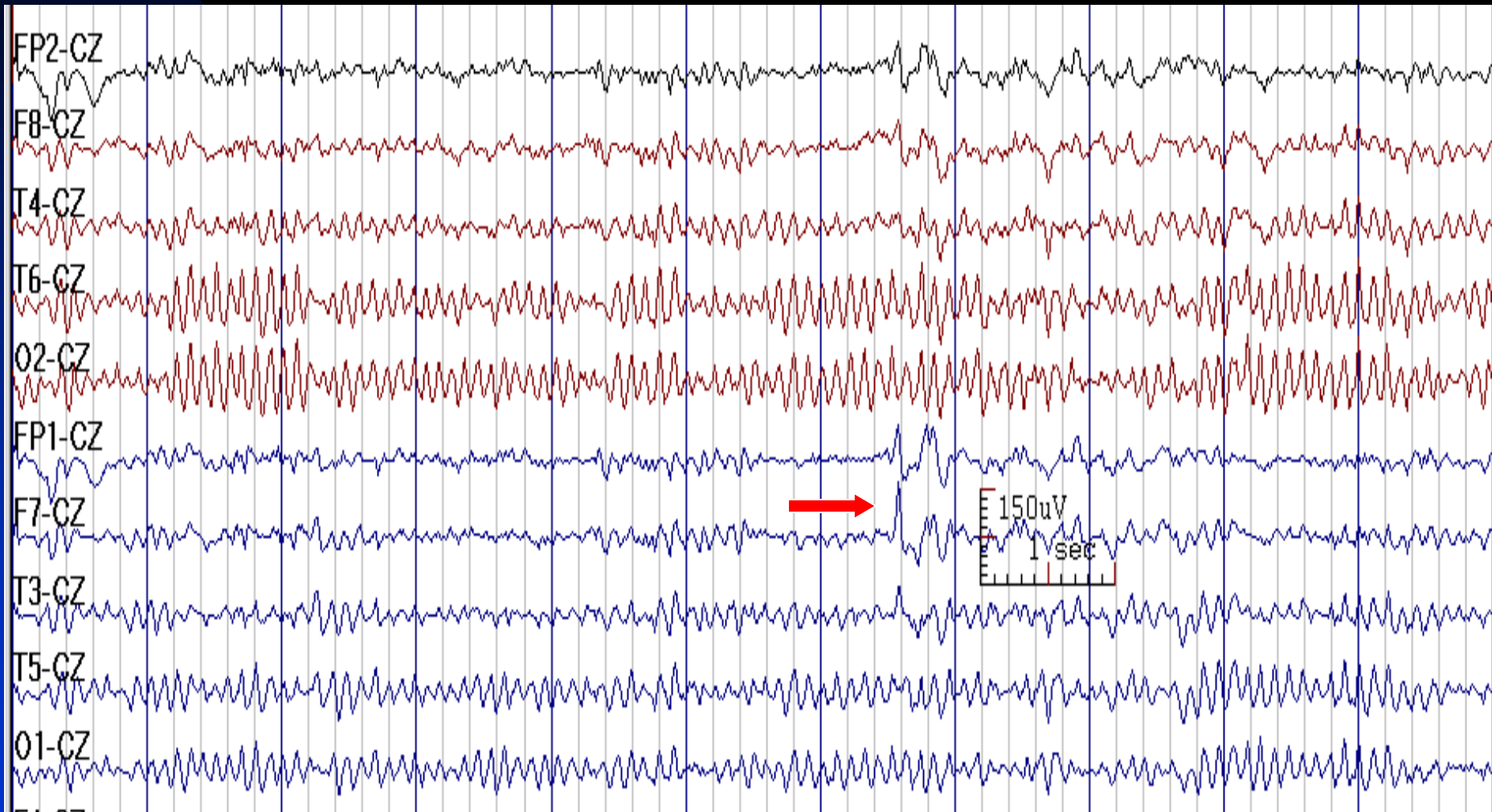


# F7 Sharp Wave in a 40-Year-Old Woman with Frontal Lobe Epilepsy



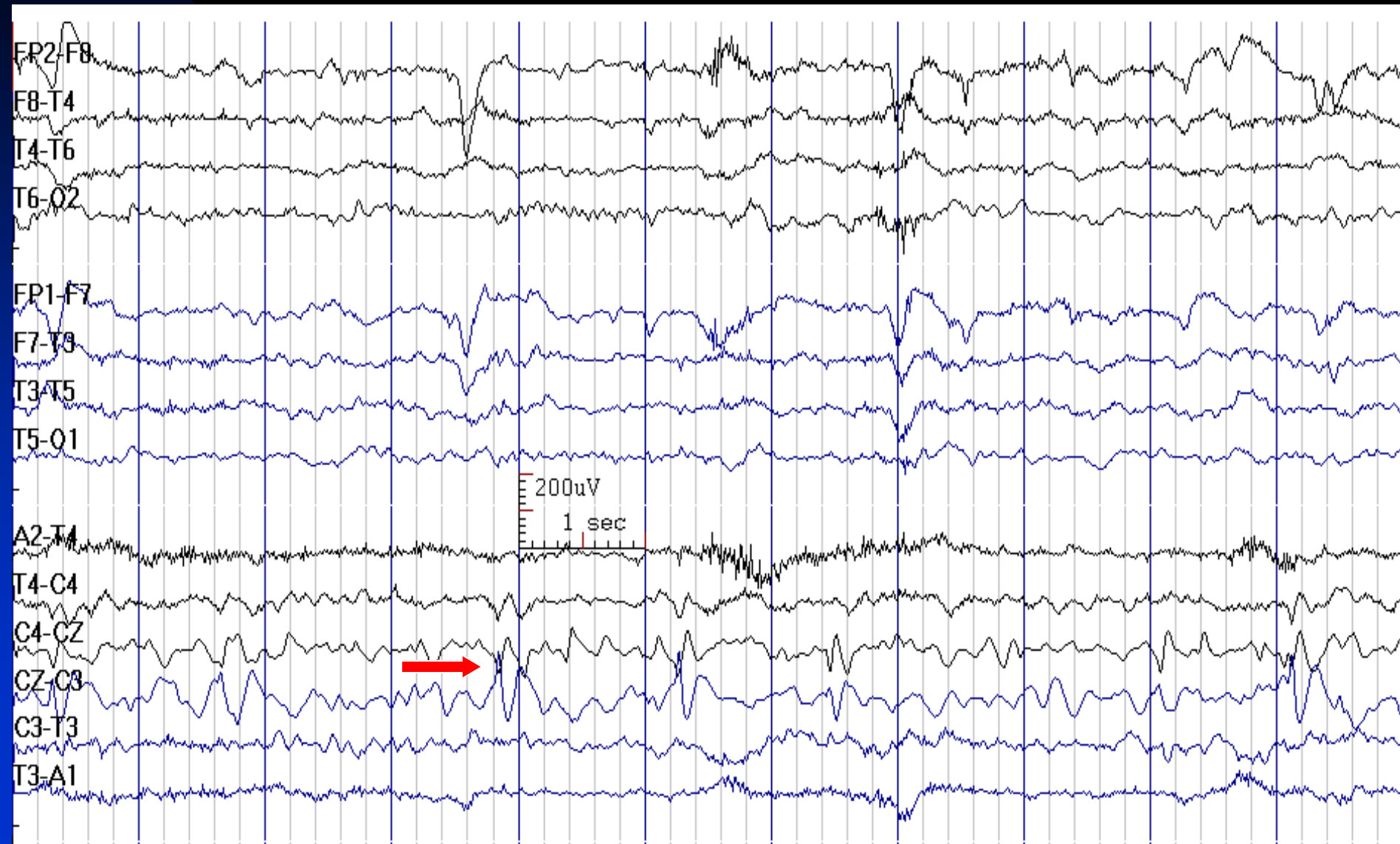
See the next image for the same finding in reference montage

# Same Page as Previous Slide in Cz Reference Montage: Negativity is F7 > Fp1 > T3

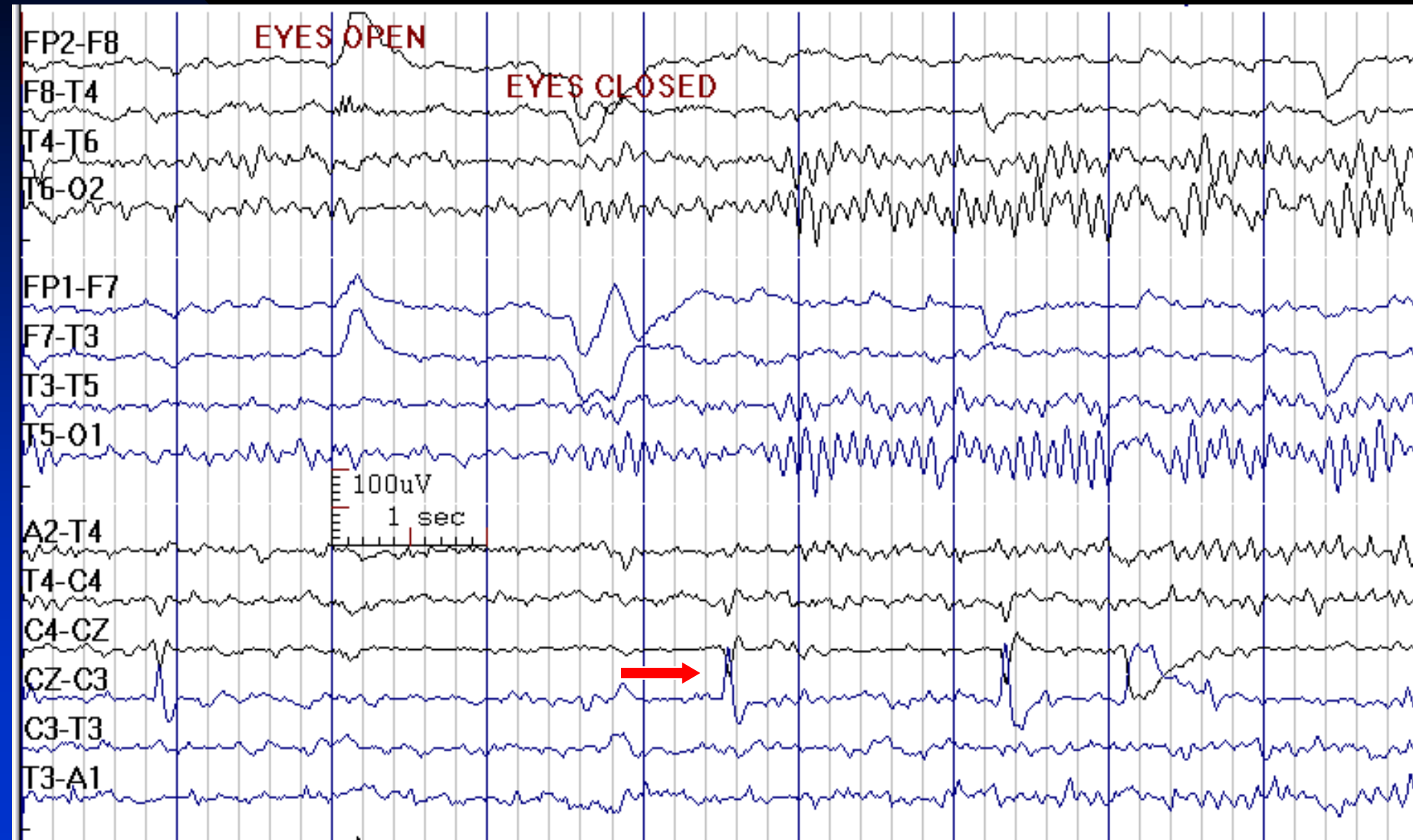


See the previous image for the same finding in temporal longitudinal montage

# Cz Sharp Waves in Wakefulness in a 7-Year-Old Boy with Epilepsy and Autism



# Cz Sharp Waves in Wakefulness in a 10-Year-Old Boy with Focal Epilepsy



# How to Report Frontal IEDs

- ***In conclusion section, write:***

**1. Frontal IEDs with history of seizures:** This EEG is consistent with a diagnosis of a localization-related (focal) epilepsy.

*Note: Frontal IEDs have limited localizing value.*

**2. Frontal IEDs without history of seizures:** This EEG demonstrates cortical irritability in the *RIGHT / LEFT* frontal lobe. While interictal epileptiform discharges may be present in individuals with a history of seizures, not all patients with spikes have seizures.

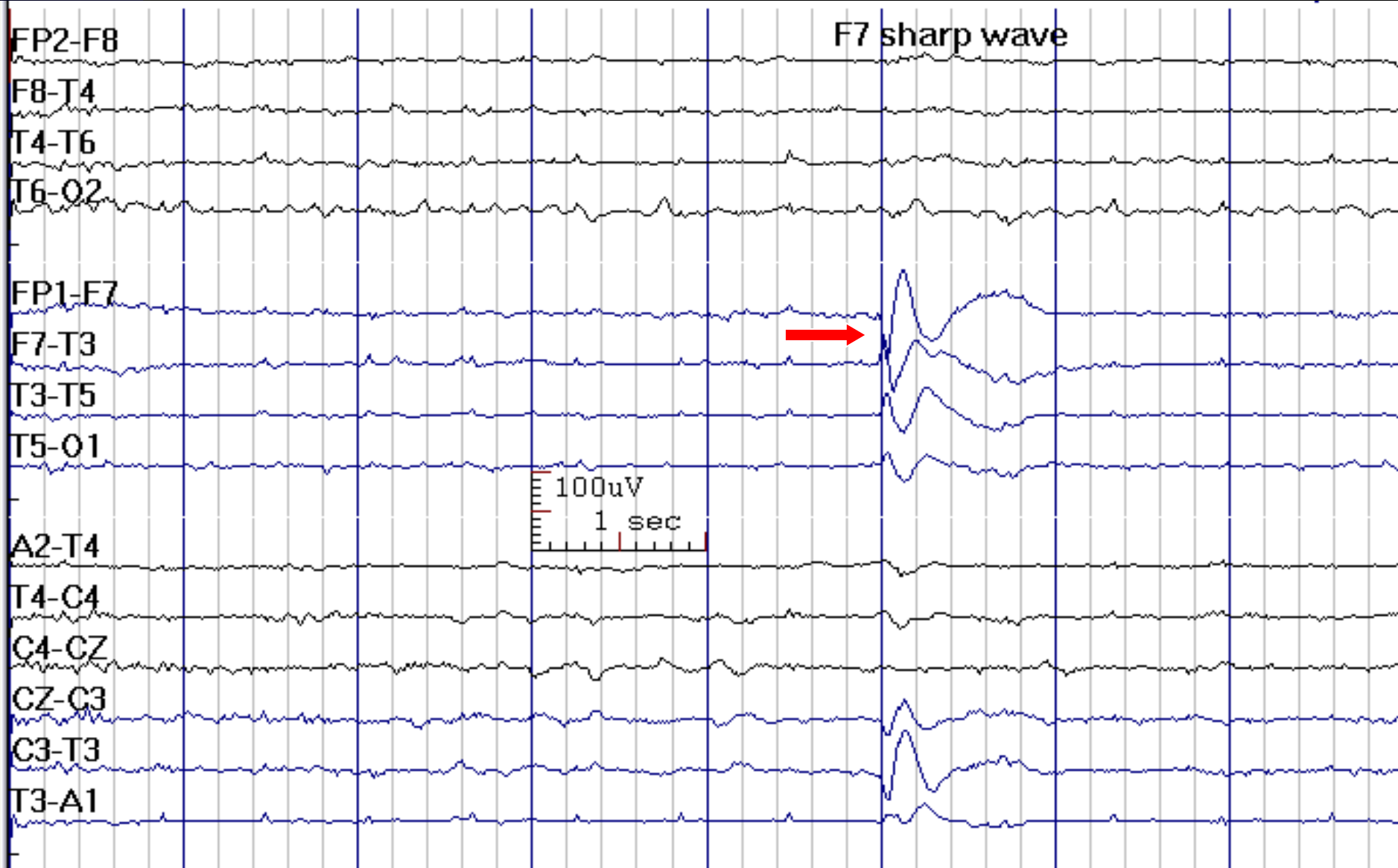


# Temporal Interictal Epileptiform Discharges

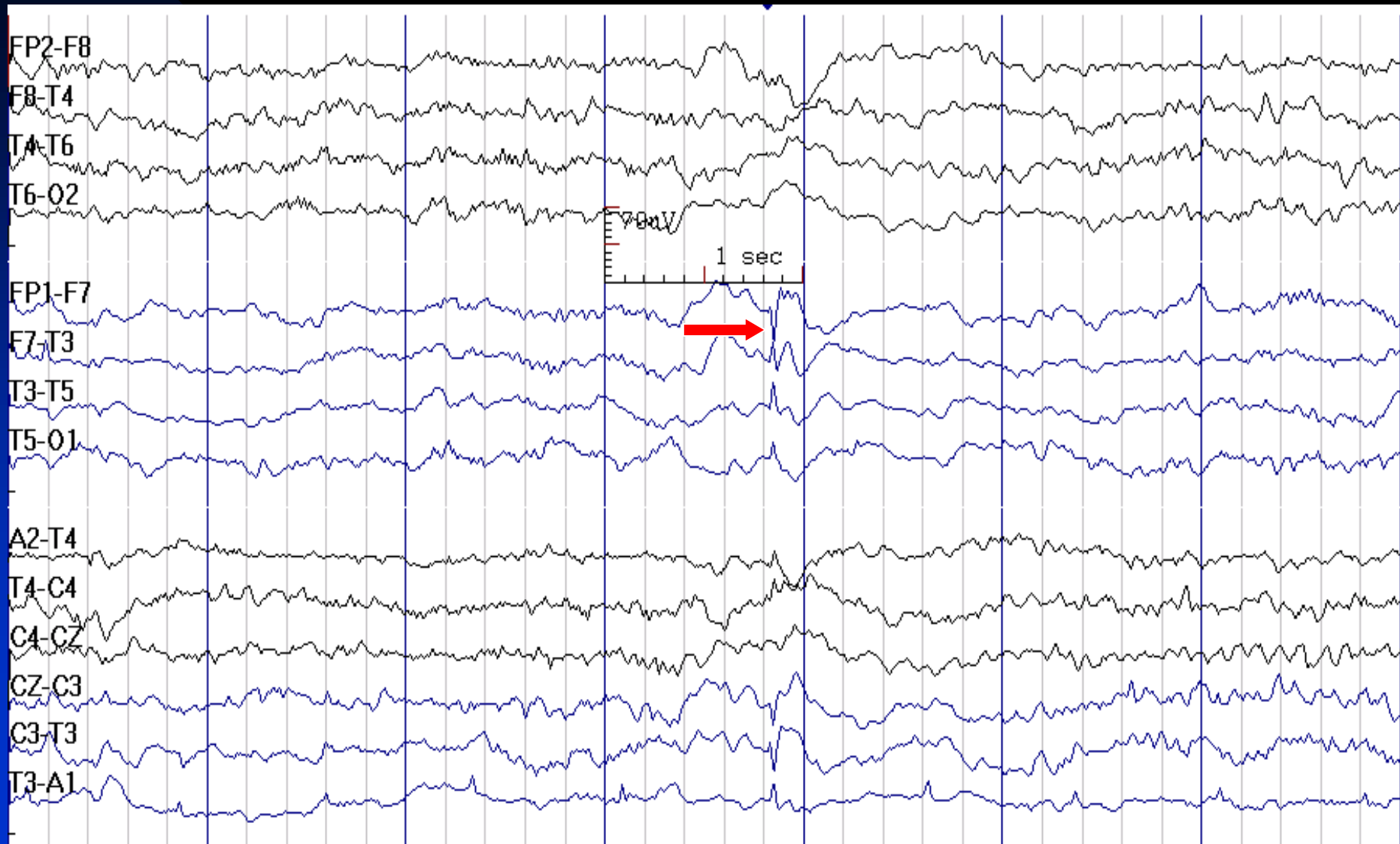
- Temporal region is the most common location for focal IEDs
- In about 1/3 of patients, temporal IEDs are present bilaterally during sleep, however strongly lateralized IEDs (> 70%) are often predictive of side of seizure onset
- F7/F8: Anterior temporal
- T3/T4: Mid-temporal
- T5/T6: Posterior temporal
- T1/T2: True anterior temporal (important in mesial temporal lobe epilepsy)



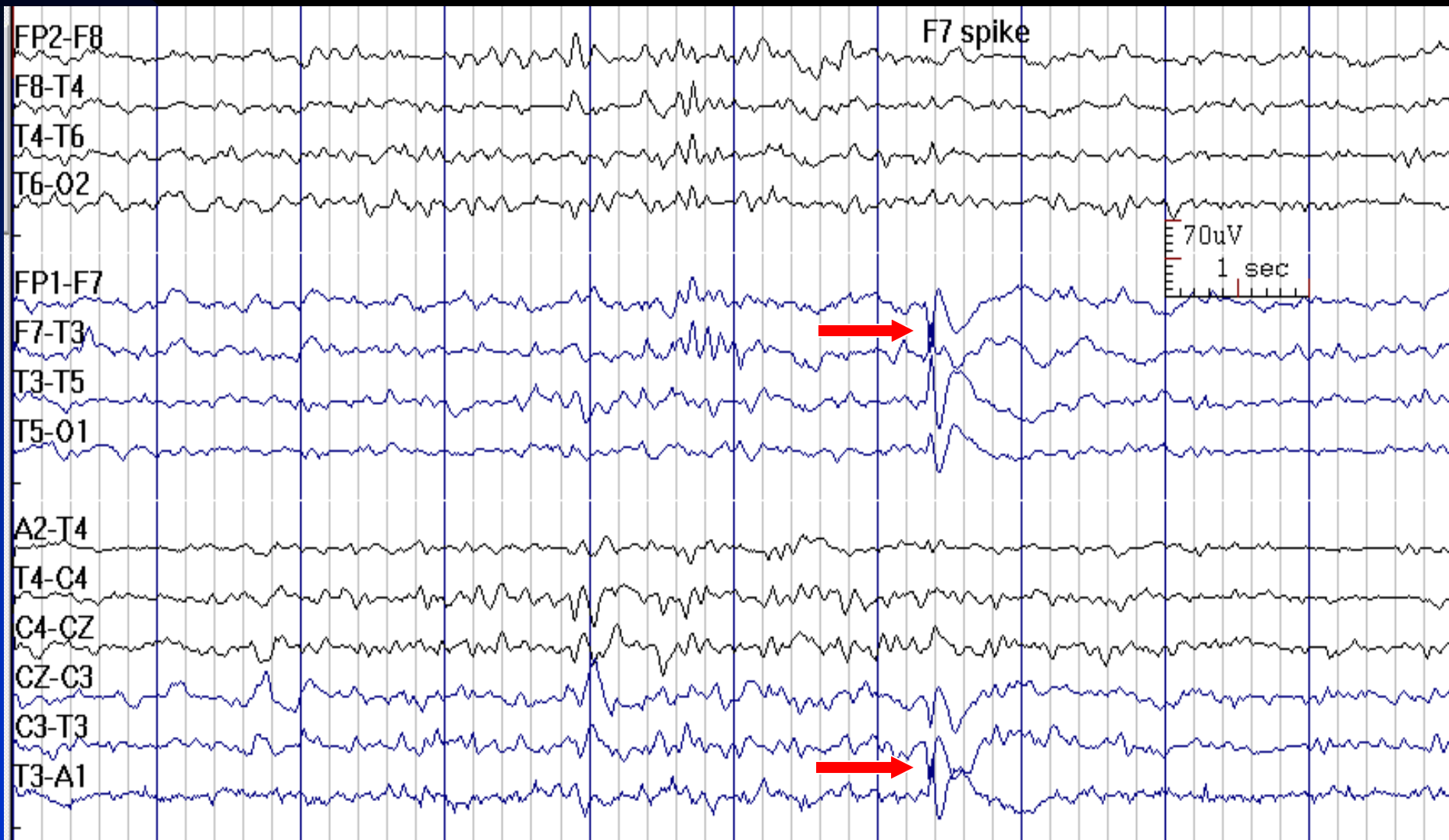
# F7 Sharp Wave in Bipolar Montage



# F7 Spike in a 35-Year-Old Woman with Post-Traumatic Temporal Lobe Epilepsy



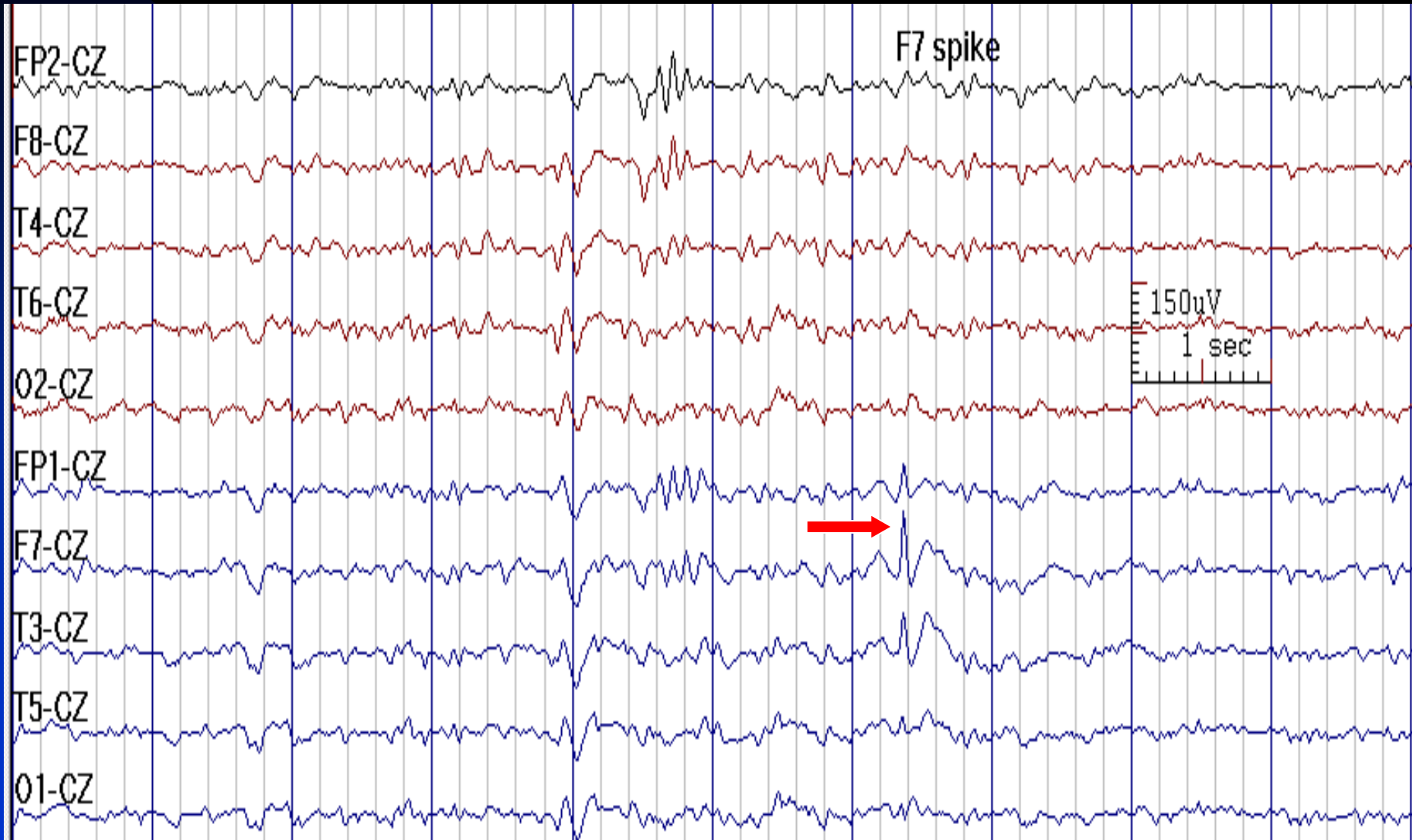
# F7 Sharp Wave in a 29-Year-Old Man with Temporal Lobe Epilepsy



See the next image for the same finding in reference montage

# F7 Sharp Wave (Highest Amplitude) in Cz Reference

(Same Discharge as in Previous Image)

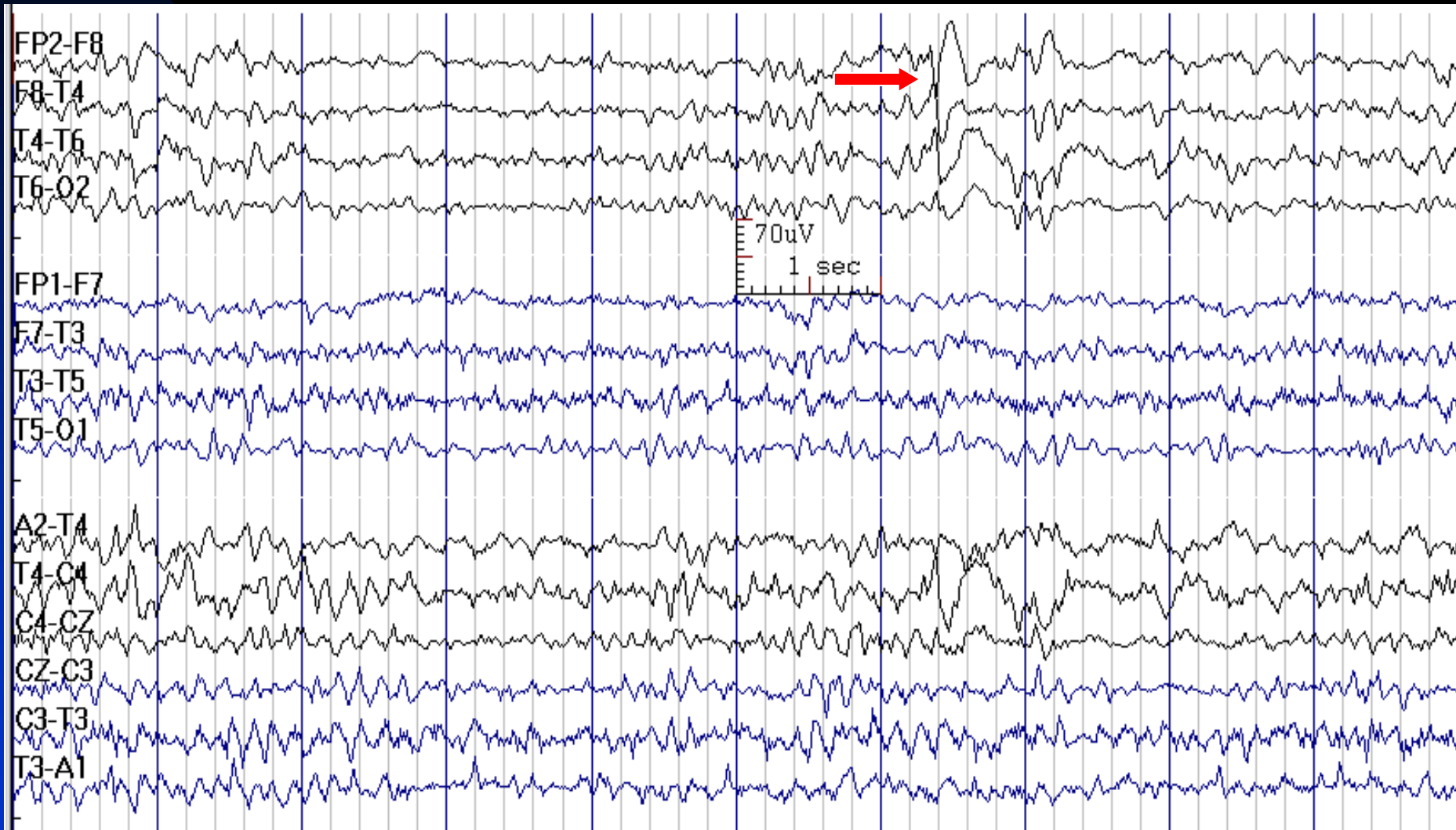


See the previous image for the same finding in temporal longitudinal montage

# Use of Reference Montage

- Reference should not be involved in the field of importance
- For temporal chain (F7/F8, T3/T4, T5/T6), Cz is a good reference
- For parasagittal chain (F3/F4, C3/C4, P3/P4), ear is a good reference
- Presence of out of phase potential in a reference montage indicates involvement of the reference in the field of the discharge of interest

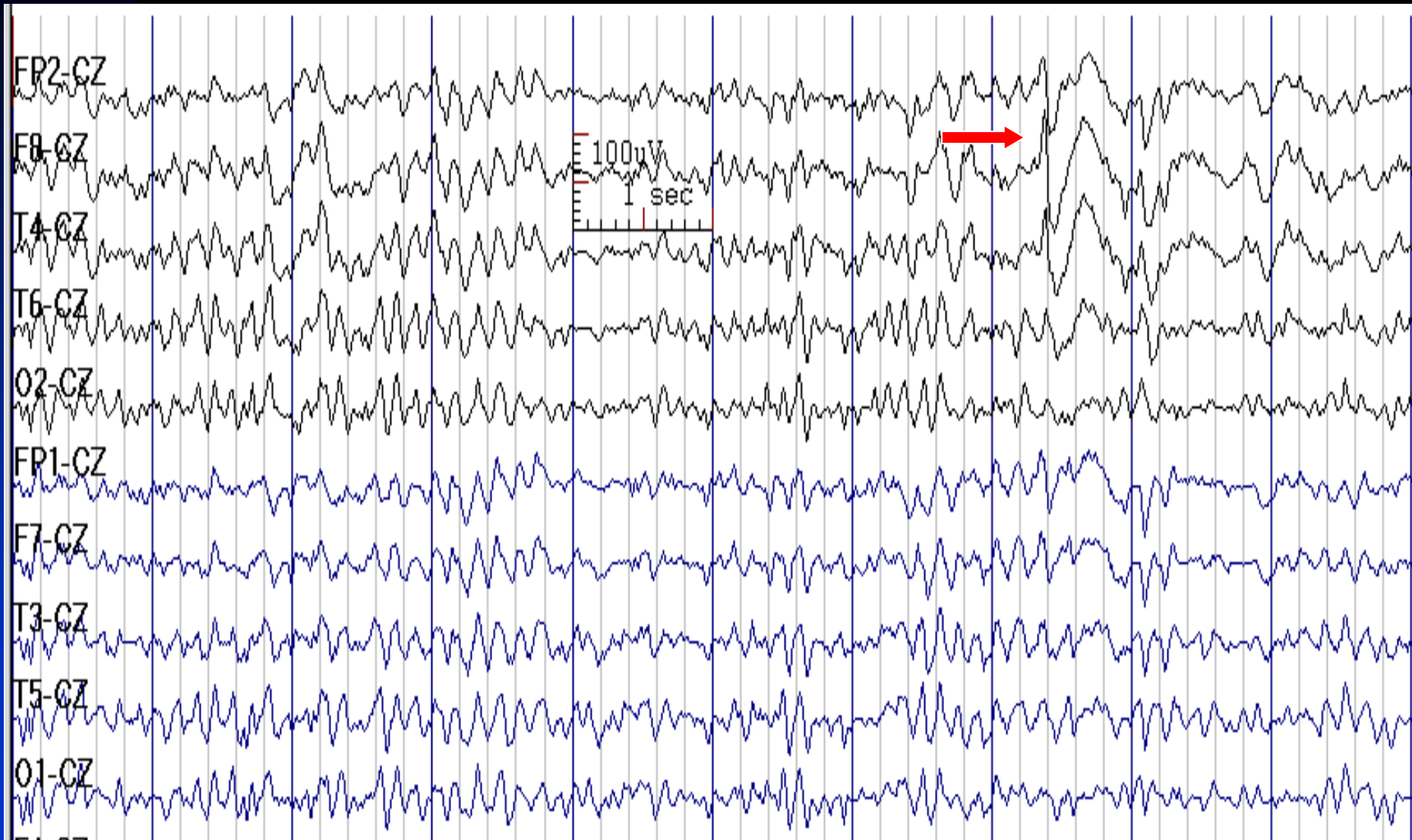
# F8 Spike in a 35-Year-Old Man with Temporal Lobe Epilepsy (Maximum Negativity in Bipolar Montage)



See the next image for the same finding in reference montage

# F8 Spike

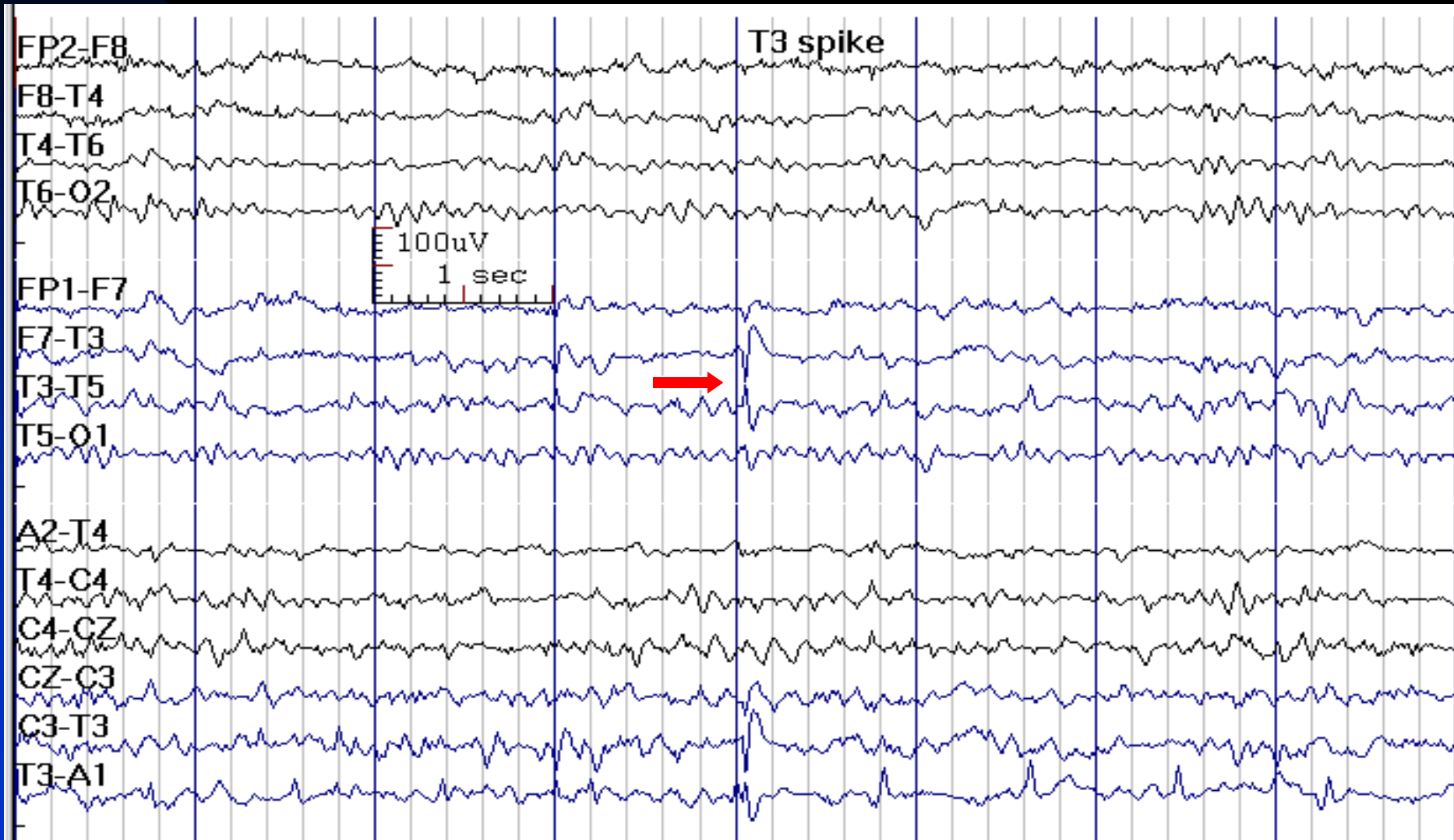
(Maximum Amplitude in Cz Reference Montage, Previous Image)



See the previous image for the same finding in temporal longitudinal montage



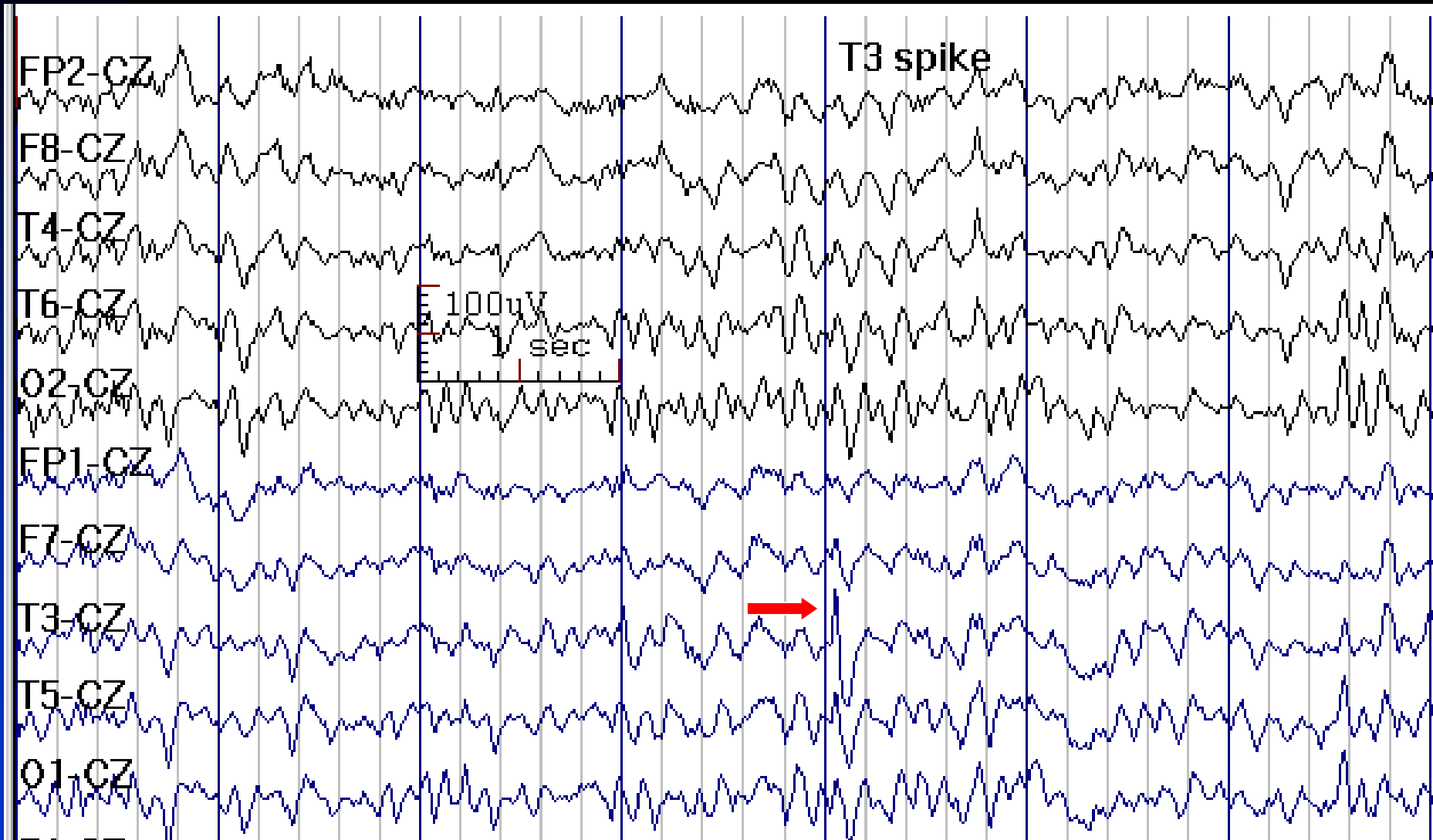
# T3 Spike in a 26-Year-Old Man with Temporal Lobe Epilepsy (Maximum Negativity in Bipolar Montage)



See the next image for the same finding in reference montage

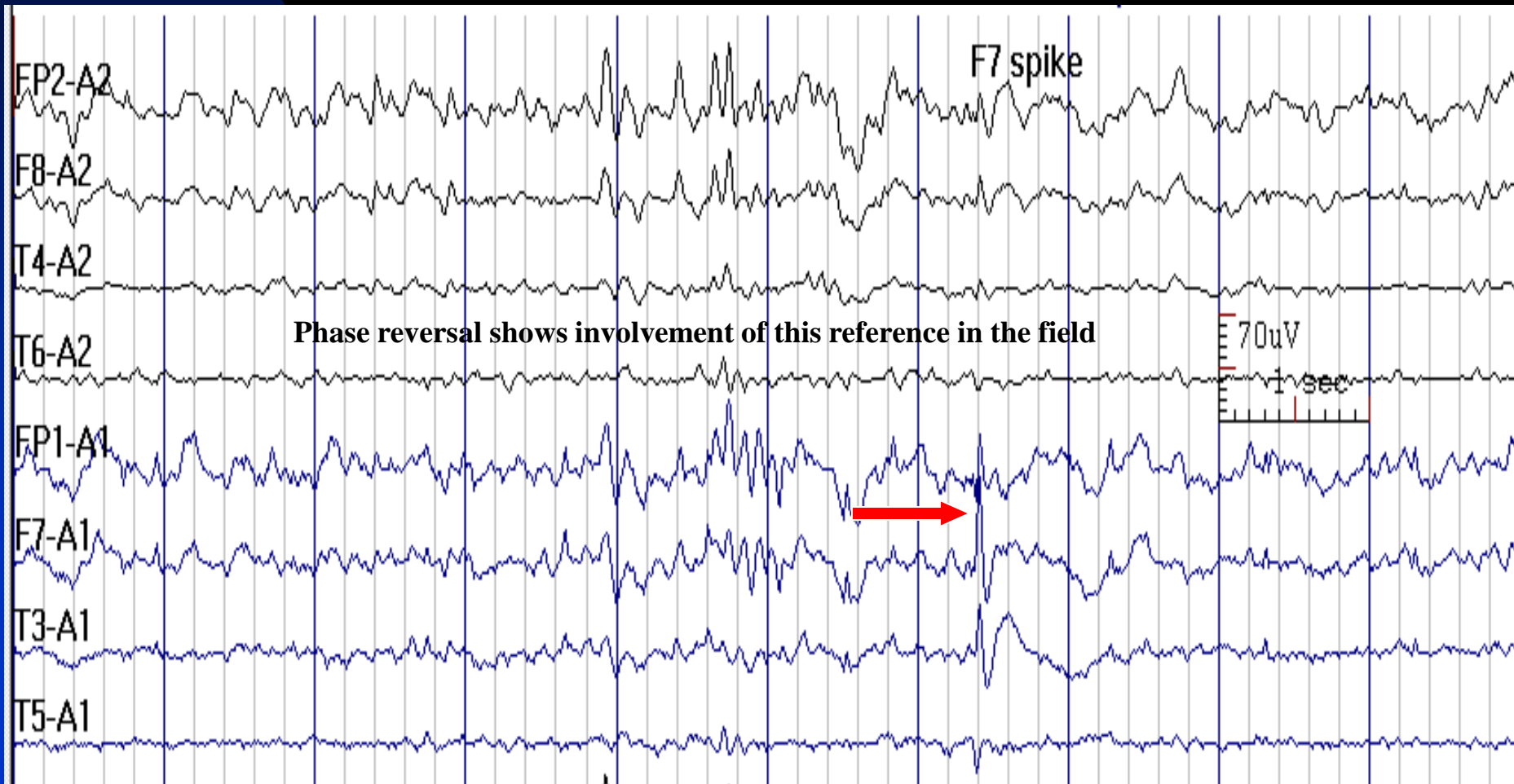


# T3 Spike (Maximum Amplitude in Reference Montage)

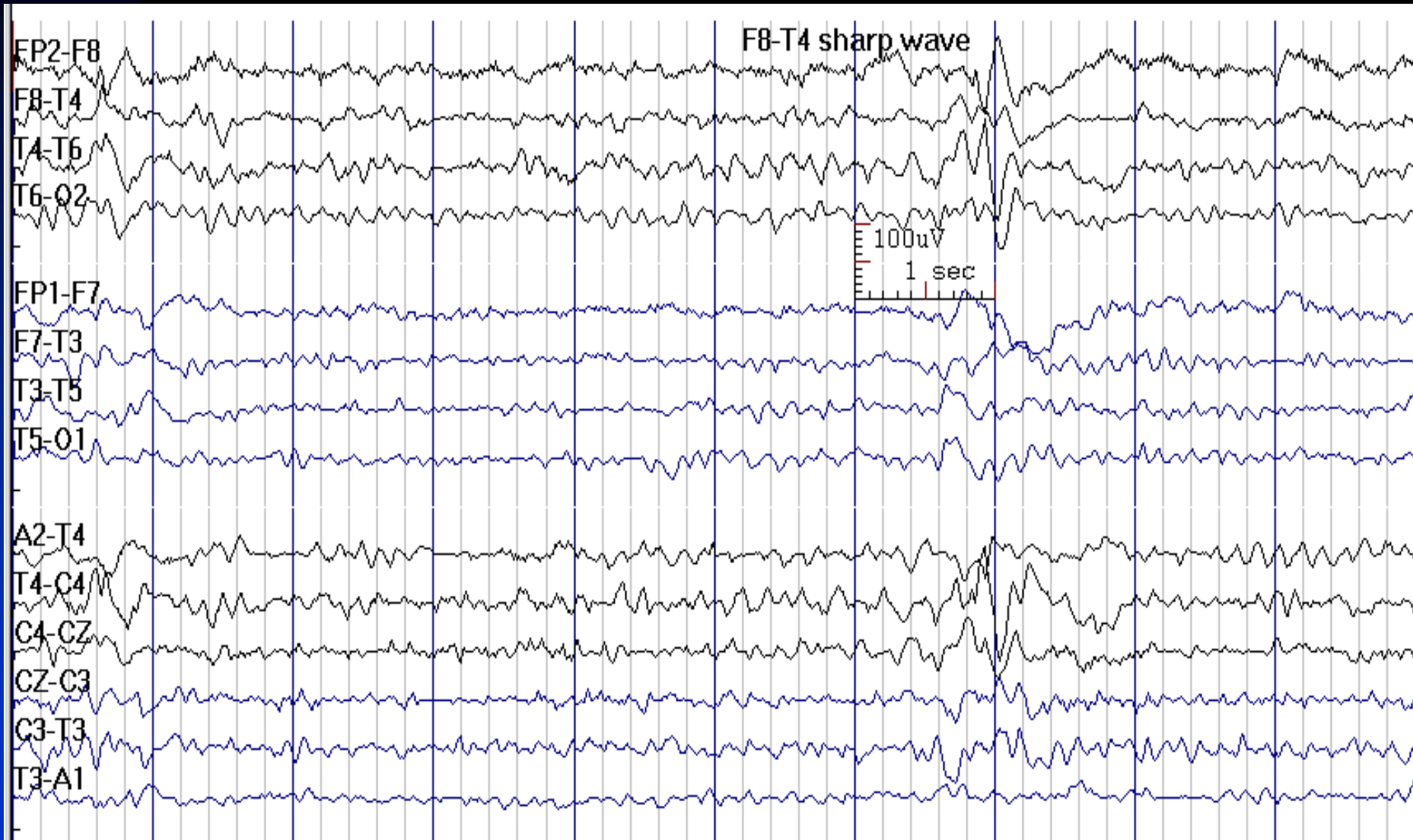


See the previous image for the same finding in temporal longitudinal montage

# Ear is not a Good Reference for Temporal Chain

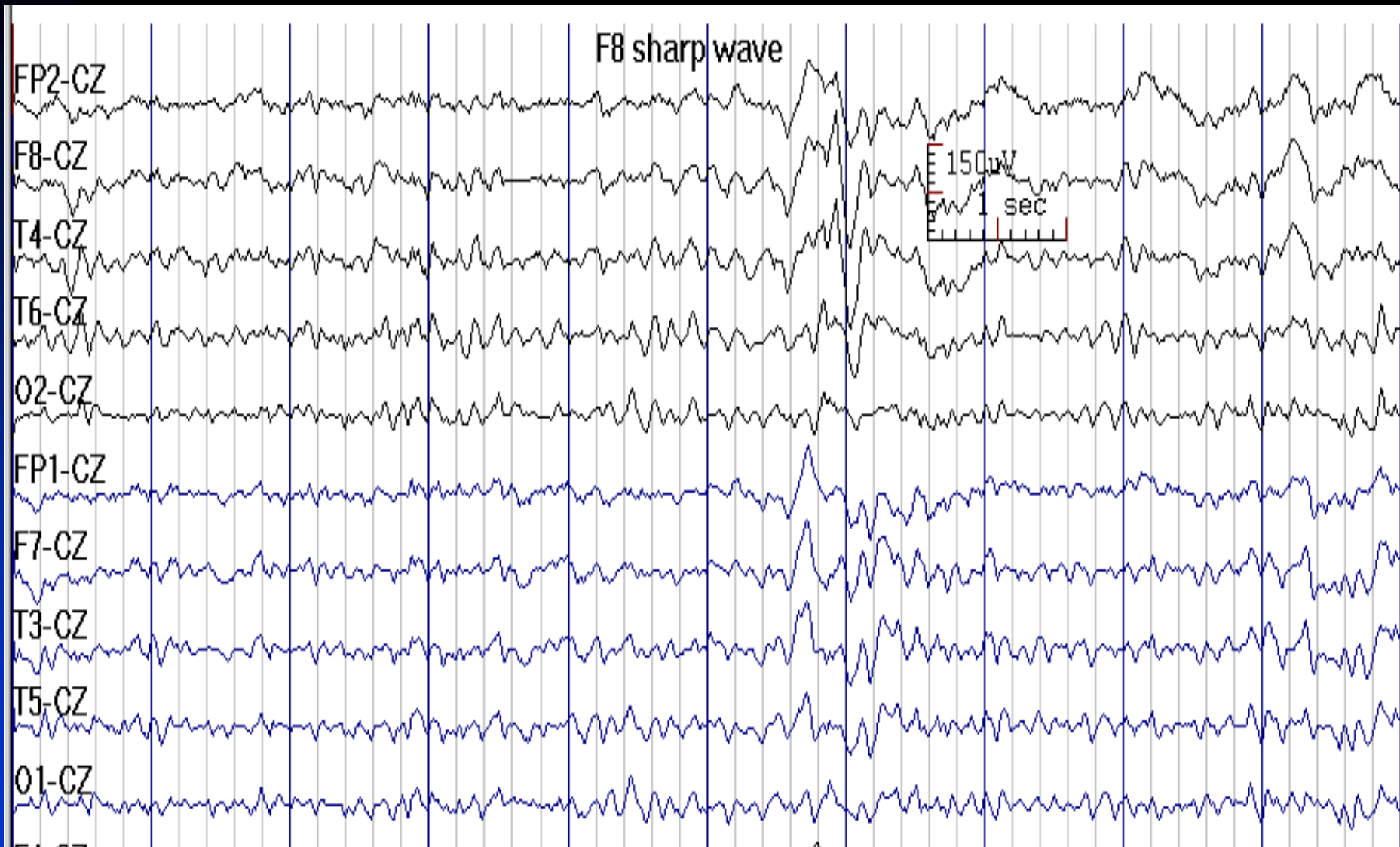


# F8/T4 Sharp Wave in a 51-Year-Old Man with Mesial Temporal Lobe Epilepsy



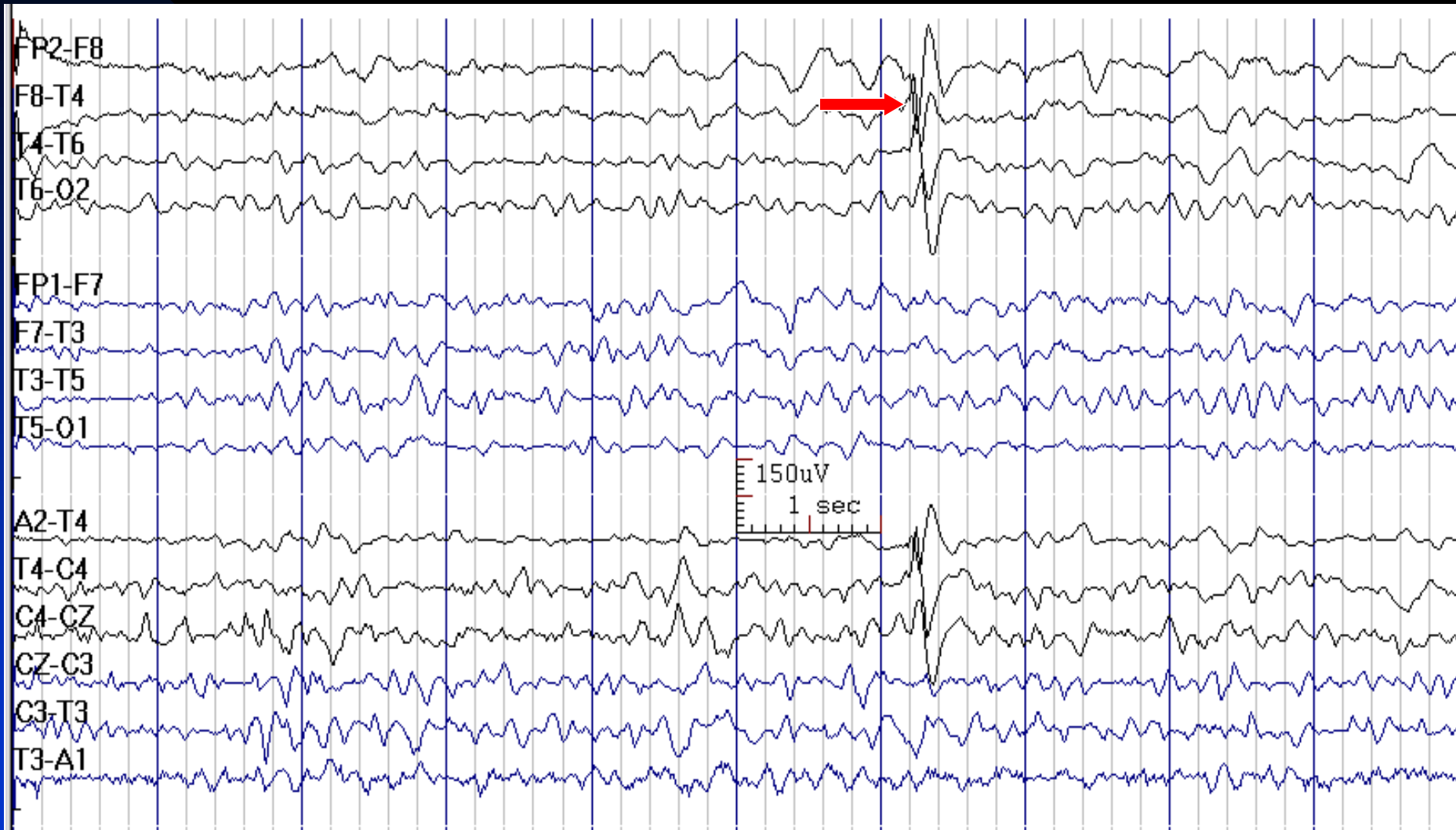See the next image for the same finding in reference montage

# F8 Sharp Wave in Cz Referential Montage



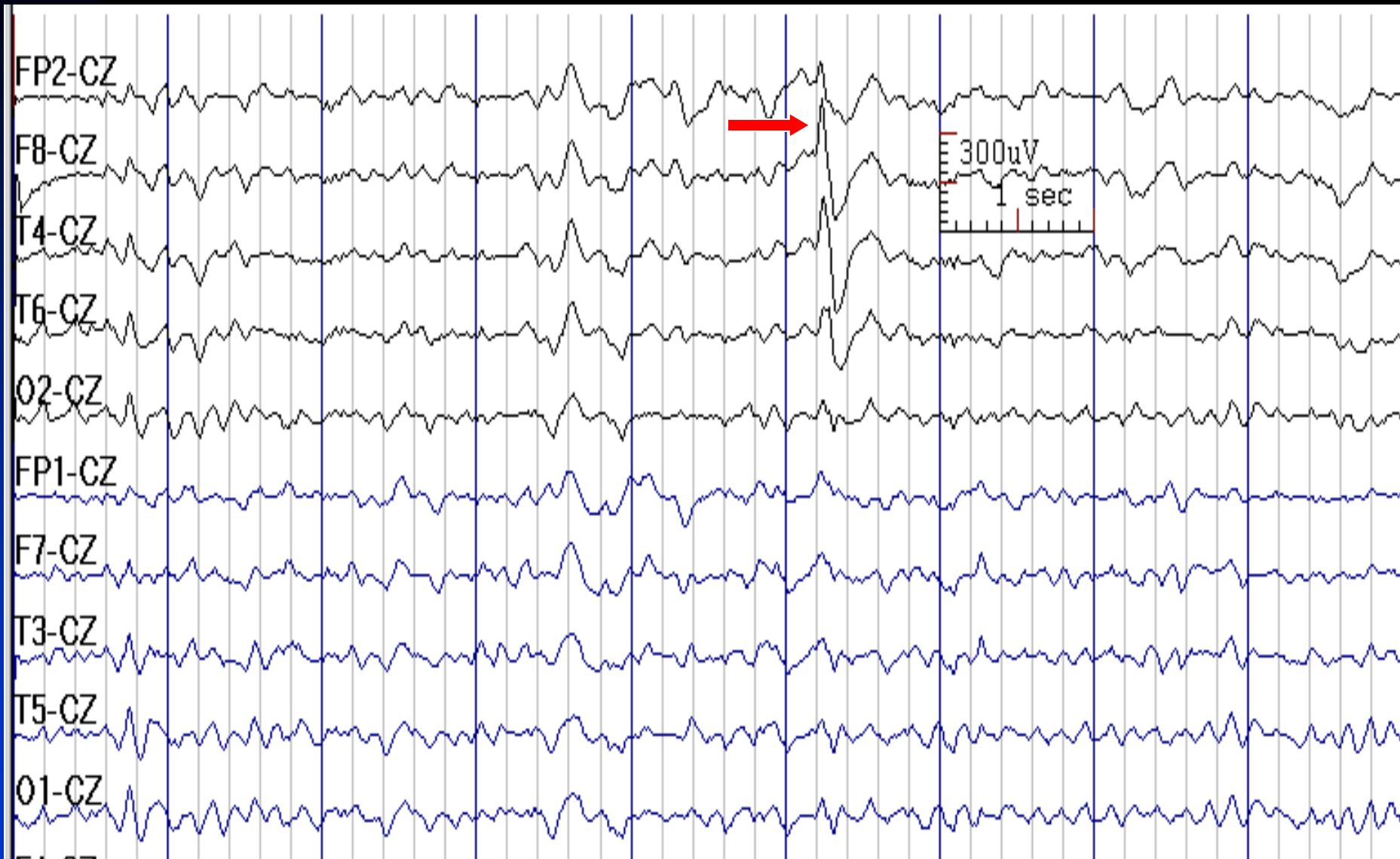
See the previous image for the same finding in temporal longitudinal montage

# F8 Sharp Wave in a 83-Year-Old Woman with Focal Epilepsy



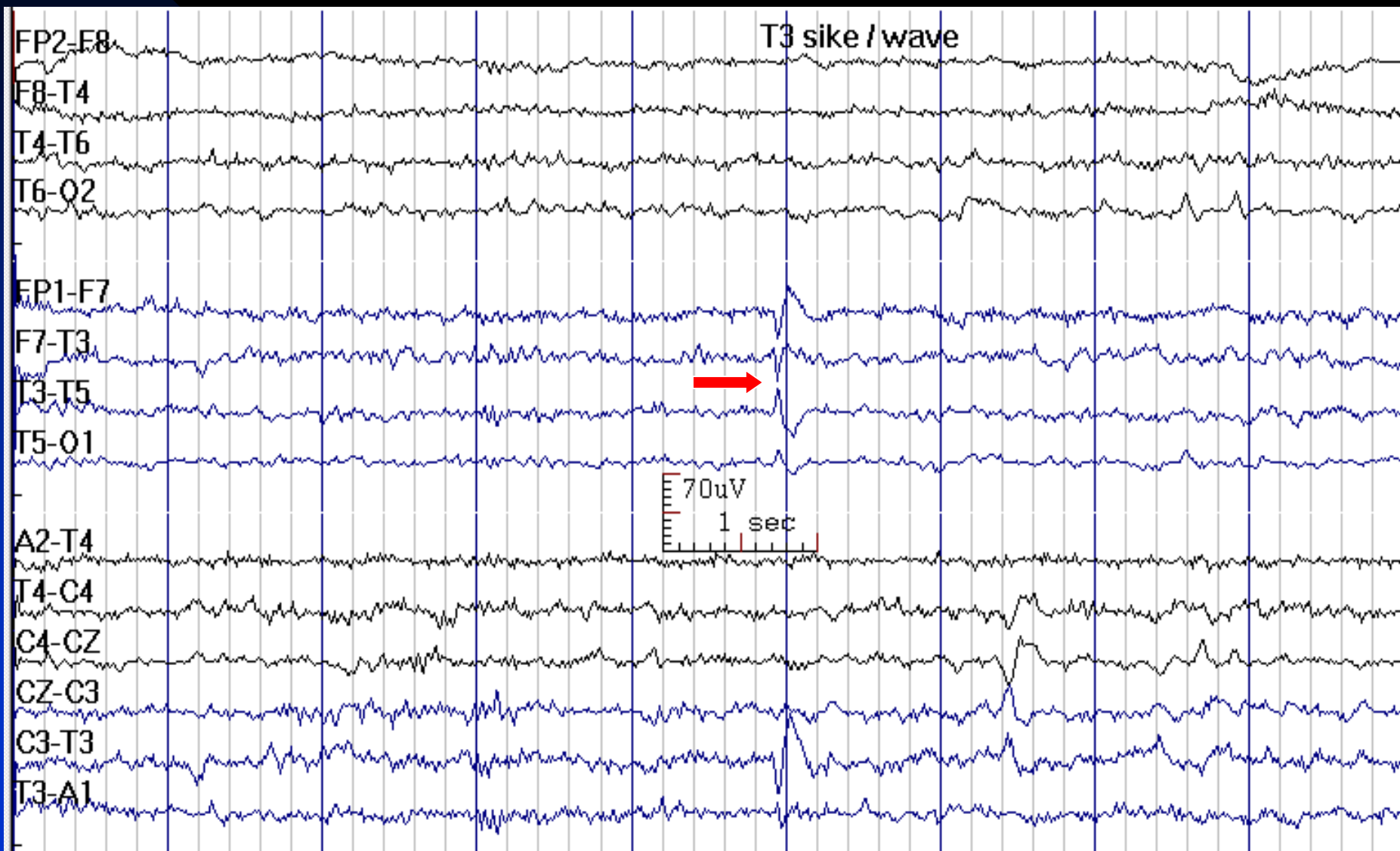
See the next image for the same finding in reference montage

# F8 Sharp Wave (Previous Image in Reference Montage)



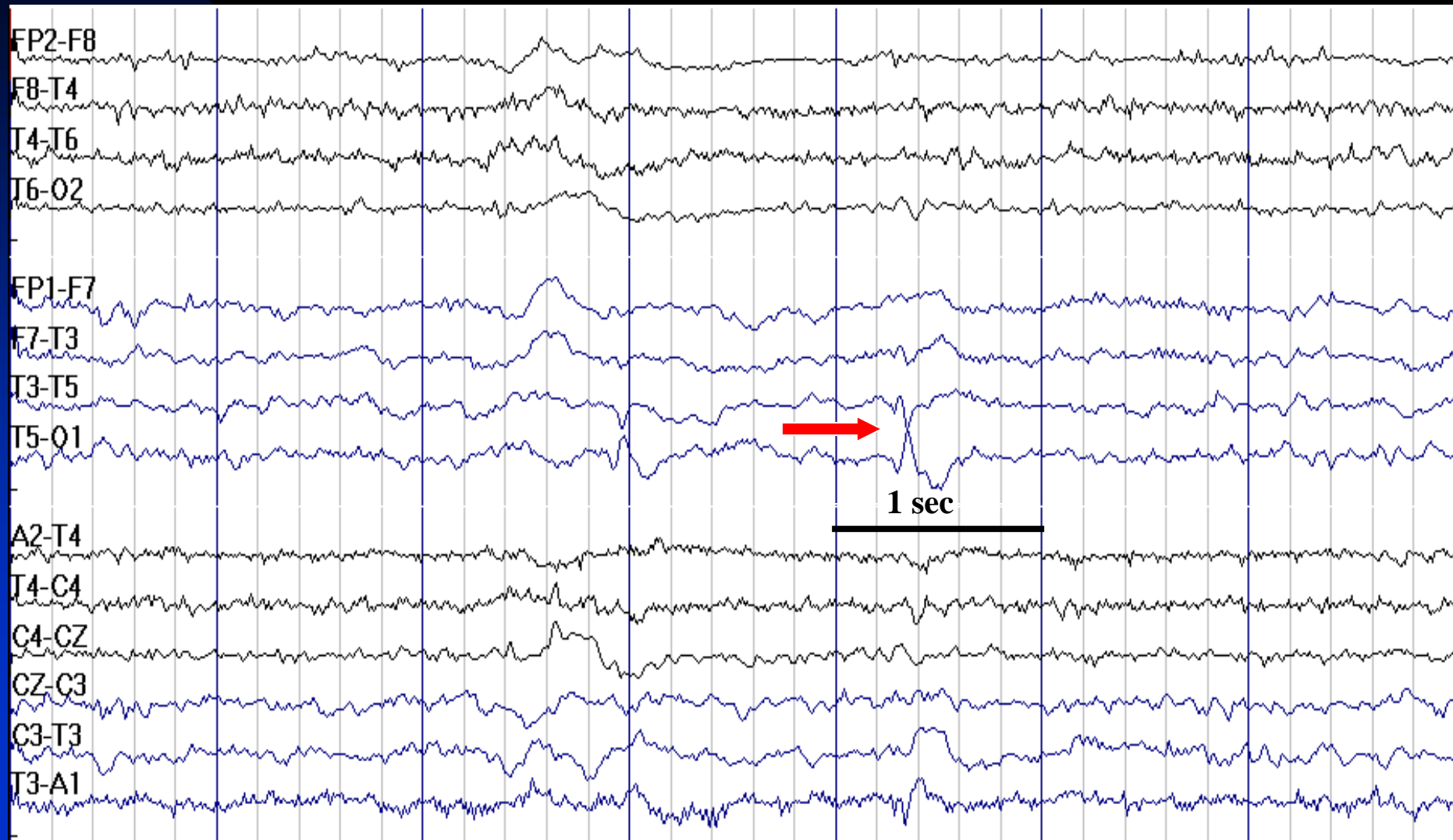
See the previous image for the same finding in temporal longitudinal montage

# T3 Spike in a 27-Year-Old Man with Temporal Lobe Epilepsy



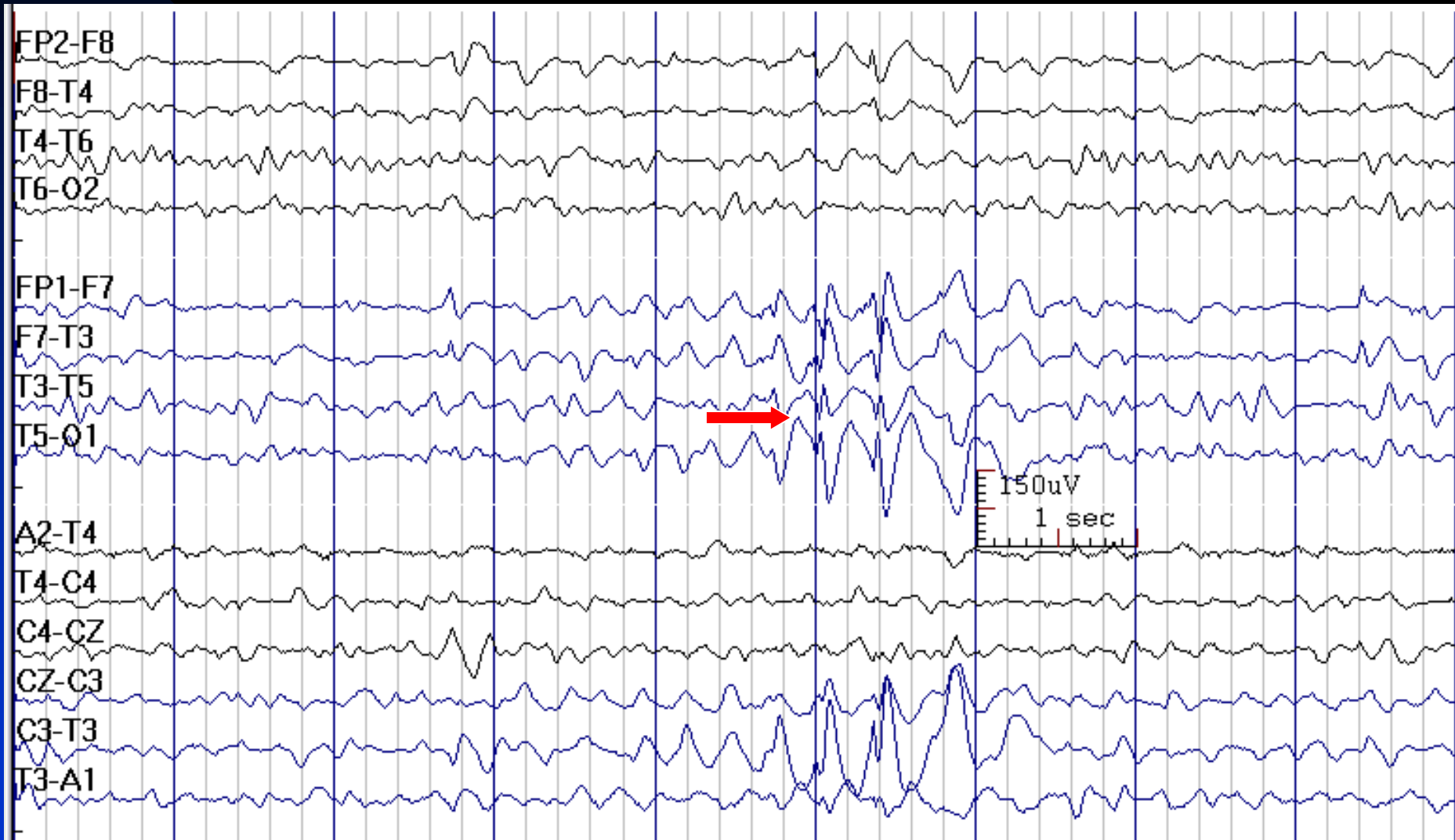

# T5 Sharp Wave in a 35-Year-Old Woman with Post-Traumatic Epilepsy



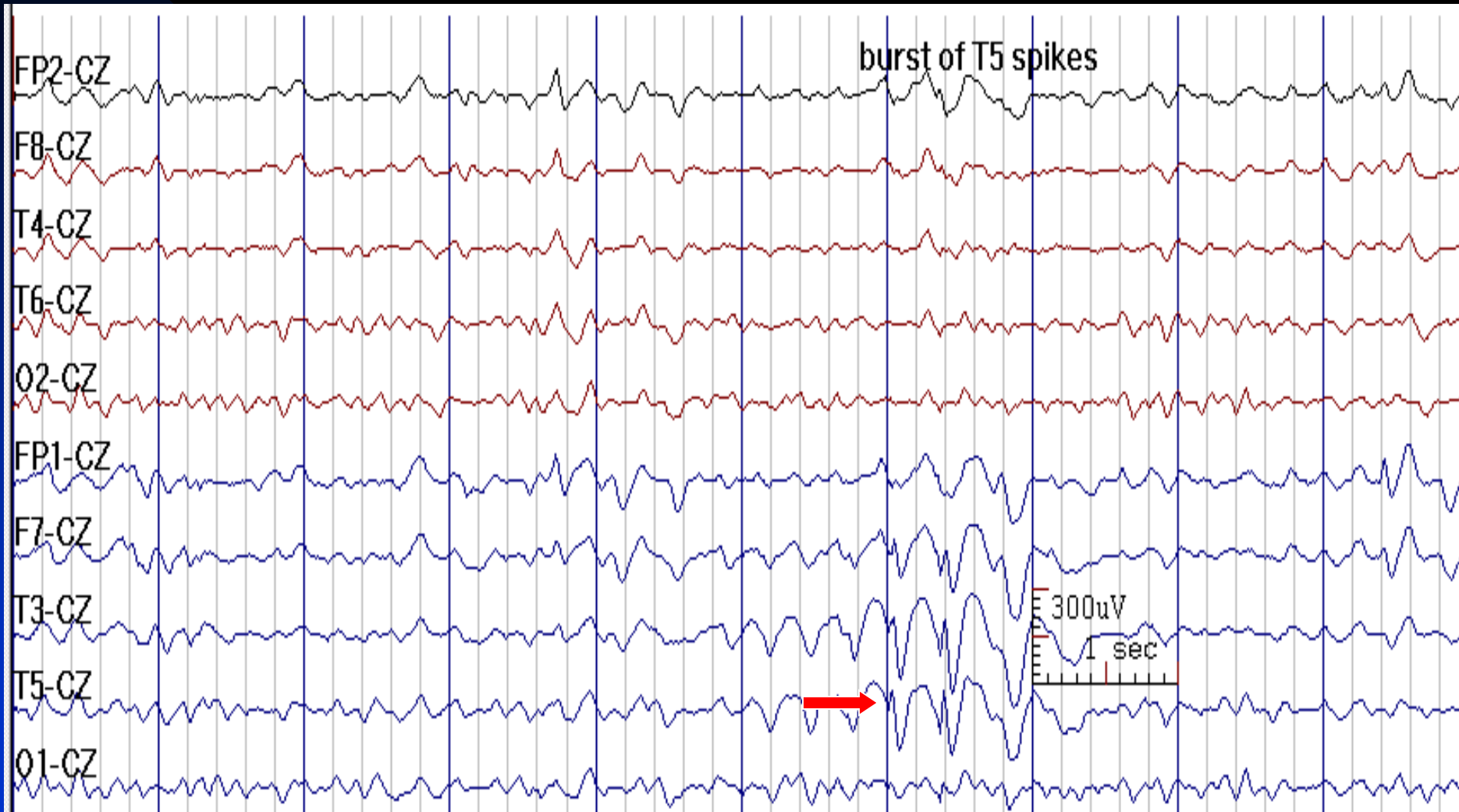


# T5 Spike with Broad Field Extent in Bipolar Montage in a 9-Year-Old Girl with Epilepsy



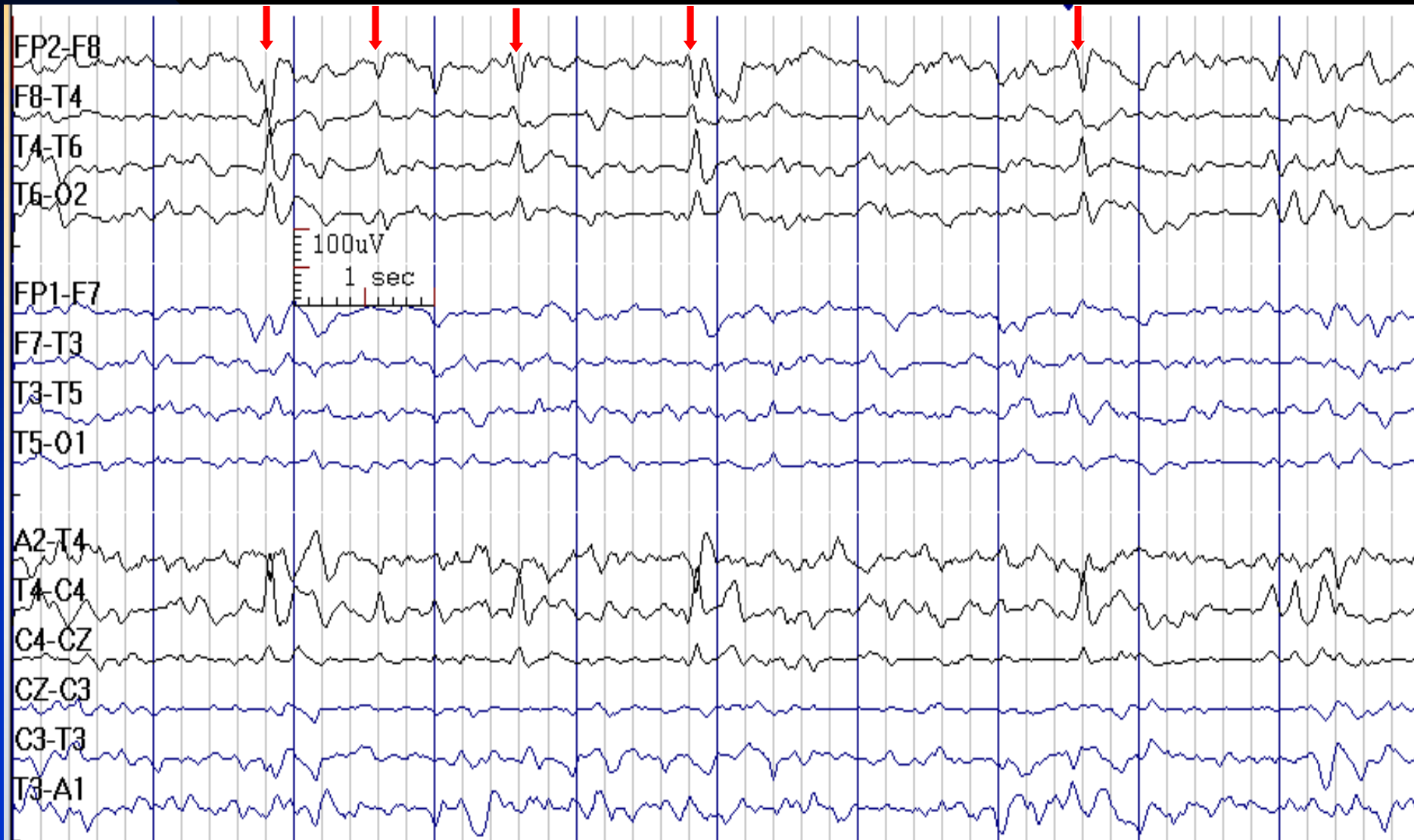
See the next image for the same finding in reference montage

# T5 Spikes (Same as the Previous Image) in Cz Reference Montage



See the previous image for the same finding in temporal longitudinal montage

# Frequent F8 Sharp Waves



# How to Report Temporal IEDs

- ***In conclusion section, write:***

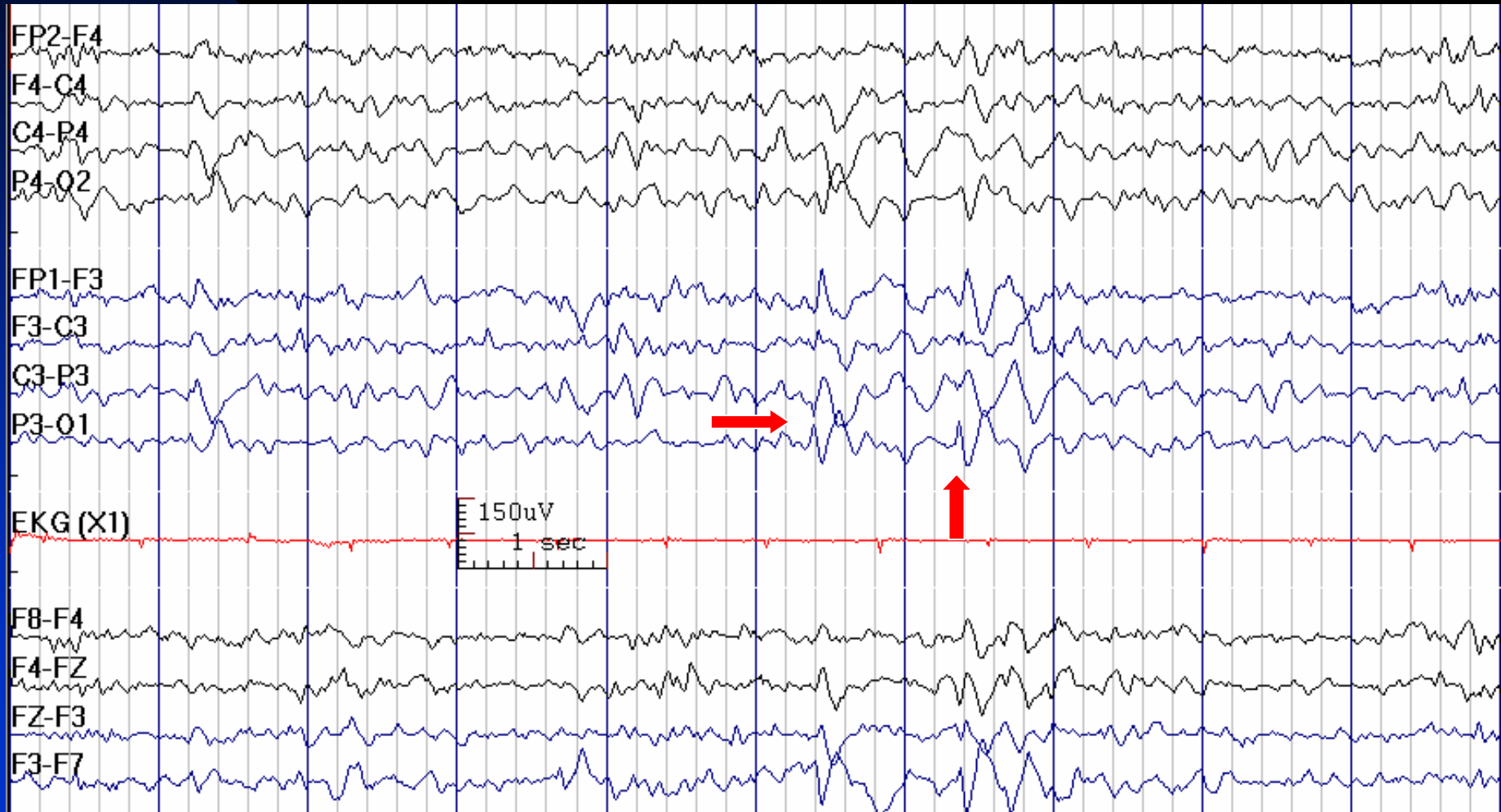
**1. Temporal IEDs with history of seizures:** This EEG is consistent with a diagnosis of a localization-related (focal) epilepsy with seizures possibly arising from RIGHT / LEFT temporal lobe.

**2. Temporal IEDs without history of seizures:** This EEG demonstrates cortical dysfunction and irritability in the RIGHT / LEFT temporal lobe. While interictal spikes may be present in individuals with a history of seizures, not all patients with spikes have seizures, though the specificity of temporal lobe interictal epileptiform discharges is fairly high.

# Parietal Interictal Epileptiform Discharges

- P3/P4 (possibly with central spread)
- Less common location for IEDs
- Parasagittal montage is appropriate to analyze epileptiform discharges in these areas
- In parietal lobe epilepsy, scalp EEG recordings are usually nonlocalizing or falsely localizing

# 13-Year-Old Boy with Right Arm and Shoulder Twitches with P3 Spikes



# How to Report Parietal IEDs

- ***In conclusion section, write:***

**1. Parietal IEDs with history of seizures:** This EEG is consistent with a diagnosis of a localization-related (focal) epilepsy.

*Note: Parietal IEDs have limited localizing value.*

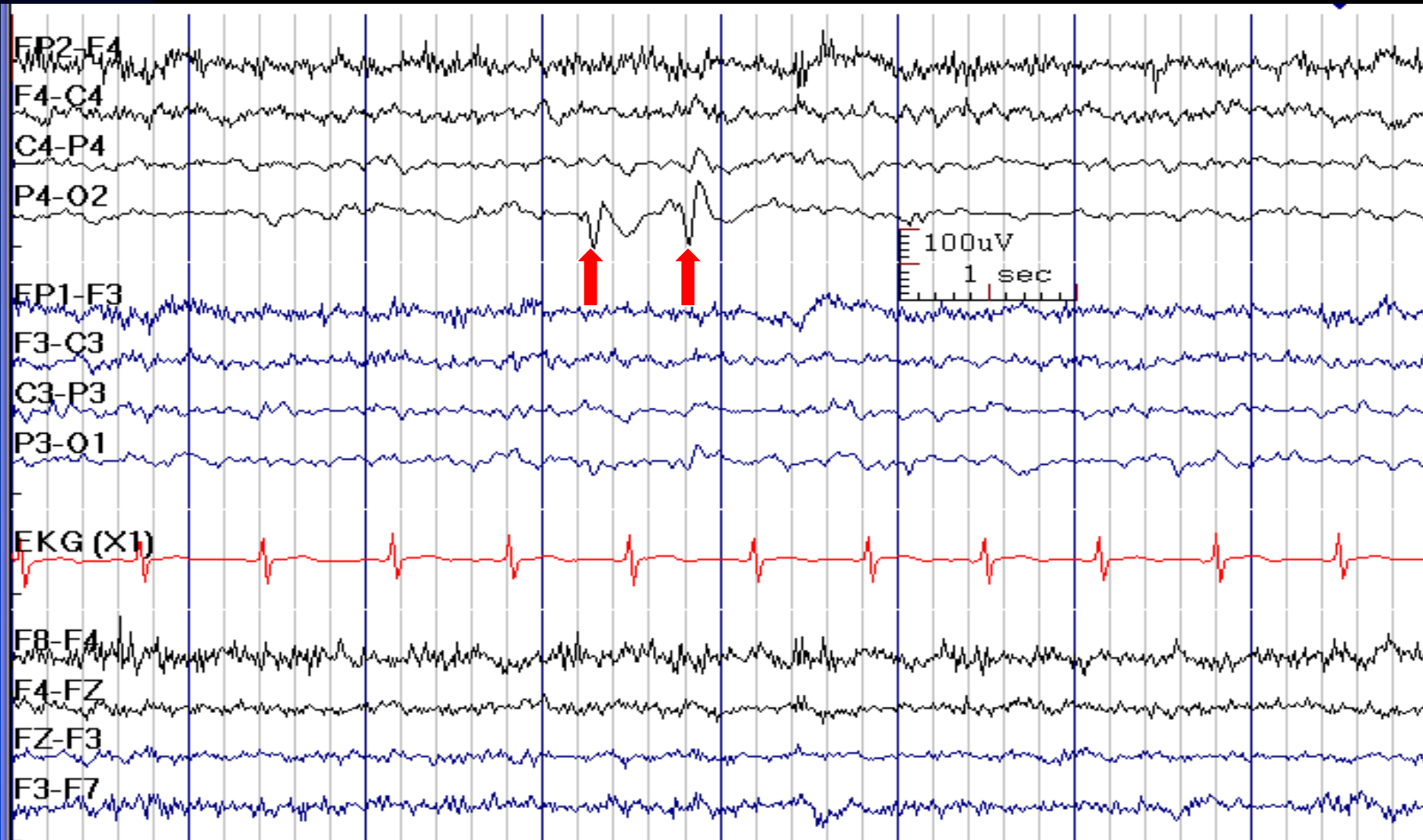
**2. Parietal IEDs without history of seizures:** This EEG demonstrates cortical irritability in the *RIGHT / LEFT* Parietal lobe. While interictal epileptiform discharges may be present in individuals with a history of seizures, not all patients with spikes have seizures.

# Occipital Interictal Epileptiform Discharges

- Maximum at O1 or/and O2
- Circle montage is appropriate to analyze epileptiform discharges at O1 or O2 leads
- Carefully check reactivity to eye closure and eye opening.  
Occipital spikes are most abundant with eyes closed
- In occipital lobe epilepsy, scalp EEG recordings are often nonlocalizing or falsely localizing

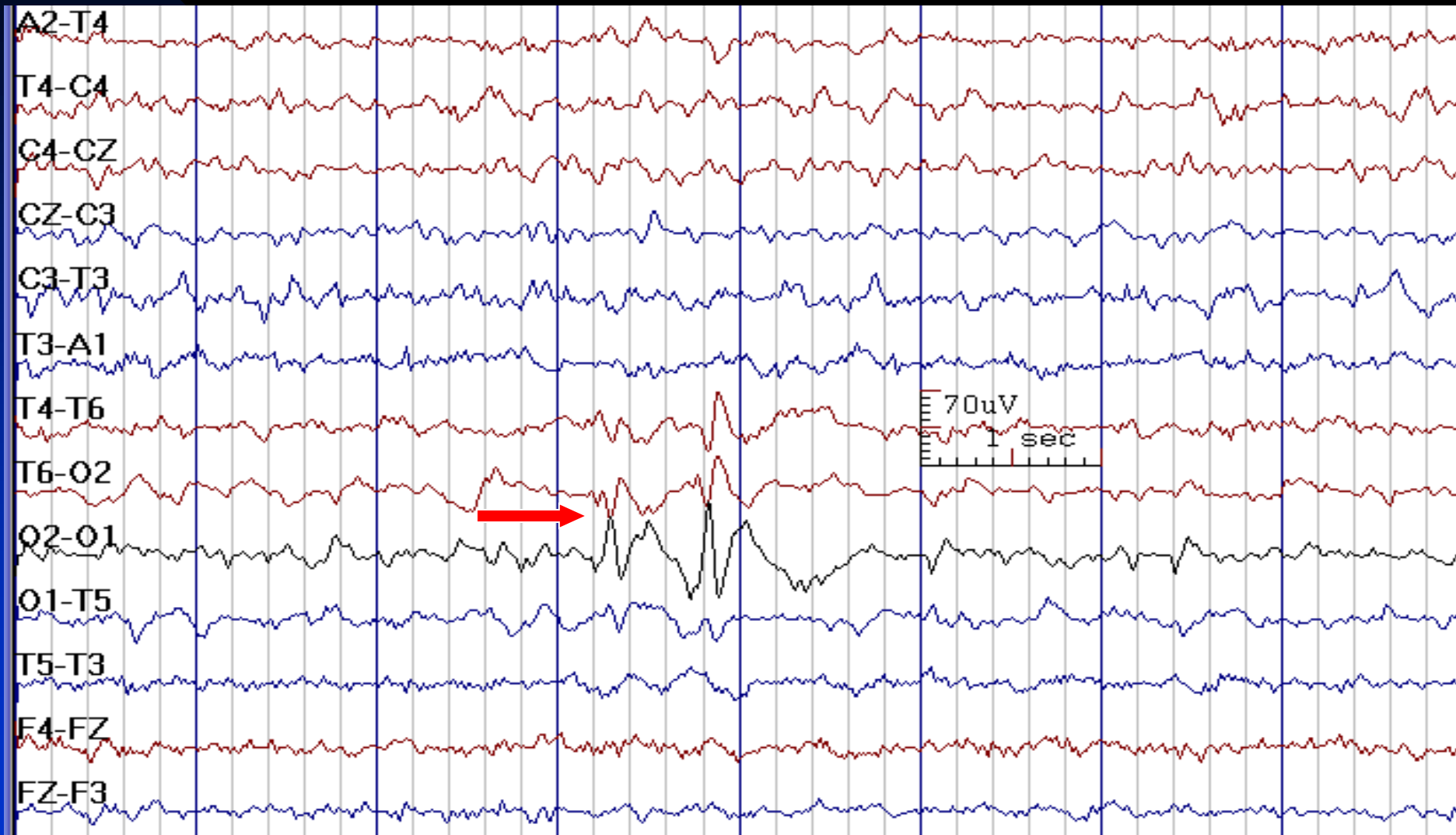


# O2 Sharp Waves in a 9-Year-Old Boy with Occipital Epilepsy



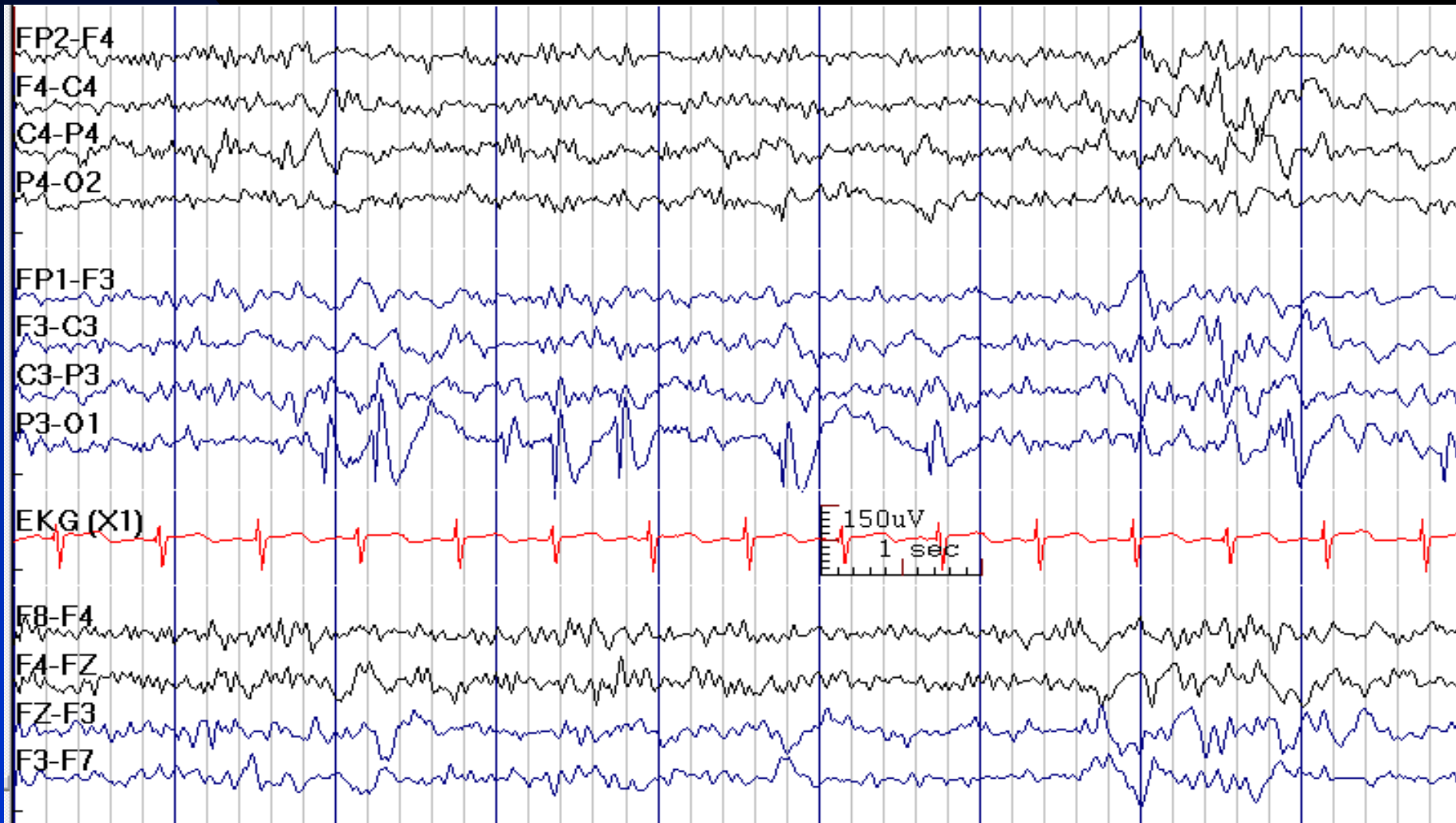
See the next image for the same finding in circular montage

# Previous Slide in Circle Montage (O2 Sharp Waves)



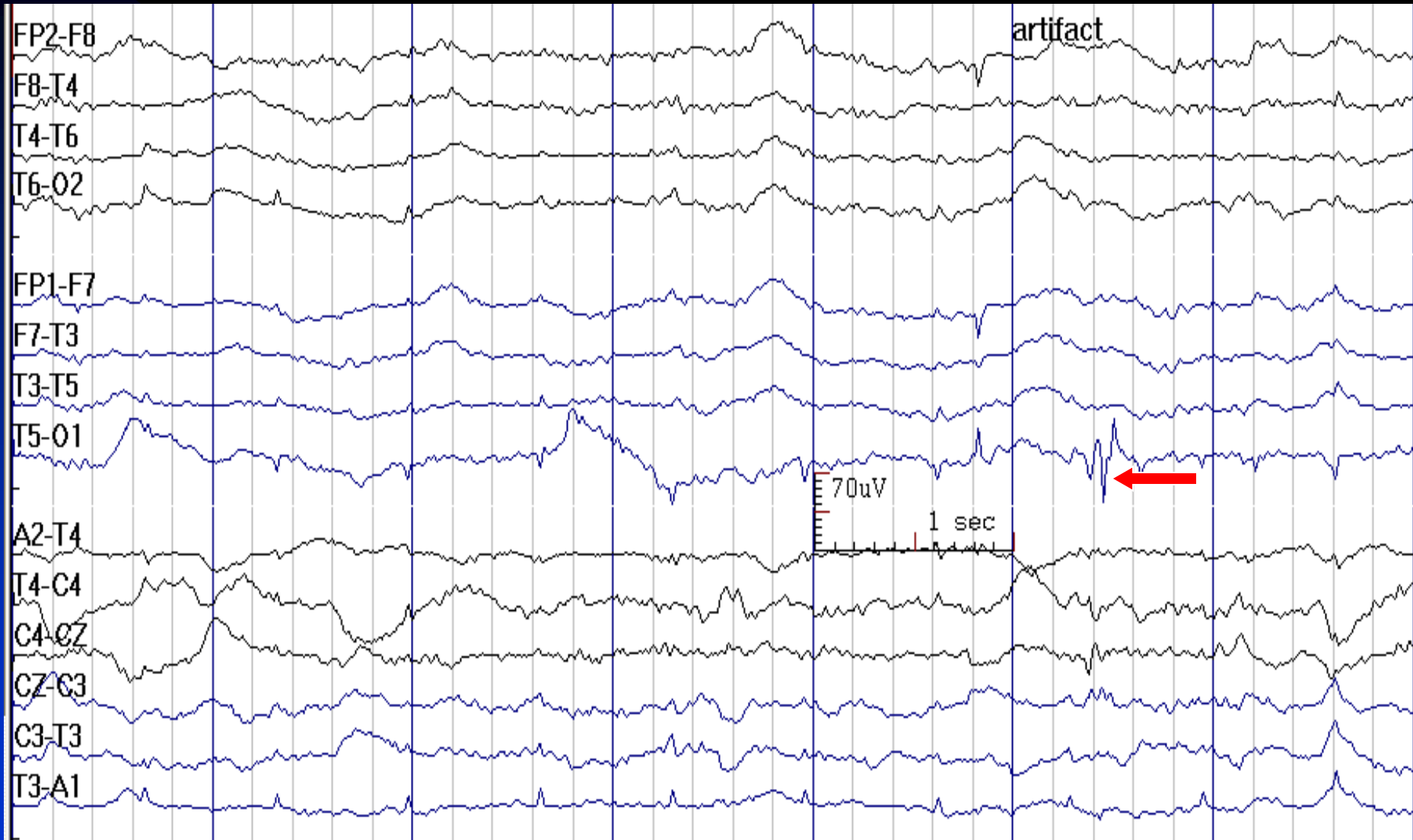
See the previous image for the same finding in parasagittal longitudinal montage

# Run of O1 Spikes in Sleep in a 6-Year-Old Boy



# O1 Artifact Mimicking a Spike

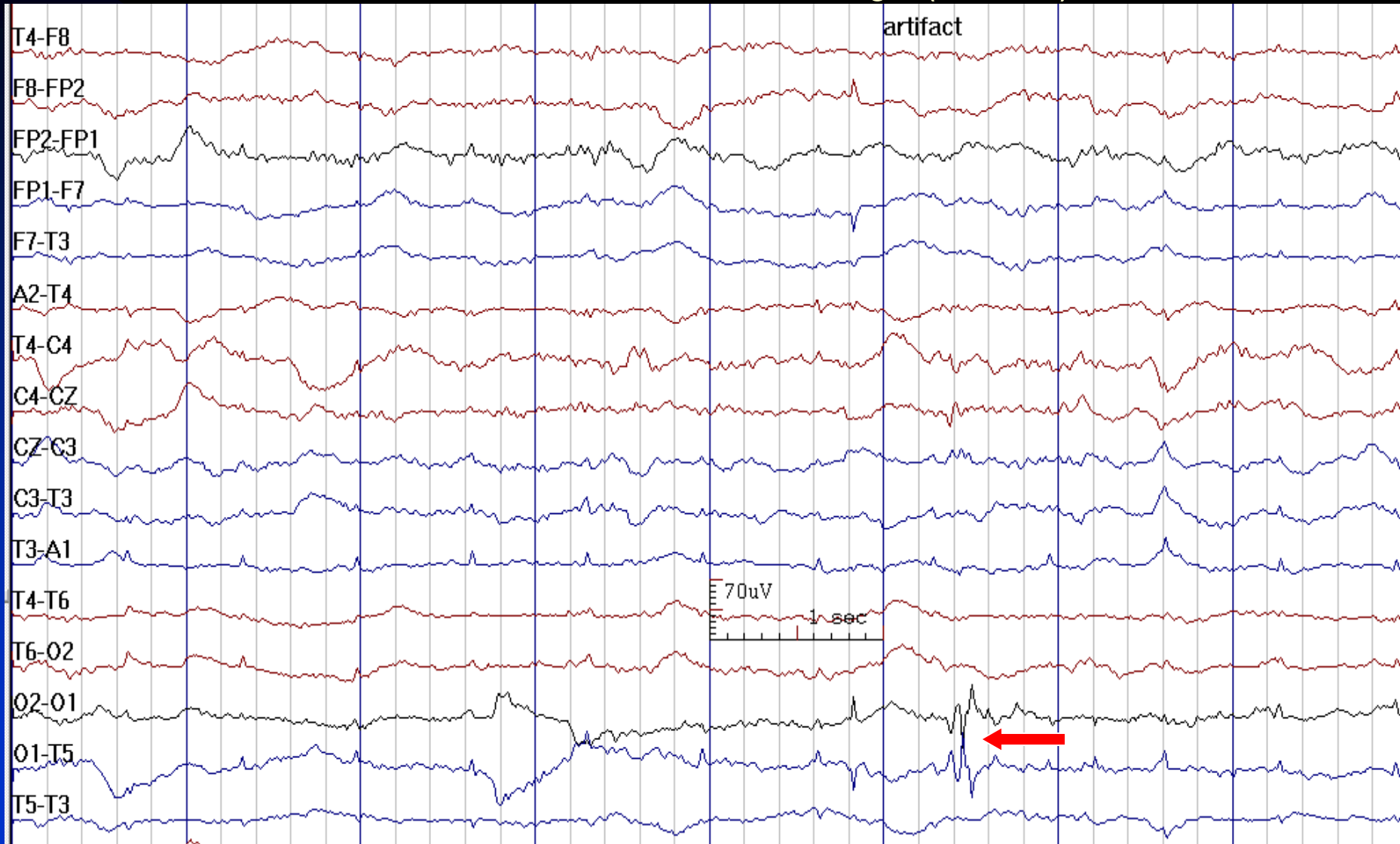
It Does Not Have A Field



See the next image for the same finding in circular montage

# Previous Slide in Circle Montage

## O1 Electrode Has Mirror Image (Artifact)



See the previous image for the same finding in temporal longitudinal montage

# How to Report Occipital IEDs

- ***In conclusion section, write:***

**1. Occipital IEDs with history of seizures:** This EEG is consistent with a diagnosis of a localization-related (focal) epilepsy.

*Note: Interictal occipital spikes have limited lateralizing value because interhemispheric occipital cortex may project to the opposite hemisphere.*

**2. Occipital IEDs without history of seizures:** This EEG demonstrates cortical irritability in the *RIGHT / LEFT* Occipital lobe. While interictal epileptiform discharges may be present in individuals with a history of seizures, not all patients with spikes have seizures.

# Multifocal Interictal Epileptiform Discharges

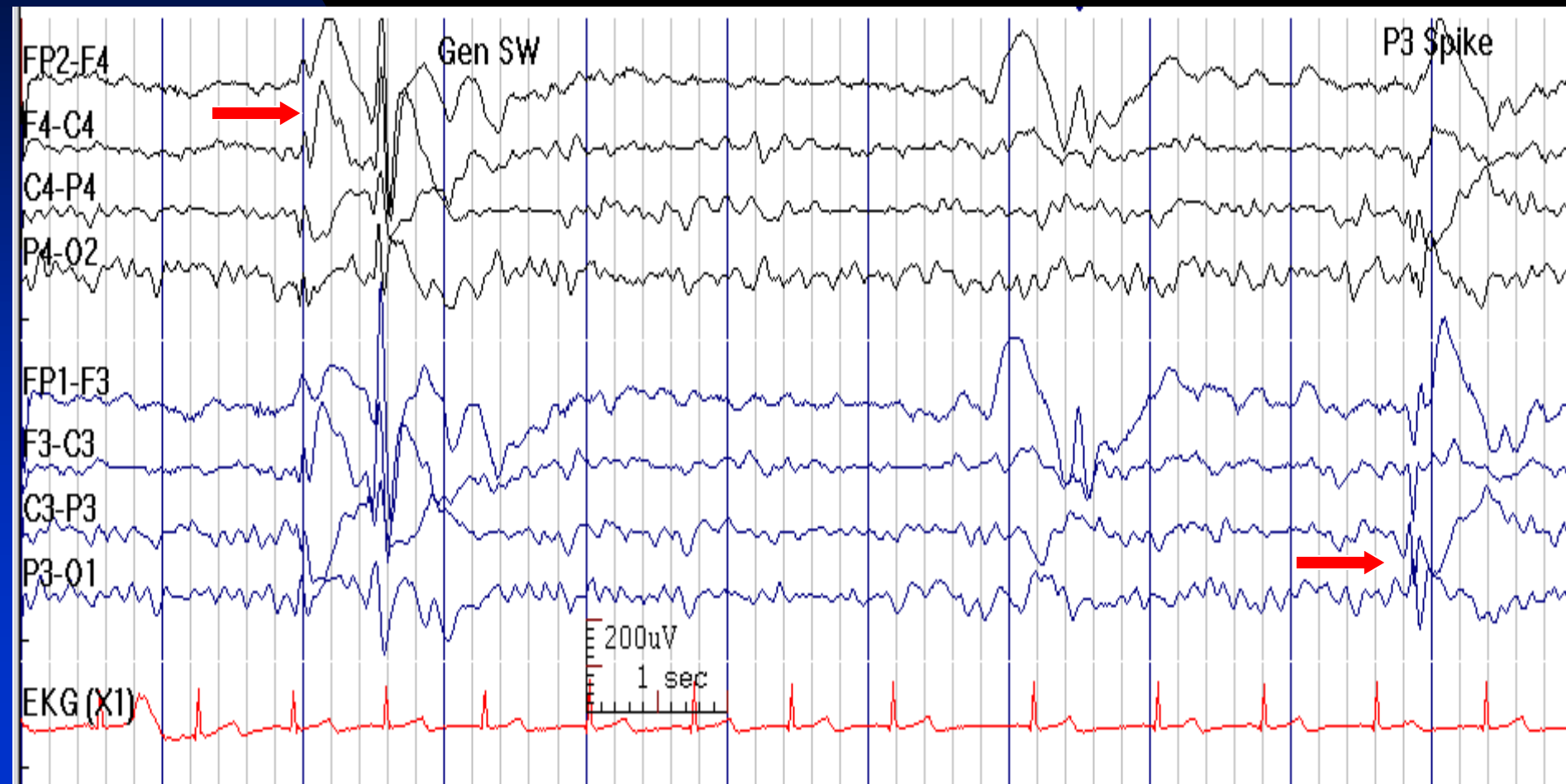
- Multiple IEDs from 3 distinct locations, separated by  
> 1 inter-electrode distance and in both hemispheres

# Focal Interictal Epileptiform Discharges with Secondary Bilateral Synchrony

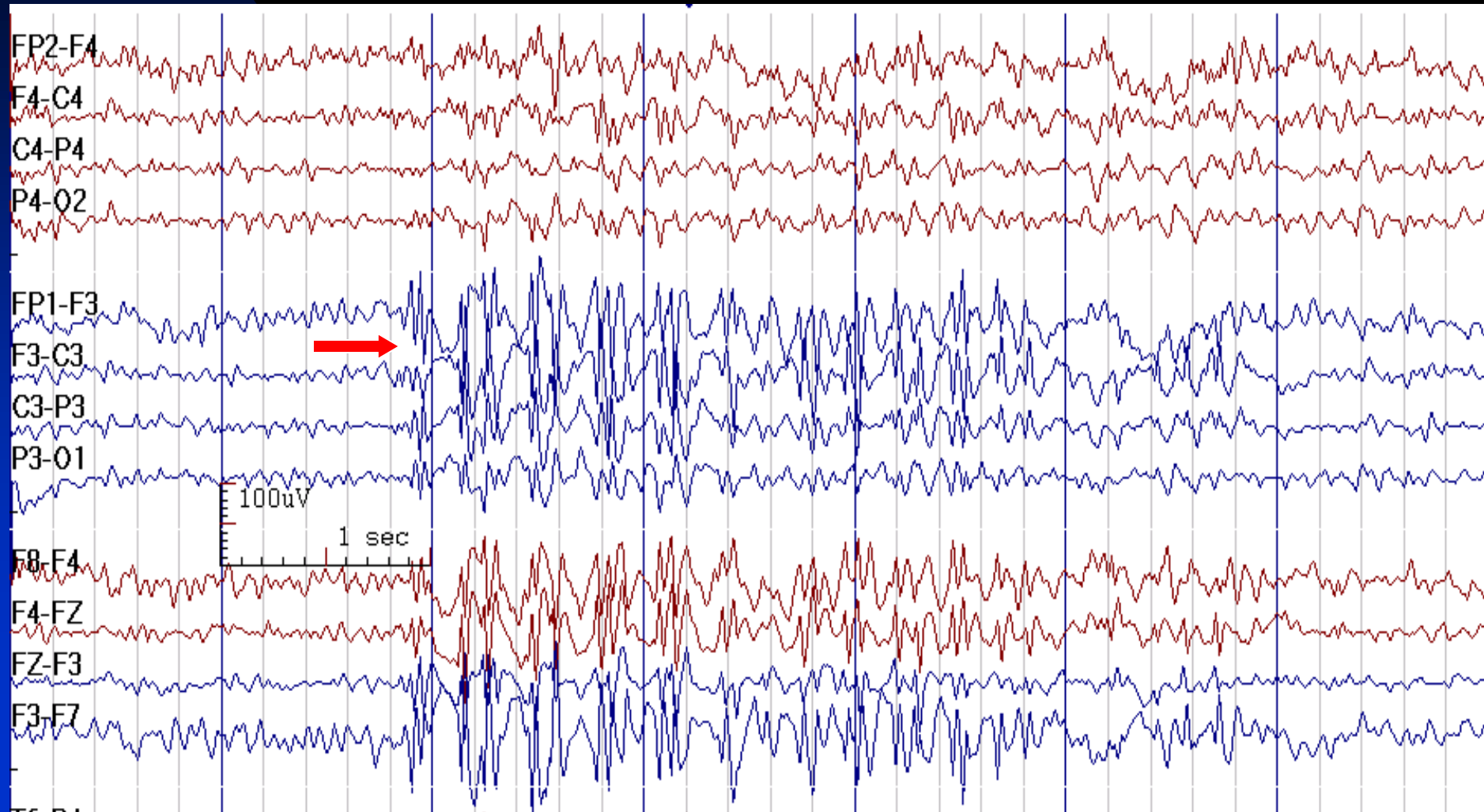
- Distinction from generalized discharges is usually difficult
- Clues to diagnosis:
  - ◆ Persistent asymmetry of amplitude
  - ◆ Persistent asymmetry of the side of onset
  - ◆ Ipsilateral focal slowing
  - ◆ Presence of focal IEDs
- Changing to 5 seconds per page expands the EEG visually and allows for better visualization of very fast events such as secondary bilateral synchrony



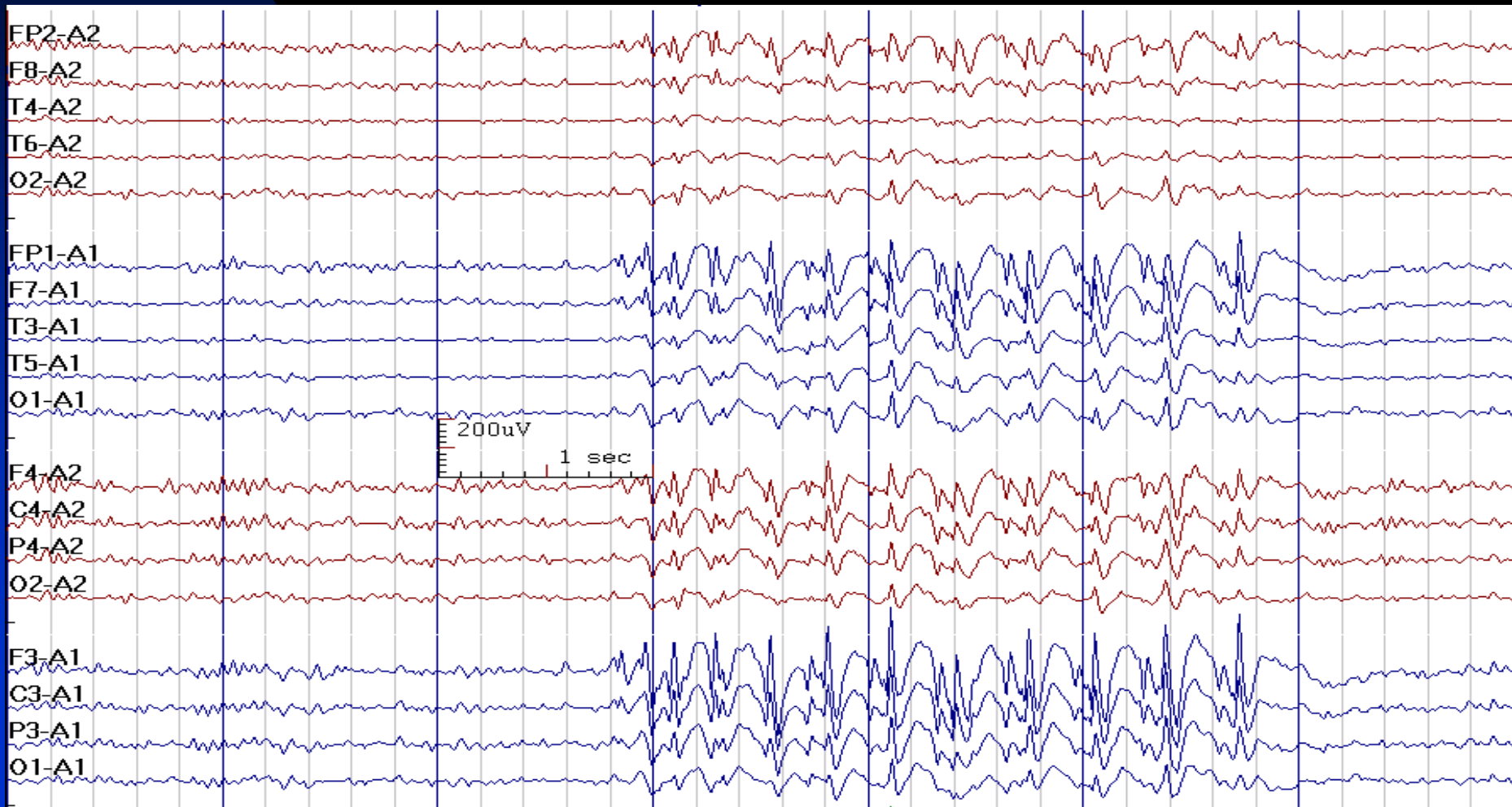
# Generalized Spike-Wave in Addition to P3 Spike Raises the Question of Secondary Bilateral Synchrony



# Run of Asymmetric (Dominant at F3) Spike-Waves in a 39-Year-Old Woman with Refractory Post-Traumatic Epilepsy



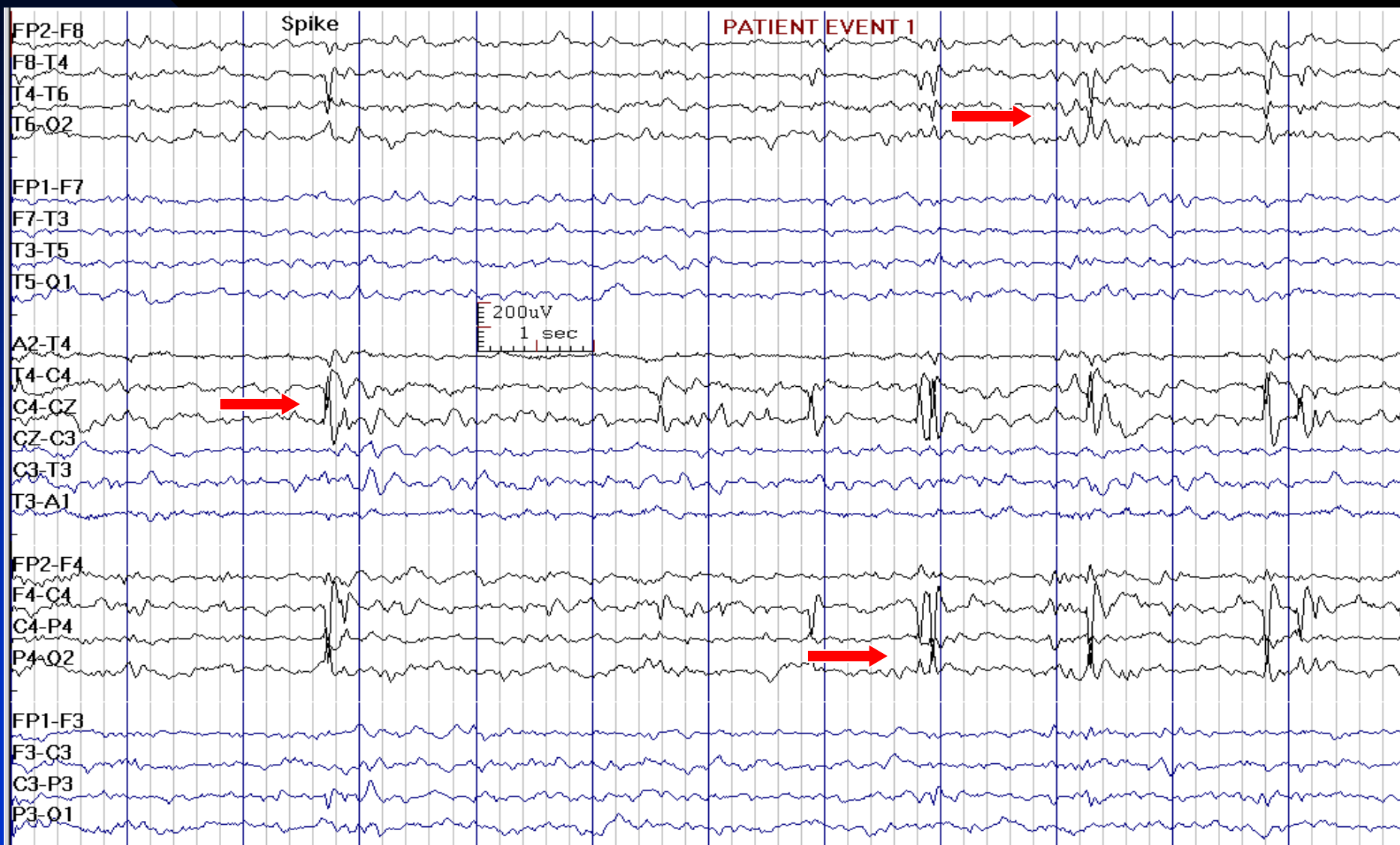
# Asymmetric Run of Spike-Waves: Note Higher Amplitude on the Left (Secondary Bilateral Synchrony)



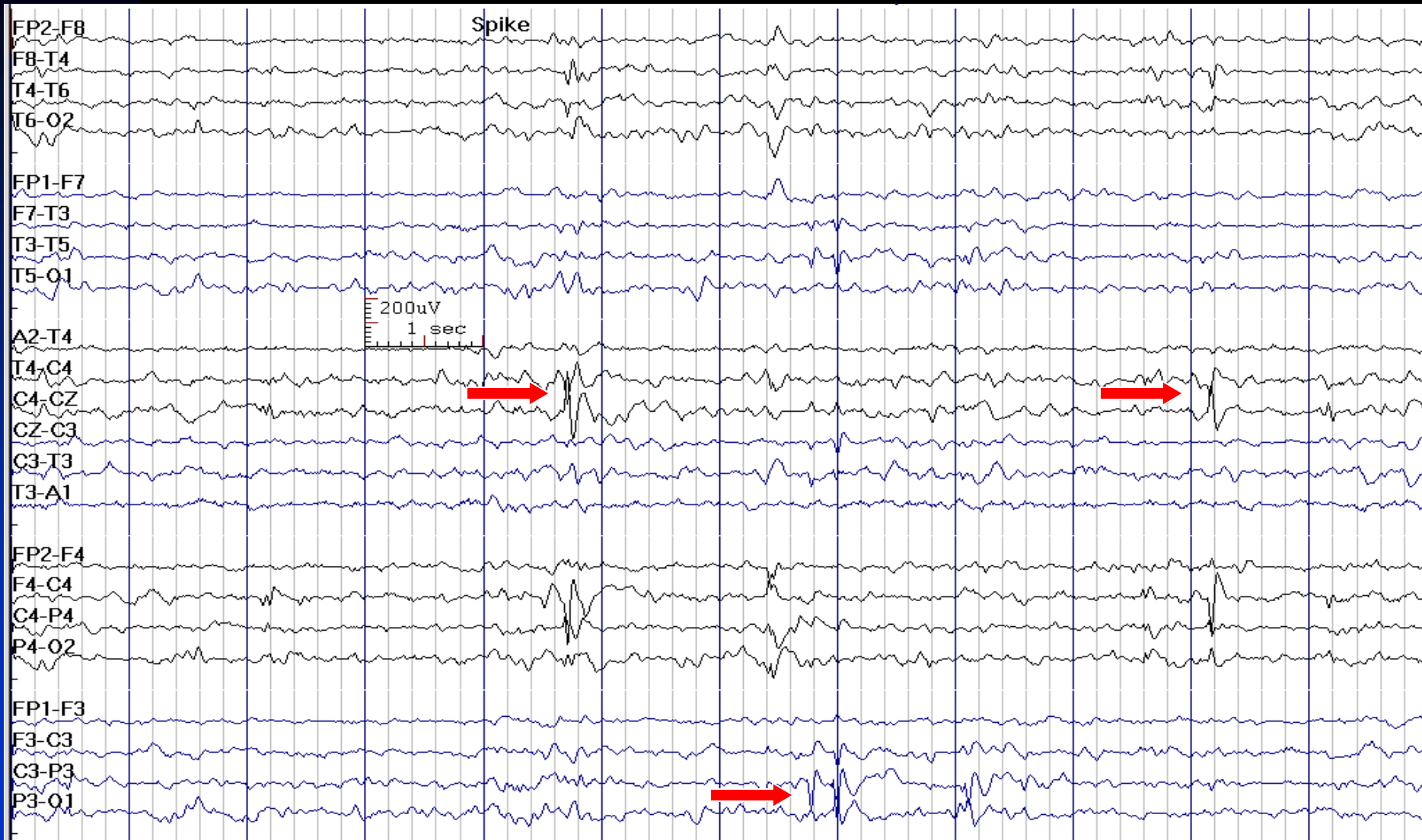
# Centro-Temporal (Rolandic) Spikes

- Central and mid-temporal IEDs: Maximum voltage at C3/C4 and T3/T4, occasionally at P3/P4 or T5/T6
- Diphasic or triphasic sharp waves usually followed by aftergoing slow waves
- Bilaterally and independently in homologous areas of both hemispheres
- Sleep enhances spikes
- Tangential dipole: Peak negativity over central, mid-temporal or parietal areas and peak positivity over frontal regions
- Characteristic for benign partial epilepsy of childhood with central-midtemporal spikes (BECTS)

# Rolandic (Centro-Temporal) Spikes in a 10-Year-Old Boy with BECTS



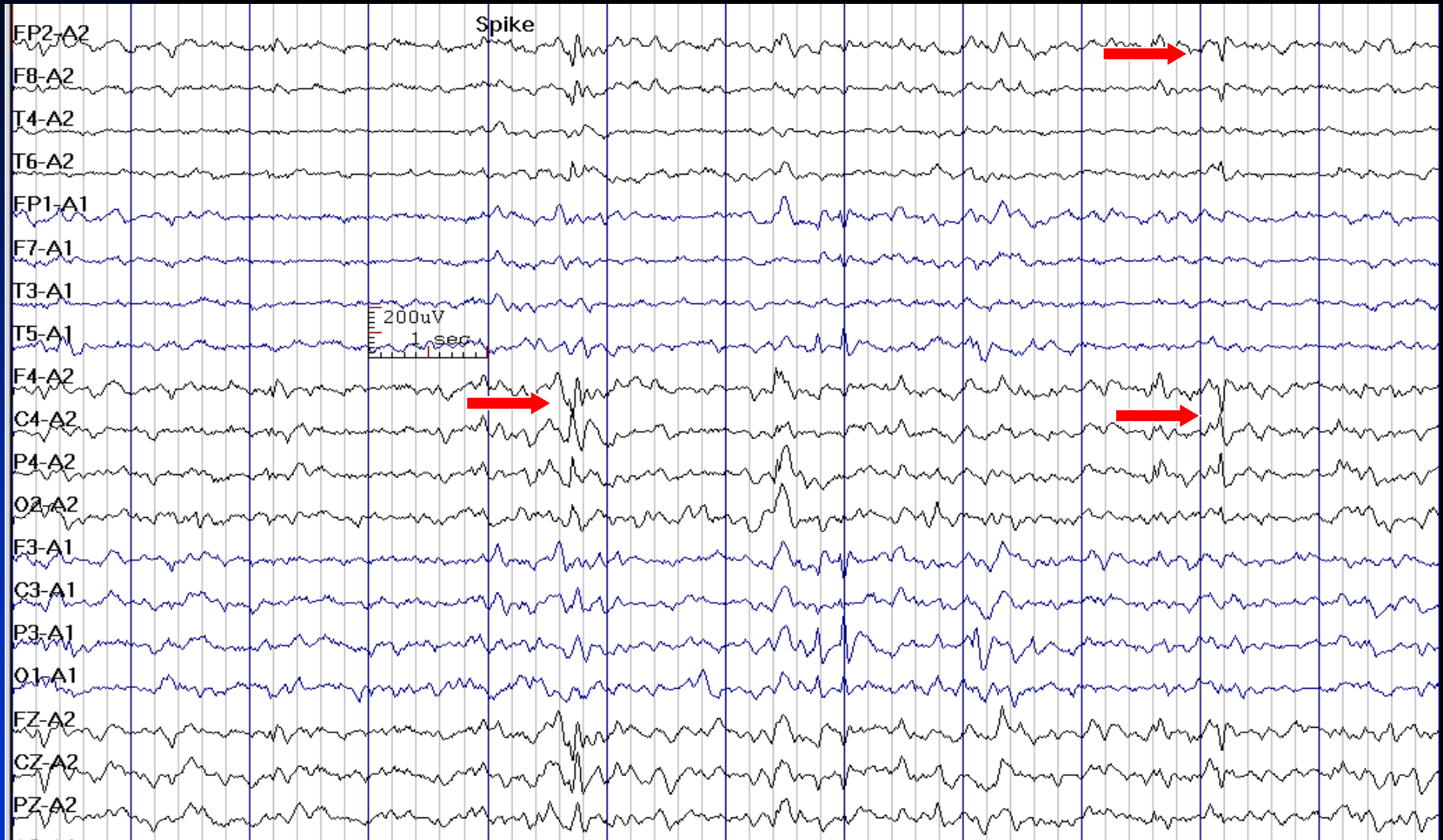# Rolandic (Centro-Temporal) Spikes in a 10-Year-Old Boy with BECTS



See the next image for the same finding in reference montage

# Tangential Dipole in Rolandic Spikes

(Negativity at C4/T4 and Positivity at Fp2/F4)

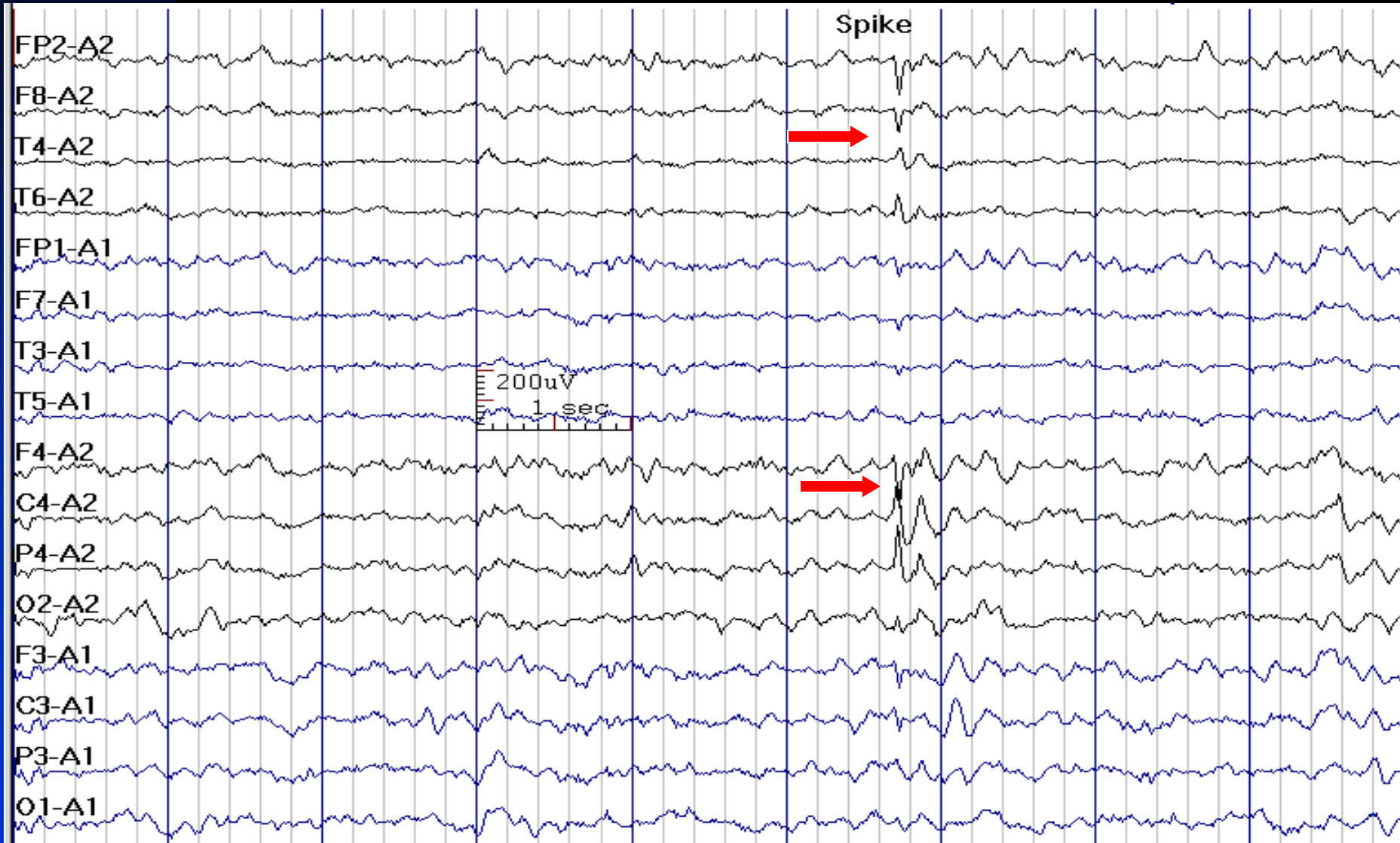

See the previous image for the same finding in temporal longitudinal montage



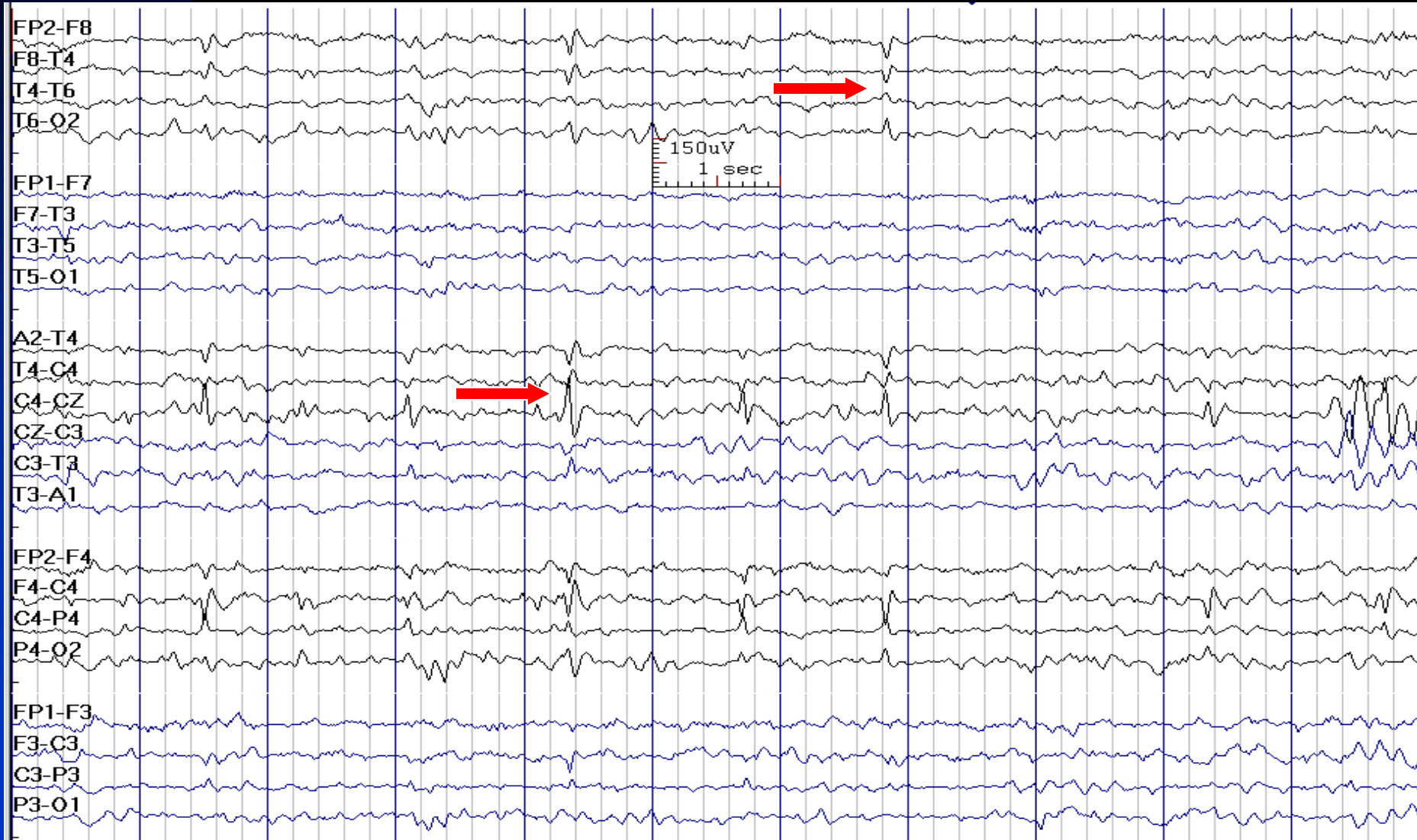
# Tangential Dipole in Rolandic Spikes

(**Negativity** at C4/T4 and **Positivity** at Fp2/F4)

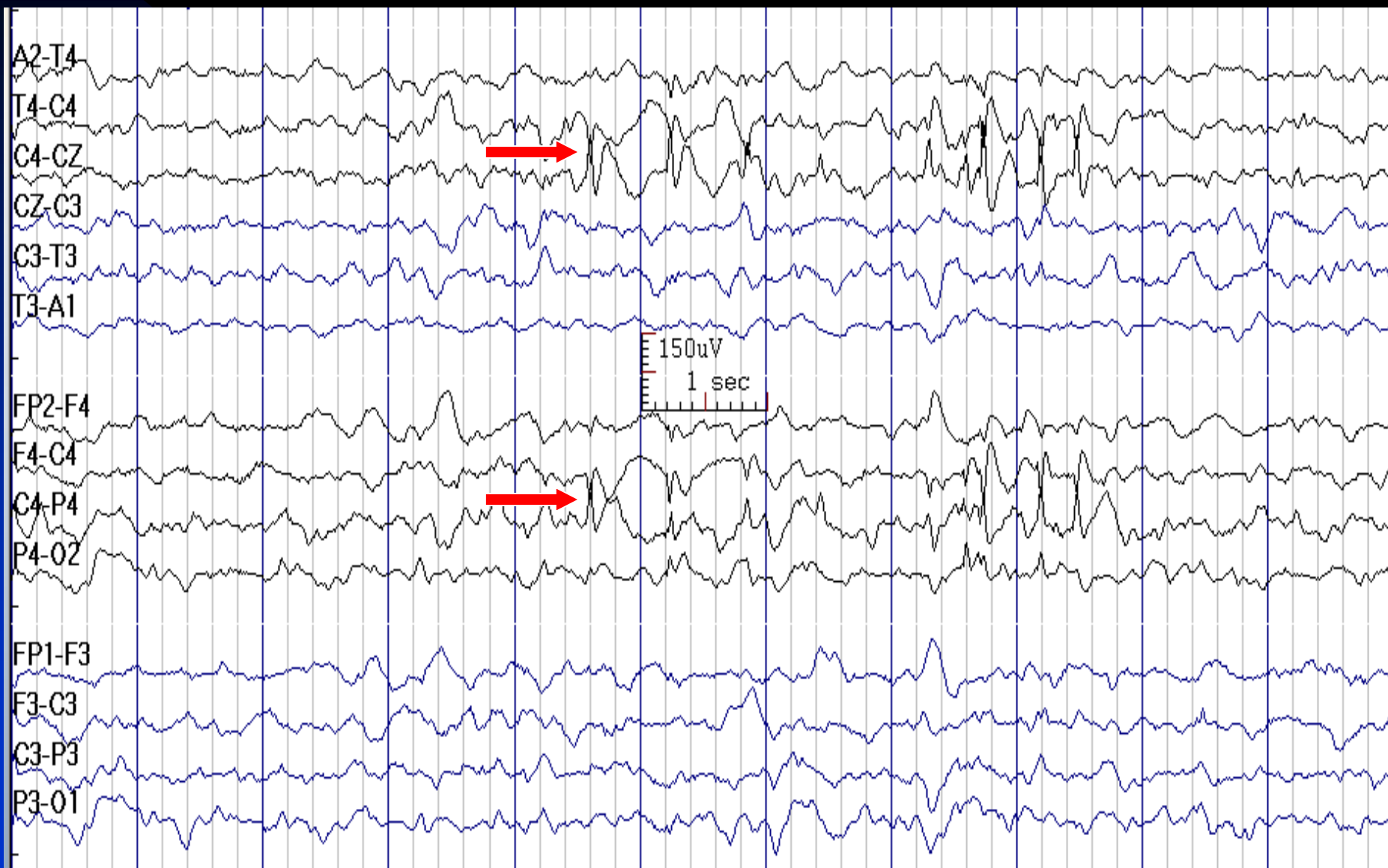



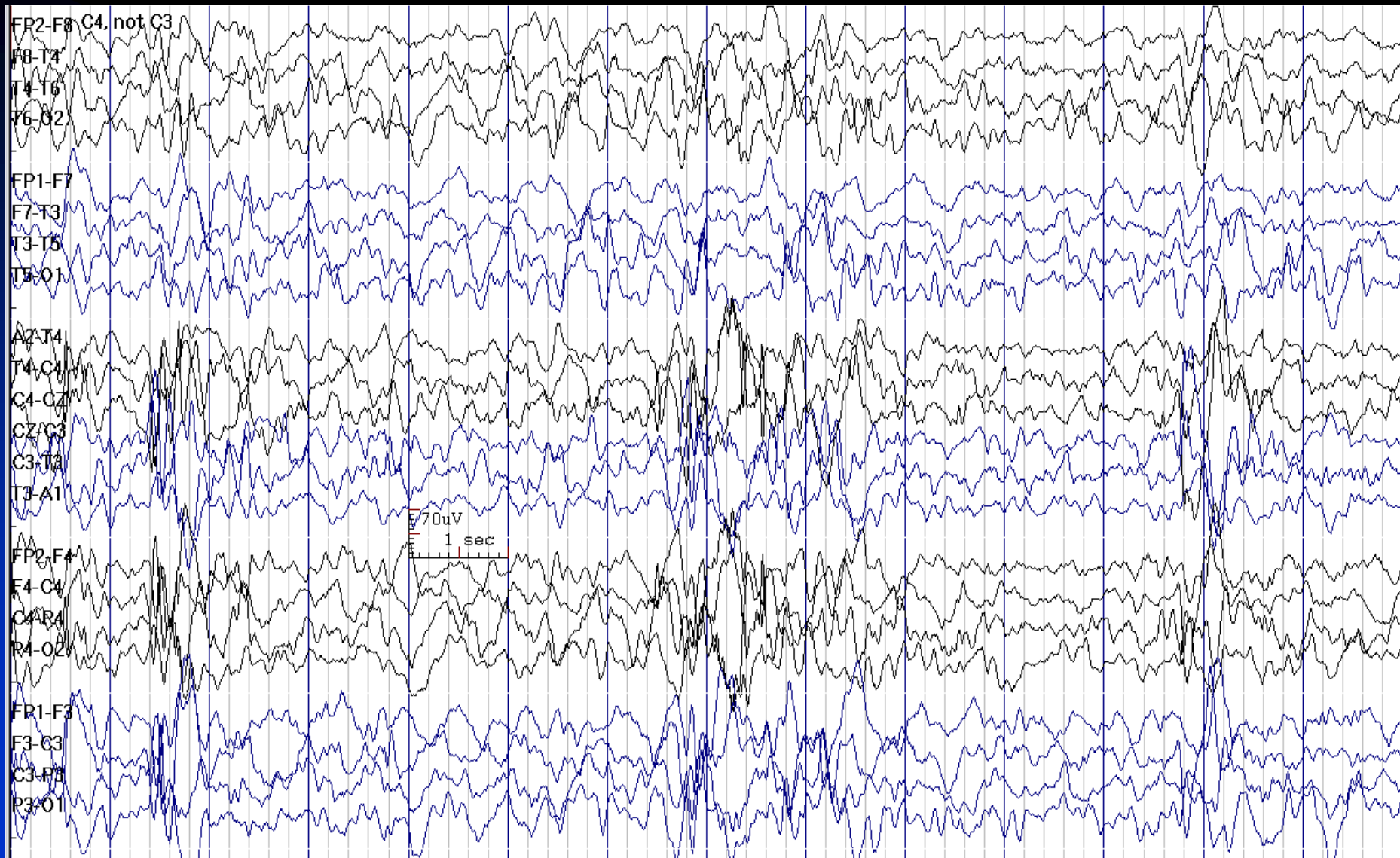
# C4 & T4 Spikes in a 10-Year-Old Boy with BECTS



# C4 Spikes in a 8-Year-Old Boy with BECTS



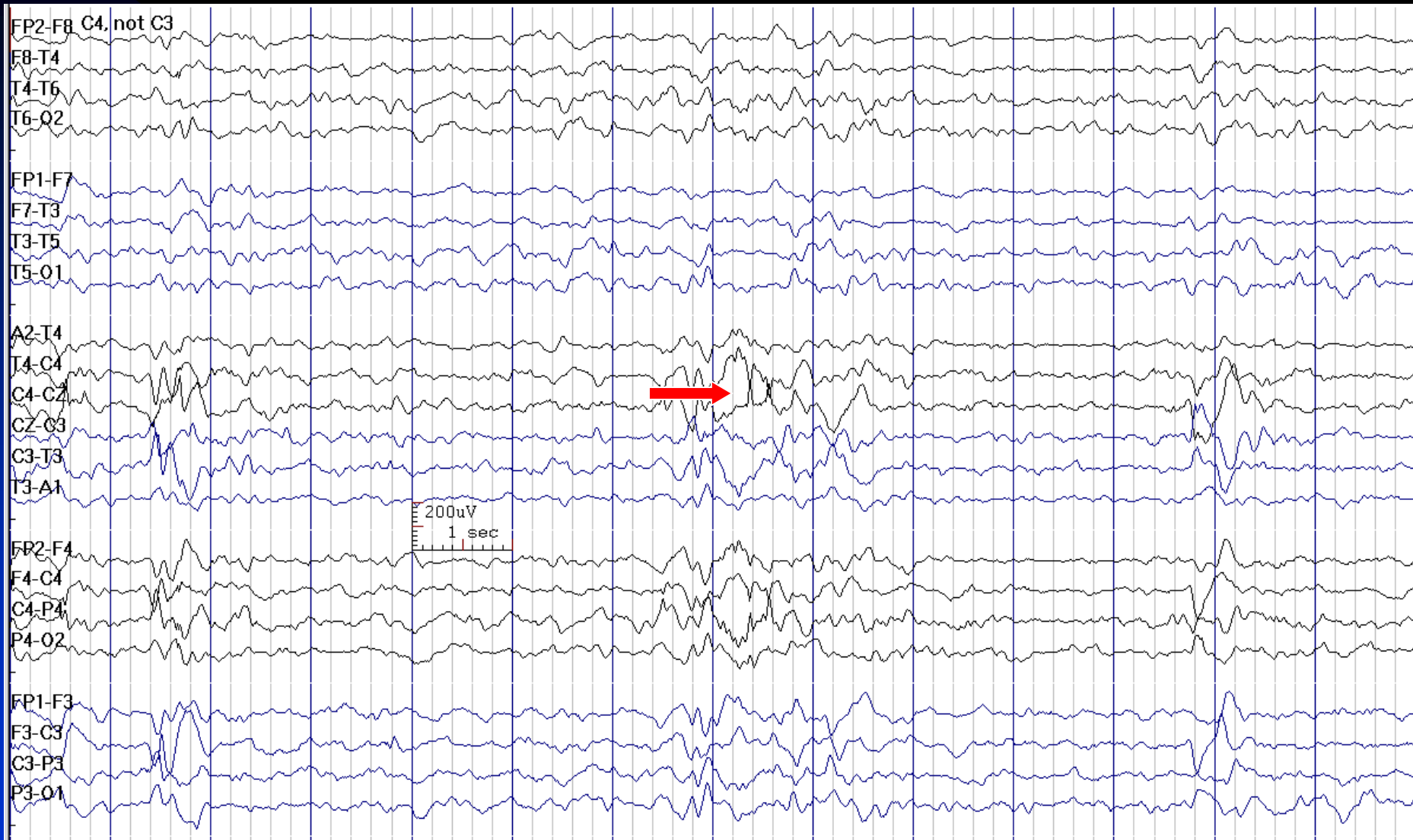
# C4 Spikes Similar to Artifact in Usual Sensitivity



See the next image for the same finding with decreased sensitivity

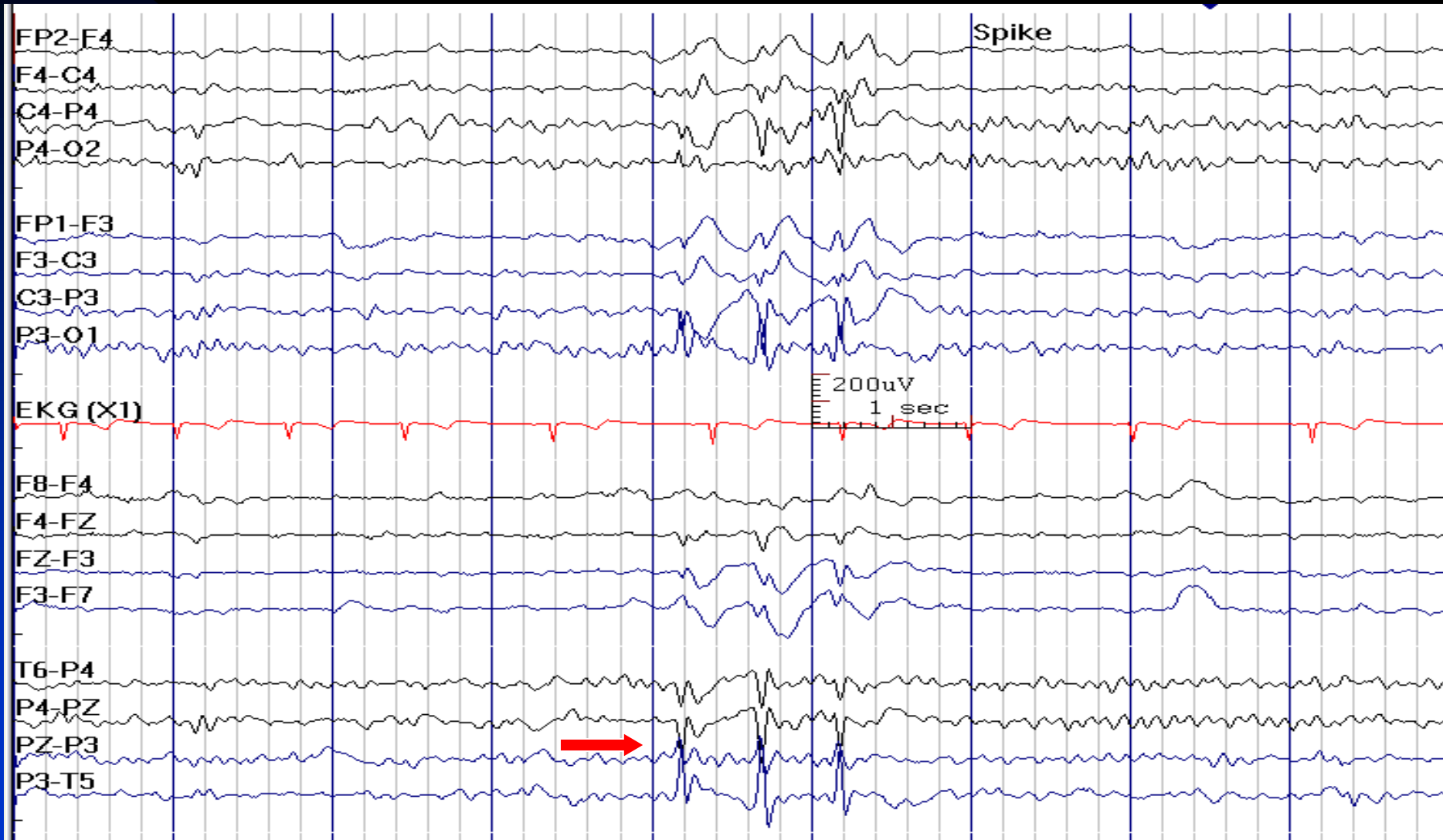
# C4 Spikes is Obvious in Reduced Sensitivity

(One Benefit of Digital EEG)



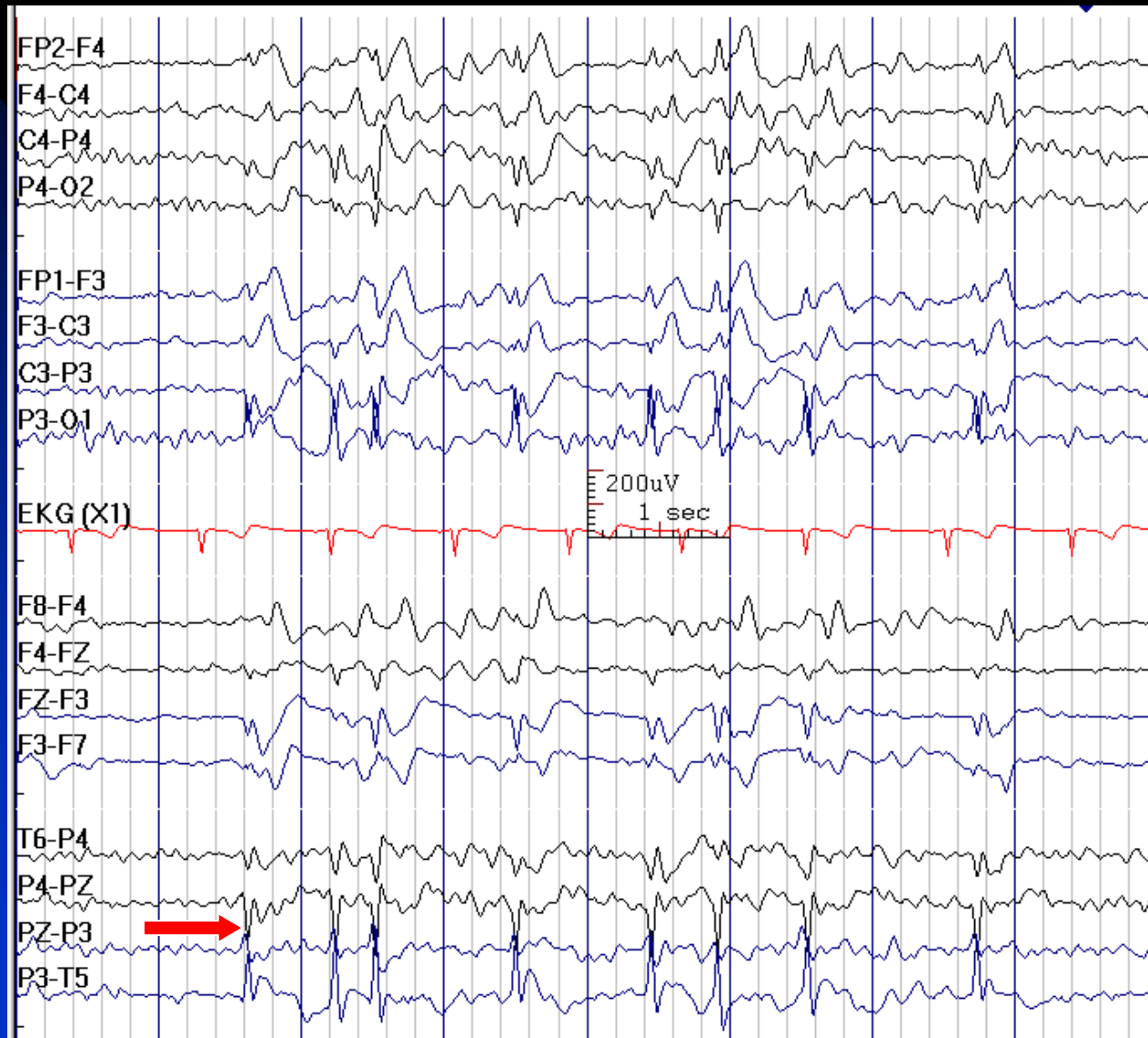
See the previous image for the same finding with normal sensitivity

# Pz Spikes with Tangential Dipole Consistent with Benign Partial Epilepsy of Childhood



Go to the next image to see the effect of sleep in this patient

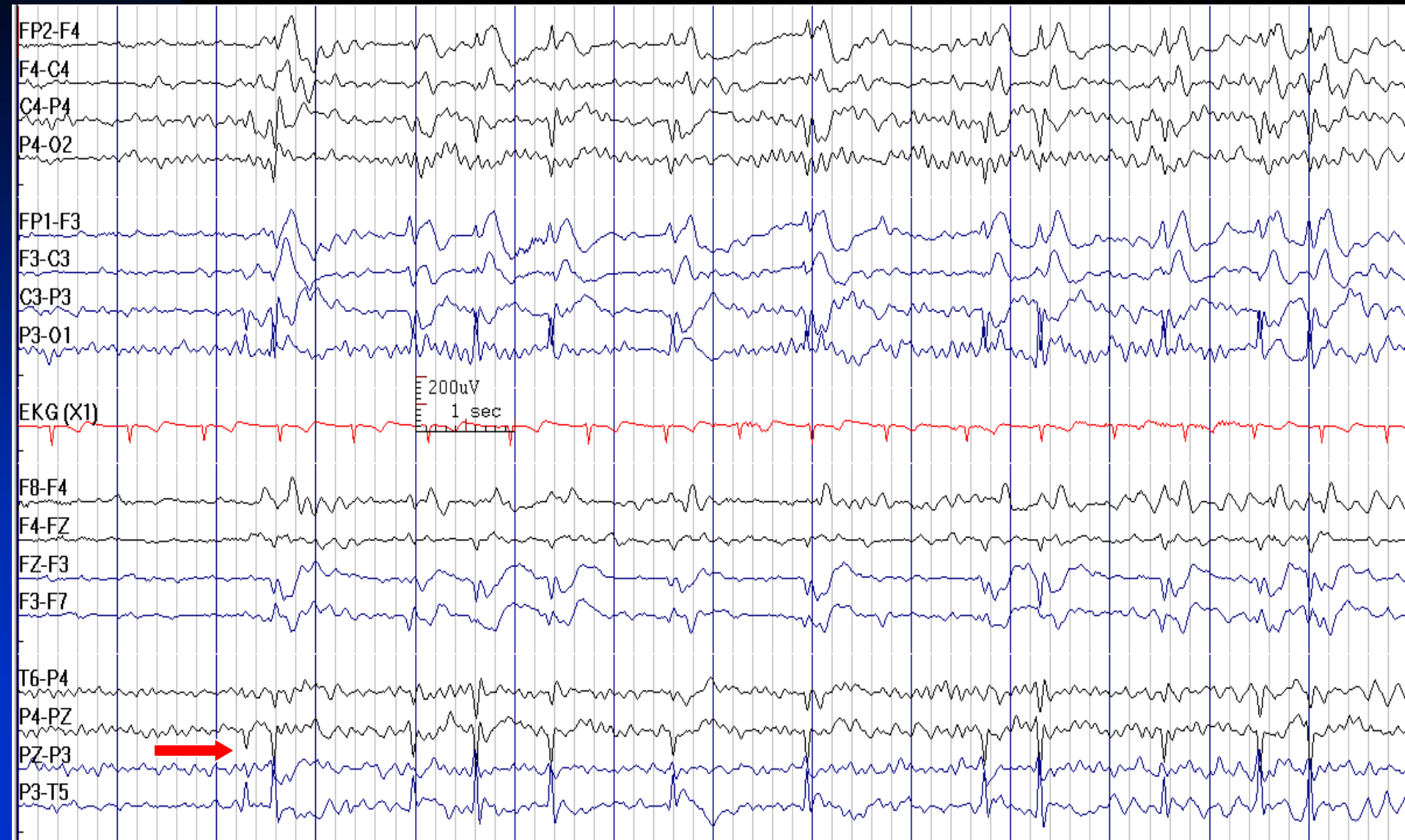
# Activation Of Pz Spikes with Sleep Consistent with Benign Partial Epilepsy of Childhood



Go to the previous image to see the awake EEG in this patient



# Activation Of Pz Spikes with Sleep Consistent with Benign Partial Epilepsy of Childhood



# How to Report Centro-Temporal (Rolandic) Spikes

- ***In conclusion section, write:***

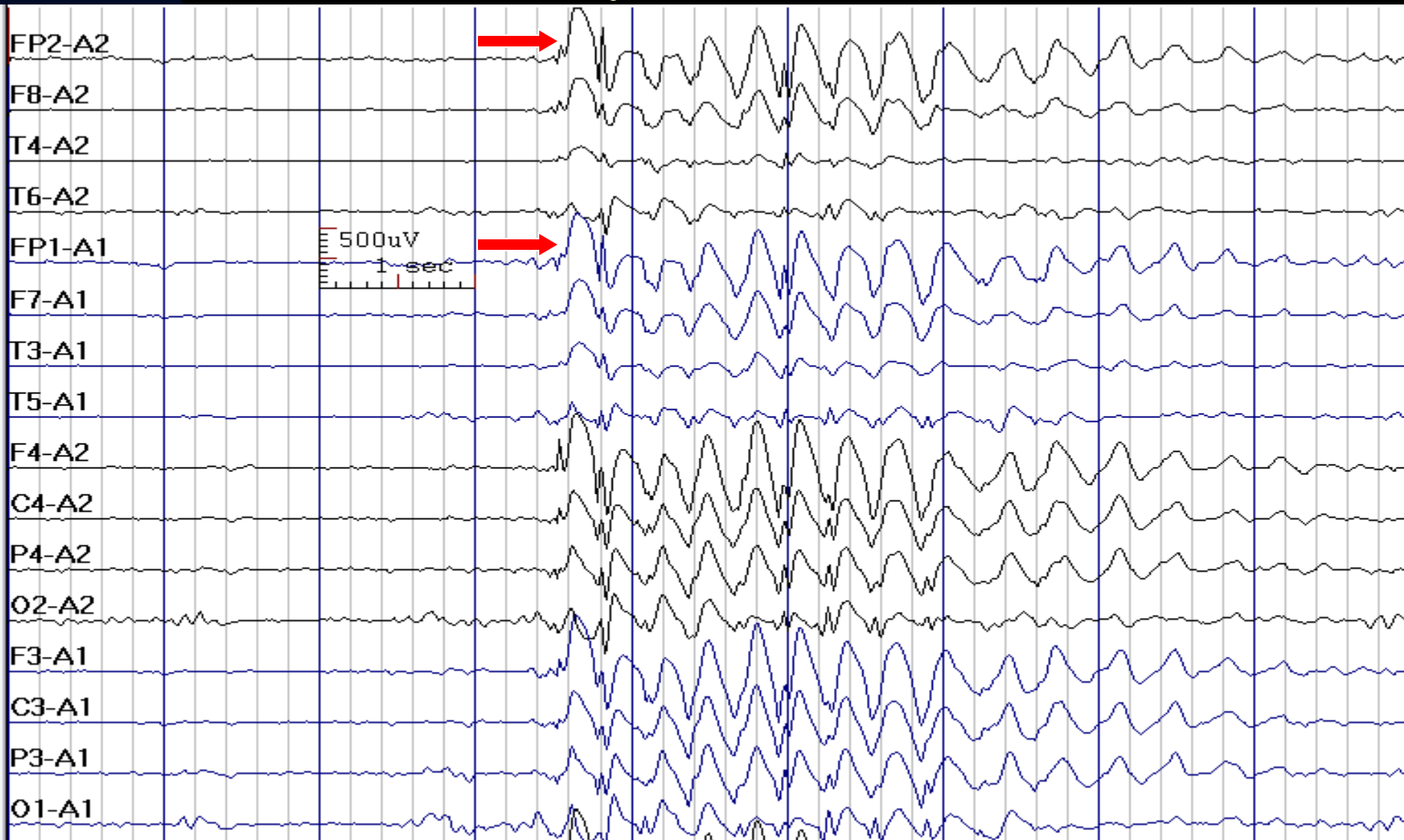1. **Central-midtemporal (Rolandic) spikes with a history of seizures:** This EEG is consistent with a diagnosis of benign epilepsy of childhood with central-midtemporal spikes (benign Rolandic epilepsy).
2. **Central-midtemporal (Rolandic) spikes without history of seizures:** This EEG demonstrates cortical dysfunction and irritability in the central-midtemporal (Rolandic) areas. These spikes may be present in individuals without a history of seizures (e.g., in those with asymptomatic genetic EEG trait).



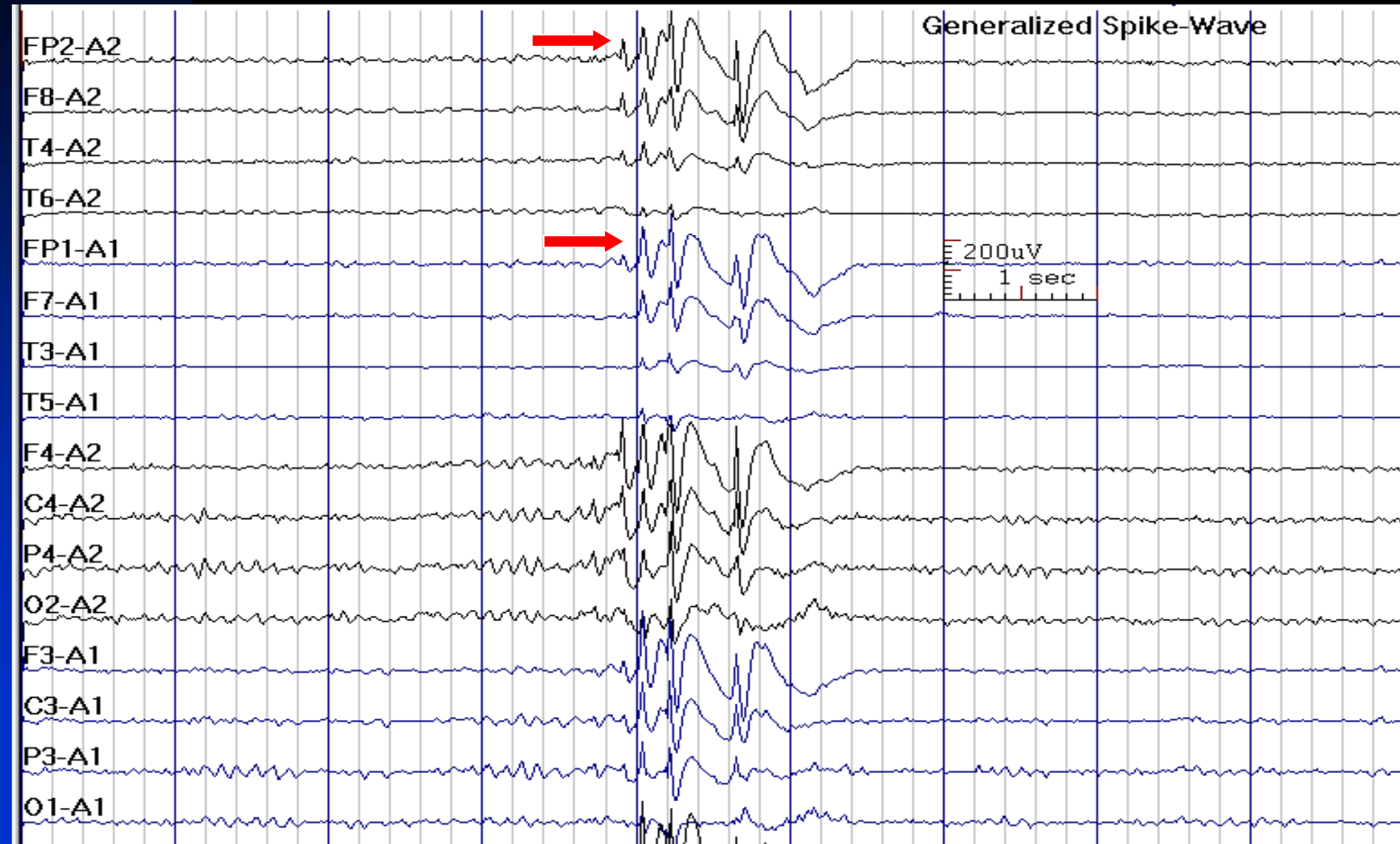
# Interictal Epileptiform Discharges in Idiopathic (Genetic) Generalized Epilepsies

- The classic EEG finding in IGEs is 3 Hz or faster generalized spike-wave complexes (also called typical generalized spike-wave complexes) or generalized polyspikes (with or without waves). The background activity is characteristically normal.
- Spikes are bilaterally synchronous and symmetric, but maximum amplitude may shift from side to side
- Usually maximum potential field frontally (Fz, F3, F4)

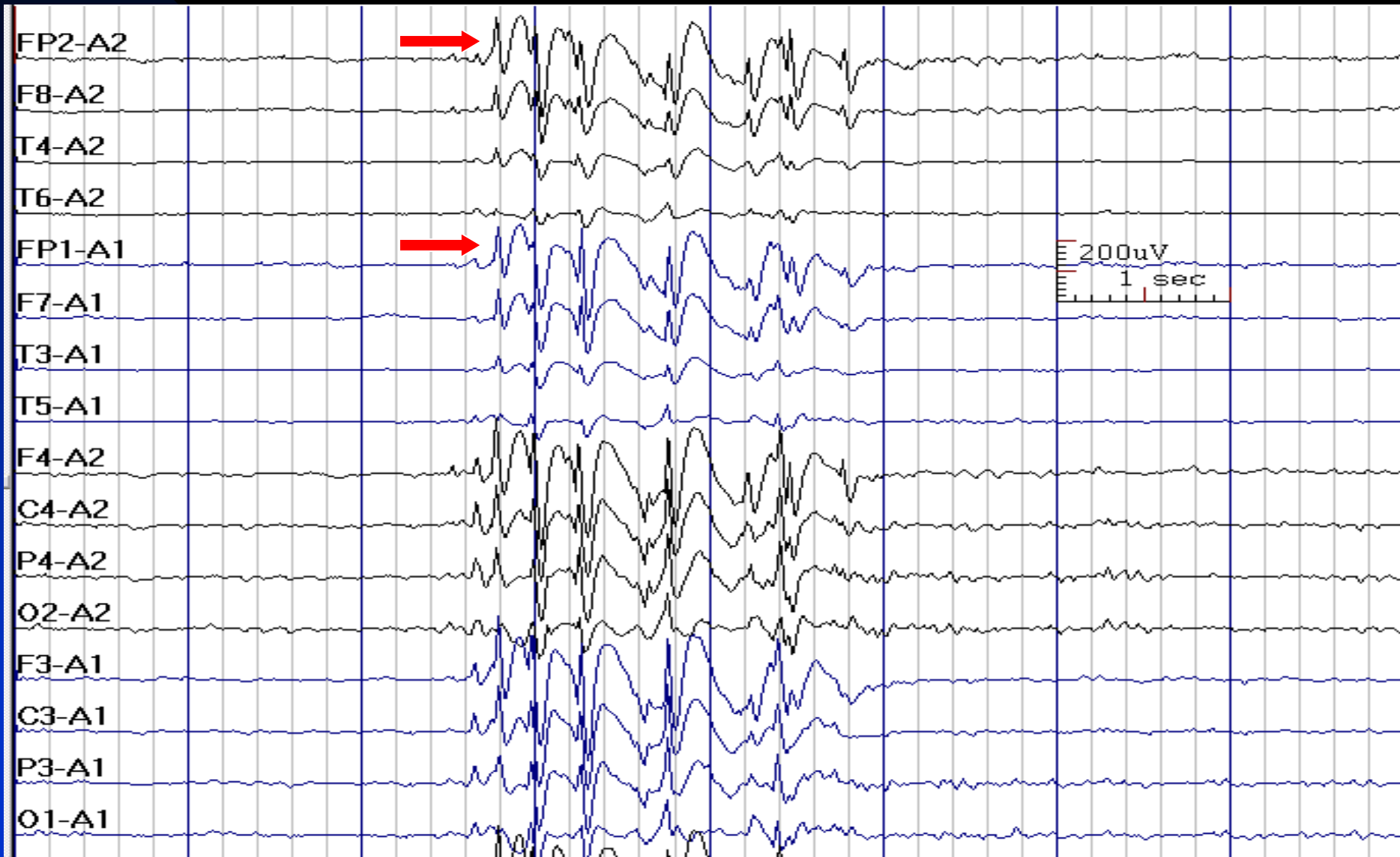# 3.5 Hz Generalized Spike-Waves in a 13-Year-Old Boy with Absence Seizures



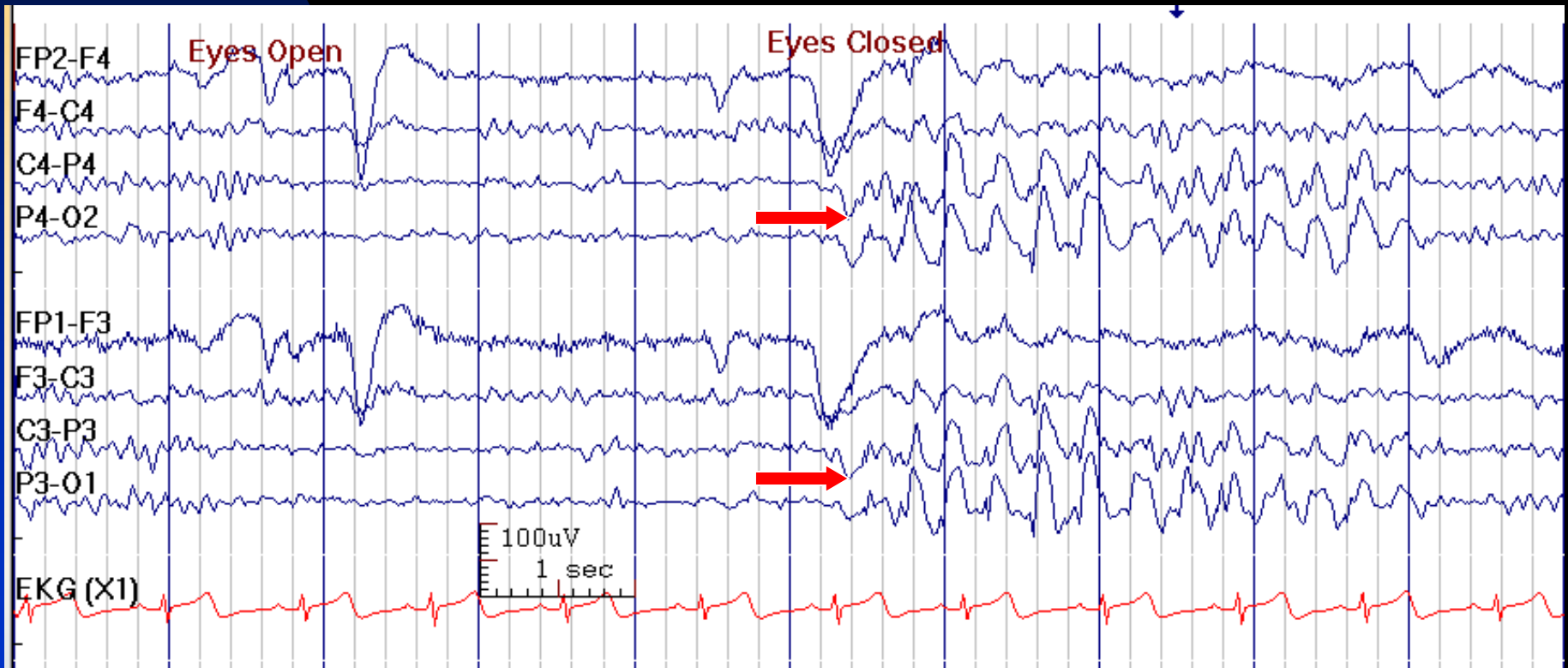
# 4 Hz Generalized Spike-Waves in a 42-Year-Old Woman with Absence Seizures



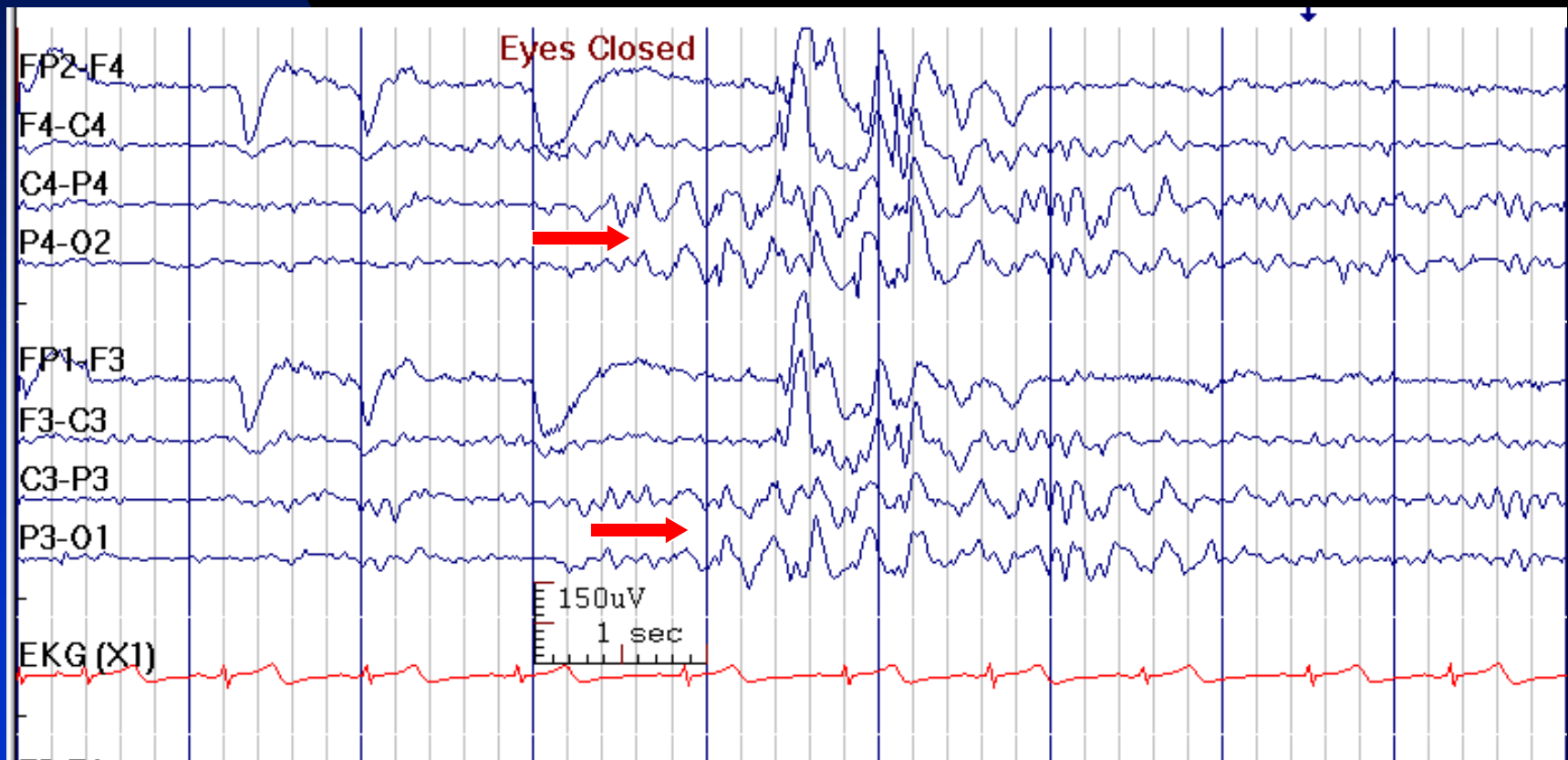
# 3 Hz Generalized Spike-Waves in a 20-Year-Old Man with Absence Seizures



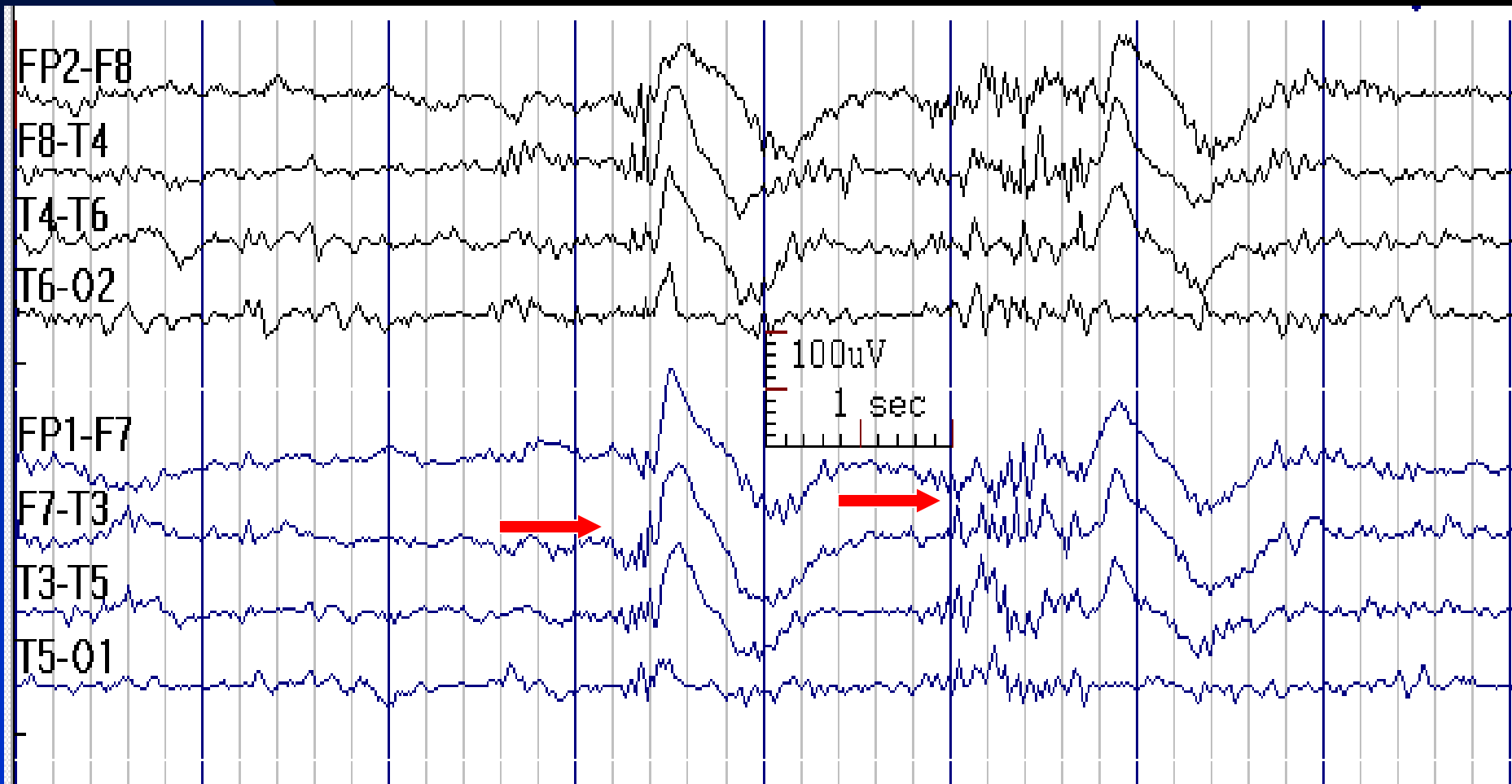
# Posterior Dominant 3 Hz Generalized Spike-Waves after Eye Closure in a 14-Year-Old Boy with Absence Seizures Treated with Ethosuximide



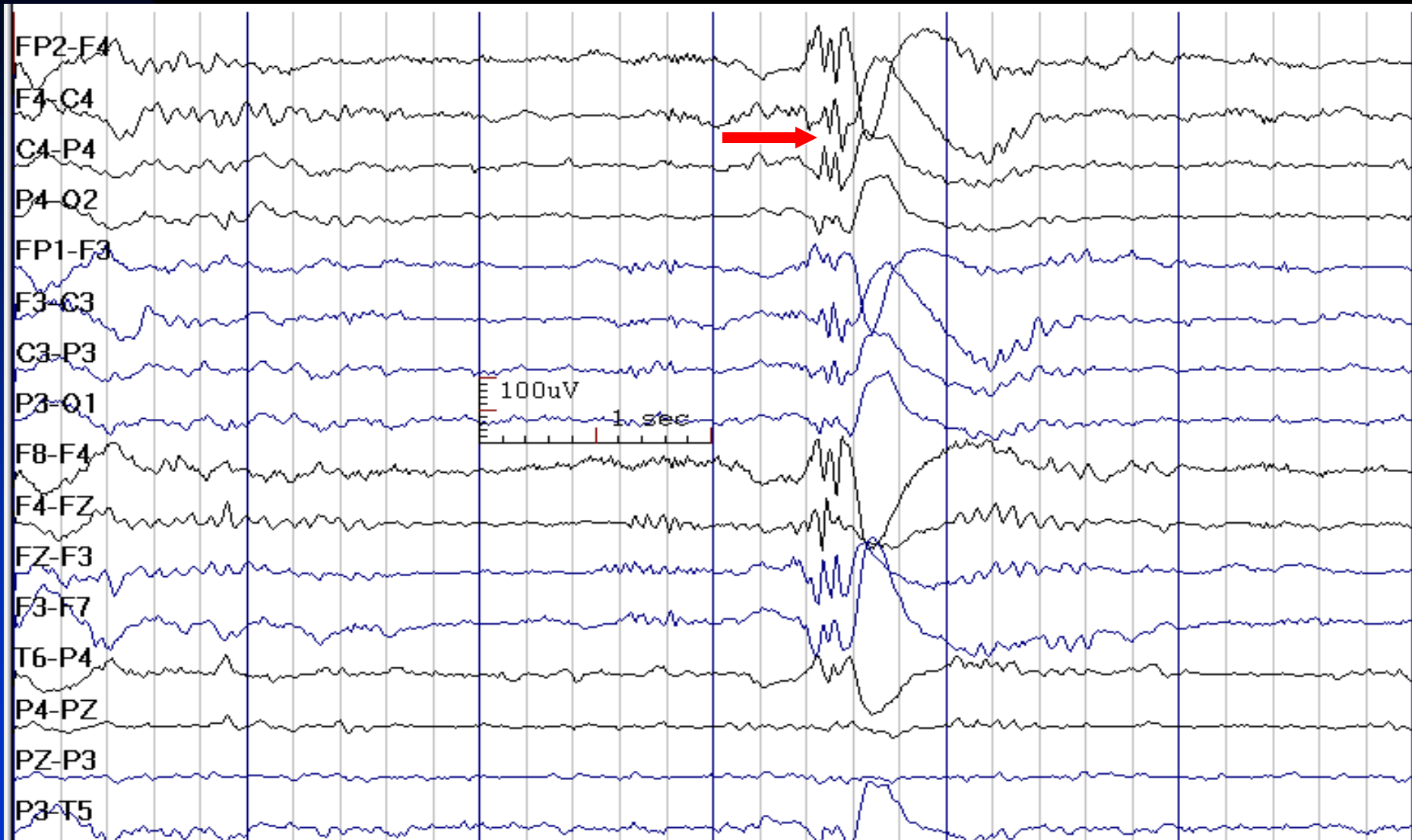
# Posterior Dominant Generalized Spike-Waves after Eye Closure Leading to Frontally Predominant GSW in a 14-Year-Old Boy with Absence Seizures



# Polyspikes Discharge



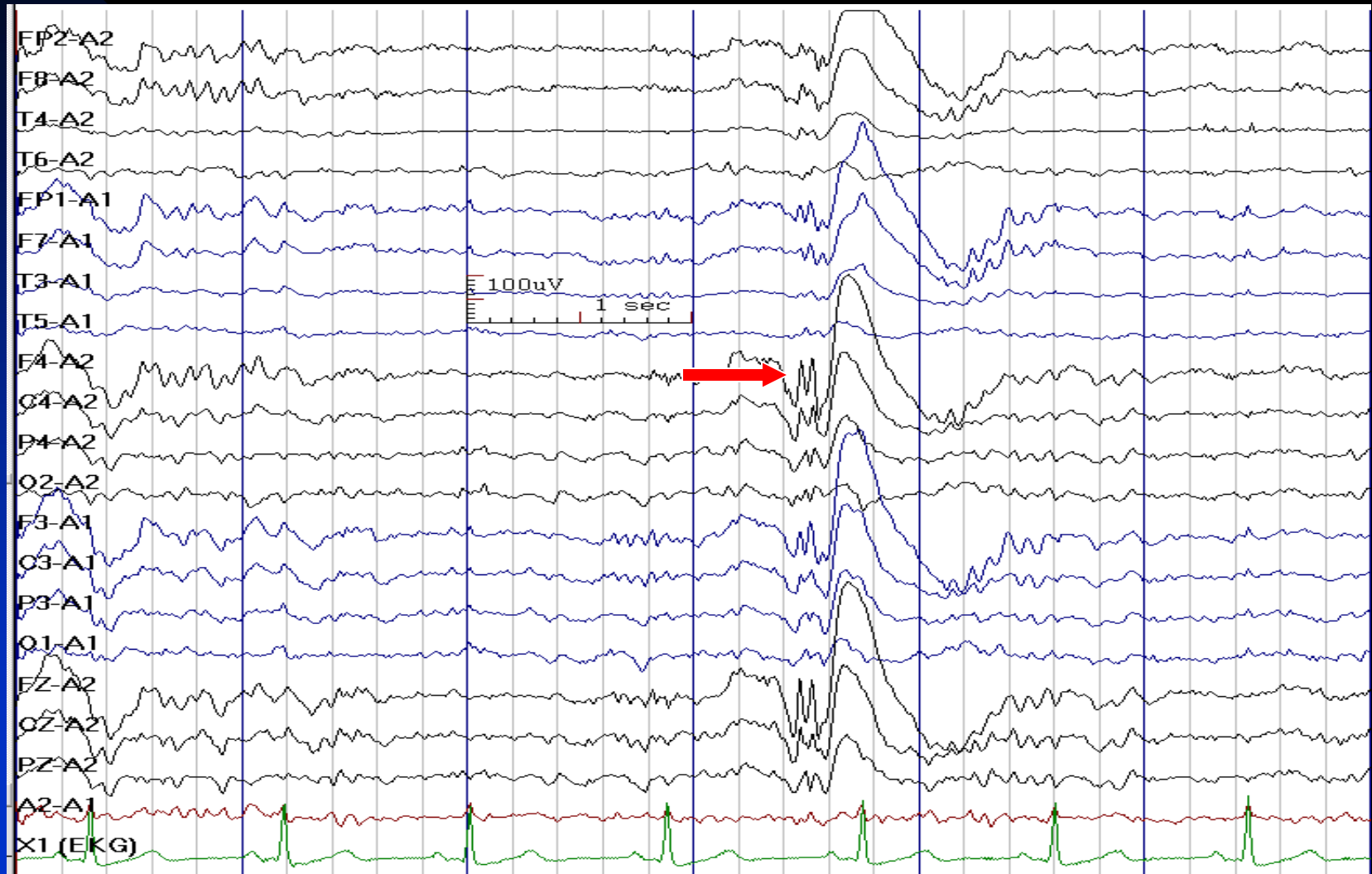
# Generalized Polyspike-Wave in a 16-Year-Old Girl with Juvenile Myoclonic Epilepsy



See the next image for the same finding in reference montage

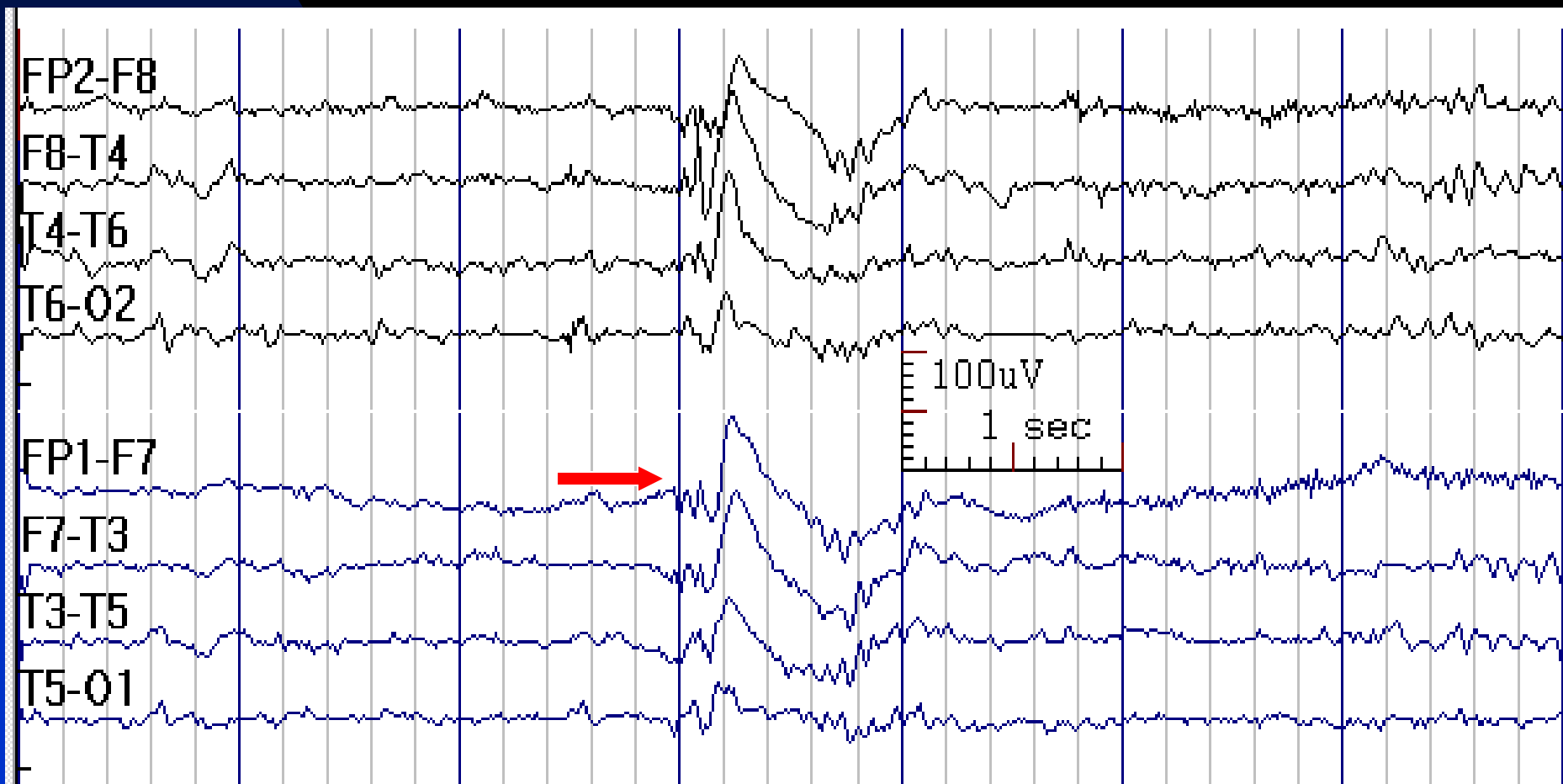


# Ear Reference Montage is Useful for Analysis of Polyspike-Wave Discharges

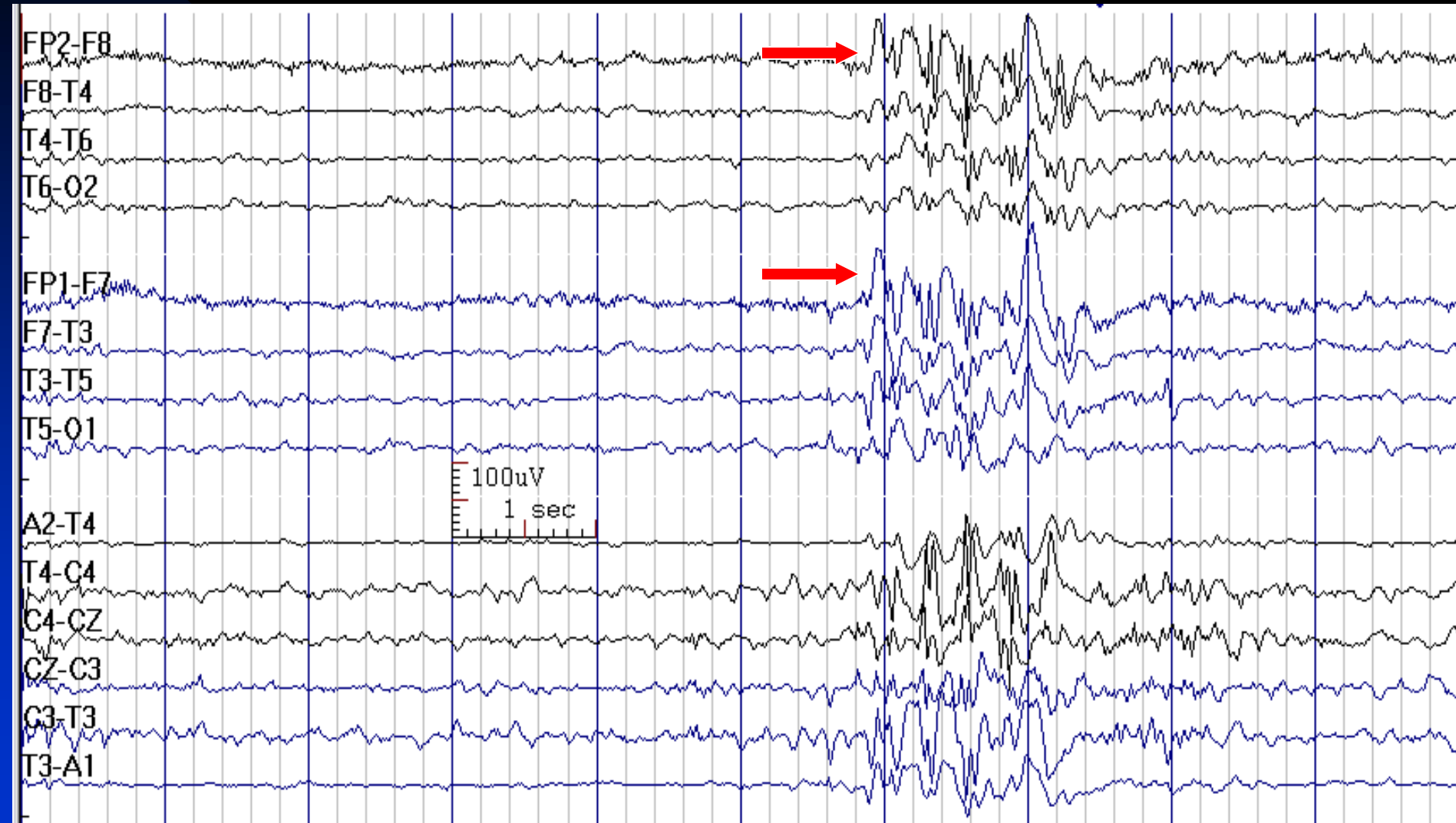


See the previous image for the same finding in parasagittal bipolar montage

# Polyspike-Wave in a 37-Year-Old Man with Idiopathic (Genetic) Generalized Epilepsy

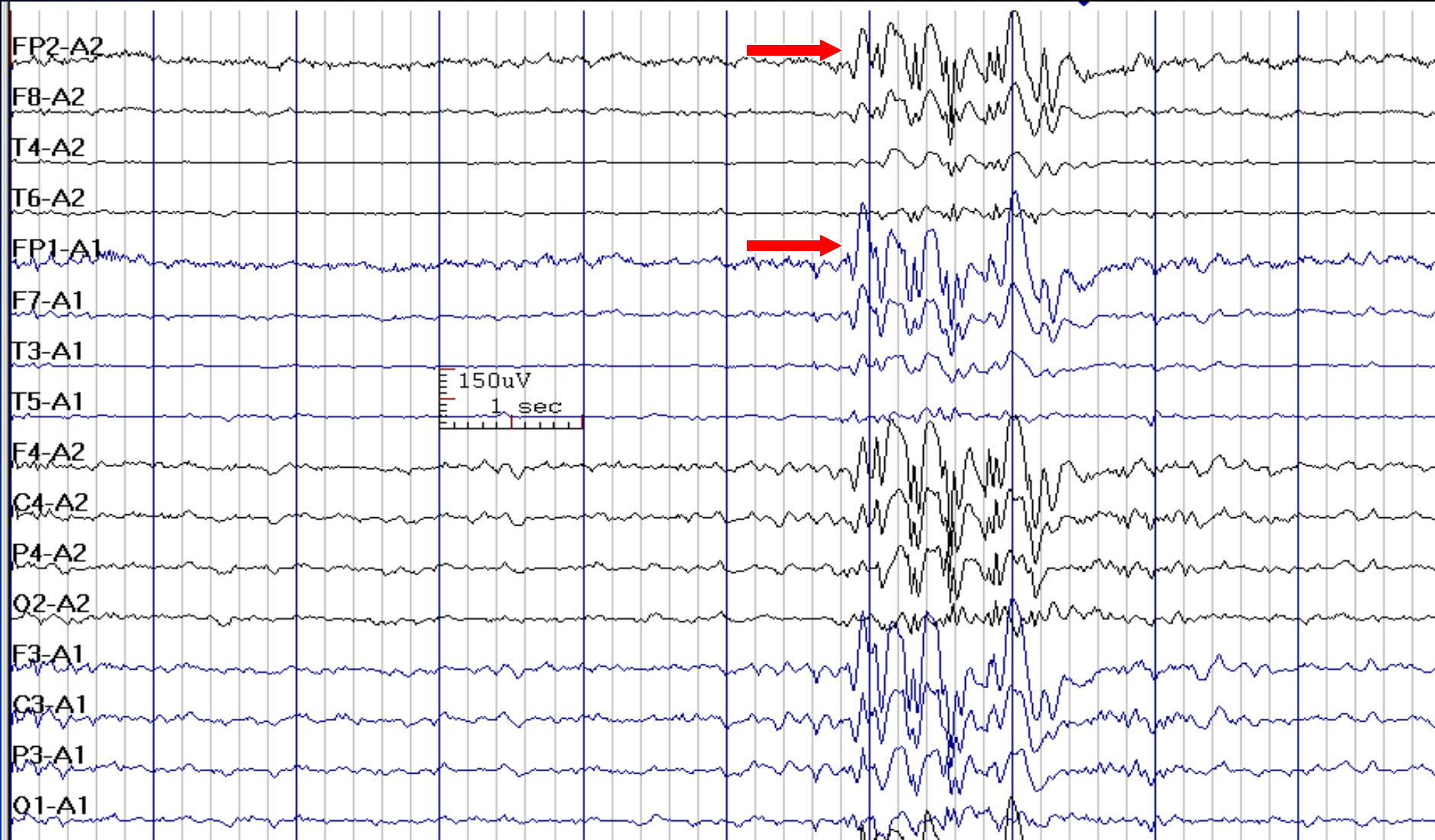


# Polyspike-Waves in a 19-Year-Old Woman with Idiopathic (Genetic) Generalized Epilepsy



See the next image for the same finding in reference montage

# Polyspike-Waves in Idiopathic (Genetic) Generalized Epilepsy (Ear Reference Montage)



See the previous image for the same finding in bipolar montage

# How to Report Interictal Epileptiform Discharges in Idiopathic (Genetic) Generalized Epilepsies

- ***In conclusion section, write:***

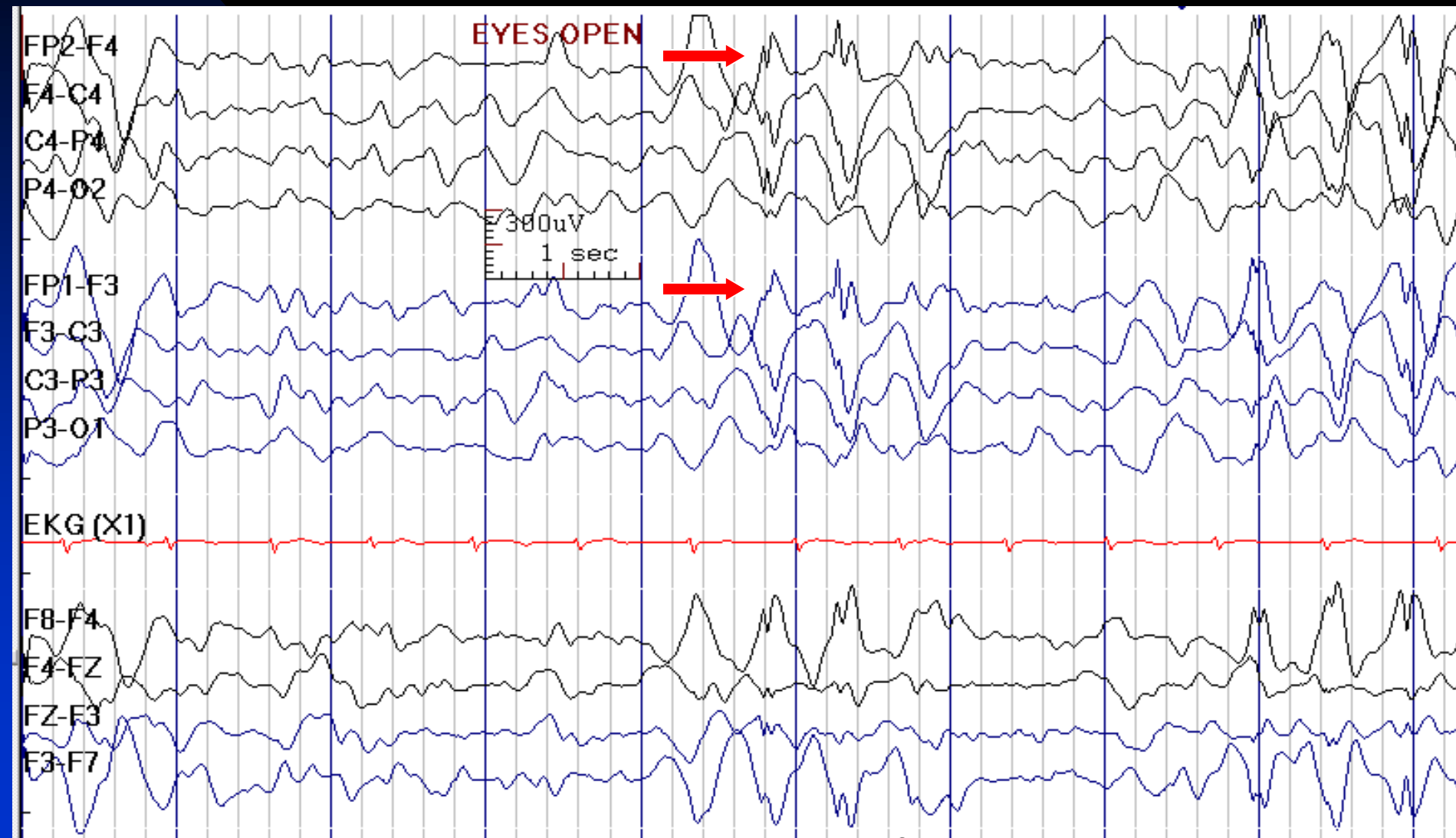
**1. With a history of seizures:** The presence of typical generalized spike-wave discharges / polyspikes discharges is consistent with the diagnosis of idiopathic (genetic) generalized epilepsy.

**2. Without a history of seizures:** This EEG demonstrates cortical dysfunction and irritability. These spikes may be present in individuals without a history of seizures (e.g., in those with asymptomatic genetic EEG trait).

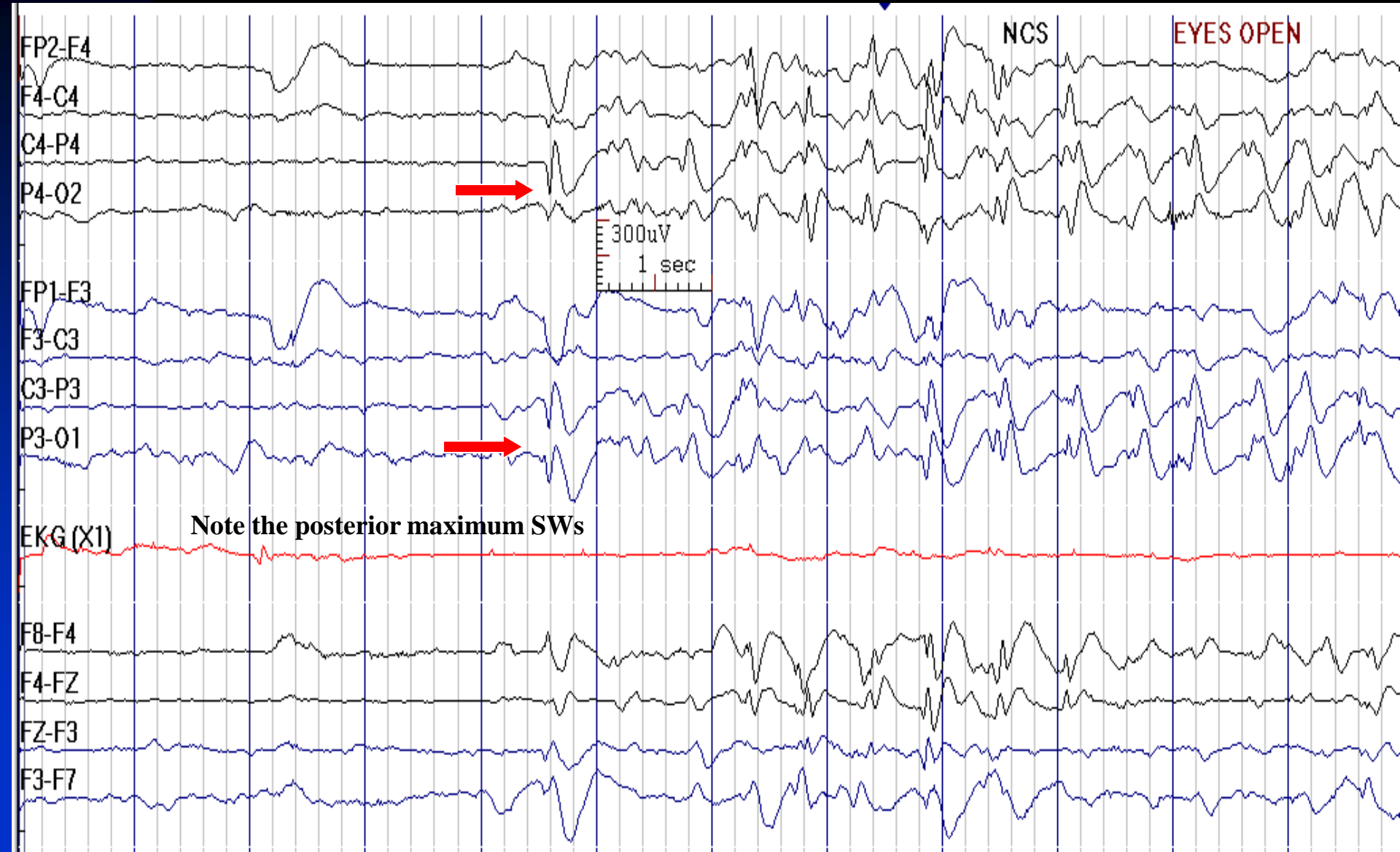
# Symptomatic (Structural-Metabolic) Generalized Epilepsy

- Diffuse slowing of the background rhythms
- Evidence for focal or diffuse pathology
- Slow spike-wave (or sharp and slow wave) complexes with frequency of  $\leq 2.5$  Hz is typical in symptomatic generalized epilepsies
- Generalized paroxysmal fast activity (GPFA) is another typical finding
- Multifocal spikes may be present as well

# Slow Spike-Waves and Diffusely Slow Background in a 5-Year-Old Boy with Lennox-Gastaut Syndrome

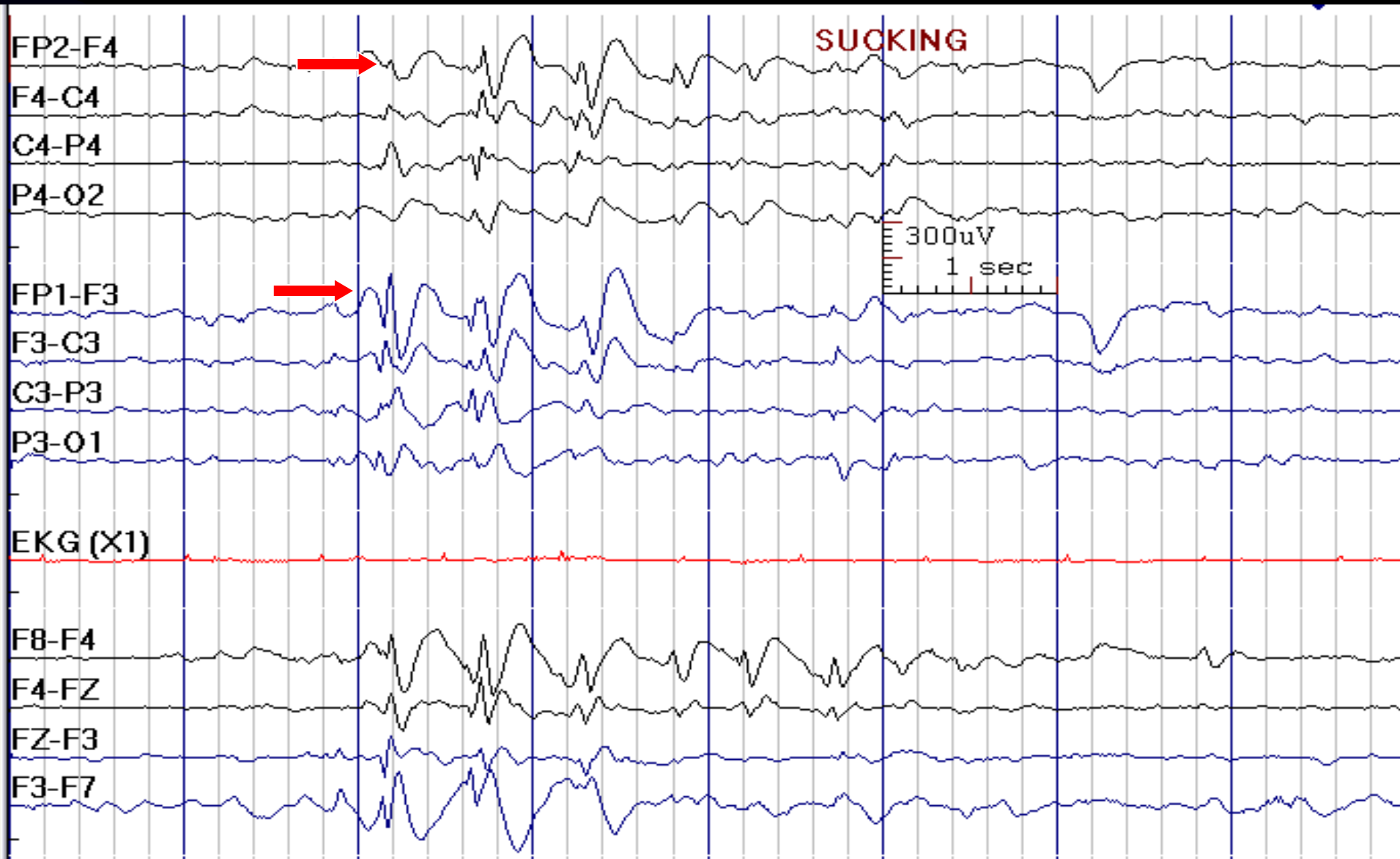


# Slow Spike-Waves and Diffusely Slow Background



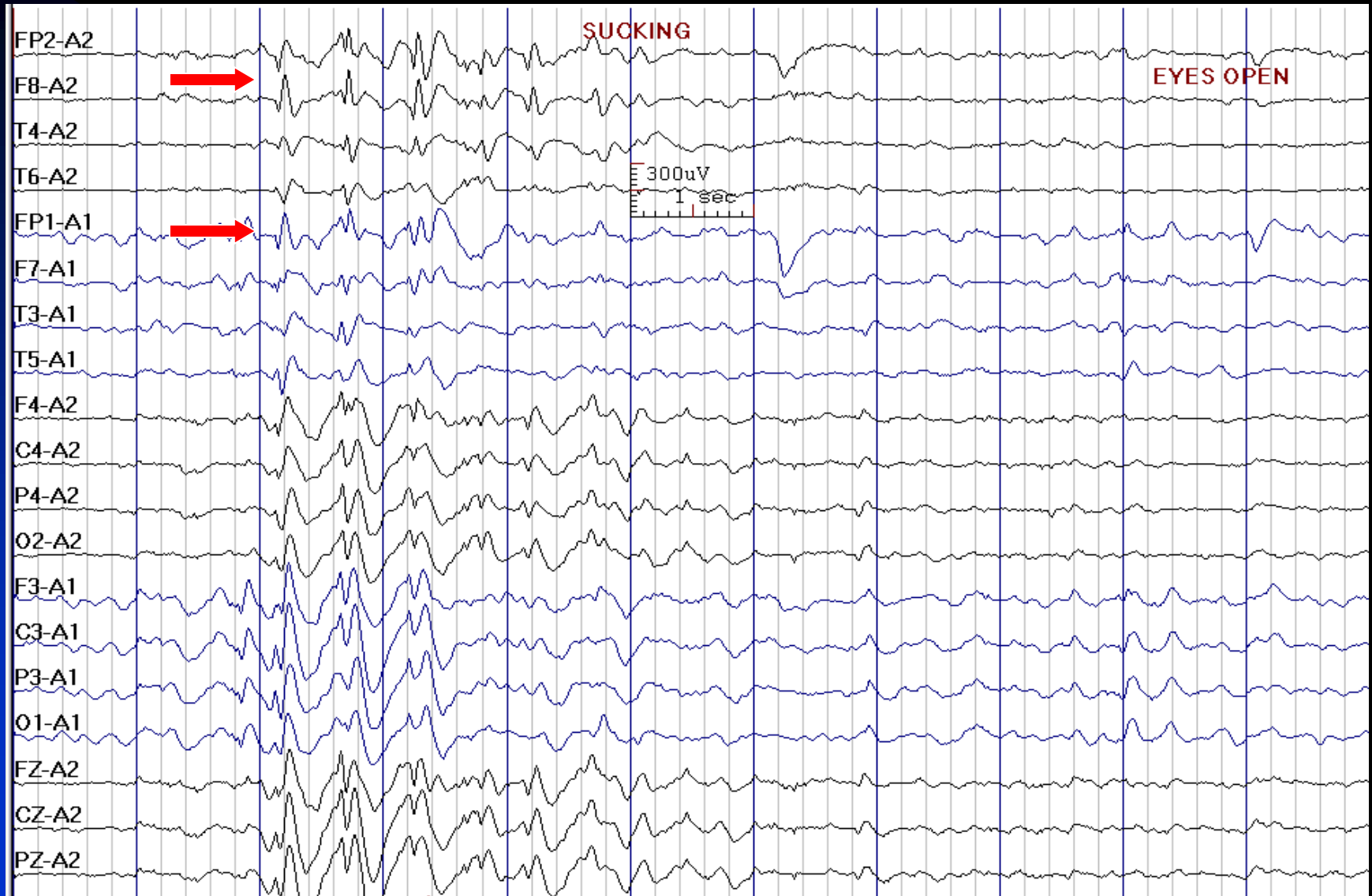


# Slow Spike-Waves and Diffusely Slow Background



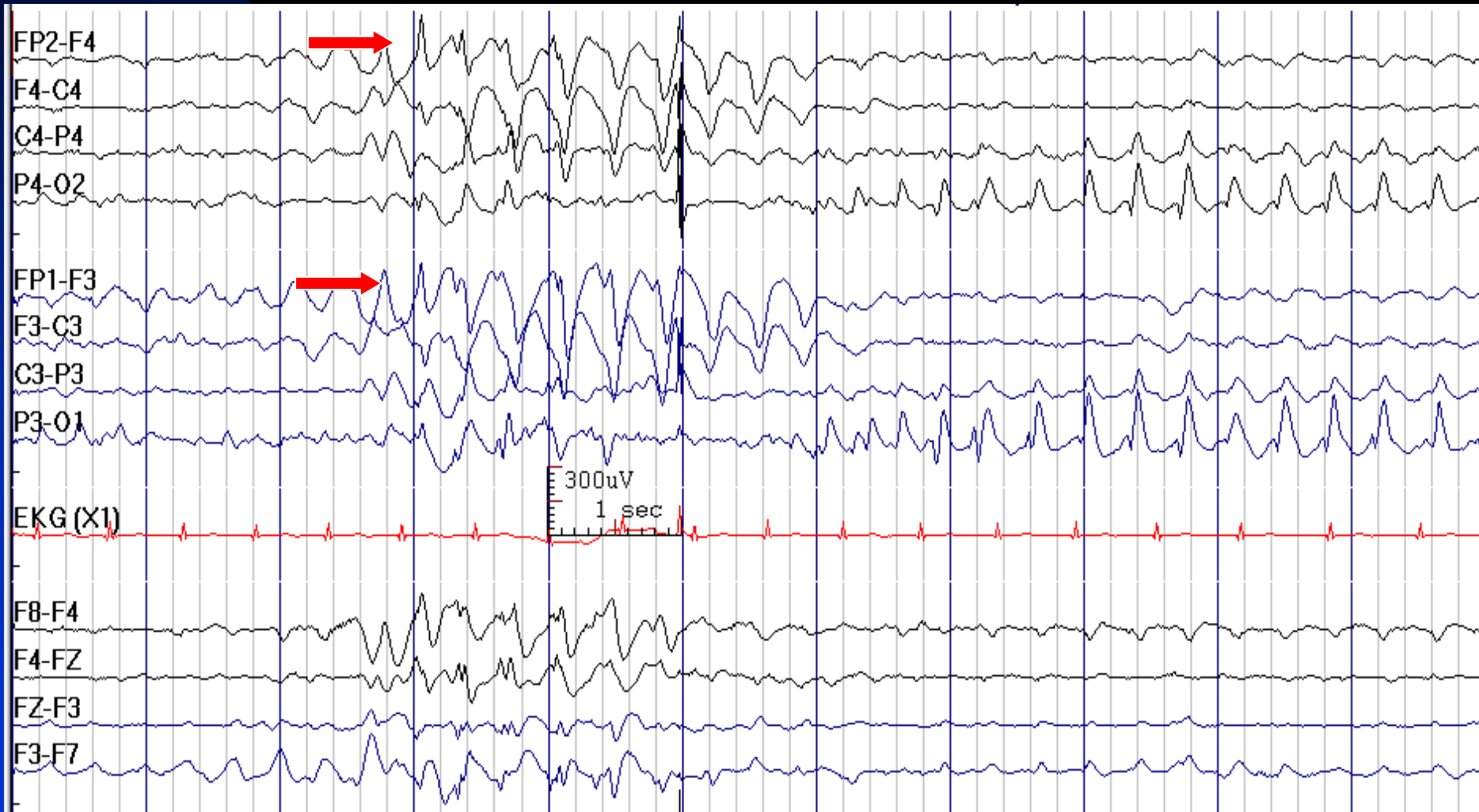
See the next image for the same finding in reference montage

# Slow Spike-Waves and Diffusely Slow Background in Reference Montage



See the previous image for the same finding in bipolar montage

# 2.5 Hz Spike-Waves, First Frontally and then Occipitally Predominant in a 10-Year-Old Girl with Angelman Syndrome



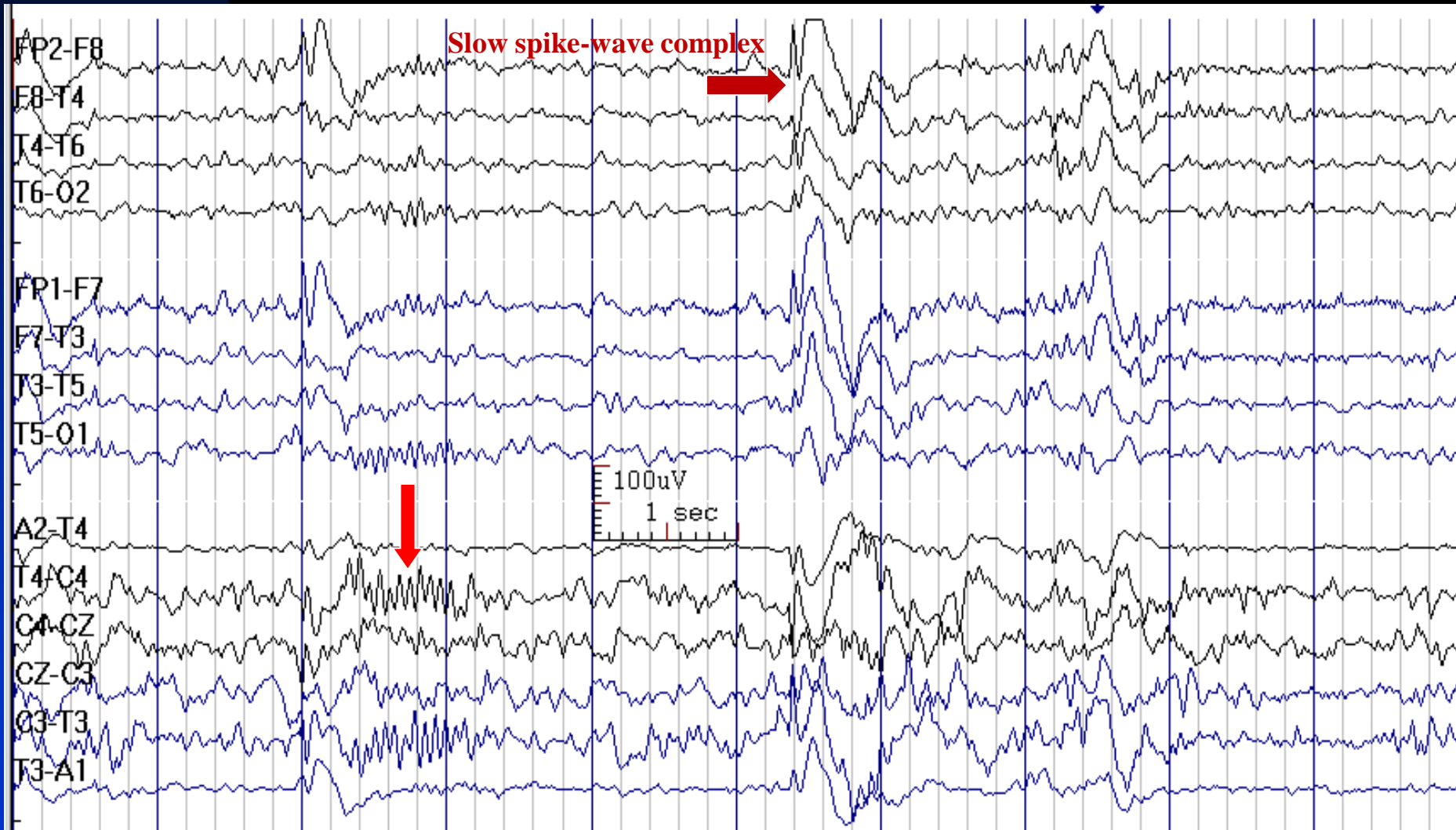
# How to Report Slow Spike-and-Wave Discharges

- *In conclusion section, write:*
  - ◆ The presence of slow spike-wave discharges is consistent with the diagnosis of symptomatic generalized epilepsy. This is often seen in the setting of a diffuse disturbance of brain function with a mixed seizure disorder.

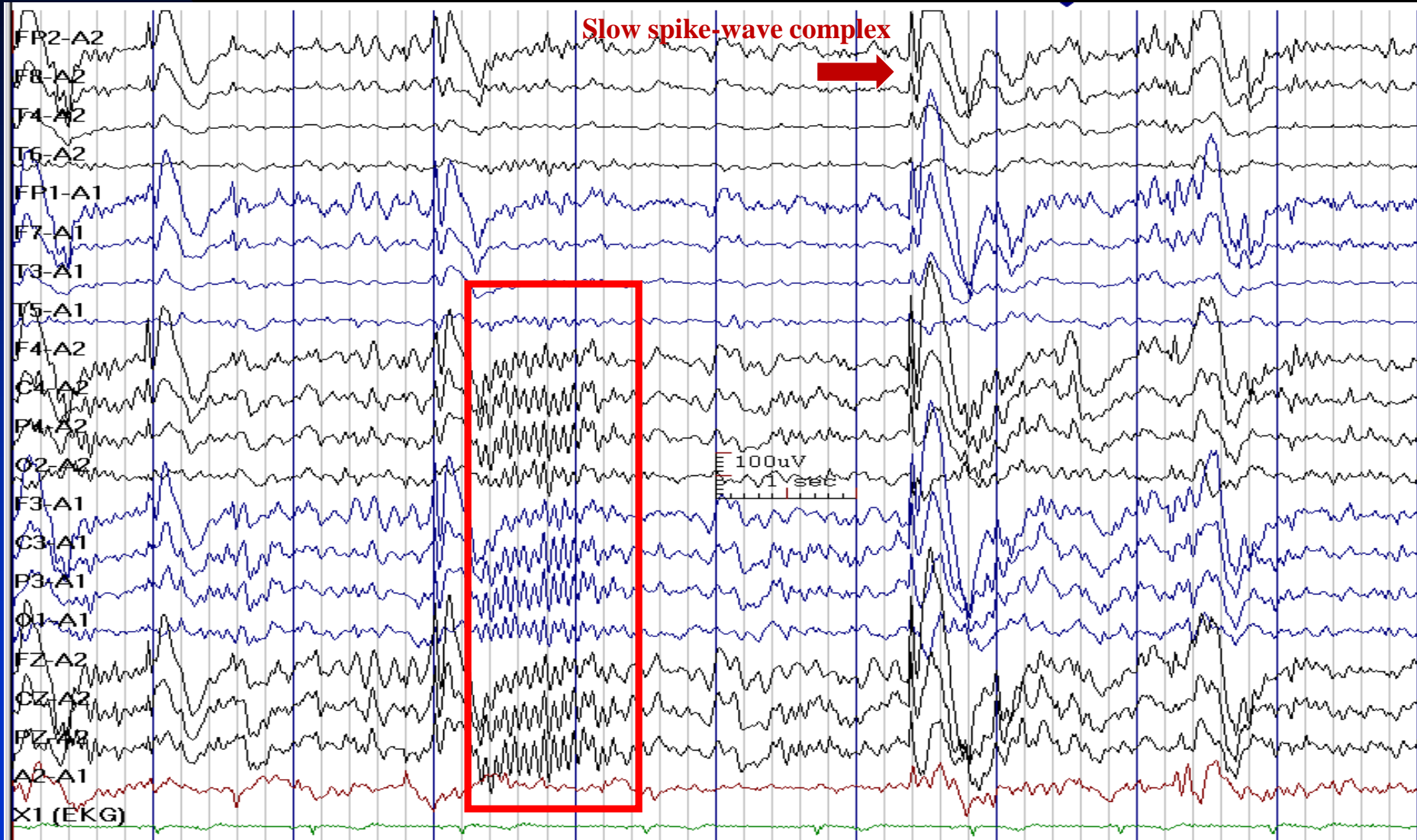
# Paroxysmal Fast Activity (PFA)

- **Activity:** 10-25 Hz
- **Amplitude:** Higher than the background and often greater than 100  $\mu\text{V}$
- **Characteristics:** Sudden onset and resolution
- **Duration:** 0.25-2 seconds in localized PFA and 3-18 seconds in generalized PFA (when GPFA is longer than 5 seconds, it is usually accompanied by a tonic seizure)
- **State:** Sleep
- **Age:** Children and young adults

# GPFA in a 19-Year-Old Woman with Symptomatic Generalized Epilepsy

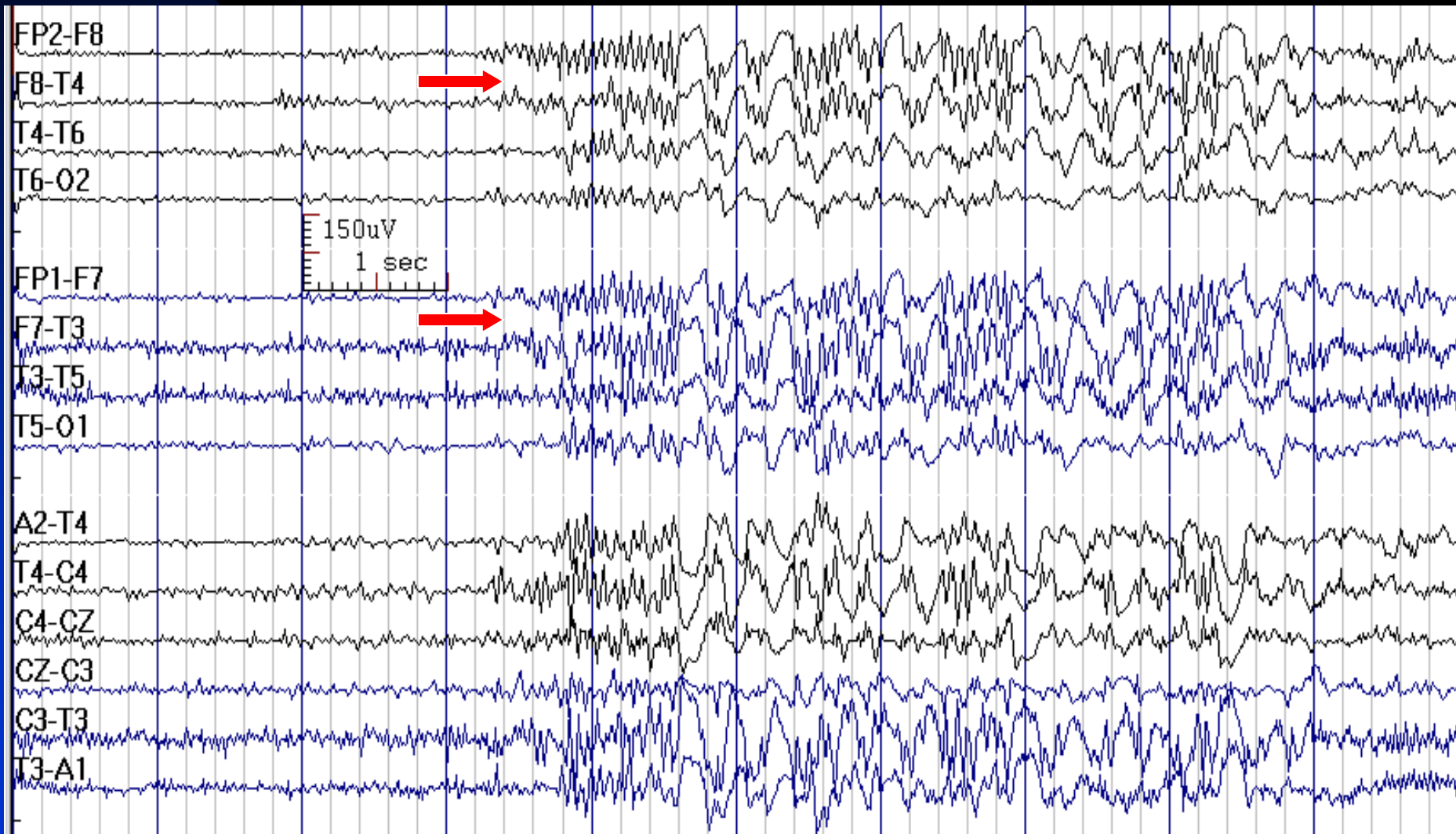


# GPFA in a 19-Year-Old Woman with Symptomatic Generalized Epilepsy



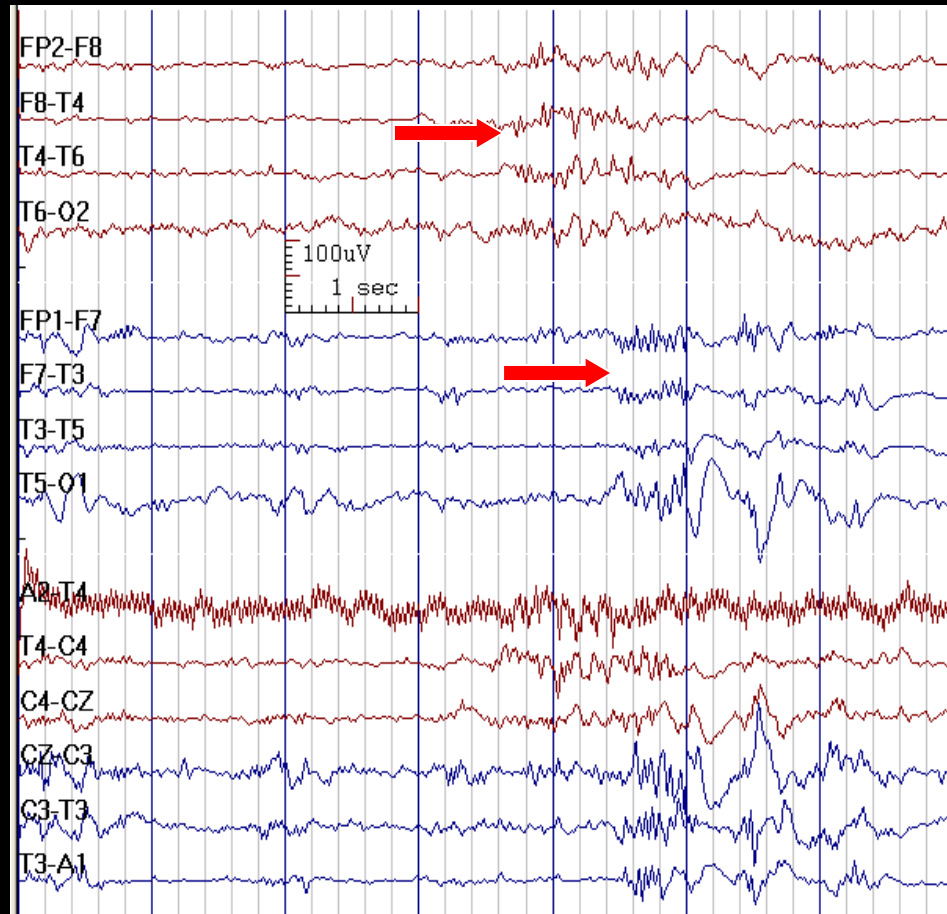
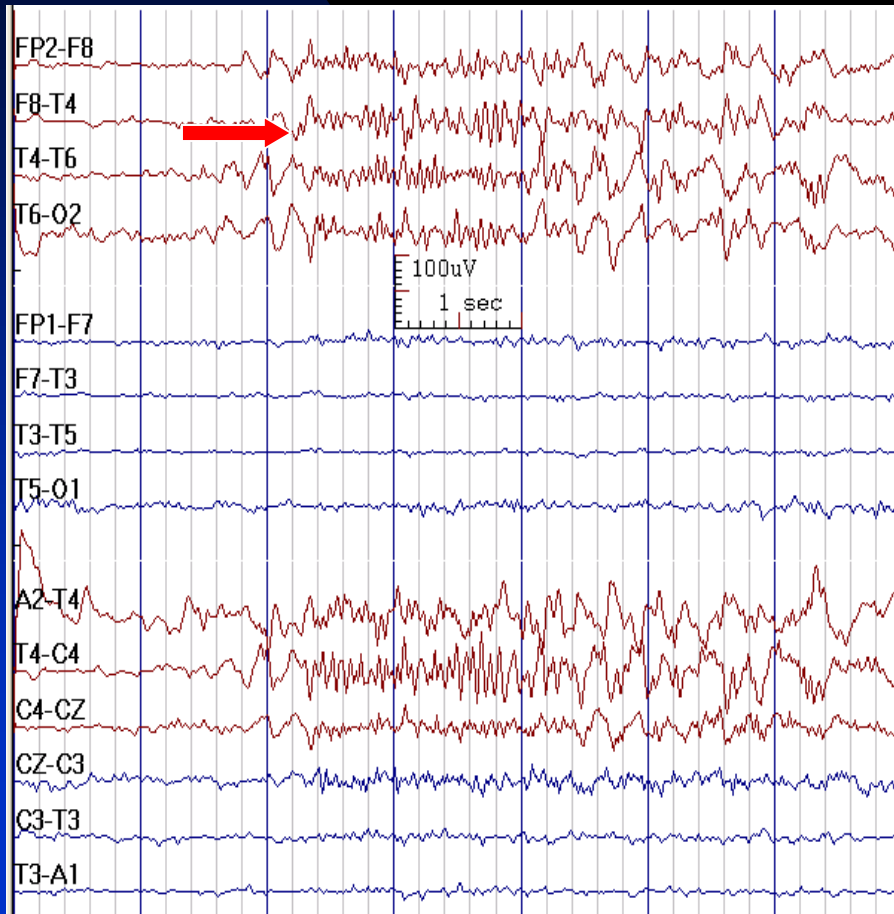


# GPFA Progressing to Polyspike-Waves in a 35-Year-Old Woman with Refractory Absence Seizures





# Bilateral Independent Paroxysmal Fast Activity after Callosotomy in a Man with Lennox-Gastaut Syndrome



# How to Report GPFA

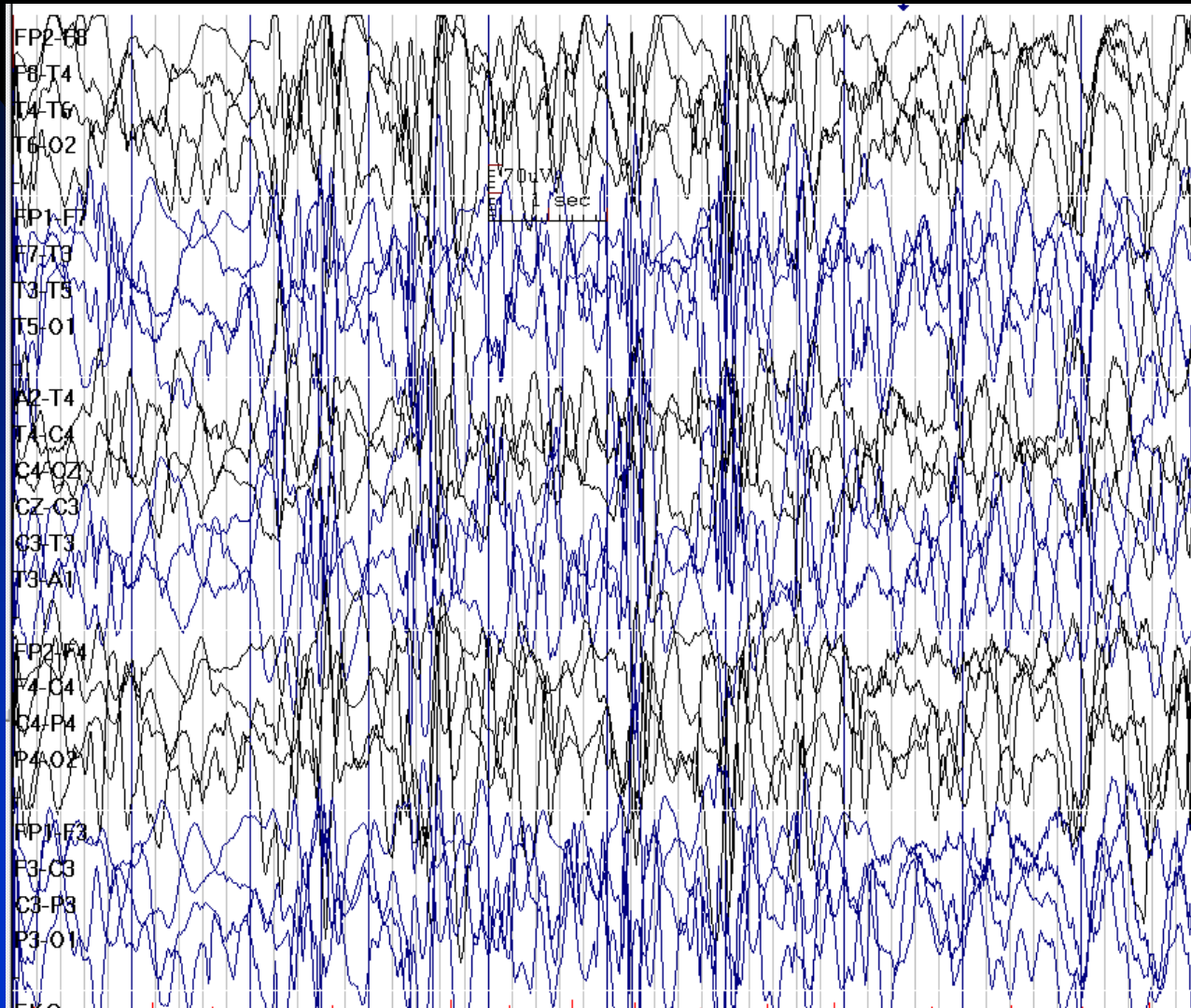
- *In conclusion section, write:*
  - ◆ The presence of generalized paroxysmal fast activity (GPFA) is consistent with the diagnosis of symptomatic generalized epilepsy. This is often seen in the setting of a diffuse disturbance of brain function with tonic seizures.

# Hypsarrhythmia

- Chaotic, high-voltage, irregular slow waves with variable synchrony
- Absence of all normal activities, very disorganized
- Multifocal, posterior maximum spikes/sharp waves
- Hypsarrhythmia is continuous in wakefulness and light sleep, it may be discontinuous in deep sleep and disappears in REM sleep
- It may increase in sleep (non-REM)
- Usually correlates with infantile spasms and seen in West syndrome
- Usually seen in ages 3 months to 5 years
- The sensitivity should be lowered when recording a hypsarrhythmic EEG

- **Symmetrical hypsarrhythmia:** often in idiopathic or cryptogenic cases
- **Asymmetrical hypsarrhythmia:** ipsilateral structural brain lesions. Intravenous diazepam reduces the amount of hypsarrhythmia and focal slow waves indicating localized lesions may become more evident
- **Lissencephaly and Aicardi syndrome:** burst-suppression activity

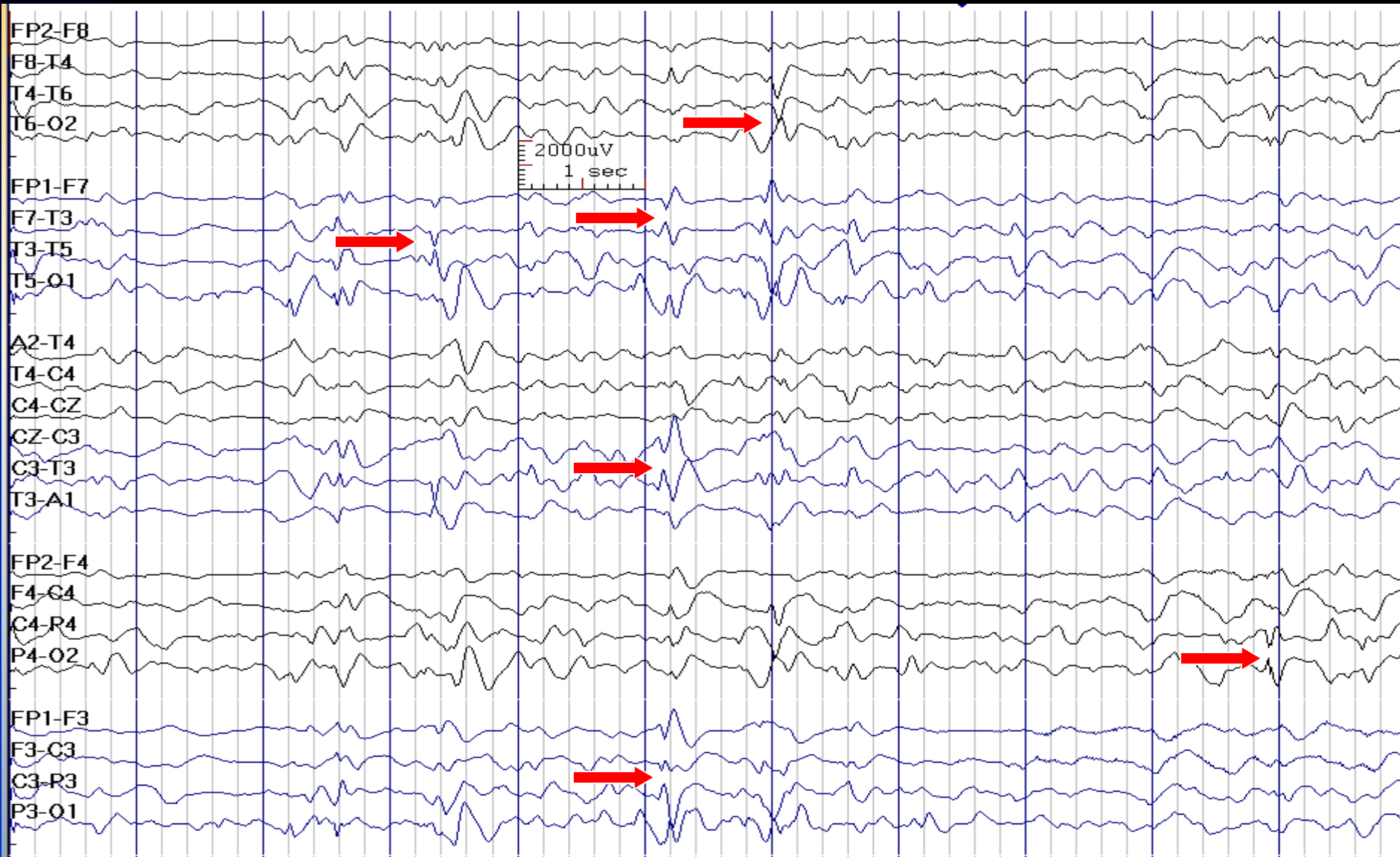
# Hypsarrhythmia in a 1-Year-Old Boy (normal sensitivity)



See the next image for the same finding with reduced sensitivity

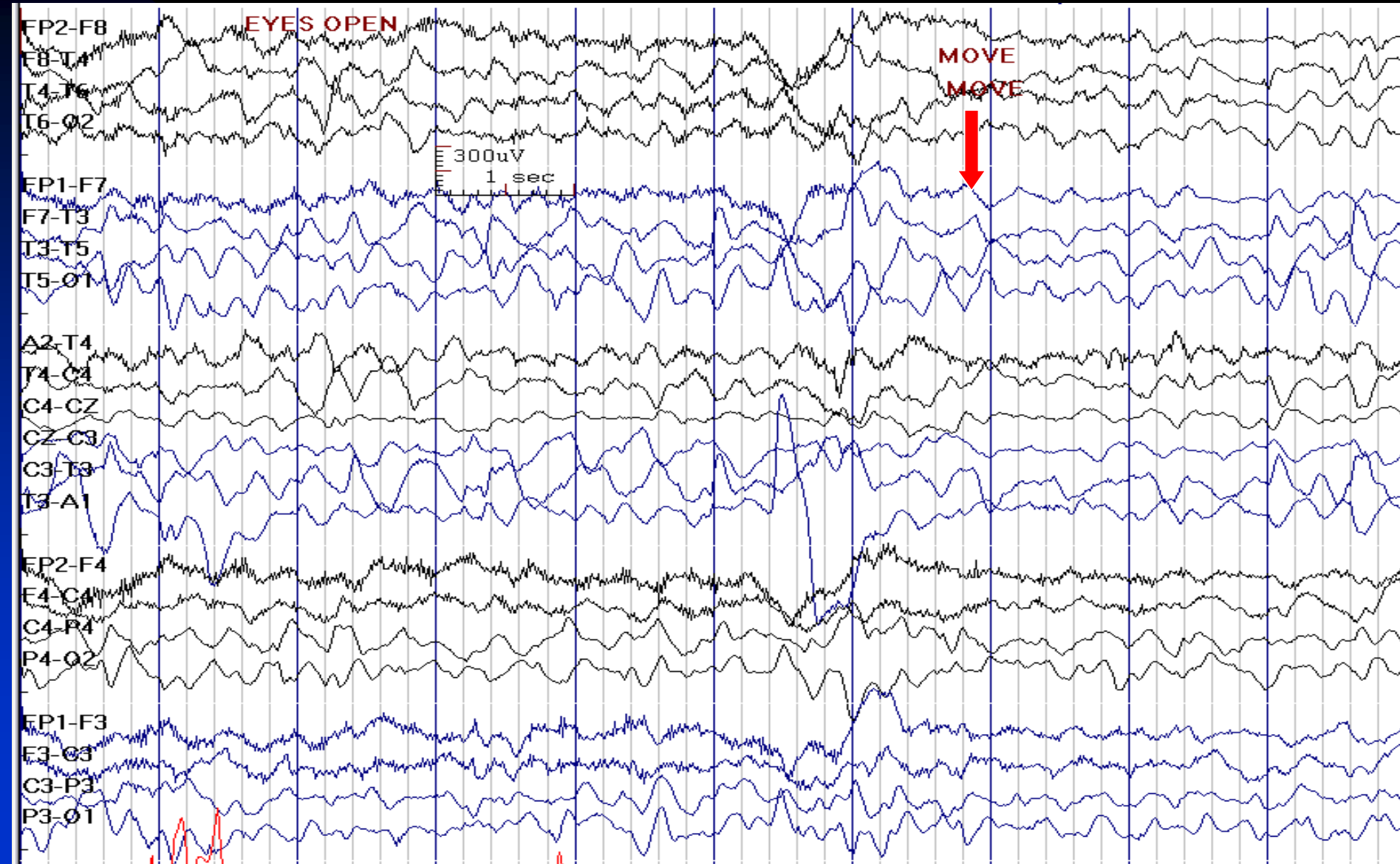
# Hypsarrhythmia: 1-Year-Old Boy with West Syndrome

(same patient, reduced sensitivity; arrows point to sharp waves)



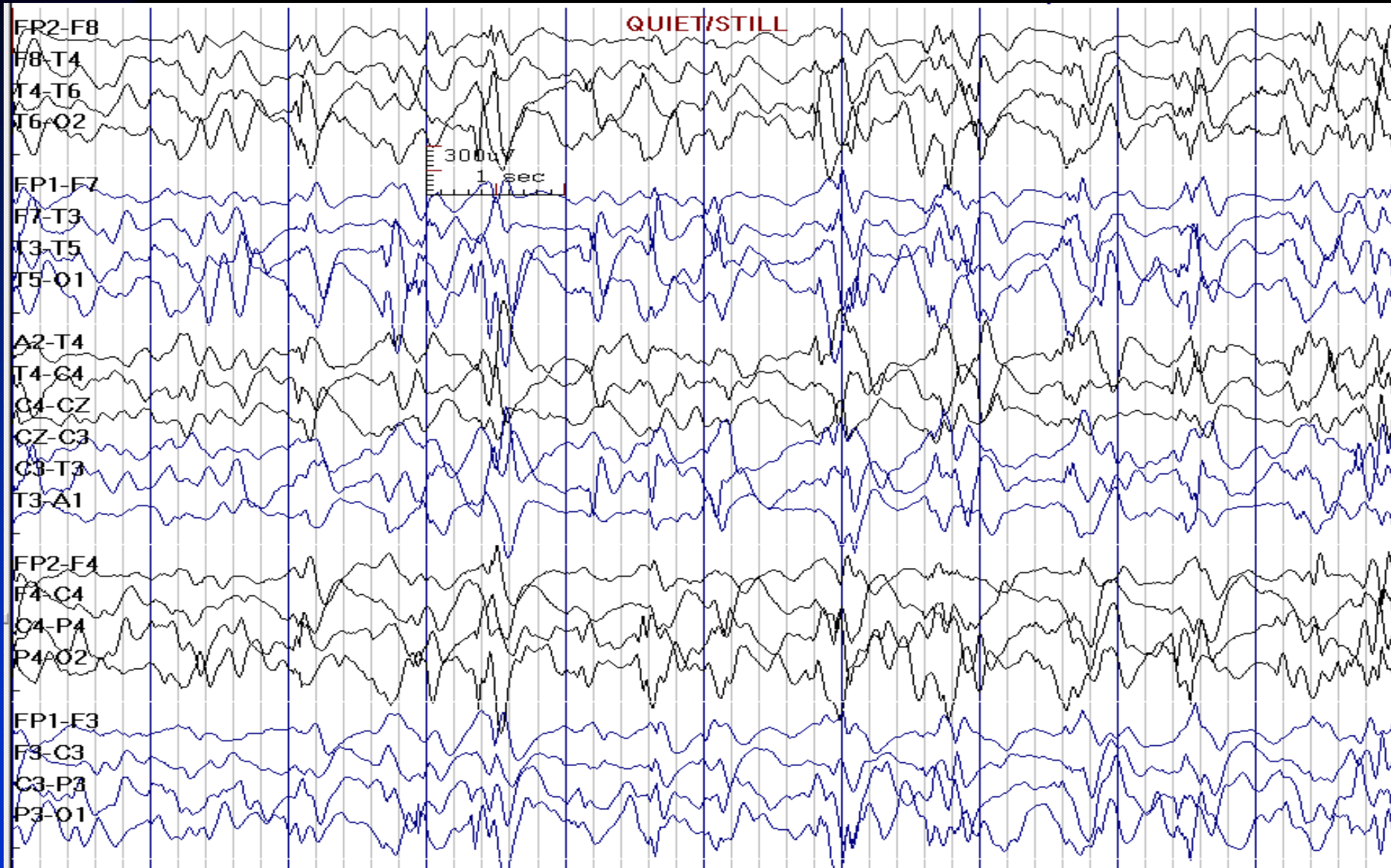
See the previous image for the same finding with normal sensitivity

# Hypsarrhythmia during Wakefulness (reduced sensitivity)



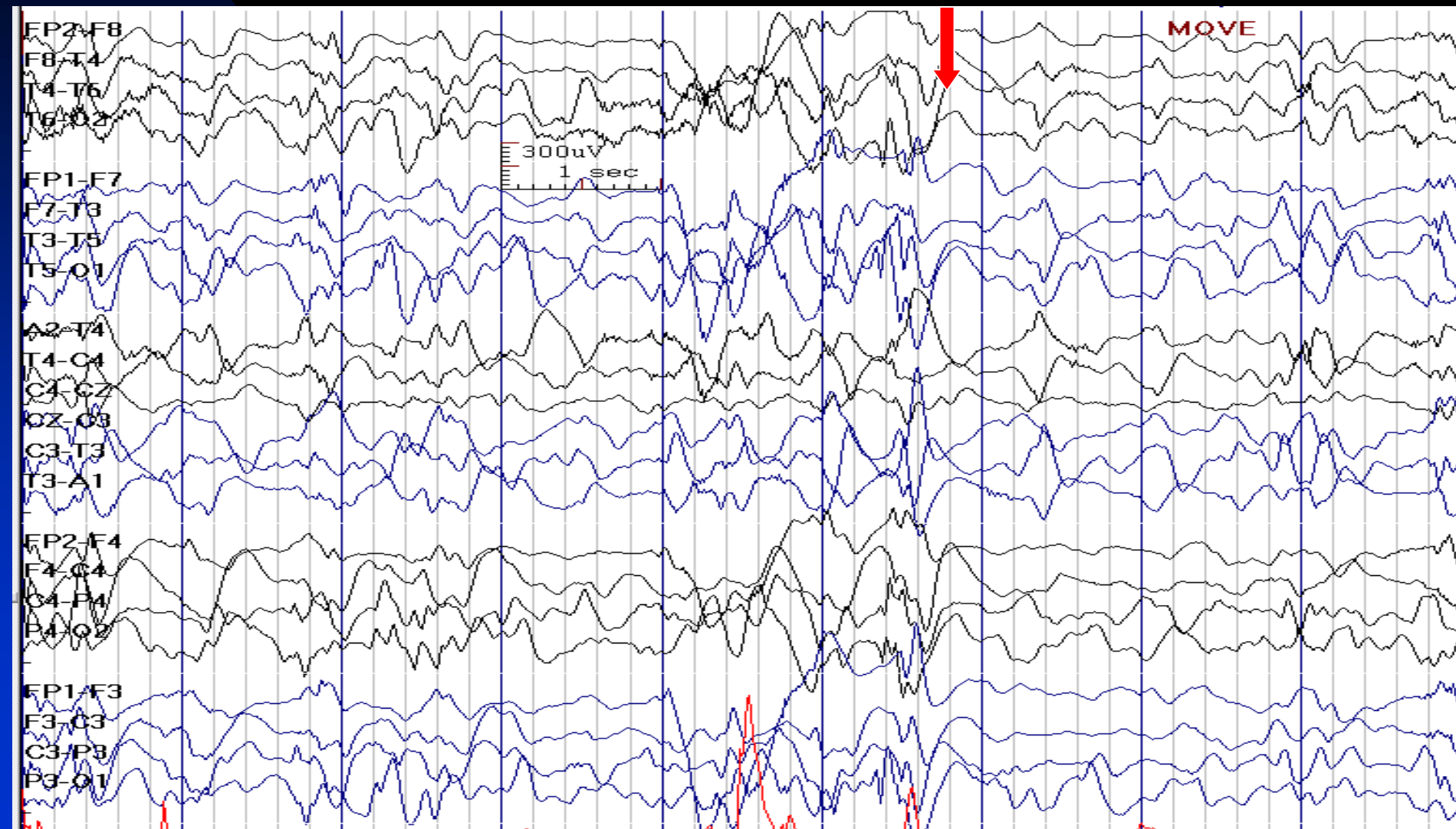


# Hypsarrhythmia is Increased during Sleep (same patient)

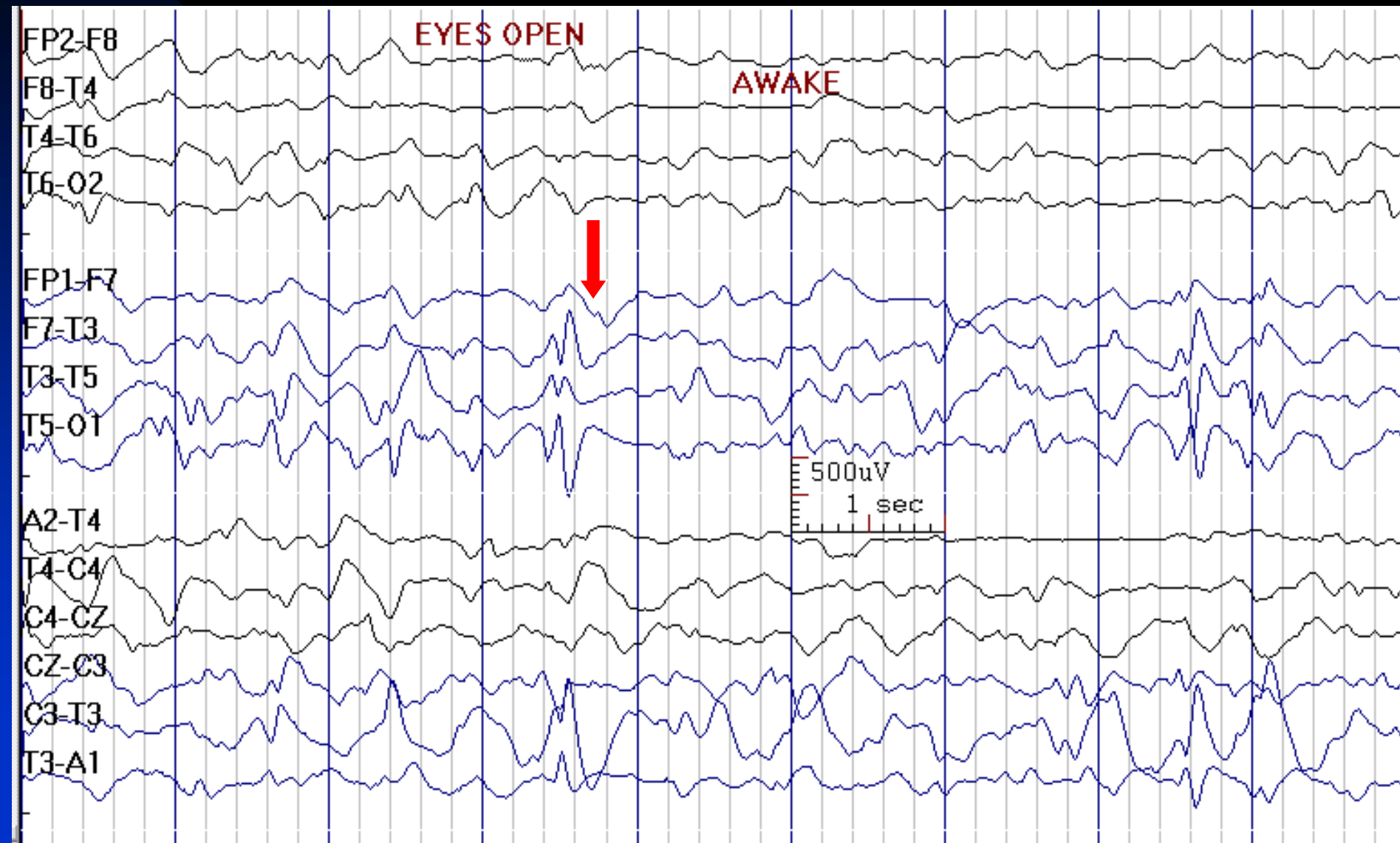




# Immediately after Arousal, the EEG May Transiently Normalize in Hypsarrhythmia (same patient)



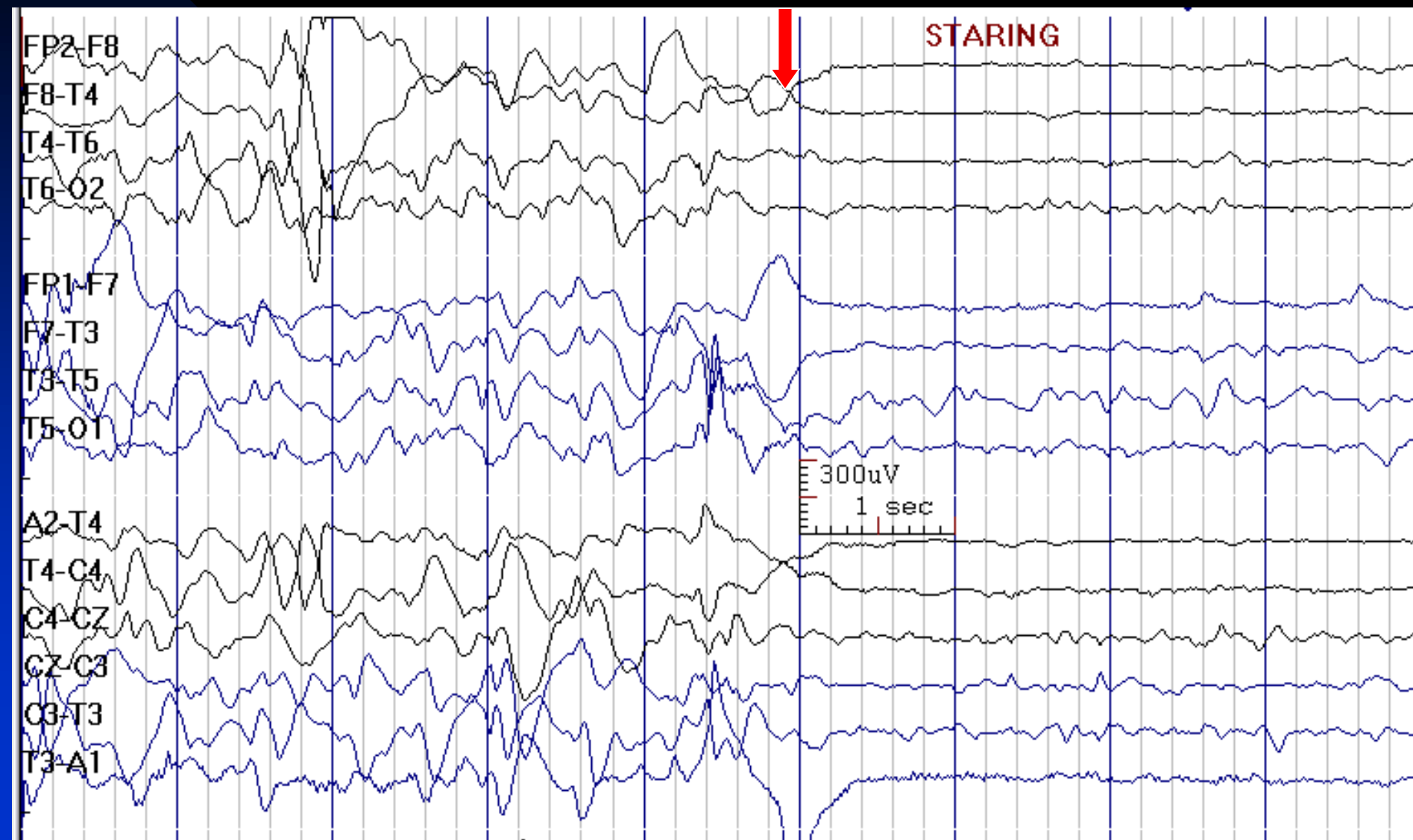# Asymmetrical Hypsarrhythmia Suggests Ipsilateral Structural Brain Lesion



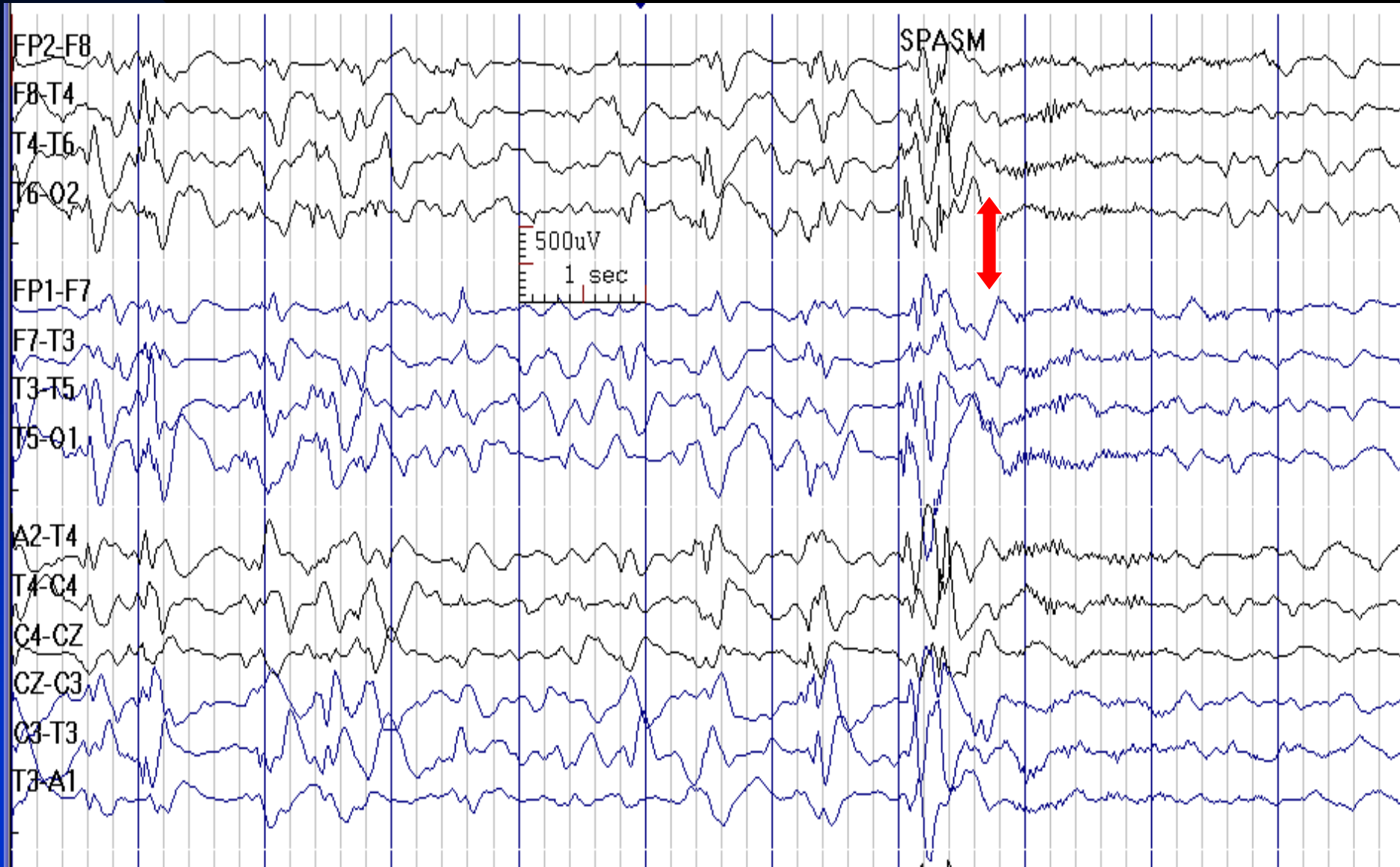
# Ictal EEG in Hypsarrhythmia

- High voltage frontally predominant, generalized slow wave transient, followed by diffuse voltage attenuation (**electrodecremental event**): 38%
- Generalized sharp-and-slow-wave complexes, with or without following attenuation: 31%
- Period of attenuation only: 12%
- Generalized slow-wave transients: 11%
- Attenuation with superimposed fast activity: 7%

# Electrodecremental Event in Hypsarrhythmia



# Attenuation with Superimposed Fast Activity in Hypsarrhythmia



# How to Report Hypsarrhythmia

- *In conclusion section, write:*
  - ◆ The presence of hypsarrhythmia is consistent with the diagnosis of epileptic spasms and is usually seen in West syndrome.

# Spread of EEG Potentials

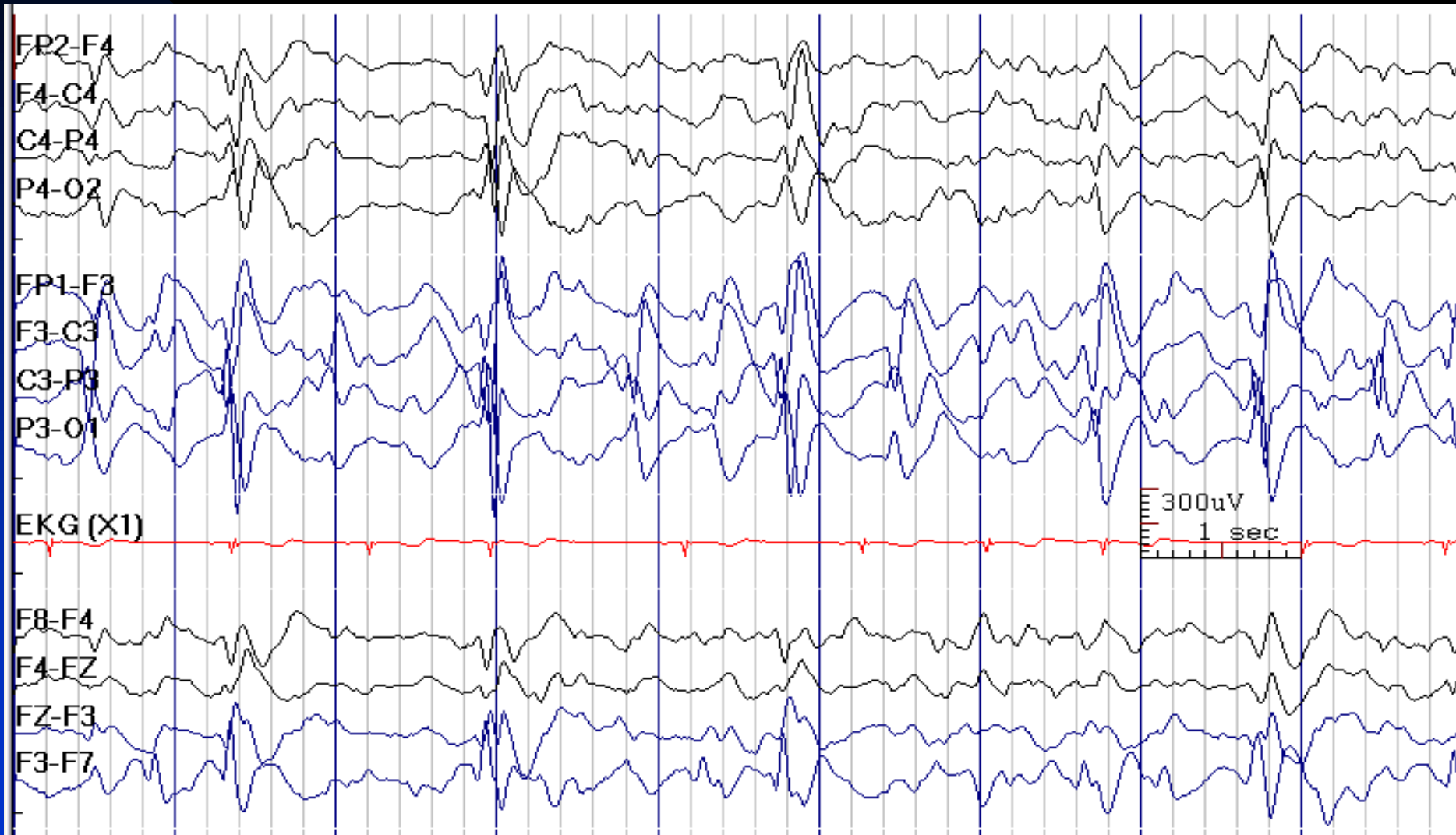
## ■ Propagation:

- ★ Transmission of neuronal signals through axonal and synaptic pathways from the generating neurons at the source to remote neurons near the recording electrode
- ★ The EEG potential recorded remote from the source is delayed, dispersed and often attenuated compared to the potential recorded close to the source

## ■ Volume conduction:

- ★ Transmission of current through the tissues between the generator and the recording electrode
- ★ Current travels at the speed of light. Voltage drops exponentially with distance from source
- ★ EEG potential is attenuated in voltage, but not delayed in time (it is synchronous with the potential recorded closer to the source)

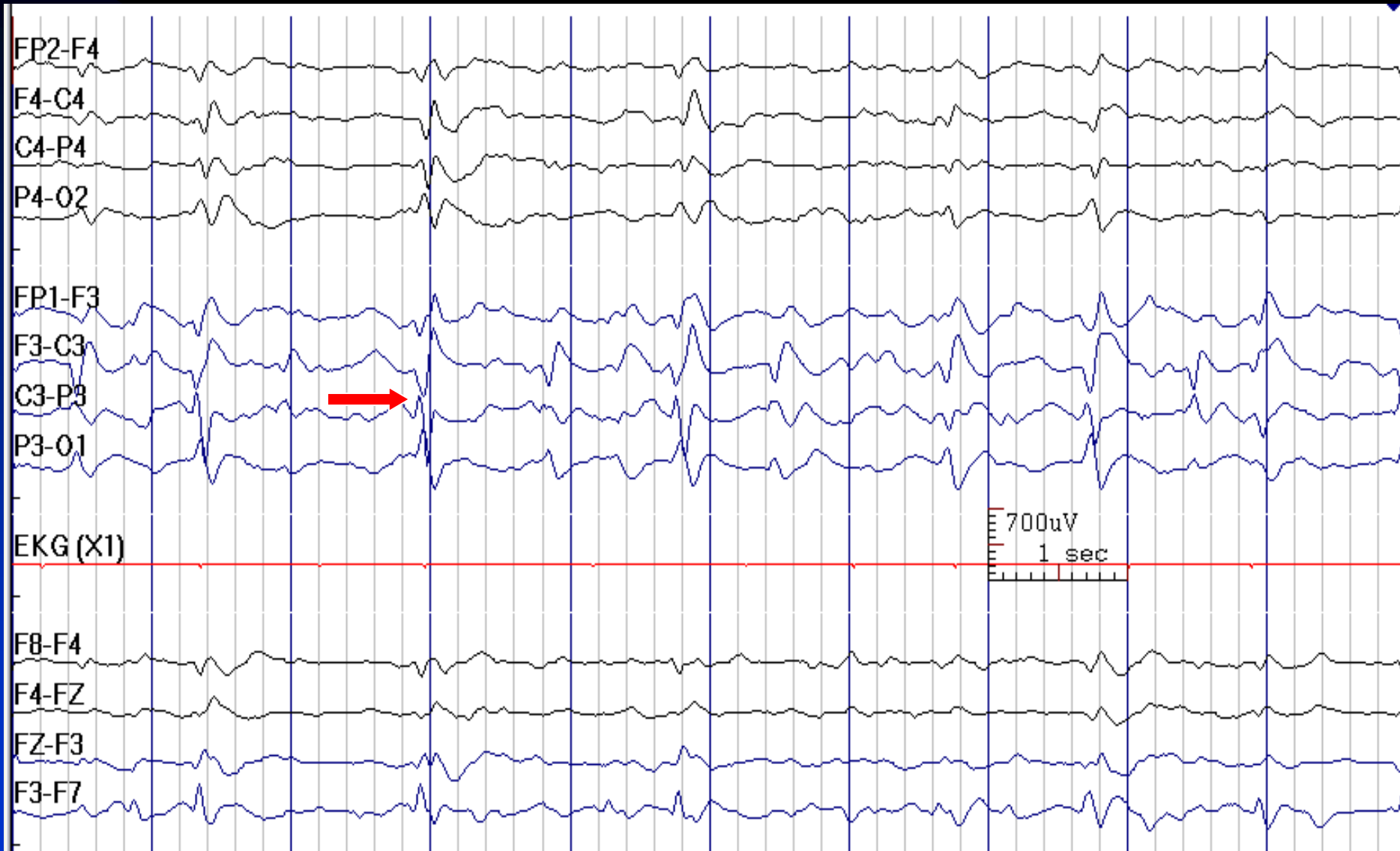
# Spread of Left Sided EEG Potentials to the Right due to Volume Conduction



See the next image for the same finding with reduced sensitivity



# C3 Sharp Waves in a 11-Year-Old Boy with Polymicrogyria (Previous Image)



See the previous image for the same finding with normal sensitivity

# Interictal Epileptiform Discharges in Normal Individuals

- Some normal individuals (about 2% of children and 0.5% of adults) who has never had a seizure may carry the genetic trait for IEDs
- The most common IEDs seen in normal individuals include:
  - ★ Centro-temporal spikes
  - ★ Generalized spike wave discharges
  - ★ Photoparoxysmal discharges

# Interictal Epileptiform Discharges in Non-epileptic Conditions

- Some patients who has never had a seizure may have IEDs in their EEGs (e.g., congenital blindness, cerebral palsy, migraine headaches)
- IEDs typical for temporal lobe epilepsy are unusual in individuals without epilepsy



# **Ictal Epileptiform Discharges**

## **(Seizures)**

# Seizures

- **Definition:** paroxysmal changes in behavior or perception with associated abnormal hypersynchronous firing of neurons
- **Expanded definition:** abnormal hypersynchronous neuronal firing with or without behavioral or perceptual correlate (i.e., clinical versus electrographic or subclinical seizures)

# EEG in Seizures

- Does it differ from the background?
- Is there a sustained rhythmic pattern?
- Does the frequency, amplitude or morphology evolve?
- Is there a behavioral change?
- Can it be explained as an artifact?
- Does it resemble a known normal variant?

# Ictal Scalp EEG

## ■ Isomorphic seizure pattern:

- ★ Ends similar to the way in which it begins, without progression through multiple phases into a postictal phase
- ★ Ictal morphology is similar to interictal epileptiform patterns and differs only in greater rhythmicity, duration, spatial extent and amplitude
- ★ Characteristic for generalized seizures (e.g., absence seizures)

## ■ Metamorphic seizure pattern:

- ★ Ends quite differently from its beginning, commonly progressing through different ictal phases into a postictal state
- ★ Seen both in generalized and partial seizures

# Characteristics of Generalized Seizures

- Generalized onset seizure patterns:
  - ★ Generalized spike-waves (often in absence seizures)
  - ★ Generalized polyspike-waves (often in myoclonic seizures)
  - ★ Generalized paroxysmal fast activity (often in tonic seizures)
  - ★ Electrodecremental pattern (often in epileptic spasms)



# Characteristics of Partial Seizures

- An identifiable change from the interictal background at seizure onset
- A clear evolution in frequency, amplitude and usually of spatial extent of that activity during the seizure
- An identifiable end of that activity
- Onset patterns in partial seizures :
  - ◆ Delta, theta, alpha, or beta frequency
  - ◆ Focal, lateralized or non-lateralized onset
  - ◆ Increase in interictal spikes or cessation of interictal spikes
  - ◆ Focal attenuation of the background

# Ictal EEG in Mesial Temporal Lobe Epilepsy

- Lateralized rhythmic theta or alpha activity (5 Hz or greater) is seen in most people with MTLE
- It typically occurs 10 to 40 seconds after clinical seizure onset
- It shows evolution in frequency and amplitude
- If present, this activity correctly lateralizes seizure onset zone in about 85-95% of patients

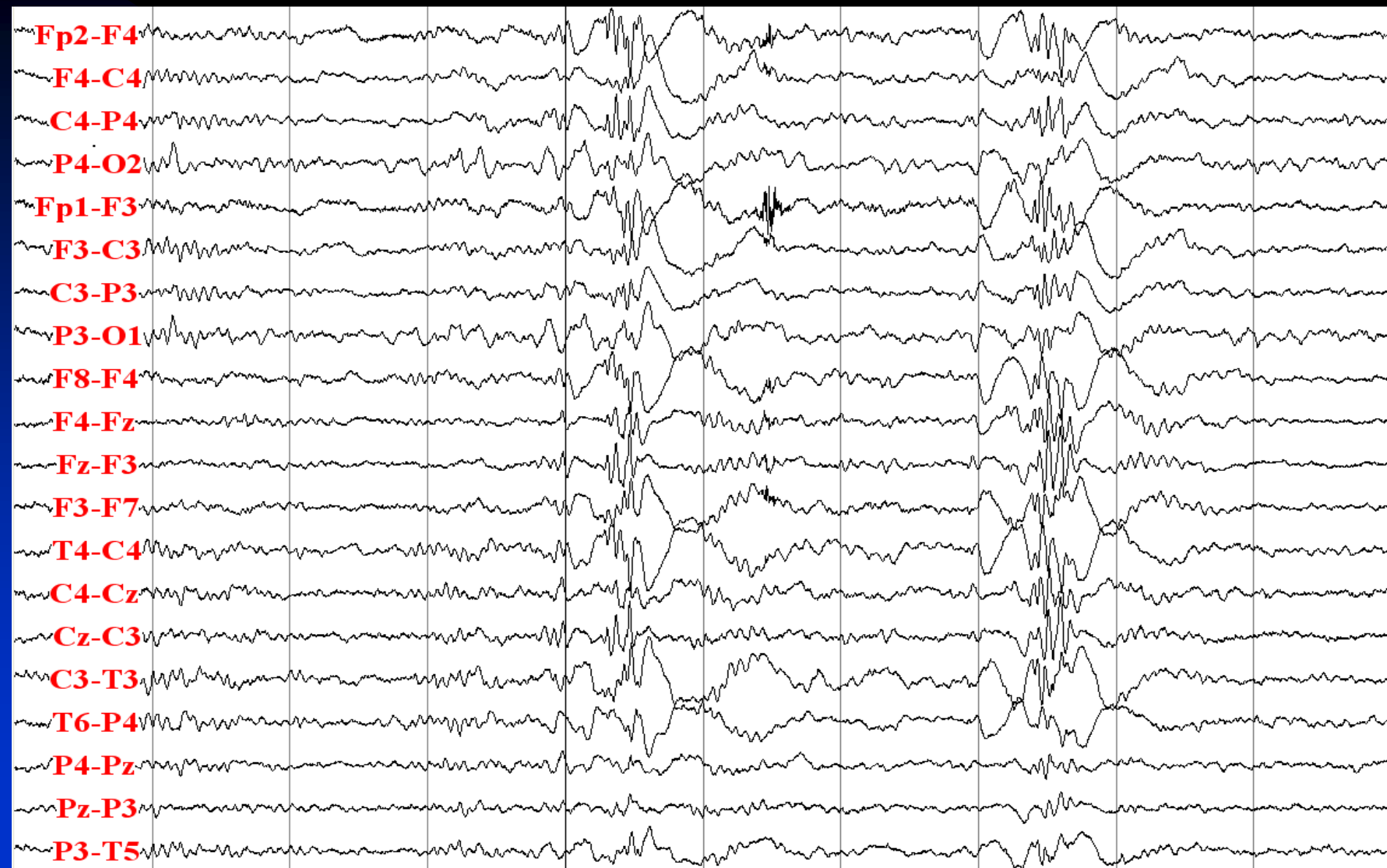
# Ictal EEG Case Studies

Know seizure patterns, aim for clinical correlation when possible

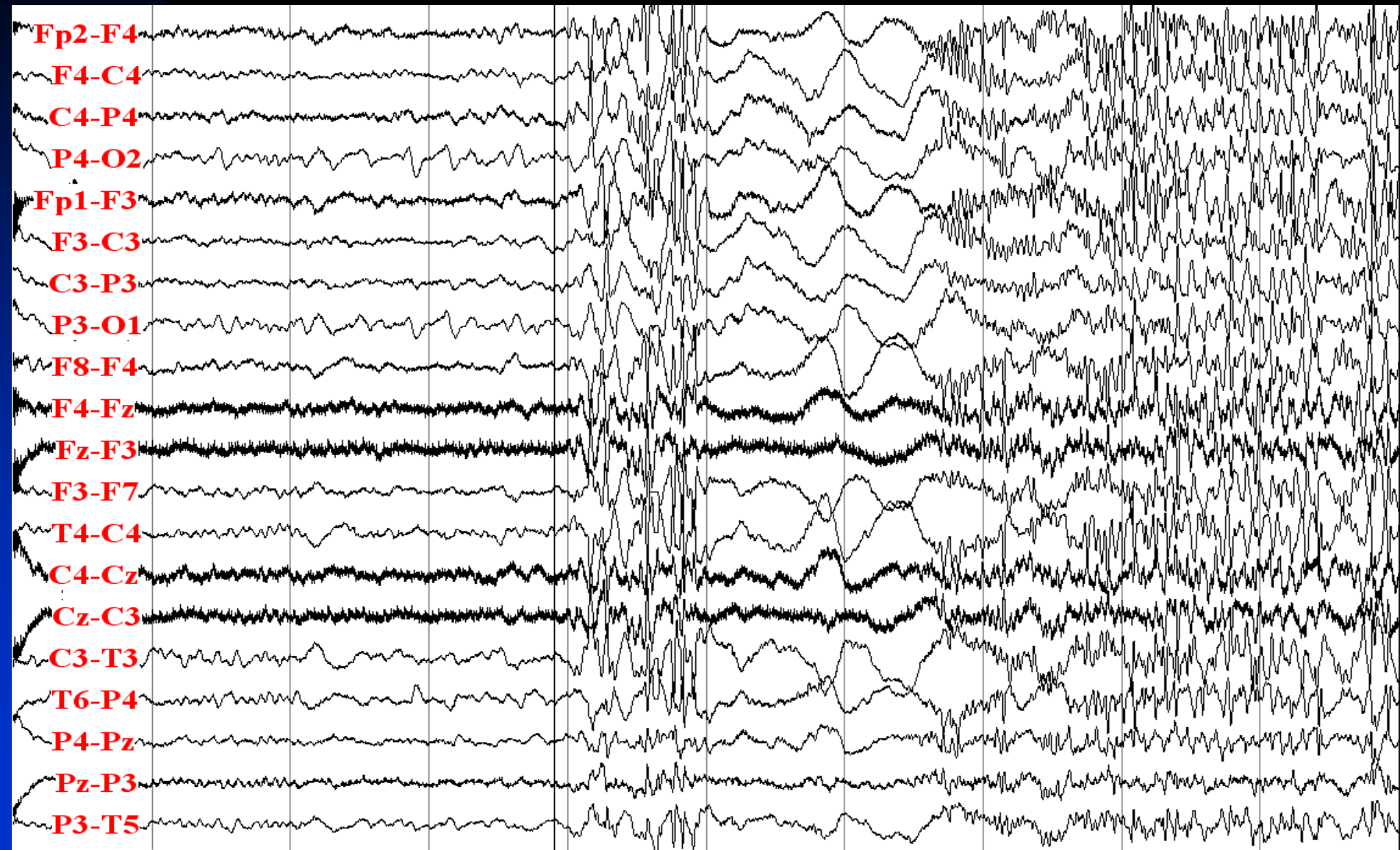
# Idiopathic (Genetic) Generalized Epilepsy (GTCS only)

- 57-year old right-handed woman with 37-year history of seizures
- Risk factor: epilepsy in paternal grandfather
- Neurological examination: normal
- Description of seizures: generalized tonic-clonic seizures
- Semiology (video-EEG monitoring): vocalization (screaming) starting 10 seconds after electrographic onset, tonic and then clonic activity in all extremities, prolonged confusion in postictal phase
- MRI: normal
- Interictal EEG: generalized polyspike-waves
- Ictal EEG: polyspike-wave, then diffuse attenuation, followed by generalized fast activity with increasing muscle artifact, finally intermittent generalized activity obscured by muscle artifacts


# Interictal: Generalized Polyspike-Waves




# Seizure Onset: Generalized Polyspikes, Then Diffuse Attenuation, Then Diffuse Fast Activity



# Tonic Phase with Increase in Muscle Activity

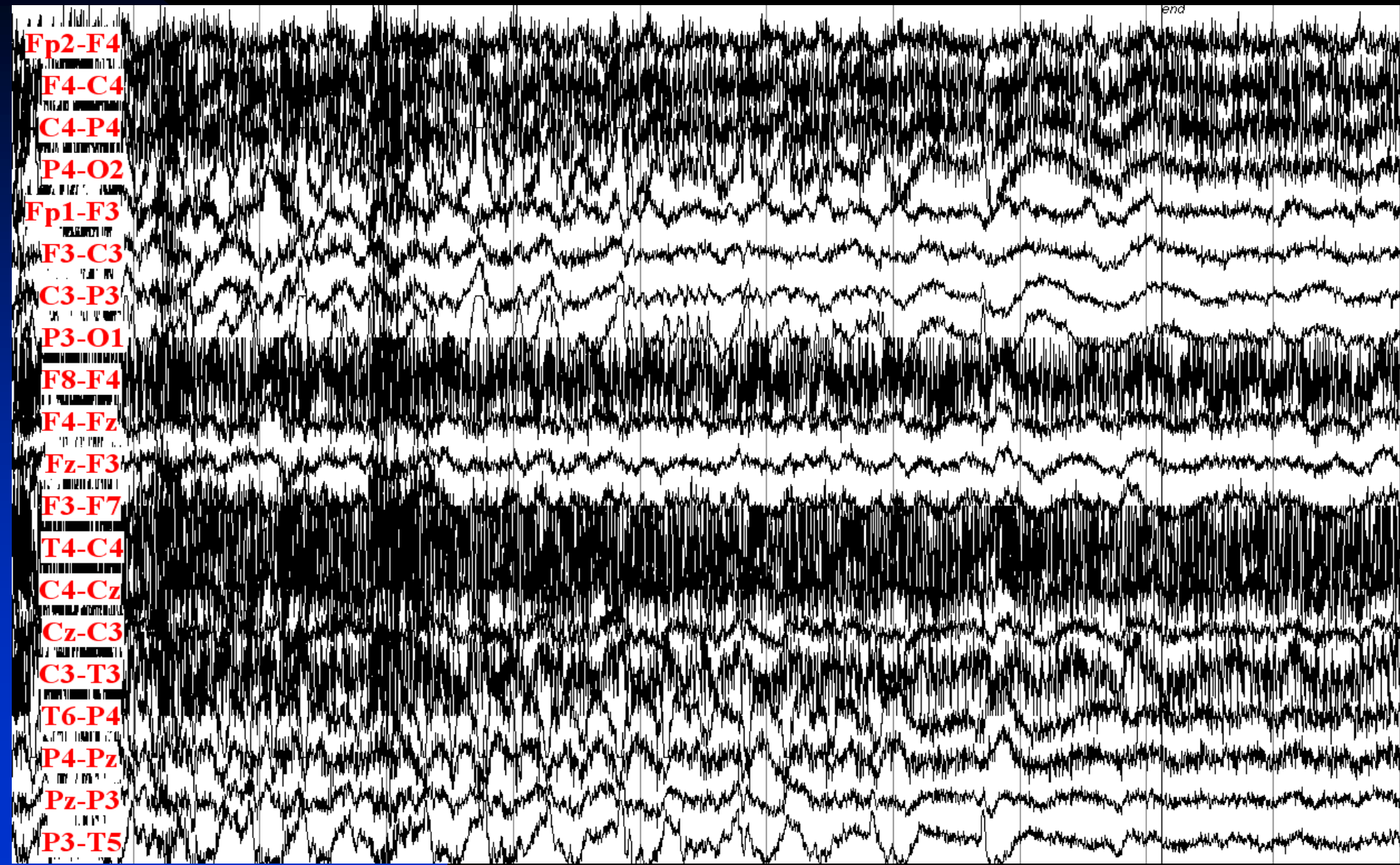


# Clonic Phase with Intermittent Muscle Activity





# Seizure Ends with Postictal Diffuse Attenuation



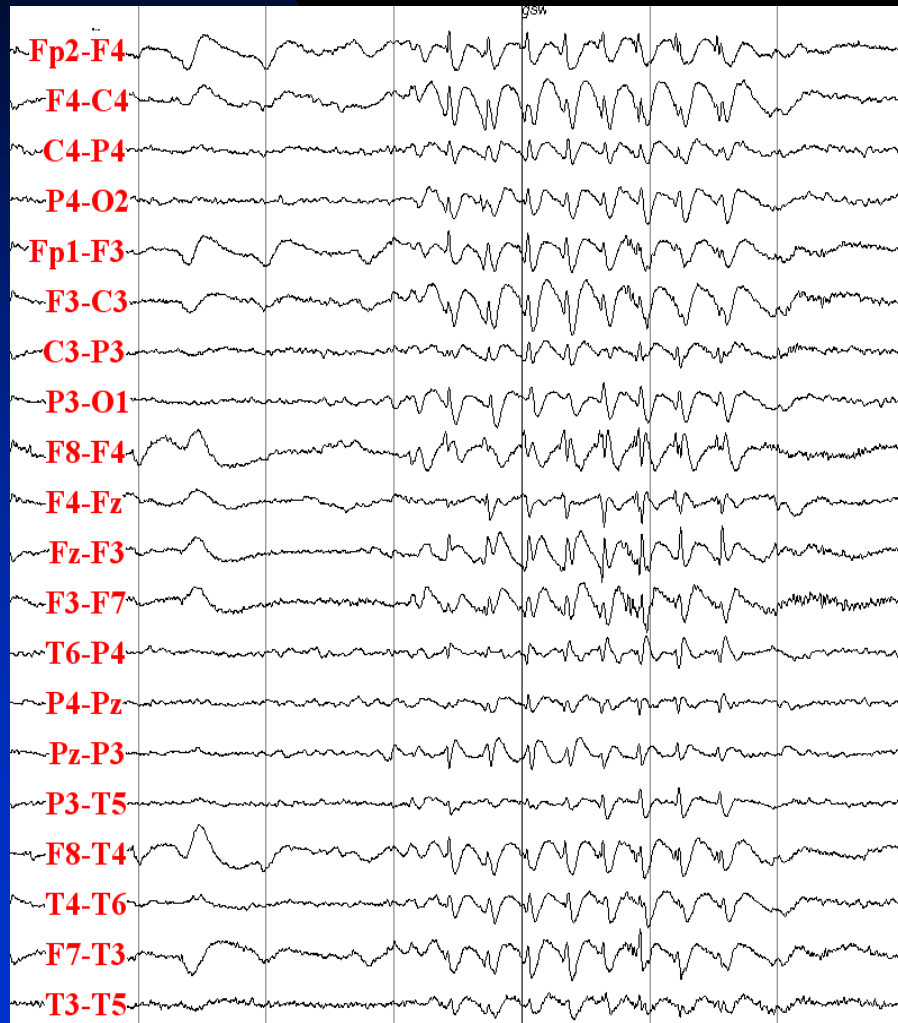
# Idiopathic (Genetic) Generalized Epilepsy

## (Juvenile Myoclonic Epilepsy)

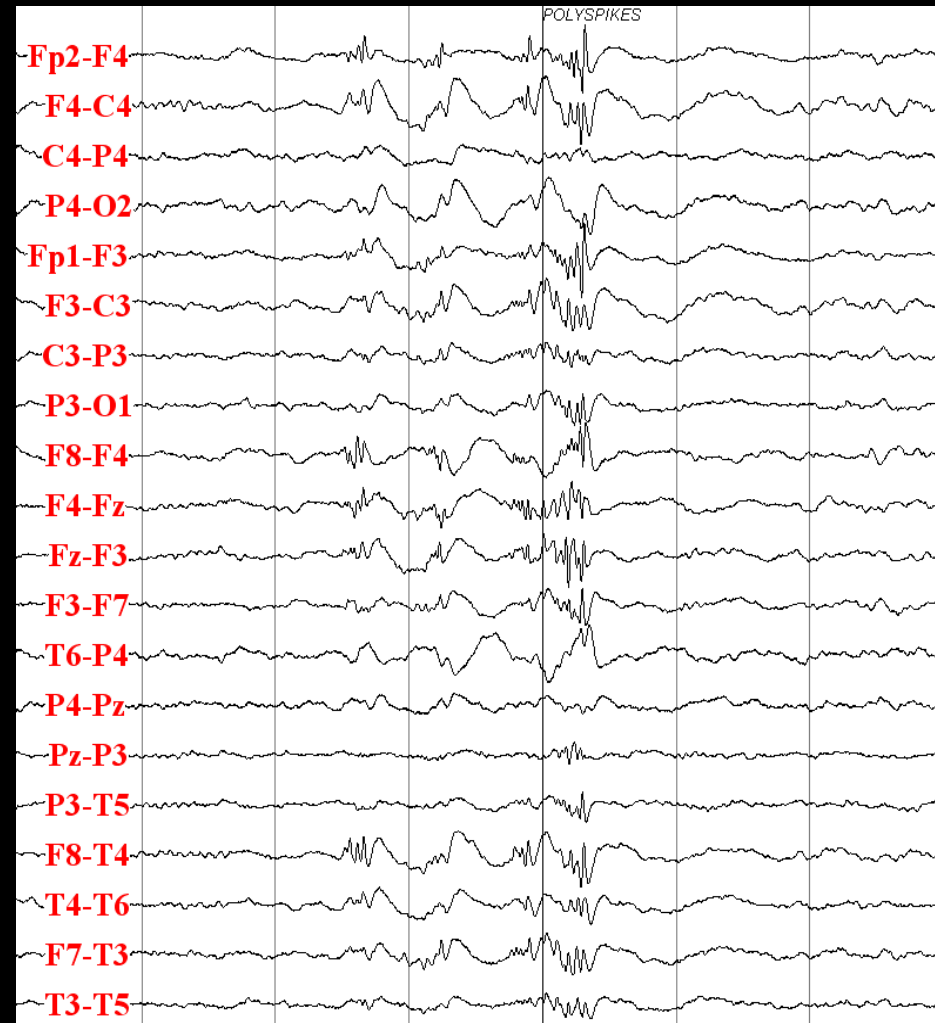
- 22-year old right-handed woman with seizures
- Risk factor: epilepsy (generalized tonic-clonic seizures) in mother
- Neurological examination: normal
- Description of seizures: myoclonic jerks associated with dropping objects in the morning, occasional staring spells, and rarely generalized tonic-clonic seizures
- Semiology (video-EEG monitoring): myoclonic jerks in both arms at the time of polyspikes and absence seizure at the time of prolonged 3 Hz spike-wave complexes
- MRI: normal
- Interictal EEG: generalized polyspike-waves and spike-waves
- Ictal EEG: polyspike-waves associated with myoclonic jerks, and 3-3.5 Hz spike-wave complexes associated with absence seizures

# Interictal Epileptiform Discharges

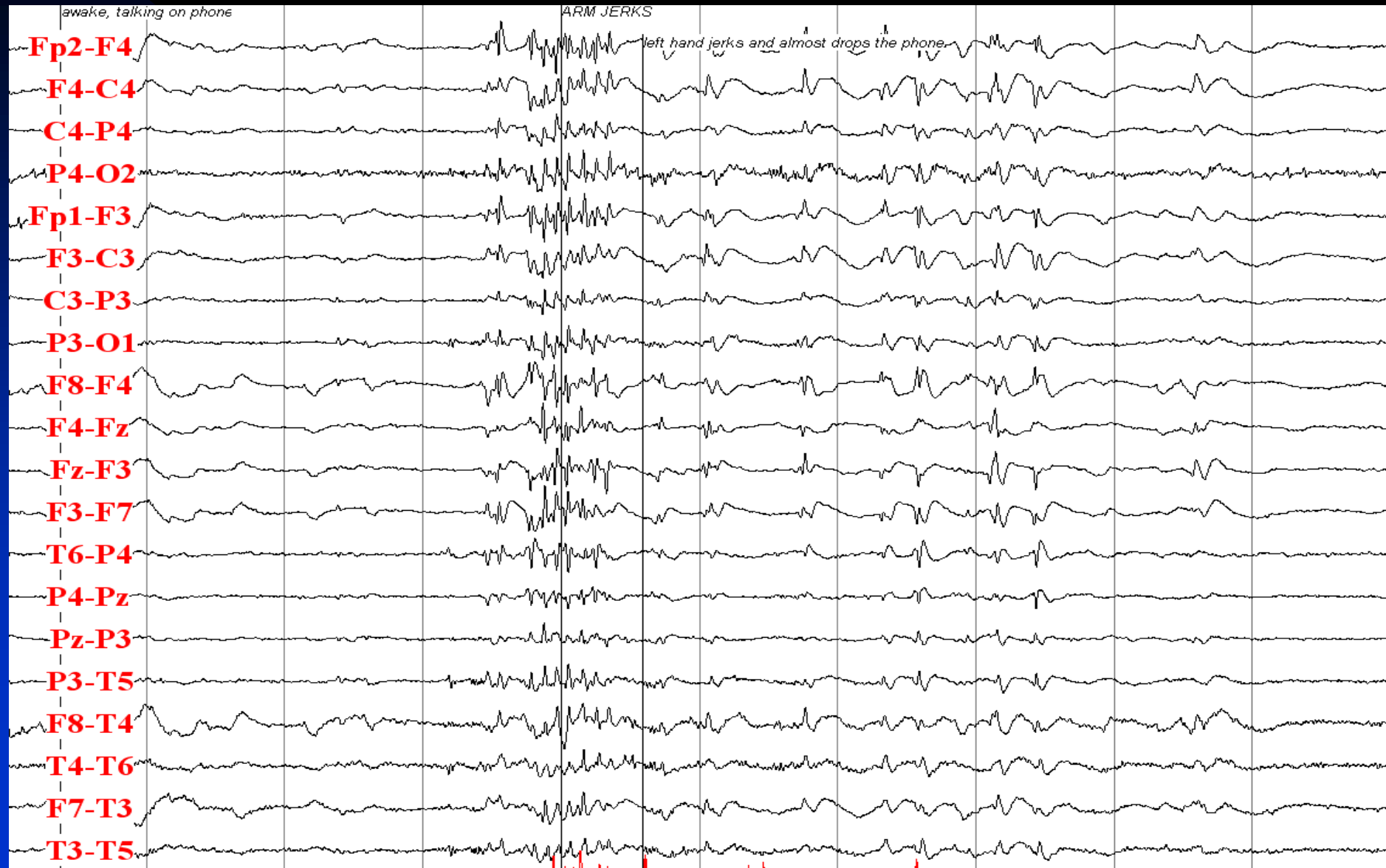
## Generalized 3 Hz spike-Waves



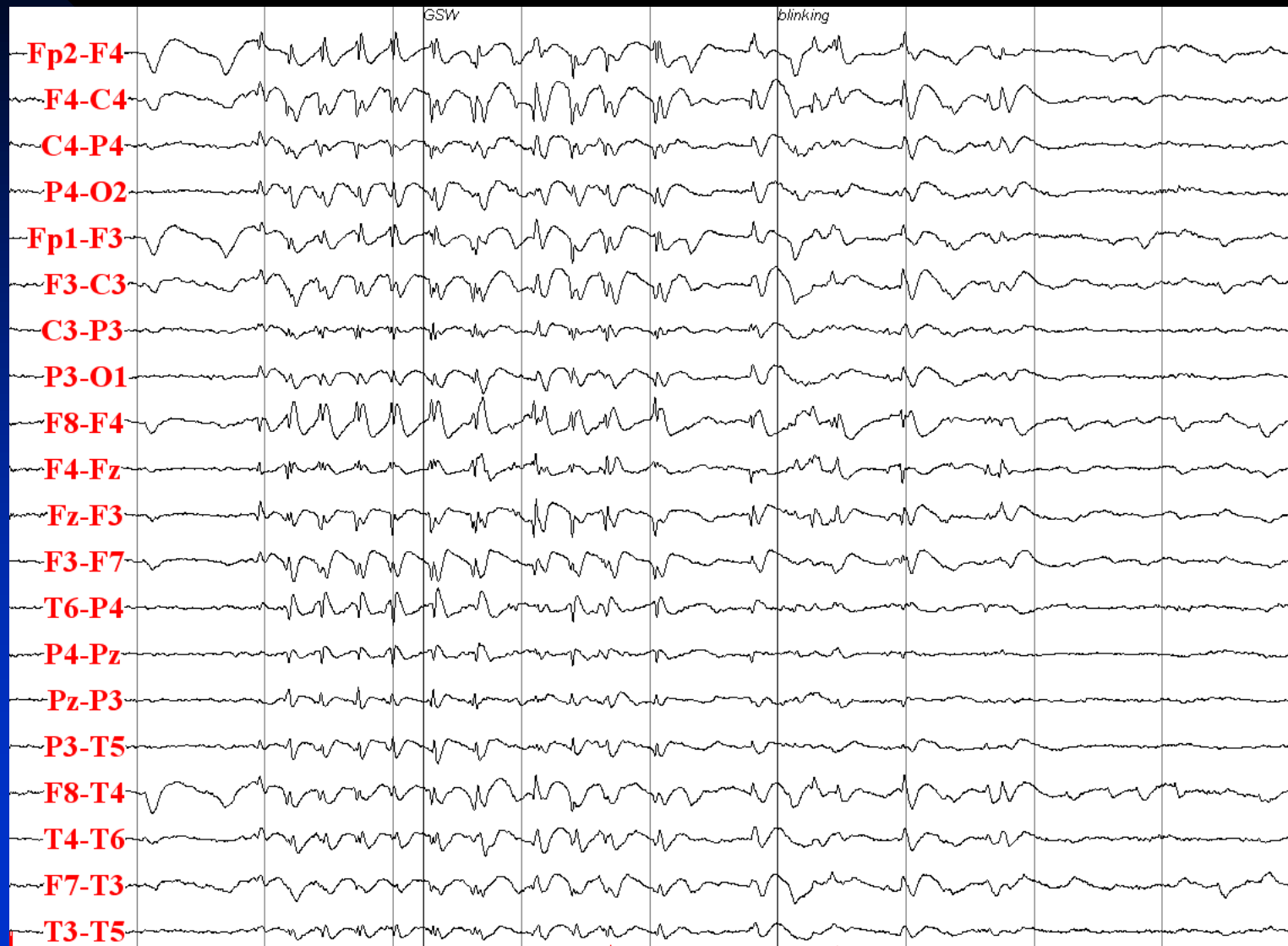## Polyspikes and Wave



# Polyspikes Associated with Myoclonic Seizure



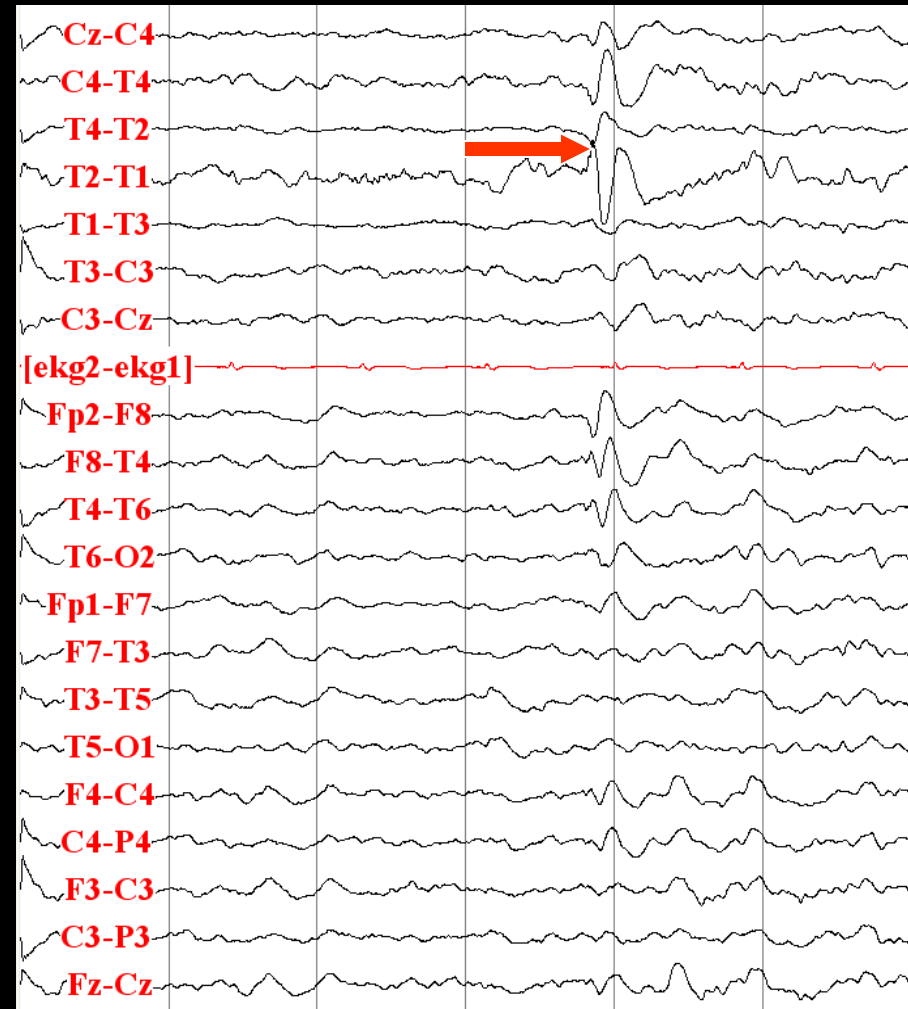
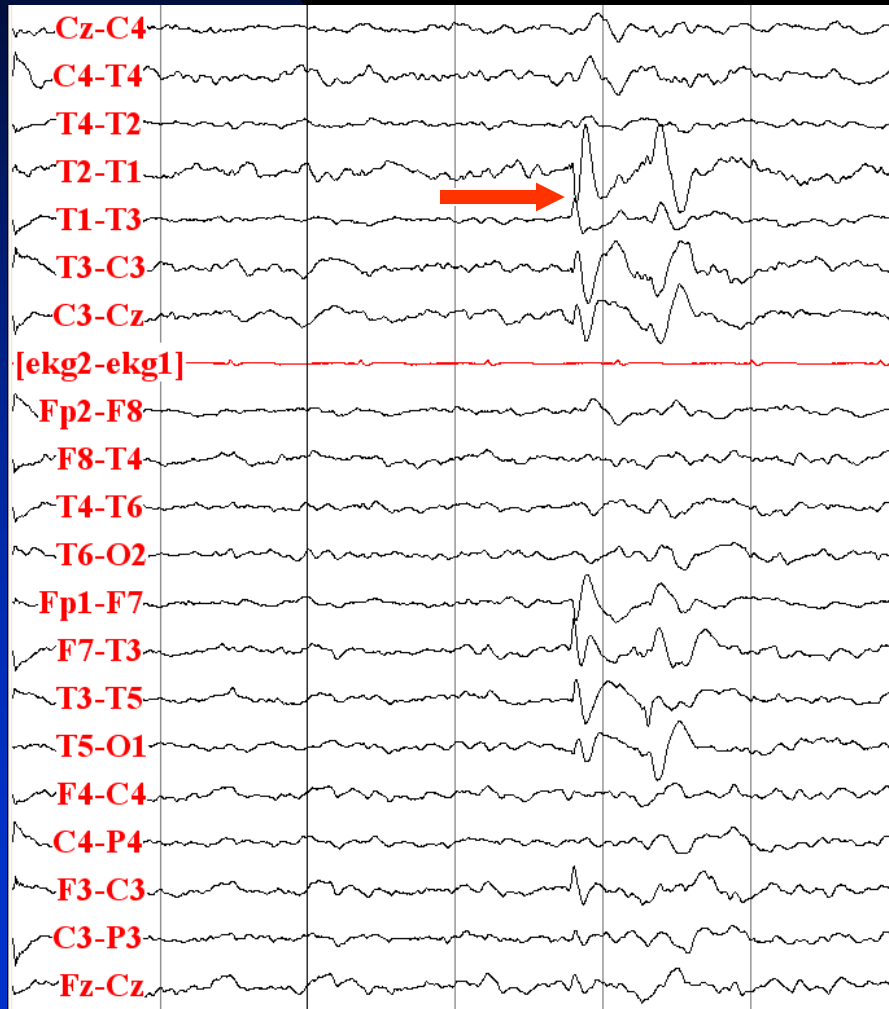
# 3.5 Hz Generalized Spike-Waves, Associated with Absence Seizure



# Temporal Lobe Epilepsy

- 32-year old right-handed man with 7-year history of seizures
- Risk factor: epilepsy in paternal grandfather
- Neurological examination: normal
- Description of seizures: odd feeling in body, followed by tingling of right upper and lower extremities, inability to move, loss of consciousness and falling
- Semiology (video-EEG monitoring): loss of responsiveness and staring, then right hand dystonic posture, eyes to left, clonic movements of arms and jaws
- MRI: normal
- Interictal EEG: independent right and left anterior temporal sharp waves (50:50)
- Ictal EEG: rhythmic delta in left temporal channels (T1 and T3 isoelectric), evolving with increase in amplitude and frequency and then spread to the right side 12 seconds after the onset

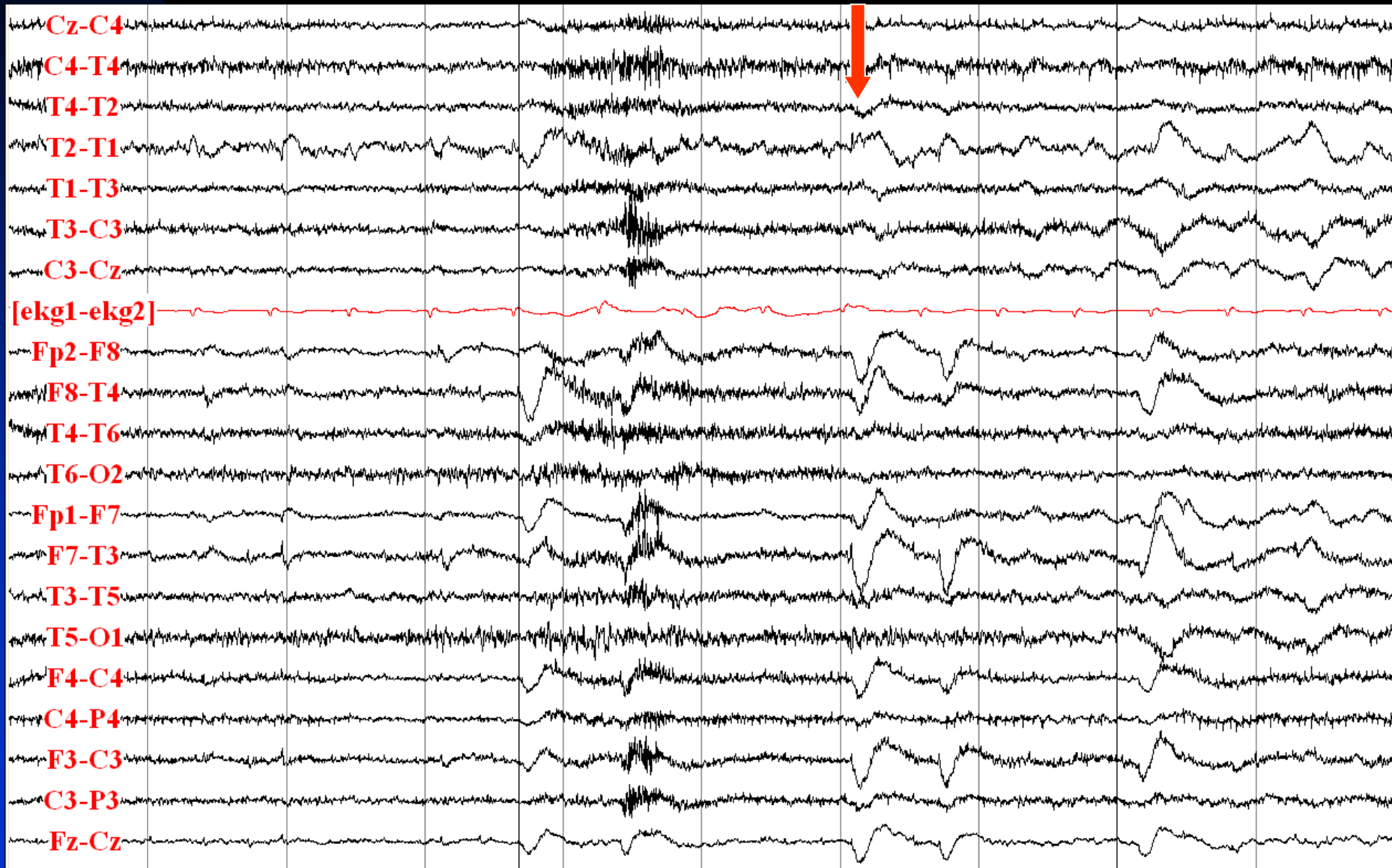
# Interictal: T1 and T2 Sharp Waves





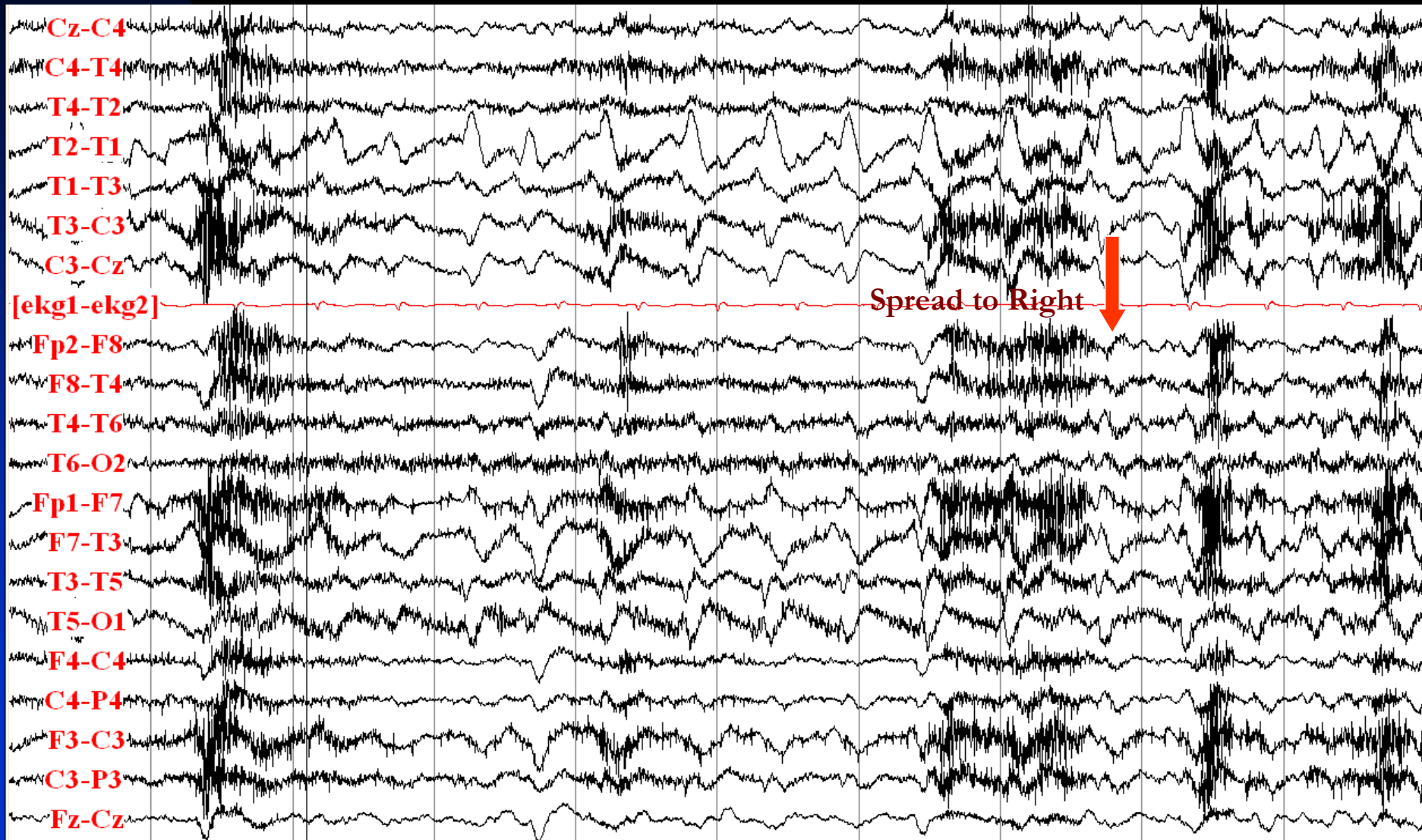
# Left Temporal Seizure Onset: Rhythmic Delta Activity

## in Left Temporal Region, Isoelectric at T1-T3

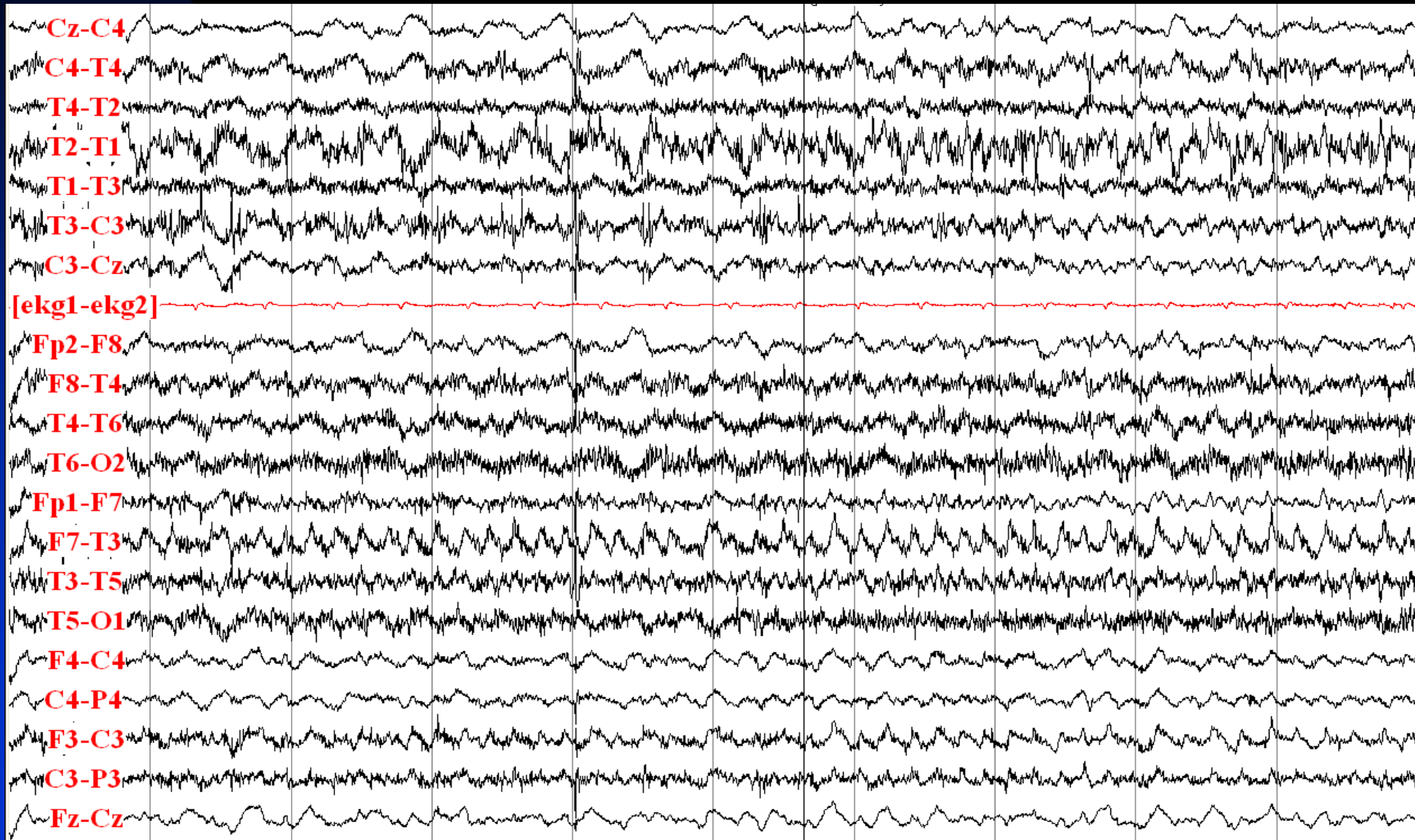




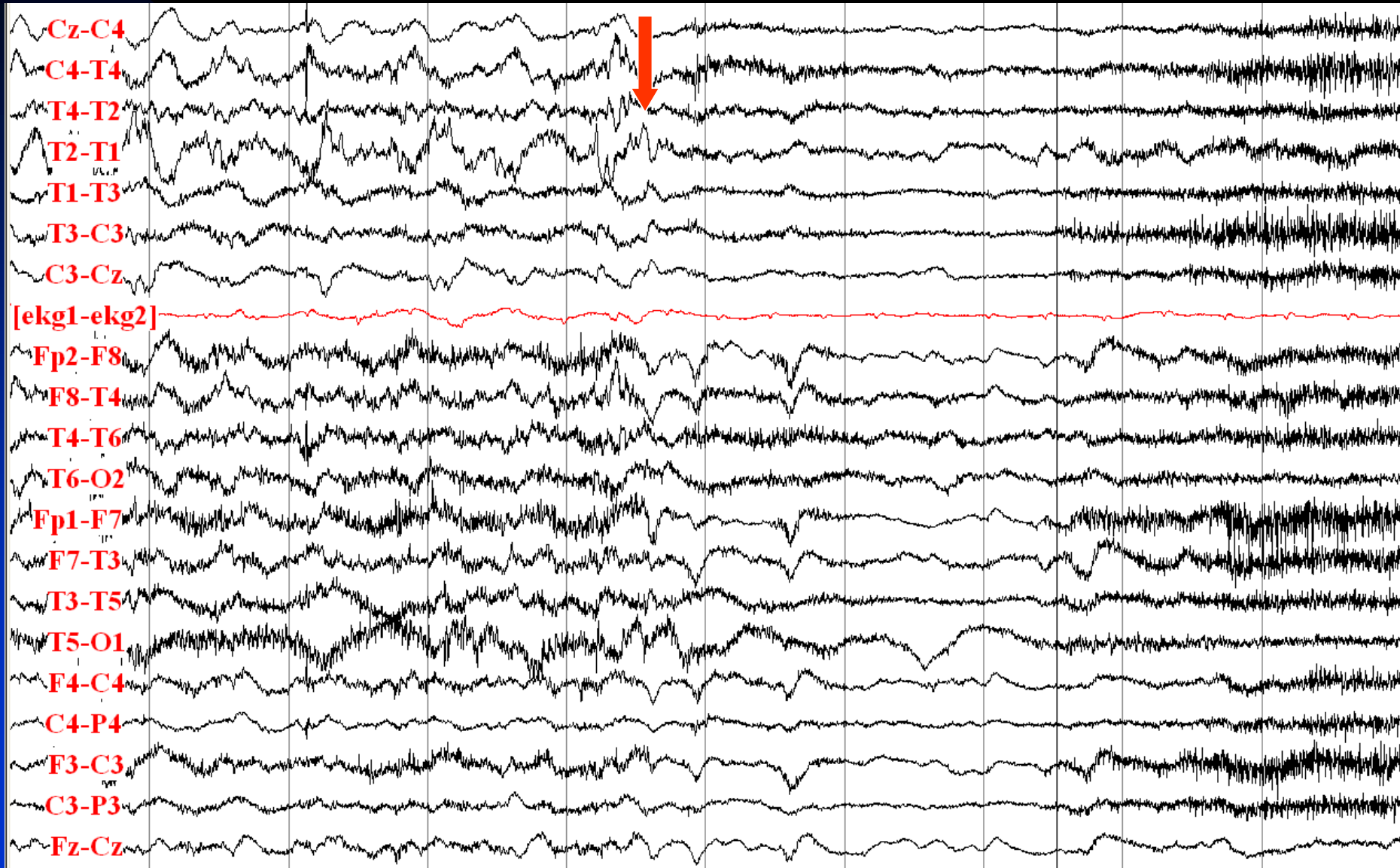
# Left Temporal Seizure Evolution and Spread: Increase in Amplitude and Frequency of Delta Activity; Later, Spread to the Right Side



# Left Temporal Seizure Evolution and Spread: Different Frequency Activities on Right and Left Sides



# Left Temporal Seizure Ends: Postictal Diffuse Attenuation

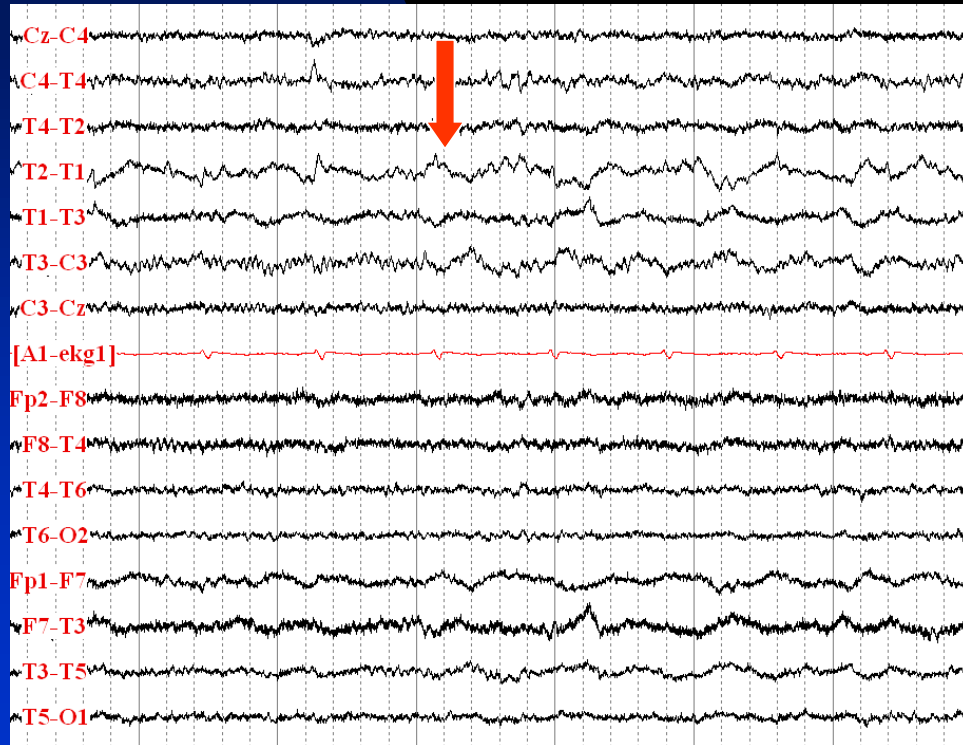


# Temporal Lobe Epilepsy

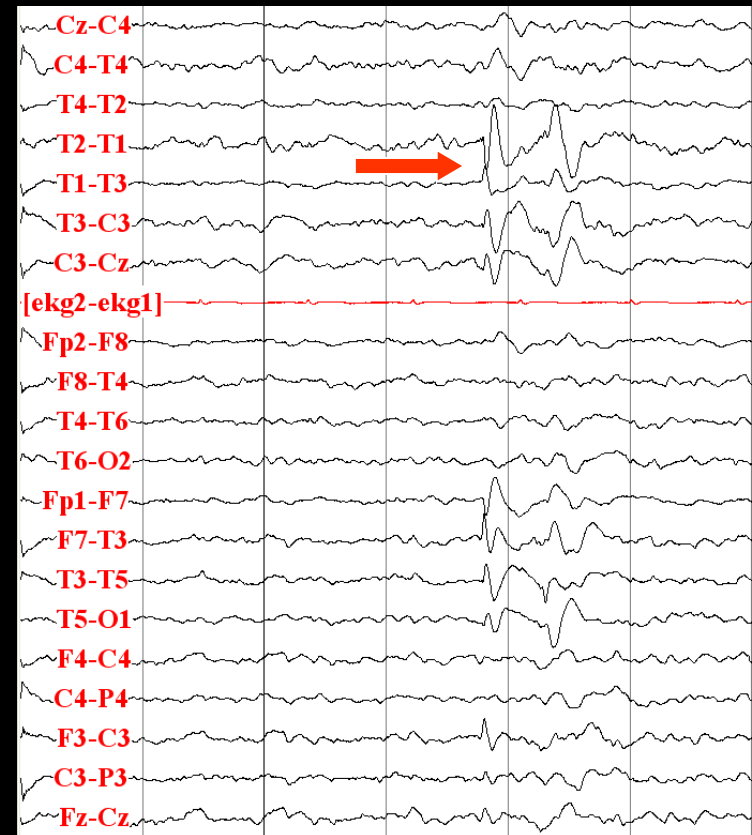
- 35-year old right-handed man with drug-resistant epilepsy since the age 14
- Risk factor: complex febrile seizure at age 4 years
- Neurological examination: normal
- Description of seizures: rising epigastric sensation, staring, mouth movements, right arm shaking, postictal confusion
- Semiology (video-EEG monitoring): aura, staring, unresponsiveness and lip smacking, right arm clonic activity, postictal nose wiping with the left hand
- MRI: left mesial temporal sclerosis
- Interictal EEG: left anterior temporal (T1) sharp waves and delta activity
- Ictal EEG: T1/T3 rhythmic theta activity, evolution to 6 Hz spiky activity at T1 and spread to the right side, with postictal diffuse attenuation

# Interictal EEG

## T1 Delta Activity

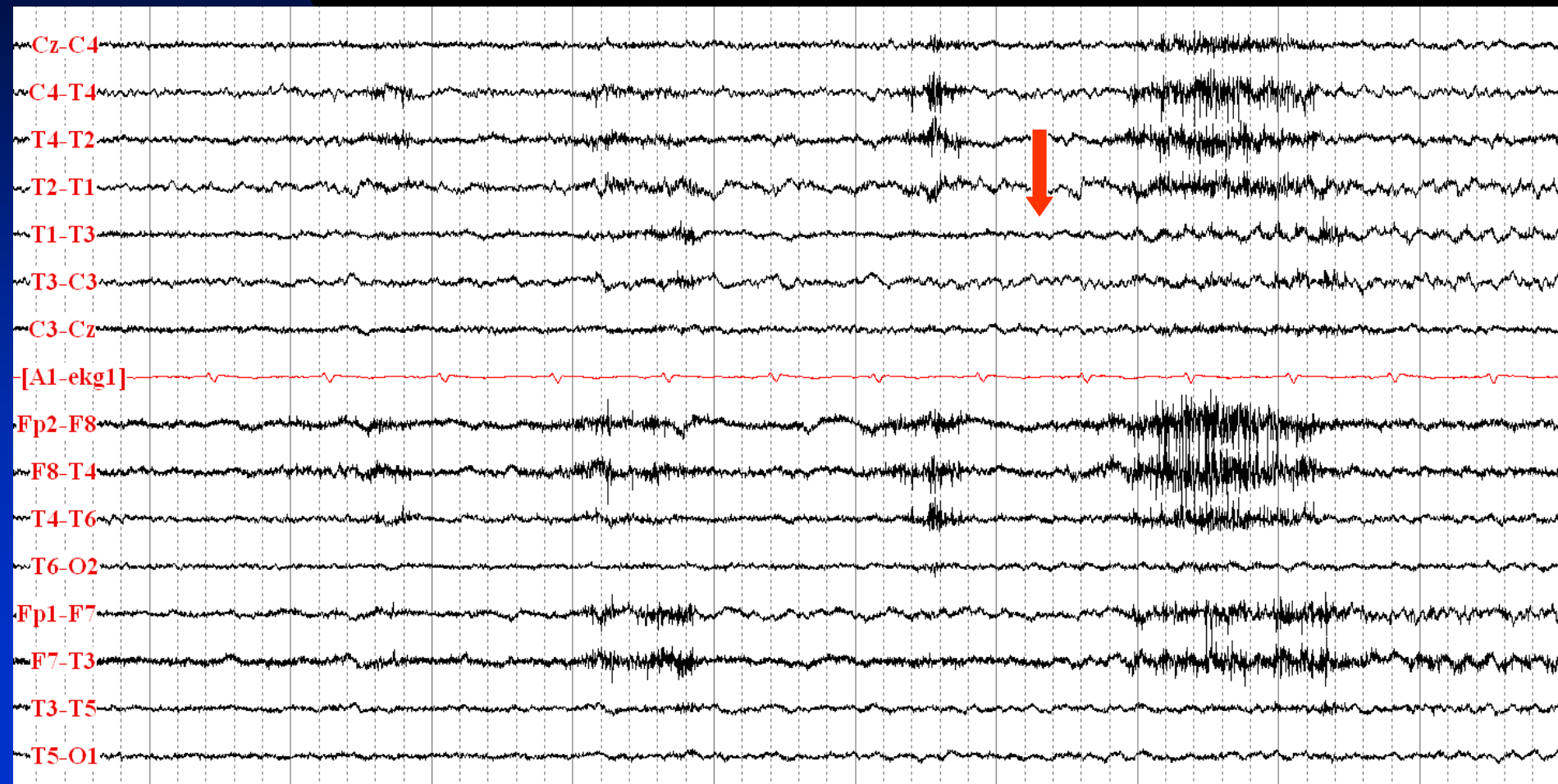


## T1 Sharp Wave

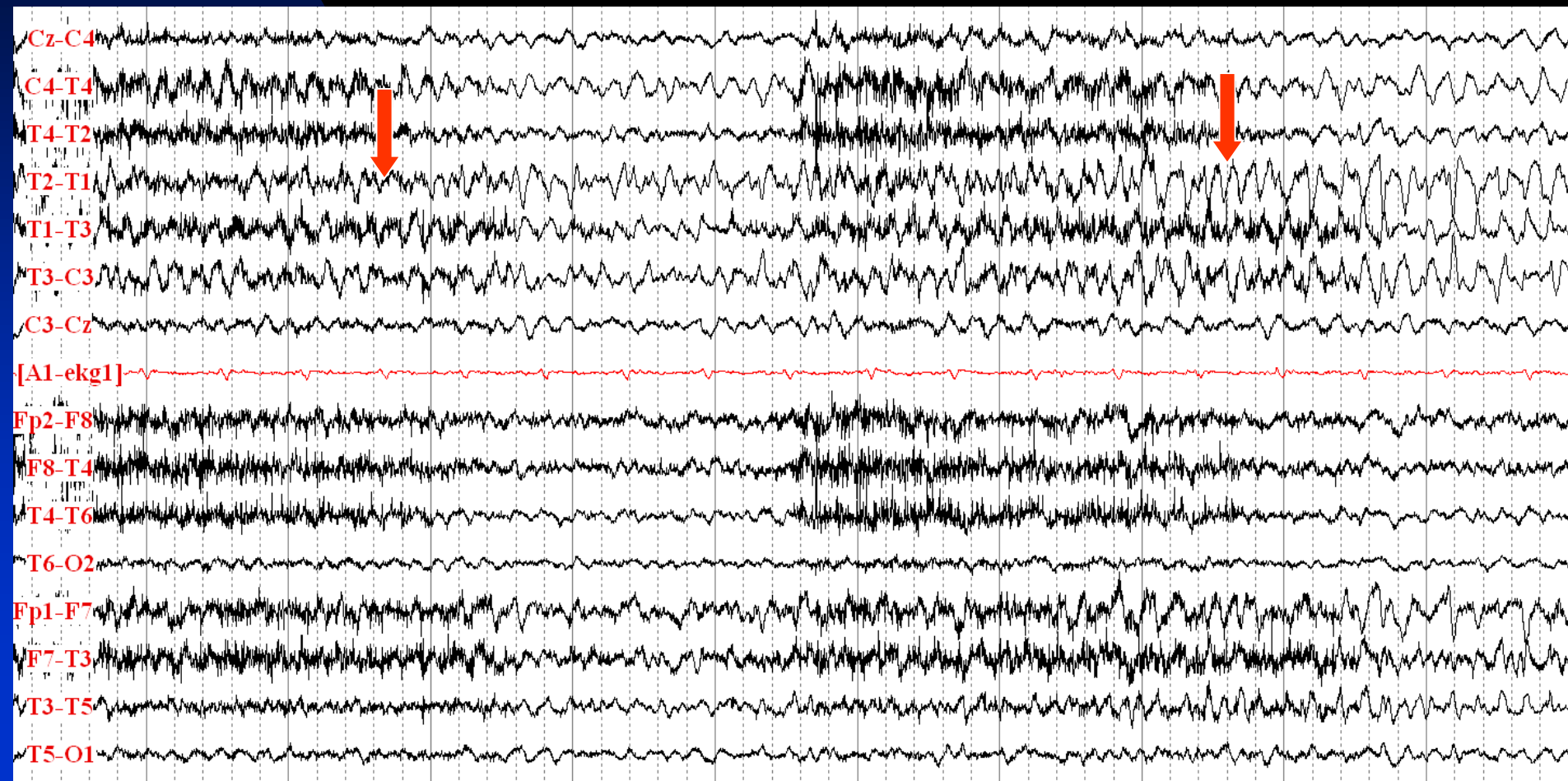




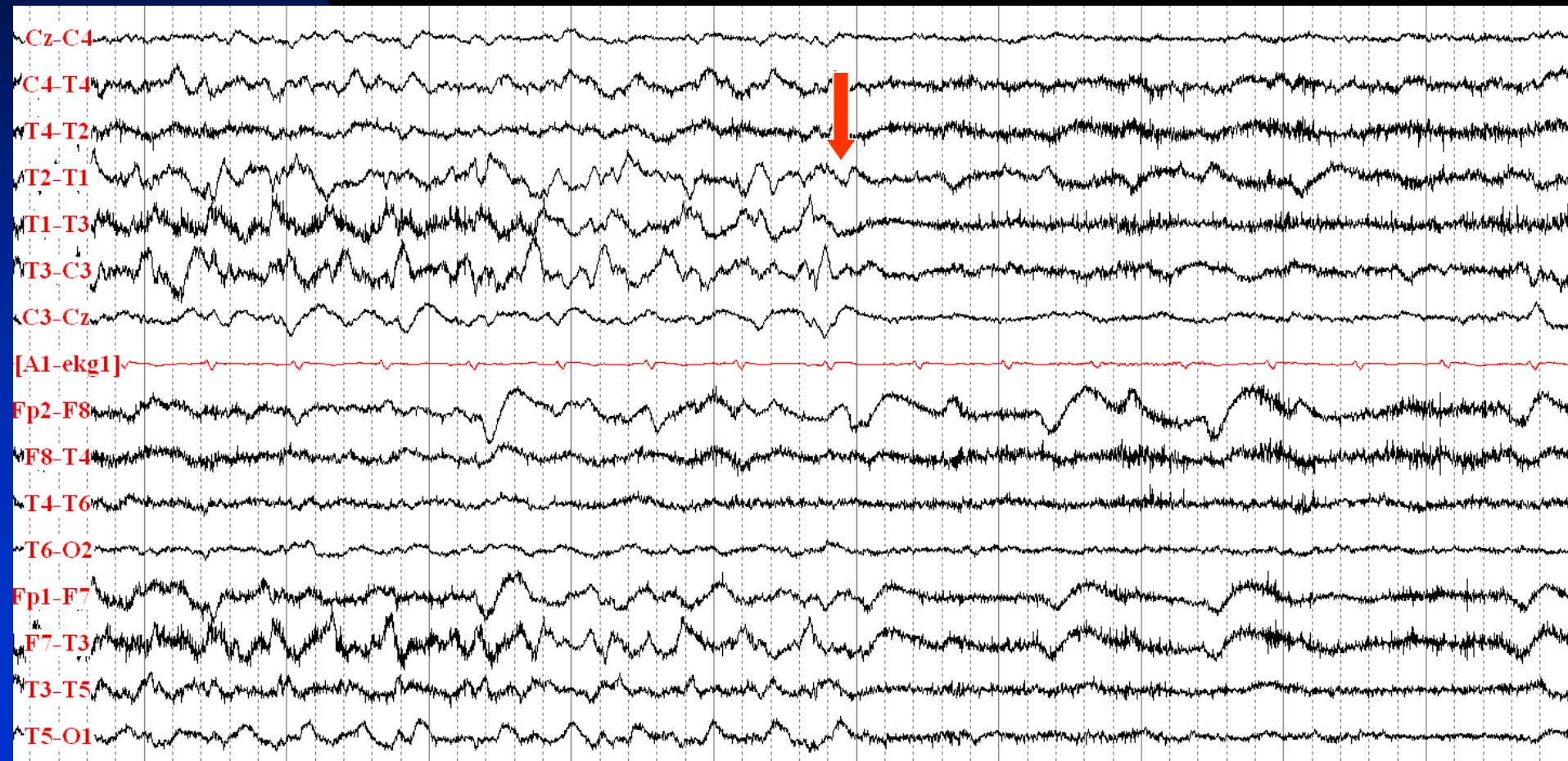
# Ictal Onset: T1/T3 Rhythmic Theta Activity



# Evolution of Ictal Activity to 6 Hz Spiky Activity at T1 and Spread to the Right Side



# Seizure Ends with Postictal Diffuse Attenuation

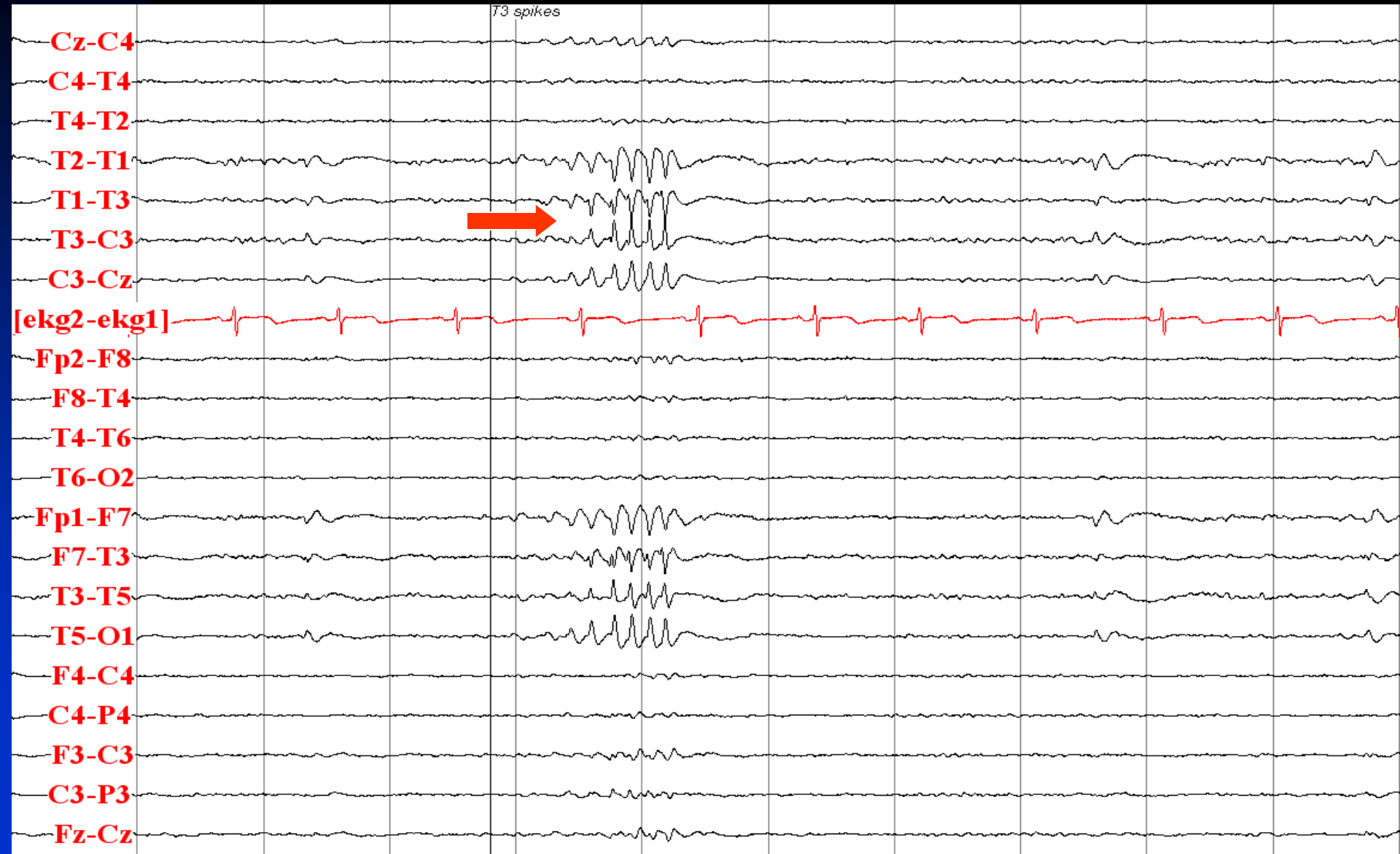




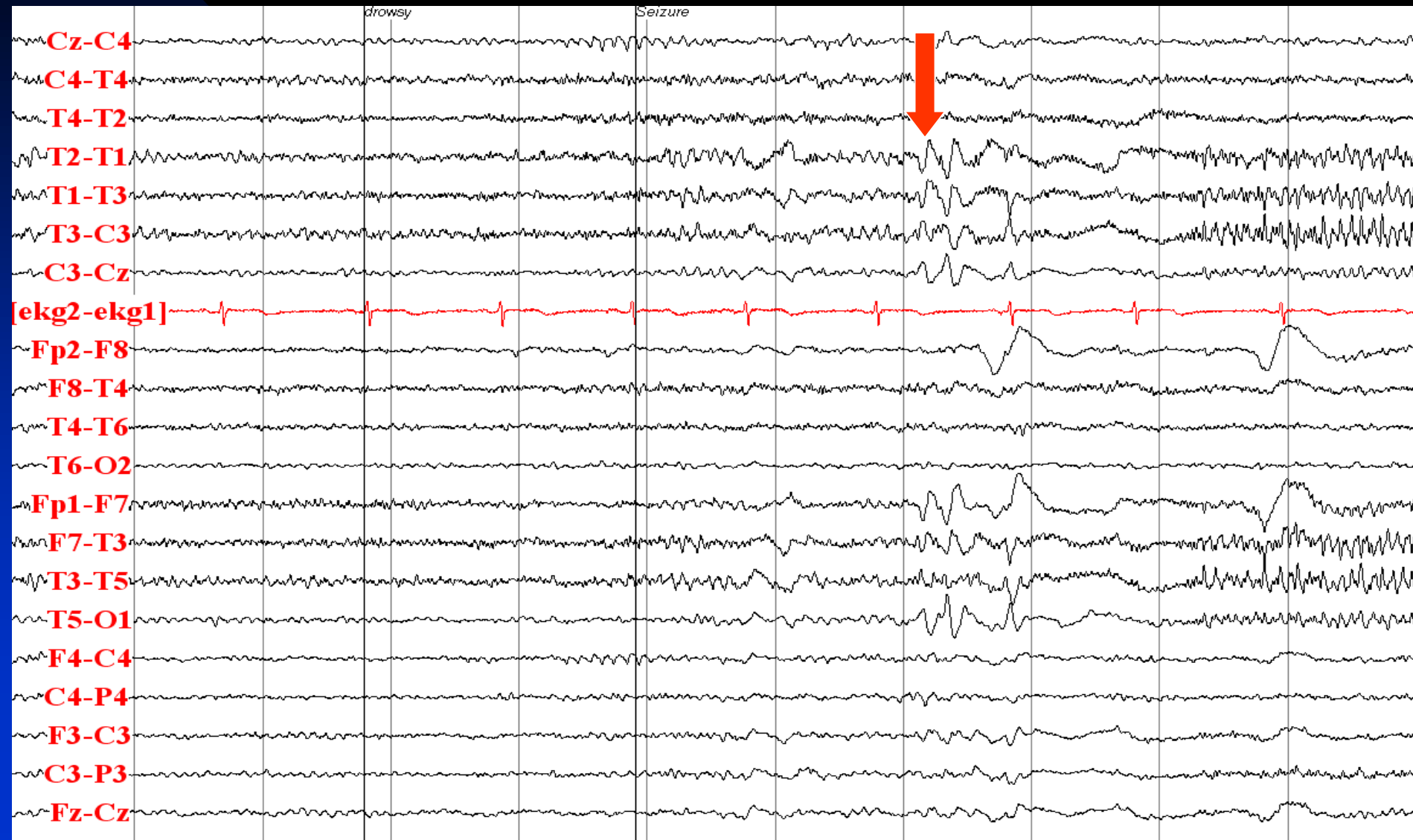# Temporal Lobe Epilepsy

- 45-year old right-handed woman with seizures since the age 14
- Risk factor: complex febrile seizure at 2 years of age
- Neurological examination: normal
- Description of seizures: rising sensation in stomach, followed by loss of consciousness for about one minute, postictal confusion
- Semiology (video-EEG monitoring): aura, unresponsiveness, right hand dystonic and left hand automatism, postictal nose wiping with left hand
- MRI: normal
- Interictal EEG: left mid-temporal spikes
- Ictal EEG: seizure onset with sharply contoured rhythmic theta activity at T3, then diffuse attenuation of EEG activity followed by rhythmic spiky activity at T3, then evolution of rhythmic spiky activity at T3 without spread to other regions. Seizure ends with diffuse attenuation postictally

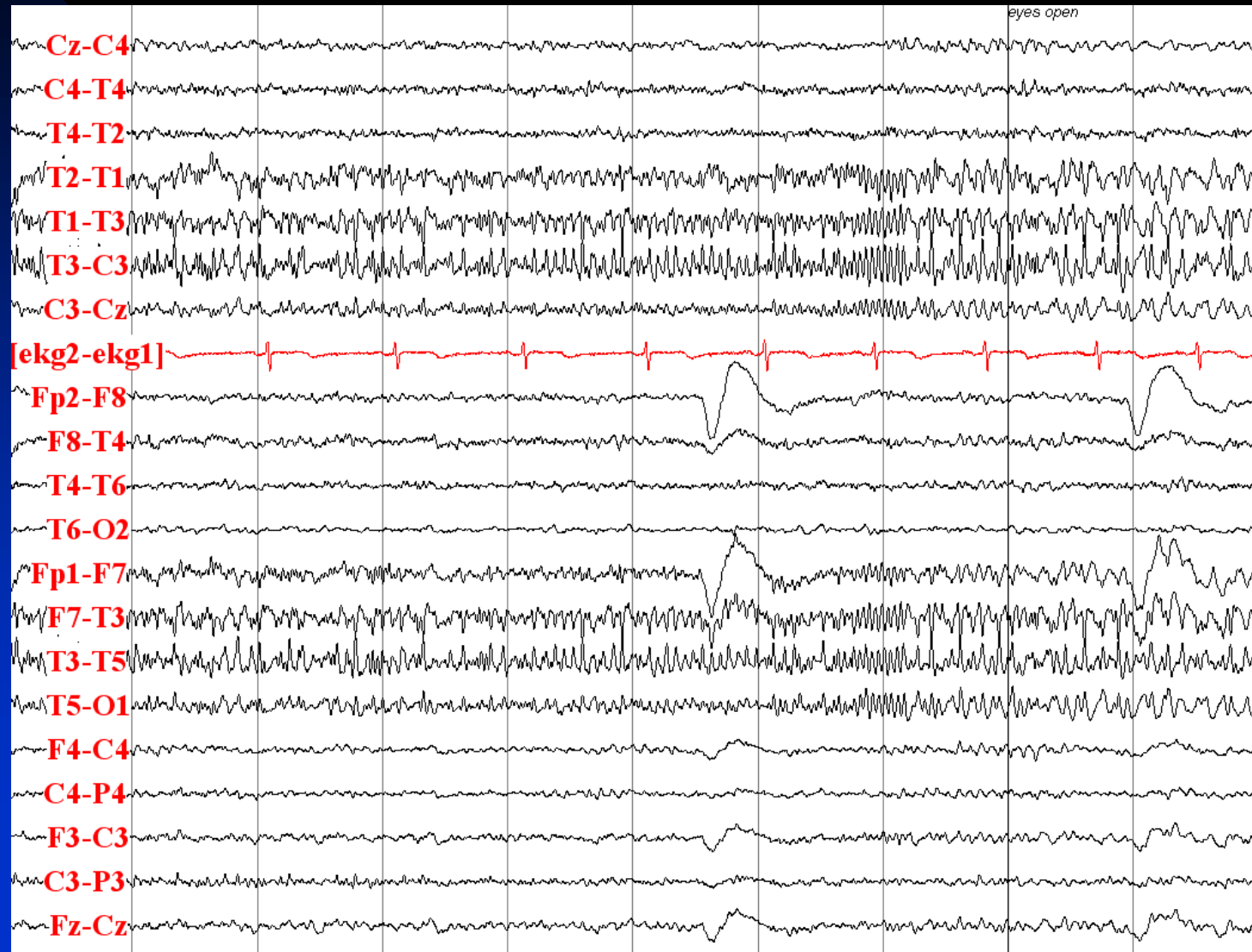
# Interictal: Run of T3 Spikes in Sleep



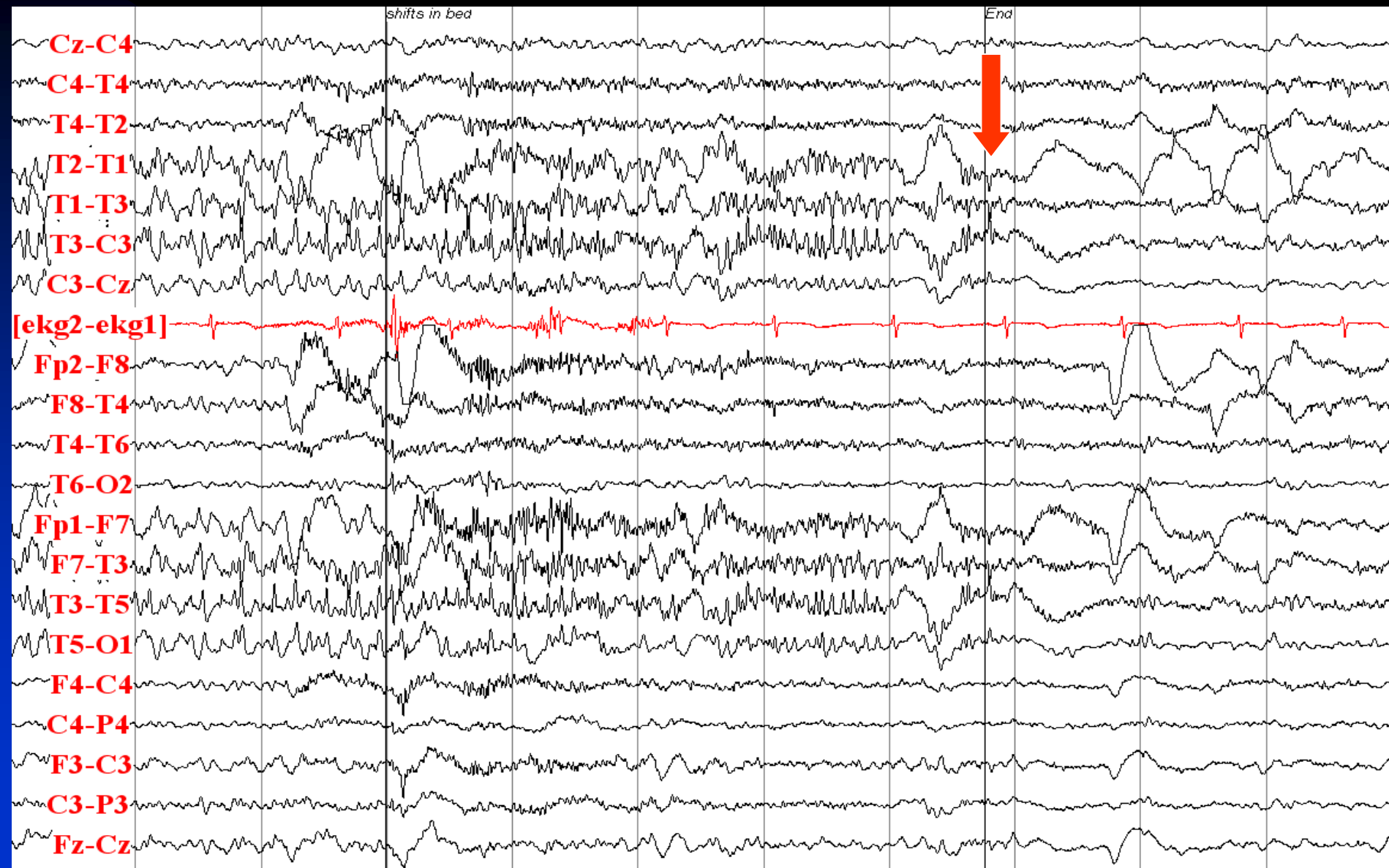# Seizure Onset with Sharply Contoured Rhythmic Theta Activity at T3, Then Diffuse Attenuation of EEG Activity Followed by Rhythmic Spiky Activity at T3



# Evolution of Rhythmic Spiky Activity at T3 without Contralateral Spread



# Seizure Ends with Diffuse Attenuation Postictally

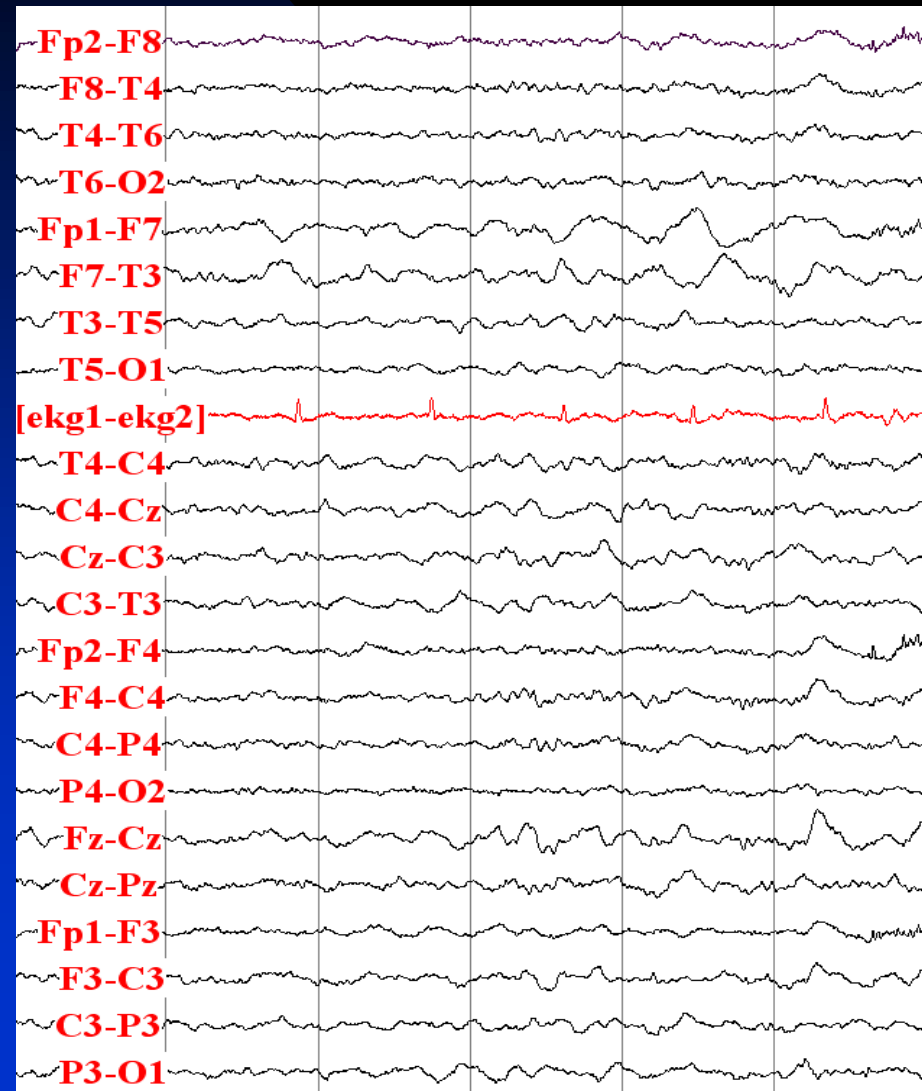


# Temporal Lobe Epilepsy

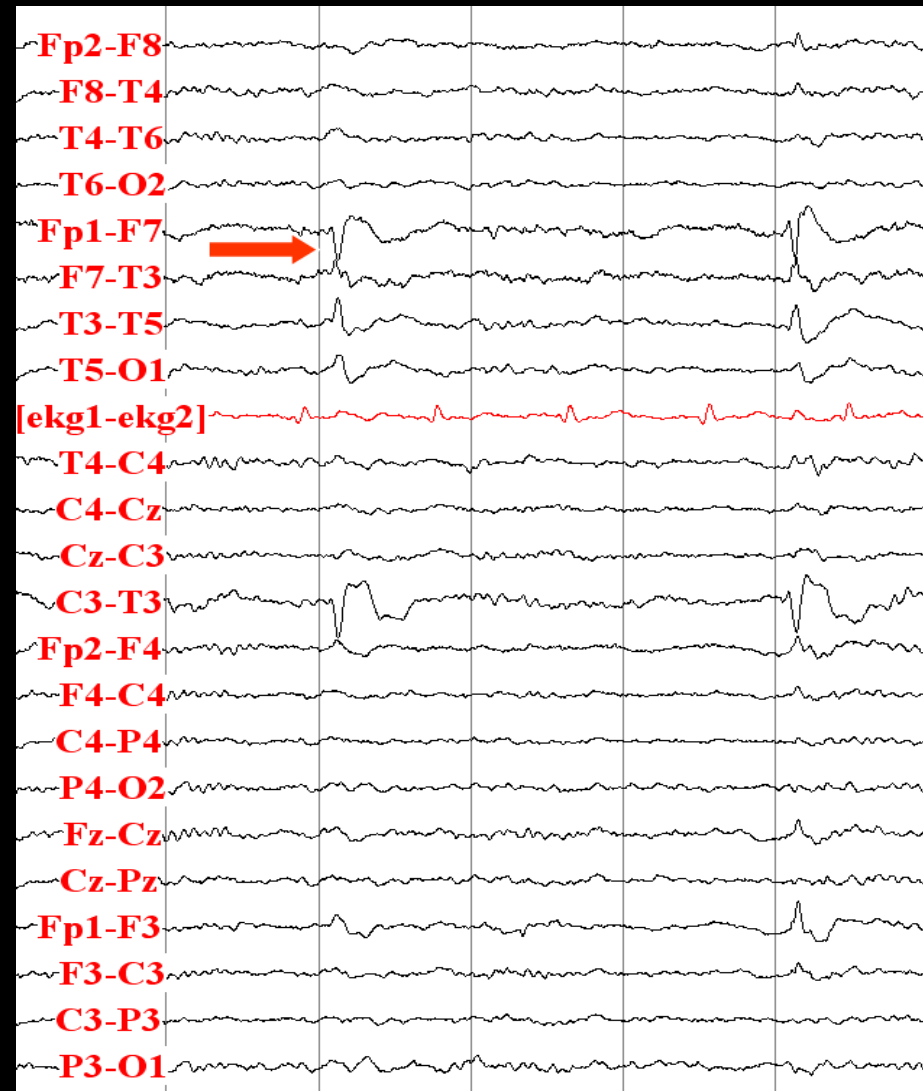
- 65-year old right-handed woman with epilepsy since the age 51
- Risk factor: stroke
- Neurological examination: normal
- Description of seizures: staring for one minute, occasionally leading to generalized tonic-clonic seizures
- Semiology (video-EEG monitoring): Sleep, arousal 9 seconds after electrographic seizure onset, staring, unresponsiveness and lip smacking, going to sleep again
- MRI: left temporal old infarction
- Interictal EEG: left anterior temporal sharp waves
- Ictal EEG: Diffuse attenuation of EEG activity, followed by F7/T3 rhythmic theta activity and minimal spread to the right side, with postictal diffuse attenuation

# Interictal EEG

## Continuous F7 Polymorphic Delta Activity

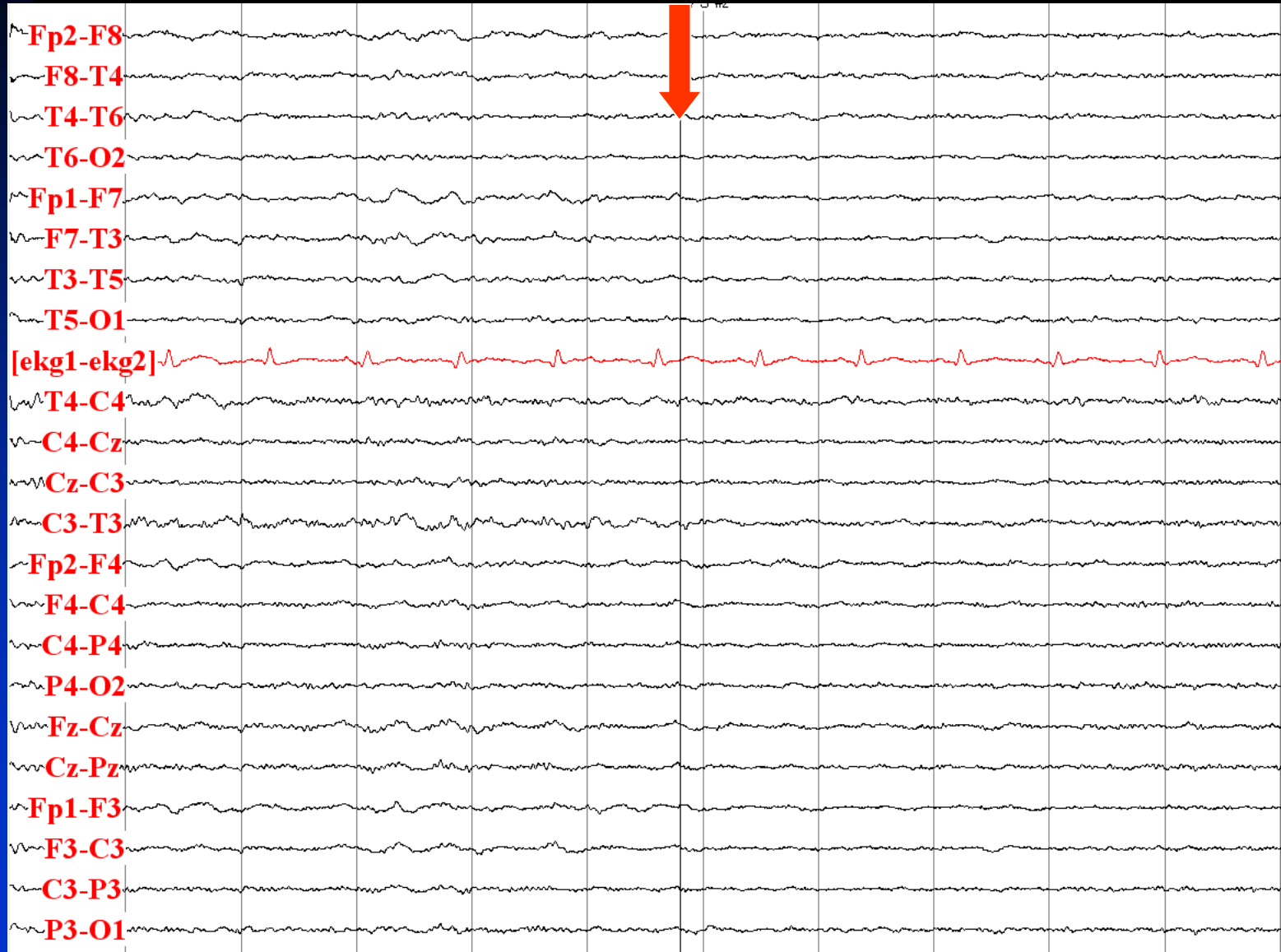


## F7 Sharp Waves



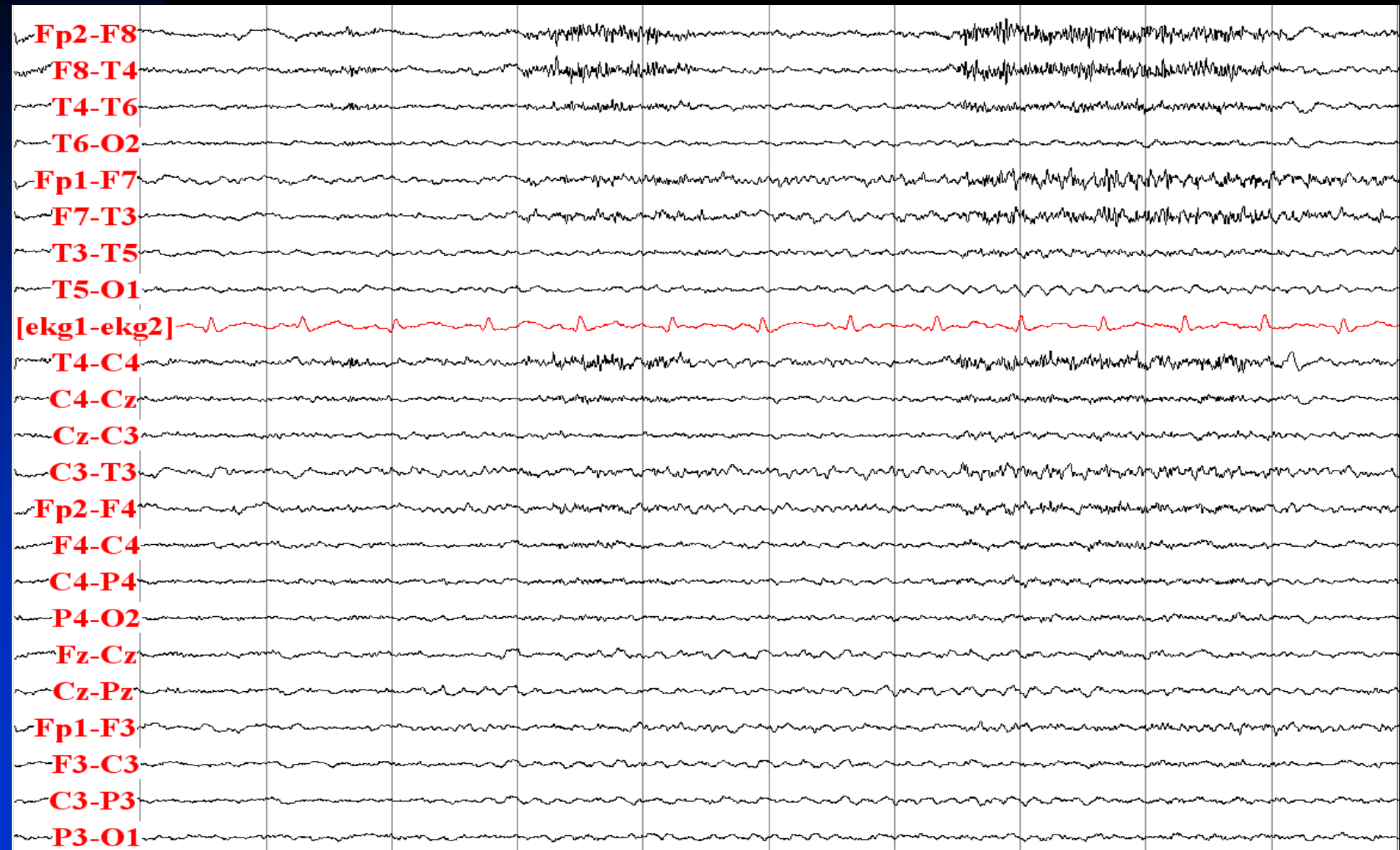


# Seizure Onset with Diffuse Attenuation of EEG Activity

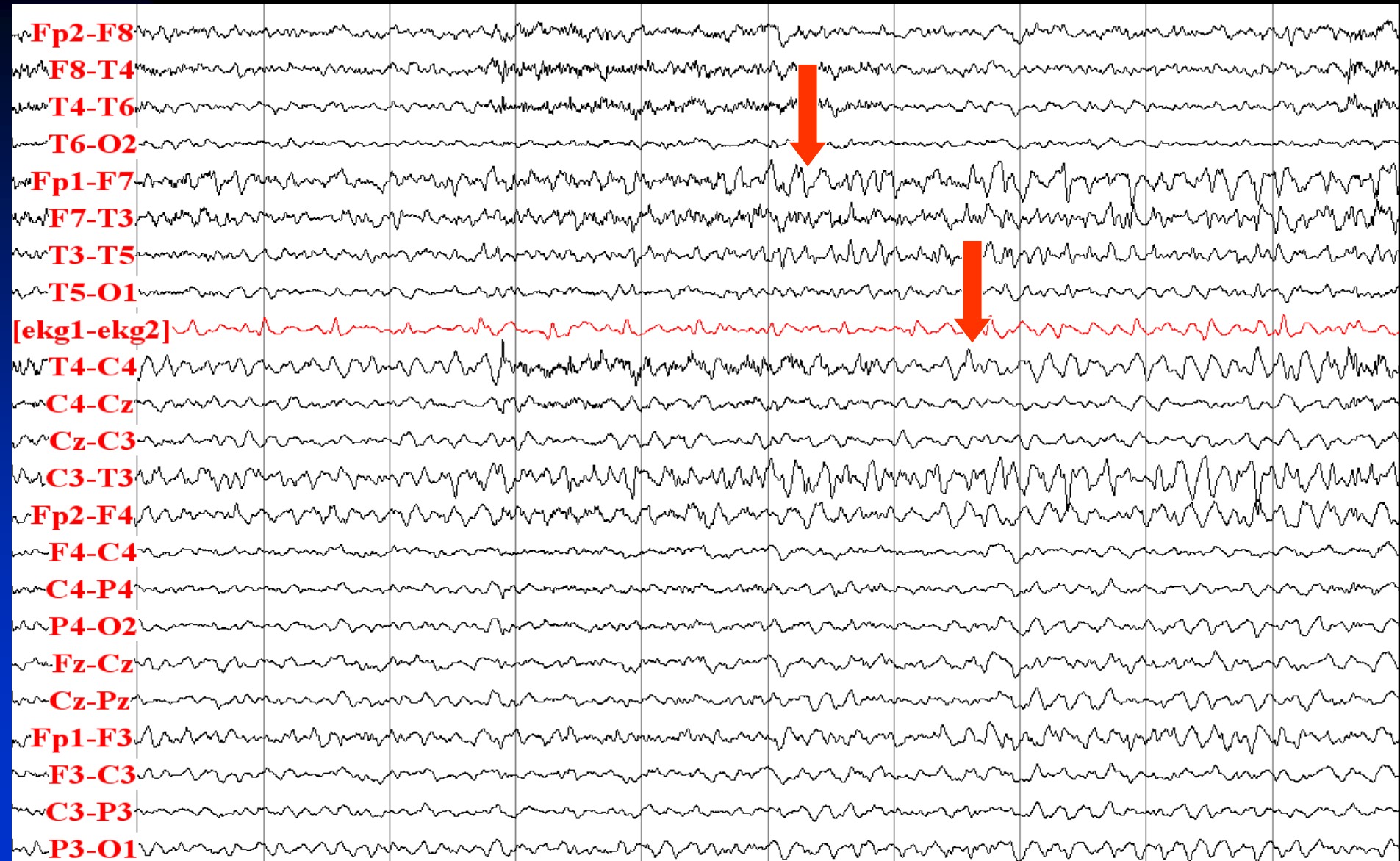




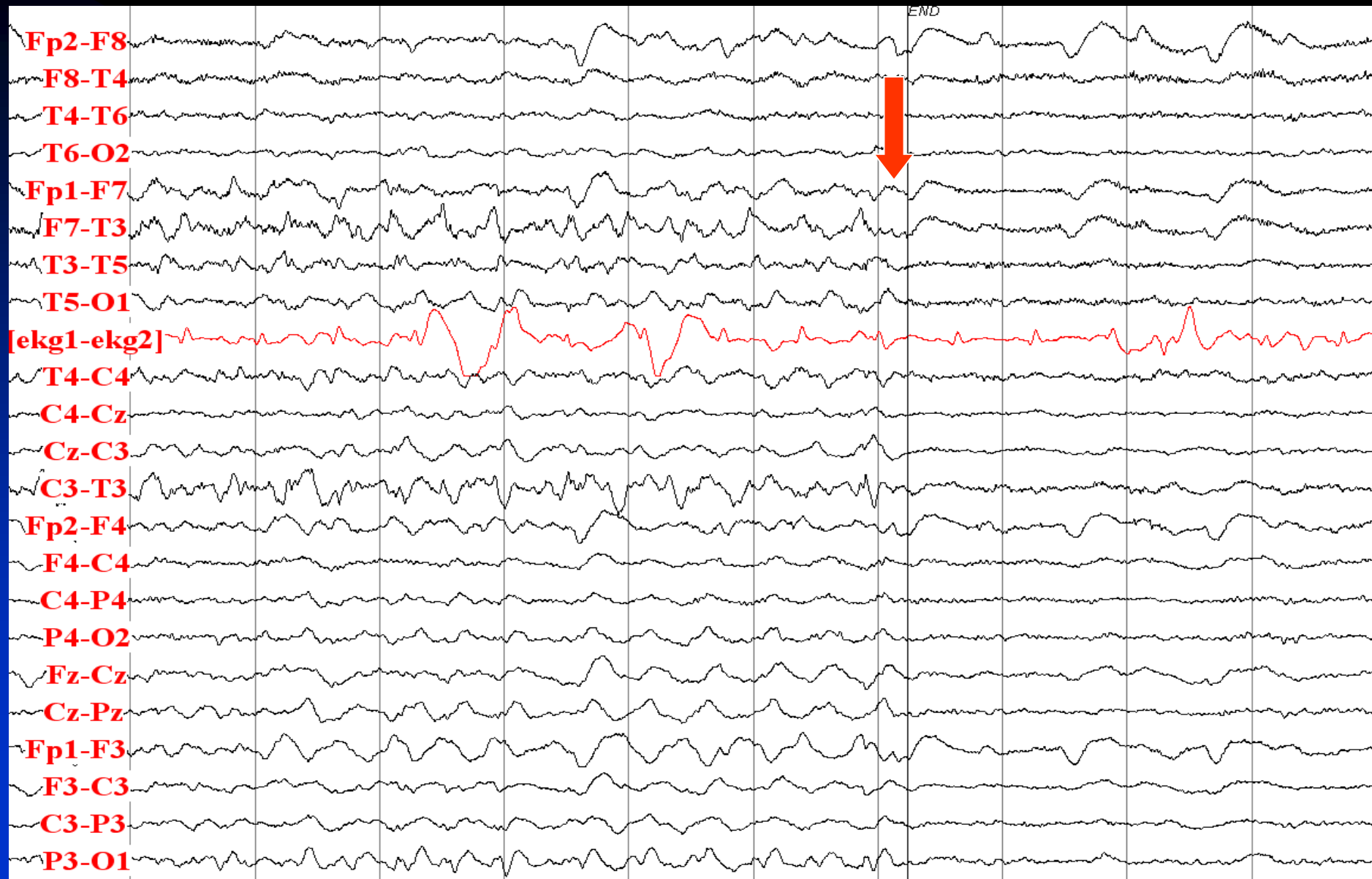
# Build Up of Rhythmic Theta Activity in Left Temporal Region



# F7-T3 Rhythmic Theta Activity with Spread to the Right Side



# Seizure Ends with Diffuse Attenuation

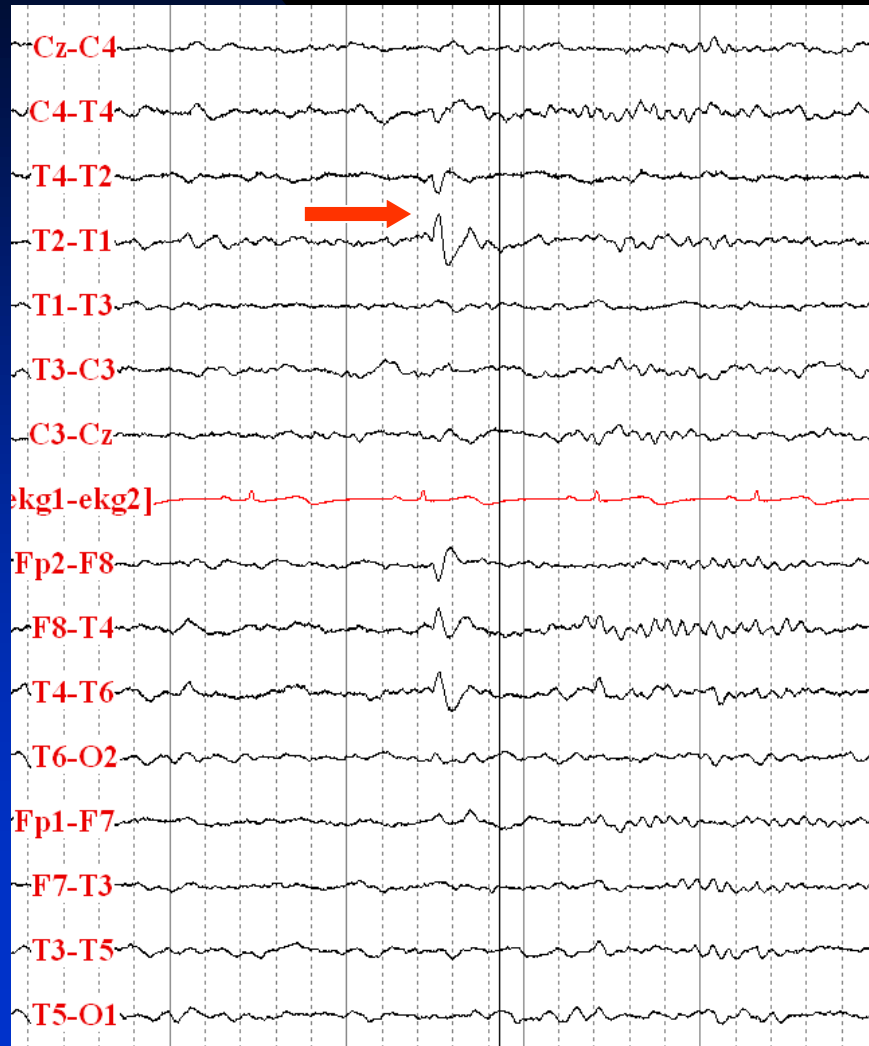


# Temporal Lobe Epilepsy

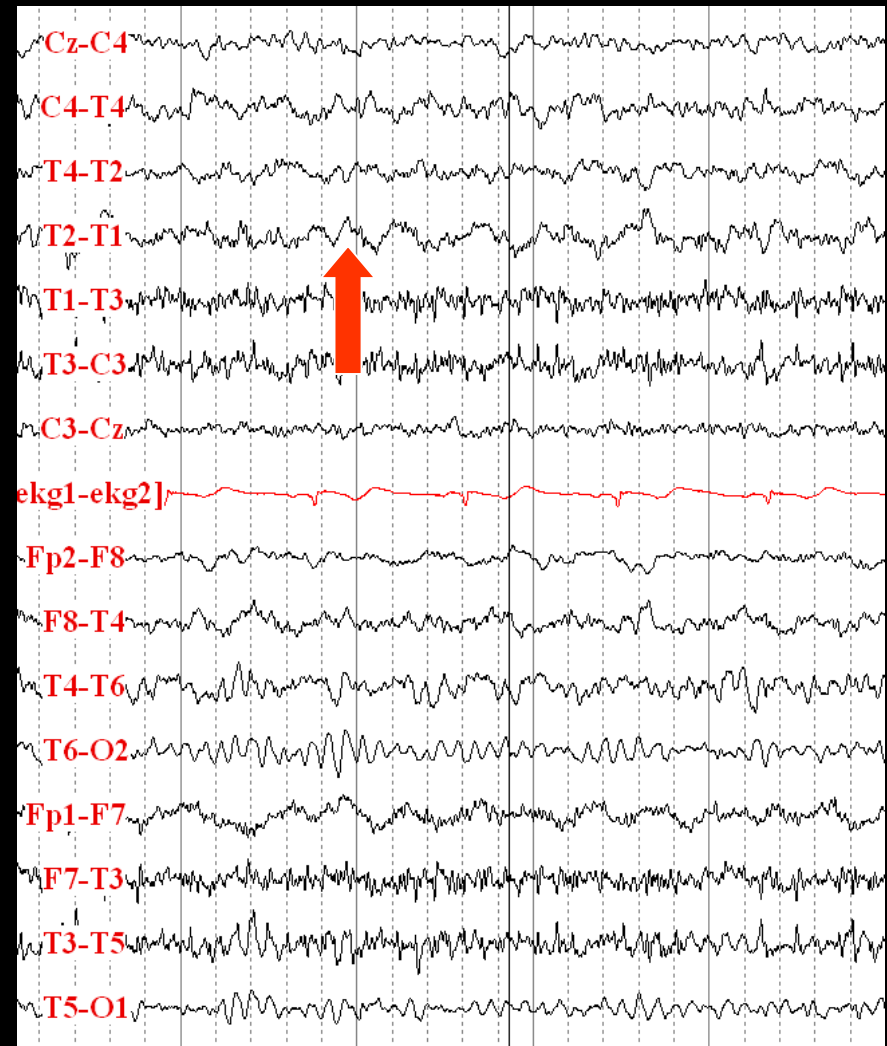
- 21-year old right-handed woman with epilepsy since the age 18
- Risk factor: none
- Neurological examination: normal
- Description of seizures: fearful warning, lip smacking, staring for one minute while looks very frightened, occasionally leading to generalized tonic-clonic seizures
- Semiology (video-EEG monitoring): aura, lip smacking, staring for one minute while looks very frightened, postictal amnesia and confusion
- MRI: right hippocampal sclerosis
- Interictal EEG: right anterior temporal sharp waves and delta activity
- Ictal EEG: right temporal rhythmic delta activity with evolution

# Interictal EEG

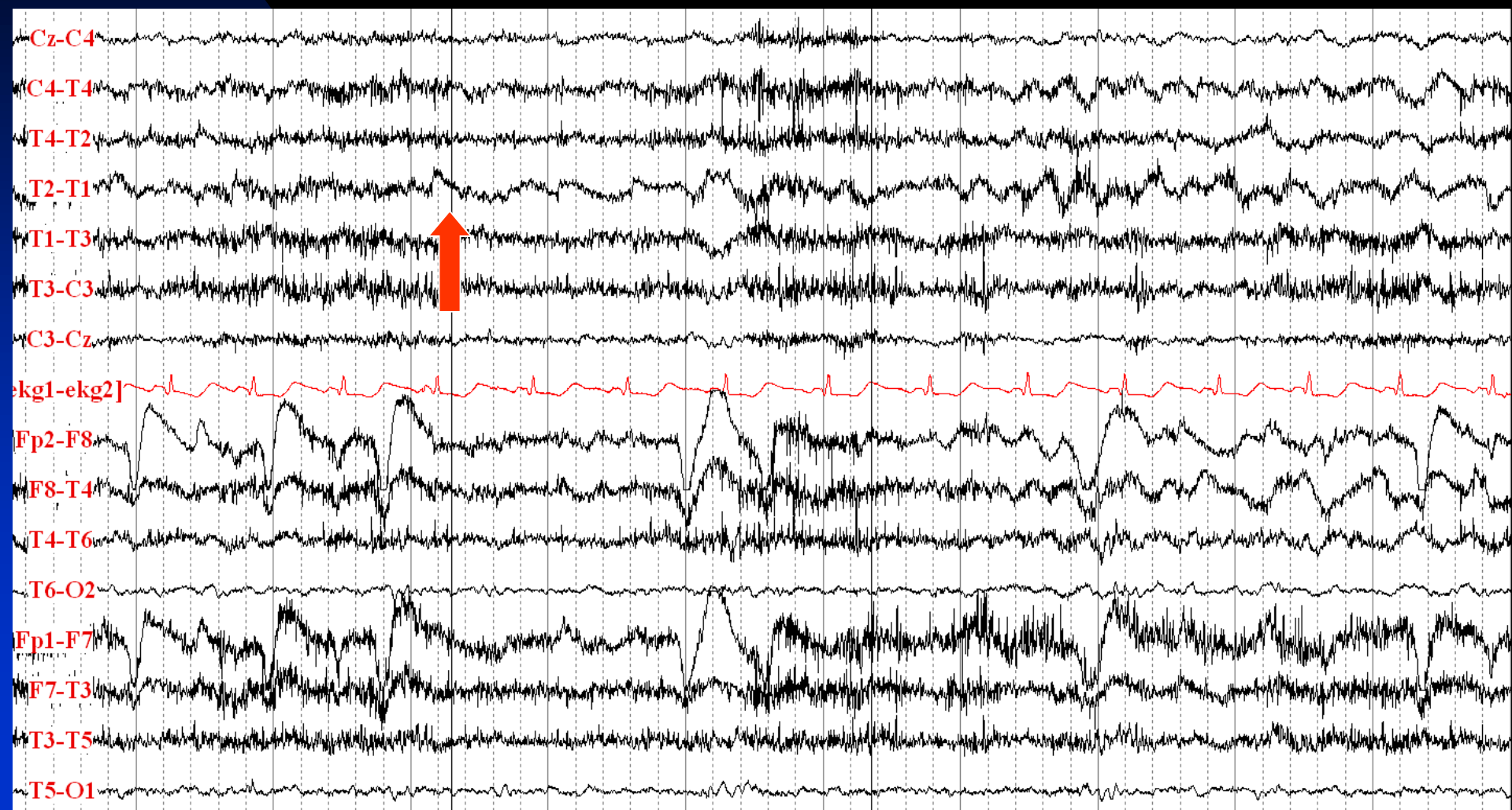
## T2 Sharp Wave in Sleep



## T2 Polymorphic Delta Activity

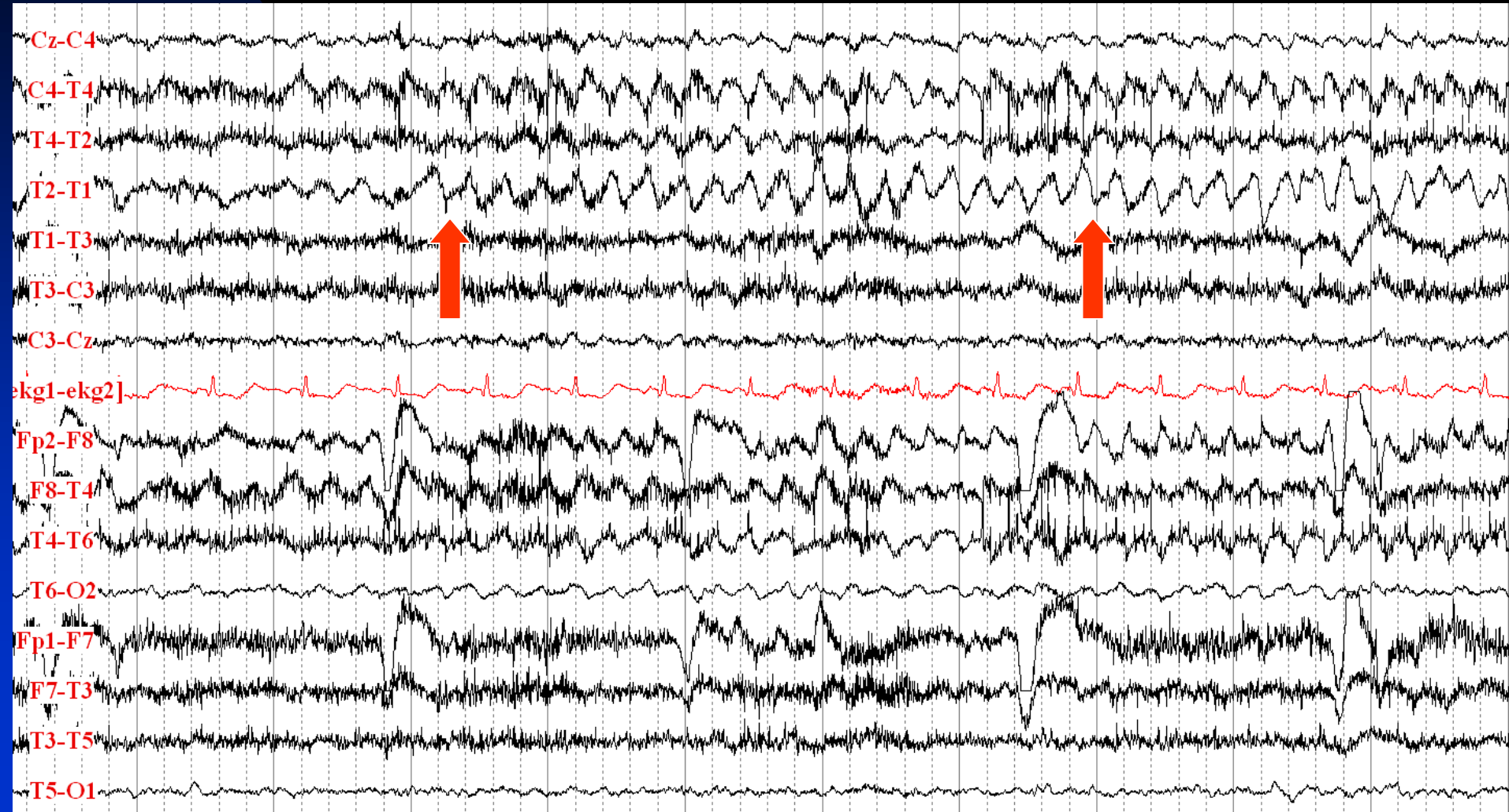


# Seizure Onset with Right Temporal Rhythmic Delta Activity

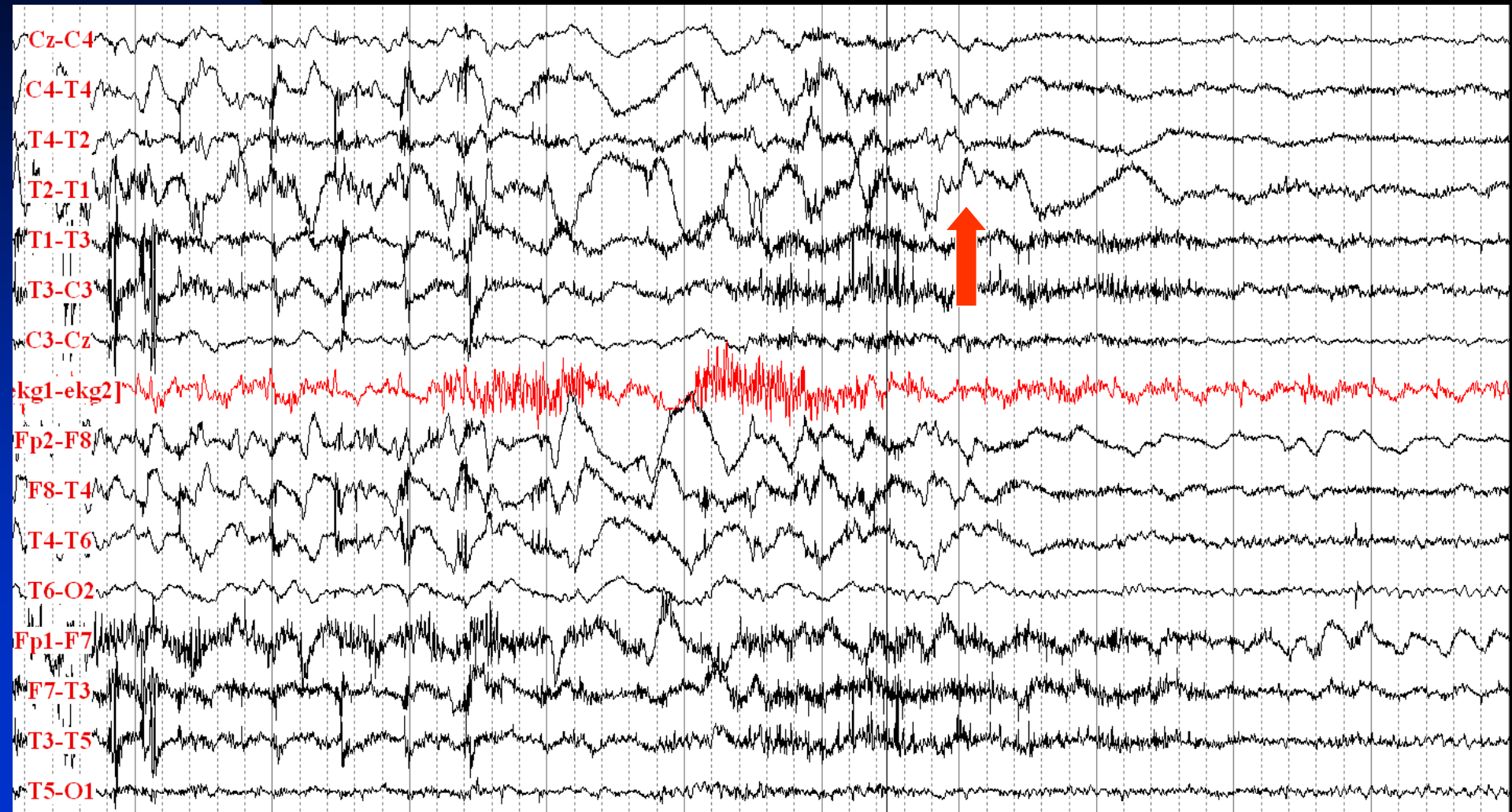




# Ictal Activity Evolves



# Seizure Ends

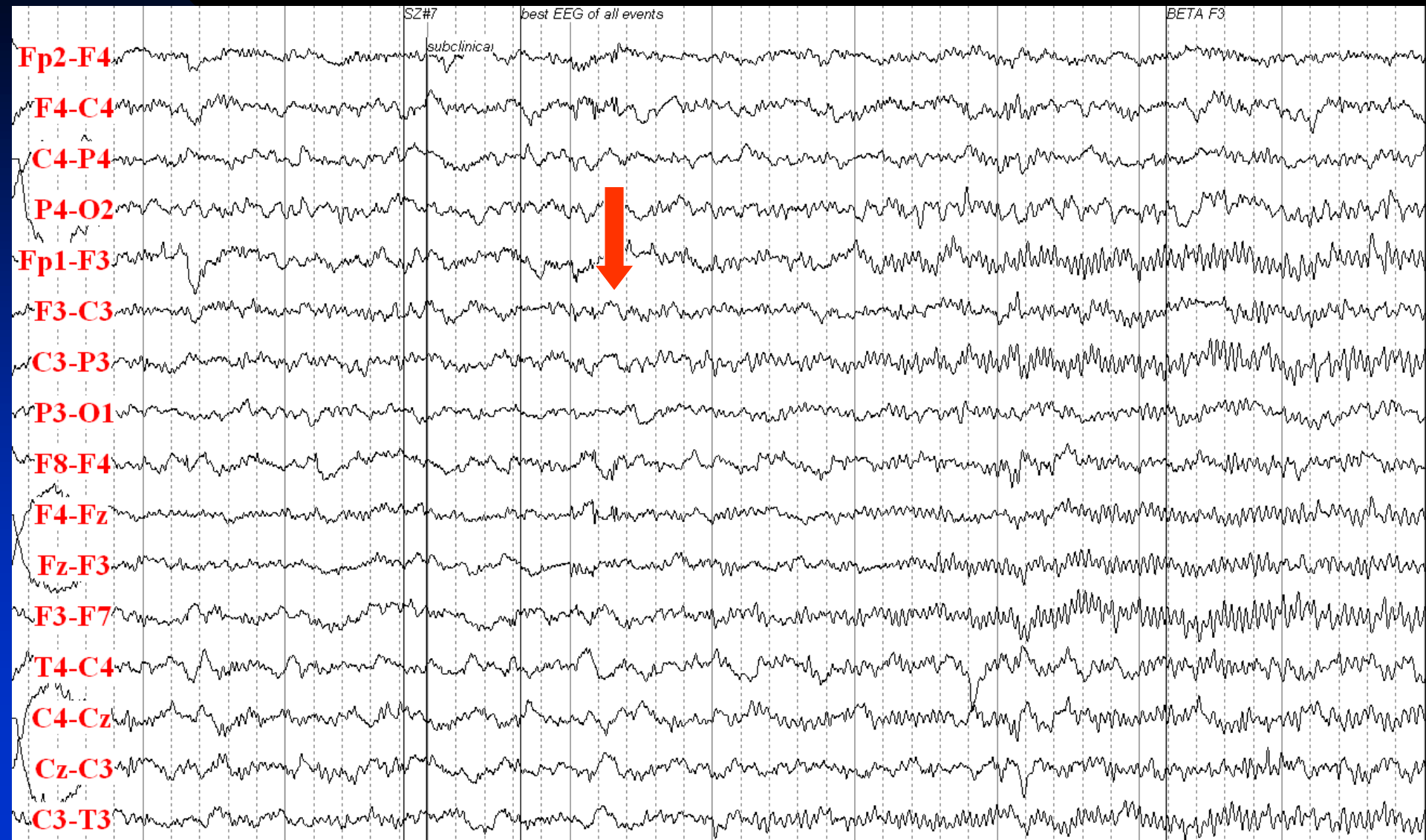




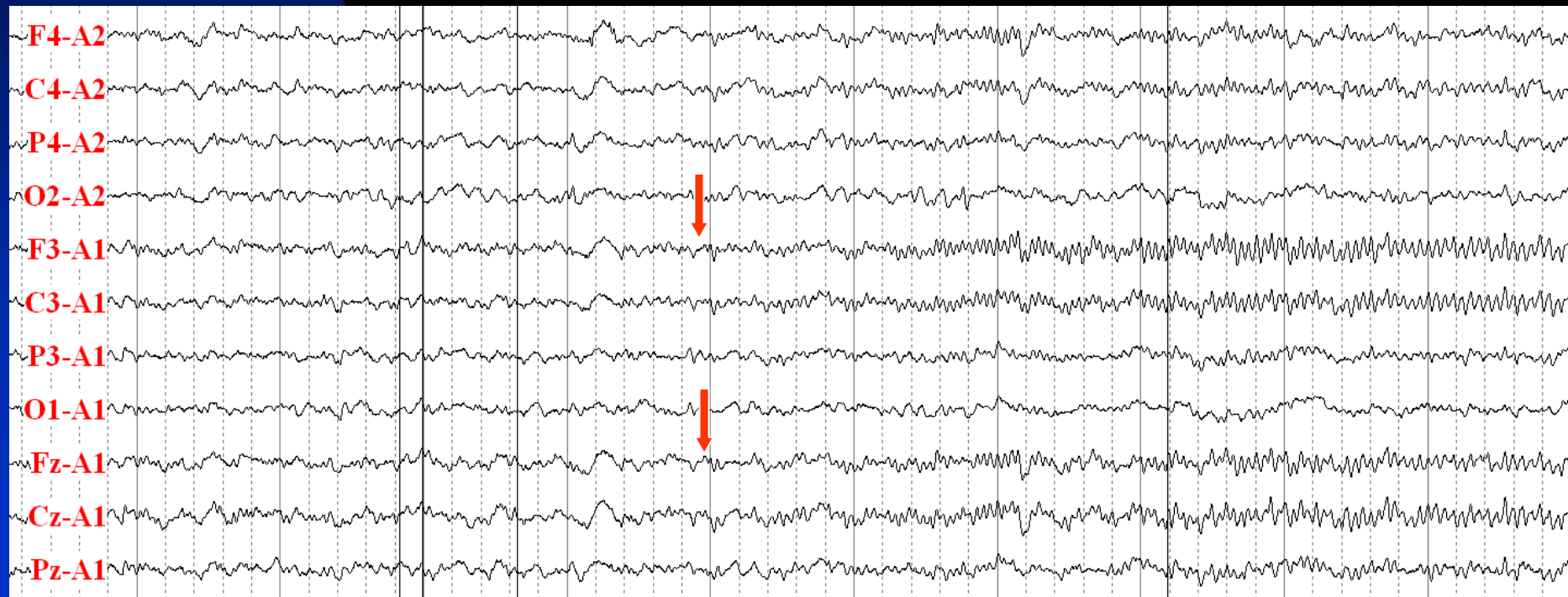# Frontal Lobe Epilepsy

- 28 year-old woman with epilepsy since the age 20
- Risk factor: paternal uncle with grand mal seizures
- Precipitating factor: menstruation
- Neurological examination: normal
- Description of seizures: sound amplification and then fear lasting up to one minute, occasionally followed by right gaze and then bilateral upper extremity shaking. No loss of consciousness or amnesia
- Semiology (video-EEG monitoring): aura, right gaze deviation, right head turn, facial twitching. She was responsive and remembered the code word
- MRI: normal
- Interictal EEG: normal
- Ictal EEG: F3-C3 fast activity with spread to other regions

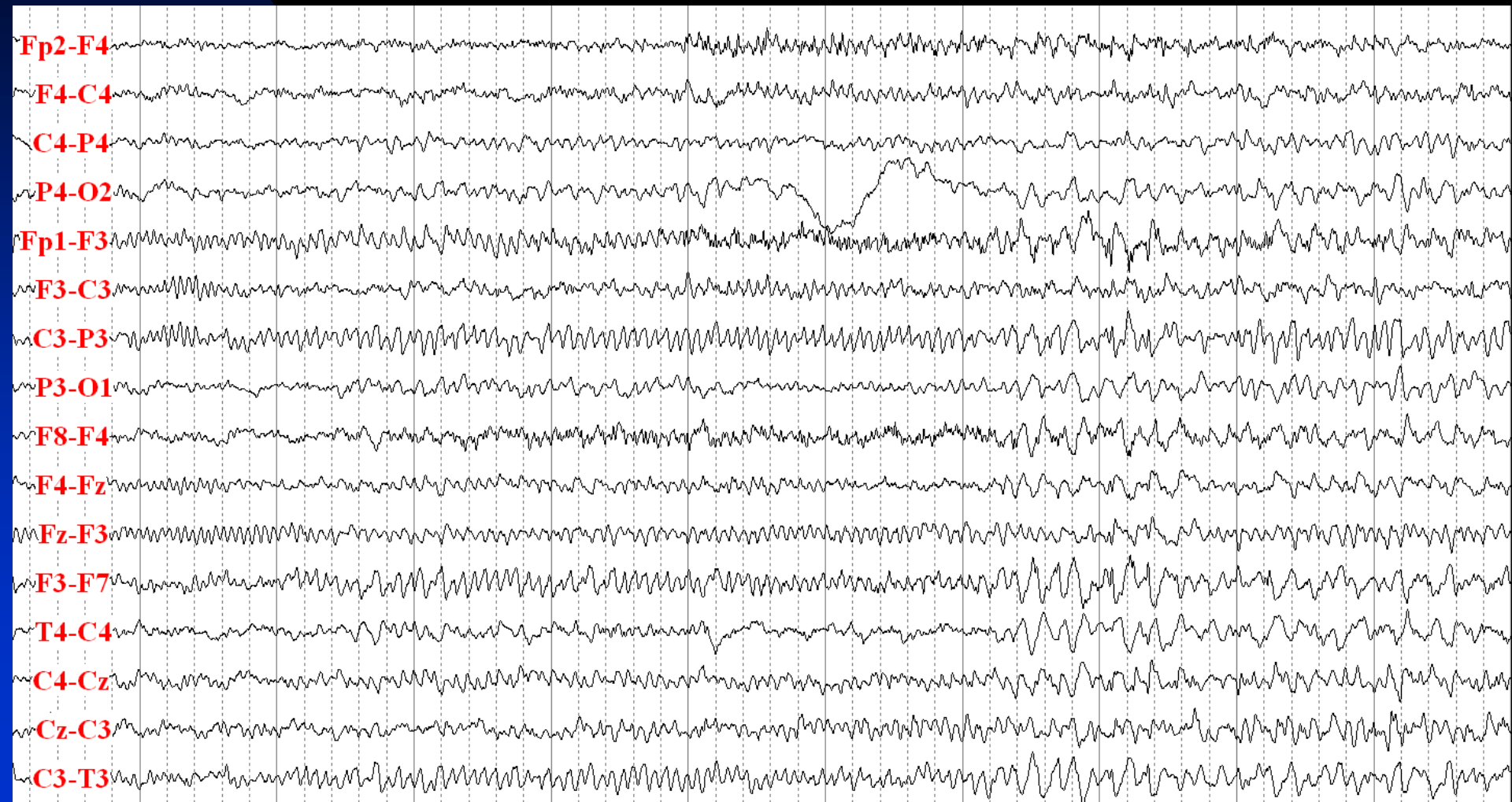
# Seizure Onset: Fast Activity at F3-C3 (Isoelectric)



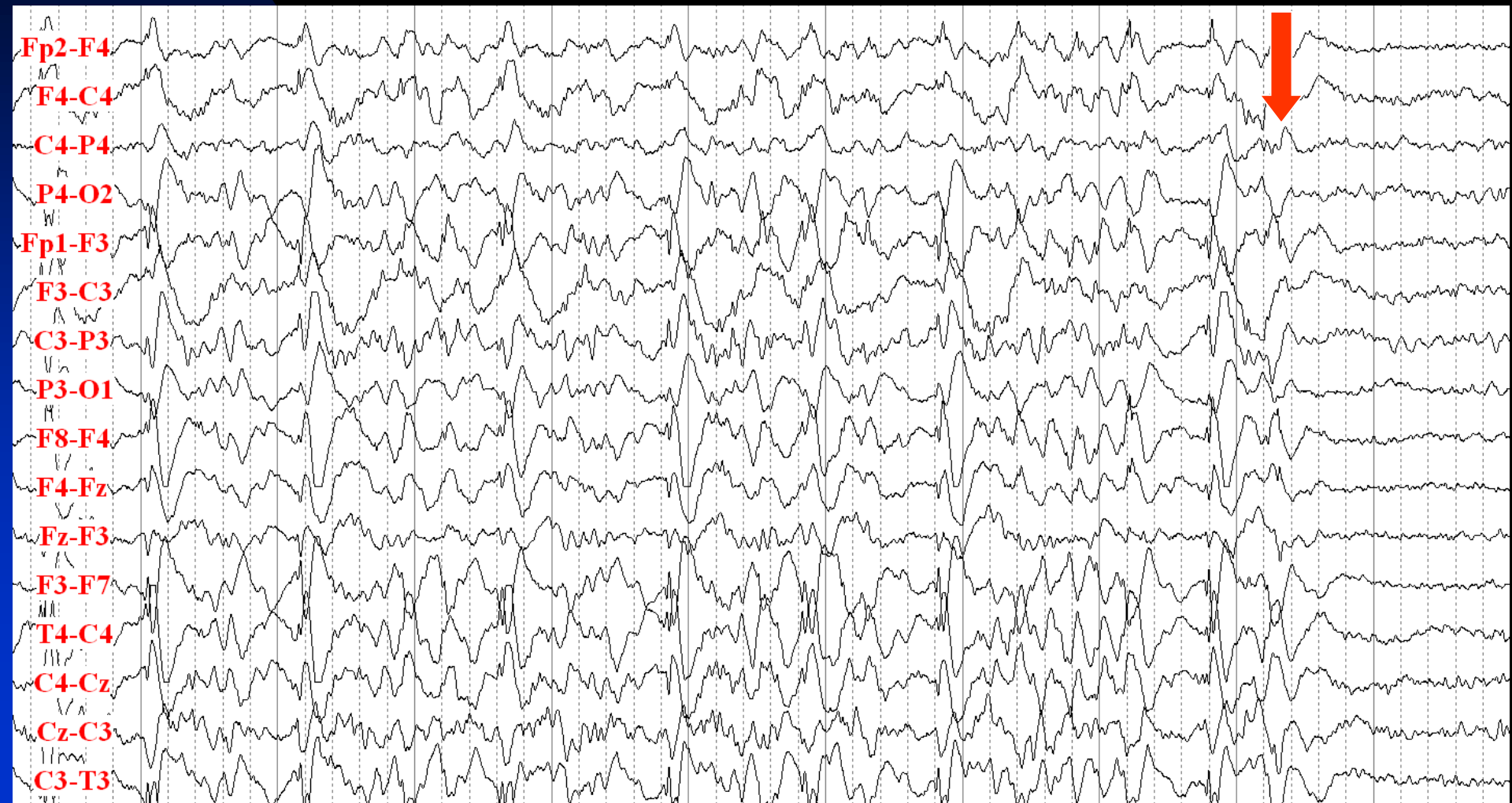
Previous Slide in Ipsilateral Ear Reference Montage:  
Fz and Cz are involved at the Same Time as F3 and C3  
(Probably a Left Mesial Frontal Epileptogenic Focus)



# Left Frontal Seizure Continues with Evolution of Ictal Activity



# Seizure Ends

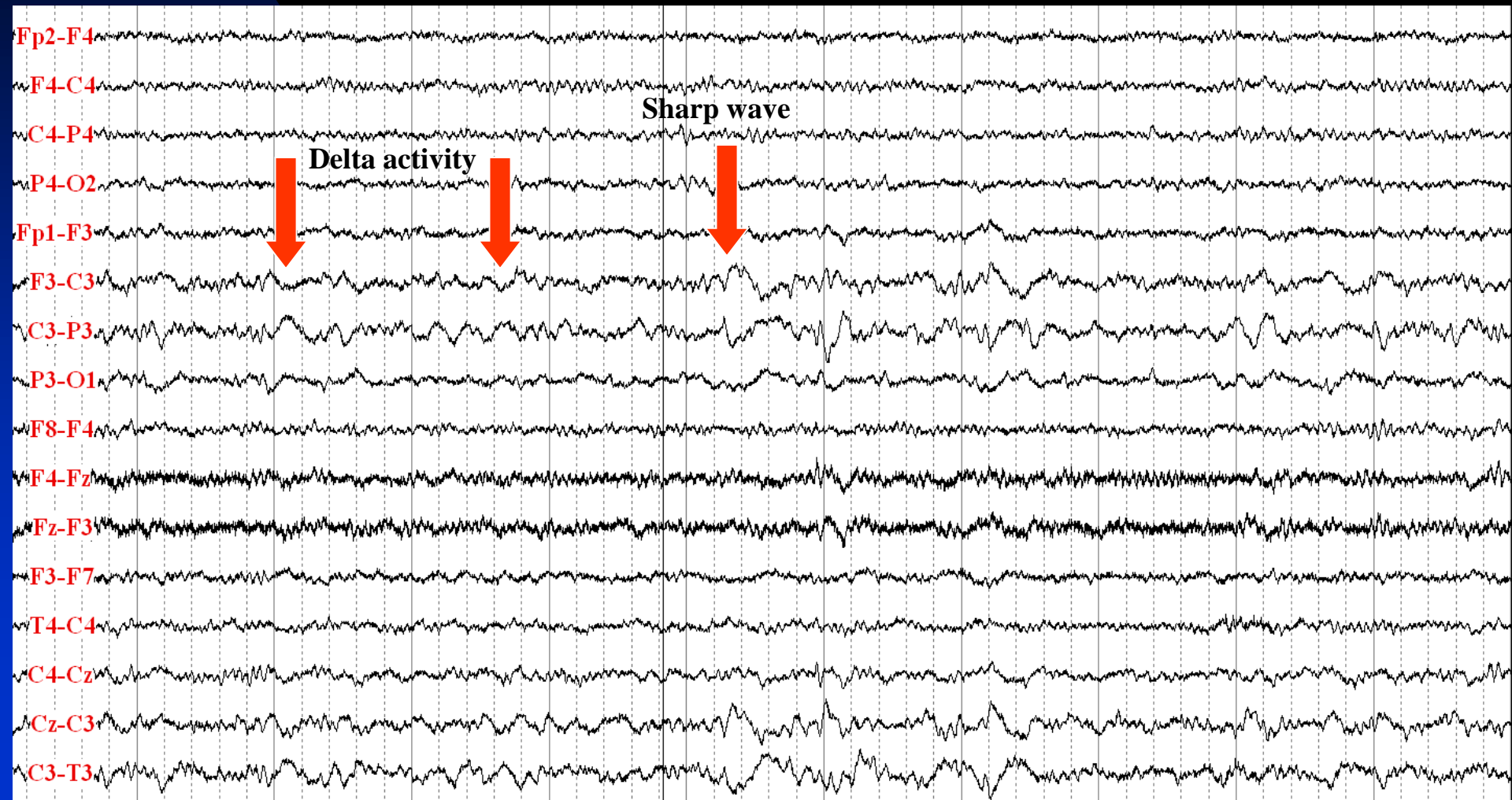


# Frontal Lobe Epilepsy

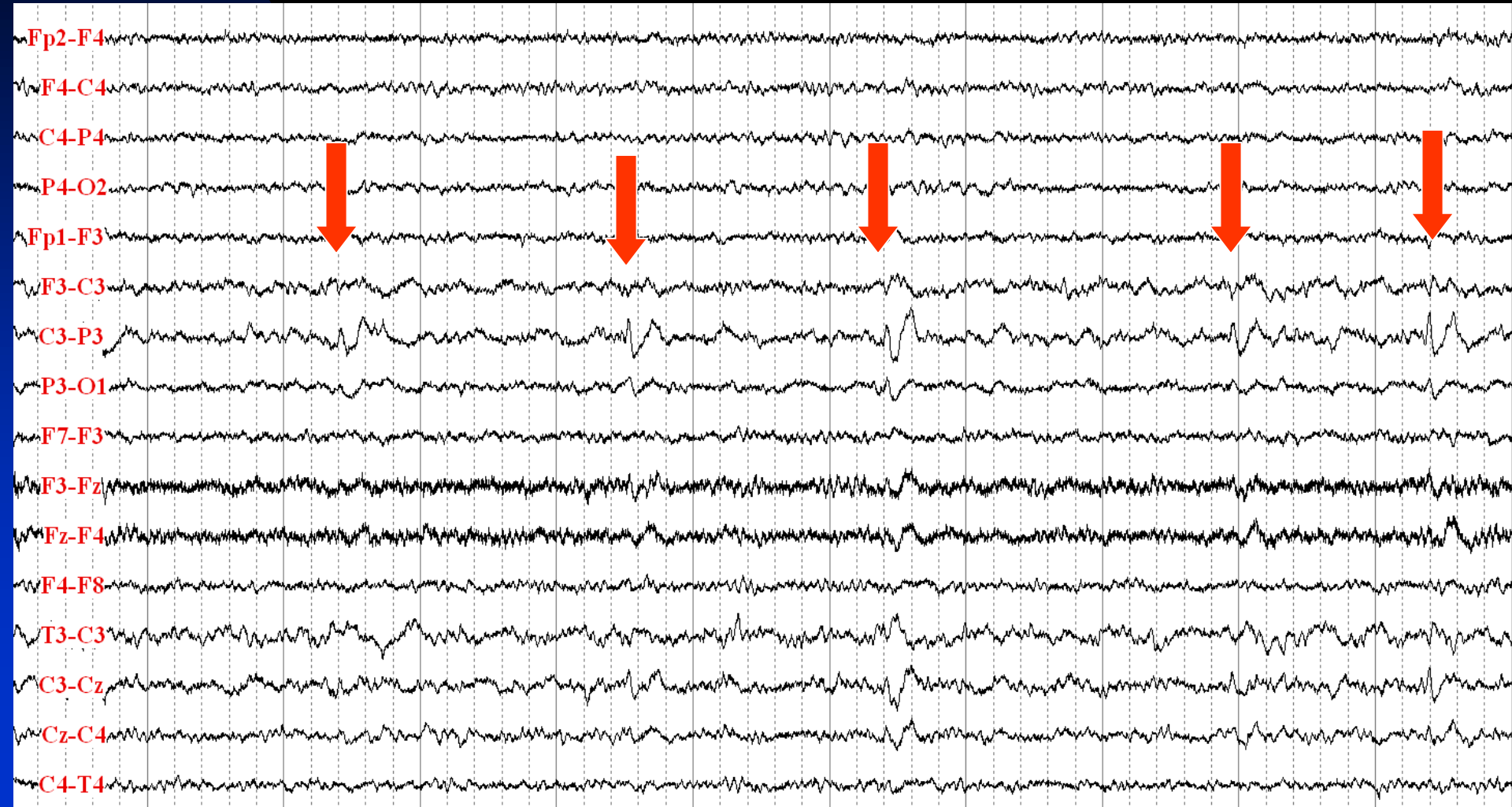- 30 year-old man with epilepsy since the age 29 years
- Risk factor: none
- Precipitating factor: sleep
- Neurological examination: normal
- Description of seizures: coarse body trashing and movements for less than a minute, most seizures occur in sleep
- Semiology (video-EEG monitoring): asleep, open eyes, moaning, right arm tonic, whole body tonic and then jerking
- MRI: left frontal tumor
- Interictal EEG: continuous C3 polymorphic delta activity, C3 sharp waves and periodic lateralized epileptiform discharges (PLEDs)
- Ictal EEG: C3 PLEDs leading to C3 rhythmic activity (7 Hz) with evolution in frequency, amplitude and space, with spread to other areas and generalization



# Interictal EEG: Continuous C3 Polymorphic Delta Activity and C3 Sharp Wave

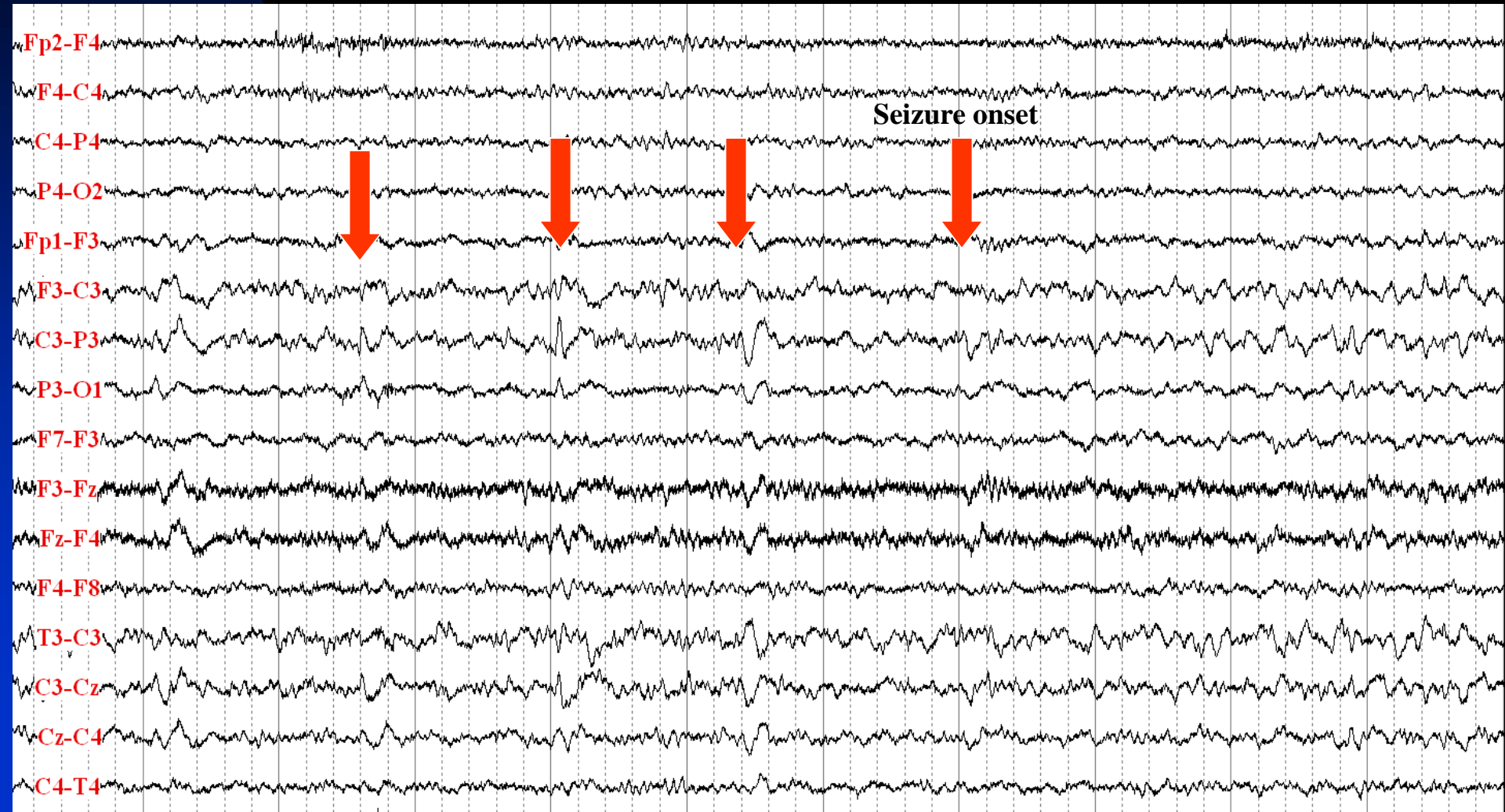

# C3 Periodic Lateralized Epileptiform Discharges (PLEDs)

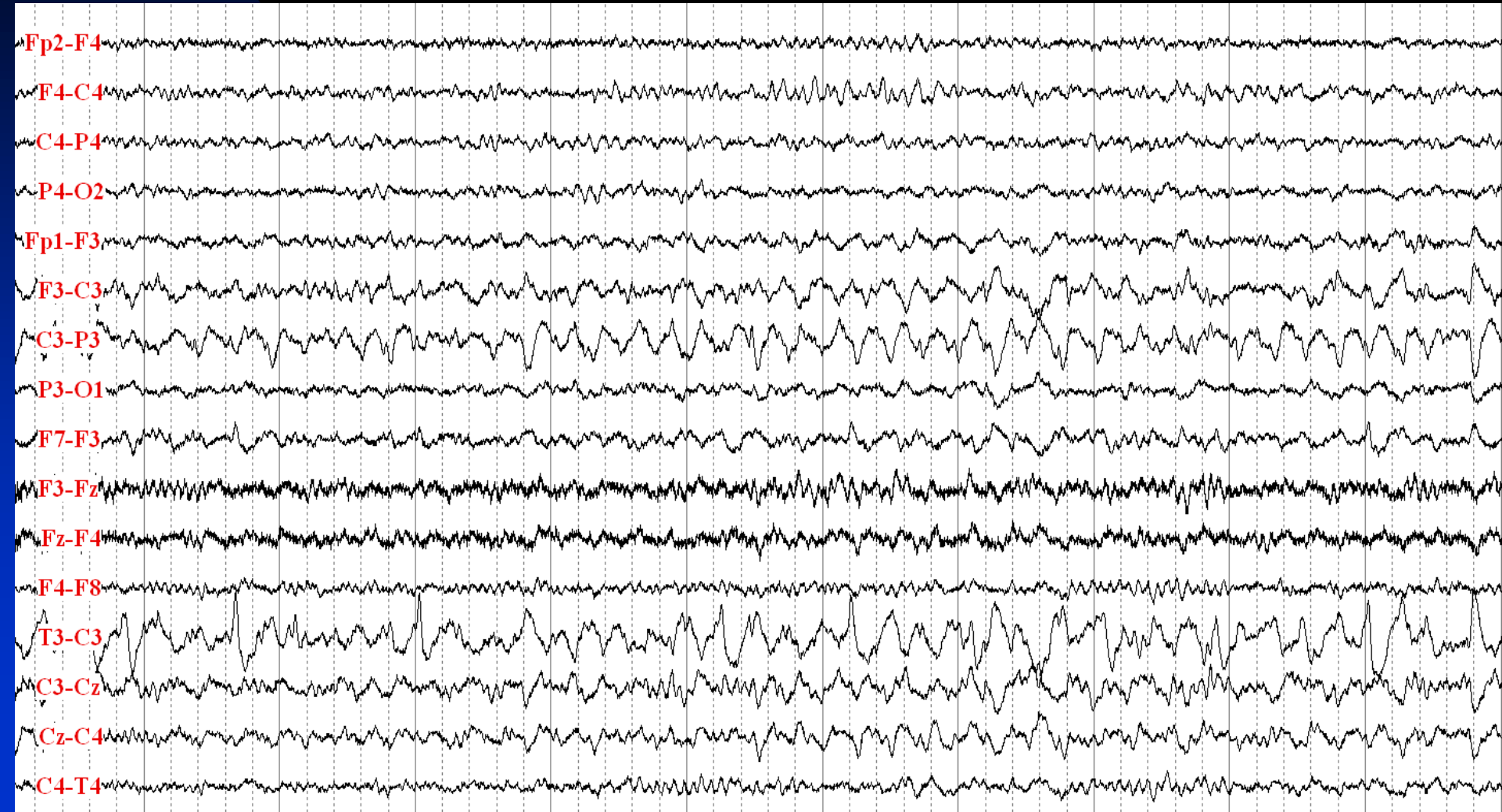




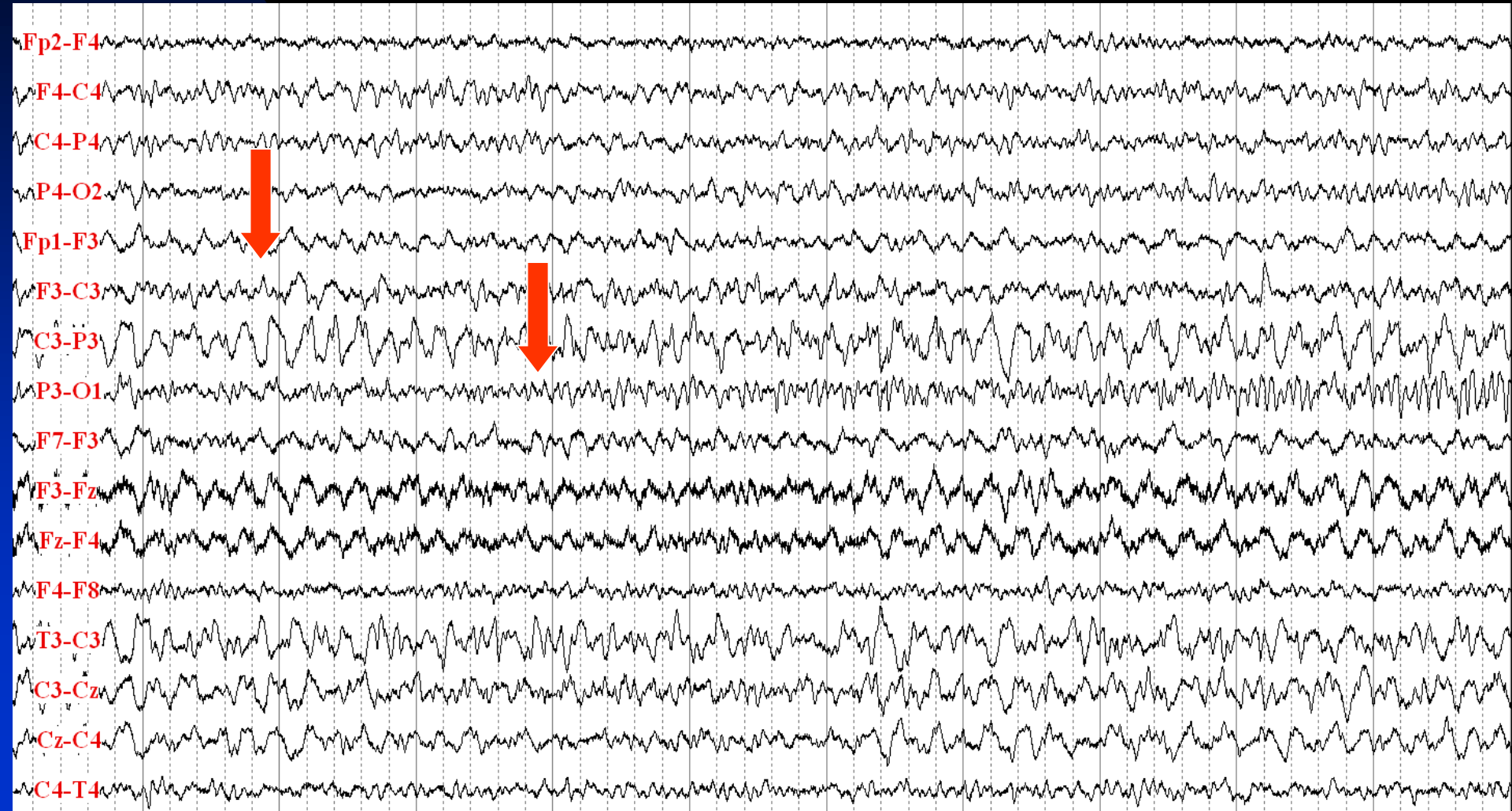
# C3 PLEDs Leading to 7 Hz Rhythmic Activity (Seizure Onset)



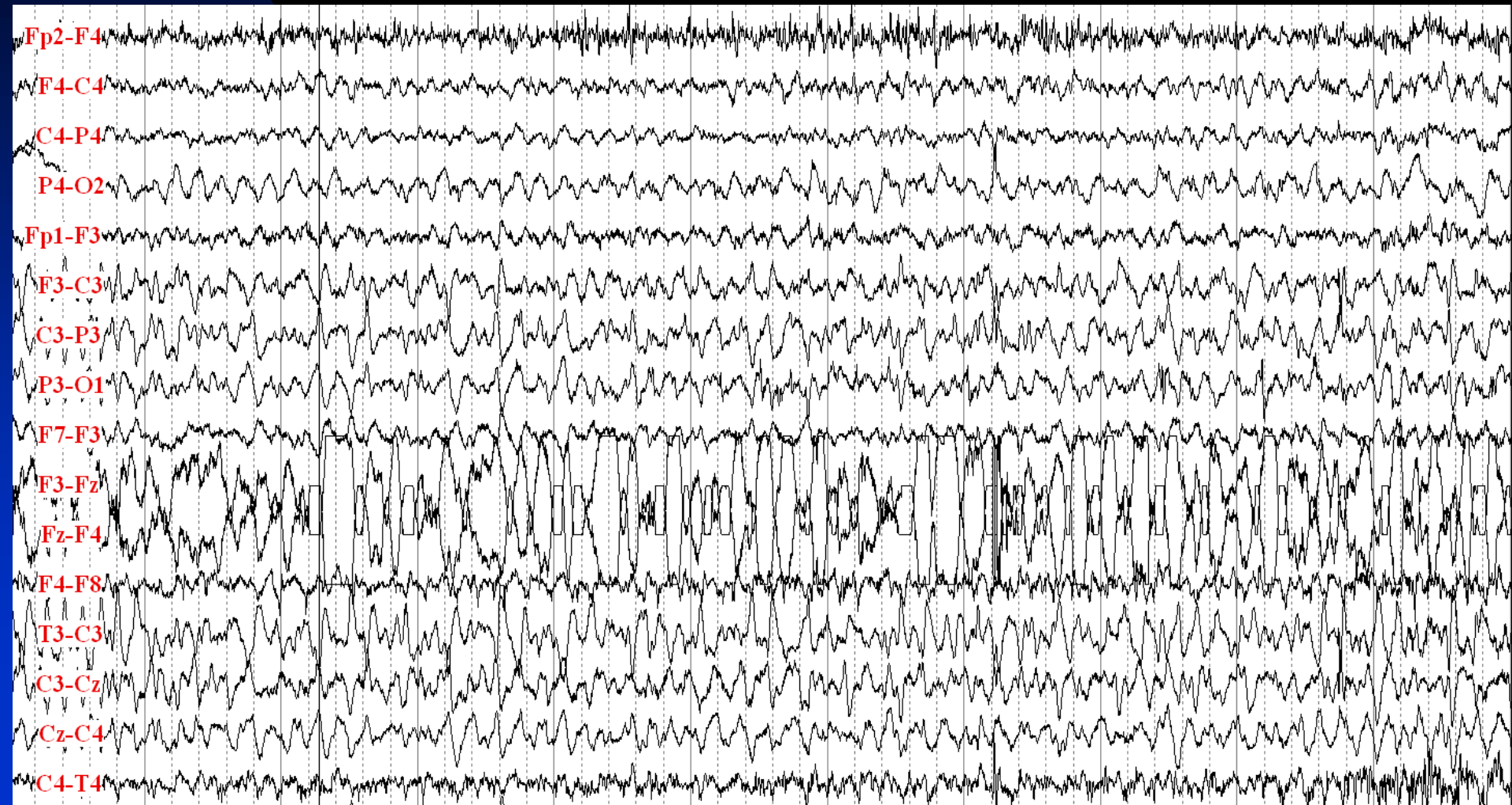
# C3 Ictal Activity Evolves in Frequency and Amplitude



# C3 Ictal Activity Spreads to Other Areas

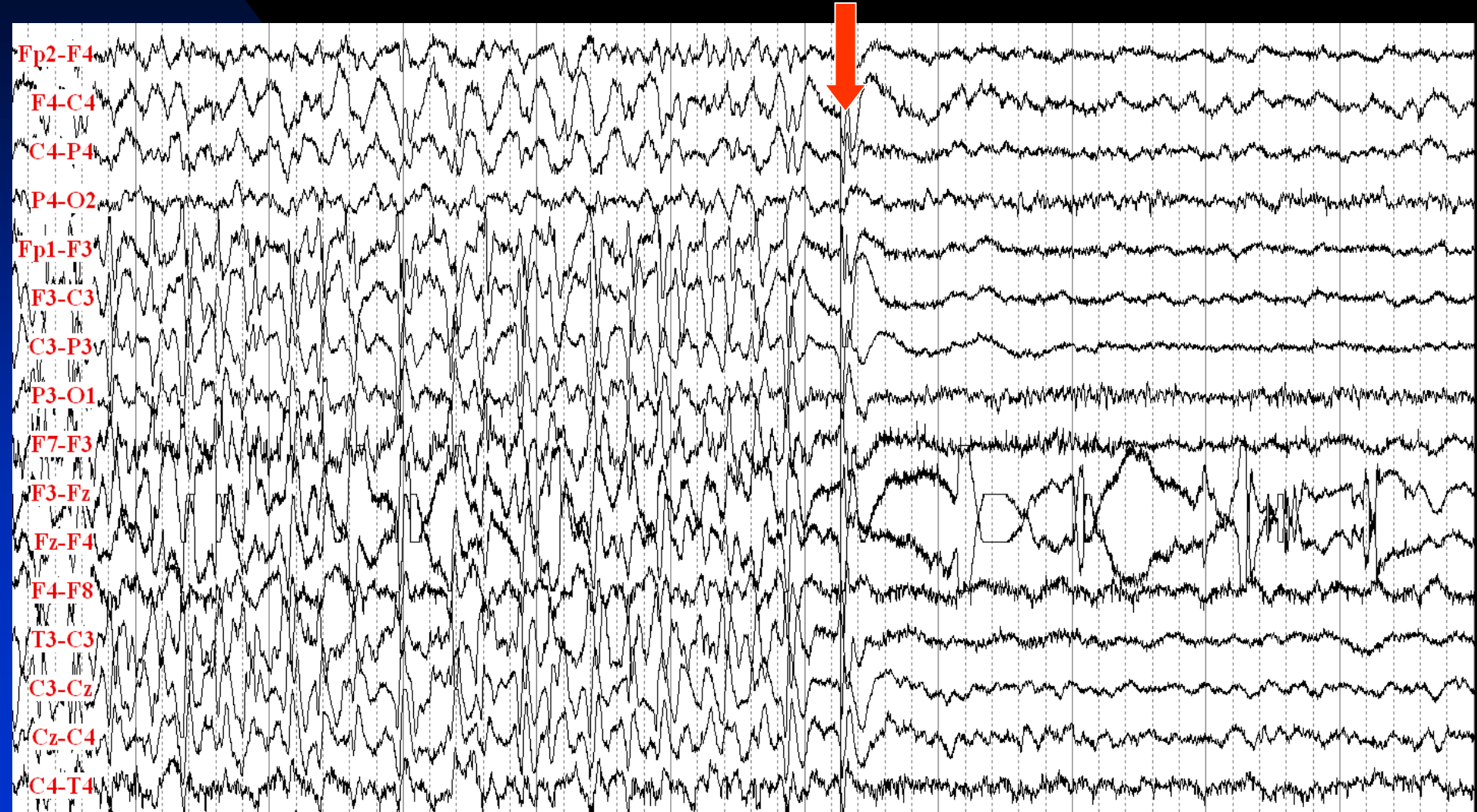


# Secondary Generalization of the Seizure





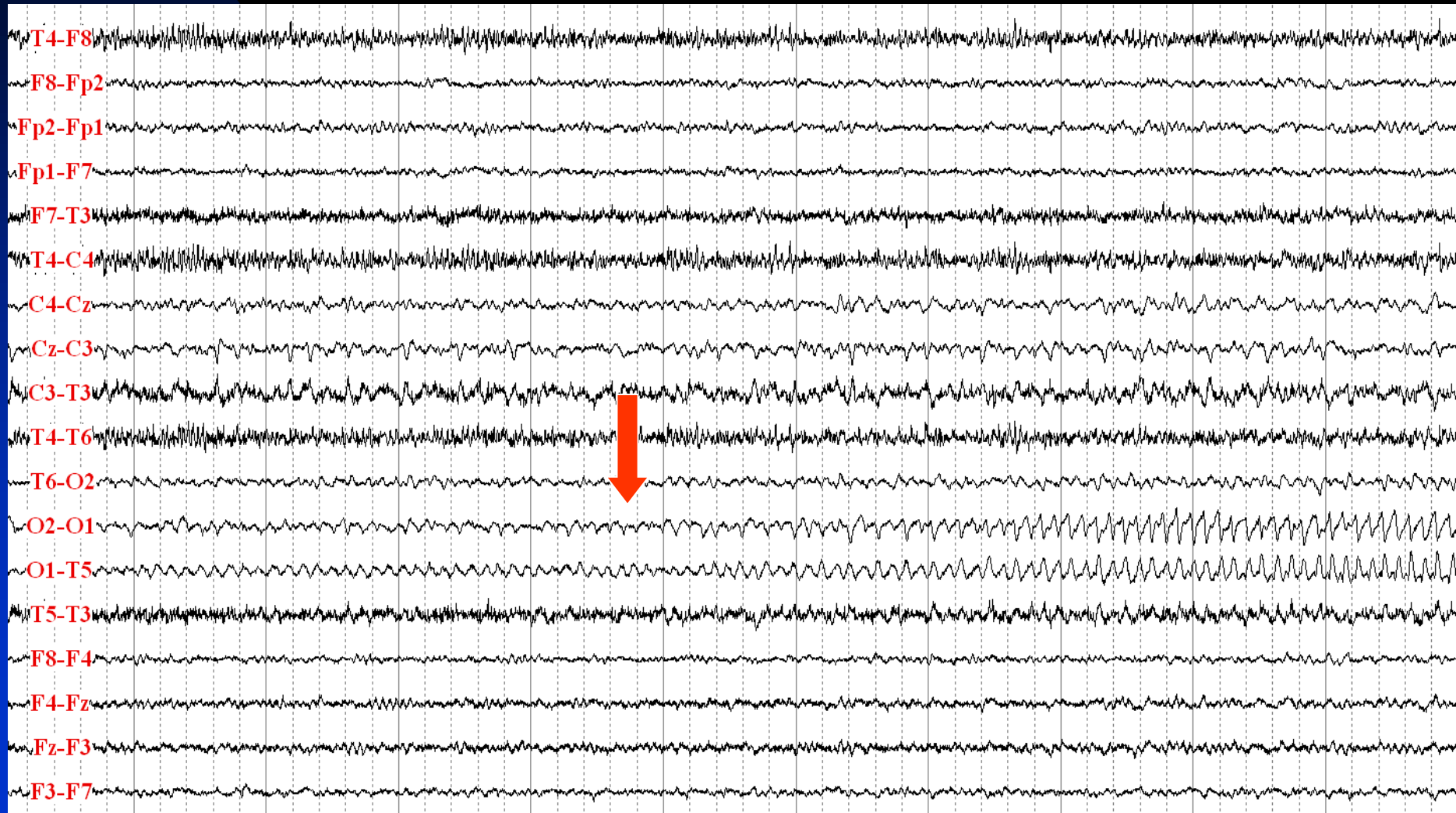
# Seizure Ends with Postictal Attenuation of EEG Activity, Especially in the Left side



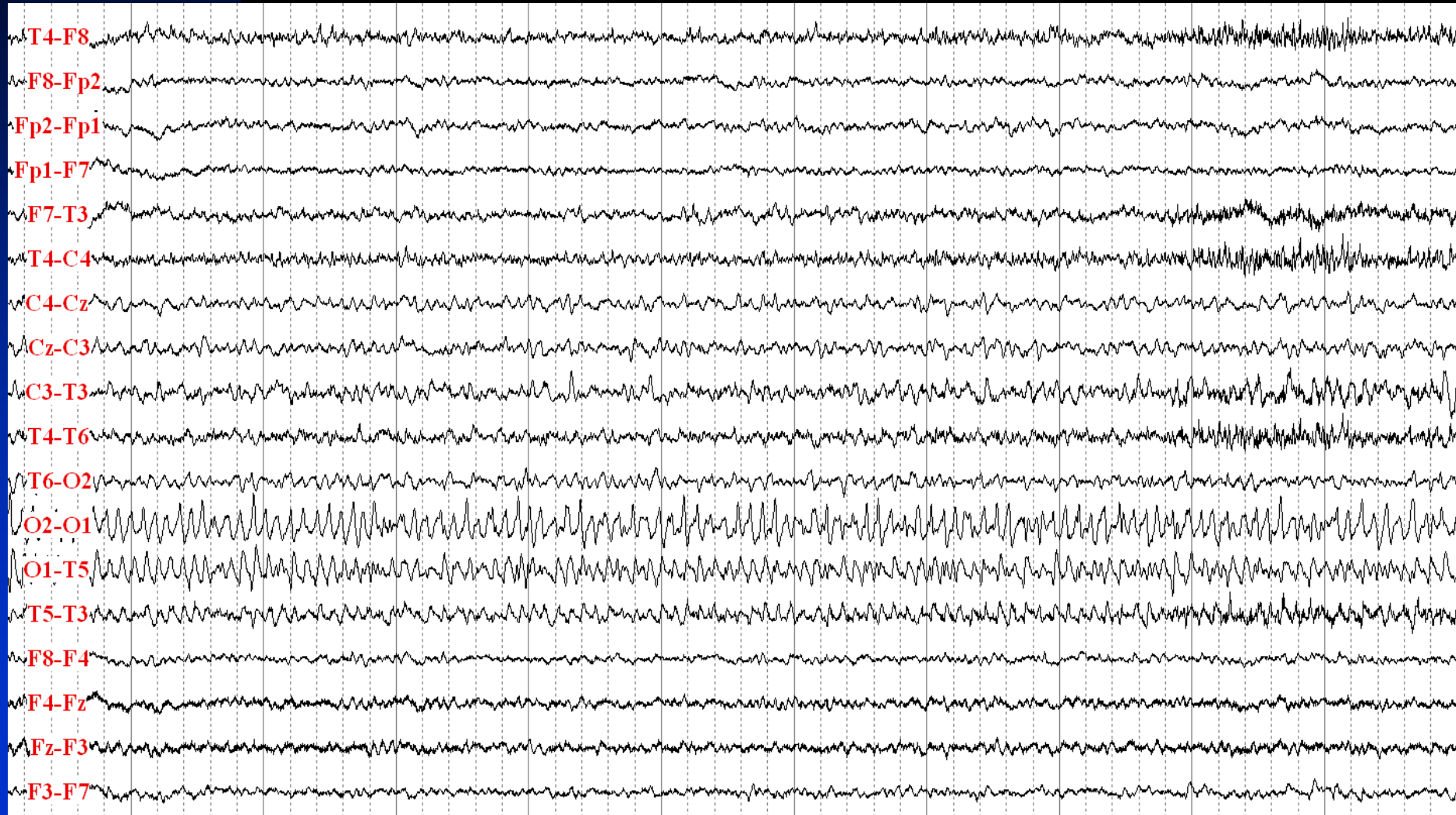# Occipital Lobe Epilepsy

- 20 year-old man with focal epilepsy since the age 14 years
- Risk factor: none
- Precipitating factor: flash lights
- Neurological examination: normal
- Description of seizures: seeing flashing lights, then blindness for 30 seconds, with sensation of ocular movements, sometimes leading to grand mal seizures
- Semiology (video-EEG monitoring): aura, right gaze deviation, right head version, was not responsive and did not remembered the code word
- MRI: normal
- Interictal EEG: normal
- Ictal EEG: rhythmic spiky 10 Hz O1 activity with evolution in amplitude and morphology

# Left Occipital Seizure: Rhythmic Spiky 10 Hz Activity with Evolution in Amplitude and Morphology

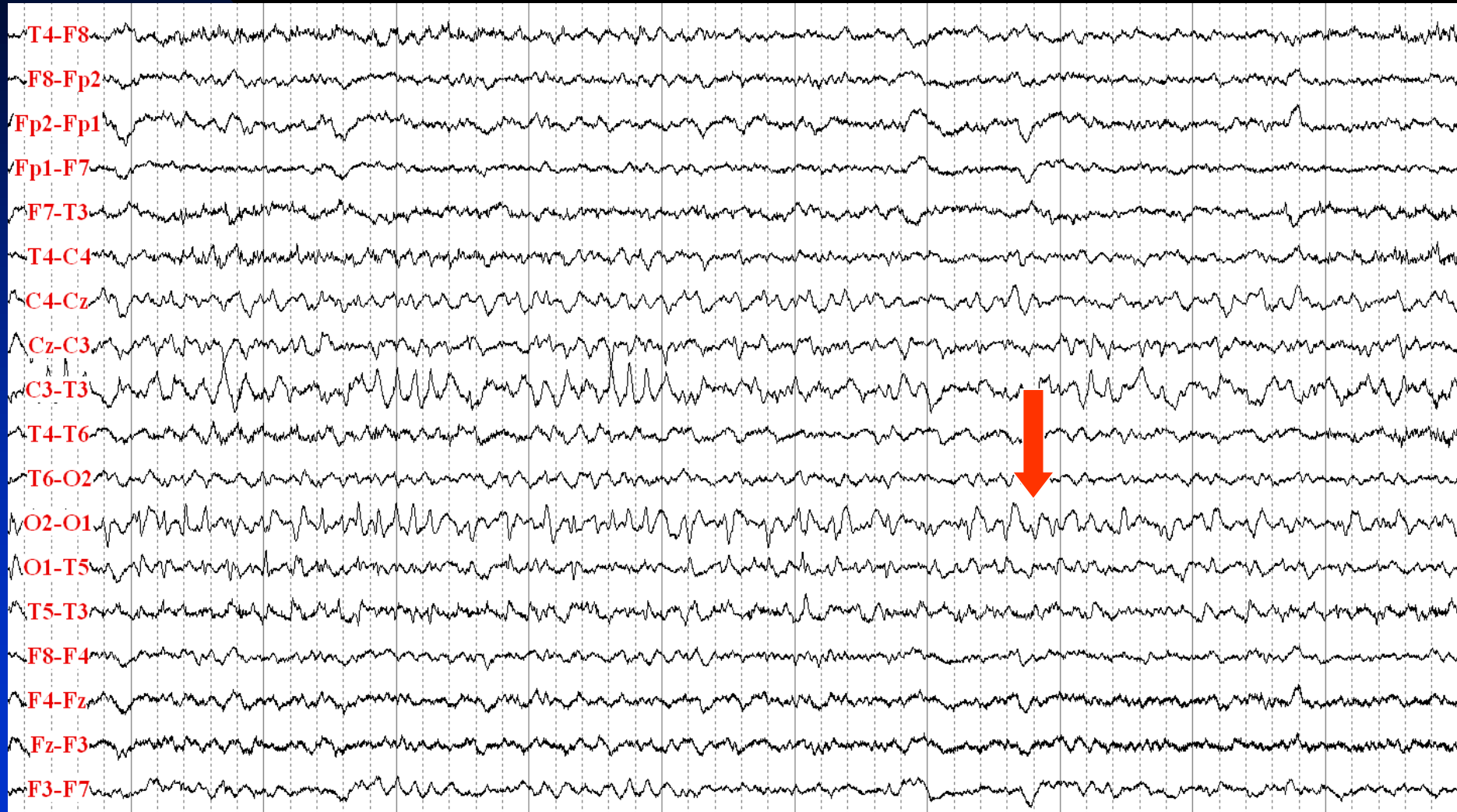

# O1 Seizure Continues With Spread to the Left central Area and Minimal Spread to the Right Hemisphere





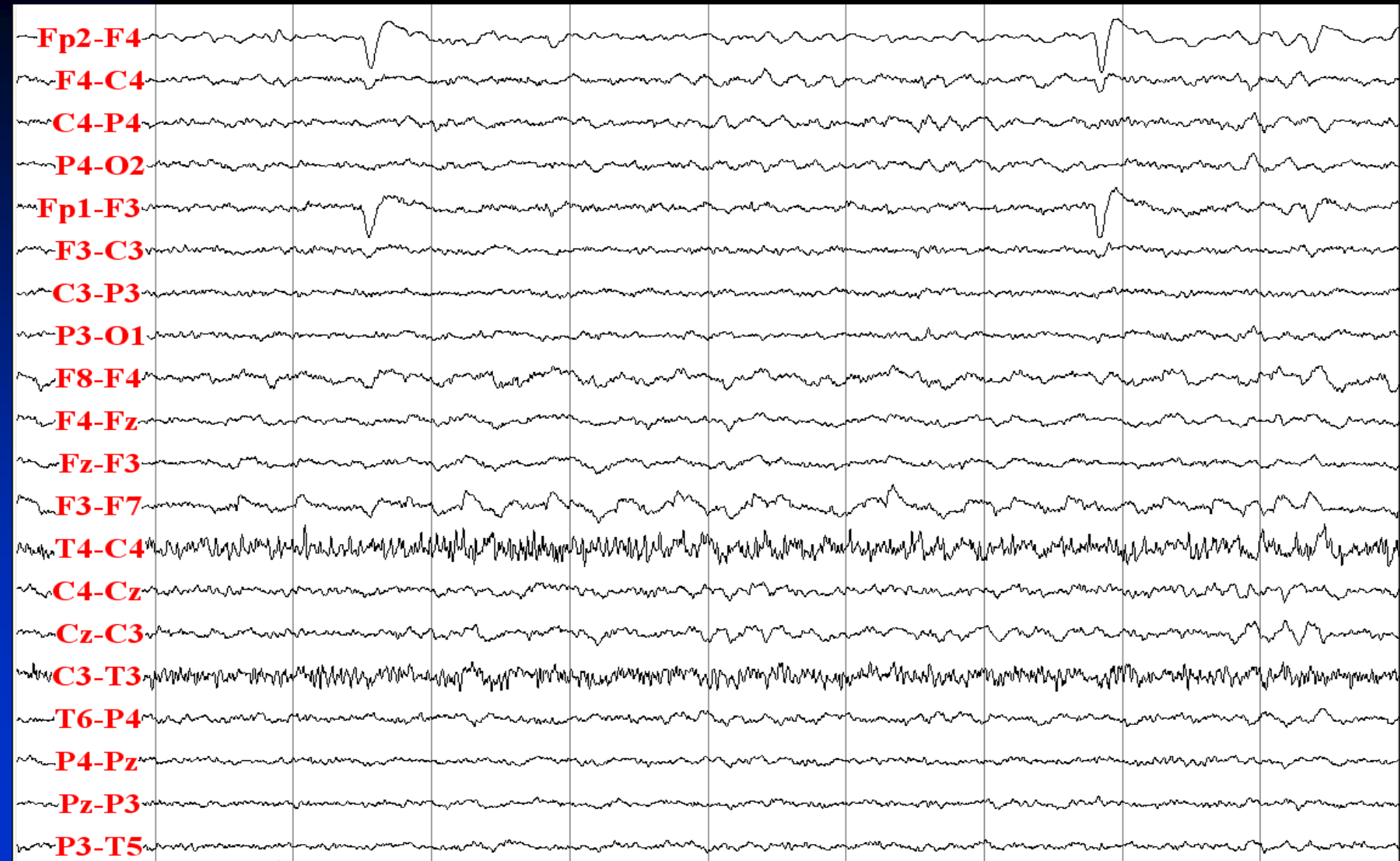
# O1 Seizure Ends



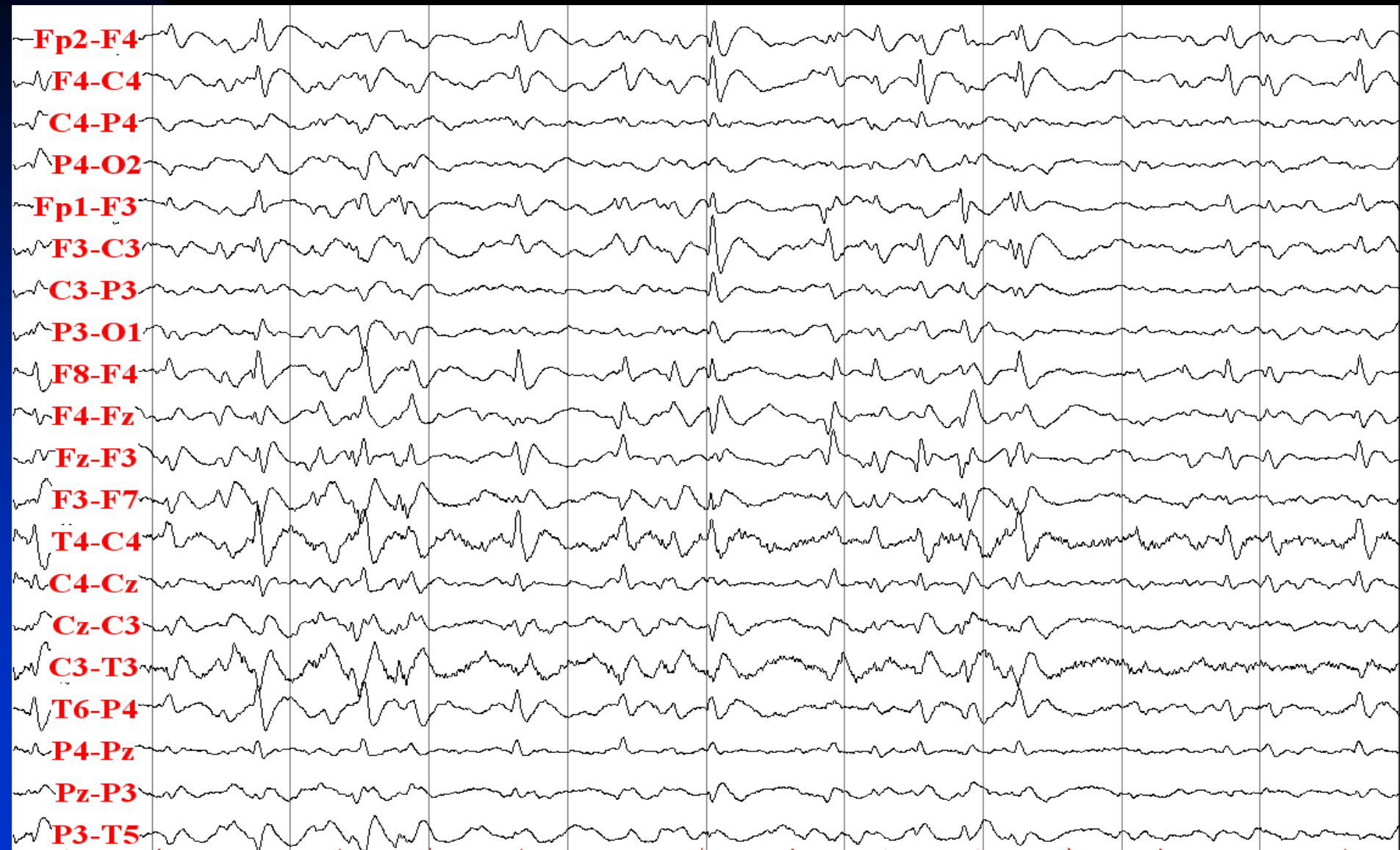# Lennox-Gastaut Syndrome

- 21 year-old man with drug-resistant mixed seizure types since childhood
- Risk factors: none
- Neurological examination: mental retardation, microcephaly
- Description of seizures:
  - ◆ Tonic seizures: bilateral asymmetric arm extension for 20-40 seconds
  - ◆ Atypical absences: unresponsiveness for about 10-40 seconds
  - ◆ Atonic seizures: falls while standing, head drop while sitting
- MRI: diffuse brain atrophy
- Interictal EEG: diffusely slow background, generalized slow spike and waves
- Ictal EEG (tonic seizures): a large diffuse slow wave, diffuse attenuation, build up of diffuse fast activity with evolution to higher amplitude and lower frequency activity, and finally with sudden termination

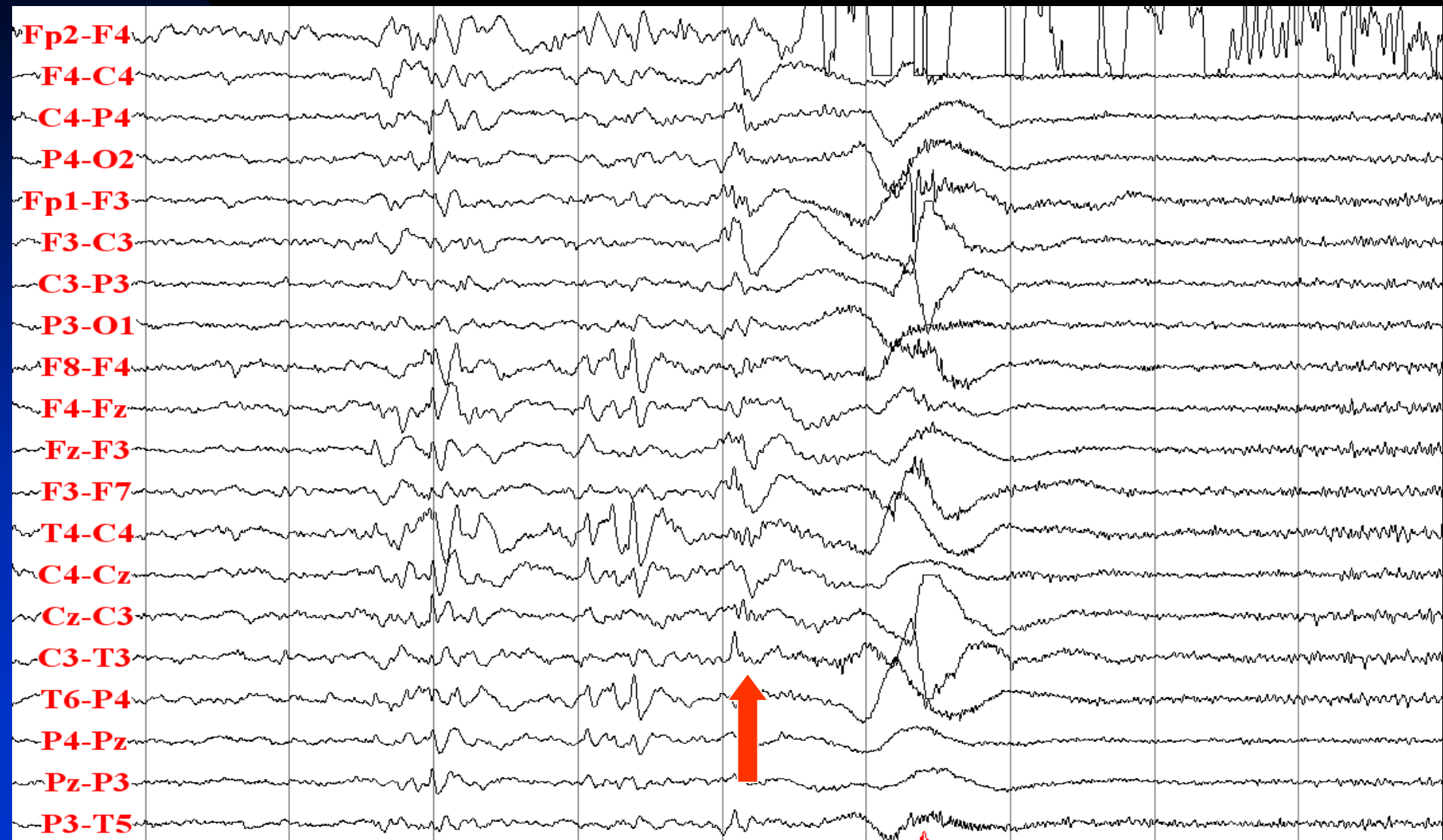# Diffusely Slow Background



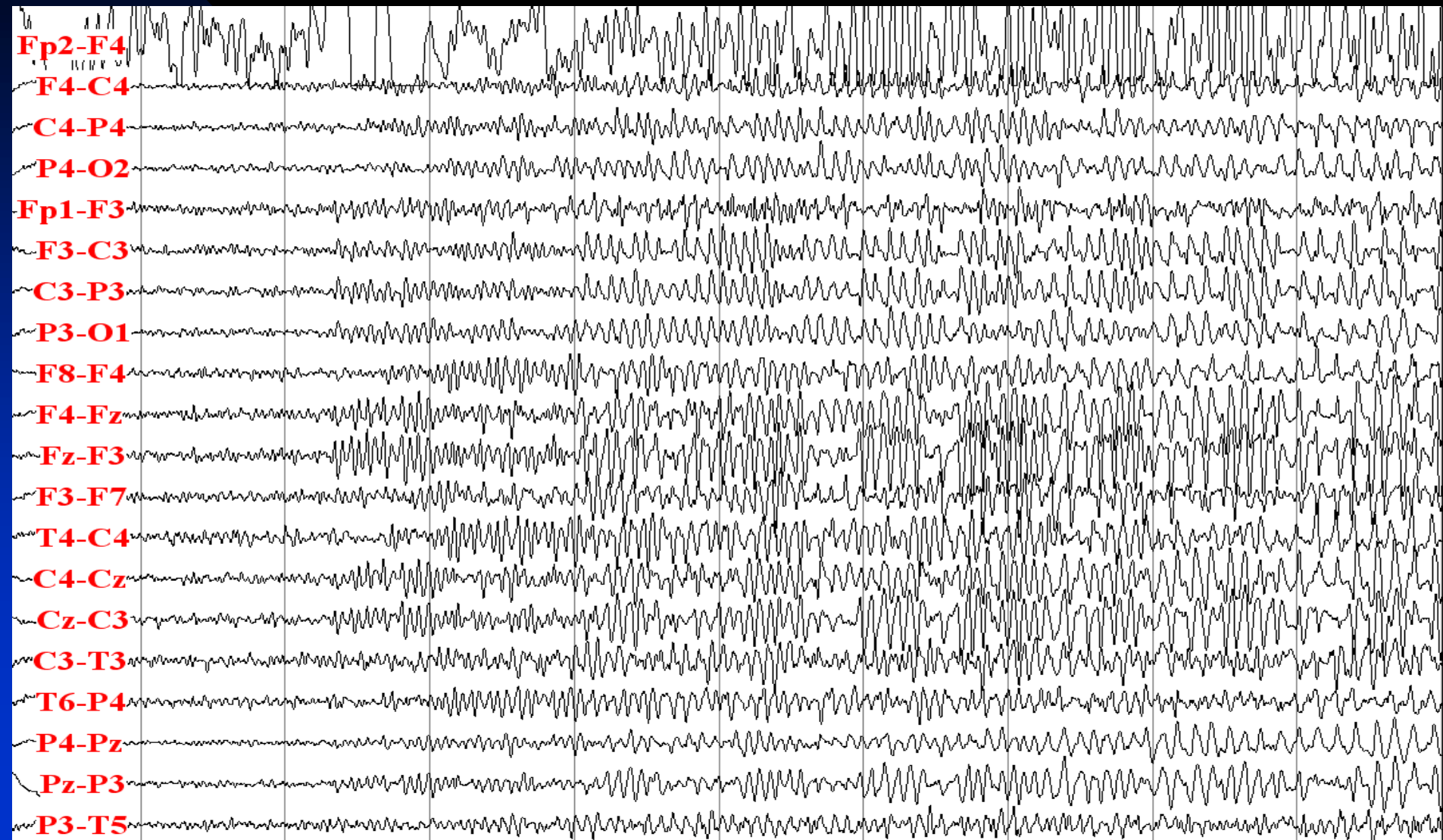
# 2 Hz Generalized Spike-Waves



# Tonic Seizure Starts with a Large Slow Wave and Then Diffuse Attenuation and Fast Activity

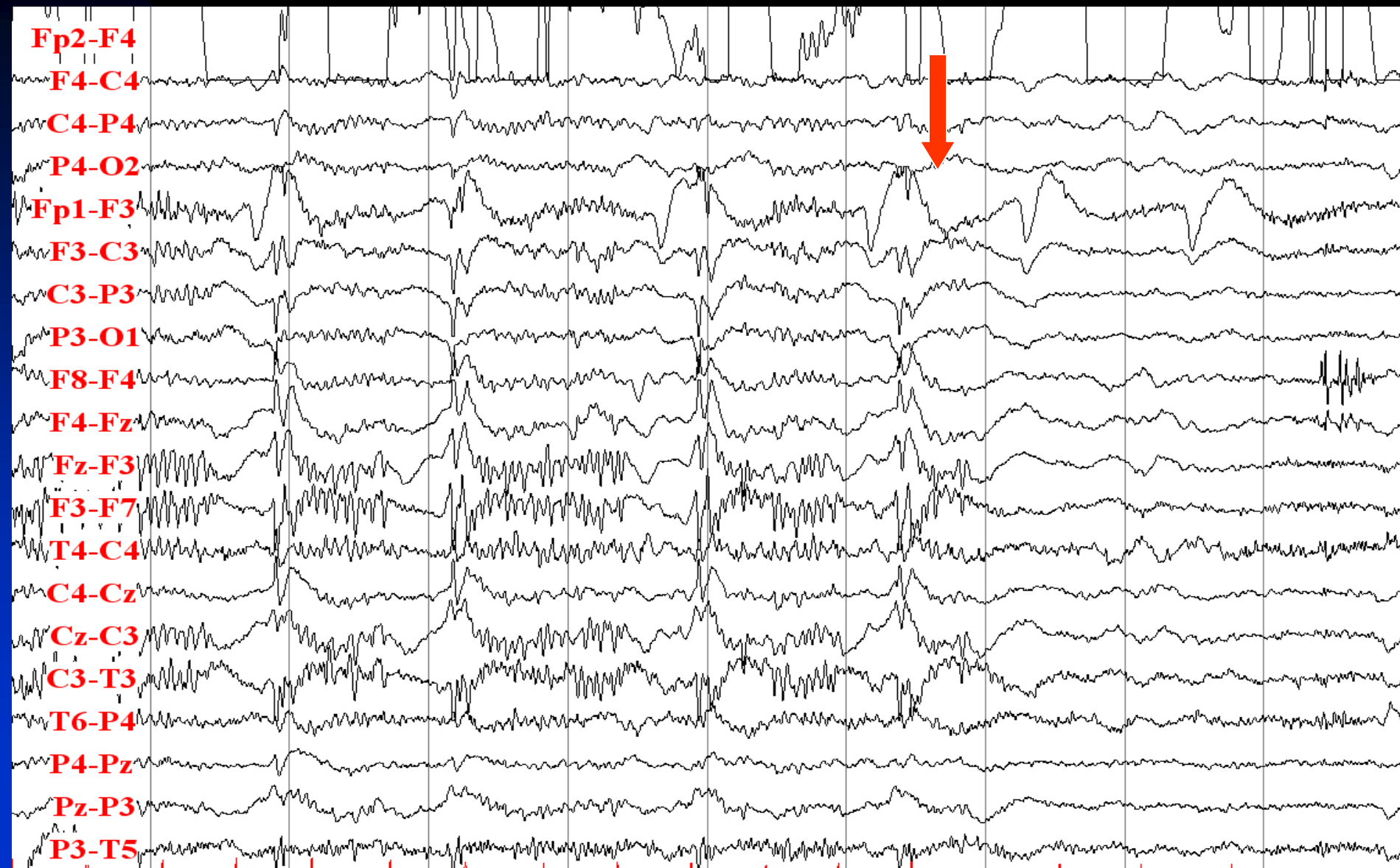

# Build-up of Diffuse Fast Activity with Evolution to Higher Amplitude and Lower Frequency Activity





# Termination of Tonic Seizure



# **Periodic Epileptiform Discharges**



# Periodic Lateralized Epileptiform Discharges (PLEDs)

- **New terminology:** Lateralized periodic discharges (LPDs)
- **Morphology:** Triphasic with sharply contoured waves followed by a slow waves
- **Duration:** 100-300 msec
- **Amplitude:** Greater than the background (100-300  $\mu$ V)
- **Location:** Usually has a singular focus
- **Main characteristic:** Periodic recurrence every 0.5-4 sec, sometimes with varying degrees of regularity
- **Etiology:** Acute, large, destructive CNS lesions (e.g., CVA, malignancies, herpes encephalitis)
- **Significance:**
  - ★ Occurrence of acute overt clinical seizures in 70-80% of cases
  - ★ Occurrence of subsequent epilepsy in 3-66% of patients

# Periodic Lateralized Epileptiform Discharges

- PLEDs commonly resolve over days to weeks
- Traditionally, PLEDs have been considered to be interictal:
  - ★ Does not evolve
  - ★ Does not have clinical correlate
  - ★ Resolve gradually
- PLEDs are sometimes ictal phenomenon:
  - ★ They have clinical correlate: focal motor jerking, focal weakness, altered mental status
  - ★ They are associated with a focal increase in blood flow seen with SPECT scan

# Other Periodic Epileptiform Discharges

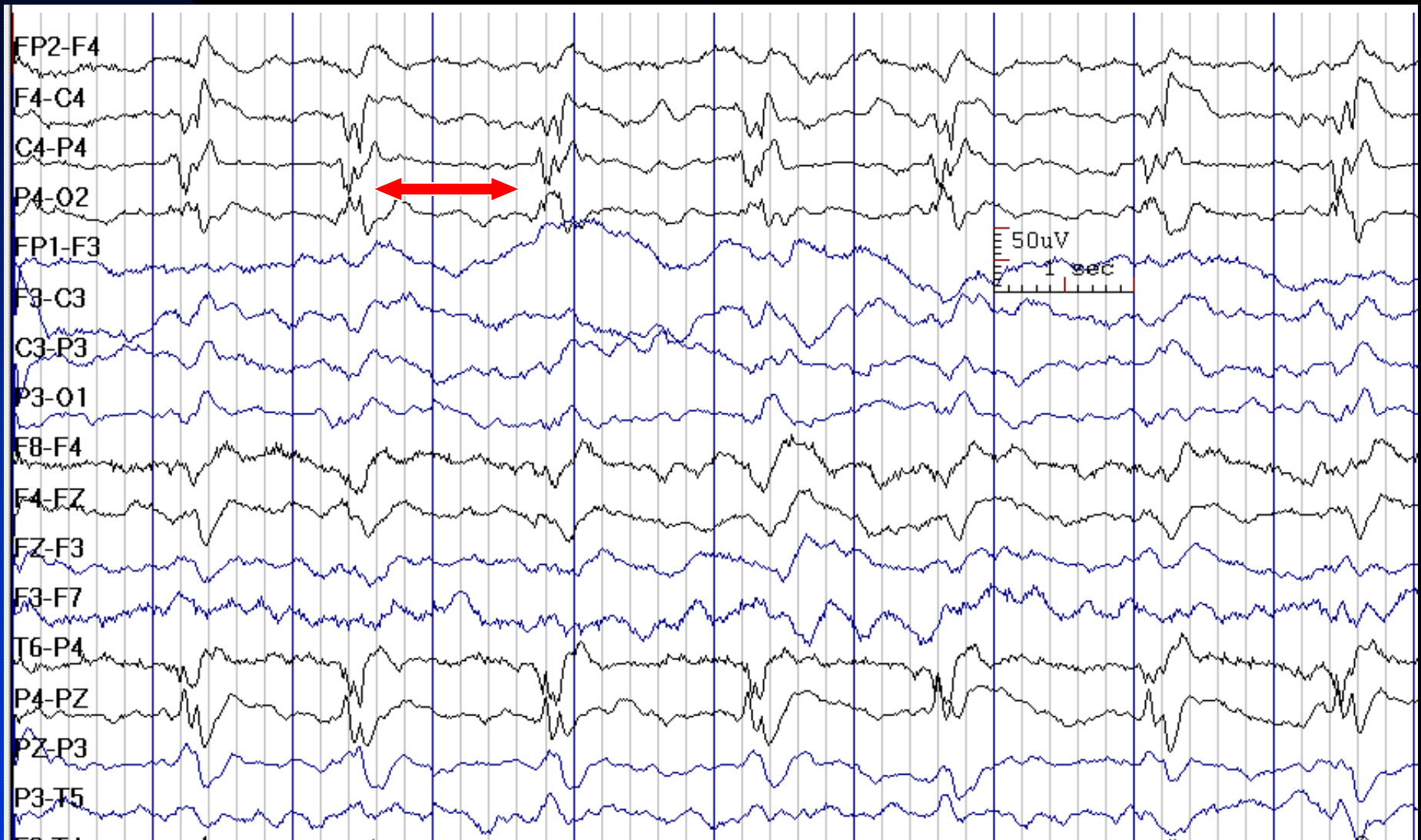
## ■ BiPLEDs (Bilateral independent PLEDs):

- ◆ **New terminology:** Bilateral periodic discharges (BPDs)
- ◆ **Etiology:** CNS infections, anoxia, severe chronic epilepsy
- ◆ **Significance:** Seizures occur in the majority of patients; mortality is high

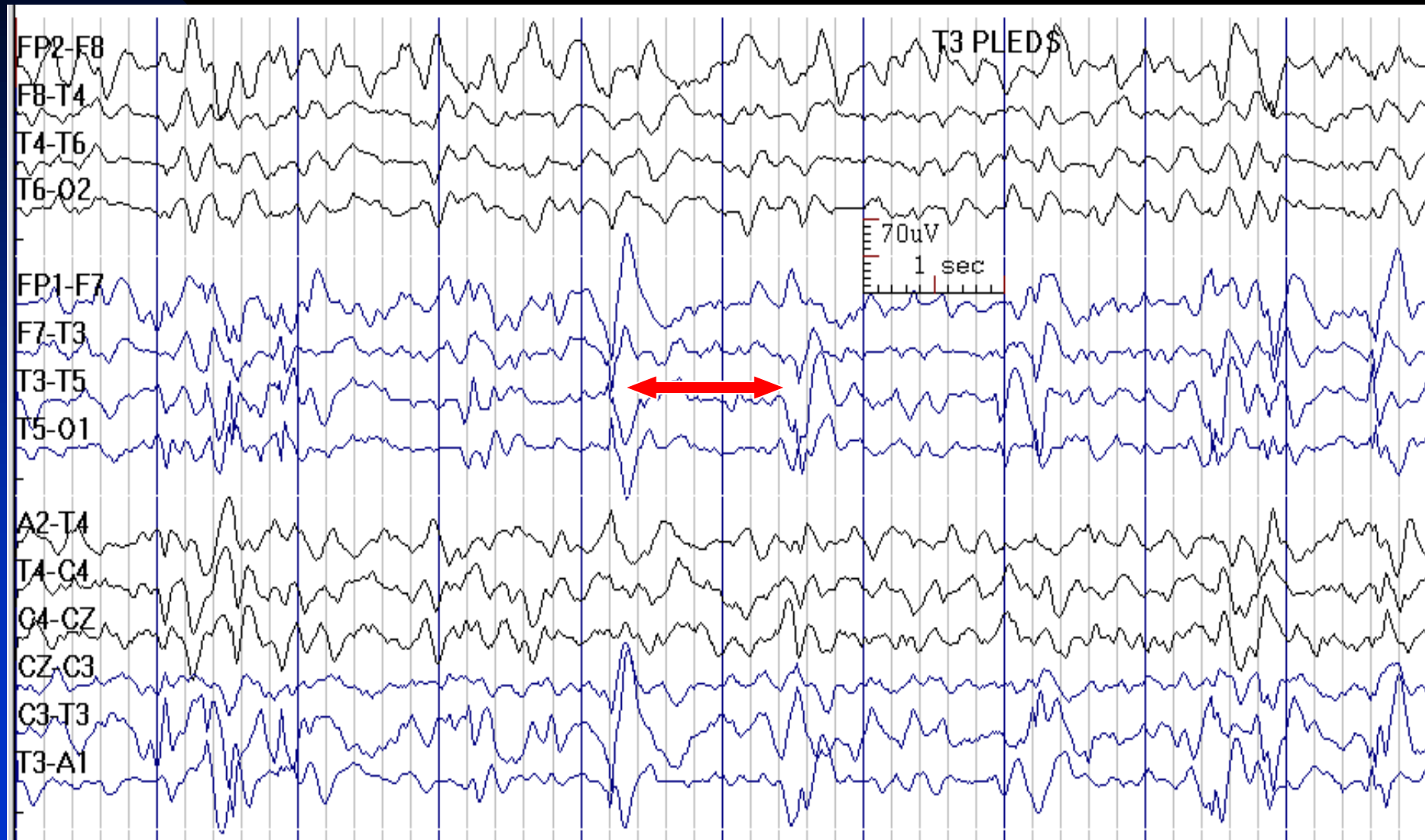
## ■ GPEDs (Generalized Periodic Epileptiform Discharges):

- ◆ **New terminology:** Generalized periodic discharges (GPDs)
- ◆ **Etiology:** severe bilateral brain damage (e.g., anoxia), Creutzfeldt-Jacob disease, refractory status epilepticus

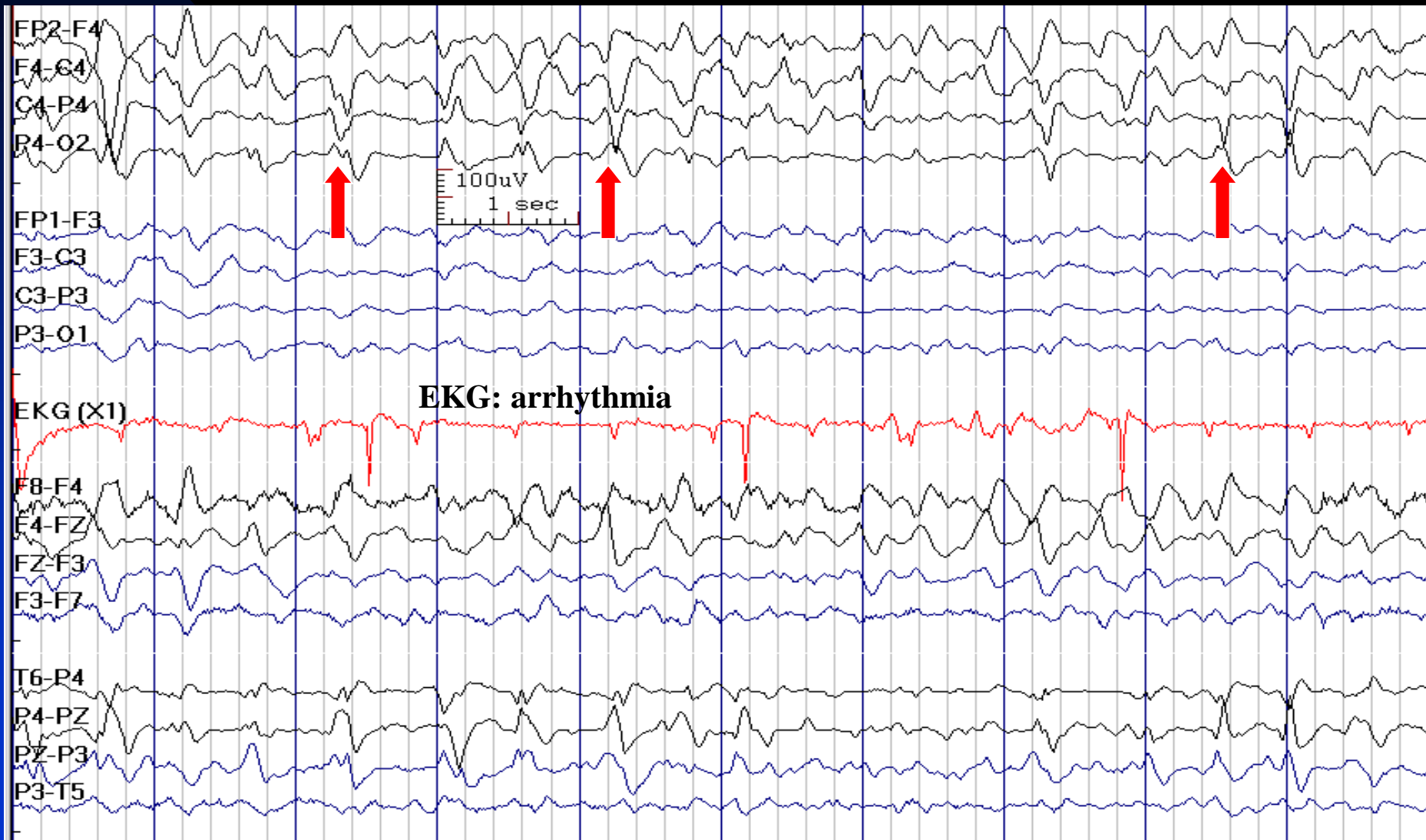
# P4 PLEDs in a 55-Year-Old Woman with Brain Metastasis



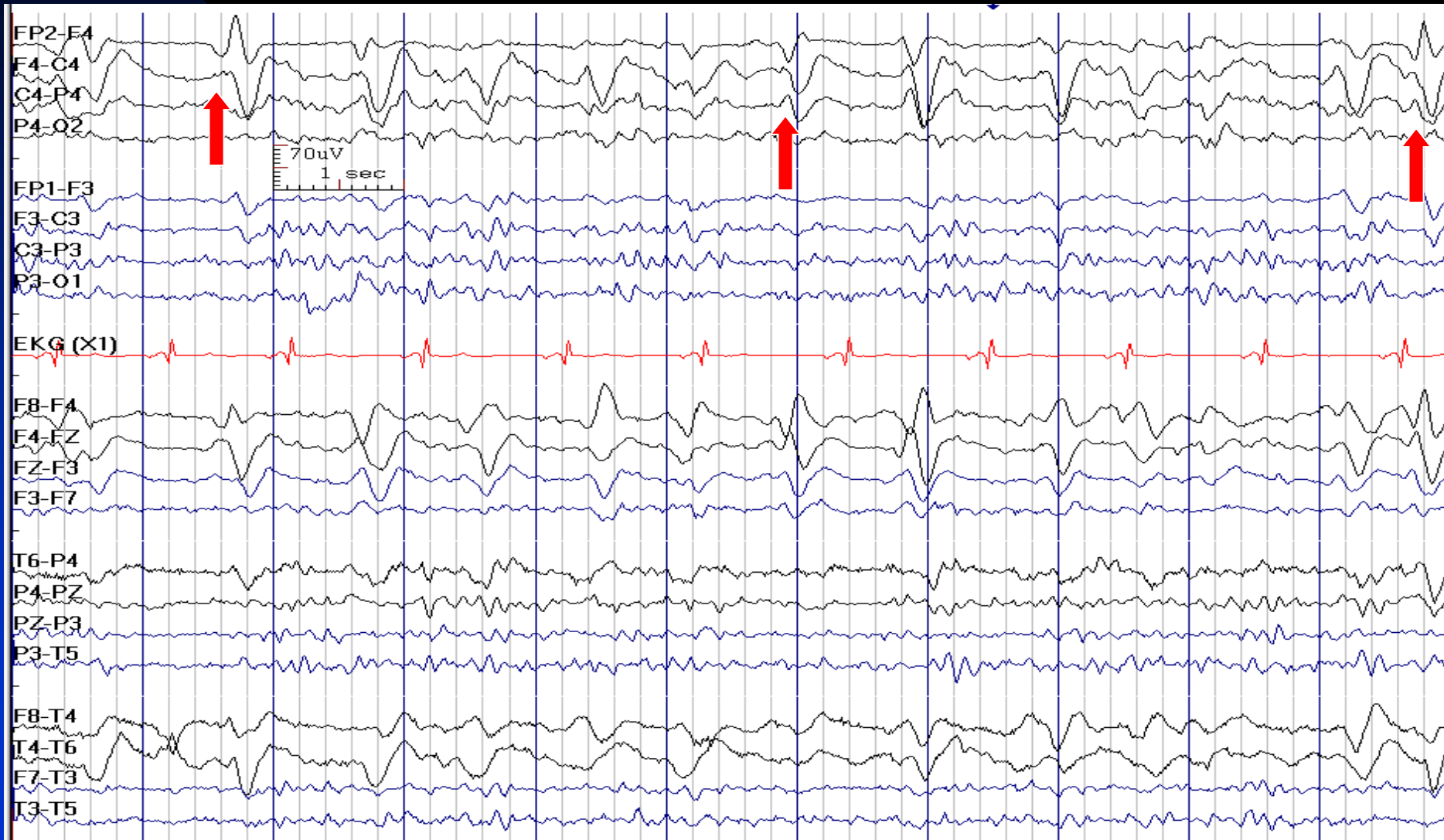
# T3 PLEDs in a 50-Year-Old Man with Kidney Transplant and Status Epilepticus



# P4 PLEDs in a 76-Year-Old Man with Hyperperfusion Syndrome after Right Carotid Endarterectomy



# F4 PLEDs in a 37-Year-Old Woman with Hemiplegic Migraine and Status Epilepticus

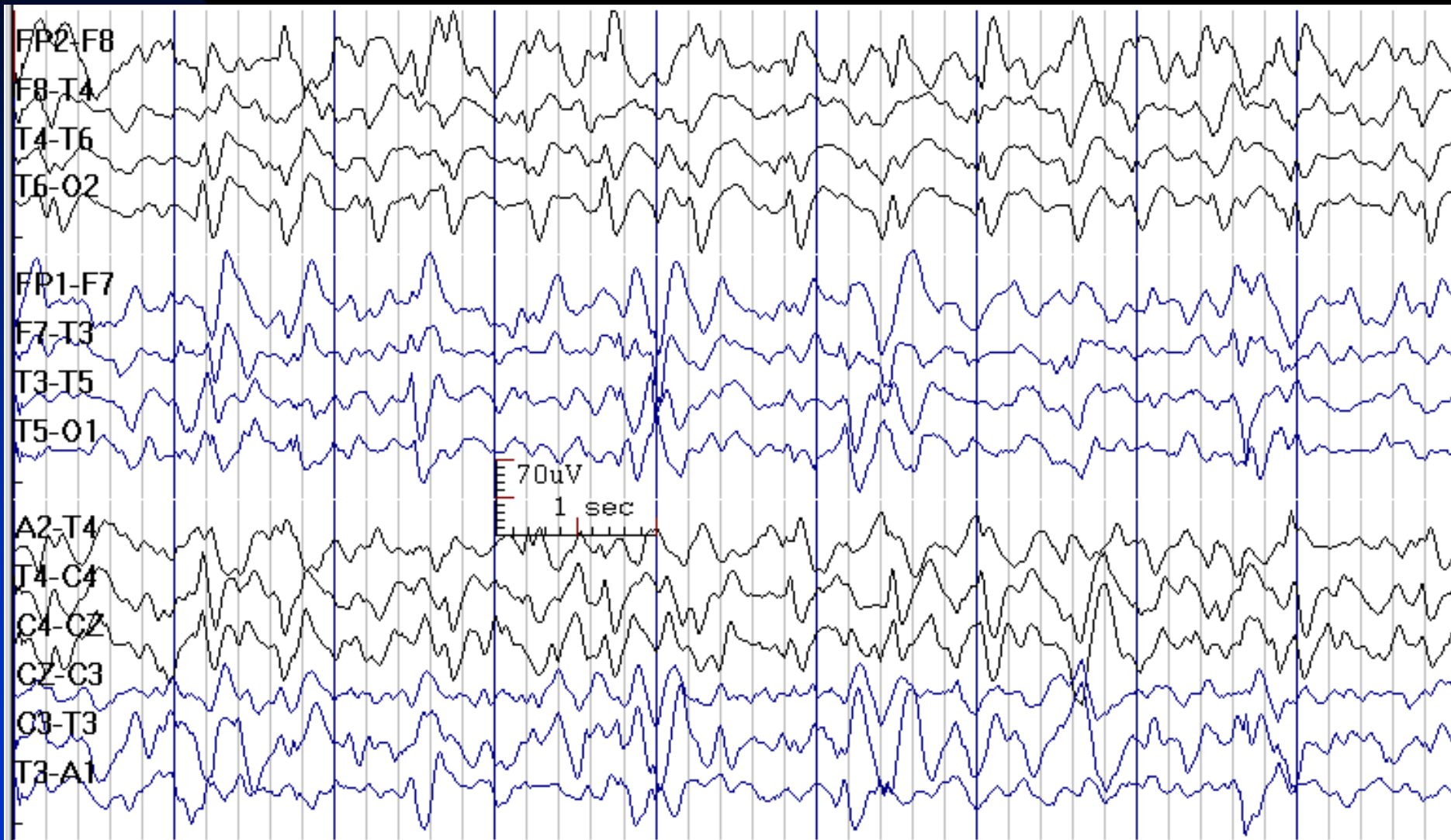


# How to Report PLEDs

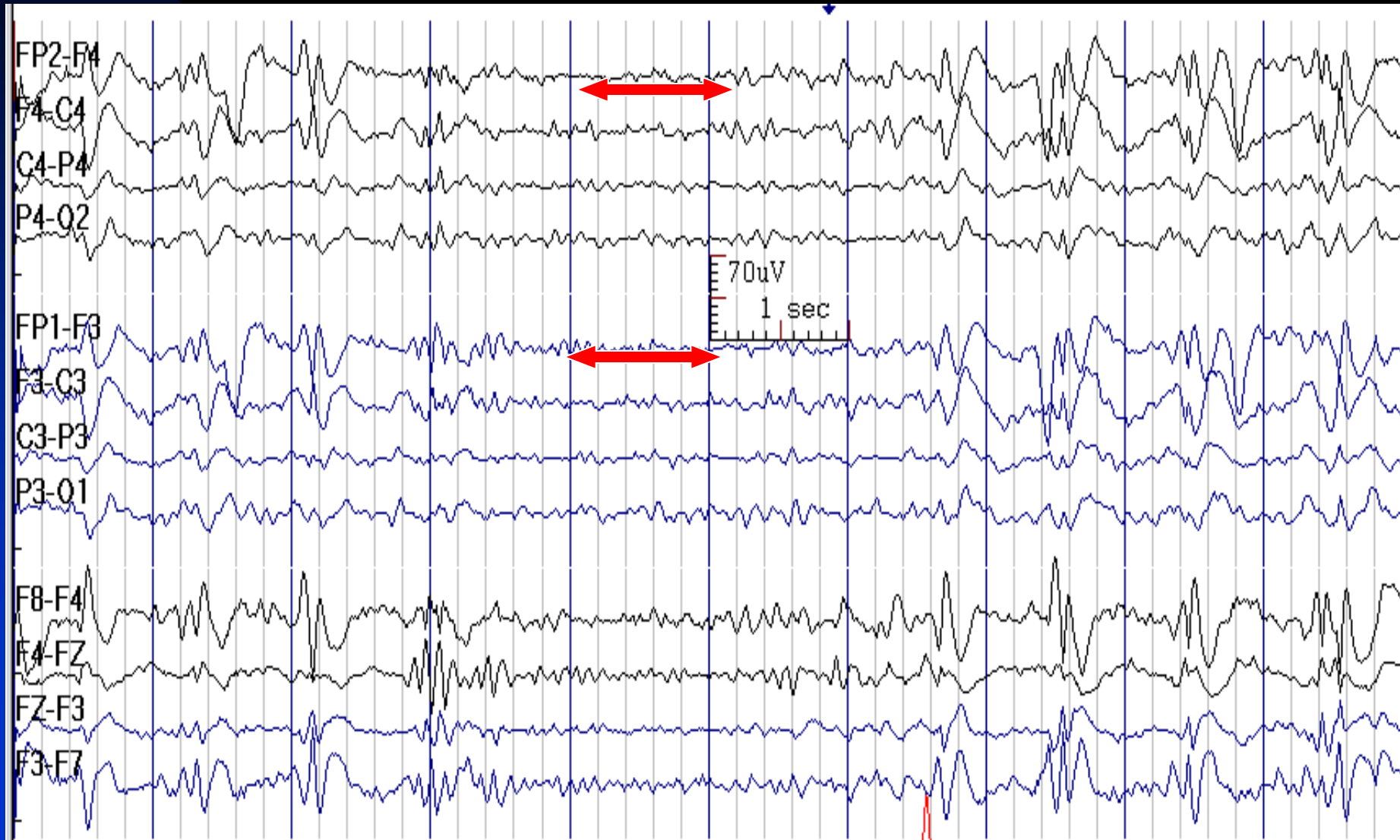
- *In conclusion section, write:*
  - ◆ This EEG shows \_\_\_\_ (location) PLEDs, which usually occur in the setting of an acute, large CNS lesion and is associated with seizures in 70-80% of patients.
- Note: If the patient's underlying problem is known, add this sentence:
  - ◆ In this patient, it is related to \_\_\_\_ (e.g., CVA, malignancies, herpes encephalitis).



# BiPLEDs (T3 and O2) in a 55-Year-Old Man With Refractory Status Epilepticus



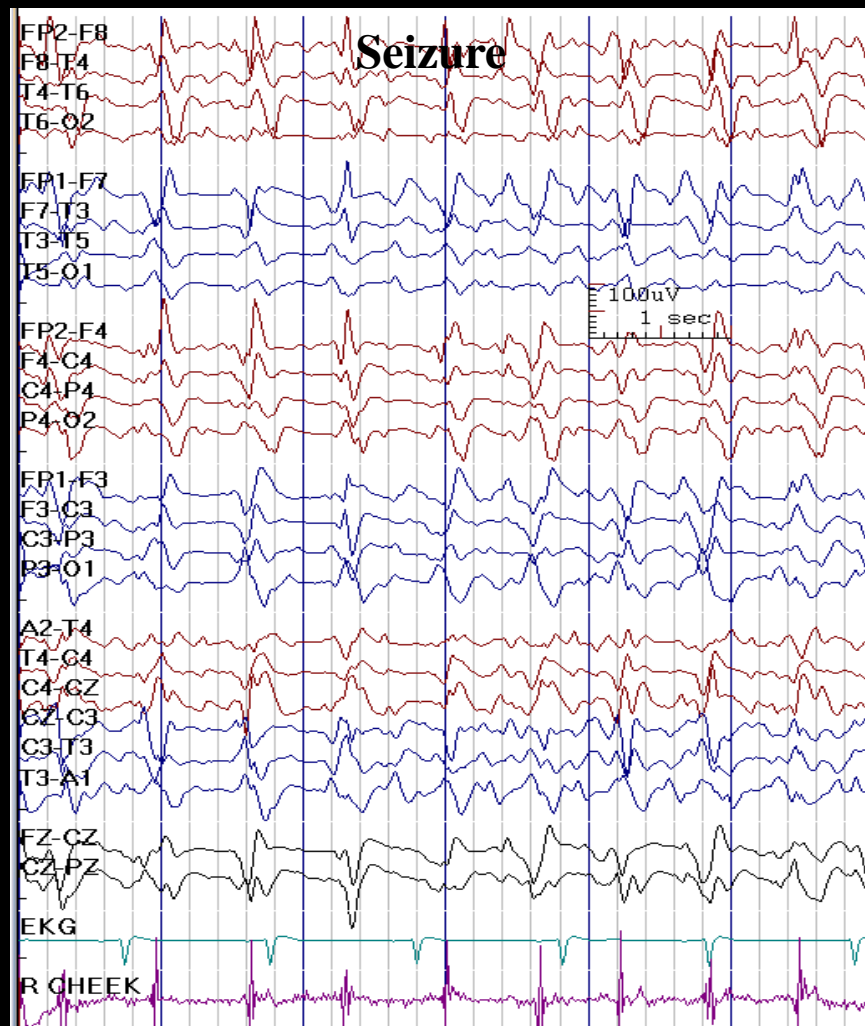
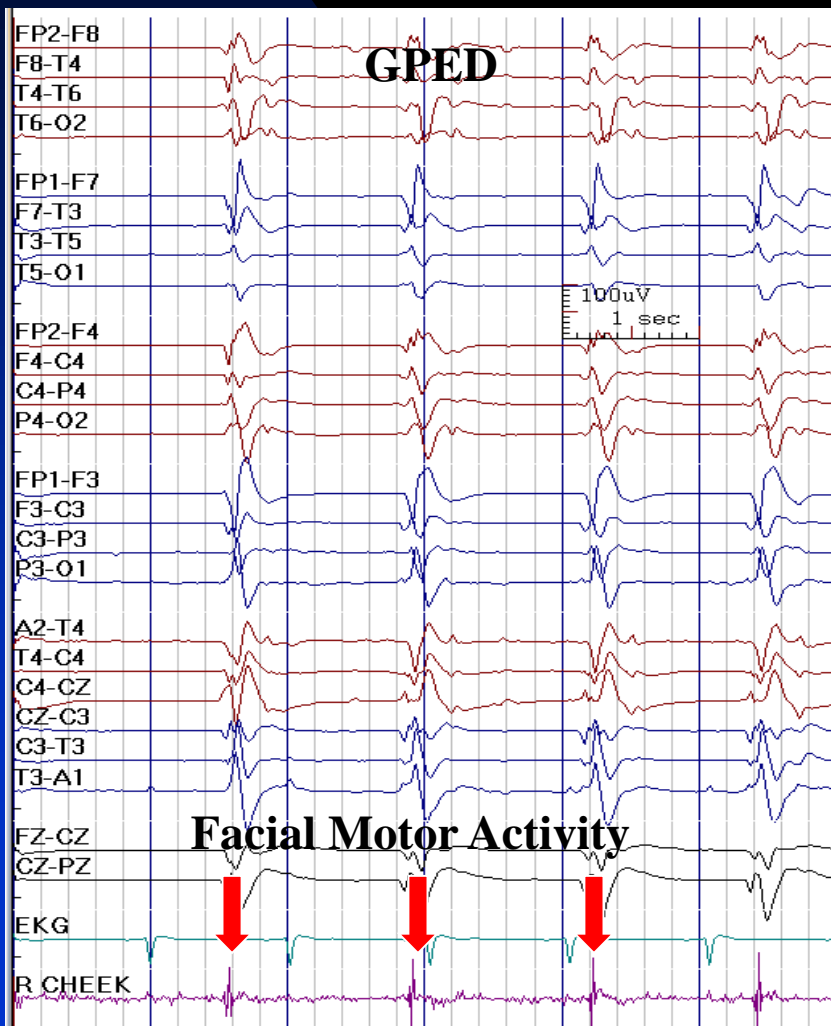
# GPEDs in a 51-Year-Old Man with Refractory Status Epilepticus



# GPEDs in a Patients with Status Epilepticus:

Sometimes They Are Ictal and Have Correlated Clinical Change:

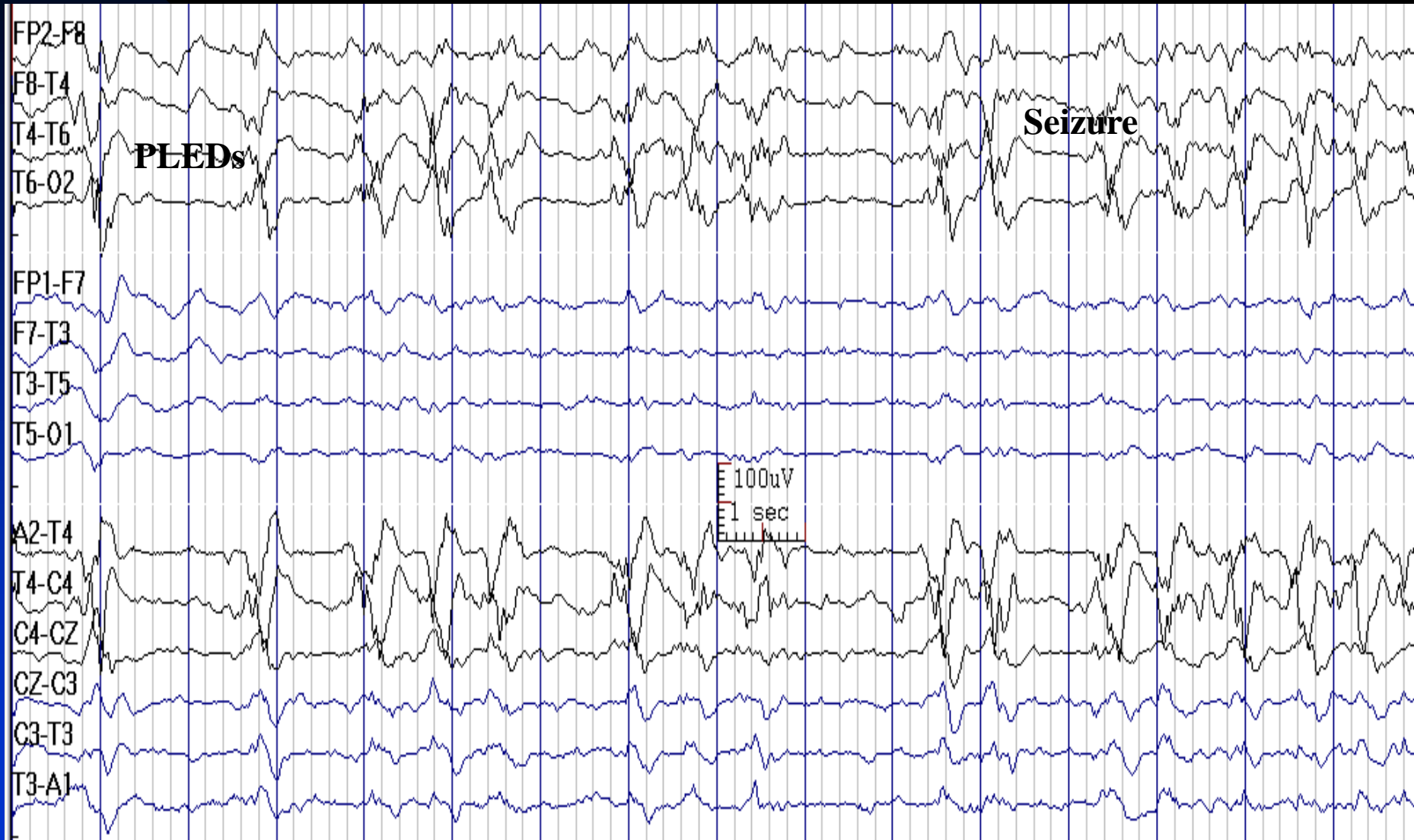Facial Motor Activity in This Patient



# How to Report GPEDs

- *In conclusion section, write:*
  - ◆ This EEG shows generalized periodic epileptiform discharges (GPEDs), which is often seen in the setting of severe bilateral brain injury. It is usually associated with a poor neurological prognosis.
- Note: If the patient's underlying problem is known, add this sentence:
  - ◆ In this patient, it is related to \_\_\_\_\_ (the underlying problem: e.g., anoxia, Creutzfeldt-Jacob disease or refractory status epilepticus).

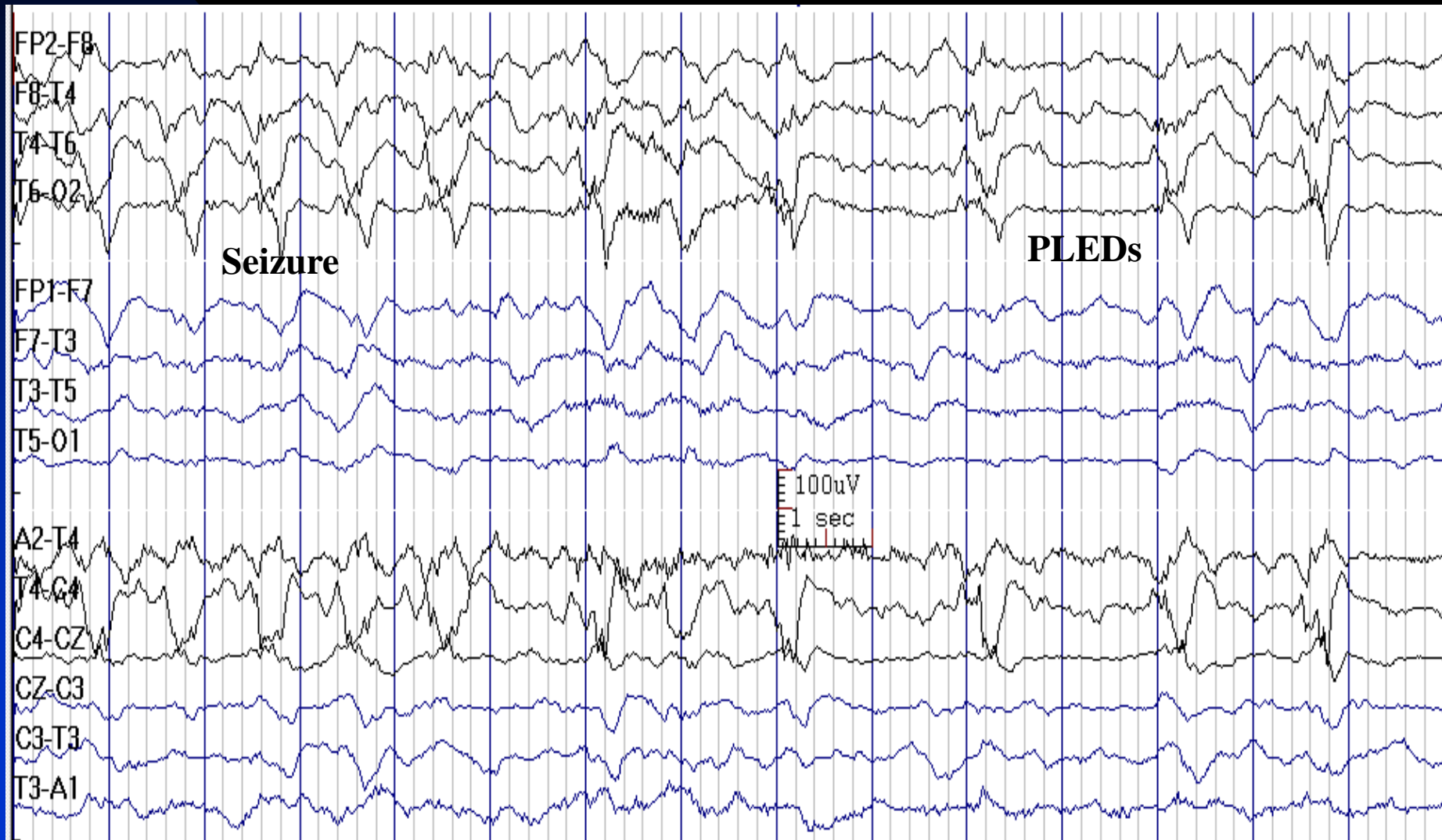
# Right Temporal PLEDs Evolving to Seizure in a 60-Year-Old Woman with CVA



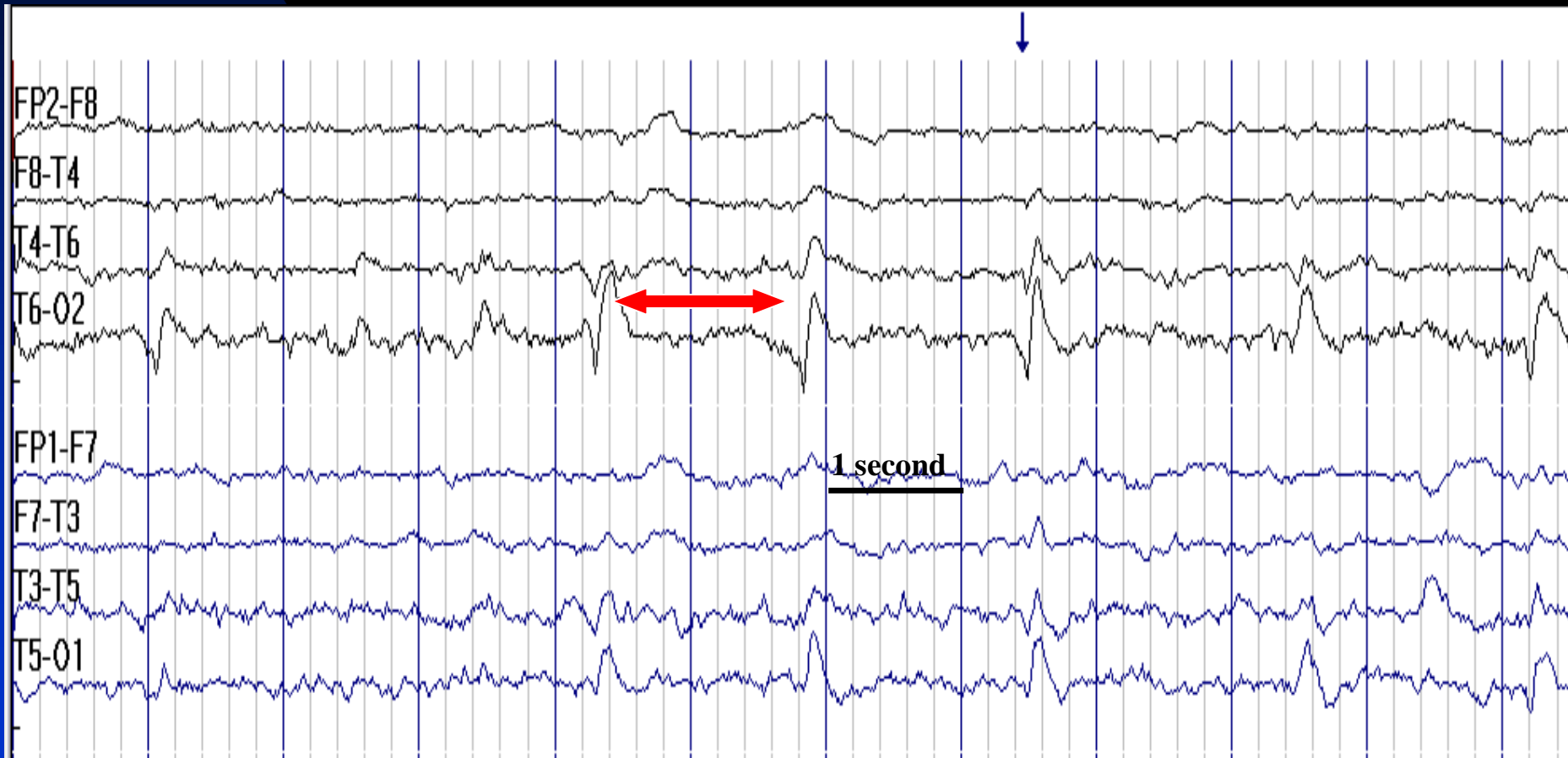Continues

# Seizure Ends and PLEDs Reappear Afterwards

(Previous Image)

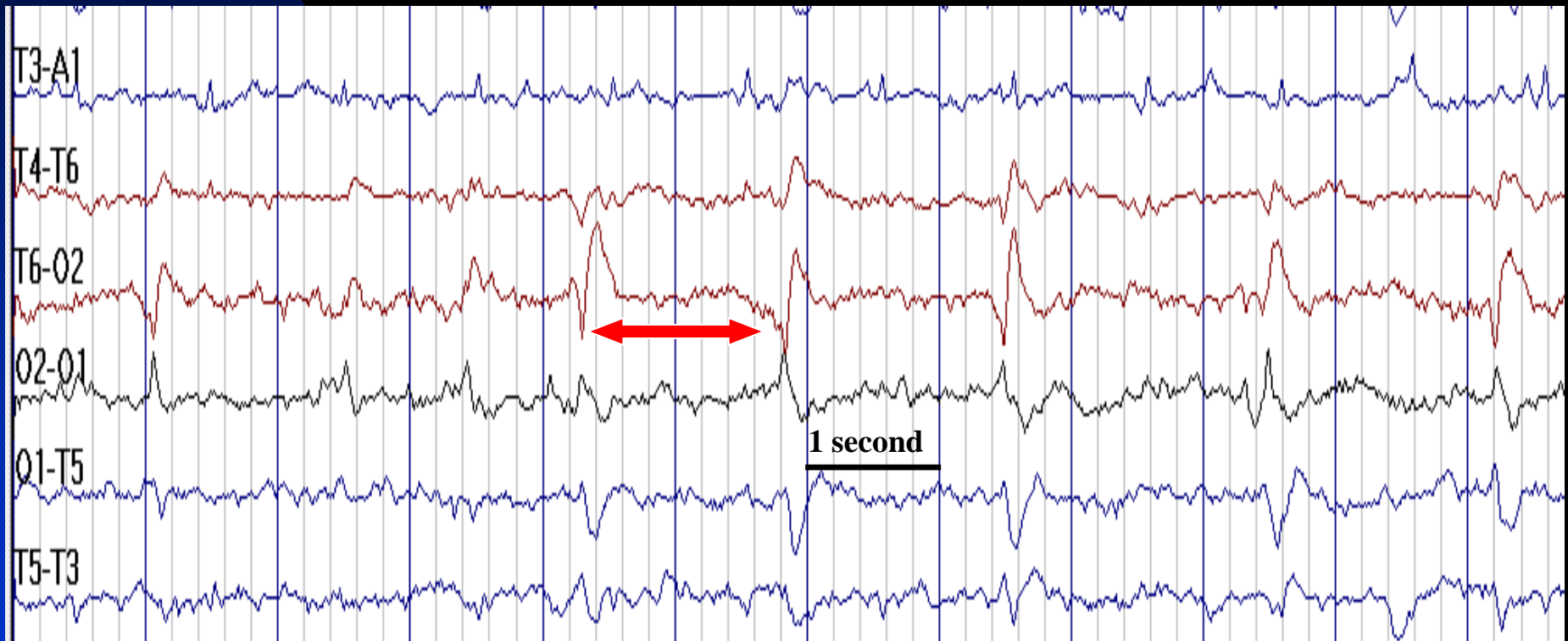


# O2 PLEDs after CVA in a 54-Year-Old Man



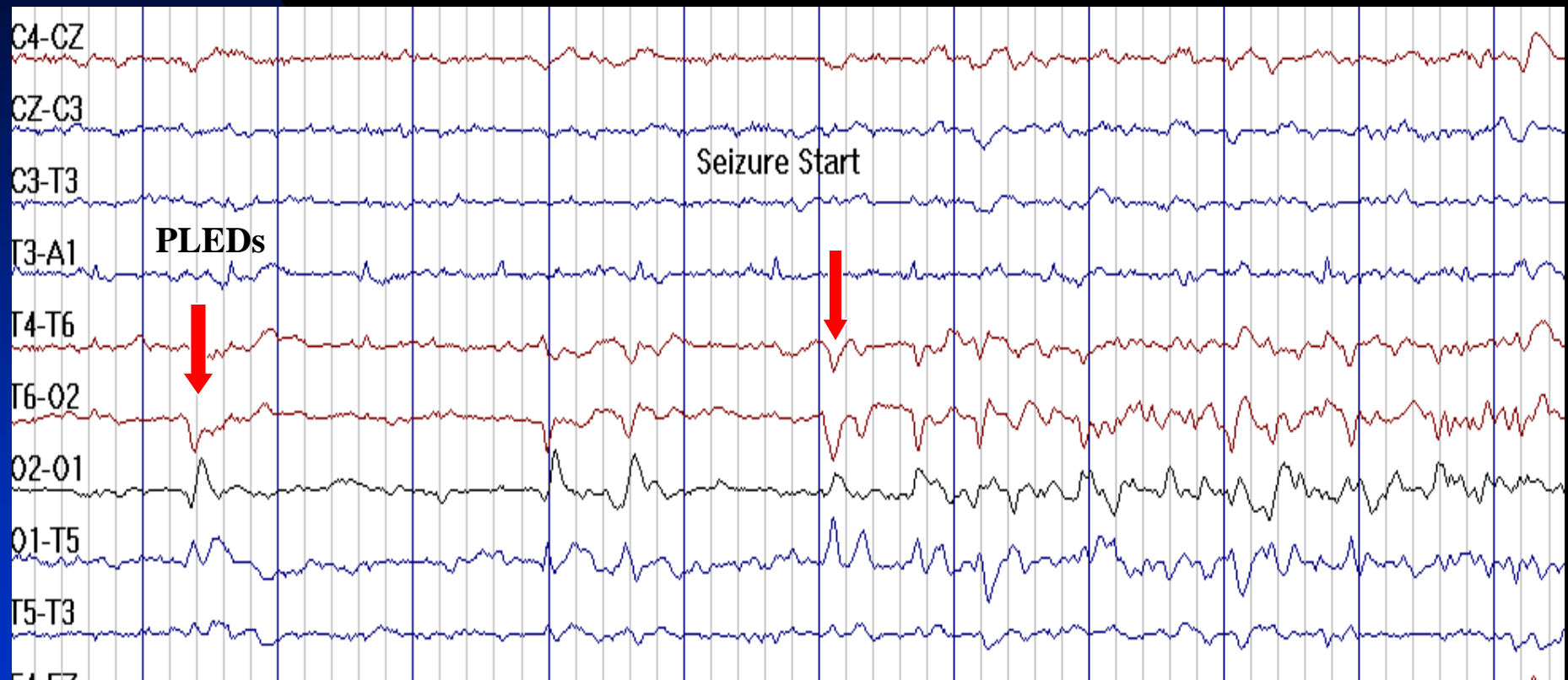

# O2 PLEDs after CVA in a 54-Year-Old Man in Bipolar Montage (Circle Montage)

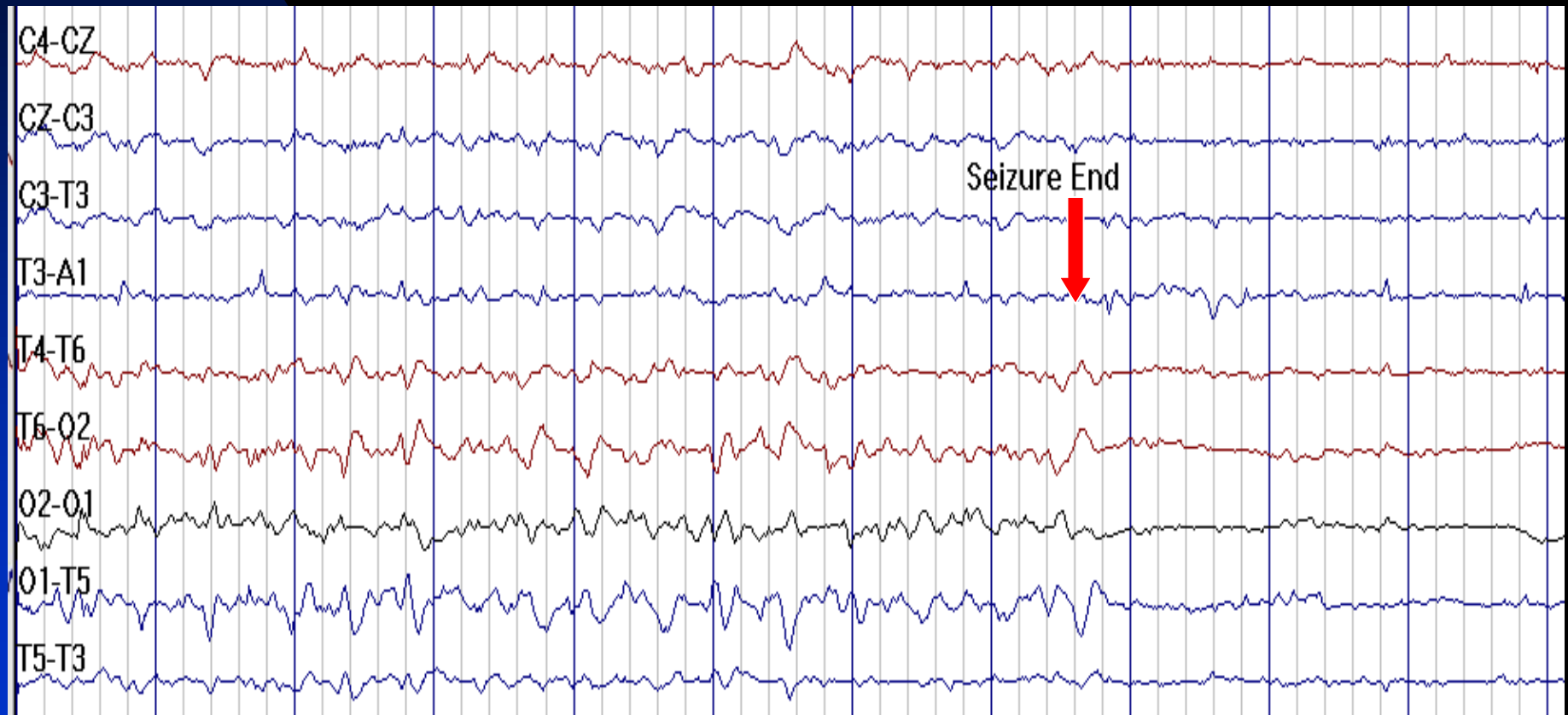




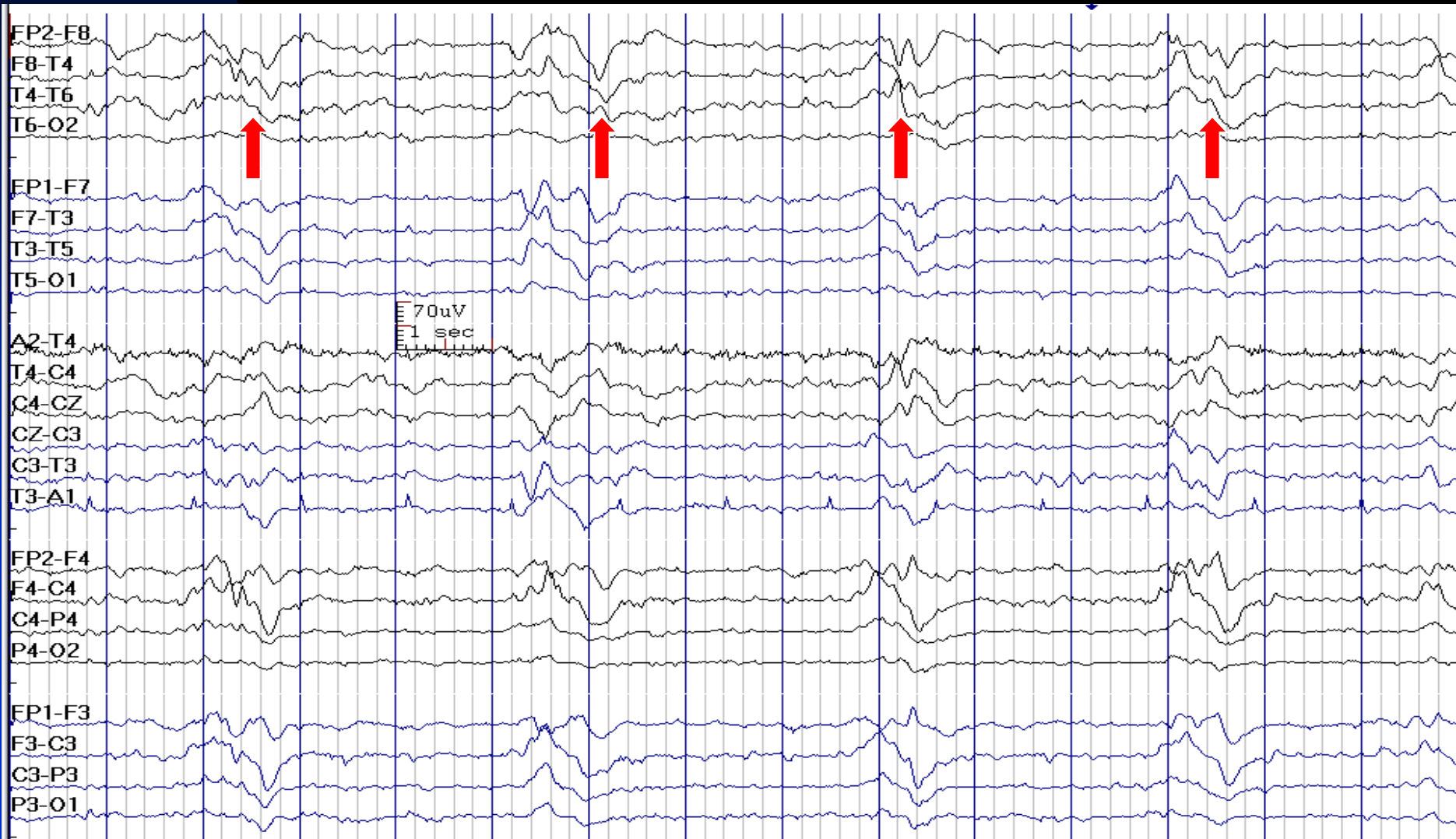
# O2 PLEDs Evolving into Partial Seizure in a 54-Year-Old Man with CVA



# End of Partial Seizure at O2 with Postictal Attenuation of the Background



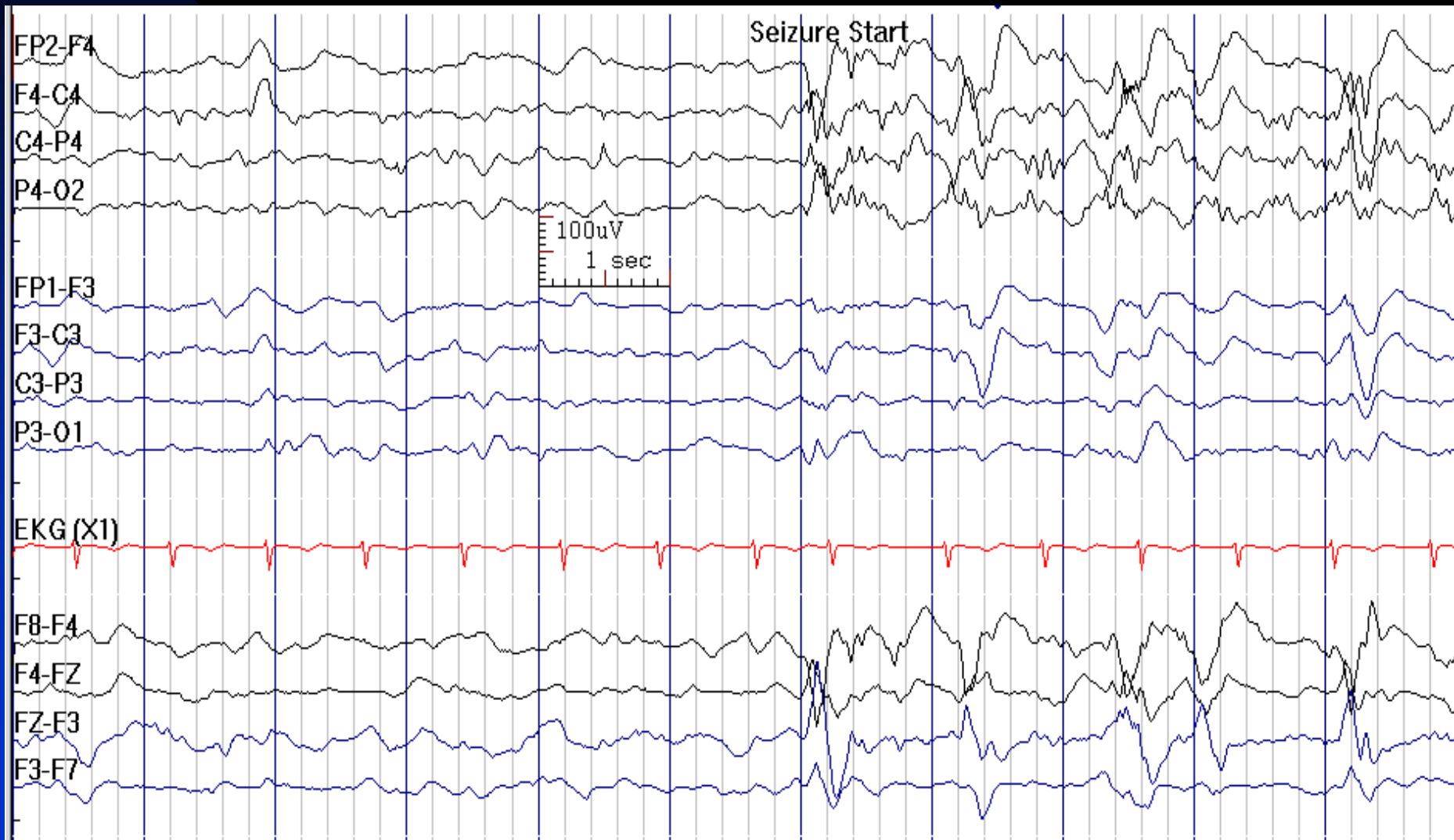
# Periodic Complexes in a 39-Year-Old Man with Cerebral Injury 9 Years After a Prolonged Status Epilepticus



# Status Epilepticus

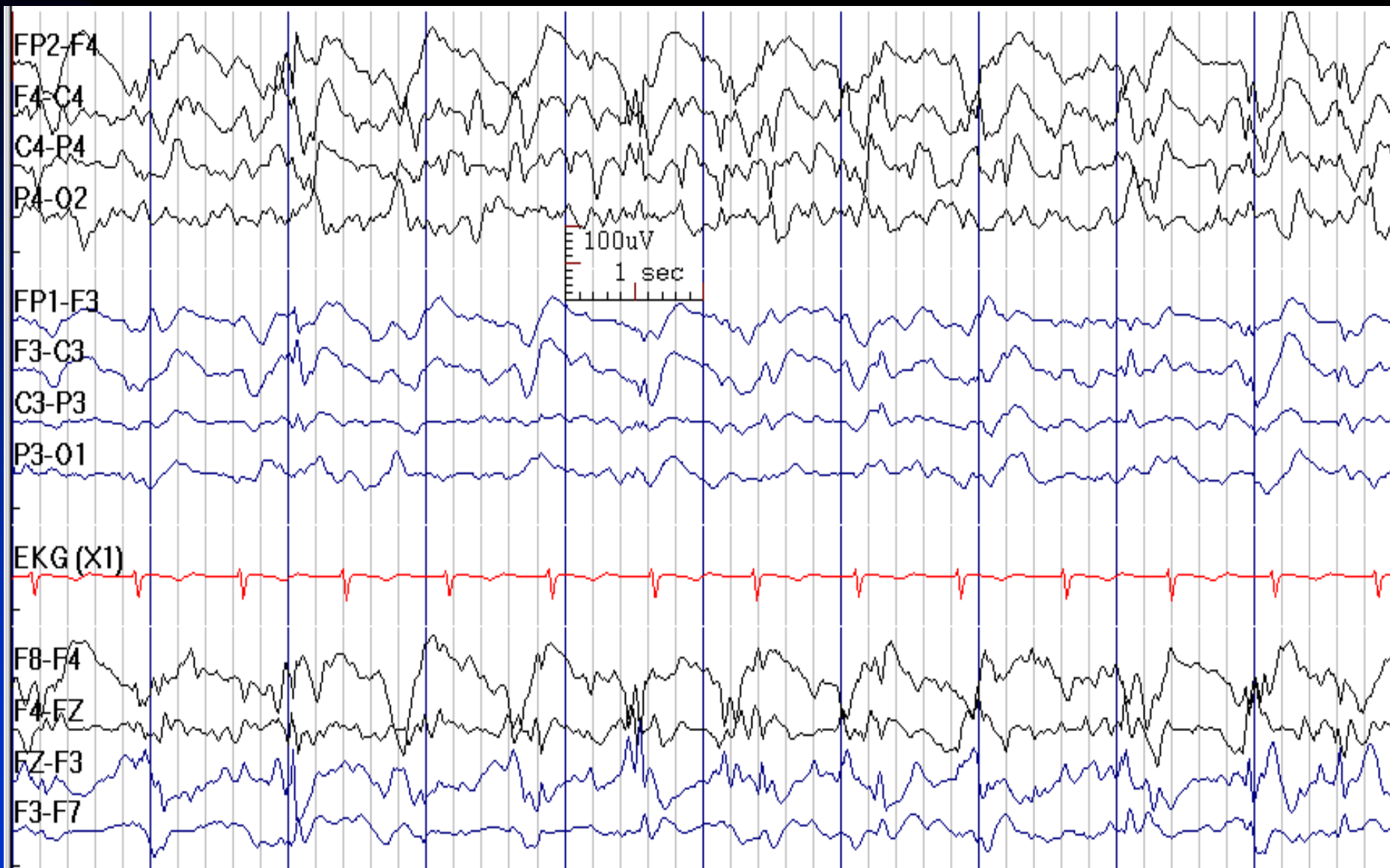
- **Status epilepticus:** SE is defined as a condition in which epileptic seizures continue (> 5-10 minutes) or are repeated without recovery to baseline

# F4 Onset Seizure, Spreading to P4 in a 88-Year-Old Woman With SE (Repeated Seizures Without Returning to Baseline)



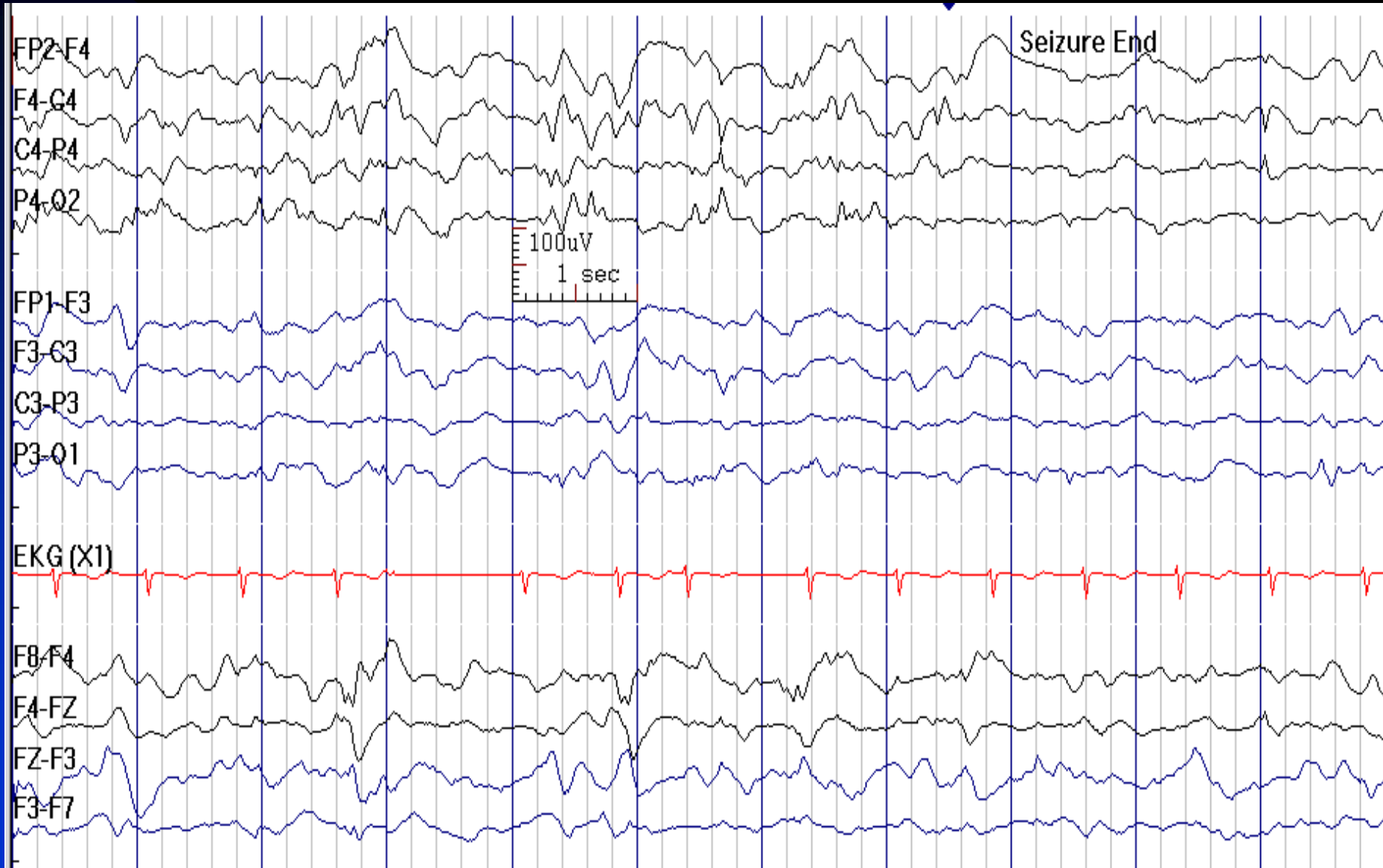
Continues

# Seizure Continues



Continues

# Seizure Ends



# EEG in Status Epilepticus

- Supplements clinical examination and helps confirm the diagnosis of status (vs. PseudoSE)
- Aids in assessing efficacy of treatment



# EEG in Generalized Convulsive SE

- A predictable sequence of EEG progression occurs during GCSE:
  - ◆ Discrete seizures and interictal slowing: often accompanied by overt generalized tonic-clonic seizures
  - ◆ Continuous ictal sharp or spike-wave discharges: continuous clonic jerks or subtle clonic movements during this time
  - ◆ Continuous ictal discharges with episodes of generalized flattening: overt or subtle clonic movements may be seen, or the patient may have no motor symptoms
  - ◆ Finally, periodic epileptiform discharges superimposed on a relatively flat background

# New Definition of Non-Convulsive SE

- Patients without known epileptic encephalopathy:
  - ◆ Epileptiform discharges (EDs) (spikes, poly-spikes, sharp-waves, sharp-and-slow-wave complexes) > 2.5 Hz, or
  - ◆ EDs  $\leq$  2.5 Hz or rhythmic delta/theta activity (>0.5 Hz) AND one of the following:
    - ★ EEG and clinical improvement after IV AED, or
    - ★ Subtle clinical ictal phenomena during the EEG patterns mentioned above, or
    - ★ Typical spatiotemporal evolution
- Patients with known epileptic encephalopathy:
  - ◆ Increase in prominence or frequency of the features mentioned above, when compared to baseline with observable change in clinical state
  - ◆ Improvement of clinical and EEG features with IV AEDs
- Clinical symptoms/signs raising suspicion of NCSE have to last at least 10 min

# EEG and Treatment in SE

- Use EEG to verify that treatment objective is met
  - ◆ Burst-suppression is not always needed
  - ◆ Burst-suppression pattern does not mean treatment is efficacious
- Monitor EEG for 24-48 hours in the absence of rapid complete recovery
- Even if recovered, monitoring may be advantageous, e.g., to diagnose intermittent seizures

## Chapter 8

# Non-epileptiform EEG Abnormalities

- Slow activity
- Periodic patterns

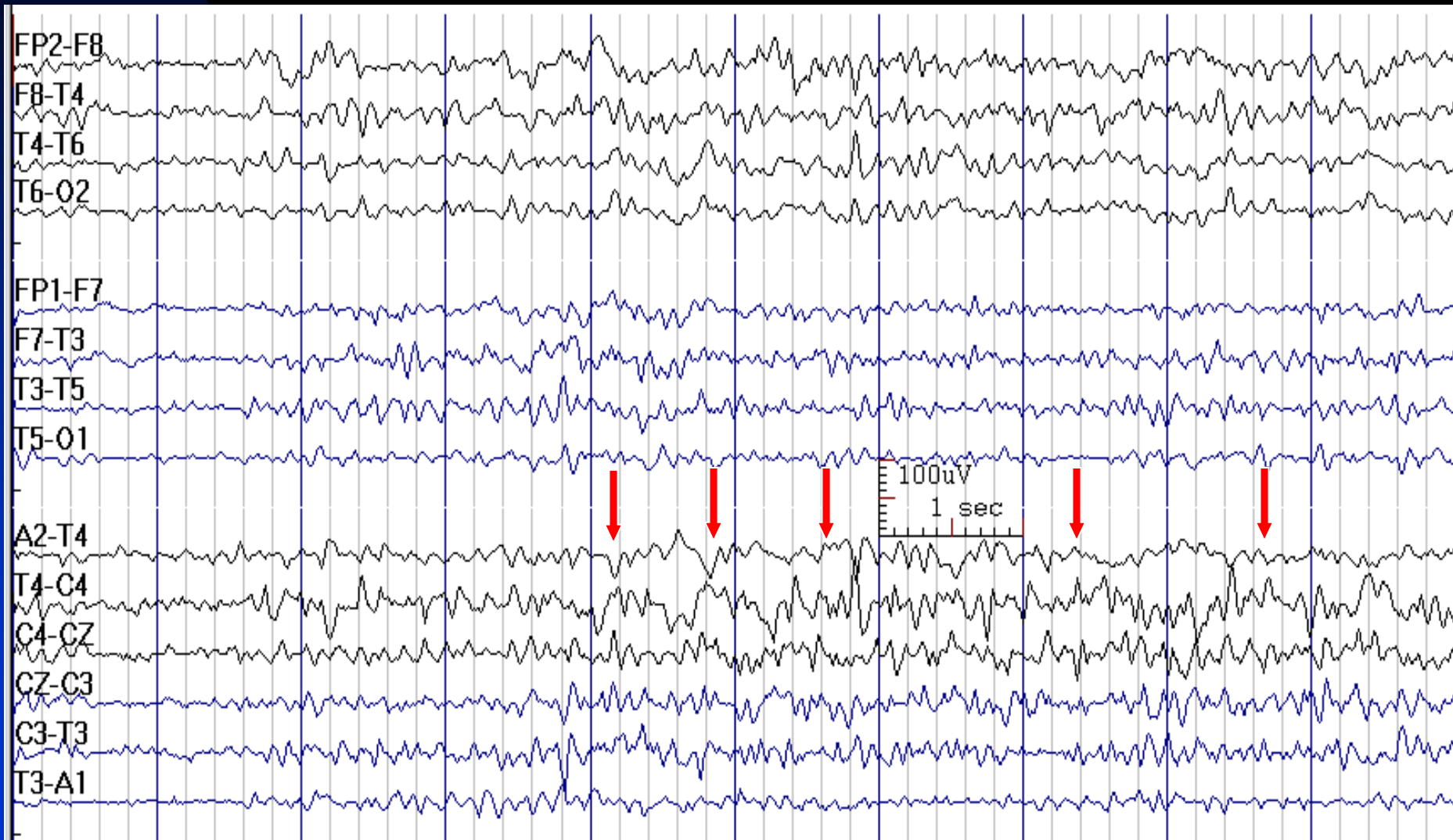
# Identifiers for Slow Activity

- **Distribution:** generalized, focal
- **Abundance:** occasional, intermittent (frequent), continuous (almost more than 80% of the recording)
- **Morphology:**
  - ◆ polymorphic or arrhythmic (irregular in shape, duration and frequency)
  - ◆ rhythmic (regular in shape with stable duration and frequency)
- **Frequency**
- **Reactivity:** to physiological state change or alerting stimuli

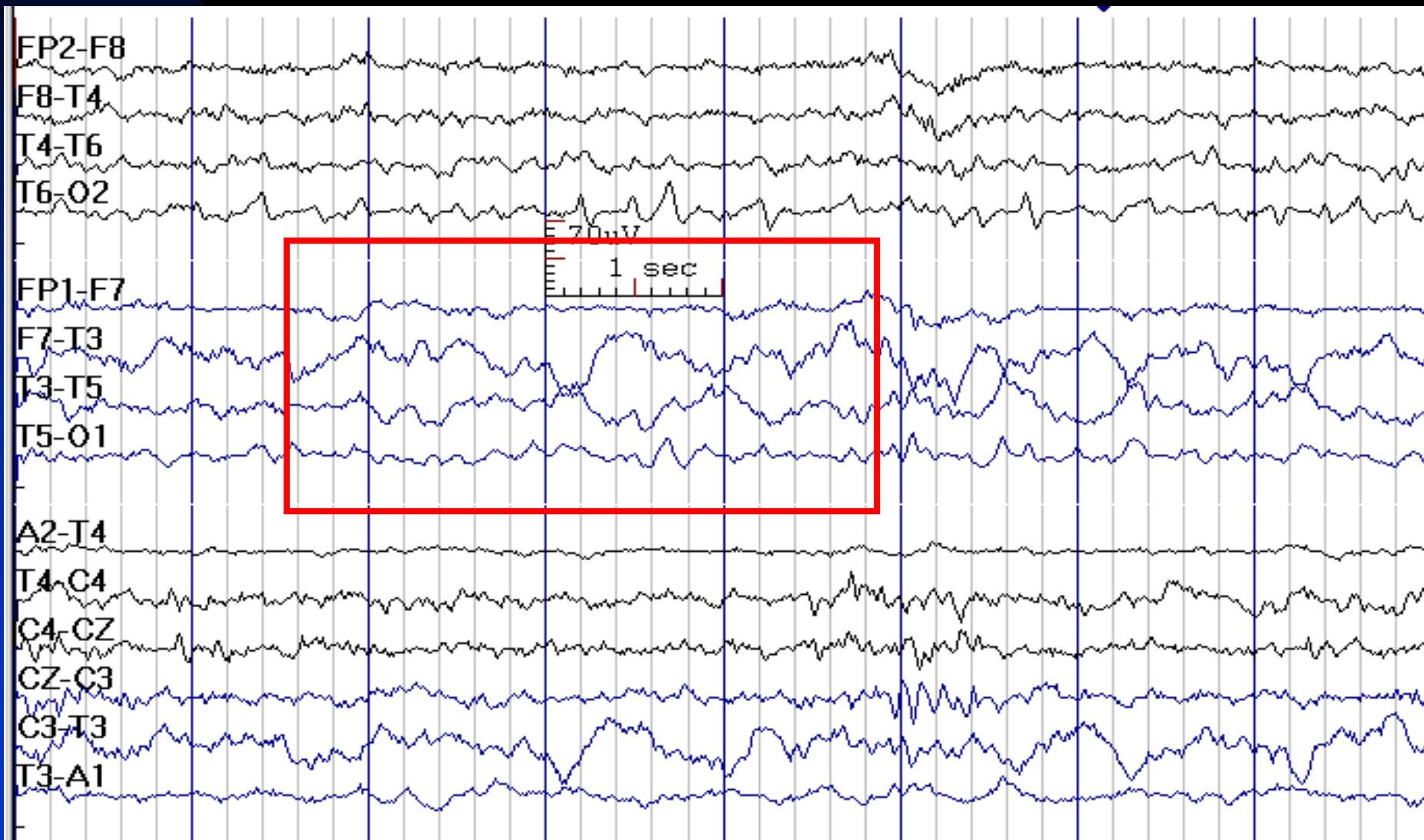
# Focal Polymorphic Delta Activity

- **Continuous:** usually due to a localized structural lesion (e.g., tumor, stroke, abscess)
- **Intermittent or occasional:** non-specific finding (migraine, trauma, postictal dysfunction, etc.)
- **Note:** occasional focal theta and delta activity (rhythmic or arrhythmic) over temporal regions, especially the left, in persons over 50 years of age is common. It is considered as **benign focal slow wave activity of the elderly**
- **Note:** Reviewing EEG at 20 seconds per page compresses the EEG visually and can be used for better visualization of low amplitude, subtle, focal slow waves

# Continuous Focal (T4) Polymorphic Delta Activity in a 44-Year-Old Man after Right Temporal Lobectomy

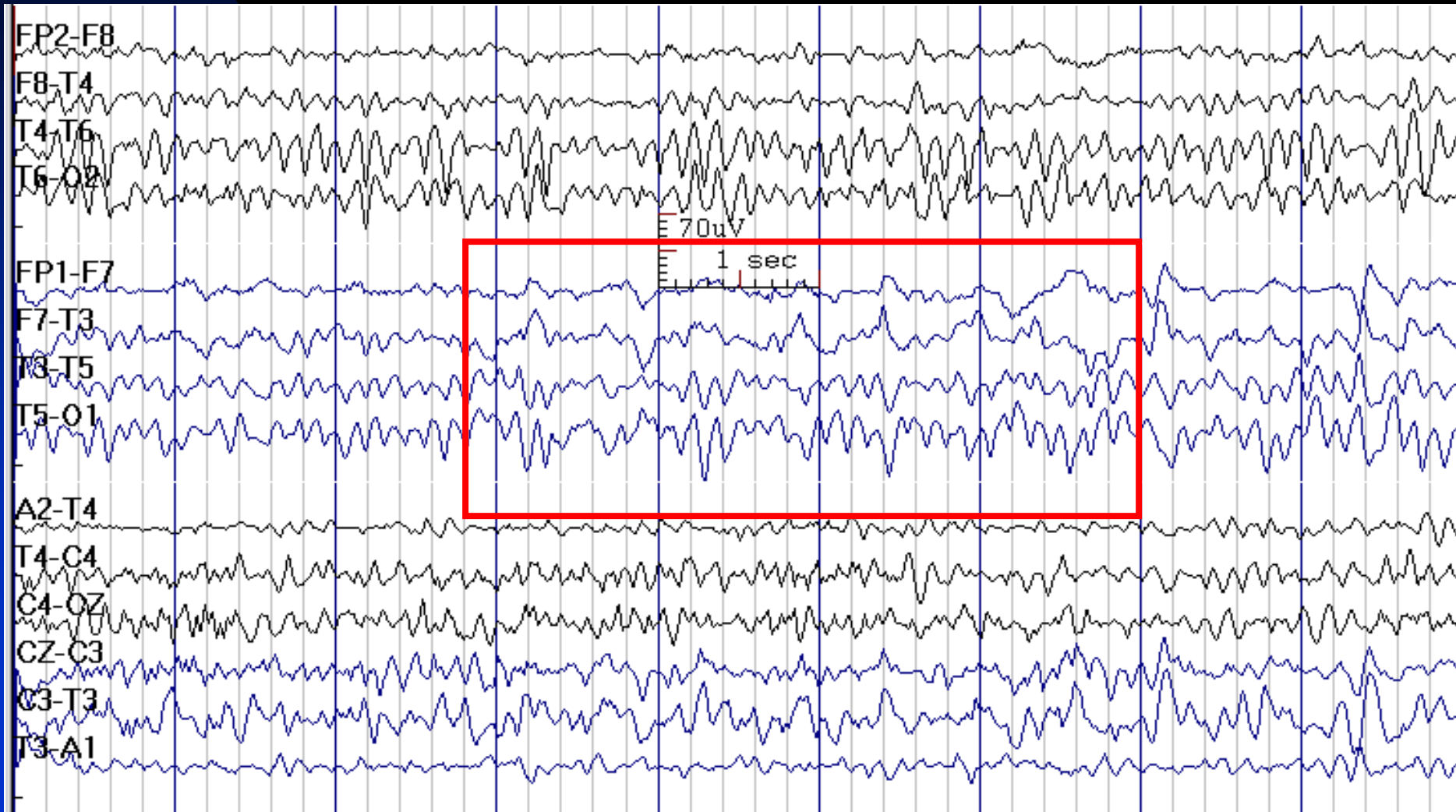


# Continuous T3 Polymorphic Delta Activity after Left Temporal Lobectomy

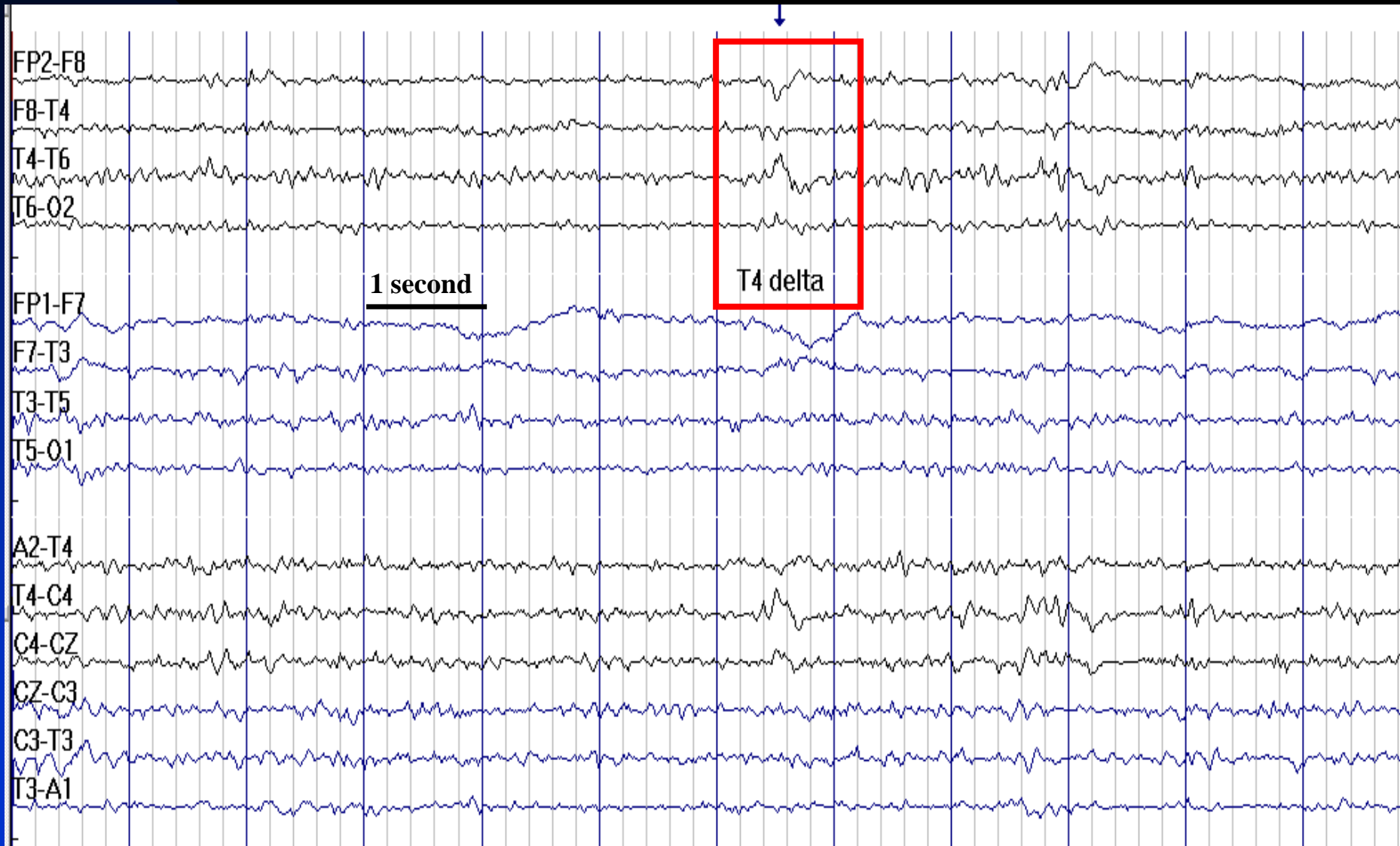




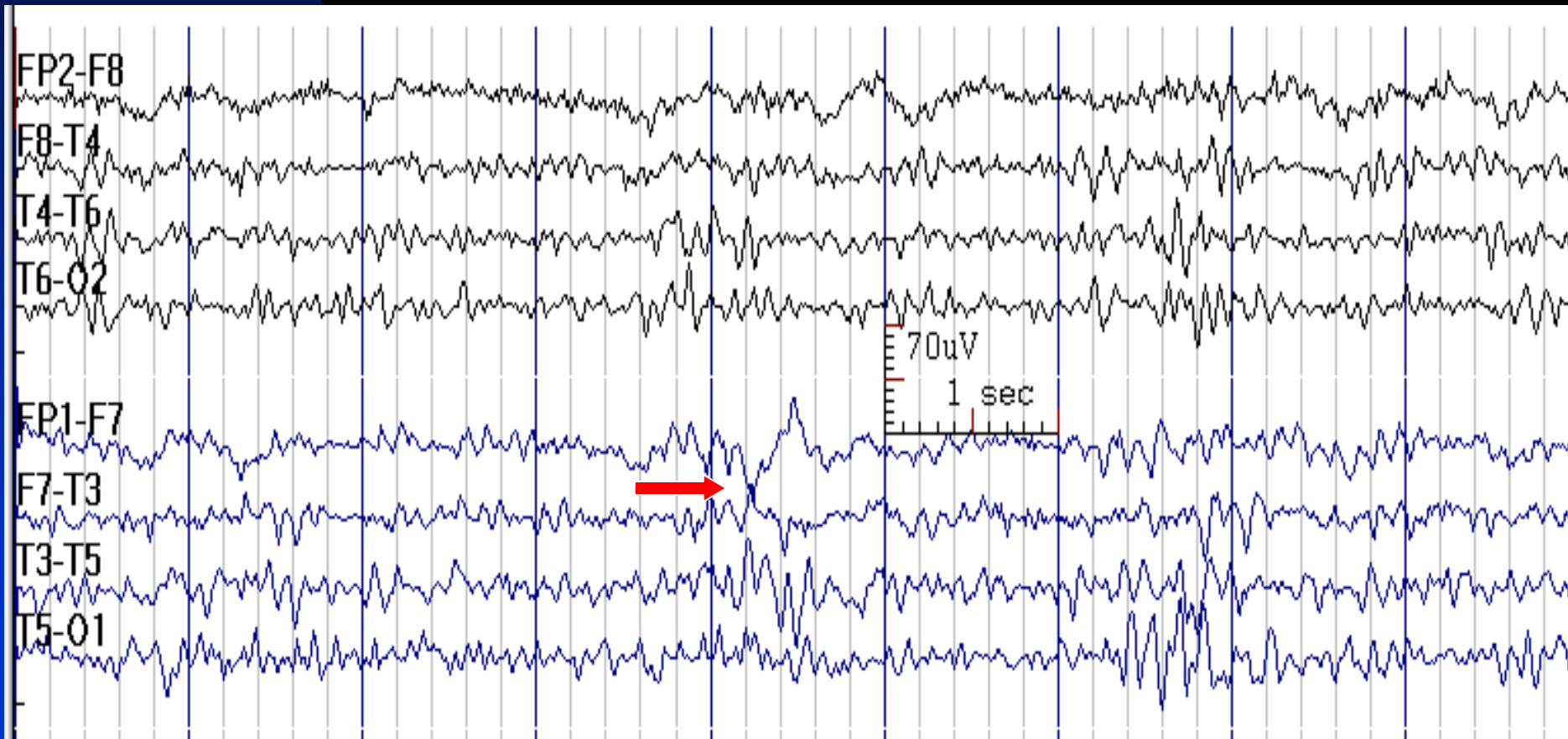
# Continuous T3 Polymorphic Delta Activity in a 26-Year-Old Man with Periventricular Nodular Heterotopia



# Intermittent Focal (T4) Polymorphic Delta Activity in a 28-Year-Old Man with Post-Traumatic Epilepsy



# Intermittent Focal (F7) Polymorphic Delta Activity in a 35-Year-Old Man with Temporal Lobe Epilepsy



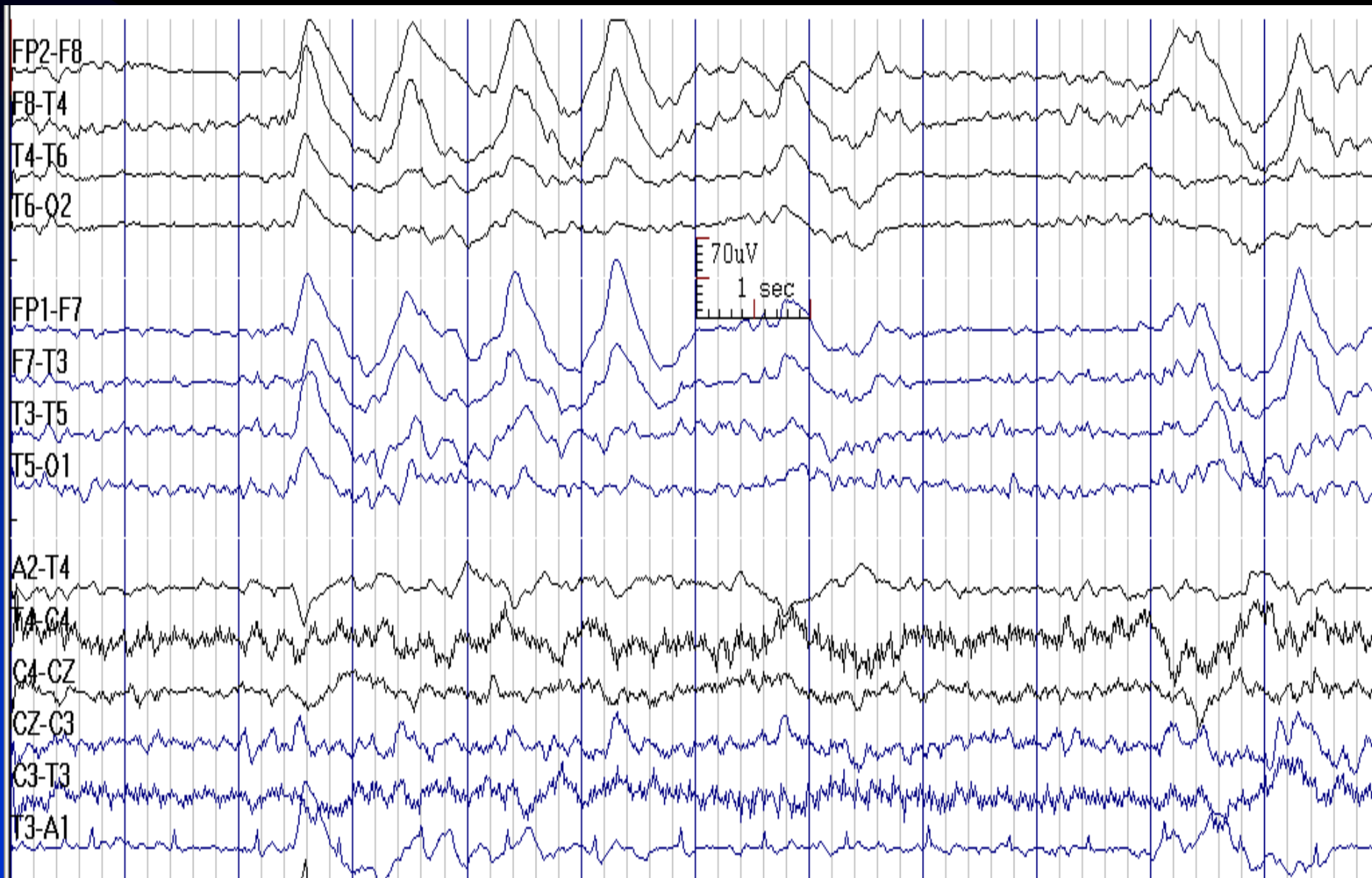
# How to Report Focal Slow Activity

- *In conclusion section, write:*
  - ◆ **Continuous Focal Polymorphic Slow Waves:** Focal slow waves suggest the presence of a structural lesion in the \_\_\_\_ lobe affecting subcortical white matter, which may be due to \_\_\_\_\_.
  - ◆ **Occasional or Frequent Focal Polymorphic Slow Waves:** This EEG suggests a focal cerebral dysfunction in \_\_\_\_ area (or lobe), which could be due to a structural lesion, postictal state, migraine, or other causes.
- If an underlying etiology is known, relate it to that cause if plausible.

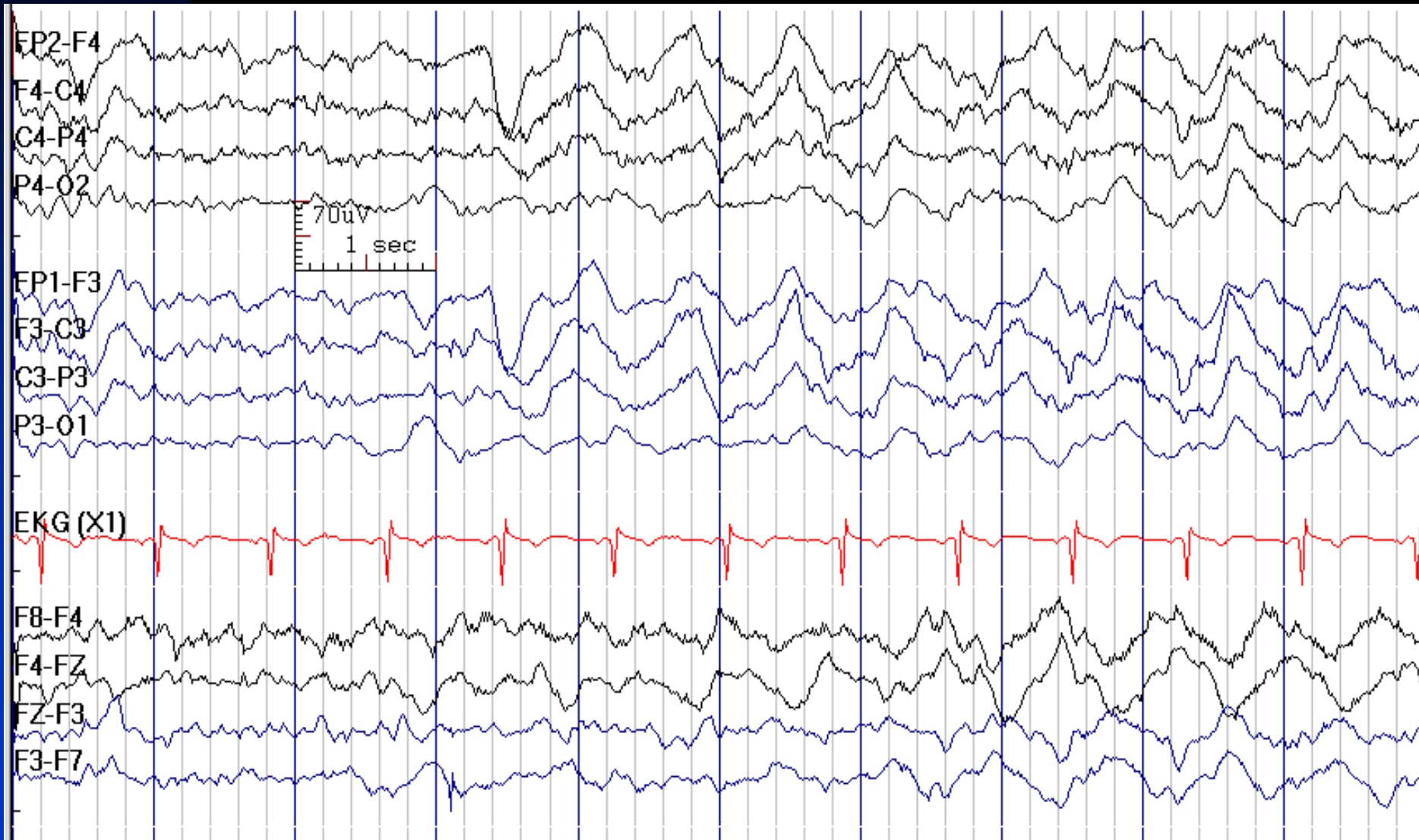
# Intermittent Rhythmic Delta Activity

- Runs of high-voltage, slow waves of relatively fixed frequency and waveform
- **FIRDA (Frontal Intermittent Rhythmic Delta Activity)**: non-specific finding, more often related to metabolic or diffuse encephalopathies, hydrocephalus (increased ICP) or disturbance of deeper structures
- **TIRDA (Temporal Intermittent Rhythmic Delta Activity)**: usually associated with temporal lobe epilepsy, however it could be seen in other conditions
- **OIRDA (Occipital Intermittent Rhythmic Delta Activity)**: usually associated with idiopathic generalized epilepsy (childhood absence epilepsy), although it is occasionally noted in encephalopathic children

# FIRDA in a 31-Year-Old Man with Encephalopathy



# FIRDA in a 49-Year-Old Man with Cirrhosis and Hepatic Encephalopathy



# How to Report FIRDA

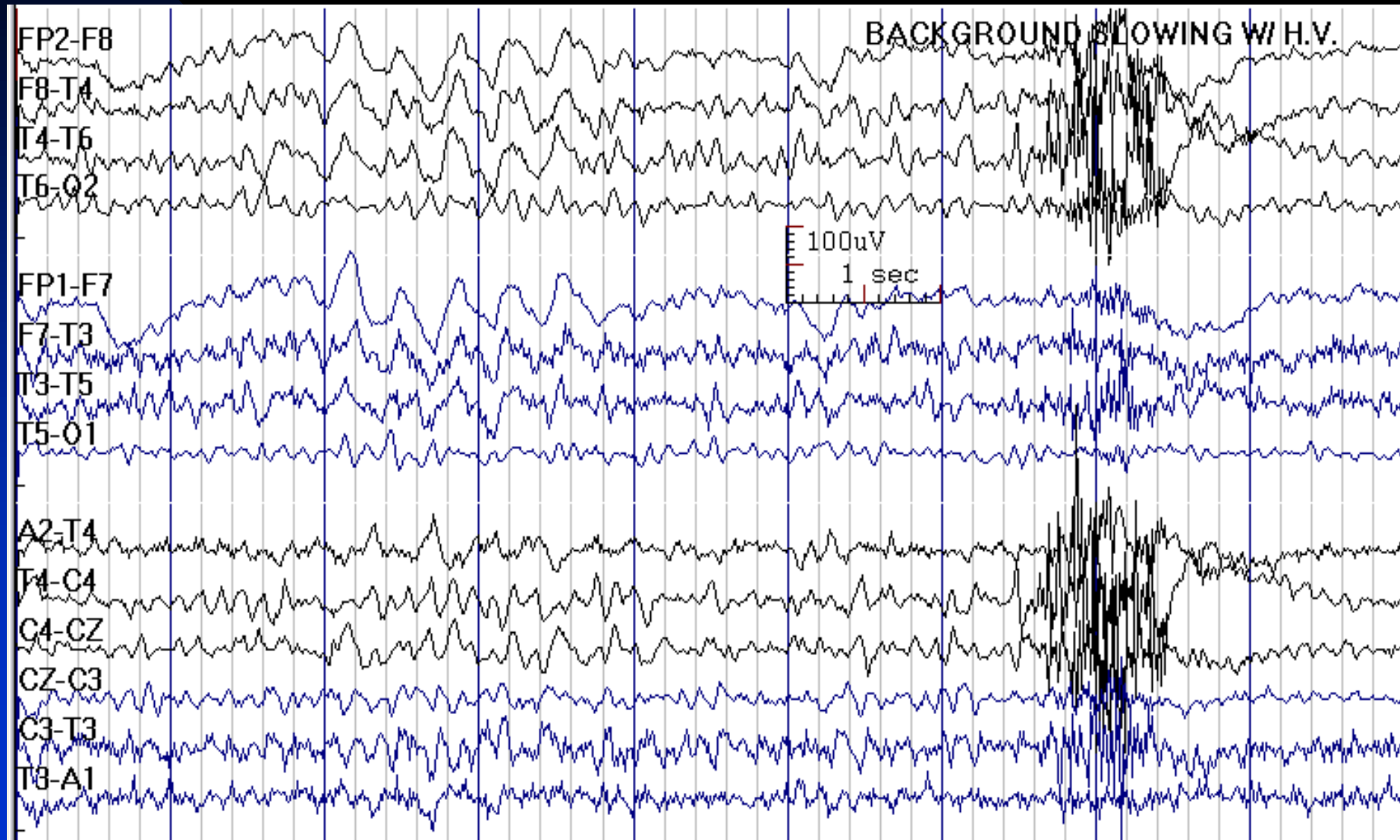
- *In conclusion section, write:*
  - ◆ This EEG shows diffuse cerebral dysfunction, which is non-specific, but is most often seen in metabolic encephalopathy, hydrocephalus (increased ICP) or disturbance of diencephalic structures.



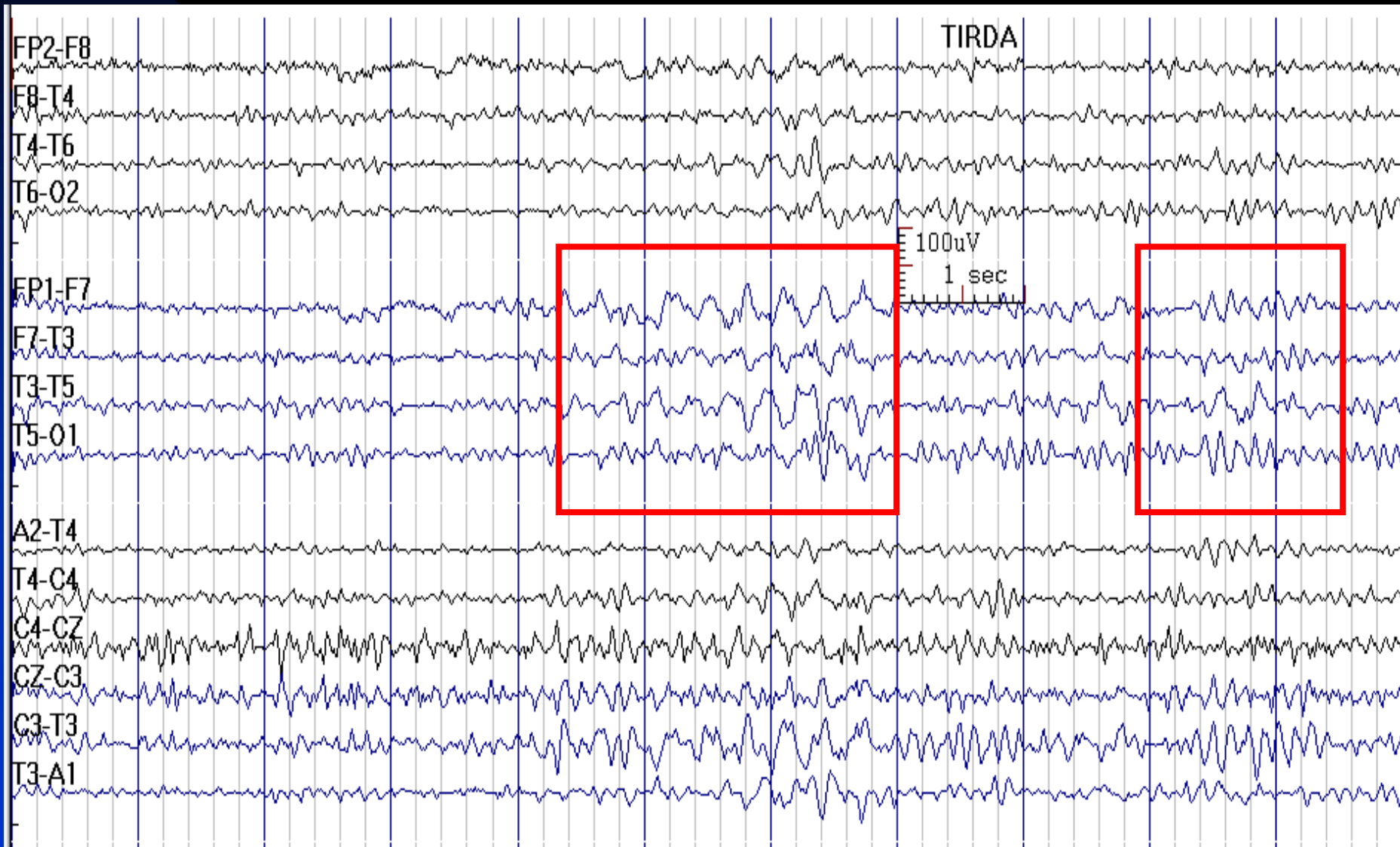# FIRDA is Normal in

- Sleep
- Hyperventilation
- Asymptomatic elderly in drowsiness

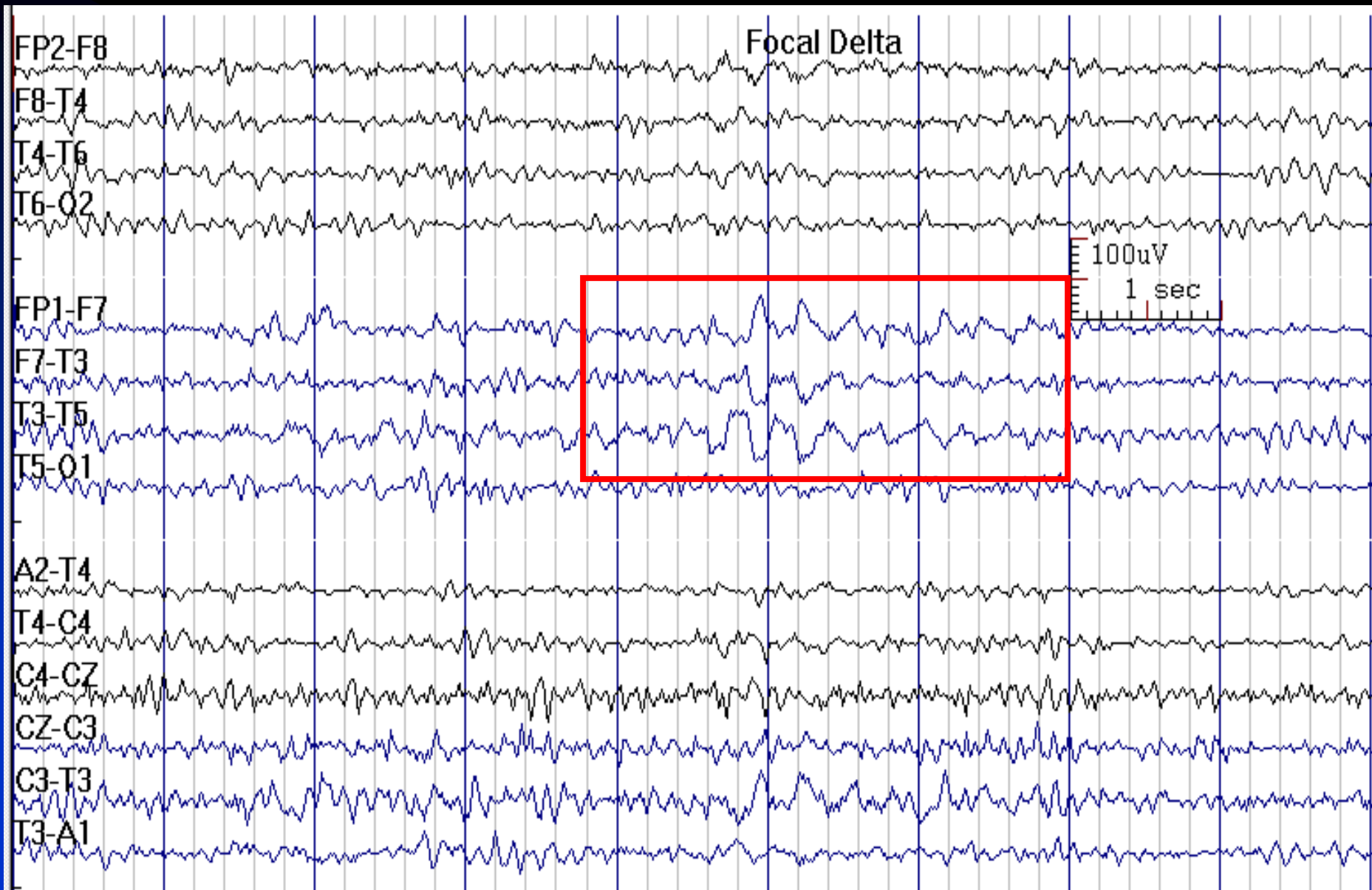
# FIRDA in Response to Hyperventilation in a 33-Year-Old Normal Woman



# TIRDA in a 35-Year-Old Man with Temporal Lobe Epilepsy



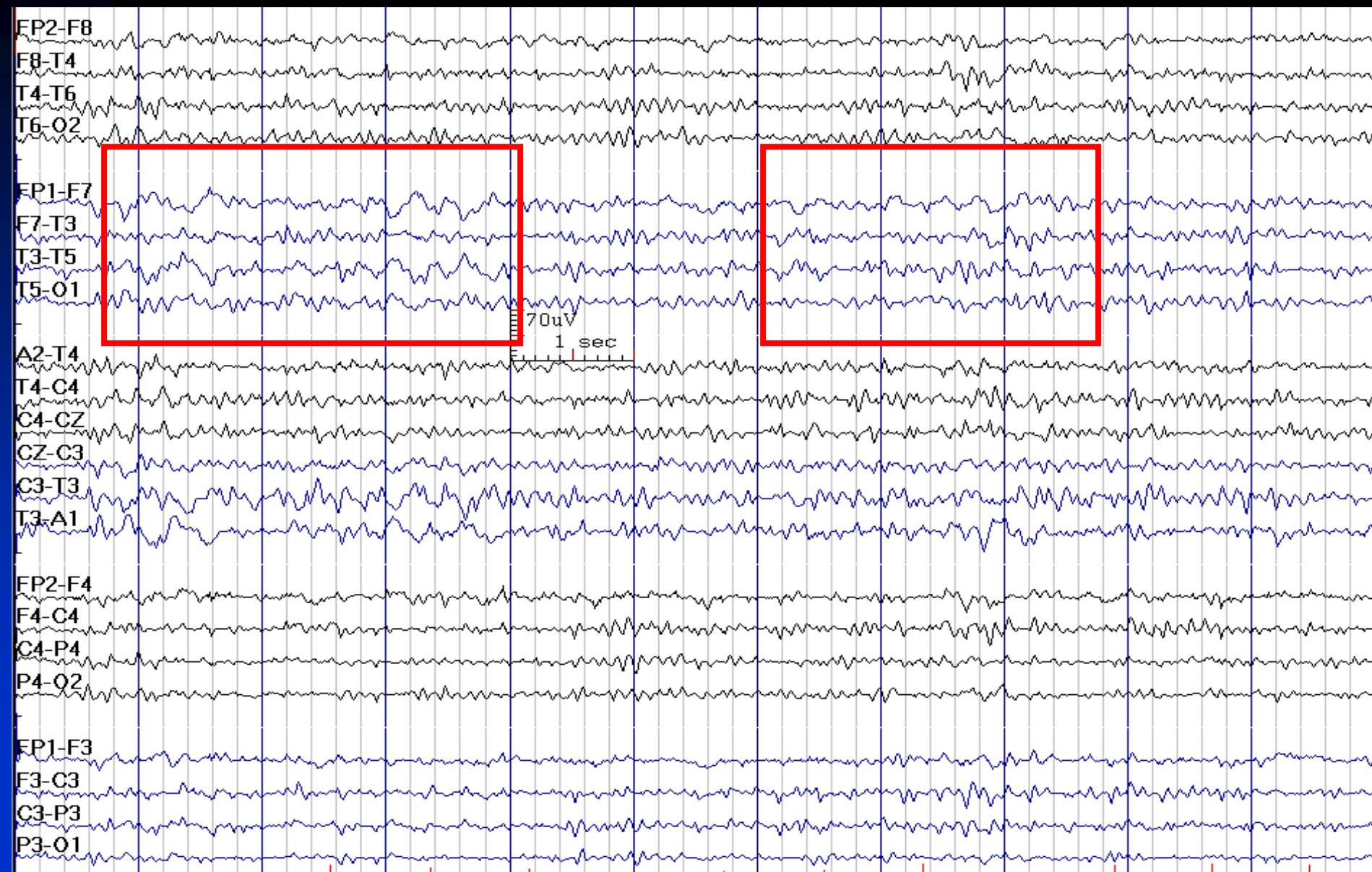# TIRDA in Temporal Lobe Epilepsy



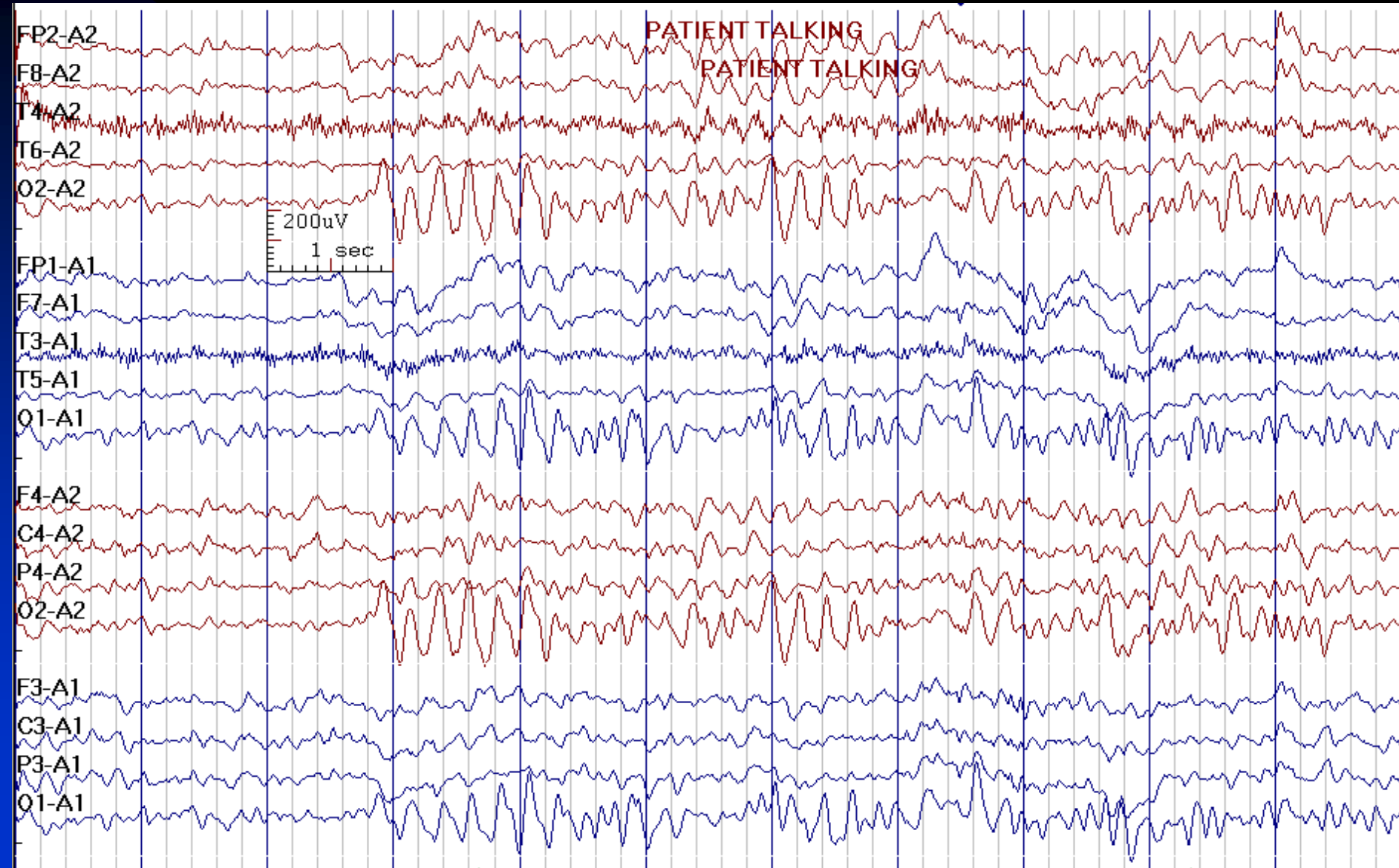
# How to Report TIRDA

- *In the conclusion section, write:*
  - ◆ TIRDA is usually associated with temporal lobe epilepsy in a patient with a history of complex partial (focal) seizures.

# TIRDA in a 38-Year-Old Woman with Migraine



# OIRDA in a 3-Year-Old Boy with Absence Seizures



# How to Report OIRDA

- *In the conclusion section, write:*
  - ◆ OIRDA is usually associated with idiopathic (genetic) generalized epilepsy, especially in children with childhood absence epilepsy, although it is occasionally noted in encephalopathic children as well.



# EEG Abnormalities in Diffuse Encephalopathies

- Slow background activity
- Diffuse intermittent or continuous slow activity
- Diffuse intermittent rhythmic slow activity
- Triphasic waves
- Periodic patterns
- Burst-suppression pattern
- **Note:** When recording comatose patients, it is important to test for reactivity. Reactivity indicates a lighter level of coma and is generally a good sign

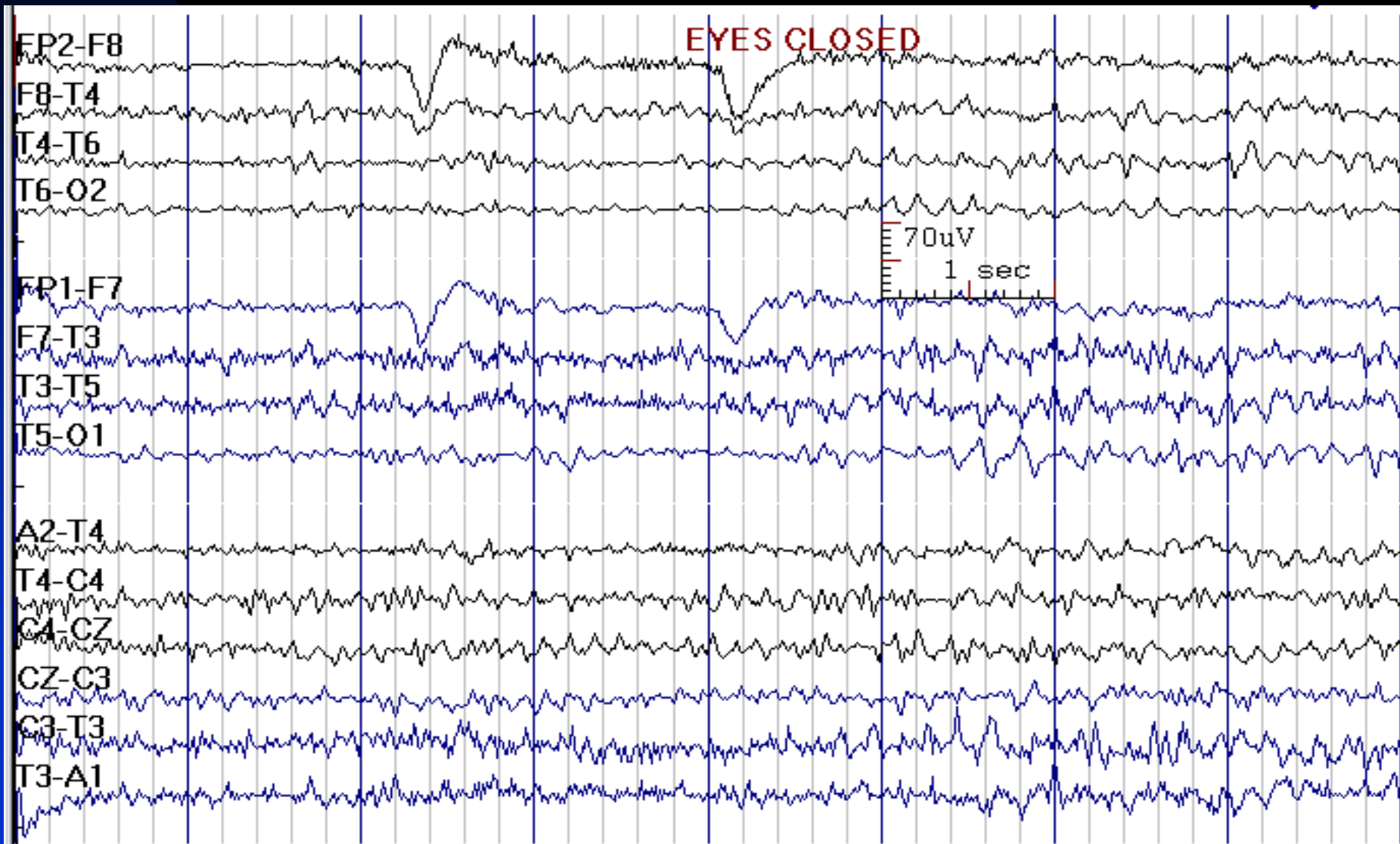
# Diffuse Slow Activity

- **Mild:** slowing of posterior dominant rhythm ( $< 8.5$ ), perhaps mixed with some bilateral theta activity
- **Moderate:** increased amount of slow activity with decreased frequency and increased amplitude; reactivity is preserved (attenuation of slow activity following arousal)
- **Severe:** diffuse continuous arrhythmic (polymorphic) non-reactive delta activity

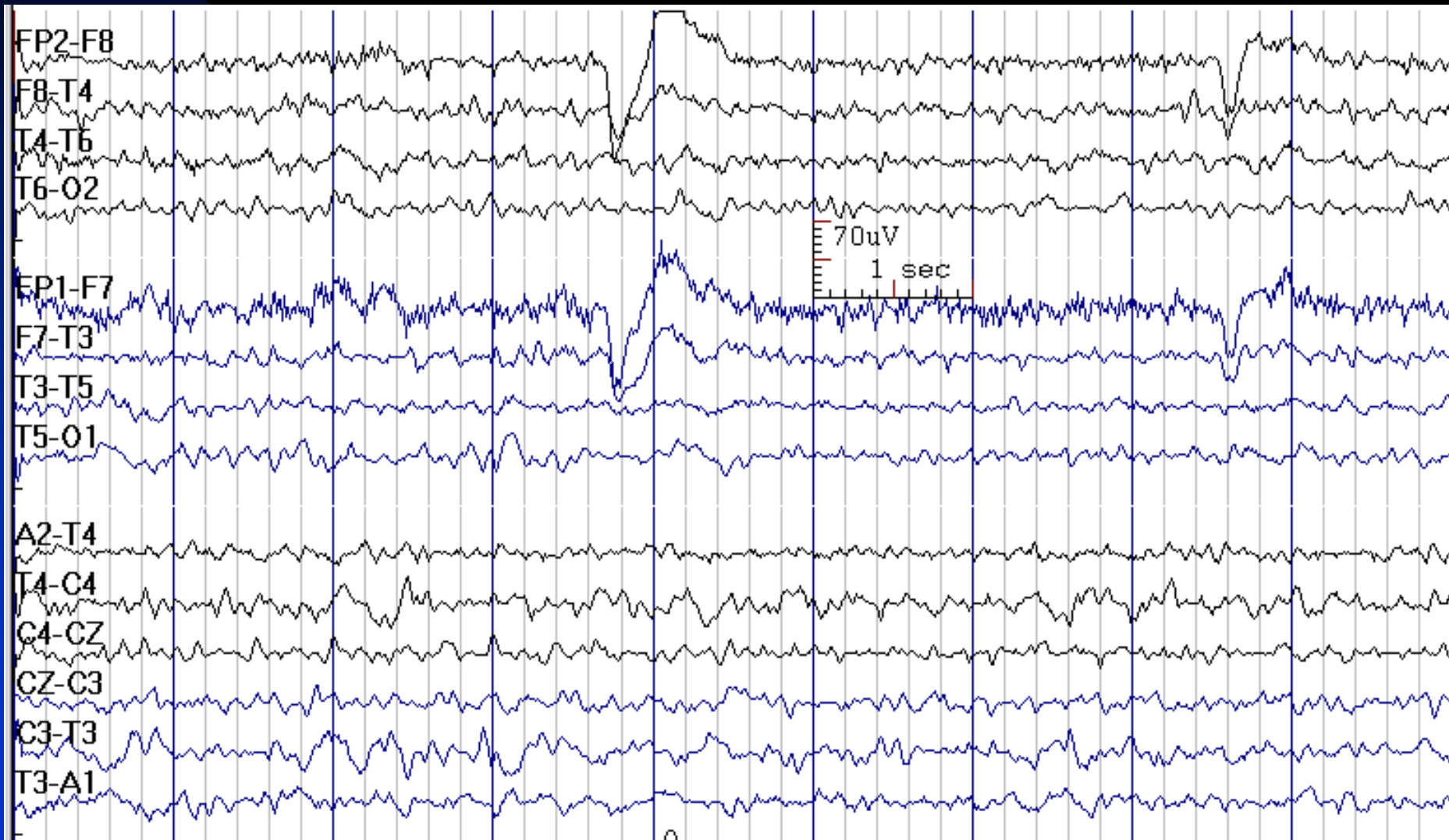
# Diffuse Arrhythmic (Polymorphic) Delta Activity

- Non-specific in etiology; could be due to diffuse cerebral dysfunction (e.g., toxic/metabolic encephalopathies, degenerative processes, multiple structural lesions, thalamic or midbrain dysfunction, encephalitis, subarachnoid hemorrhage, etc.)
- **Note:** Focal EEG abnormalities, if present, are important; would indicate a lateralized hemispheric lesion as the underlying cause

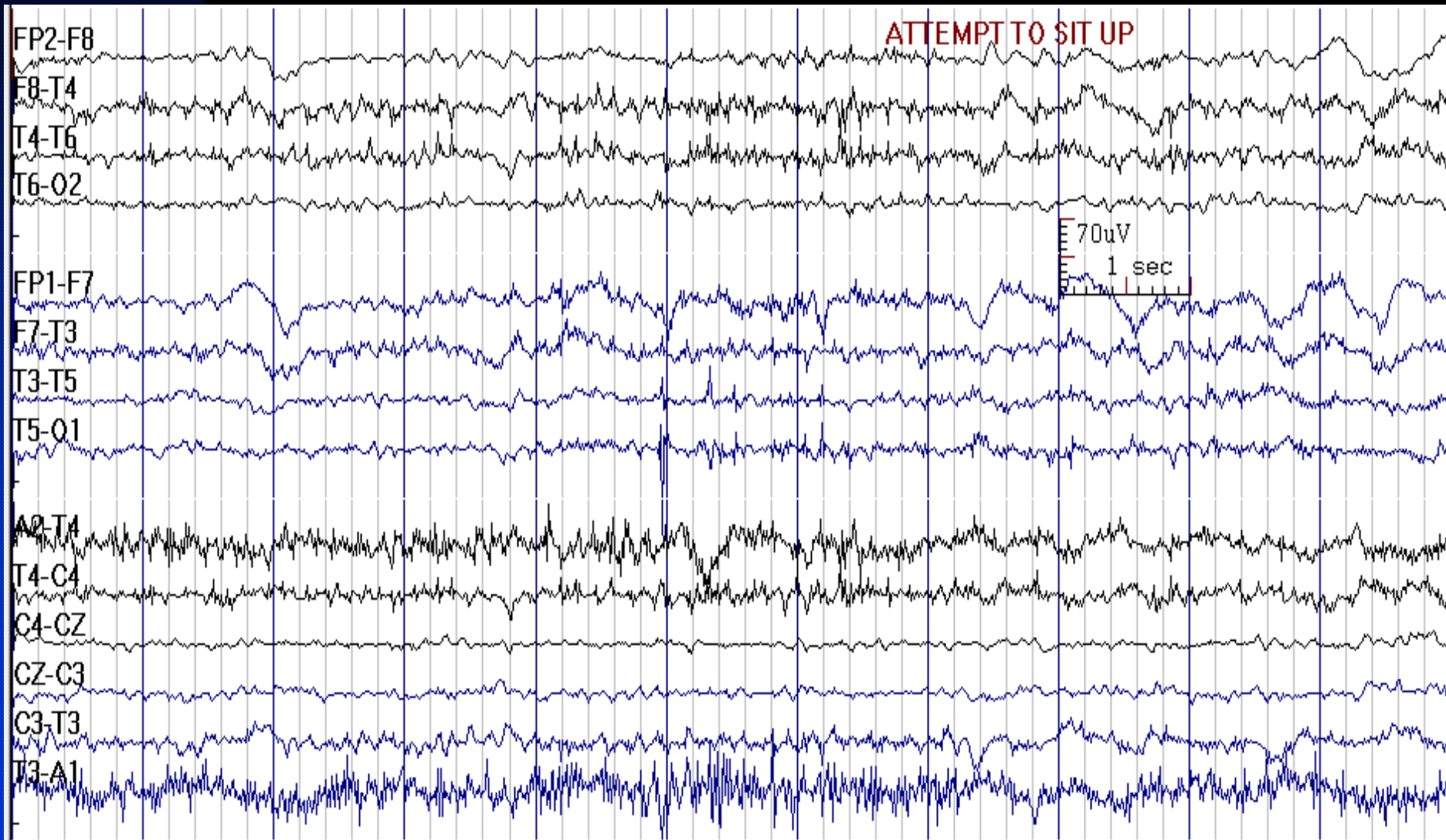
# Diffuse Theta in Wakefulness due to Mild Cerebral Dysfunction



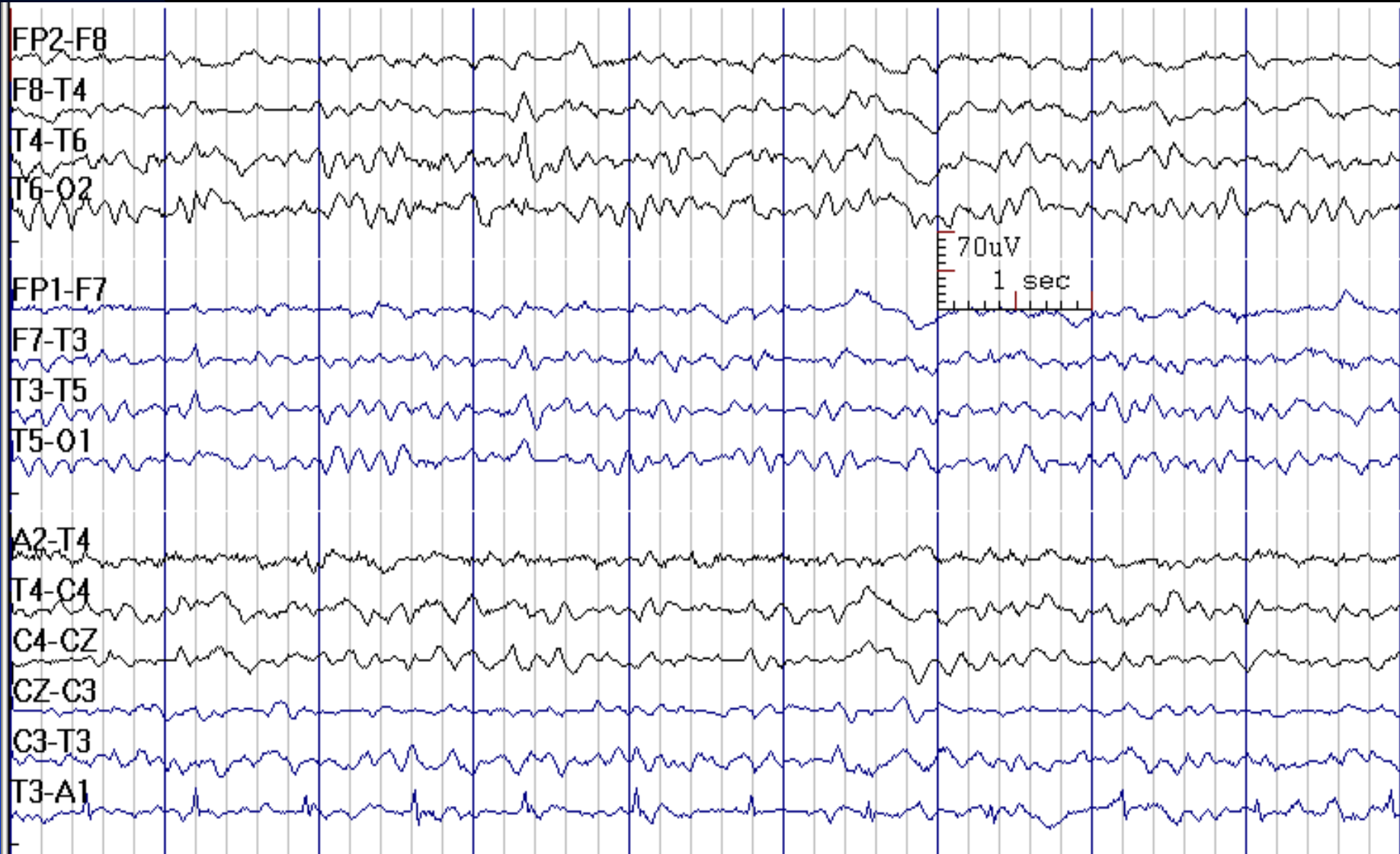
# Diffuse Theta in Wakefulness in a 26-Year-Old Man with Diabetic Hyperosmolar Coma



# Diffusely Slow Background in a 54-Year-Old Man with Confusion

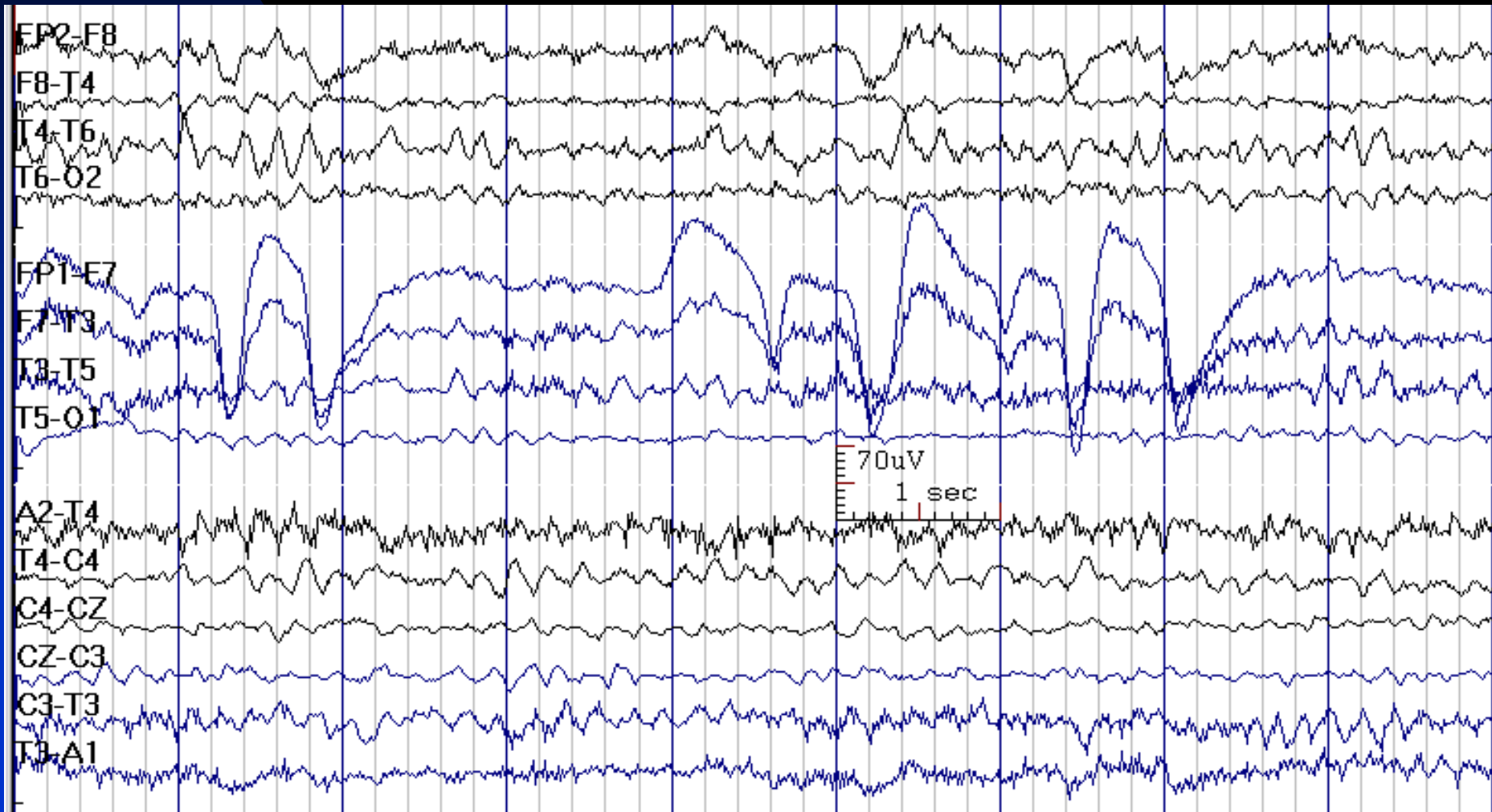


# Diffusely Slow Background in a 43-Year-Old Man with Neurosarcoidosis





# Absence of Posterior Dominant Rhythm and Diffuse Theta in Wakefulness due to Encephalopathy in a 75-Year-Old Man with Renal Failure





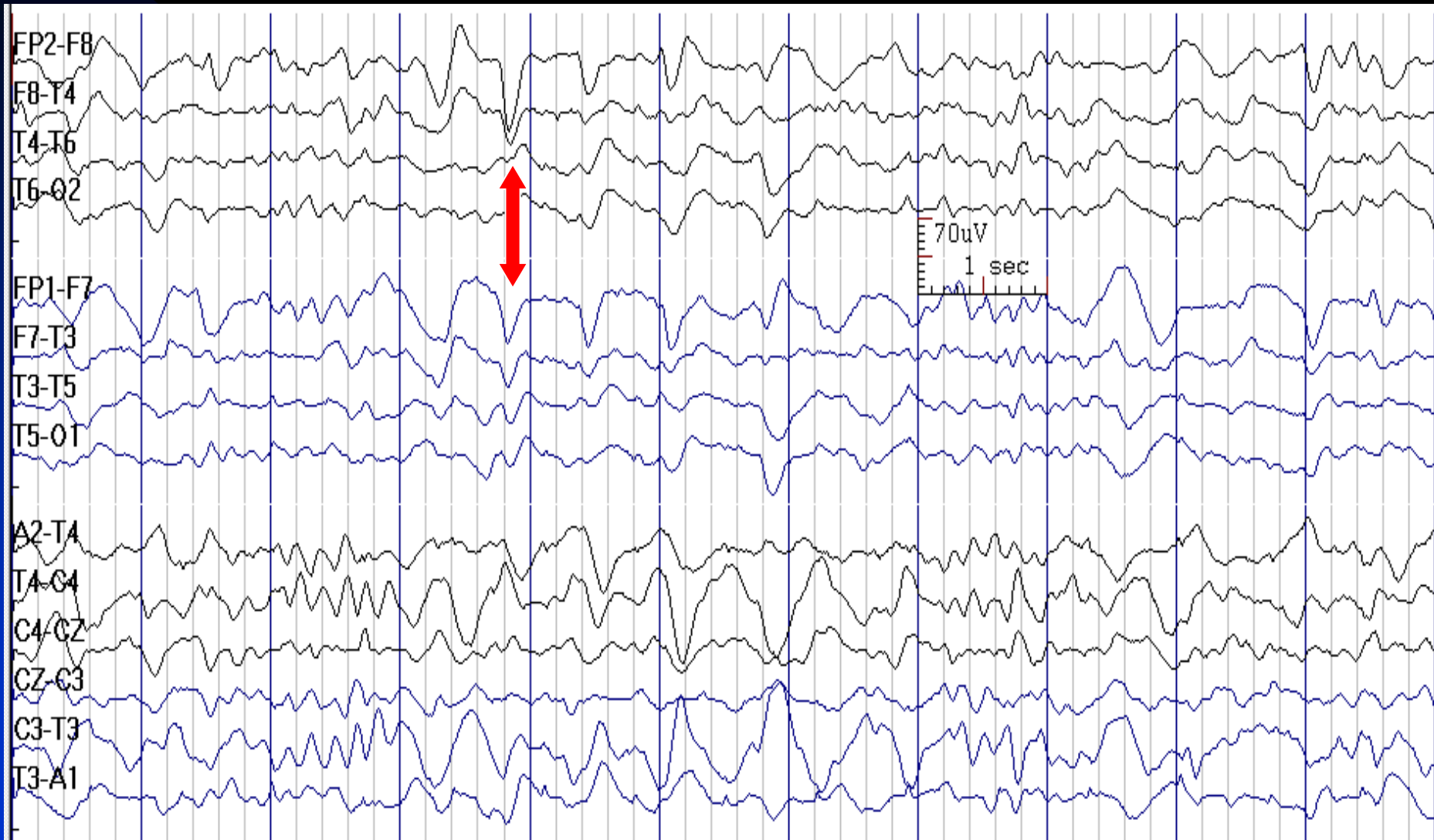
# How to Report Diffuse Slow Activity

- *In conclusion section, write:*
  - ◆ This EEG indicates a \_\_\_\_\_ (mild / moderate / severe) generalized cerebral dysfunction, which can be seen in toxic-metabolic conditions, degenerative diseases, the postictal state, or with bilateral hemispheric lesions. The prognosis depends on the reversibility of the underlying cause of the encephalopathy.

# Triphasic Waves

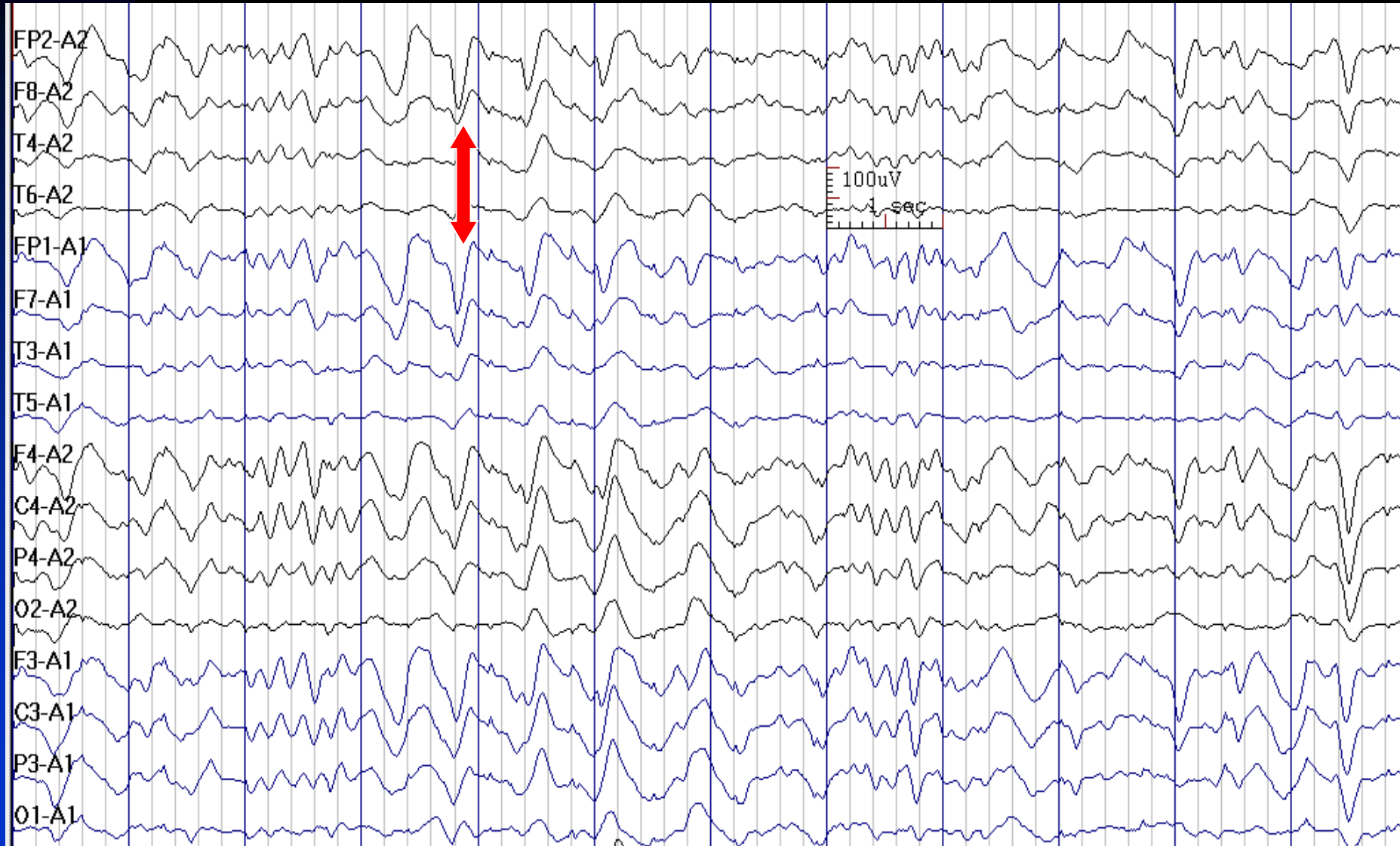
- **Morphology:** initial sharp negative component, followed by a sharp large and high amplitude positive complex and then another negative wave
- **Distribution:** generalized, bisynchronous, often anterior-dominant, probably with a fronto-occipital lag
- **Amplitude:** usually high voltage ( $> 70 \mu\text{v}$ )
- **Frequency:** approximately 1-2.5 Hz, usually in trains
- **Etiology:** metabolic encephalopathy (e.g., hepatic, uremic, hyponatremia), white-matter disease, alcohol abuse, infections, hypoxia, Alzheimer's disease, drug toxicity (e.g., lithium, baclofen, levodopa and ifosfamide)

# Triphasic Waves in a 22-Year-Old Man with Hepatic Encephalopathy



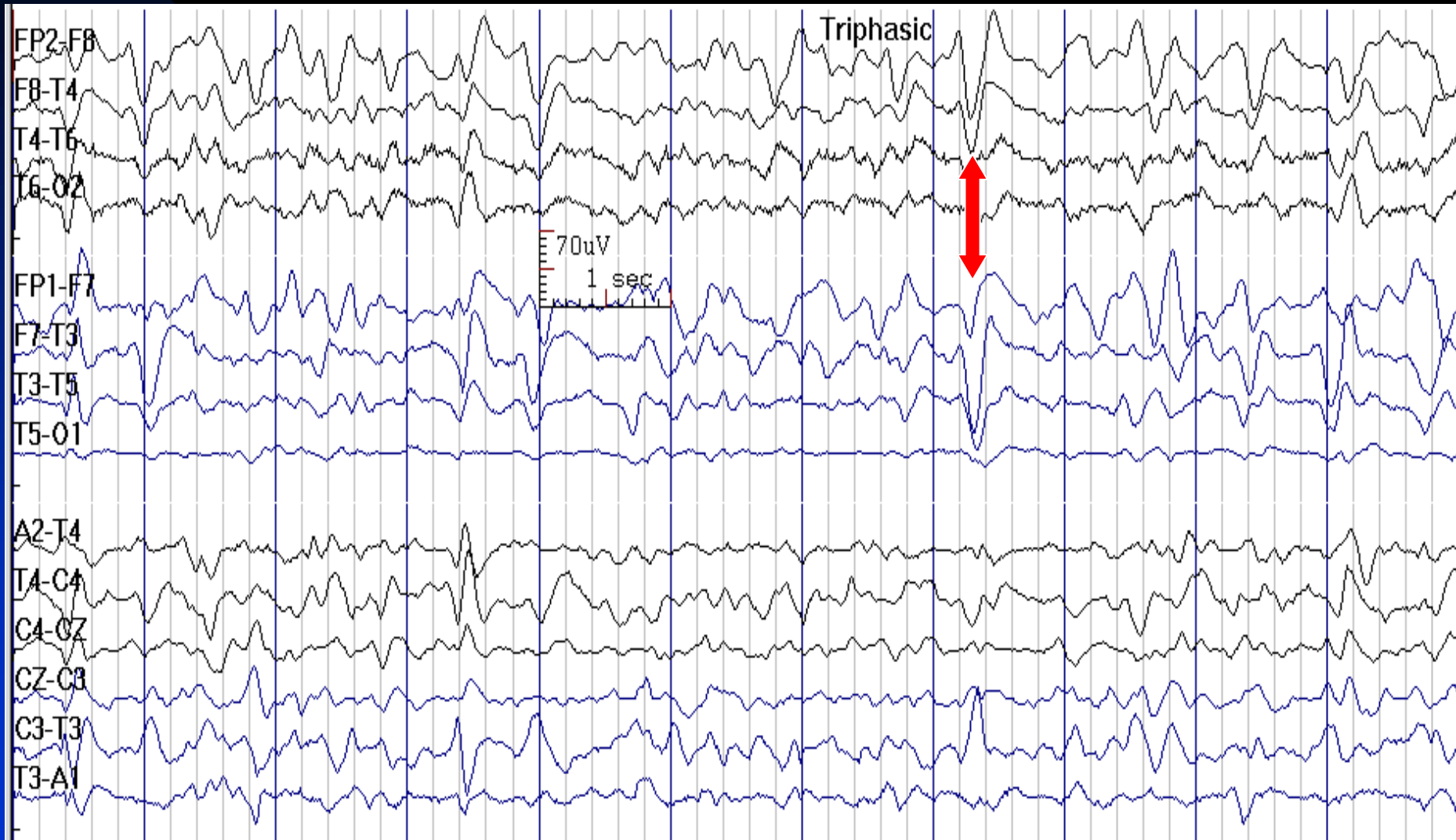
See the next image for the same finding in reference montage

# Triphasic Waves in Reference Montage in a 22-Year-Old Man with Hepatic Encephalopathy



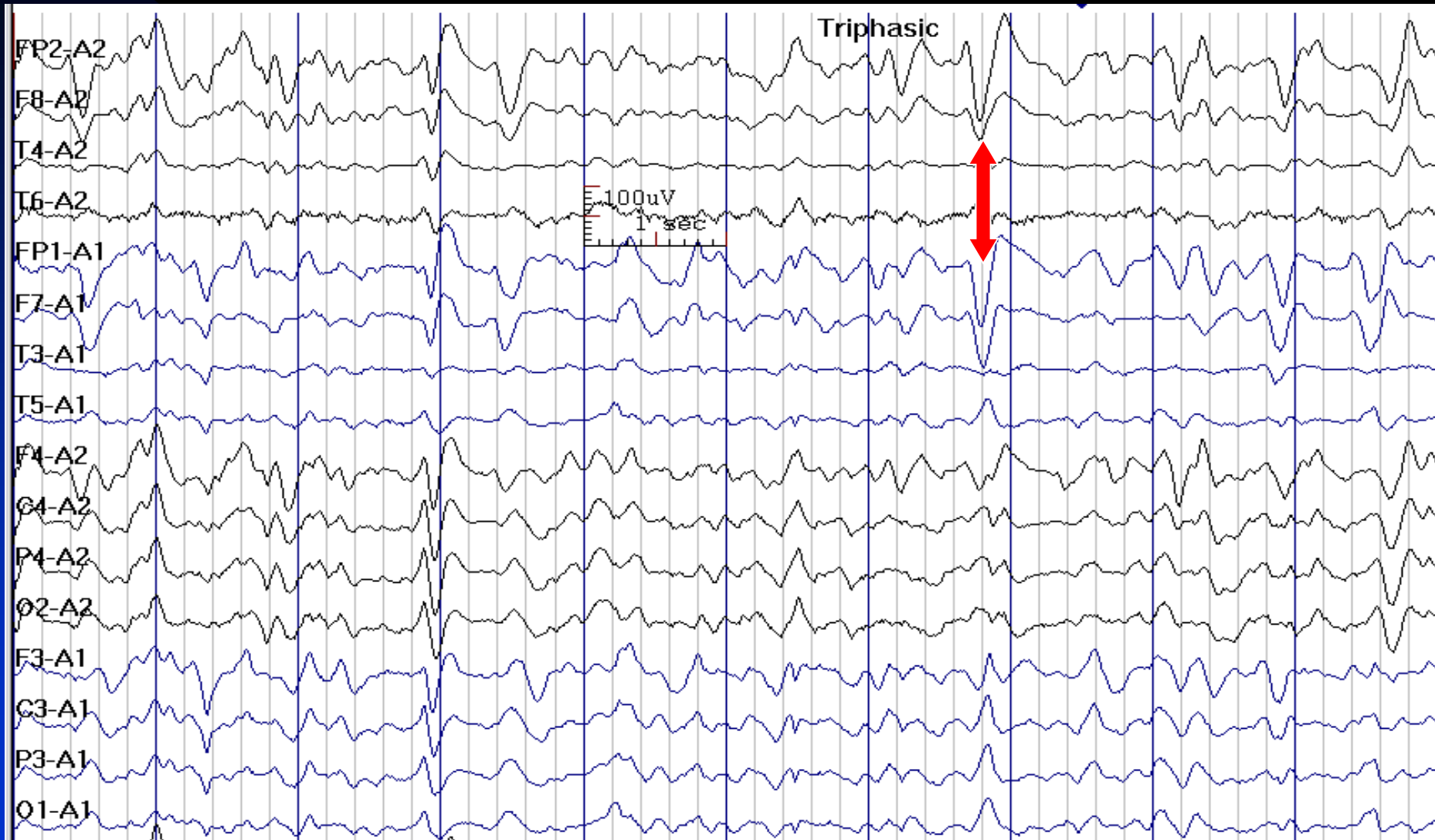
See the previous image for the same finding in bipolar montage

# Triphasic Waves in a 84-Year-Old Woman with Hepatic Encephalopathy



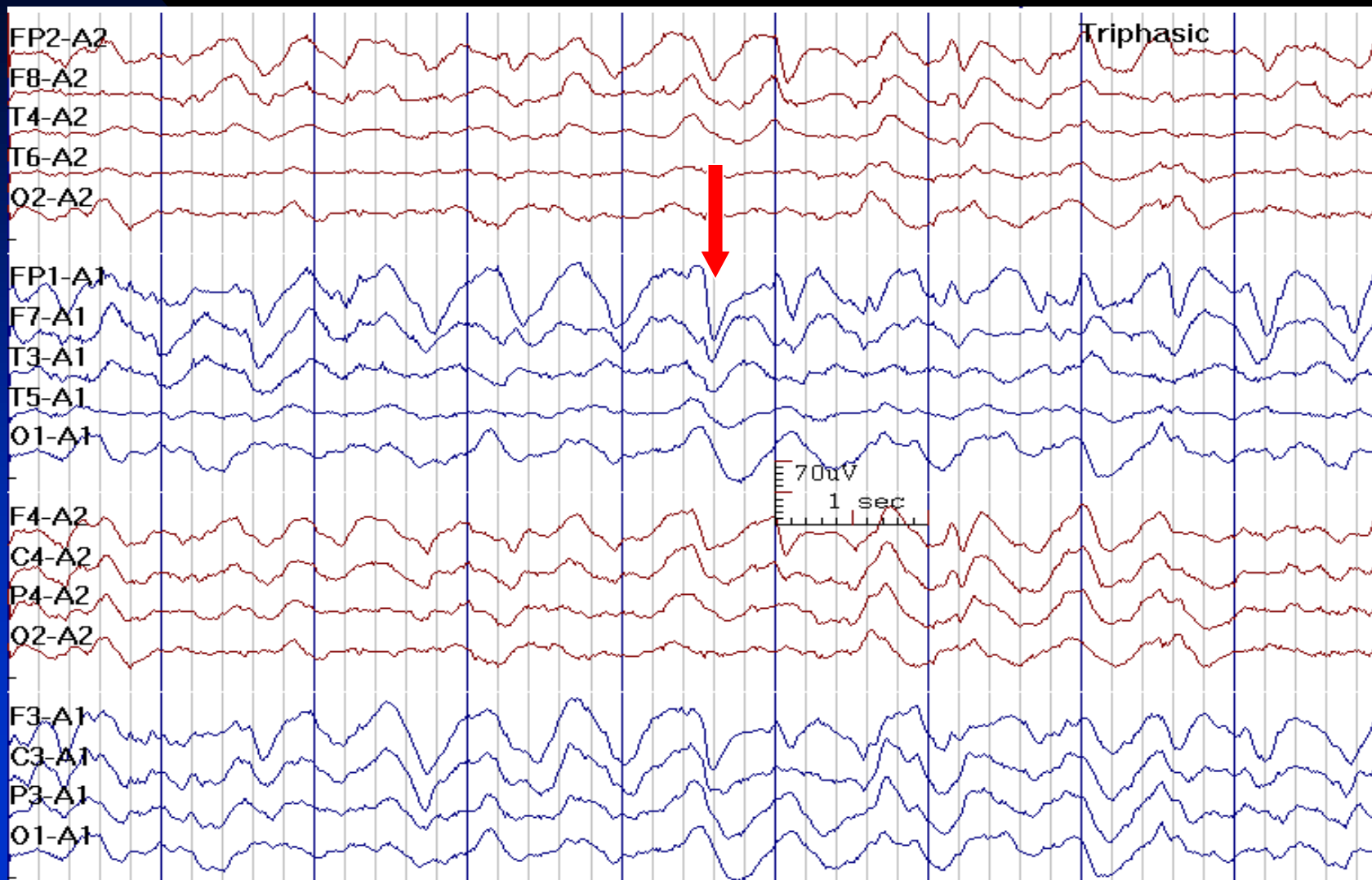
See the next image for the same finding in reference montage

# Triphasic Waves in Reference Montage in a 84-Year-Old Woman with Hepatic Encephalopathy

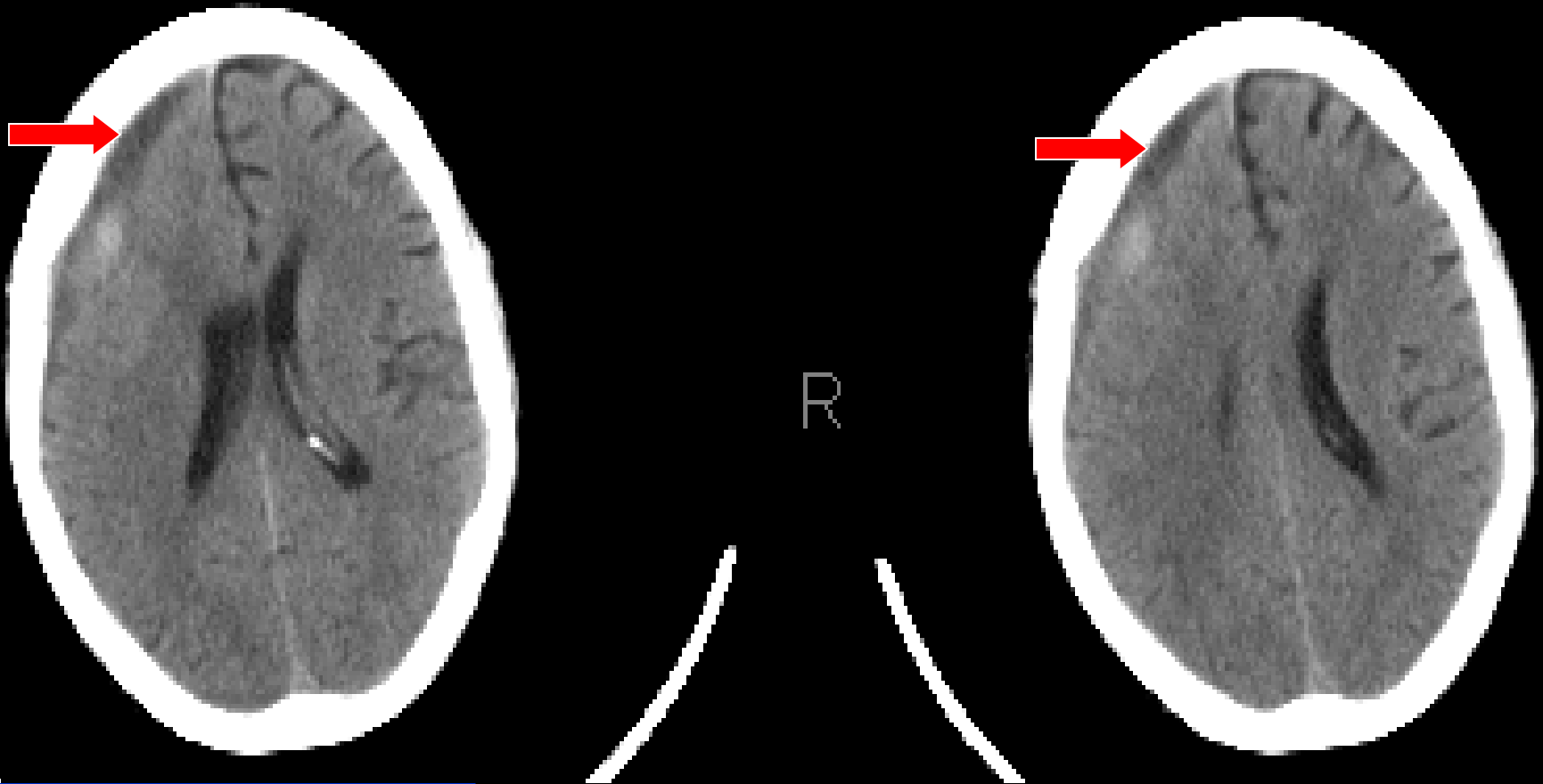

See the previous image for the same finding in bipolar montage

# Asymmetric Triphasic Waves in a 43-Year-Old Man with Hepatic Encephalopathy and Right Subdural Hematoma



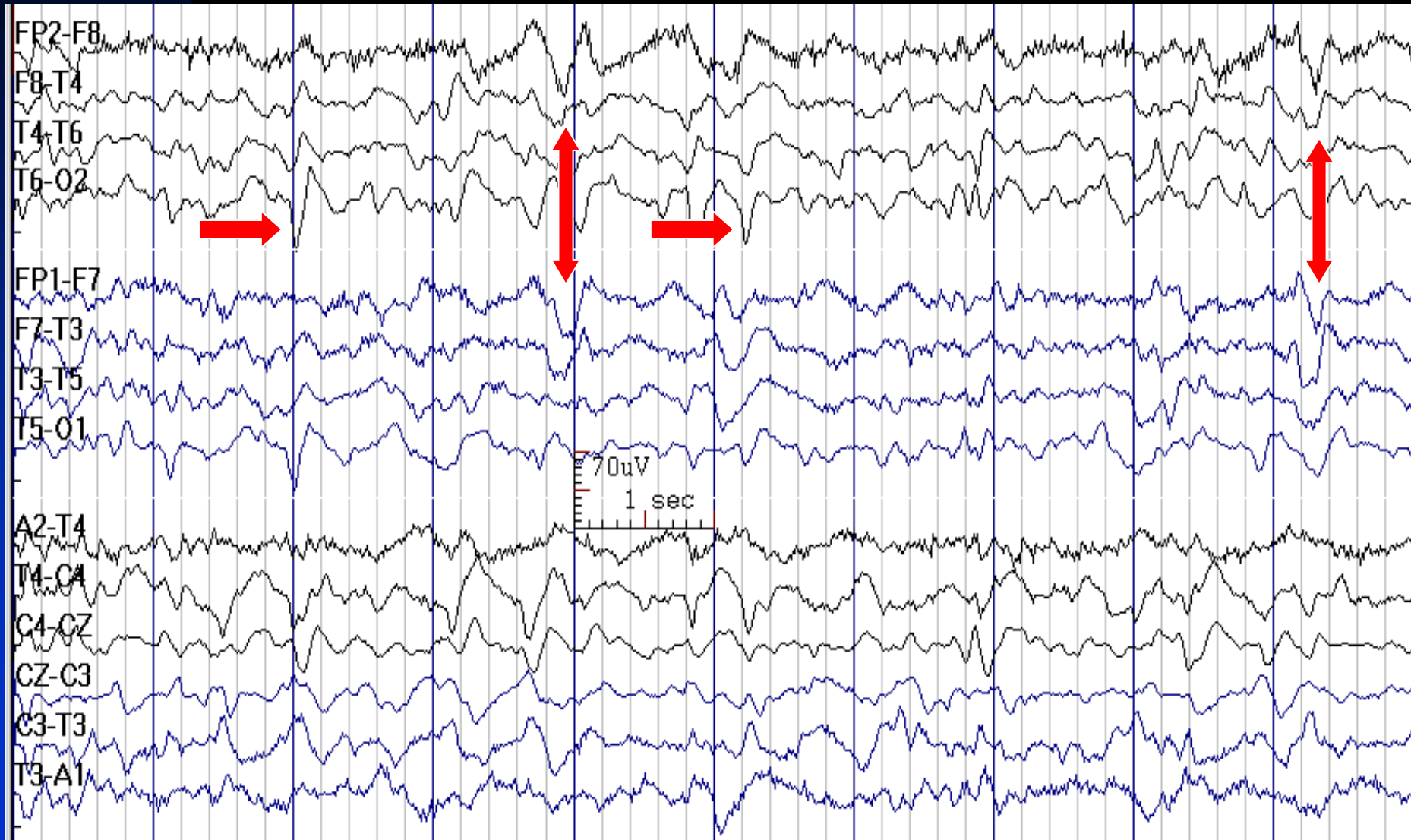
# Right Subdural Hematoma in Previous Patient



See the previous image



# O2 Sharp Waves (Horizontal Arrows) and Triphasic Waves (Vertical Arrows) in a 70-Year-Old Woman with Renal Failure



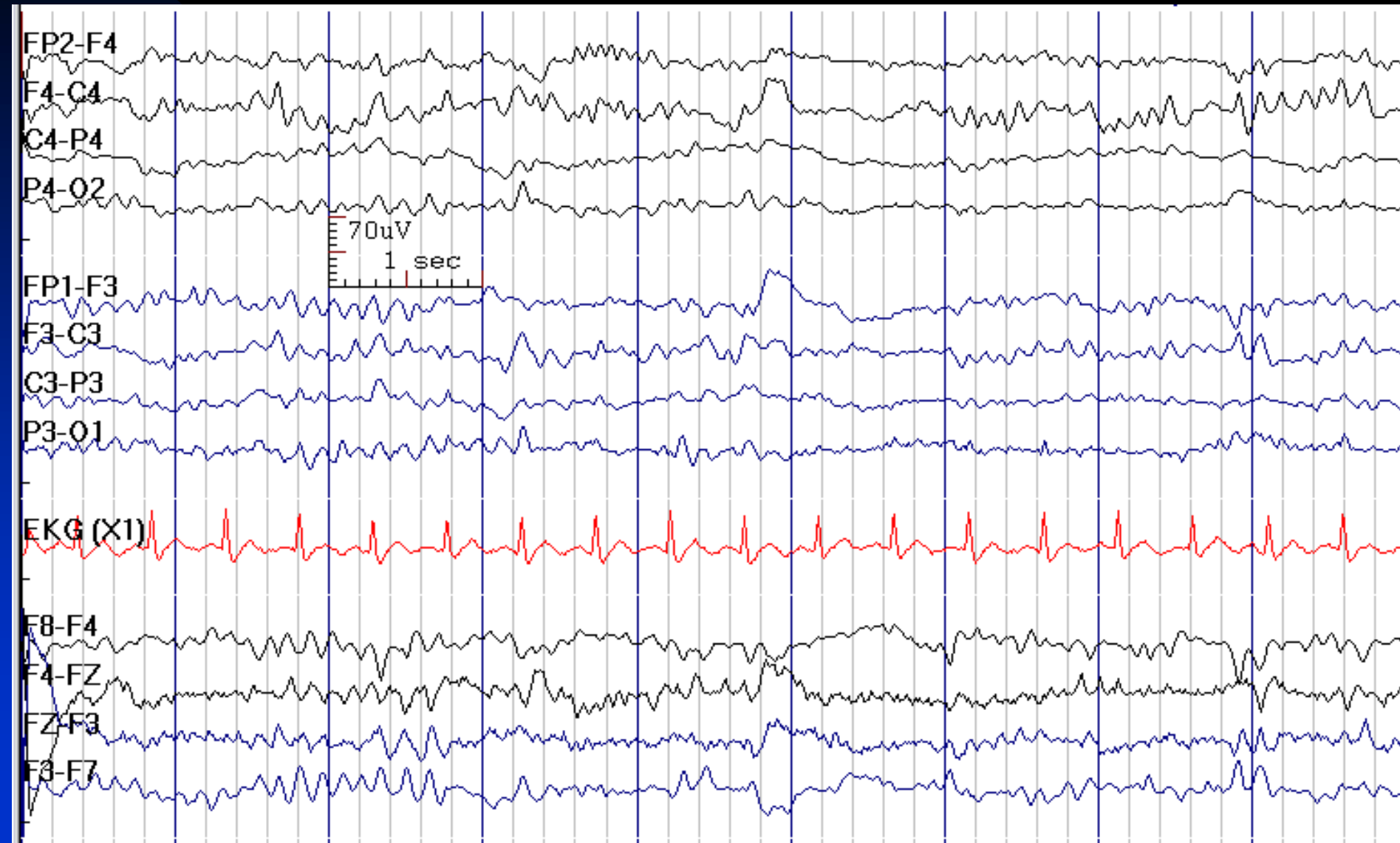
# How to Report Triphasic waves

- *In conclusion section, write:*
  - ◆ This finding is most often seen in metabolic or toxic encephalopathies. It carries a poor prognosis with severe anoxia, and the prognosis varies in other conditions.

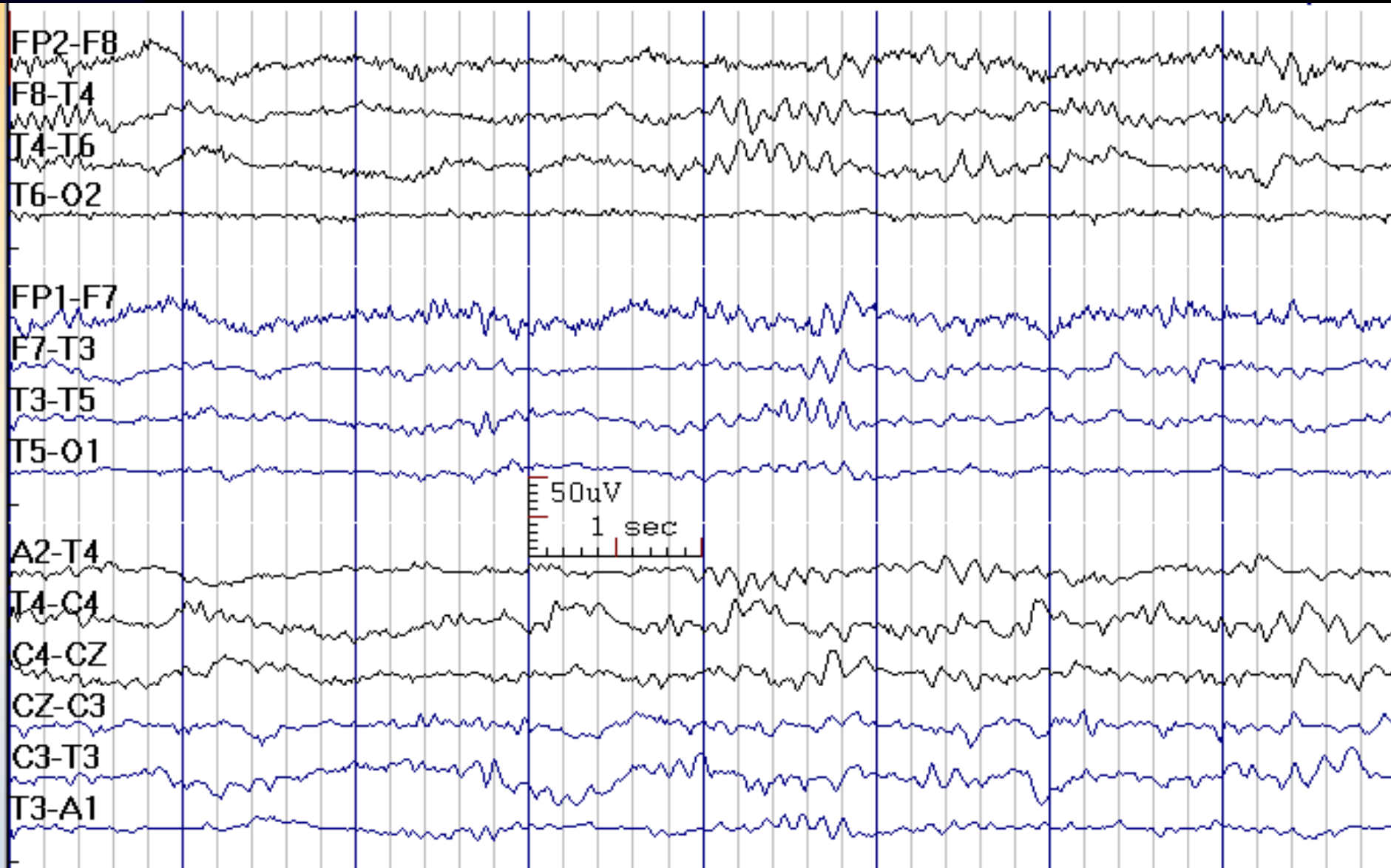
# Alpha Coma

- Alpha frequency (8-13 Hz, 10-50  $\mu$ V) activity, distributed over the head, but predominates frontally
- No reactivity to stimuli
- Widespread intermixed theta and delta activities
- **Etiology:** diffuse cerebral anoxia after cardiac or respiratory arrest, toxic or metabolic encephalopathies
- **Prognosis:** variable; usually grave in postanoxic coma, but good in toxic/metabolic encephalopathies

# Alpha Coma in a 25-Year-Old Man after Cardiac Arrest



# Alpha Coma in a 35-Year-Old Man after Cardiac Arrest



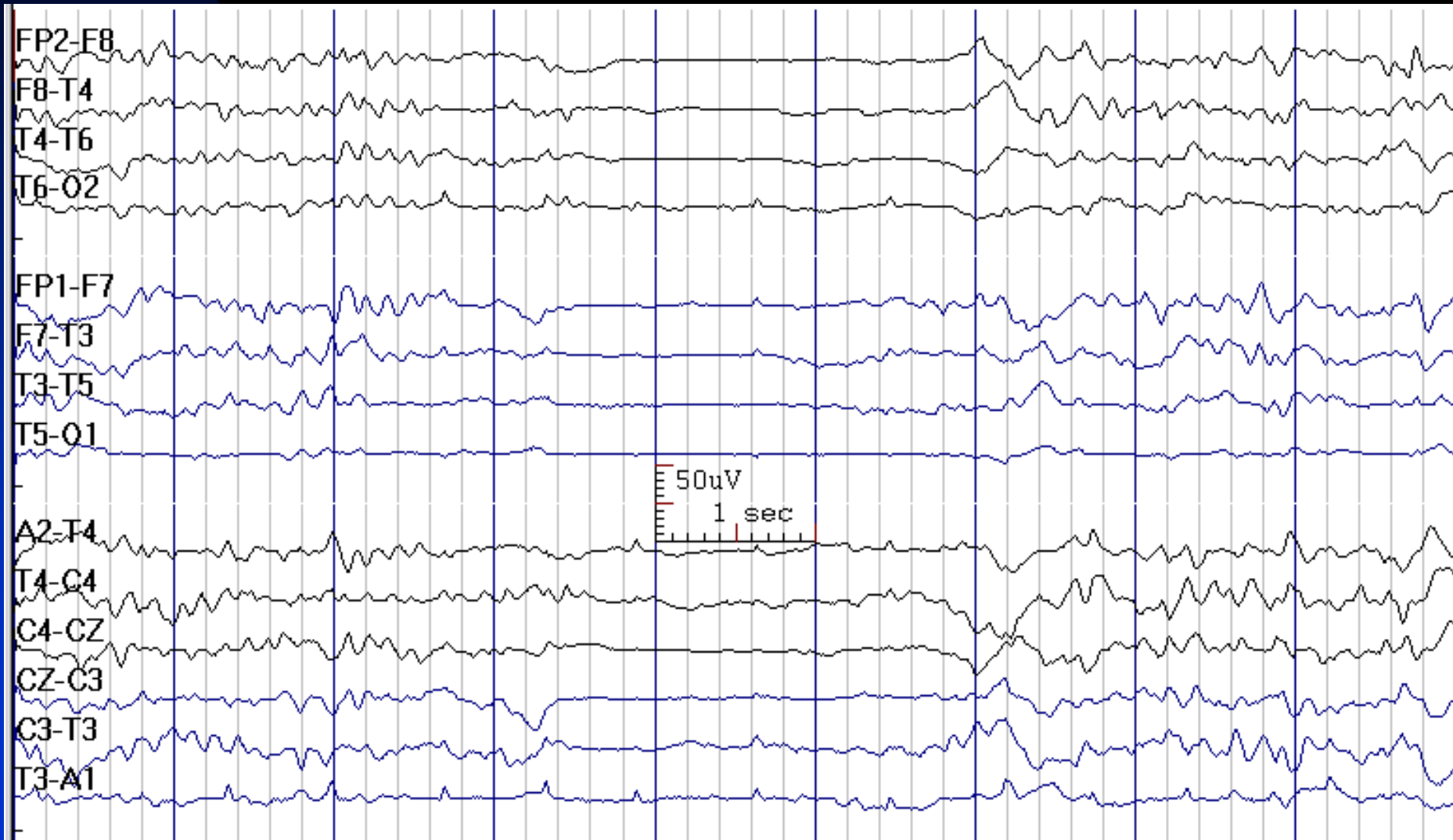
# How to Report Alpha Coma

- *In conclusion section, write:*
  - ◆ These EEG indicates a severe diffuse cerebral dysfunction (alpha coma), which carries a poor prognosis in the setting of cerebral anoxia (after cardiac or respiratory arrest), but has a favorable prognosis in drug-induced, toxic, or metabolic encephalopathies.

# Burst-Suppression

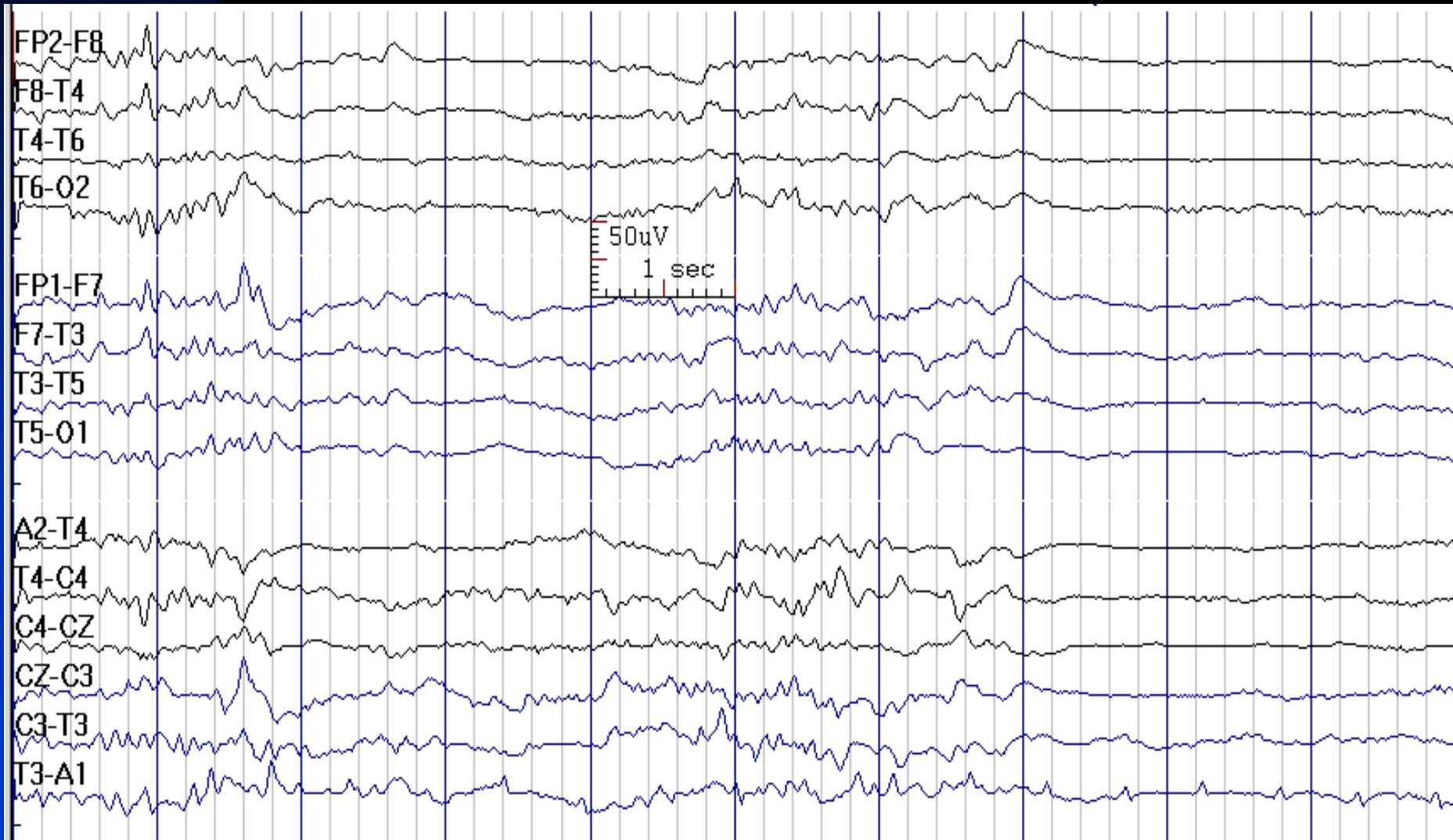
- A periodic pattern, in which the activity between the complexes is attenuated (less than 10  $\mu\text{V}$ )
- **Etiology:** severe toxic or anoxic encephalopathy or drug-induced
- **Prognosis:** depends on etiology; poor in the setting of anoxia [immediately precedes electrocerebral inactivity (no electrical brain activity exceeding 2  $\mu\text{V}$  when recording from scalp electrode pairs, 10 or more cm apart)]
- **Note:** a generalized periodic pattern after a cardiorespiratory arrest carries a poor prognosis

# Burst-Suppression Pattern in a 67-Year-Old Man with Status Epilepticus, Sedated with Propofol

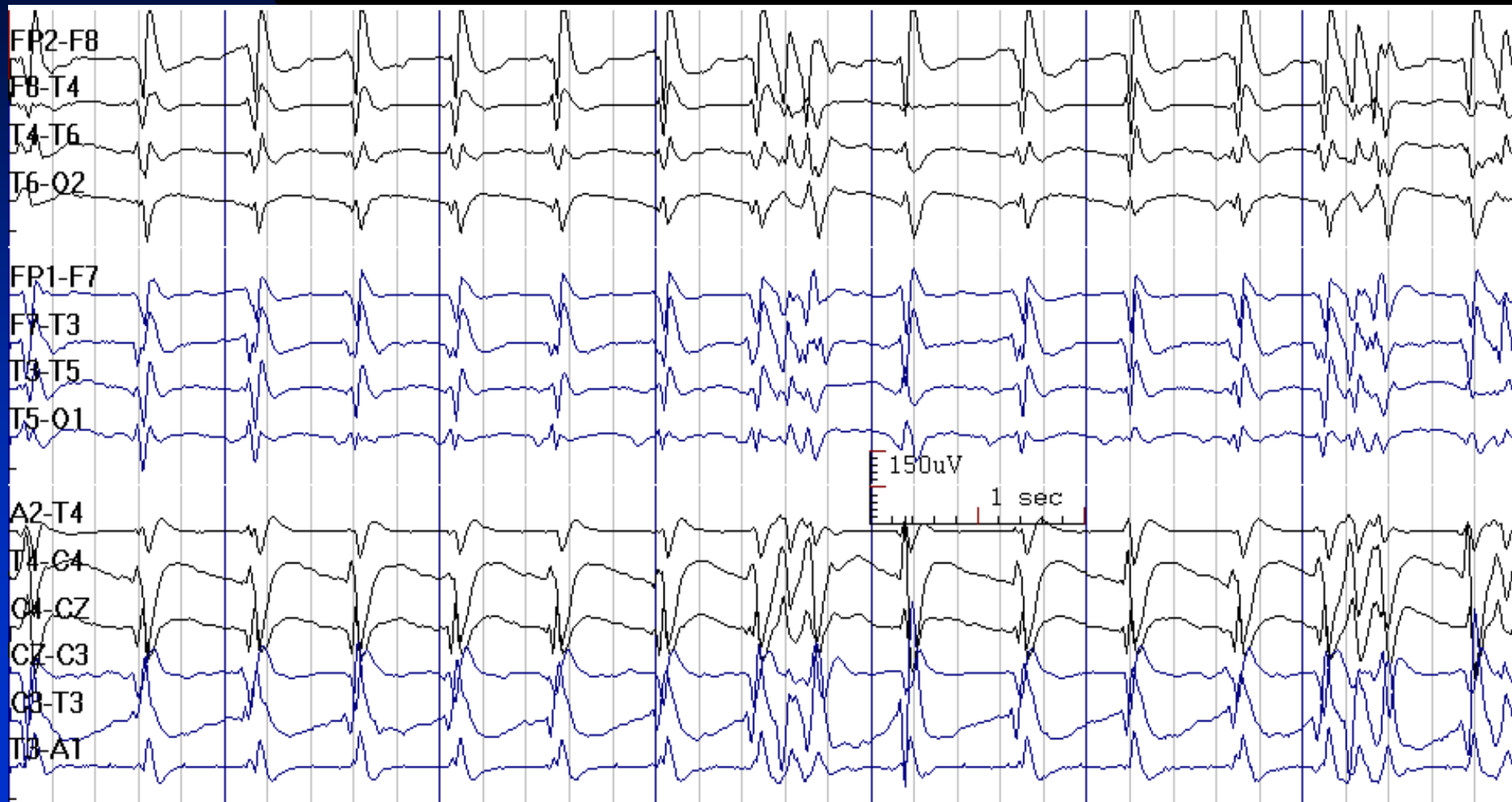




# Burst-Suppression Pattern in a 25-Year-Old Man with ARDS, Sedated with Propofol

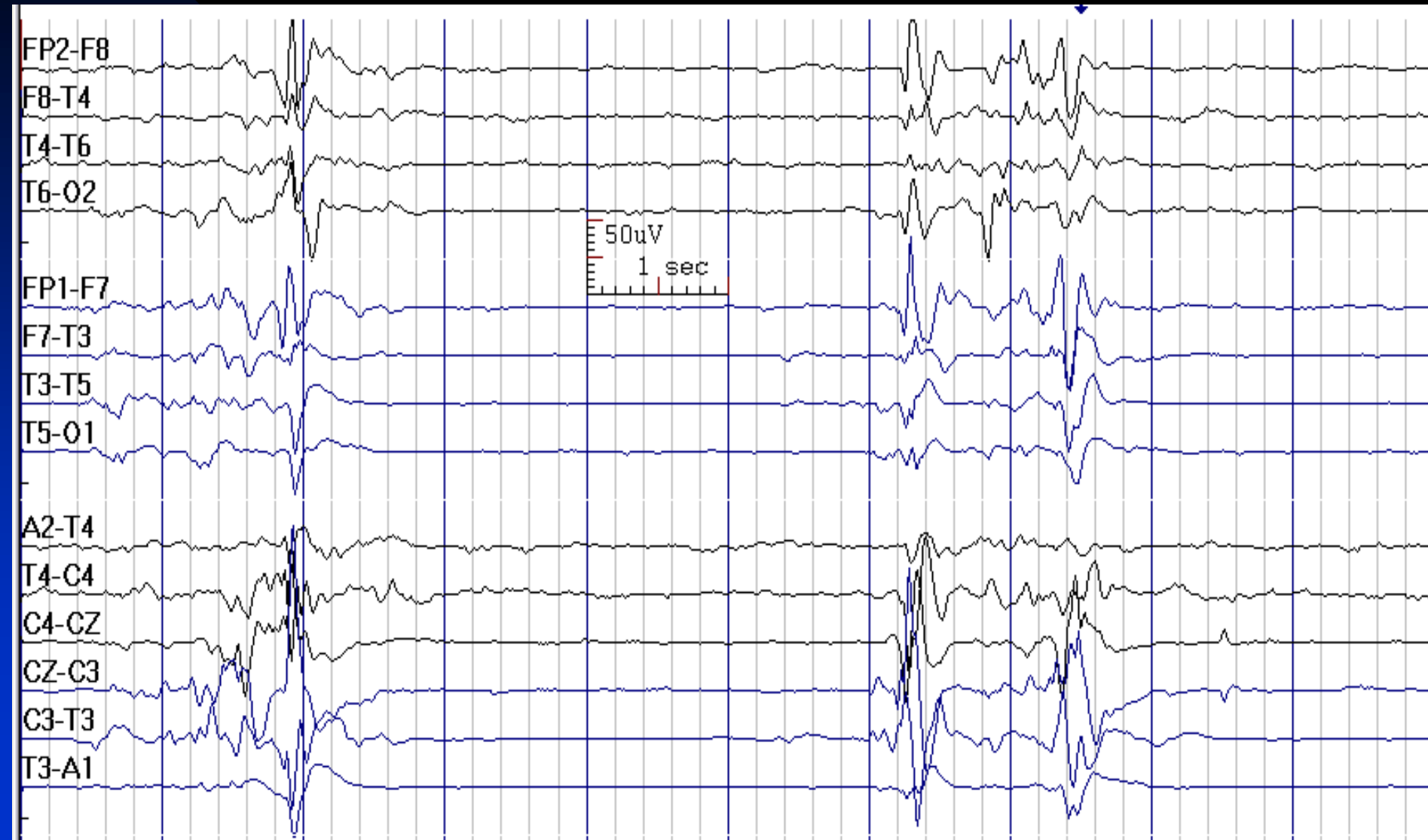

# Spike Burst-Suppression in a 55-Year-Old Woman with Anoxic Brain Injury; It is a Poor Prognostic Sign for Recovery

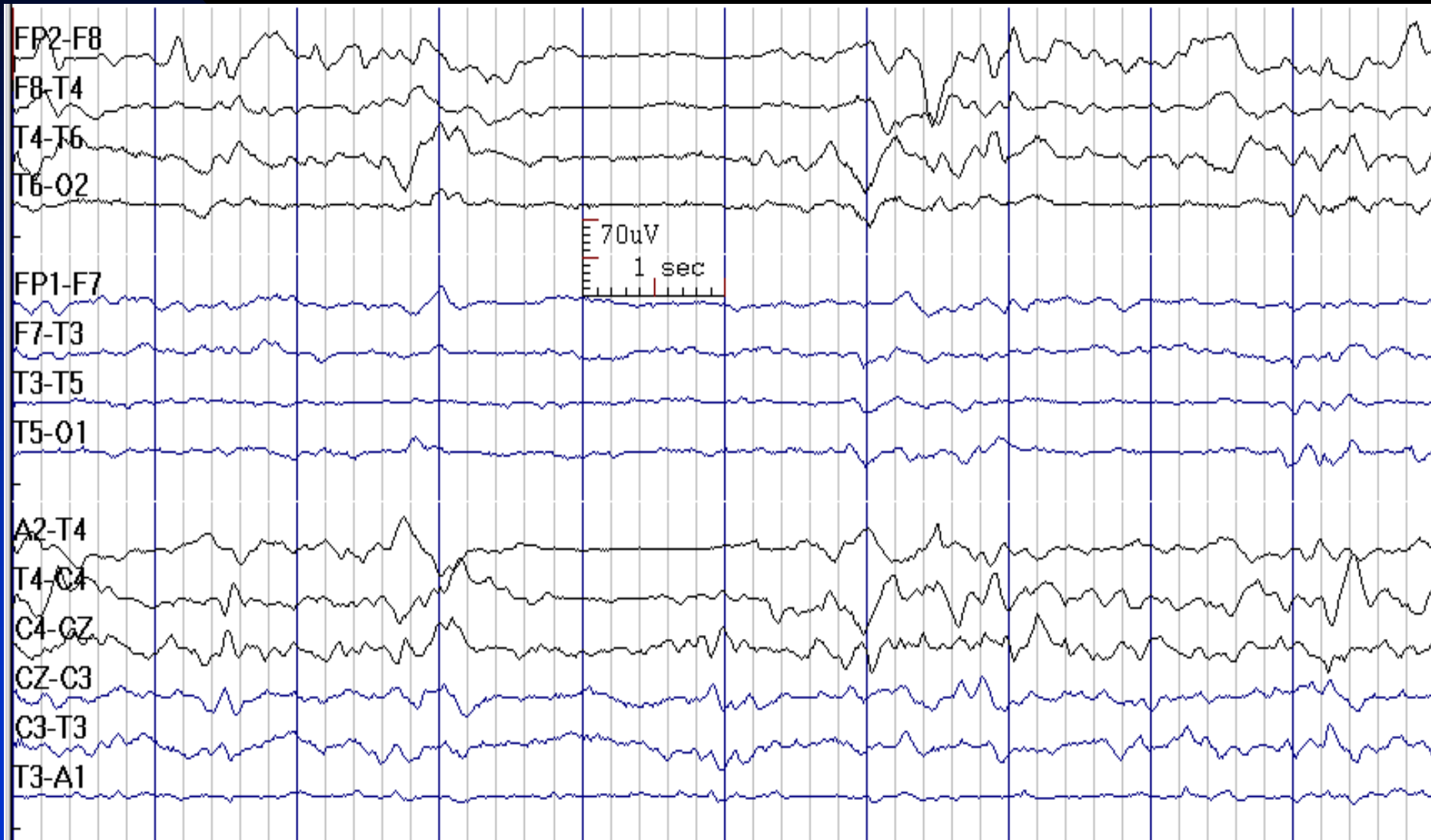


# Burst-Suppression in a 20-Year-Old

## Man with Anoxic Brain Injury

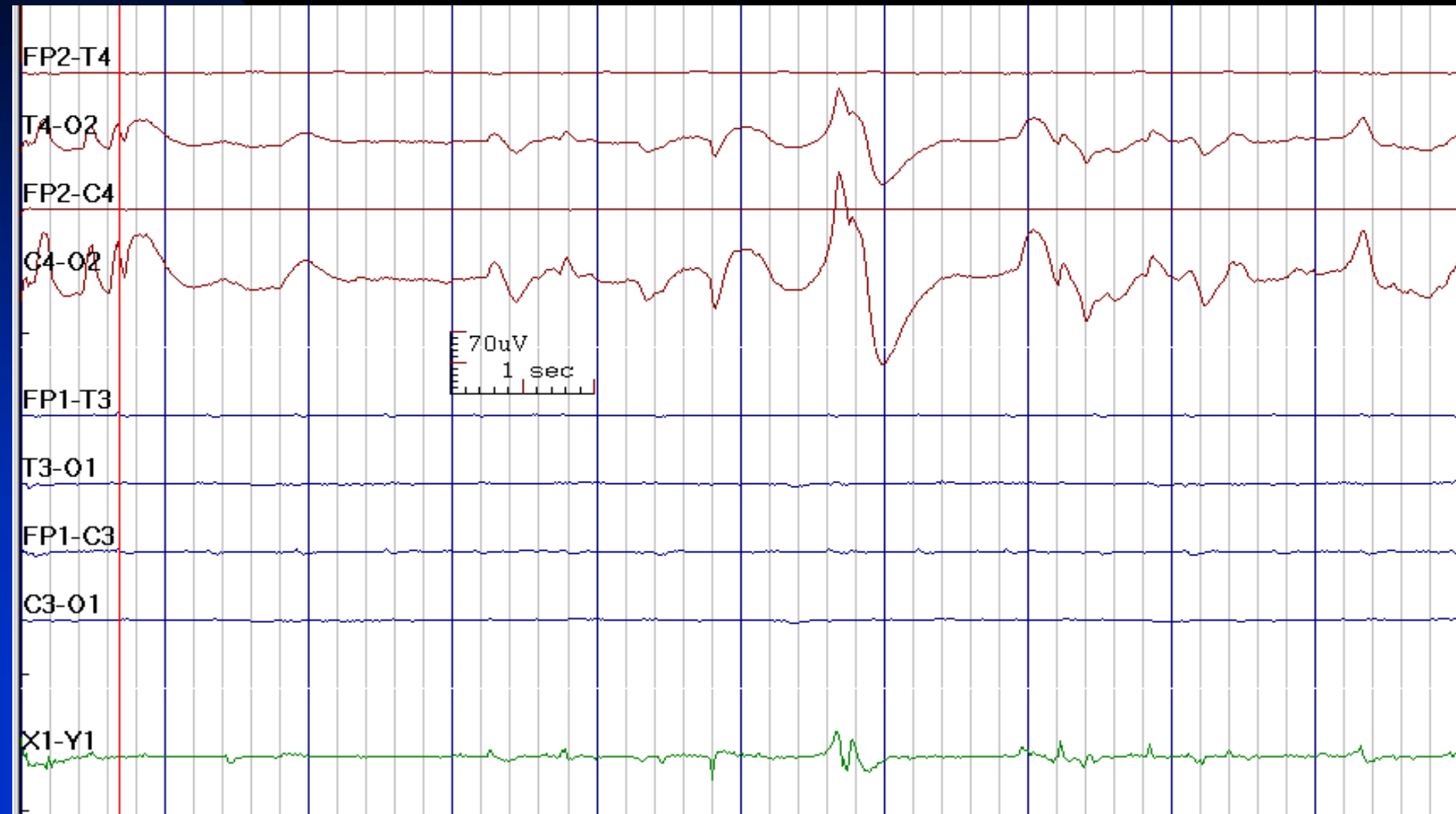


# Burst-Suppression Pattern in a 82-Year-Old Woman after Resuscitation for Cardiac Arrest



# Electrocerebral Inactivity after Cardiorespiratory Arrest:

Prognosis is Very Poor (Note O2 Electrode Artifact)



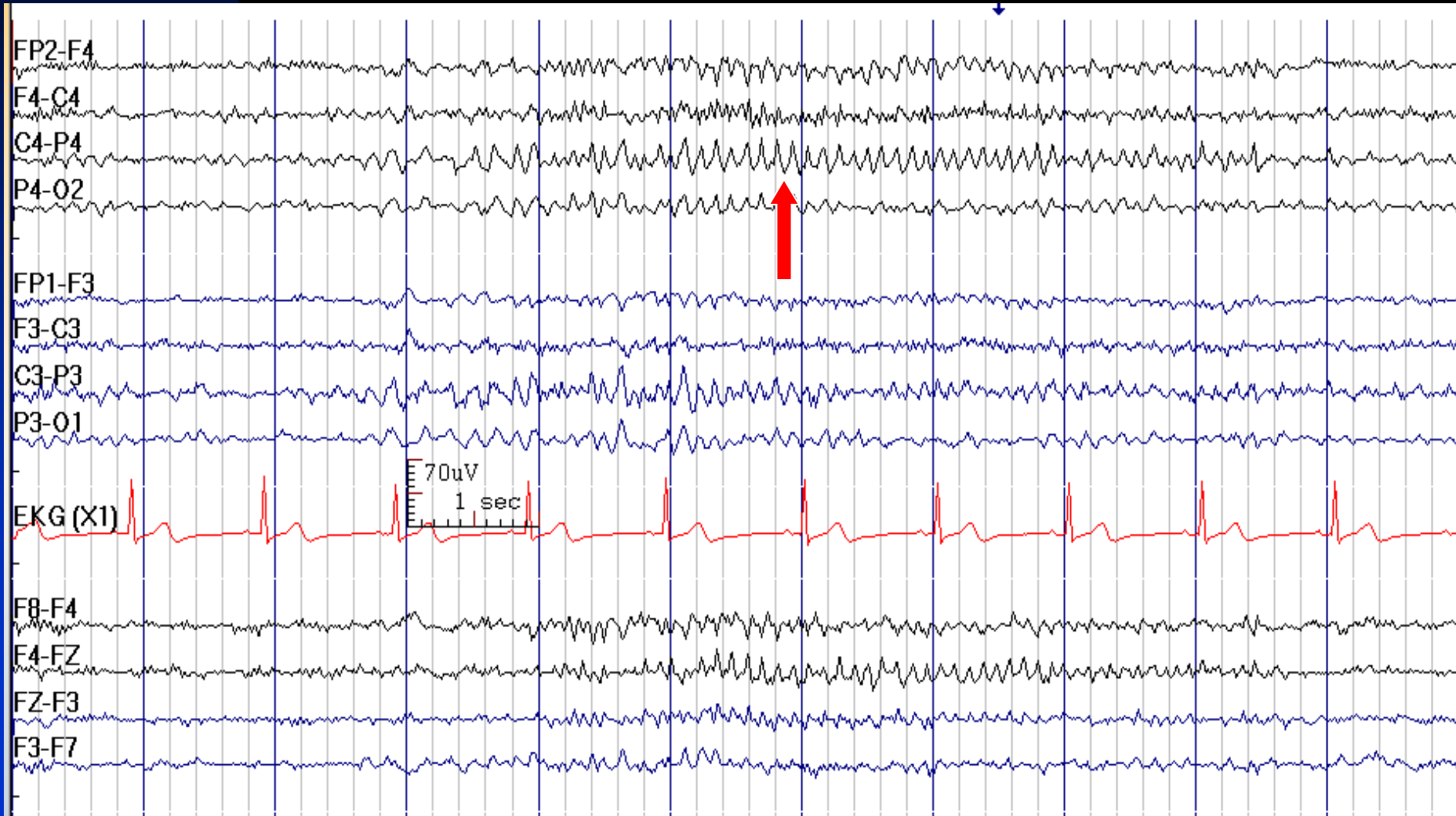
# How to Report Burst-Suppression Pattern

- *In conclusion section, write:*
  - ◆ This EEG shows evidence for severe, diffuse cerebral dysfunction, and carries a poor prognosis in the setting of cerebral anoxia (after cardiac or respiratory arrest), but has variable prognosis with toxic / metabolic encephalopathy.

# **Chapter 9**

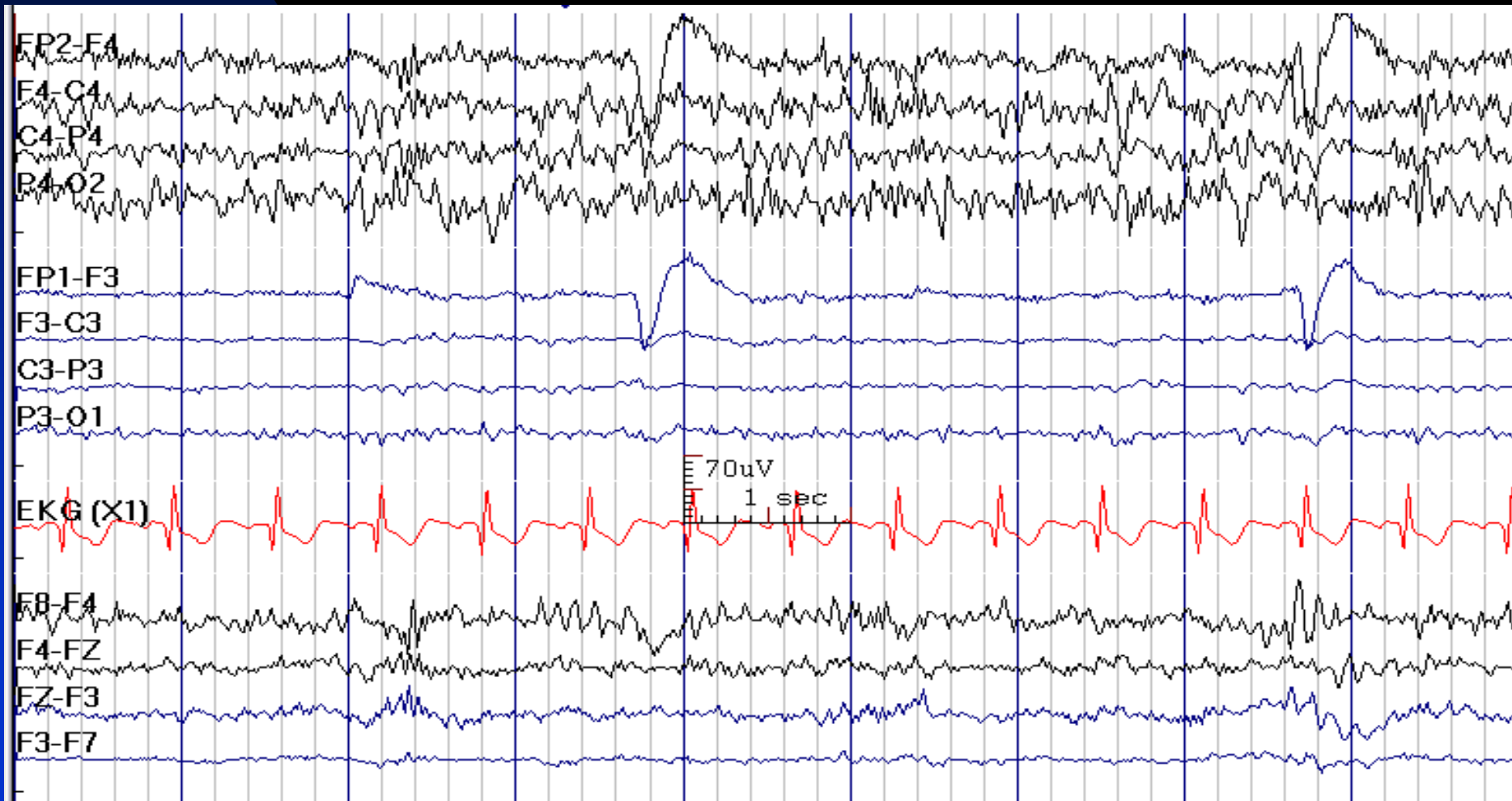
## **Unclassified EEG Findings**

# Mu Like Activity in Sleep over Right Central Region in a 40-Year-Old Man with Cortical Gliosis and Epilepsy





# Great Asymmetry with Almost Absence of EEG Activities in a 11-Year-Old Boy after Left Hemispherectomy (Rasmussen Encephalitis)

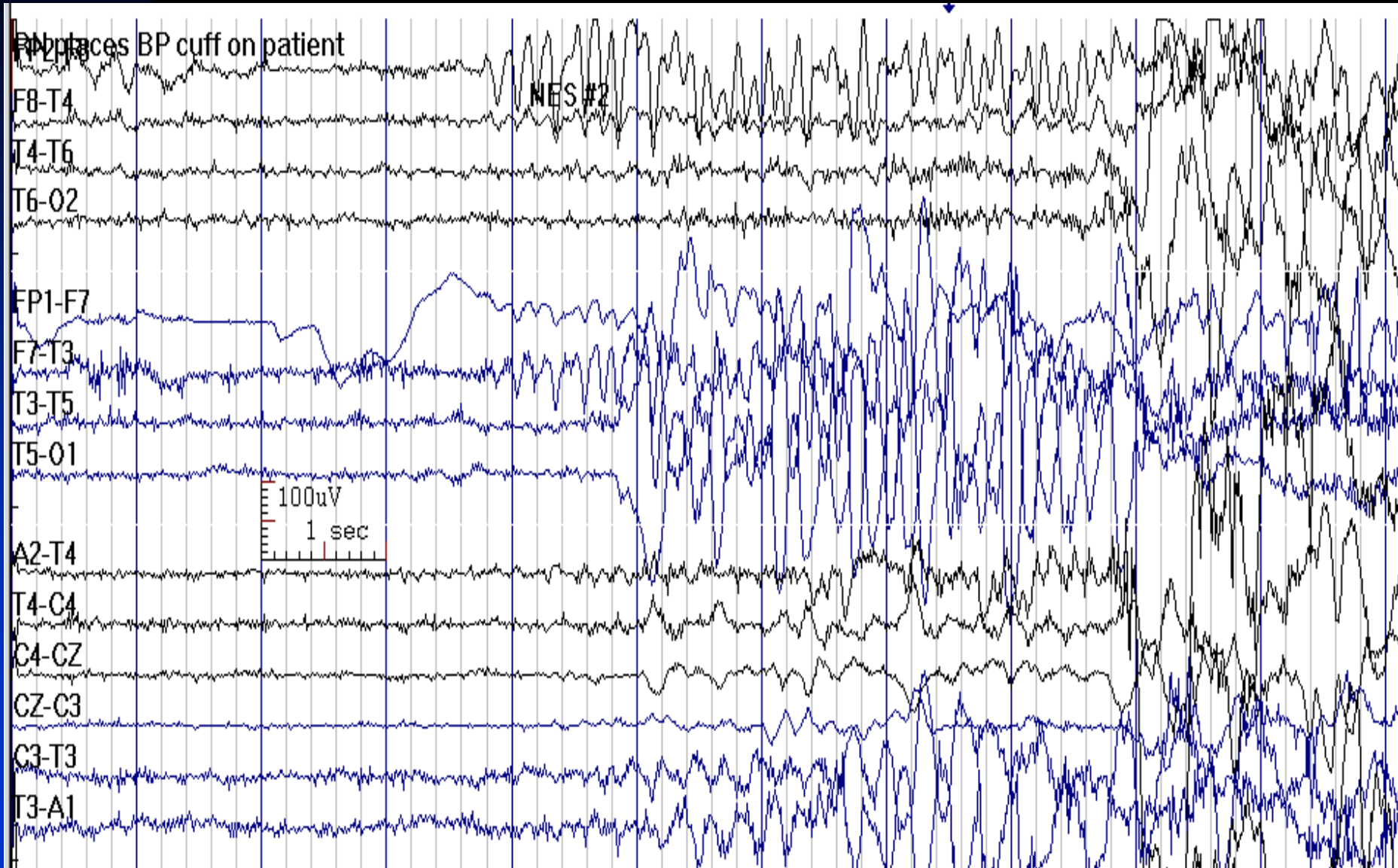


# A Normal Appearing EEG in a Comatose Patient

- Psychogenic unresponsiveness
- Locked-in syndrome: lesions in ventral pons
- Brainstem lesion: upper pons and caudal midbrain (bilateral pontine tegmentum involvement)

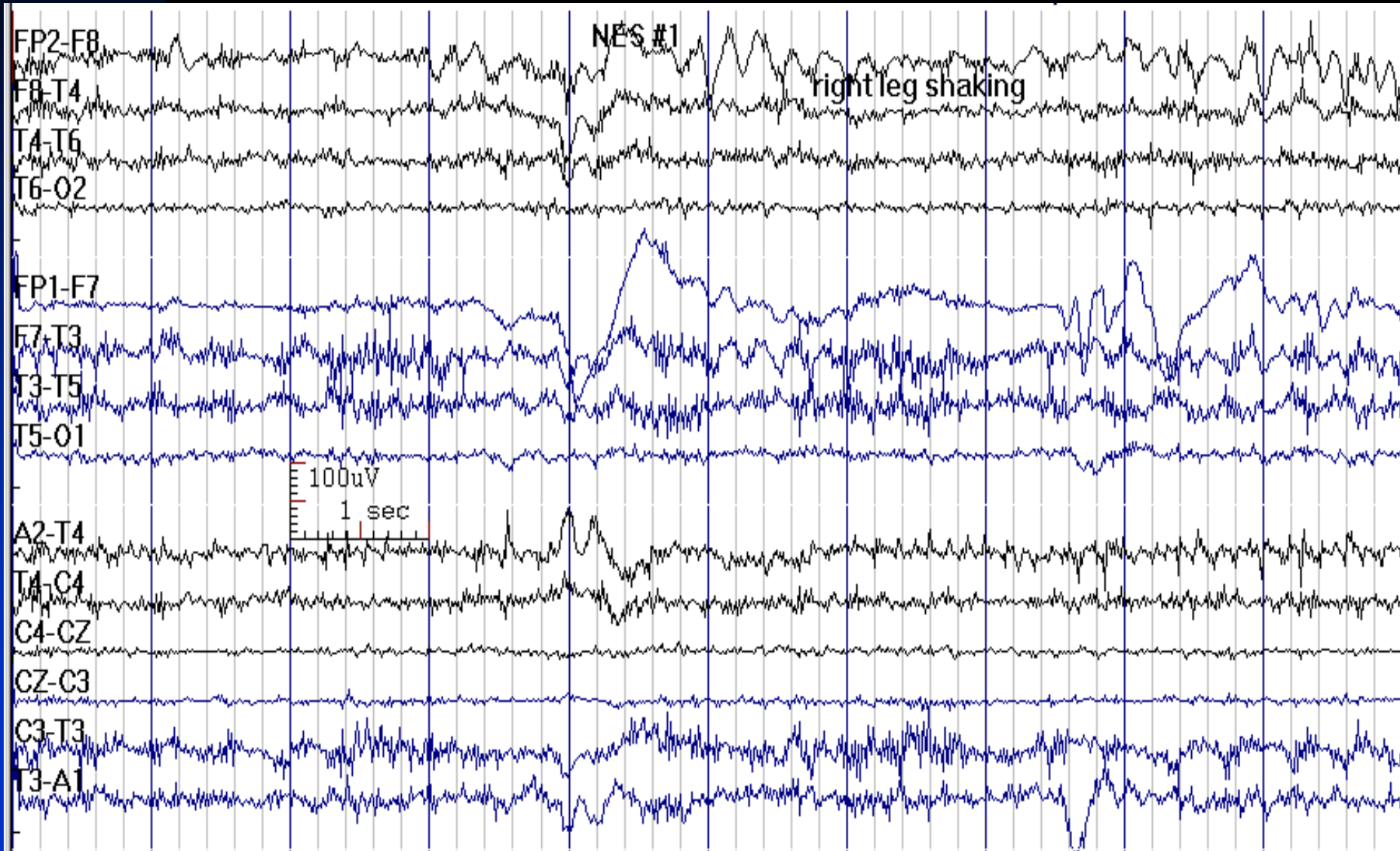
# Psychogenic Non-Epileptic Seizure:

## The Background Rhythm is Normal; Note Movement Artifacts



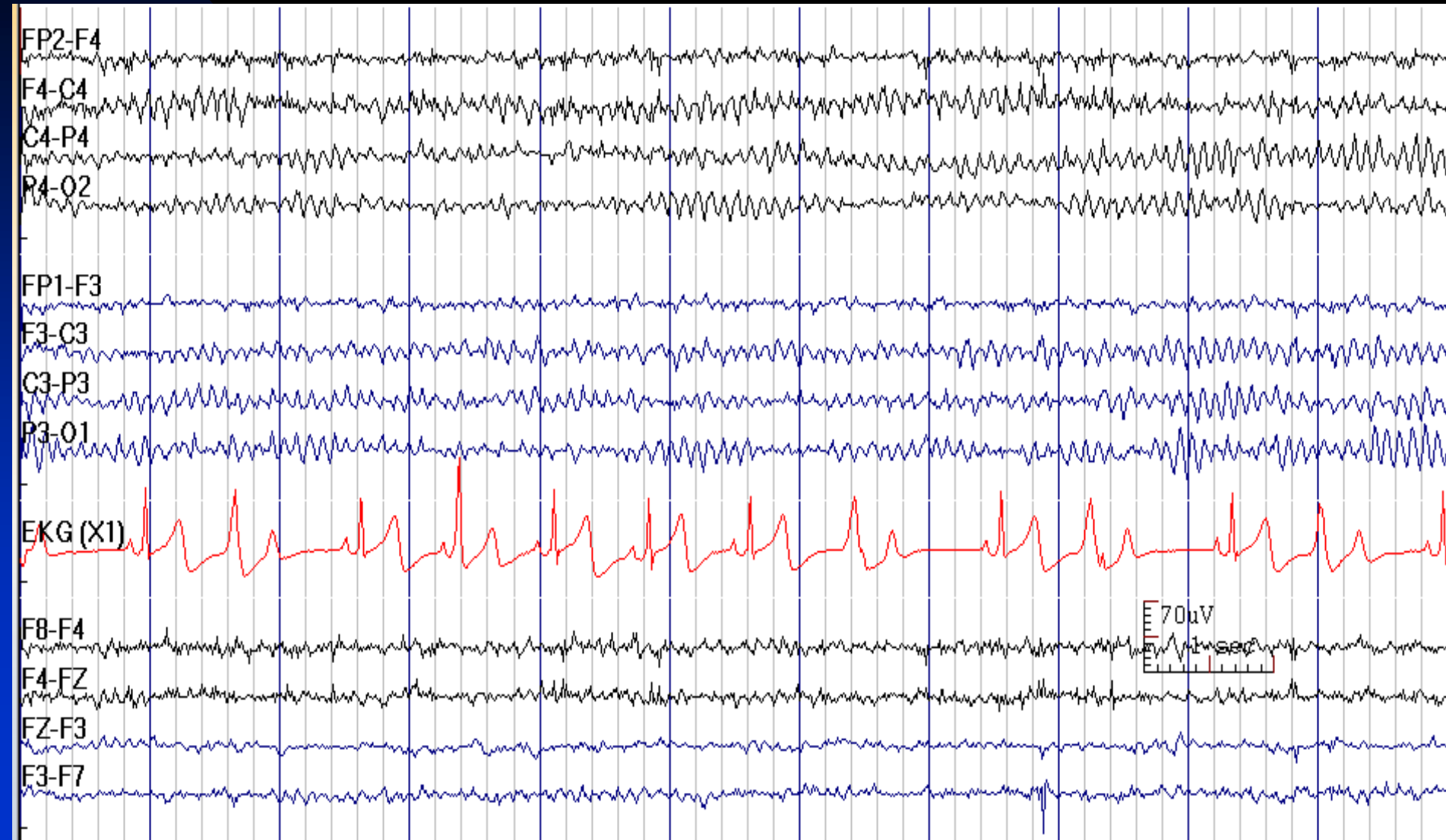
# Psychogenic Non-Epileptic Seizure:

## The Background Rhythm is Normal at the Time of Seizure

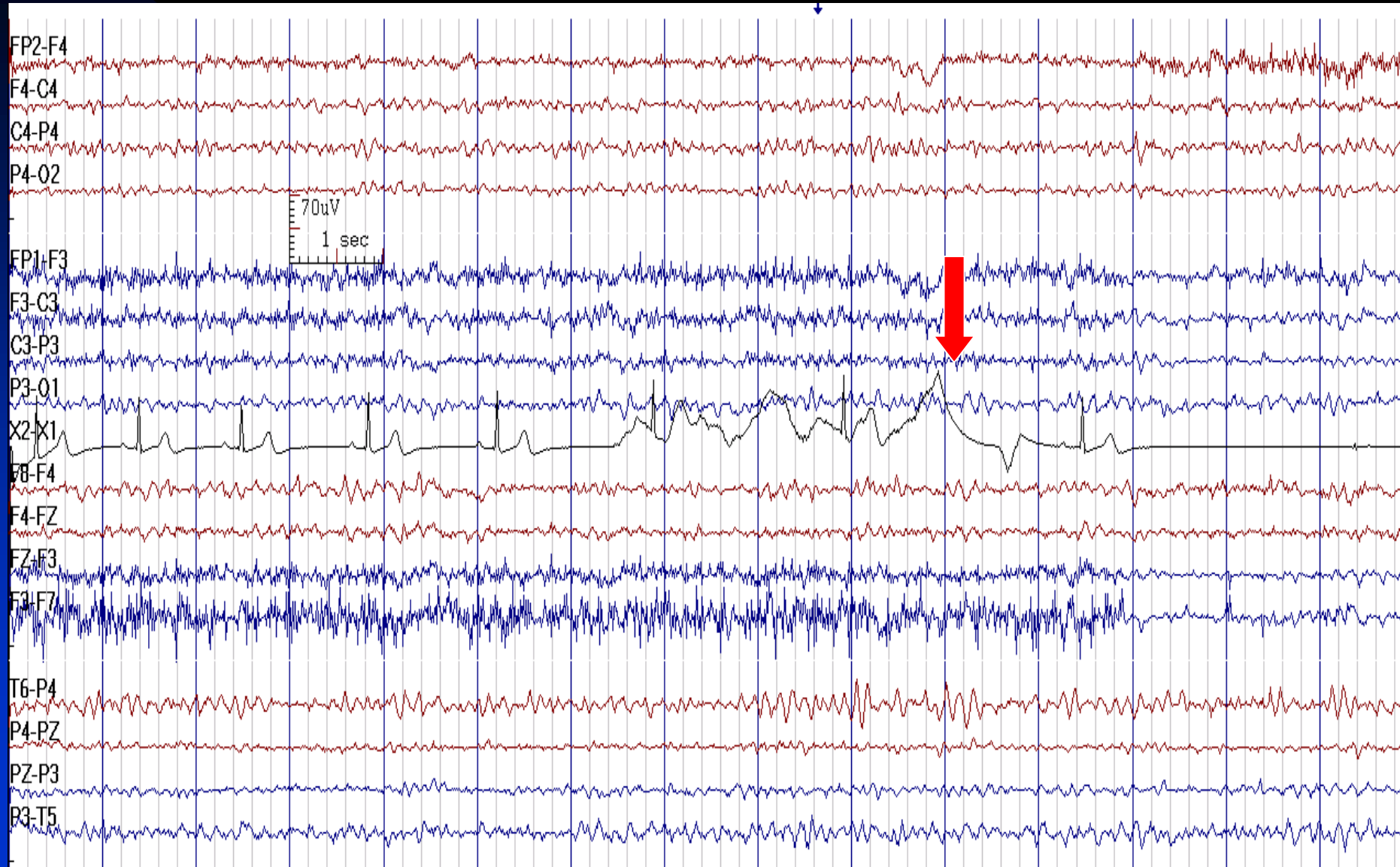


# Cardiac Dysrhythmia and Normal EEG

## in a Patient with Syncope

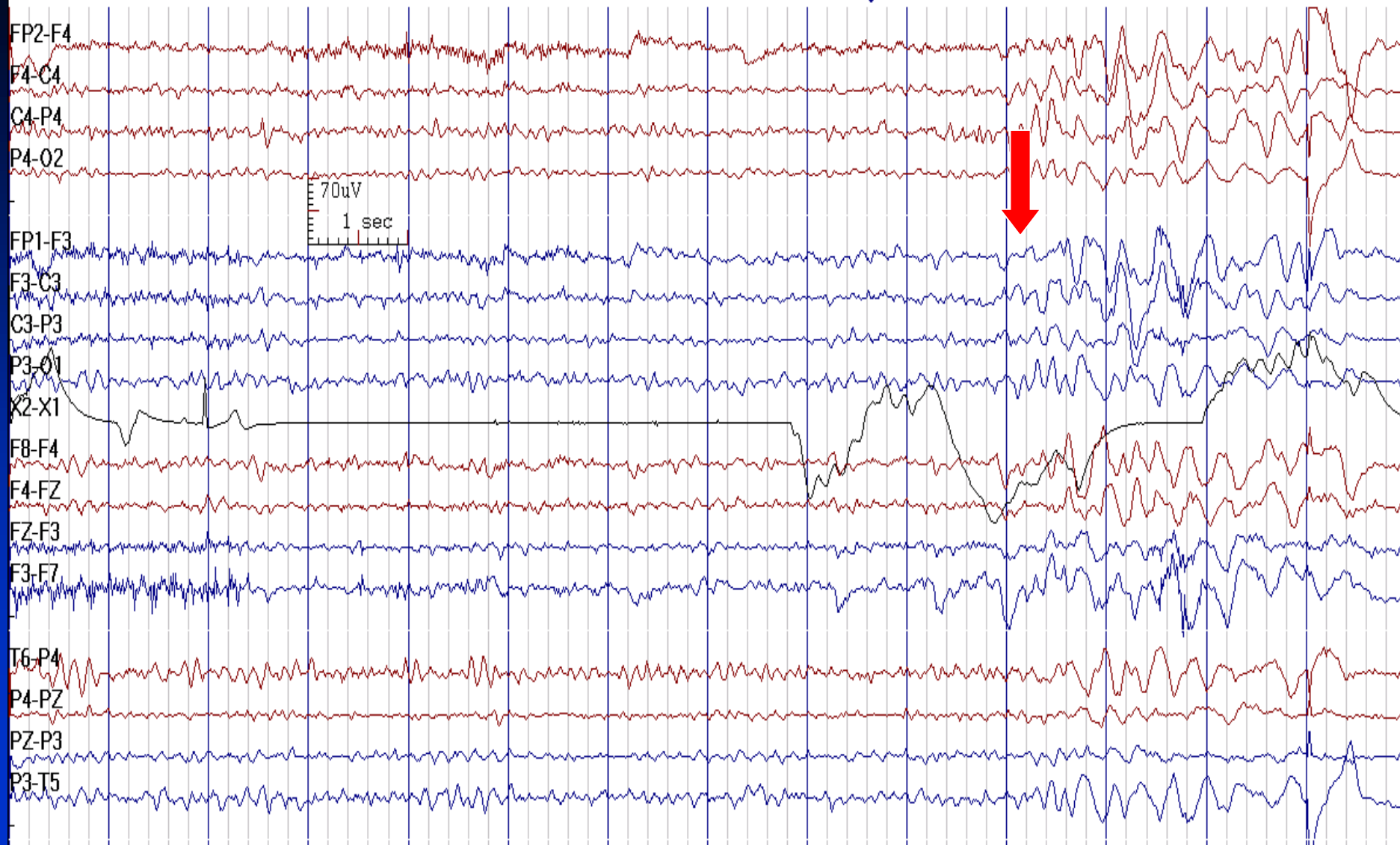


# Cardiac Asystole in a Patient with Syncope

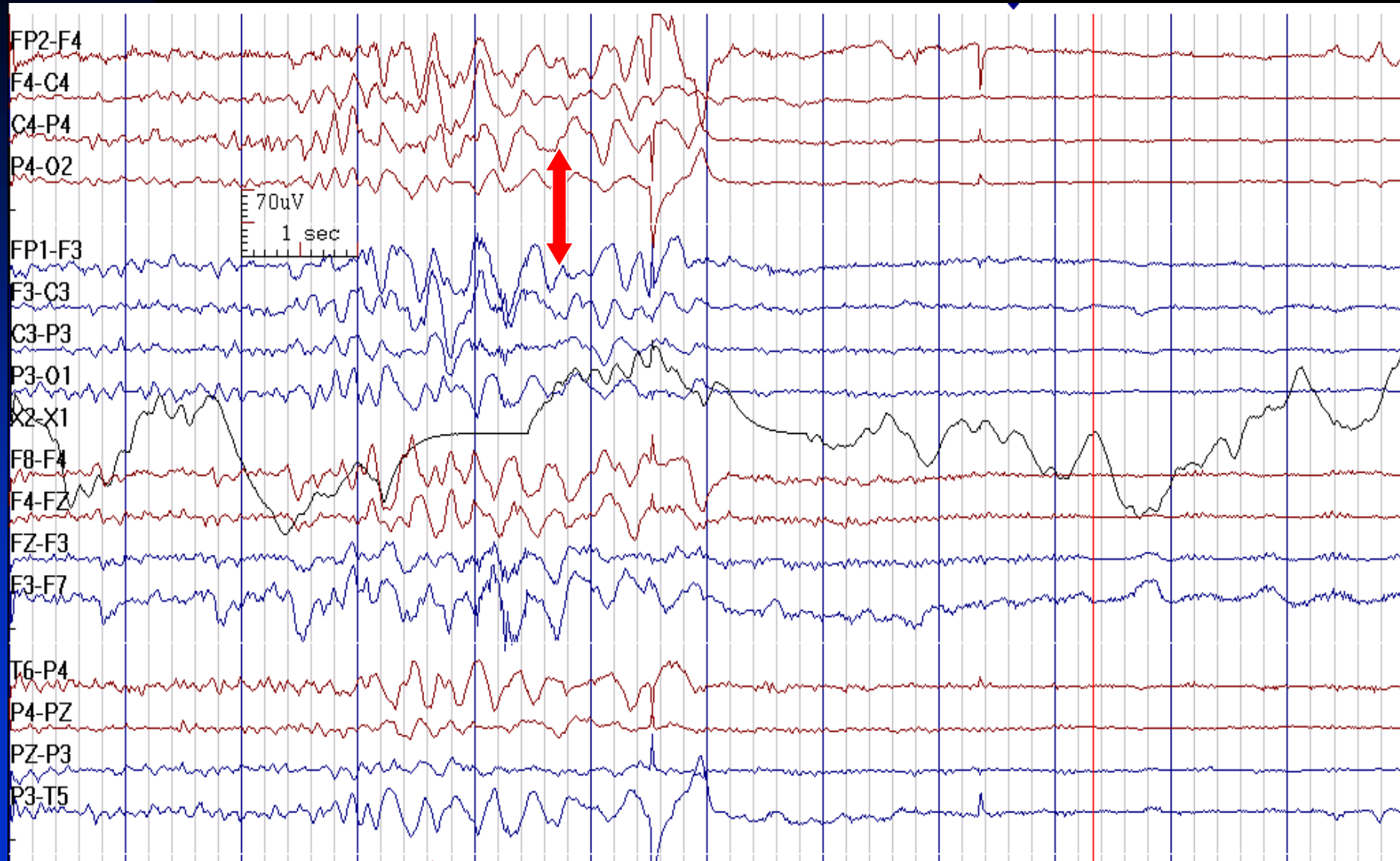




# Cardiac Asystole Leading to Generalized EEG Slowing

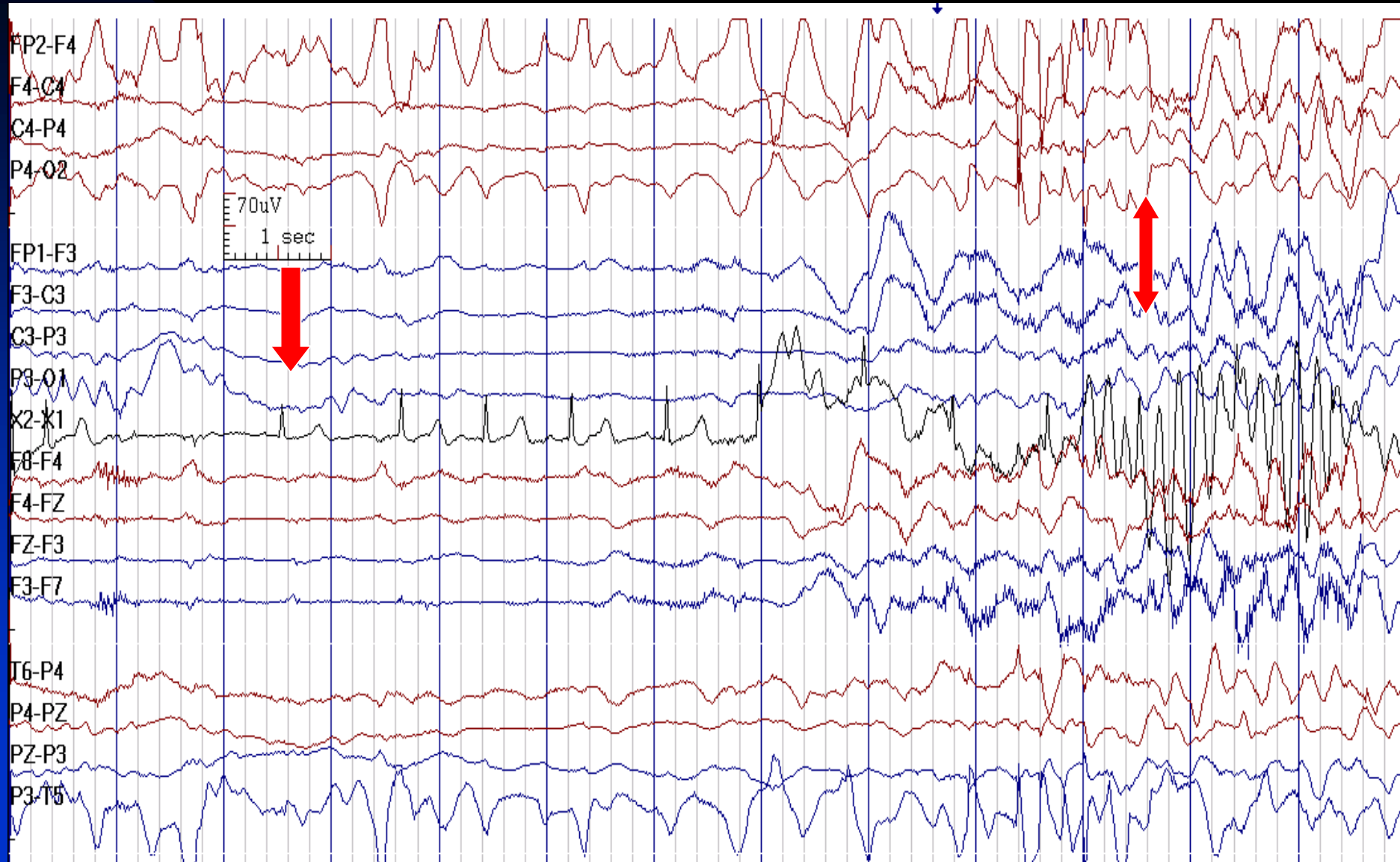


# Cardiac Asystole Leading to Diffuse Attenuation of EEG Activities

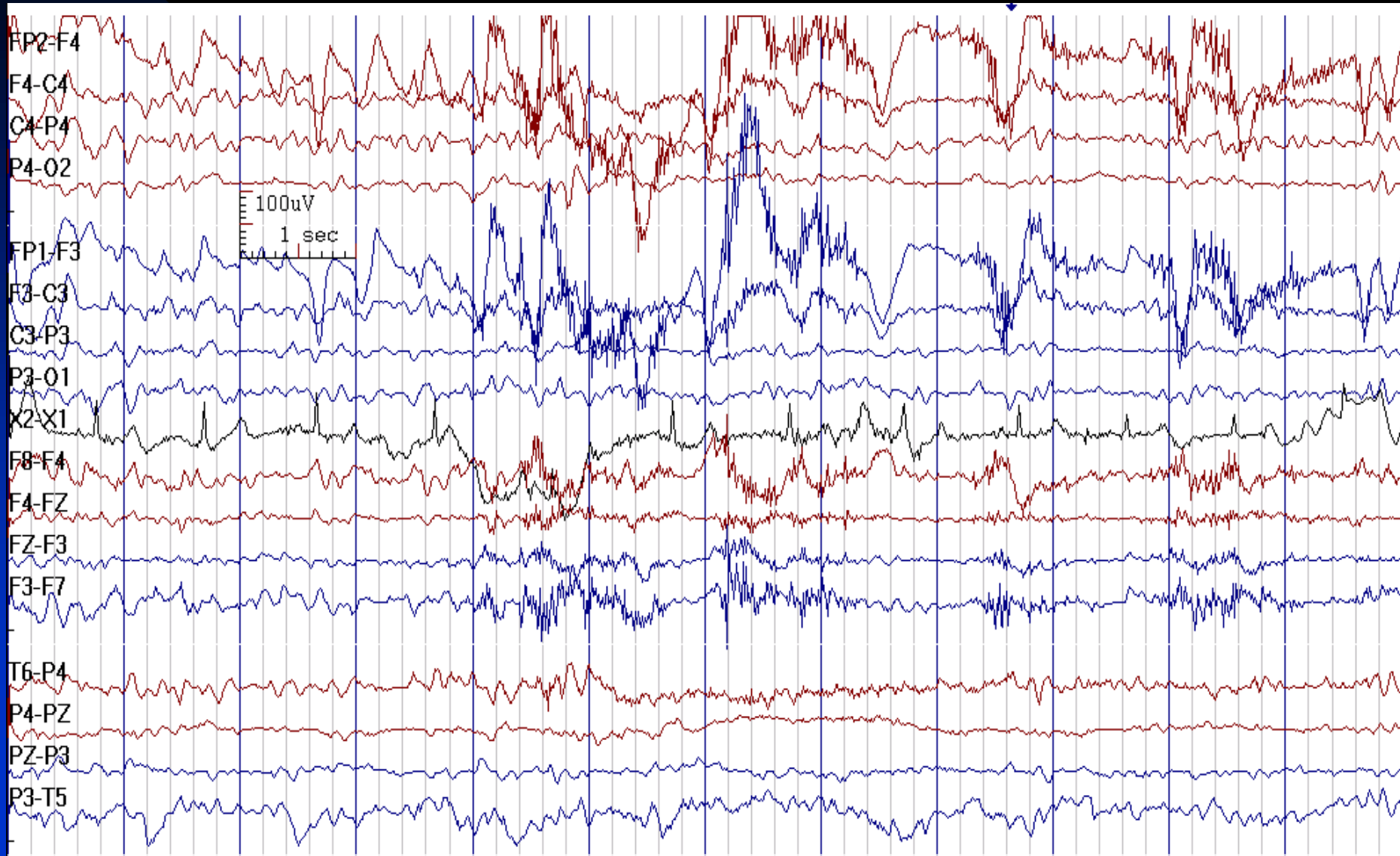




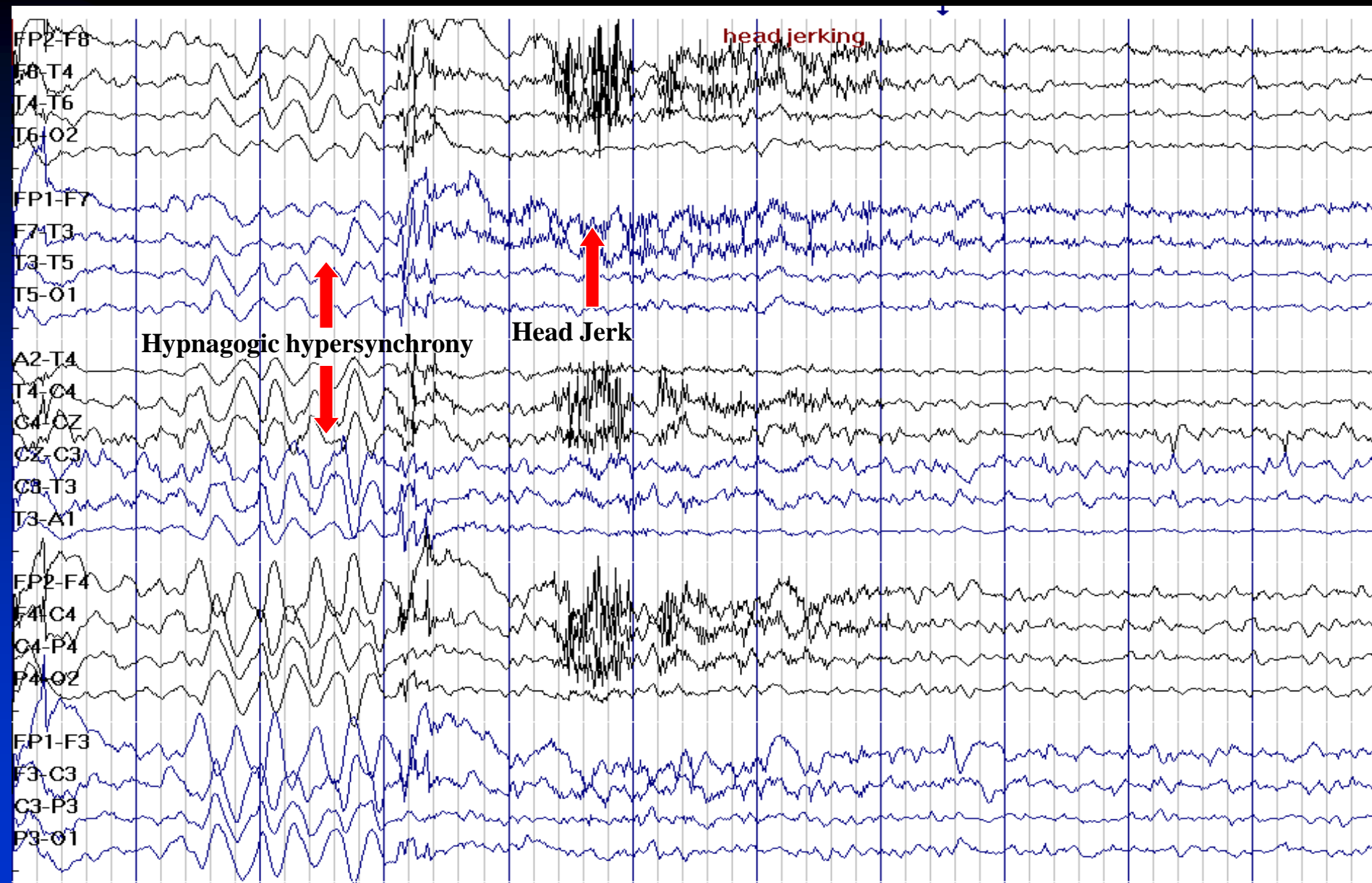
# Resolution of Asystole Leading to Resolution of EEG Activities



# Resolution of Asystole Leading to Resolution of Normal EEG Activities



# Sleep Myoclonus (Hypnic Jerk): A Normal Event



# References

- Asadi-Pooya AA, Emami M, Sperling MR. A clinical study of syndromes of idiopathic (genetic) generalized epilepsy. J Neurol Sci 2013; 324(1-2): 113-117
- Asadi-Pooya AA. Atlas of Ictal EEG. Shiraz, Iran; Shiraz University of Medical Sciences Publications; 2014
- Asadi-Pooya AA & Sperling MR. Atlas of EEG reports. Shiraz, Iran; Shiraz University of Medical Sciences Publications; 2014
- Beniczky S, Hirsch LJ, Kaplan PW, et al. Unified EEG terminology and criteria for nonconvulsive status epilepticus. Epilepsia 2013;54 Suppl 6: 28-29
- Blume WT, Kaibara M. Atlas of Pediatric Electroencephalography. 2<sup>nd</sup> Ed. 1999, Lippincott-Raven
- Brenner RP. The Interpretation of the EEG in Stupor and Coma. The Neurologist 2005;11:271-284
- Ebersole JS, Pedley TA. Current Practice of Clinical Electroencephalography. 3rd ed. 2003, Lippincott Williams & Wilkins

- Fisch BJ. Fisch and Spehlmann's EEG Primer: Basic Principles of Digital and Analog EEG. 3<sup>rd</sup> Ed. 1999, Elsevier
- Goldensohn ES, Legatt AD, Koszer S, Wolf SM. Goldensohn's EEG Interpretation: Problems of Overreading and Underreading. 2nd Ed. 1999, Wiley-Blackwell
- Niedermeyer E, Da Silva FL. Electroencephalography. 5th Ed. 2004, Williams & Wilkins
- Rowan AJ, Tolunsky E. Primer of EEG: With A Mini-Atlas. 2003, Butterworth-Heinemann
- Tatum WO. Handbook of EEG Interpretation. 2007, Demos Medical Publishing
- Trinka E, Leitinger M. Which EEG patterns in coma are nonconvulsive status epilepticus? Epilepsy Behav 2015; 49: 203-222
- Verma A, Radtke R. EEG of Partial Seizures. J Clin Neurophysiol 2006; 23: 333-339
- <https://www.acns.org/> accessed on 04.18.2017