

Supplementary figure 1. The Moro reflex elicited in an anencephalic infant. The figure is taken from the original report by the Austrian neurologist, Eduard Gamper (1887–1938), Head of the Department of Neuropsychiatry at the Charles University's German Faculty of Medicine in Prague, with the first medical description of anencephaly [1].

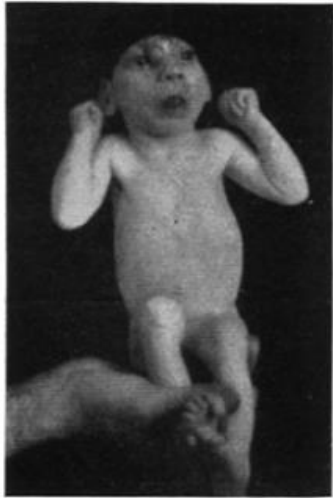

Abb. 6 a.

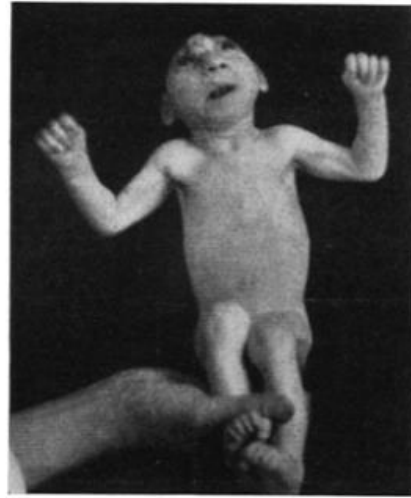


Abb. 6 b.

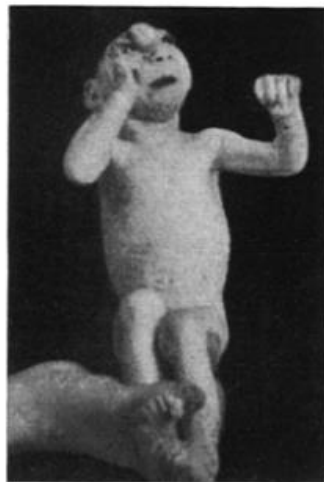

Abb. 6 c.

Abb. 6a – c. Moroscher Umklammerungsreflex bei Anblasen des Kindes. Dorsalflexion des Kopfes, Abduction in beiden Schultergelenken unter Streckung der Vorderarme und Handgelenke, darauf (c) Adduction in beiden Schultergelenken unter Beugung der Ellbogen.

Supplementary figure 2. The “Madonna and Child enthroned with Saints” fresco by Ambrogio Lorenzetti (1290-1348), preserved in St. Augustine Church (Siena, Italy).

