

# Split-screen synchronized display. A useful video-EEG technique for studying paroxysmal phenomena

Paolo Tinuper, Carlo Grassi, Francesca Bisulli, Federica Provini, Giuseppe Plazzi, Elena Zoni, Elio Lugaresi

Department of Neurological Sciences, University of Bologna, Bologna, Italy

Received November 4, 2003; Accepted December 18, 2003

**ABSTRACT** – Video-EEG is an indispensable and widely used technique for studying paroxysmal phenomena. We present a method of processing video recordings to compare the sequence of ictal manifestations of different episodes. Five presentations of two seizures recorded in each of five patients are shown, in which apparently different ictal features are strongly superimposed and stereotyped. Split-screen synchronized display is a simple and valid technique for studying and presenting particular semeiological aspects of epileptic seizures. (Published with videosequences)

**KEY WORDS:** epileptic seizures, video-EEG, semeiology, video-synchronisation, video-EEG monitoring

Since its introduction [1, 2], video-EEG has provided tremendous insight into the semeiological aspects of epileptic seizures. The possibility of reviewing the video in real time, slow motion, and accelerated time allows the sequence of the ictal signs to be studied in depth and to be correlated to the ictal epileptic discharge. Prolonged video-EEG monitoring is widely used in the presurgical evaluation of drug-resistant epilepsies, and for studying paroxysmal motor phenomena of uncertain origin, and particularly for differentiating epileptic from non-epileptic (psychogenic) seizures. Furthermore, recording seizures by video and storing them in stable supports (U-MATIC, VHS and SVHS cassettes, and more recently CD or DVD diskettes) meets other important targets such as teaching, staff training, exchange of information between specialists, and clinical follow-up of the seizure pattern of

certain patients. Recording different seizure types in the same patient could pose a clinical problem, especially in a presurgical setting, because of the consequent need to define different epileptogenic areas or to exclude non-epileptic seizures. On the other hand, recording more seizures with the identical clinical sequences in the same patient confirms the presence of a unique and stable epileptogenic zone. In addition, the possibility of recording many identical seizures in the same patient, even those with prolonged and complex semeiology, confirms the nature of clear-cut cortical phenomena. To achieve a more direct comparison of different episodes, we adopted a simple method that we named split-screen synchronized display (SSSD). The object of this paper is to briefly describe the SSSD method and to show some examples of elaboration.



**Correspondence:**

Paolo Tinuper  
Dipartimento di Scienze Neurologiche,  
Università di Bologna,  
Via Ugo Foscolo 7, 40123 Bologna, Italy  
E-mail: tinuper@neuro.unibo.it

## Methods

Analogue recording of seizures, currently performed during video-EEG sessions, are stored on SVHS tapes. The different seizures we want to compare are then digitalised on Pentium III 400 computer with a double processor and with a Windows NT operative system. Images are processed with Liquid Purple software (Pinnacle). On one monitor, the two different seizures are displayed. On the second monitor a Time line (8 audio channels and 16 parallel video channels) is used to synchronize the clips of the two seizures.

From the first monitor we choose the first clip of the first seizure and the first clip of the second seizure, putting a marker at the beginning of the sequences to be processed. We transport the clips on the Time line and we synchronize the markers.

The programme records the two seizures and displays the final sequence on a split-screen.

Processed images can thereafter be stored on a digital or an analogue support (*figure 1*).

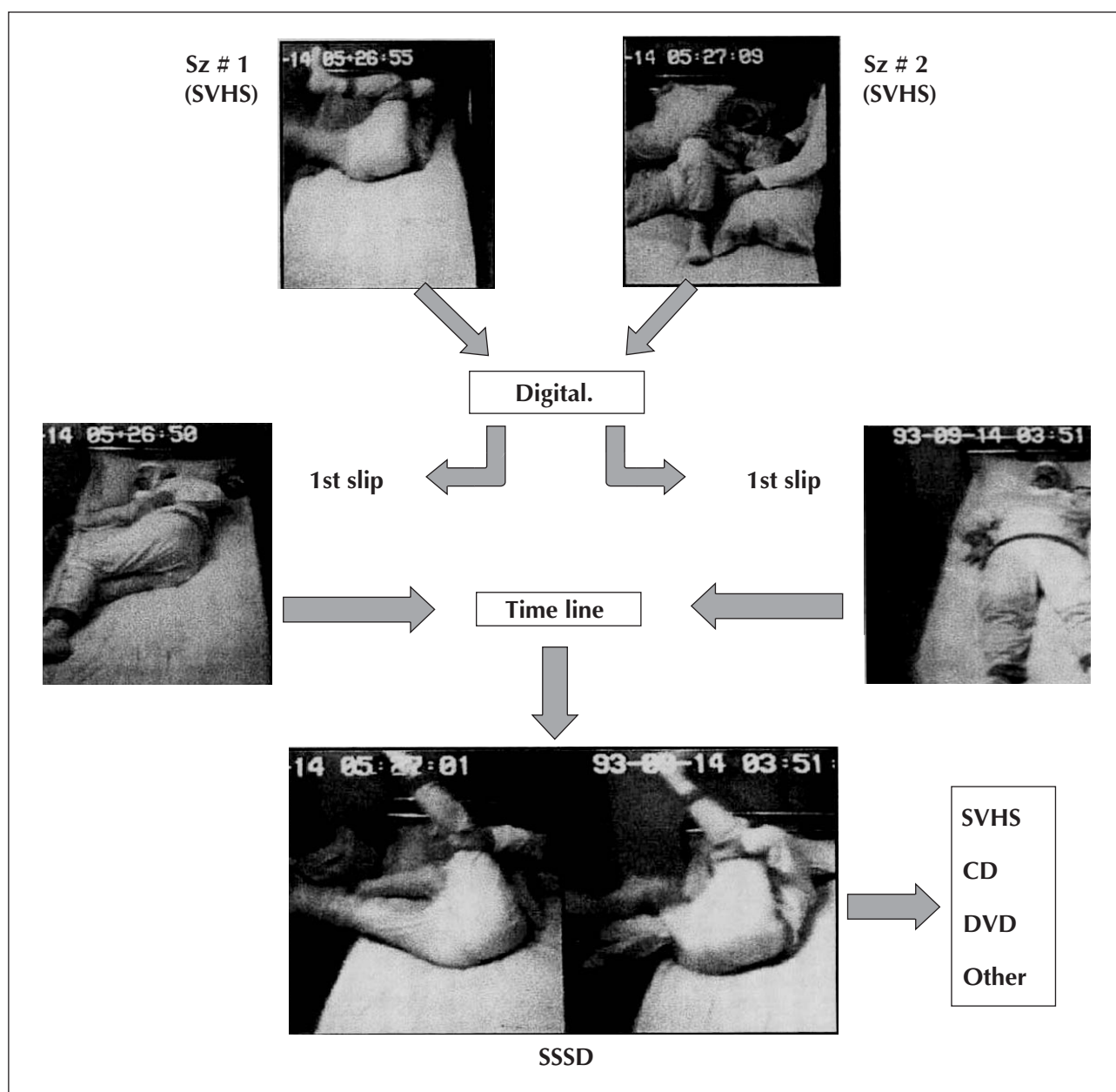


Figure 1.

## Discussion

The method we have presented has several clinical uses. Firstly, in a clinical setting, the possibility of comparing two or more sequences of different phenomena makes it easier for the examiner to grasp similarities, differences or stereotypy. This can be useful in studying different seizures in different patients, or different fits in the same patient. Moreover, the simplicity and immediacy of the final product enhances its teaching impact. Another important point, not tackled here, is the scientific interest in recording almost identical, often complex motor sequences in the same patient, even years apart, suggesting a pre-coded ictal behaviour, following the same progression and in the same rate over days or years. As shown in the video samples, we present patients with seizures of frontal origin, almost all with nocturnal frontal lobe epilepsy. This is due to the fact that we perfected the SSSD method when studying this series of patients. It would be of great interest however, to perform the same video processing, studying patients with extra-frontal seizures, to help elucidate the physiopathological mechanisms underlying the production of ictal motor sequences. □

### Acknowledgements

We are grateful to the patients, who gave permission to use the video documents. We thank the EEG technicians of the Department of Neurological Sciences of the University of Bologna who performed video-EEG recordings. Anne Collins edited the manuscript.



### Videotape captions

#### Segment 1

A 22 year-old man, with drug-resistant partial seizures originating from the left frontotemporal areas since infancy. Two seizures are displayed, recorded on different days during prolonged presurgical monitoring. At the beginning of both seizures, the patient opens his eyes, raises his right arm and whistles repeatedly, rocking backwards and forwards in the chair. Suddenly, he turns his head and trunk towards the left, stiffening his right limbs, the upper one flexed at the wrist and at the elbow, while the left limbs are used to balance his posture. Thereafter, a slow, clonic version of the head and eyes towards the right side appears, with the patient looking at his right arm, raised and flexed.

Note the stereotyped semeiology of the two seizures, not only regarding the motor phenomenon, but also the timing of the progression of the seizure.

#### Segment 2

This 40 year-old-man presents repetitive seizures during sleep. The previous diagnosis was "psychogenic

seizures". We display two seizures recorded during the same night. Even if the seizures are characterized by violent, quasi-ballistic limb movements, it is impressive how the two seizures have identical motor features and progression of the motor behaviour, making the effects of the same seizures a mirror image. The final diagnosis was nocturnal frontal lobe epilepsy (NFLE) [3, 4, 9-13], and carbamazepine proved effective.

#### Segment 3

This 19 year-old woman was referred for repetitive "convulsive" seizures during sleep since adolescence. The previous diagnosis was generalized idiopathic epilepsy with *grand mal* seizures, and she was treated with phenobarbital without effect. On one night, we recorded several attacks, characterized by a bilateral, asymmetric, tonic posturing, involving the trunk and the limbs, more pronounced on the right side. During the seizures, the patient maintained contact but she was unable to speak. The clinical semeiology indicates an ictal involvement of the supplementary motor area [7, 12, 13]. SSSD makes it easy to observe the absolute stereotypy of the seizures.

#### Segment 4

This 24 year-old patient had paroxysmal arousals (PA) during sleep, a subtype of NFLE seizures [5, 9-13], characterized by sudden awaking during non-REM sleep. As is shown in the video, the patient, sleeping in stage 2, suddenly sits up in bed, with a frightened expression. Even if the attacks are very brief, it is noteworthy how the motor sequence is identical in the two seizures displayed.

#### Segment 5

This boy had presented very frequent nocturnal episodes of differing intensities since an early age. On some occasions during attacks, he jumped out of bed and began to walk or run in the bedroom, trying to go out. In this regard, he was assumed to have pavor episodes and sleep walking. However, episodes were very frequent, occurring many times a night, and the patient came to us for prolonged video-polygraphic recording. Several seizures have been recorded. Some very short attacks constituted PA, whereas other, longer and more complex episodes had the characteristics of typical NFLS. We also recorded very prolonged episodes mimicking sleep-walking, but which were accompanied on EEG by a prolonged epileptiform discharge predominant over the frontal regions, leading to a diagnosis of epileptic wandering [6-10]. In the tape, we show two episodes, recorded during the same night. Even if the behaviour is complex, the two seizures were remarkable for their stereotypy in the sequence and the timing of the complete act.

## References

1. Hunter J, Jasper HH. A method of analysis of seizure pattern and electroencephalogram: a cinematographic technique. *Electroencephalogr Clin Neurophysiol* 1949; 1: 113-4.
2. Goldensohn ES. Simultaneous recording of EEG and clinical seizures using a kinescope. *Electroencephalogr Clin Neurophysiol* 1966; 21: 623.
3. Lugaresi E, Cirignotta F. Hypnogenic paroxysmal dystonia: epileptic seizures or a new syndrome? *Sleep* 1981; 4: 129-38.
4. Lugaresi E, Cirignotta F, Montagna P. Nocturnal paroxysmal dystonia. *J Neurol Neurosurg Psychiatry* 1986; 49: 375-80.
5. Montagna P, Sforza E, Tinuper P, Cirignotta F, Lugaresi E. Paroxysmal arousals during sleep. *Neurology* 1990; 40: 1063-6.
6. Montagna P. Nocturnal paroxysmal dystonia and nocturnal wandering. *Neurology* 1992; 42 (Suppl.6): 61-7.
7. Morris HH, Dinner DS, Luders H, Wyllie E, Kramer R. Supplementary motor seizures: clinical and electroencephalographic findings. *Neurology* 1988; 38: 1075-82.
8. Plazzi G, Tinuper P, Montagna P, Lugaresi E. Epileptic nocturnal wanderings. *Sleep* 1995; 18: 749-56.
9. Provini F, Plazzi G, Tinuper P, Vandi S, Lugaresi E, Montagna P. Nocturnal frontal lobe epilepsy. A clinical and polygraphic overview of 100 consecutive cases. *Brain* 1999; 122: 1017-31.
10. Provini F, Plazzi G, Montagna P, Lugaresi E. The wide clinical spectrum of nocturnal frontal lobe epilepsy. *Sleep Med Rev* 2000; 4: 375-86.
11. Tinuper P, Cerullo A, Cirignotta F, Cortelli P, Lugaresi E, Montagna P. Nocturnal paroxysmal dystonia with short-lasting attacks: three cases with evidence for an epileptic frontal lobe origin of seizures. *Epilepsia* 1990; 31: 549-56.
12. Tinuper P, Baruzzi A. Seizures during sleep. In: D. Schmidt, S. Schachter Eds. *Epilepsy: Problem Solving in Clinical Practice*. Martin Dunitz, London, 1999: 5-17.
13. Tinuper P, Lugaresi E, Vigeveno, Berkovich SF. Nocturnal frontal lobe epilepsy. In: R. Guerrini, J. Aicardi, F. Andermann and M. Hallett (Eds.). *Epilepsy and movement disorders in children*. Cambridge University Press, Cambridge 2002: 97-110.
14. Wada J.A. Nocturnal recurrence of brief, intensely affective vocal and facial expression with powerful bimanual, bipedal, axial, and pelvic activity with rapid recovery as manifestations of mesial frontal lobe seizure. *Epilepsia* 1988; 29: 209.