

# Semiological study of ictal affective behaviour in epilepsy and mental retardation limited to females (EFMR)

Elena Antelmi<sup>1</sup>, Massimo Mastrangelo<sup>2</sup>, Francesca Bisulli<sup>1</sup>, Luigina Spaccini<sup>2</sup>, Carlotta Stipa<sup>1</sup>, Barbara Mostacci<sup>1</sup>, Davide Mei<sup>3</sup>, Renzo Guerrini<sup>3</sup>, Paolo Tinuper<sup>1</sup>

<sup>1</sup> IRCCS, Institute of Neurological Sciences, Department of Neurological Sciences, University of Bologna, Bologna

<sup>2</sup> Pediatric Neurology Unit, V Buzzi Hospital, AO ICP, Milan

<sup>3</sup> Paediatric Neurology Unit and Laboratories, A Meyer Children's Hospital, University of Florence, Florence, Italy

Received June 22, 2011; Accepted May 29, 2012

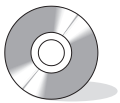**ABSTRACT** – Epilepsy and mental retardation limited to females (EFMR) is a genetic disorder that affects females but spares transmitting males. The condition is caused by protocadherin 19 mutations and is characterised by seizures beginning at around 1 year of age, frequently associated with cognitive regression at seizure onset or later. Seizures can be generalised or focal, exacerbated by febrile illnesses, and grouped in clusters. This report shows the first video-EEG recording of EFMR, in a 7-year-old female presenting peculiar ictal features. [*Published with video sequences*]

**Key words:** epilepsy and mental retardation, EEG, protocadherin 19, ictal fear

Epilepsy and mental retardation limited to females (EFMR) was originally described in a large pedigree from North America, with a peculiar sex-limited expression whereby affected females were related to unaffected carrier males. The authors identified the locus for the disorder in the reported family, mapping to Xq22 (Ryan *et al.*, 1997). Dibbens and colleagues first identified the causative gene encoding protocadherin 19 (*PCDH19*) (Dibbens *et al.*, 2008). EFMR is easily identified in large pedigrees, but is difficult to recognise in smaller pedigrees. EFMR is characterised by

seizures beginning at around 1 year of age and is frequently associated with cognitive regression at seizure onset or later. Patients may have autistic features (Scheffer *et al.*, 2008; Marini *et al.*, 2010). Seizures can be generalised or focal, exacerbated by febrile illnesses, and grouped in clusters. Ictal electroclinical epileptic features, however, have not been extensively reported in the literature.

Here, we describe a patient with EFMR. This is the first video-EEG recording that clearly documents the peculiar ictal features of EFMR, in a 7-year-old female.



**Correspondence:**

Paolo Tinuper  
IRCCS, Institute of Neurological Sciences,  
Department of Neurological Sciences,  
University of Bologna,  
Via Ugo Foscolo 7,  
40123 Bologna, Italy  
<paolo.tinuper@unibo.it>

## Case study

The patient was a left-handed, 7-year-old girl of northern Italian descent. Family history in the father's line (an uncle, an aunt, a female cousin, and two male cousins) showed episodes of febrile seizures until the age of 3 years, and episodes of febrile and afebrile seizures in the mother's line (an aunt) during the first year of life (figure 1).

Pregnancy, delivery, and neonatal course were unremarkable, except for oligohydramnios. Motor development was reported as normal. The patient did not speak until 3 years of age. She subsequently developed a poor vocabulary and currently speaks in two-to-three word sentences with echolalia. Behaviourally, she exhibits anxiety, stereotypes, and perseveration, and has difficulty engaging in social play. She received speech and language therapy and she currently has weekly psychological therapy and attends school with a special education teacher.

Seizures started at the age of 5 months, exhibiting a heterogeneous semiology including tonic-dystonic and clonic seizures, atypical absences, and generalised tonic-clonic seizures. Seizures typically presented in clusters lasting 24 to 36 hours (up to 50 seizures a day), often precipitated by fever.

Since onset, she has had monthly-to-weekly seizure clusters, with long seizure-free periods of 2-3 months, especially after changes in pharmacological treatment. In the past, treatment included phenobarbital, benzodiazepine, sodium valproate, topiramate, carbamazepine (CBZ), vigabatrin, lamotrigine (LTG),

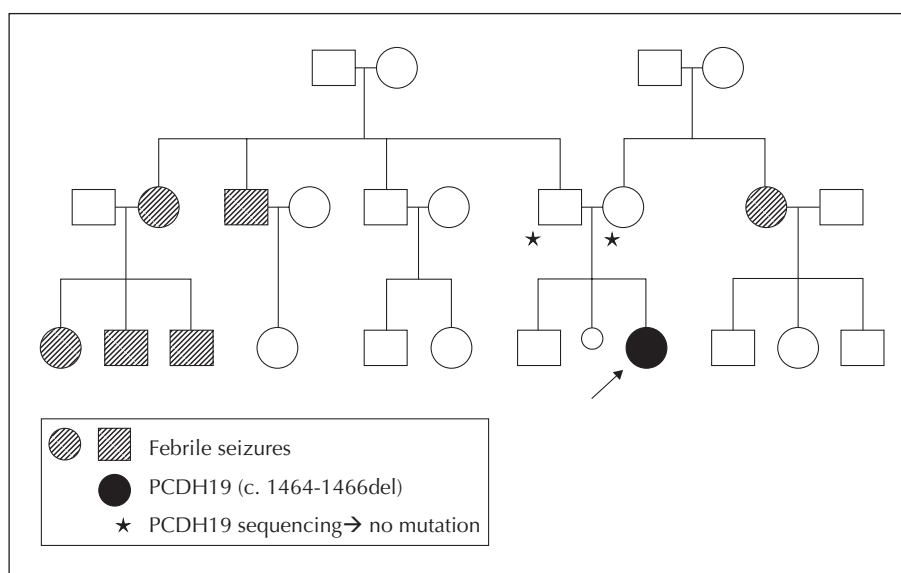
levetiracetam (LEV), and phenytoin, with no improvement in seizure frequency.

At examination, the patient was in the third and tenth percentiles for weight and height. Neurological examination was normal except for diffuse hypotonia. Neuropsychological investigations revealed moderate cognitive impairment (Stanford-Binet III R scale) and the patient was described as inattentive and very impulsive.

At the time of our investigation, clusters of attacks occurred every 2-3 days. By three months, clusters were heralded by a "state of fear" with behavioural features of terror, accompanied by restlessness and screaming. AED polytherapy included: LTG at 0.7 mcg (blood levels, range: 3-15 mcg), LEV at 4.7 mcg (10-40 mcg), and CBZ at 4.7 mcg (5-12 mcg).

The following laboratory tests were normal: dosage of plasma and urinary amino acids, vitamin B12 and folic acid, ceruloplasmin, lactic and pyruvic acid, cerebrospinal fluid, and abdominal echography and echocardiography. Serial brain MR scans were unremarkable. Genetic tests (investigating ring chromosome 20, *SCN1A*, *SCN1B*, and *GABRG2* sequencing, and CGH micro-array) were unrevealing. *PCDH19* sequencing revealed a c.1464\_1466del p.Ser489del (p.S489del) mutation. Mutational analysis for *PCDH19* in both parents was negative.

The day prior to hospital admission, the girl had a cluster of seizures interrupted by rectal diazepam (DZP). The next day, a video-polygraphic recording showed an irregular background activity. A polymorphic slow activity was evident on the fronto-central



**Figure 1.** Family pedigree shows episodes of febrile seizures in the father's line and of febrile and afebrile seizures in the mother's line. The index case reports a *de novo* mutation of the *PCDH19* gene (c.1464\_1466del p.Ser489del -p.S489del- mutation). Mutational analysis for *PCDH19* in both parents was negative.

and fronto-temporal regions of the right hemisphere. In the same regions, focal paroxysmal discharges were present with some diffusion to both hemispheres. There was no photosensitivity. The next day, background activity was less irregular and symmetric on both hemispheres. During the fourth day, the patient woke up in the morning complaining of a feeling of fear that became progressively more intense. Videopolygraphic recording showed fearful behaviour with restlessness and vocalisation of fear and a fearful expression. Psychomotor agitation culminated in recurrent episodes of speech arrest, unresponsiveness, asymmetric dystonic/hypertonic posturing (predominant on either the left or right side in different episodes), lateral turning of the eyes and head (to the right or to the left), and manual automatisms (see *video sequence*). Seizures were always associated with a diffuse erythematous reaction on the face and upper extremities. The seizure cluster began at 7:52 a.m. and was stopped at 8:49 a.m. by rectal administration of 10 mg DZP. The patient presented with six major episodes and other minor episodes characterised only by a few seconds of staring. Each episode lasted from a few seconds to a maximum of two minutes and was separated from the next by a 10-second to 20-minute interval. After each episode, the patient seemed confused, but soon after she became agitated with the re-emergence of the feeling of fear, progressively increasing with time. Ictal EEG disclosed bilateral discharges (polyspikes and spike-waves) that appeared to arise from the temporo-parietal or centro-temporal regions of the left hemisphere. Interictal EEGs showed multifocal epileptiform abnormalities with slower activity on the left hemisphere. While the state of fear progressively increased, EEG showed multifocal discharges predominantly on the temporal regions that then translated into more rhythmic and bilateral paroxysmal discharges at the onset of the motor event (*figures 2 and 3*). Two minutes after DZP administration, the patient appeared quieter. EEG showed an asymmetric activity, slower on the left hemisphere with some brief more rapid discharges on the right hemisphere.

## Discussion

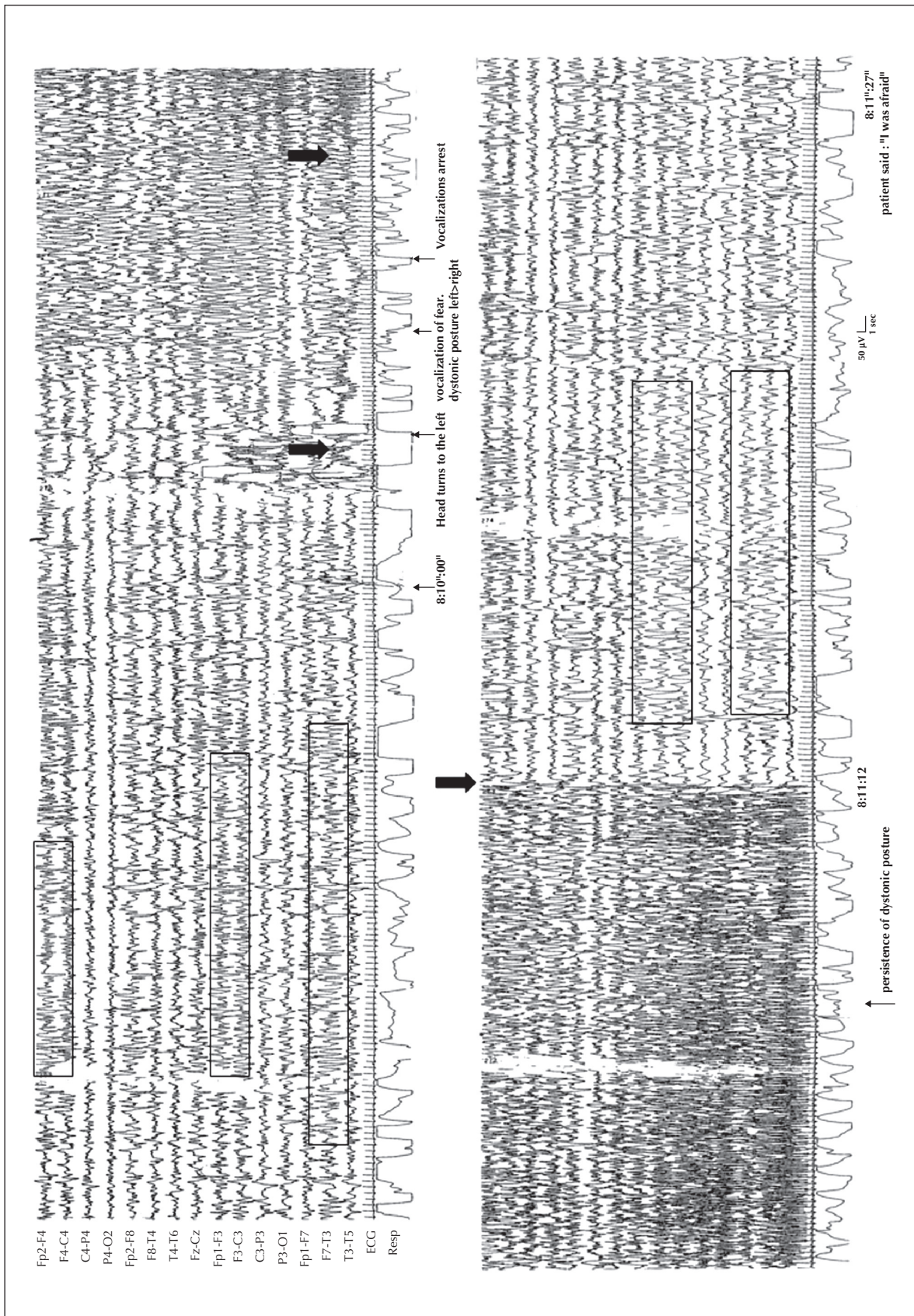
EFMR is a disorder with an X-linked mode of inheritance that spares transmitting males and affects only females. The causative role of *PCDH19* gene mutations in EFMR was first reported in 2008 (Dibbens *et al.*, 2008). *PCDH19* is expressed in developing brains of humans and mice and was the first member of the cadherin superfamily to be directly implicated in epilepsy or mental retardation. Our report describes ictal semio-

logy in a patient with EFMR with a *de novo* mutation of *PCDH19* gene and highlights the opportunity of screening *PCDH19* mutations in cases of early-onset epilepsy with mental retardation, even in the absence of a characteristic pedigree. The semiological characteristics of epilepsy in EFMR are seldom reported in detail in the literature. Seizures may be focal, multifocal or generalised (including tonic-clonic, absence, myoclonic, tonic, and atonic seizures). The phenotypic spectrum of *PCDH19* mutations also includes Dravet syndrome-like epileptic encephalopathy (Depienne *et al.*, 2009; Marini *et al.*, 2010). Typically, seizures present in clusters (monthly to yearly), often triggered by fever. At onset, clusters are more frequent and sometimes evolve into status epilepticus and cognitive impairment worsens, while over time seizure frequency decreases with a plateau in cognitive regression. Treatment does not seem to prevent the recurrence of clusters.

Seizure semiology in our patient disclosed two main patterns. The first was mainly characterised by subjective symptoms, particularly a feeling of fear and anxiety that gradually increased and behaviour expressed as terror (vocalisations, fearful expression, and motor agitation). The subsequent period was dominated by arrest of vocalisation and unresponsiveness and motor events mainly with dystonic features. Previous reports on seizure semiology and EEG show heterogeneous features but the few detailed studies typically show focal ictal discharges involving mainly the temporal or frontal regions (Depienne *et al.*, 2011; Specchio *et al.*, 2011). Fear, as a main affective ictal symptom, has been sporadically reported in patients with EFMR (Depienne *et al.*, 2011; Specchio *et al.*, 2011). However, this report provides the first detailed documentation of ictal semiology and EEG features in a patient with EFMR. We believe that in some patients with *PCDH19* mutations, seizures can have suggestive phenomenology with peculiar "ictal" symptoms such as an affective sensation of fear often gathered in prolonged sequences, that, if confirmed in further studies, may be a marker to search for *PCDH19* mutations in a female with early-onset epilepsy and mental deterioration.

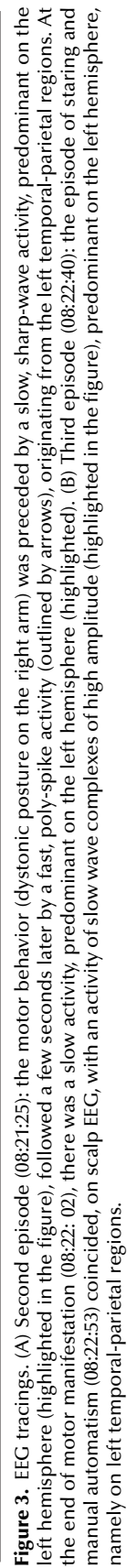
Since Hughlings Jackson's first description, fear has been recognised as an affective state that can occur during seizures and is usually associated with involvement of the amygdala (Gloor *et al.*, 1982). Moreover, anxiety and fear are the most common affective symptoms in temporal lobe epilepsy (Biraben *et al.*, 2001). In our patient, the intense emotional behaviour with facial expressions suggestive of anger and terror, screaming, and motor agitation was probably related to the involvement of neural networks implicated in fear: the amygdala, temporal pole, prefrontal orbital, and opercular regions.





**Figure 2.** EEC tracing. First episode (08:09:55): the fearful behaviour corresponded, on scalp EEG, to a pattern of single, rapid spikes followed by sharp waves, predominant on the left fronto-temporal and right frontal regions (highlighted in the figure). The motor behaviour (08:10:07) coincided with the onset of a diffuse paroxysmal activity (outlined by arrows) with high-voltage spikes that appeared to originate from the left temporal-parietal-occipital regions and that abruptly ceased (outlined by arrow at 08:11:12), followed by a slow activity, predominant on the left hemisphere (highlighted).





*Non-clustered protocadherins (PCDHs)* are calcium-dependent adhesion molecules implicated in neuronal circuit formation during brain development with circuit-dependent expression patterns in thalamocortical connections (Kim *et al.*, 2007). In particular, the expression of *PCDH19* showed temporal preferences and exhibited region-specific expression patterns in the areas connected to hippocampal formation (Kim *et al.*, 2010). This led to the hypothesis that *PCDHs* are involved in the maintenance and plasticity of adult hippocampal circuitry.

Interestingly, previous studies report that cognitive prognosis does not seem completely related to the severity of epilepsy and a causative role of *PCDH19* loss of function in cognitive decline was postulated (Depienne *et al.*, 2011).

In this setting, the occurrence of mental retardation and peculiar “ictal” behaviour resembling the typical expression of temporo-limbic involvement is not surprising, but further evidence is needed to support this hypothesis. □

#### Acknowledgements.

We thank E. Zoni for figures and video editing as well as our EEG technicians.

#### Disclosures.

The authors have no conflicts of interest to declare.

#### References

- Biraben A, Taussig D, Thomas P, *et al.* Fear as the main feature of epileptic seizures. *J Neurol Neurosurg Psychiatry* 2001; 70: 186-91.
- Depienne C, Bouteiller D, Karen B, *et al.* Sporadic infantile epileptic encephalopathy caused by mutations in *PCDH19* resembles Dravet syndrome but mainly affects females. *PLoS Genet* 2009; 5: e10000381.
- Depienne C, Trouillard O, Bouteiller D, *et al.* Mutations and deletions in *PCDH19* account for various familial or isolated epilepsies in females. *Hum Mutat* 2011; 32: e1959-75.
- Dibbens LM, Tarpey PS, Hynes K, *et al.* X-linked protocadherin 19 mutations cause female-limited epilepsy and cognitive impairment. *Nat Genet* 2008; 40: 776-81.
- Gloor P, Olivier A, Quesney LF, *et al.* The role of the limbic system in experiential phenomena of temporal lobe epilepsy. *Ann Neurol* 1982; 12: 129-44.
- Kim SY, Chung HS, Sun W, Kim H. Spatiotemporal expression pattern of non-clustered protocadherin family members in the developing rat brain. *Neuroscience* 2007; 147: 996-1021.
- Kim SY, Mo JW, Han S, *et al.* The expression of non-clustered protocadherins in adult rat hippocampal formation

and the connecting brain regions. *Neuroscience* 2010; 170: 189-99.

Marini C, Mei D, Parmeggiani L, *et al.* Protocadherin 19 mutations in girls with infantile-onset epilepsy. *Neurology* 2010; 75: 646-53.

Ryan SG, Chance PF, Zou CH, *et al.* Epilepsy and mental retardation limited to females: an X-linked dominant disorder with male sparing. *Nat Genet* 1997; 17: 92-5.

Scheffer JE, Turner SJ, Dibbens LM, *et al.* Epilepsy and mental retardation limited to females: an under-recognized disorder. *Brain* 2008; 131: 918-27.

Specchio N, Marini C, Terracciano A, *et al.* Spectrum of phenotypes in female patients with epilepsy due to protocadherin 19 mutations. *Epilepsia* 2011; 52: 1251-7.

#### Legend for videosequence

(Fz-Cz, Left: Fp1-F3, F3-C3, C3-P3, P3-O1, Fp1-F7, F7-T2, T3-T5, ECG)

**First episode (08:09:55).** The patient had a fearful expression with psychomotor agitation and vocalisations of fear. At 08:10:03, the patient said “I am afraid”, then (08:10:07) she suddenly looked to her right as if there was something frightening and then rapidly turned her head to the left, assuming an asymmetric dystonic posture (predominantly on the left side) with other vocalisations of fear and repetitive movements with the fingers of the left hand. When vocalisations stopped (08:10:22), the asymmetric dystonic posture persisted for a few seconds. The episode stopped (08:11:12) and the patient appeared prostrated and confused.

**Second episode (08:21:25).** At 08:19, the patient had already become agitated and she repeatedly said she was afraid (not shown). The psychomotor agitations progressively increased with restlessness and vocalisations of fear, then (08:21:29) she slowly assumed a dystonic posture with the right arm, followed by speech arrest and slow right oculocephalic version. After a few seconds, the dystonic posture stopped (08:22:02) and the girl appeared confused and soon after agitated.

**Third episode (08:22:40).** The patient said repeatedly “it’s here” (an expression that she usually used to indicate the sensation of fear). A few seconds later (08:22:53), there was an episode of staring with manual automatism of the left hand. At 08:23:05, the episode stopped and the patient appeared agitated.

**Key words for video research on**  
**[www.epilepticdisorders.com](http://www.epilepticdisorders.com)**

*Syndrome:* epilepsy not classified  
*Etiology:* genetic disorder  
*Phenomenology:* fear; automatisms  
*Localization:* not applicable