

# Generalised electrographic seizures presenting as perioral myoclonia

Jennifer L Dearborn, Peter W Kaplan

Johns Hopkins Hospital Bayview Medical Center, Baltimore, MD, USA

Received June 13, 2013; Accepted December 04, 2013

**ABSTRACT** – A 41-year-old man, during a neurological consultation, reported “chin twitching” over a period of a week, which was diagnosed as intermittent perioral myoclonia. With only one tonic-clonic seizure seven years before, he had mentioned several episodes of chin twitching over the years. In the clinic, there were intermittent chin movements without apparent confusion, as he was able to provide a complete history and was fully oriented with intact memory. His video-EEG showed paroxysms of polyspike and slow-wave activity, with the longest burst-free interval being 20 seconds. Discharges were maximal over the fronto-central regions, correlating with the chin myoclonus. He was able to tap his hand continuously, and remained alert. The case represents an atypical presentation of idiopathic generalised epilepsy without manifestation of absence or limb myoclonus. Although juvenile myoclonic epilepsy and other idiopathic epilepsies are rarely associated with perioral myoclonia, this sign was the principal clinical feature for this patient. Oral treatment with levetiracetam resolved his seizures. [Published with video sequences]

**Key words:** idiopathic generalized epilepsy, adult myoclonic epilepsy, epilepsy, seizure, juvenile myoclonic epilepsy

Idiopathic generalised epilepsies (IGE) are usually diagnosed in childhood or adolescence, when there are absence, myoclonic or tonic-clonic seizures (Nordli, 2005). Less frequently, patients present in early adulthood or later, often with similar EEG features (Gilliam *et al.*, 2000). The International League Against Epilepsy (ILAE) recognises three major types of epilepsy with absences: absence epilepsy (AE), juvenile myoclonic epilepsy with absences (JME), and myoclonic absence epilepsy (MAE). The demographics of such cases (AE in childhood and JME in teen years) and

clinical presentation (prominent absences in AE, myoclonic jerks upon awakening in JME, and myoclonus during absences in MAE) serve as distinguishing features for diagnosis (Panayiotopoulos *et al.*, 1989). A rare syndrome of perioral myoclonia with absences (POMA) was described by Panayiotopoulos *et al.* as a distinct type of IGE, and is not yet recognised by the ILAE (Panayiotopoulos *et al.*, 1994). We review the case of a 41-year-old man who presented with primary semiology of perioral myoclonus. A diagnosis of POMA was made in the clinic based on video-EEG correlation.



**Correspondence:**

Peter W Kaplan  
The Johns Hopkins Hospital,  
Department of Neurology,  
Bayview Medical Center,  
4940 Eastern Avenue,  
Baltimore, MD 21224, USA  
<pkaplan@jhmi.edu>

doi:10.1684/epd.2014.0625

## Case report

A 41-year-old man, during a neurological consultation, reported a major complaint of chin twitching. He had been previously followed for a diagnosis of epilepsy. During this visit, he noted chin twitching that was rhythmic and intermittent, which had started a week ago. He had no other concerns and felt that his ability to think and perform his daily routine was unimpaired. There was no clear precipitant, such as illness or new medications. Concerned about the twitching, he had self-administered valproate (1,000 to 2,000 mg per day) of which he had extra at home. This did not decrease the frequency of the twitching, and so he presented to the emergency room the day prior to his consultation. Perplexed, he was assumed to have simple partial status and the physician referred him for outpatient follow-up. He drove himself to the appointment on the day of presentation.

Seven years previously, he presented with his first seizure and he required hospitalisation, which brought him to the attention of a neurologist. During that episode, co-workers first noticed twitching of the right side of the face and he had difficulty in answering questions. Although he reported understanding what they were saying, he had difficulty replying. Later that day, he had a tonic-clonic seizure and was taken to a hospital, and was subsequently discharged without medication. Later that year, he was admitted with chin twitching, followed by confusion and "passing out", with a presumed diagnosis of complex partial seizures with secondary generalisation. His EEG was reported to show diffuse slowing, and his brain MRI was normal. He was given valproate to prevent further seizures. He reported no childhood seizures or descriptions of absence or limb myoclonus prior to his seizure seven years ago.

On a follow-up visit two years ago, he described intermittent unilateral chin twitching without impairment of consciousness, which occurred at irregular intervals during the previous several years. As the episodes were not witnessed, it was felt that they likely represented simple partial seizures, as EEG recordings were normal between episodes. He was continued on daily valproate, which he would only take during the episodes that lasted for several days. He had been free of the twitching until two months previously when he had had another episode, which responded on the first day to oral valproate. Otherwise, his past medical history was unremarkable. He reported no episodes of seizures, myoclonus or chin twitching in any family members. During the recent consultation for chin twitching, he was treated with an oral load of levetiracetam which, together with the valproate, resolved the twitching by the next day.

On examination, he was quiet, with barely perceptible delays in questions and commands. Every few seconds or so, he would have a burst of chin twitching. There was involvement primarily of the depressor *anguli oris* and *orbicularis oris*. Two or three times during the interview, he paused with a momentary delay in speech or behaviour during the chin movements, however, apart from this, his speech was fluent and there were no obvious clinical signs other than the twitching. This chin twitching occurred throughout the one-hour clinic visit. He did not drop objects, or show myoclonus of the outstretched arms, and he was unaware of the minor pauses in his behaviour. The interval between bursts of chin twitching was about 10 to 20 seconds. A video of his physical examination is shown and this demonstrates the extent of the physical findings during the examination (see *video sequence*).

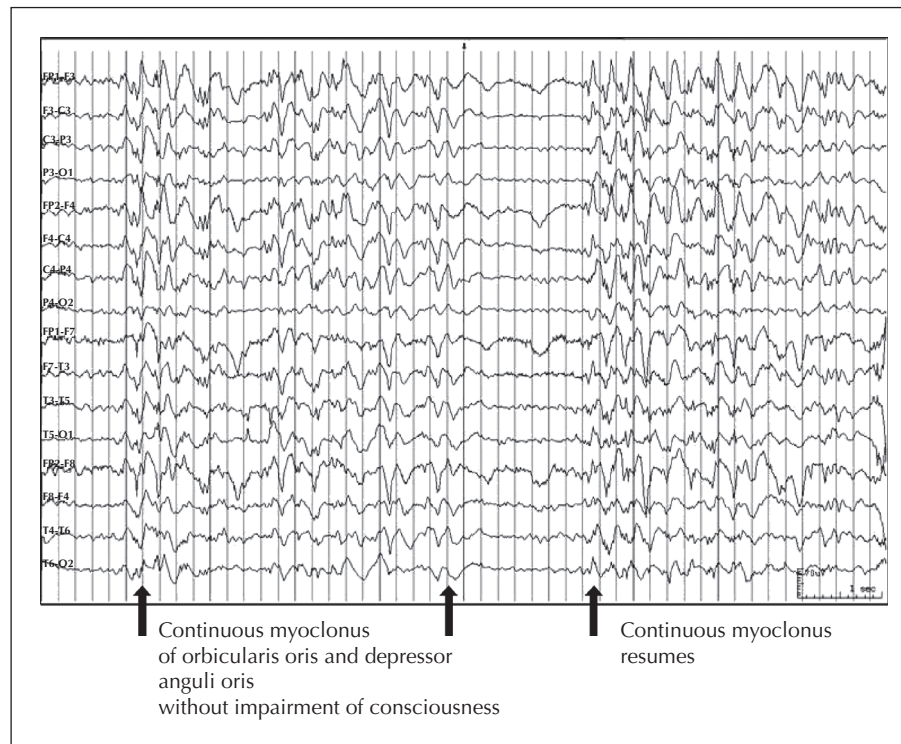
## Electrophysiology

The video-EEG showed frequent bursts, occurring every few seconds, of polymorphic polyspike-slow-wave activity, with bursts of polyspikes lasting up to 500 milliseconds over the fronto-central regions, followed by spike waves at 4 Hz (*figure 1*). The bursts lasted from just under a second to close to four seconds, with the longest burst-free interval being about 20 seconds. These bursts correlated to the patient's chin movements, without other myoclonic movements of the face or outstretched arms, and the EEG was normal in between the chin movements. His brain MRI was unremarkable.

## Discussion

This case represents a rare diagnosis of perioral myoclonus with absences (POMA) and demonstrates the common pitfalls in diagnosis. The patient presented with perioral myoclonus with minimal impairment of sensorium, with ongoing generalised EEG epileptiform activity. He had been under occasional neurological review for seven years without diagnosis. IGE was diagnosed when chin movements were observed to correlate with video-EEG seizure activity. Reasons for the delay in diagnosis included the inability to previously record his chin movements with EEG correlation as well as the common misclassification of IGEs as simple or complex partial seizures, based on a presumption of unilateral motor activity with no or minimal impairment of awareness.

POMA, as first described in six patients, is distinct from other IGEs because of the prominent feature of



**Figure 1.** EEG showing runs of generalised spike-wave and polyspike-slow-wave discharges at 3-4 Hz, that, at times, exceed four seconds.

There is no discernible “bedside” clinical correlate other than the observed perioral myoclonus, involving the orbicularis oris and depressor anguli oris with some masseter involvement. Between the runs of spike and wave discharges, the myoclonus resolved.

perioral myoclonus during absences (Panayiotopoulos *et al.*, 1994) and consists of rhythmic contractions of: *orbicularis oris* causing protrusion of the lips, *depressor anguli oris* causing the corners of the mouth to depress, and occasionally the masseter muscles and other muscles of mastication (Panayiotopoulos, 2005). Several case reports have described this disorder in children (Clemens, 1997; Bilgic *et al.*, 2001), in addition to a report of POMA in a 31-year-old man (Baykan and Noachtar, 2005). This syndrome is described with near-normal cognition during absences, poor response to treatment, and predominance of absence status epilepticus early in the disease process. Patients frequently have generalised tonic-clonic status epilepticus at some point in the disease process. Unlike our patient, cases of POMA tend to be girls presenting between the ages of 2 and 13 (Panayiotopoulos, 2005). An adult form of myoclonic epilepsy has been described, but it is not clear whether it is the same as juvenile myoclonic epilepsy (JME), the most common form of myoclonic epilepsy, or a distinct entity (Gilliam *et al.*, 2000). Cases of myoclonic epilepsy are increasingly diagnosed in adulthood. In one study, 43 cases of JME were diagnosed after age 18 in a cohort of 443 patients with IGE (Asadi-Pooya *et al.*, 2012), but

none had chin movements. Our patient had no history of seizures or myoclonus in childhood, which is unlike the prior case report of POMA in an adult, who had seizures since his youth (Baykan and Noachtar, 2005). It is therefore difficult to say whether our patient represents a later phenotypic presentation of the same disease as the childhood forms, or a genetically distinct form based on his later age at onset (Hempelmann *et al.*, 2006).

An important differential diagnosis for POMA is MAE. In MAE, myoclonus during absence is usually unmistakable given the jerking usually present in the limbs, however, a minority of cases include facial myoclonus which could be confused with POMA. Compared to POMA, the absences tend to be more profound, ranging from complete interruption in behaviour to partial interruption (Bureau and Tassinari, 2005). Rarely, AE can also present with perioral myoclonus, however, our patient had minimal impairment of vigilance (Shorvon and Walker, 2005).

Patients may provide a history of lateralised movements with confusion that is suggestive of complex partial seizures, however, our case clearly demonstrated generalised EEG epileptic activity with minimal impairment. Although myoclonus is usually bilateral, it

can be unilateral, which makes it possible to confuse IGE with epilepsy of partial onset (Ferrie, 2005). Our patient was relatively cognitively intact, with only minimal ideamotor slowing and extremely brief delay in response to questioning. This was concerning because he was unaware of his deficits, and had been driving throughout the previous week. It was questioned at the visit whether he should drive home. We chose to call a family member for pick-up.

This case highlights a presentation in adulthood of a rare type of IGE, POMA, which is more frequently found in children. Often an over-looked diagnosis, POMA should be considered in the differential diagnosis of patients who present with any form of facial movements and a history of convulsive seizures. □

#### Acknowledgments and disclosures.

We would like to acknowledge Ms. Sylvia Parham for her continued presence and dedication to the EEG service. This work has not been supported by a grant or any other funds.

Peter Kaplan added the following information: Qatar National Research Foundation: ICU EEG monitoring for status epileptics; Honoraria for national conferences and grand rounds; travel for conferences; royalties for books on EEG and epilepsy; medico-legal testimony.

This work has not been presented at a meeting or conference.

The authors have no conflicts of interests to disclose.

#### Legends for video sequences

Perioral myoclonus, arms extended. The patient is seen with perioral myoclonus. He is able to maintain his arms extended with minimal interruption. He is then able to tap his hand without interruption.

**Key words for video research on**  
**[www.epilepticdisorders.com](http://www.epilepticdisorders.com)**

*Syndrome:* perioral myoclonia with absences

*Etiology:* idiopathic

*Phenomenology:* myoclonic seizure; absence (dialeptic) seizure

*Localization:* not applicable

#### References

- Asadi-Pooya AA, Emami M, Sperling MR. Age of onset in idiopathic (genetic) generalized epilepsies: clinical and EEG findings in various age groups. *Seizure* 2012; 21: 417-21.
- Baykan B, Noachtar S. Perioral myoclonia with absences: an overlooked and misdiagnosed generalized seizure type. *Epilepsy & Behav* 2005; 6: 460-2.
- Bilgic B, Baykan B, Gurses C, Gokyigit A. Perioral myoclonia with absence seizures: a rare epileptic syndrome. *Epileptic Disord* 2001; 3: 23-7.
- Bureau M, Tassinari CA. Epilepsy with myoclonic absences. *Brain Dev* 2005; 27: 178-84.
- Clemens B. Perioral myoclonia with absences? A case report with EEG and voltage mapping analysis. *Brain Dev* 1997; 19: 353-8.
- Ferrie CD. Idiopathic generalized epilepsies imitating focal epilepsies. *Epilepsia* 2005; 46: 91-5.
- Gilliam F, Steinhoff BJ, Bittermann HJ, Kuzniecky R, Faught E, Abou-Khalil B. Adult myoclonic epilepsy: a distinct syndrome of idiopathic generalized epilepsy. *Neurology* 2000; 55: 1030-3.
- Hempelmann A, Taylor KP, Heils A, et al. Exploration of the genetic architecture of idiopathic generalized epilepsies. *Epilepsia* 2006; 47: 1682-90.
- Nordli Jr. DR. Idiopathic generalized epilepsies recognized by the International League Against Epilepsy. *Epilepsia* 2005; 46 (Suppl 9): 48-56.
- Panayiotopoulos CP, Obeid T, Waheed G. Differentiation of typical absence seizures in epileptic syndromes. A video EEG study of 224 seizures in 20 patients. *Brain* 1989; 112(Pt 4): 1039-56.
- Panayiotopoulos CP, Ferrie CD, Giannakodimos SE, Robinson RO. Perioral myoclonia with absences: a new syndrome. In: Wolf P, ed. *Epileptic seizures and syndromes*. London: John Libbey, 1994: 143-53.
- Panayiotopoulos CP. Syndromes of idiopathic generalized epilepsies not recognized by the International League Against Epilepsy. *Epilepsia* 2005; 46: 57-66.
- Shorvon S, Walker M. Status epilepticus in idiopathic generalized epilepsy. *Epilepsia* 2005; 46 (Suppl 9): 73-9.