

From hypothalamic hamartoma to cortex: what can be learnt from depth recordings and stimulation?

Philippe Kahane¹, Philippe Ryvlin², Dominique Hoffmann³, Lorella Minotti¹, and Alim Louis Benabid³

1. Neurophysiopathologie de l'Epilepsie, CHU de Grenoble (France)

2. Neurologie fonctionnelle et Epileptologie & CERMEP, CHU de Lyon (France)

3. Neurochirurgie & INSERM U318, CHU de Grenoble (France)

ABSTRACT – Patients having a hypothalamic hamartoma (HH) frequently present gelastic or dacrystic seizures, and they often later experience multiple additional seizure types which lead to a severe epileptic encephalopathy. There is now increasing evidence that the HH itself plays a crucial role in this syndrome, but the relationships between the lesion and the different types of seizures remain a questionable issue.

Stereotactic intracerebral EEG recordings were performed in 5 patients suffering from a medically intractable epilepsy associated with a HH. The hamartoma was investigated in all cases, and various cortical areas were also evaluated in 4 of the 5 patients. The epileptic discharges arose and remained confined within the hamartoma in 3 of the 4 patients in whom laughing and crying episodes were recorded. In addition, interictal spikes were recorded from the hamartoma in 4 of the 5 patients, whereas the stimulation of the HH could reproduce gelastic or dacrystic episodes in 3.

The three patients in whom other types of seizure were recorded showed that the latter were associated with cortical ictal discharges not affecting the HH. Ictal onset appeared either bifrontal, right fronto-central and lateral temporal, or bifrontal with a right side predominance. The cingulate gyrus was involved in all these 3 cases, and the lateralization of the ictal discharges was always ipsilateral to the predominating side of the hamartoma. Interestingly, these seizure types were sometimes immediately preceded by the laughing or crying attacks, as if ictal discharges within the hamartoma triggered those which seemed to originate in the cortex.

Therefore, if these findings confirm the intrinsic epileptogenicity of HH, they also demonstrate that epileptic seizures associated with HH can exhibit different types of electroclinical patterns. We propose a speculative pathophysiology in which the mamillo-thalamo-cingulate tract would serve as a relay of HH discharges towards the cortex, the excitability of which would then progressively increase, first leading to cortical interictal epileptiform abnormalities and then to seizures of cortical origin. Whether this proposal of secondary epileptogenesis is valid or not remains a major issue, since it could provide arguments on the moment to discuss surgery.

KEY WORDS: hypothalamic hamartoma, cortex

Correspondence:

Philippe Kahane
Neurophysiopathologie de l'Epilepsie
Département de Neurologie –
CHU de Grenoble
BP217X – 38043 Grenoble cedex (France)
Tel: (+ 33) 4 76 76 54 48
Fax: (+ 33) 4 76 76 56 31
E-mail: philippe.kahane@chu-grenoble.fr

Presented at the International Symposium on Hypothalamic Hamartoma and Epilepsy, Montreal Neurological Institute, Montreal, Canada, November 29th 2001.

In patients suffering from the epileptic syndrome associated with hypothalamic hamartoma (HH) [1], there is now strong evidence that resection or disconnection of HH, as well as radiofrequency thermocoagulation or gamma knife radiosurgery, may lead to complete seizure control, and to improvement of behavioural disturbances [2-14]. Thanks to neurosurgical advances, these therapeutic options are now associated with limited morbidity which, together with recent electrophysiological and functional neuroimaging findings, make surgical treatment a reasonable choice when compared with the relatively severe evolution of medically-treated HH associated epilepsy [1, 15].

A few years ago, however, the pathophysiology of this puzzling syndrome was poorly understood. Though some authors had discussed the possible role of the hamartoma in generating gelastic – or more rarely dacrystic – seizures [16], evidence was lacking. In fact, the electro-clinical presentation of the syndrome corresponded to that of a symptomatic generalised epileptic encephalopathy in many patients, with multiple seizure types, diffuse interictal scalp-EEG epileptiform abnormalities, progressive intellectual decline, frequent behavioural problems, and poor response to antiepileptic drugs [1, 15]. The relation between these diffuse abnormalities and the hypothalamic lesion remained elusive, in as much as isolated laughing (or crying) attacks, the hallmark feature of the syndrome, were not associated with any convincing concurrent scalp-EEG changes. In other patients, surface and intracranial EEG data suggested a temporal or a frontal lobe ictal onset, but resections of these regions consistently failed at reducing seizure frequency, while corpus callosum section only seemed to reduce the number of drop attacks in some patients [17].

At the beginning of the 90', stereotactic intracerebral EEG (SEEG) recordings showed for the first time that gelastic seizures [18] as well as dacrystic attacks [19] correlated with ictal discharges confined to the hamartoma. SEEG recordings and stimulations in a few additional patients have confirmed this intrinsic HH epileptogenicity [5, 20], which was subsequently corroborated by ictal SPECT findings [5, 11, 21, 22] and magnetic resonance spectroscopy data [23]. However, Munari and coworkers emphasized that the other associated seizure types (i.e. without laughing or crying component) did not arise from the hypothalamic mass but originated in various cortical areas, thus suggesting that these seizures might result from secondary epileptogenesis [18-20].

To date, five patients suffering from drug-resistant seizures associated with a hypothalamic hamartoma have underwent a SEEG study at our institution. Some of these observations have been published elsewhere [18, 20, 24, 25], and we report here the main electro-clinical features of all five cases, focusing our attention on the relationships between the different seizure types, the hamartoma, and the cortex.

Patients and methods

Population studied

All pertinent clinical data are presented in *Tables 1 and 2*. The five patients, one of whom had a Pallister-Hall syndrome, were suffering from a childhood onset long-lasting medically intractable epilepsy. All patients experienced gelastic and/or dacrystic attacks, whereas four of them also presented other seizure types.

MRI showed an intra-hypothalamic mass in all cases (see *figures 3 and 10*), the characteristics of which corresponded to those described as 'type IIb' by Valdueza *et al.* [4]. The hamartoma was predominantly lateralized to the right side in three patients, to the left side in one, and non-lateralized in the remaining patient.

Interictal scalp-EEG recordings showed diffuse abnormalities in most patients (*figure 1*). Interestingly, these abnormalities predominated on the side ipsilateral to the hamartoma in the four patients where the latter clearly showed a side predominance. Ictal scalp-EEG proved inconclusive during gelastic and/or dacrystic seizures which were recorded in all but one patient (*figure 2A*). Conversely, asymmetric bilateral EEG changes were observed at ictal onset during the other seizure types also recorded in four of the five patients (*figure 2B*). As for interictal EEG abnormalities, the lateralization of ictal discharge were ipsilateral to the predominating side of HH.

SEEG procedure

Intracerebral EEG recordings were performed in the first four patients with the aim to provide a three-dimensional assessment of the epileptogenic network, and to precisely define the relationships between the latter and the hamartoma. Thus, the stereotactic placement of the intracerebral electrodes, as well as their total number ($n = 11$ to 13), varied from one patient to another one depending on the suspected origin and areas of early seizure spread, but always targeted the HH (*figure 3*). Electrodes were 0.8 mm in diameter and included 5, 10, or 15 leads 2 mm in length, 1.5 mm apart (Dixi, Besançon, France), depending on the intra-cerebral target. Such multileads electrodes allow to investigate all the structures crossed along their trajectory, including the mesial and lateral aspects of the different lobes, but also fissural cortices, as well as the hamartoma.

In the fifth patient ($n^{\circ} 5$), intracerebral EEG recordings were conducted as part of a therapeutic procedure aiming at chronically stimulate the HH. The rationale of this therapeutic approach was based on our previous findings regarding the intrinsic epileptogenicity of hypothalamic hamartoma, on the potential benefit of chronic high frequency stimulation of the epileptogenic zone as suggested by the Velasco's group in temporal lobe epilepsy patients, on the safety of deep brain stimulation in patients with movement disorders, and on the possible reversibility of

Table 1. General characteristics.

Pts (sex)	Age at SEEG	G/D szrs (onset)	Other szrs (onset)	Seizure frequency	PP (onset)	Clinical exam	Cognitive decline	AEDs at SEEG
1 (F)	16 yrs	G (30 mths)	+ (14 yrs)	> 5/day	–	small height	moderate	CBZ-GVG-CLB
2 (F)	19 yrs	D + / – G (10 yrs)	+ (5 yrs)	> 1/day	+ (5 yrs)	obesity	moderate	CBZ-PHT-CLB
3 (M)	27 yrs	G- > D (2 yrs)	+ (5 mths)	1-5/day	–	normal	mild	CBZ-PHT-GVG-PB-CLB
4 (M)	12 yrs	G (< 1 yr)		> 5/day	–	normal	mild	CBZ
5 (F)	30 yrs	G (infancy)	+ (13 yrs)	30/mth	–	polydactyly	none	CBZ-CLB

Pts: patients; F / M = female / male; G / D szrs = gelastic / dacrystic seizures; PP: precocious puberty; AEDs: antiepileptic drugs; yr(s): year(s); mth(s): month(s); SEEG: stereotactic intracerebral EEG; CBZ: carbamazepine; GVG: vigabatrin; CLB: clobazam; PHT: phenytoine; PB: phenobarbital.

the procedure. The hamartoma was investigated using three 4-leads deep-brain stimulation electrodes (Medtronic DBS lead 3389, four contacts 1.27 mm in diameter, 1.5 mm long, space by 0.5 mm) in order to sample the entire hypothalamic lesion (see *figure 10*). In this patient, intra-cortical EEG recordings were not per-

formed, but scalp-EEG was recorded together with HH in order to provide information on the cortical EEG activity.

Intracerebral recordings and stimulation

In all patients, concurrent video and intracerebral EEG were monitored for 7 to 23 days (Biomedical Monitoring

Table 2. Video-EEG monitoring.

Pts	Interictal findings	Gelastic/dacrystic seizures		Other types of seizures	
		EEG	semiology	EEG	Semiology
1	bursts of diffuse PSp and long-lasting sequences of bilat Sp & SpW	diffuse flattening	smiling and/or laughing	biF low-voltage fast activity	backward fall, contraction of the mouth corners, R eyes deviation, R arm hypertonia \pm R or L head turning
2	bursts of diffuse PSp and R F-C PSp	delayed R F SW	crying \pm preceded by an epigastric sensation	bilat (R > L) high-voltage fast activity R F-C-T low-voltage fast activity	Staring, eyes blinking, flushing, swallowing \pm preceded by a thoracic warm, auditory illusions, dizziness and pain in the L leg same as above, followed by bradycardia, R eyes deviation, L facial contraction, bilat (L > R) hypertonia, moaning, fall
3	bursts of diffuse PSp	R anterior flattening	laughing leading to crying \pm preceded by an epigastric sensation	bilat (R > L) high-voltage fast activity	sudden fall \pm preceded by R oculocephalic deviation; possible secondary tonic-clonic generalisation
4	L hemispheric multifocal SW & Sp	L T-F-C-P theta activity	indefinable aura, flushing, laughing, gesticulating, R arm dystonia \pm R body rotation; possible R hemibody hypertonia	–	–
5	R T-P SW & Sp	not recorded	cephalic sensation or pressure to laugh \pm laughing, rarely 'déjà-vécu' at onset	biT(-P) flattening (R > L)	eyes blinking, swallowing, gestural automatisms, L oculocephalic deviation

Pts: patients; PSp: polyspikes; Sp: spikes; SpW: spike-and-waves; SW: slow waves; R: right; L: left; bi/bilat: bilateral; T: temporal; F: frontal; C: central; P: parietal.

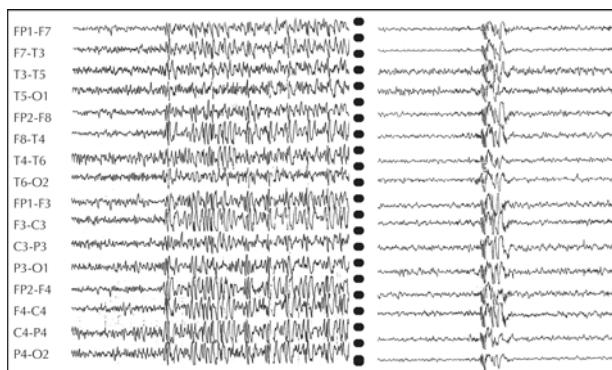


Figure 1. Interictal scalp EEG findings. Coexistence, in the same patient (n° 1), of long lasting sequences of widely extended spikes (left side) and short bursts of diffuse polyspikes (right side).

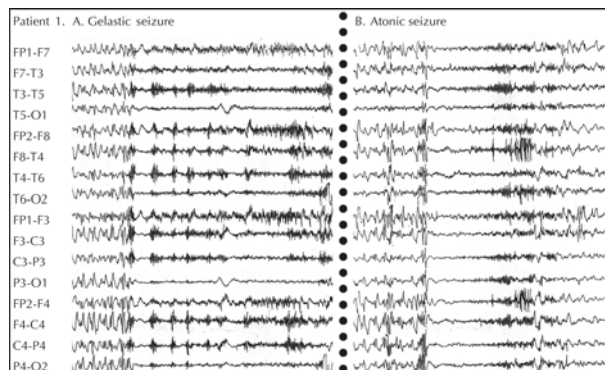


Figure 2. Ictal scalp EEG findings. Same patient as in figure 1. Recording of two different types of seizures, the ictal scalp EEG patterns of which are clearly different. Gelastic seizures manifest with a diffuse flattening of the trace (A), while a widespread (but possibly anterior right predominant) low voltage fast activity occurs during atonic seizures (B).

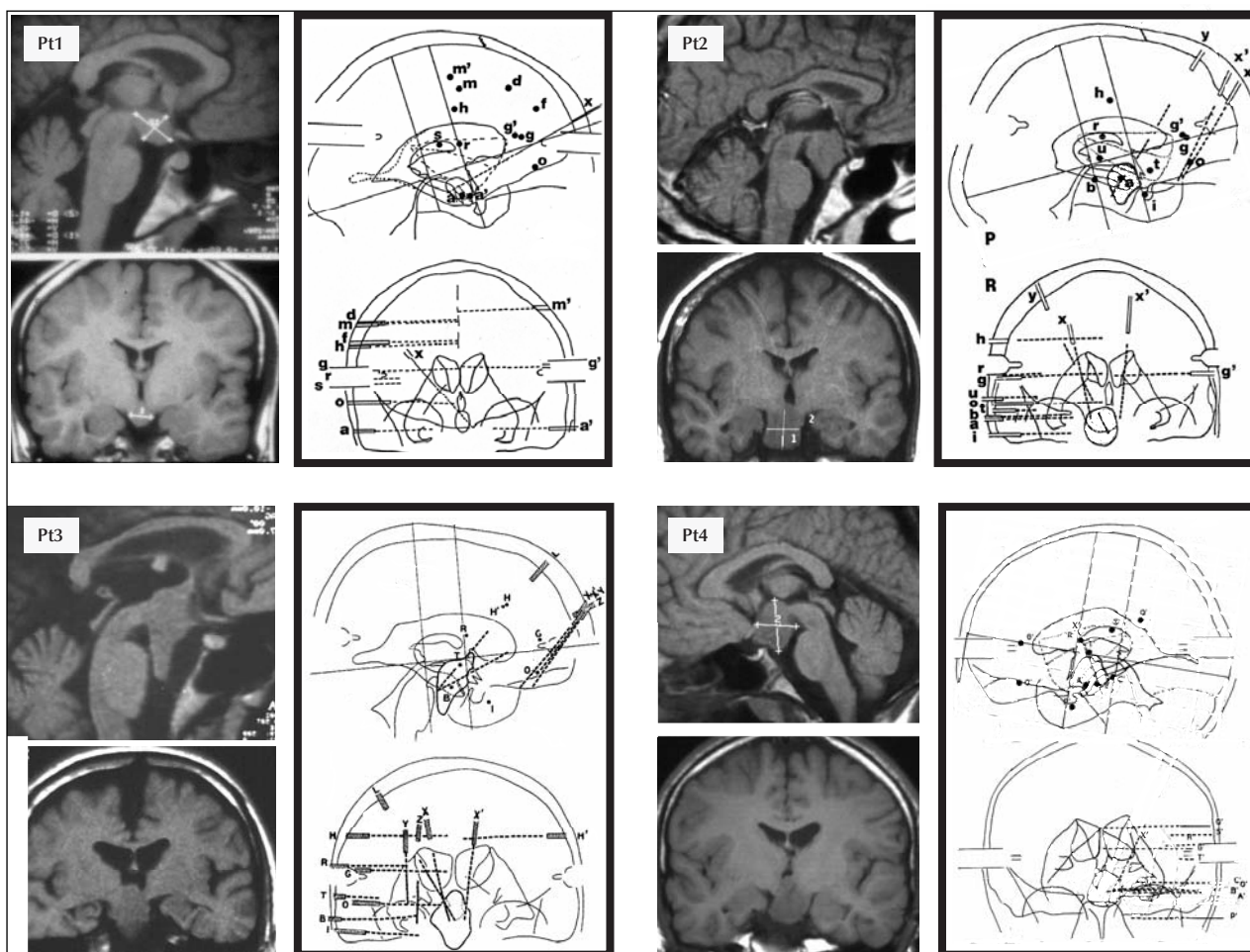


Figure 3. MRI scans and stereotactic schemes of patients n° 1 to 4. The brain areas where electrodes were implanted depended on the hypothesis(es) that had been previously formulated concerning the site(s) of seizure onset and the pathway of preferential ictal spread. Accordingly, intracerebral electrodes were implanted bilaterally but very asymmetrically in three cases (n° 1 to 3), and unilaterally in one (n° 4), targeting more especially the right fronto-central region in patient n° 1, the right fronto-temporal regions in patients n° 2 and 3, and the left temporo-perisylvian areas in patient n° 4. The hamartoma was explored in all patients using an anterior oblique electrode that passed through the frontal lobe. To note that the hamartoma was lateralized in three cases (right side in patients n° 2 and 3, left side in patient n° 4).

Table 3. SEEG findings, surgery and outcome.

Pts	interictal spikes		spontaneous seizures		electrically-induced seizures		surgery	outcome (follow-up)
	HH	cortex	G/D	other types	G/D	other types		
1	+	+	HH	biF	HH	–	stereotactic radiosurgery (2)	no change (4) (6 years)
2	+	+	HH	R F-C-T	HH	–	partial removal of the HH (3)	mild improvement (5 years)
3	+	+	HH	R F ?	–	–	–	no change (9 years)
4	–	+	? (CG ?)	–	A (Hc)	–	L temporal lobectomy	no change (9 years)
5	+	not recorded	not recorded	not recorded	HH	– (1)	chronic HFS of the HH	No change (3 years)

Pts: patients; HH: hypothalamic hamartoma; G/D: gelastic/dacrystic; bi: bilateral; R: right; L: left; F: frontal; C: central; T: temporal; CG: cingulate gyrus; A: amygdala; Hc: hippocampus; HFS: high frequency stimulation; (1): cortical stimulation not performed; (2) Lin Ac, 18 grays – no change of the hypothalamic mass on MRI suggesting that the low dose of X-rays delivered was insufficient; (3) despite two operations, the hypothalamic lesion could not be totally removed and the patient showed only a mild decrease in the frequency of seizures associated with falls; (4) patient deceased during sleep (probable SUDEP).

System, Campbell, CA, USA; and since 1996, Micromed, Treviso, Italy). We used as a reference, one of the lead located in the white matter in four patients, and the Cz scalp-EEG electrode in patient n° 5. Depth EEG activity was displayed using bipolar montage between contiguous contacts. Electrical stimulations were performed under continuous video-EEG control, during sessions that last one to three hours. According to our standard clinical practice [26], and validated safety parameters [27], stimulations were performed between contiguous leads at 1 Hz (pulse width = 3 ms) and 50 Hz (pulse width = 1 ms), using a constant current rectangular pulse generator (World Precision Instruments, New Haven, CT, USA; and since 1996, Micromed, Treviso, Italy). Chronic stimulation in patient n° 5 was applied according to the parameters used in movement disorders.

Results

The main depth EEG findings are summarized in Table 3.

Interictal SEEG findings

As expected from scalp-EEG recordings, spikes and spike-and-waves discharges were recorded in the cortex in the four patients in whom cortical recordings were available. These paroxysmal discharges, though widely extensive, were usually not recorded within the hamartoma (*figure 4*). Conversely, the latter usually exhibited independent well-localized spikes or spike-and-waves (see also *figure 10*), the frequency and amplitude of which varied from one patient to another. In one patient (n° 4), however, the lesion HH was almost electrically silent, without any detectable paroxysmal discharge. Interestingly, in one patient (n° 2), HH spikes were influenced by

sleep, where they became continuous, but disappeared during short bursts of 'spindle-like' activity of unclear significance, located in the hippocampus and the amygdala (*figure 5*).

Gelastic and dacrystic seizures

Three of the four patients in whom gelastic or dacrystic seizures were recorded demonstrated a concurrent low voltage fast activity, followed by a spike-and-waves discharge which remained confined to the hamartoma (*figure 6A*). One of these patients (n° 2) also presented many such HH ictal discharges during sleep, which remained clinically silent (*figure 7A*).

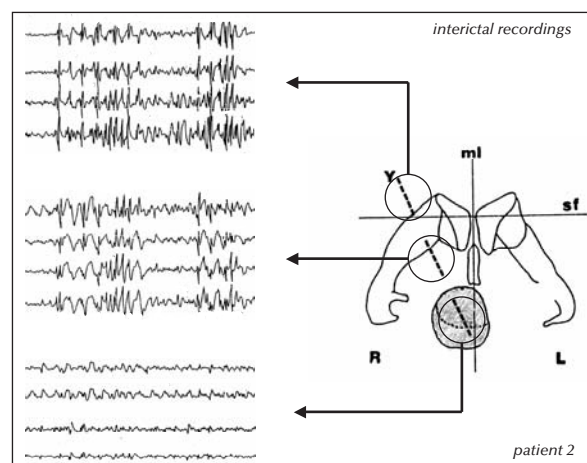


Figure 4. Bipolar recordings along the axis of the electrode that passes through the frontal lobe and explores the hamartoma. Most of the high amplitude spikes and polyspikes recorded in the frontal cortex are not visible in the hamartoma. This latter, conversely, exhibits low amplitude spikes among which most have no expression on the frontal cortex. Y: recording electrode; R/L: right/left; ml: median line; sf: horizontal plane defined by the stereotactic frame.

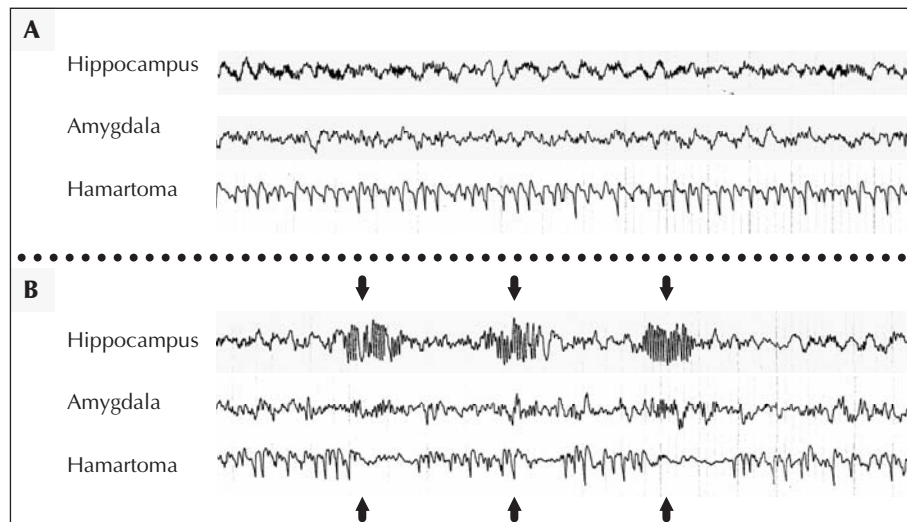


Figure 5. Interictal SEEG recordings during sleep. Same patient as in figure 4. The hamartoma exhibits continuous spikes and spike-and-waves (A), which disappear when brief bursts of fast oscillations (> 20Hz) occur in the hippocampus and amygdala (B, arrows).

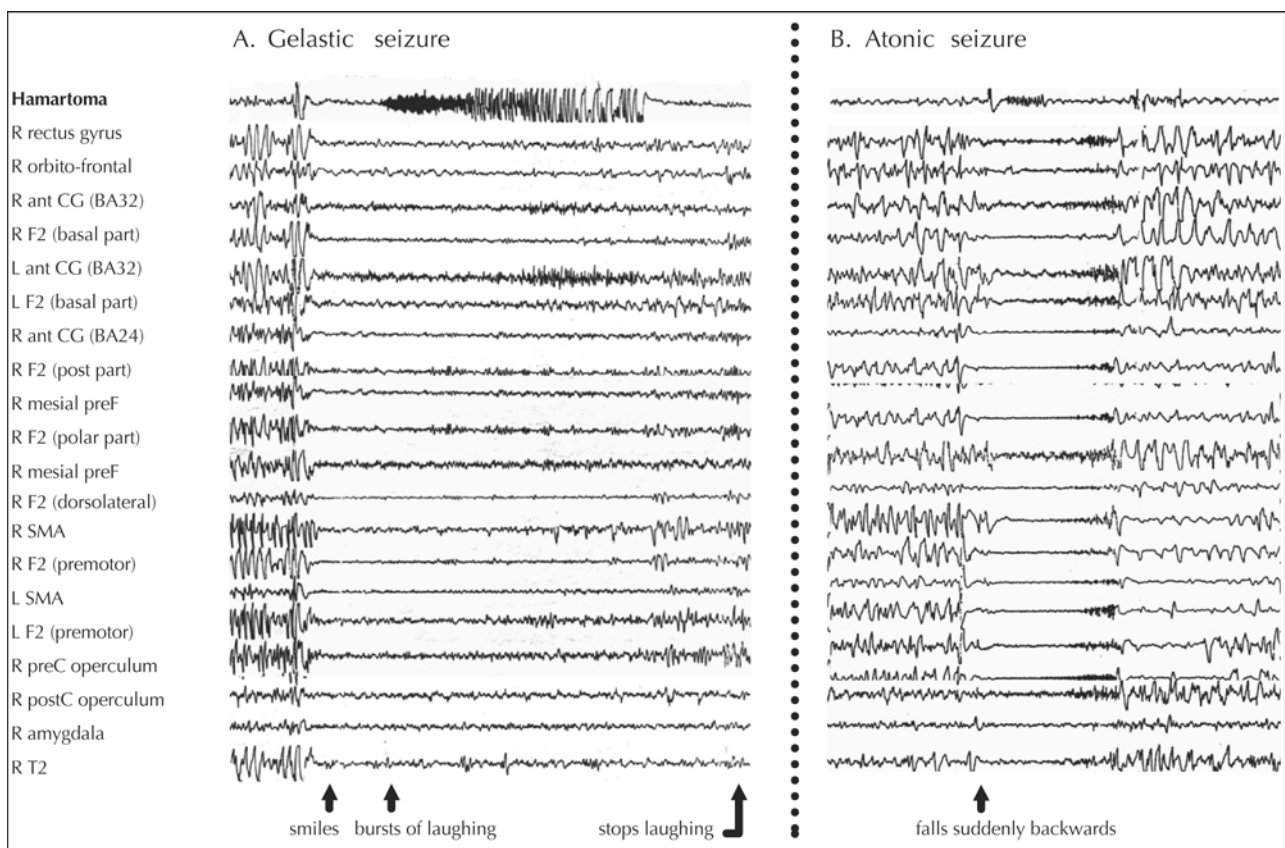


Figure 6. SEEG findings of electroclinical seizures. Same patient as in figures 1 and 2. **A.** Gelastic seizure: the ictal discharge remains well-localized in the hamartoma. Note the diffuse flattening of the cortical EEG activity with disappearance of all abnormalities, and the discrete fast activity recorded over the two cingulate gyri. **B.** Atonic seizure: the ictal discharge is bilateral and widely extended in the cortex, particularly 'tonic' over the the right and left SMA and premotor cortices. The hamartoma is not affected.

R/L: right/left; BA: Brodmann's area; ant/post: anterior/posterior; F2: mid frontal gyrus; CG: cingulate gyrus; preF: prefrontal cortex; SMA: supplementary motor area; preC/postC: precentral/postcentral; T2: second temporal convolution.

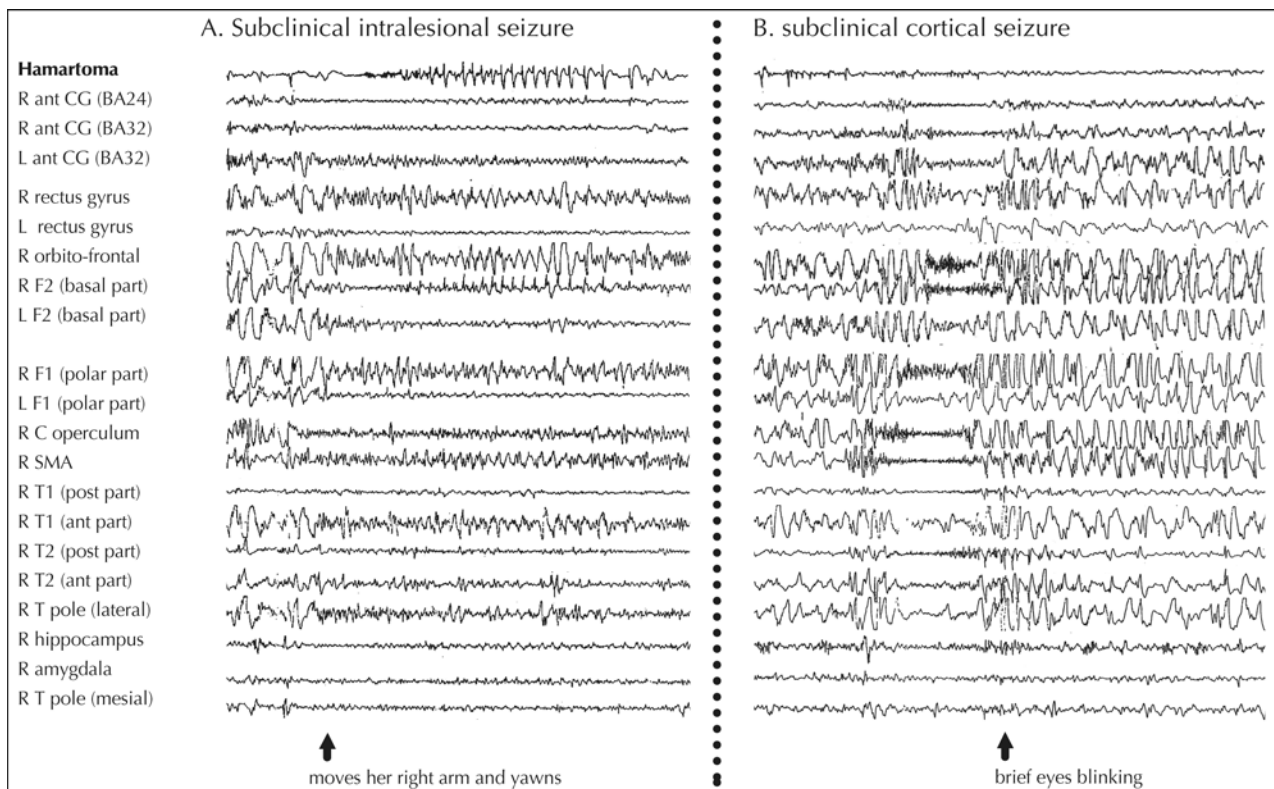


Figure 7. Subclinical ictal SEEG discharges. Same patient as in figures 4 and 5. **A.** Subclinical intralesional seizure: a fast activity occurs in the hamartoma, followed by a rhythmic discharge of spike-and-waves. These changes are partially visible in most of the cortical areas involved during the other subclinical seizures (see B), and particularly on the right fronto-basal, orbito-frontal and cingulate cortices. **B.** Subclinical cortical seizure: the ictal discharge is well-lateralized on the right hemisphere and mainly involves the fronto-basal orbito-cingulate cortices, the SMA, the central cortex, the temporal neocortex, and the fronto-polar region. The hamartoma is not involved. R/L: right/left; BA: Brodmann's area; ant/post: anterior/posterior; F1/F2: superior/mid frontal gyrus; CG: cingulate gyrus; SMA: supplementary motor area; C: central; T: temporal; T1/T2: first/second temporal convolution.

In all three patients, the HH discharges were associated with a diffuse flattening of the cortical EEG activity and a disappearance of interictal abnormalities. Subtle cortical changes (fast activity and/or rhythmic slow waves or spikes) were latter observed over the two cingulate gyri in patient n° 1, the right fronto-centro-temporal region in patient n° 2, or the right orbito-cingulate cortex in patient n° 3.

In contrast, patient n° 4 showed an ictal discharge which predominated at the cortical level, with a diffuse flattening of EEG activity associated with a marked low voltage fast activity over the left cingulate gyrus, and to a lesser degree, the left hippocampus, whereas only subtle changes were recorded in the hamartoma.

Other seizure types

The three patients in whom other types of seizure were recorded showed that the latter were associated with cortical ictal discharges not affecting the HH (see figure 6B). In patient n° 2, similar cortical ictal discharges were also recorded during sleep (see figure 7B), but proved clinically silent.

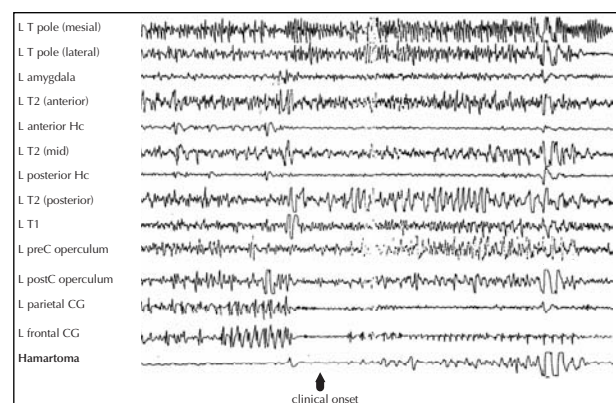


Figure 8. SEEG recorded gelastic seizure in patient n° 4. The hamartoma does not exhibit the same electrical pattern as in the three other patients in whom gelastic seizures were recorded. The low voltage fast activity followed by a spike-and-waves discharge predominates over the left cingulate gyrus. The left hippocampus exhibits a fast activity, whereas the hamartoma only demonstrates subtle changes. L: left; T: temporal; Hc: hippocampus T1/T2: first/second temporal convolution; preC/postC: precentral/postcentral; CG: cingulate gyrus.

Ictal onset appeared either bifrontal (patient n° 1), right fronto-central and lateral temporal (patient n° 2), or bifrontal with a right side predominance (patient n° 3). The lateralization of these ictal discharges was always ipsilateral to the predominating side of the hamartoma.

Interestingly, ictal discharges involved the cingulate gyrus in all three patients, as well as the regions which showed subtle depth EEG changes during gelastic/dacrystic seizures. In fact, the latter could precede the other seizure types, suggesting a causal relationship between the two (figure 9).

Electrical stimulations

Acute stimulation of the hamartoma and the cortex

Acute stimulation of the hamartoma could reproduce gelastic or dacrystic seizures in three of the five patients, when using high frequency parameters (50 Hz), but in only one patient when stimulating at 1 Hz. These stimulation-induced HH seizures were always associated with an epigastric sensation, which was recognized as being part of the dacrystic attacks in one patient (n° 2). Other symptoms could also be induced in patient n° 5, the

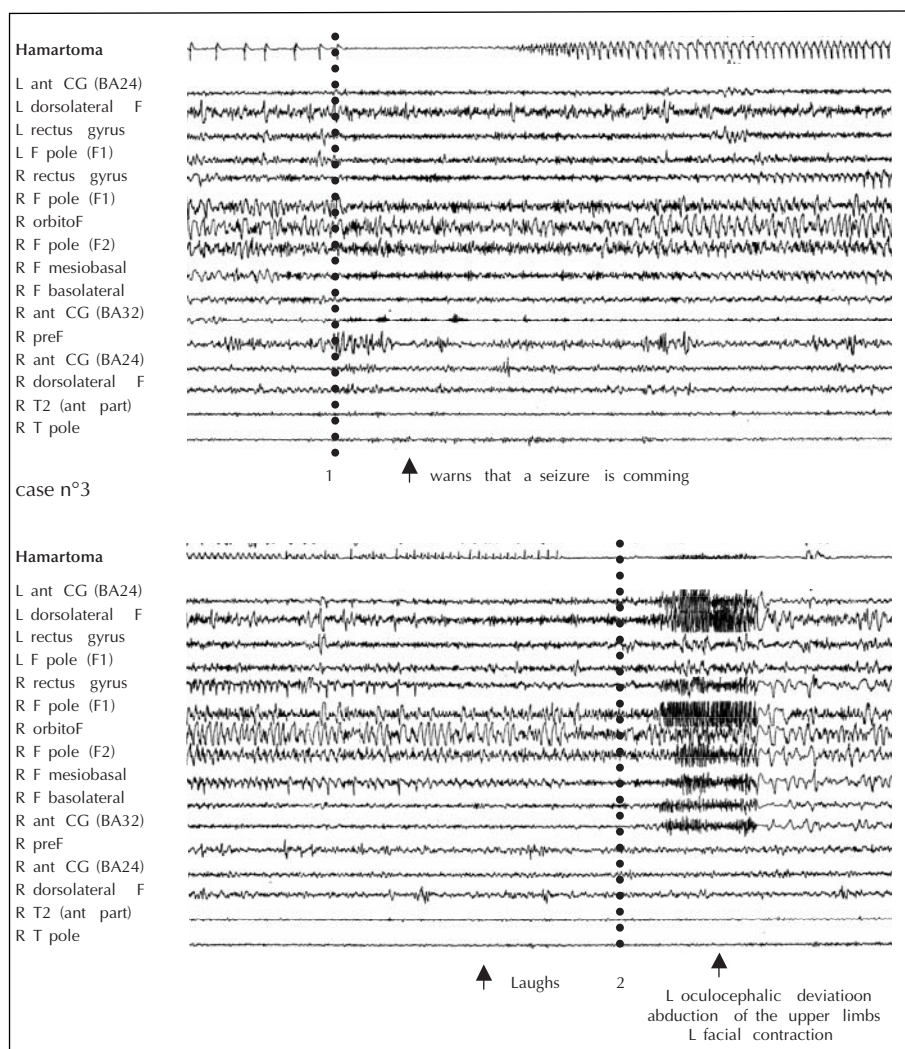


Figure 9. SEEG recording of a gelastic seizure leading to another type of seizure. A low voltage fast activity (1) followed by a spikes-and-waves discharges occurs in the hamartoma, leading to a laughing attack. The other type of seizure occurs at the termination of the intralésional discharge, characterized by a bifrontal polyspikes discharge. To note, however, the disappearance of spikes over the right orbito-cingulate cortex when the patient begins to laugh, followed by the occurrence of a fast activity when the gelastic seizure stops (2).

R/L: right/left; BA: Brodmann's area; ant: anterior; F: frontal; CG: cingulate gyrus; F1: superior frontal gyrus; T: temporal; T2: second temporal convolution.

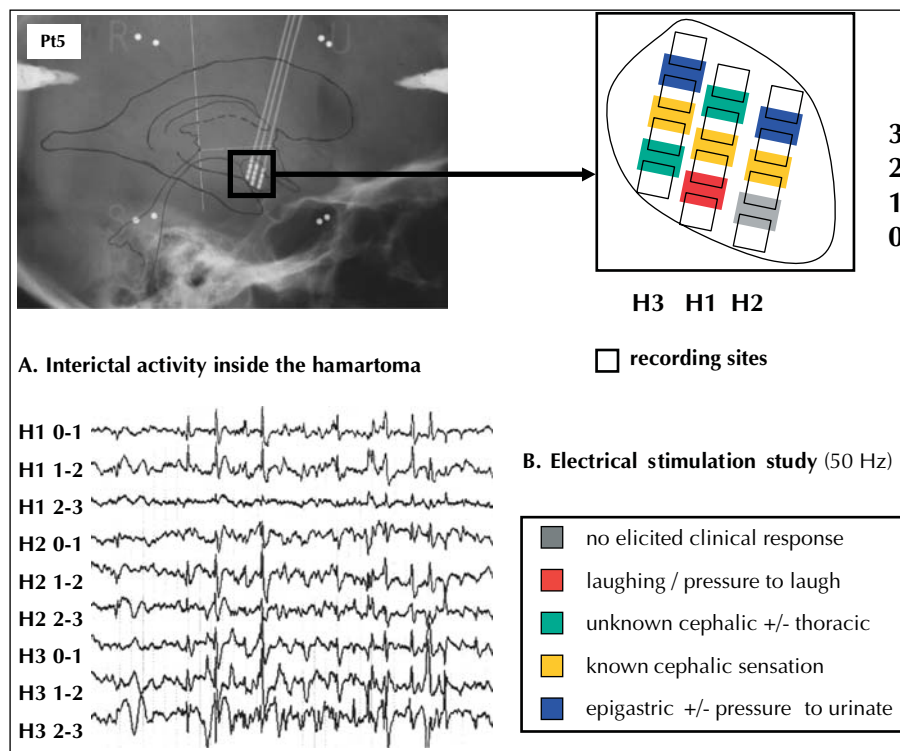


Figure 10. Electrical stimulation study of the hamartoma. In this patient (case n° 5), the hamartoma was investigated using three 4-leads deep-brain stimulation electrodes, so that 12 contacts explored the lesion. As showed on A, the spatial distribution of spikes is not evenly distributed within the hamartoma. Bipolar stimulation (50 Hz, 1 ms, under the after discharge threshold) applied between contiguous contacts shows that many symptoms can be elicited, depending on the part of hamartoma which is stimulated.

type of which varied depending on the part of HH which was stimulated (figure 10).

Conversely, cortical stimulations, performed in two of the three patients with stimulation-induced HH seizures, failed to elicit any ictal discharge or symptom.

In one of the two patients without electrically-induced HH seizure, the stimulation of the hamartoma induced an unknown sensation of warmth over the face (n° 3). In the other patient (n° 4), stimulation of the amygdala could reproduce his usual and complex gelastic seizures, whereas hippocampal stimulation elicited comparable episodes but which lacked their laughing component. However, the left temporal lobectomy performed in this patient failed to control these seizures.

Chronic stimulation of the hamartoma

In patient n° 5, the implantation of three intra-hamartoma electrodes was designed to chronically stimulate the HH. The patient first underwent subacute stimulation (130 Hz-100 μ s – 0.4 mA) during depth-EEG monitoring in order to evaluate the tolerability as well as the impact of the stimulation on the HH firing pattern. Interictal spikes recorded from the hamartoma and from scalp-EEG, almost totally disappeared during the stimulation, and reappeared when the stimulation was interrupted (figure 11). No side effect was reported.

These findings encouraged us to pursue with chronic stimulation which was started in November 1999. We initially decided to stimulate all the leads of the three electrodes, simultaneously, using the following parameters: 130 Hz/90 μ s/0.5V, and then 185 Hz/60 μ s/0.1V. The patient progressively complained of increasingly frequent cephalic auras and pressure to laugh (up to 30 per day), as well as from weight gain (from 63 kgs to 68 kgs during a 84 days period), leading us to stop the stimulation. The latter was resumed five months later, by only stimulating the electrode contact which had been stimulated during the subacute stimulation protocol. Seizure frequency, as well as seizure type, were not clearly modified over a 12 months period during which stimulation was alternatively turned off and on (figure 12), while the patient reported frequent headaches and a weight gain from 66 kgs to 72 kgs. Stimulation was then definitively stopped, allowing the weight to progressively return to 61 kgs during the following months.

Discussion

In this study, we have clearly demonstrated that epileptic seizures associated with hypothalamic hamartoma could exhibit different types of electroclinical patterns. During

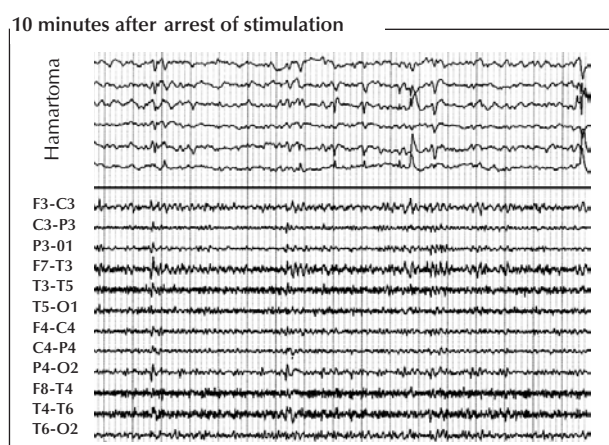
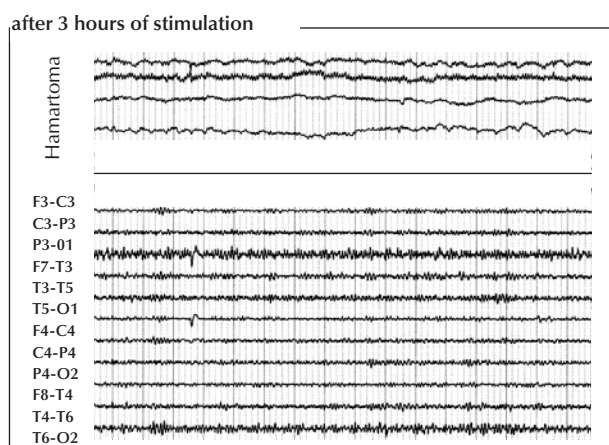
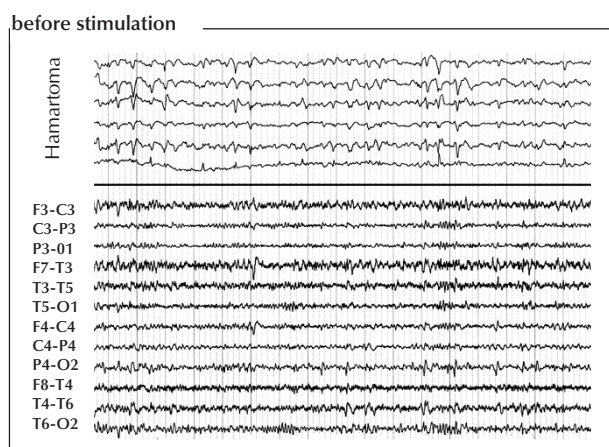


Figure 11. Subacute high frequency stimulation of the hamartoma. Same patient as in figure 10. The stimulation (130 Hz – 100 μ s – 0.4 mA) is applied on one of the 12 contacts which explore the lesion (contact H2-1, see figure 10 for explanation). During the stimulation, disappearance of the spikes located within the lesion. Note that temporo-parietal spikes recorded on the scalp-EEG also disappear.

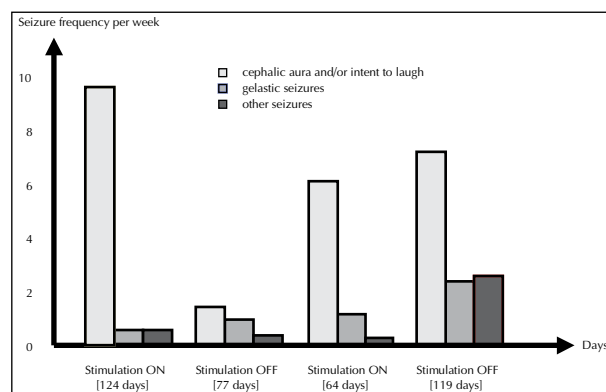


Figure 12. Chronic high frequency stimulation of the hamartoma. Results on seizure frequency, as well as on seizure type, were unclear enough to decide to continue the stimulation, in as much as this latter was not well-tolerated (see text for explanation).

the most typical seizures, i.e., laughing and crying episodes, the epileptic discharges usually arose and remained confined within the hamartoma. In addition, interictal spikes were recorded from the hamartoma in the majority of patients, whereas the stimulation of the HH could reproduce gelastic or dacrystic seizures, as observed by others [5]. These findings, corroborated by the results of ictal SPECT which showed increased blood flow changes from the hypothalamic region during gelastic seizures [5, 11, 21, 22], strongly support the intrinsic epileptogenicity of hypothalamic hamartomas, in as much as its removal, disconnection, irradiation, or coagulation can control the seizures [2-14]. These findings are reminiscent of the observation that patients suffering from hemifacial spasms and cerebellar gangliogliomas demonstrate ictal discharges originating in the vicinity of the tumor, which removal results in seizure remission [28-30].

However, the HH of one of our patient failed to demonstrate spikes or either spontaneous or electrically-induced seizures, raising the issue of other ictal onset sites responsible for gelastic seizures. However, the limited number of intra-hamartoma recording leads, as compared to the size of the HH, could also explained our negative findings in that patient. This possibility was well-illustrated in another patient where three 4-leads electrodes were placed within the hamartoma, showing differences in electrically-induced clinical symptoms from one part of the HH to another (see figure 10). Alternatively, both interictal and ictal EEG findings could be consistent with the view that this patients' gelastic seizures arose from the cortex. Accordingly, the associated ictal semiology was more rich and complex than that observed during laughing attacks in the three previous patients.

If it is now well-established that gelastic and dacrystic seizures usually originate from the hamartoma itself [31], the pathogenesis of the epileptic syndrome associated with HH is far from being fully understood. Particularly, the almost constant occurrence of seizures other than

gelastic/dacrystic episodes remains puzzling, in as much as they seem to arise from various cortical areas the removal of which has consistently failed to control the epilepsy. We have no clear explanation for the mechanisms underlying these seizures, but several arguments support the hypothesis of secondary epileptogenesis. First, the epilepsy associated with HH usually starts with gelastic seizures, while the other seizure types will tend to occur later during the evolution of the illness. Second, scalp-EEG interictal epileptiform abnormalities, which proved to be independent from those recorded in the hamartoma, usually worsen with time, particularly when non-gelastic seizures develop [21]. Third, we observed that the laughing or crying attacks were sometimes immediately followed by the other seizure types, as if ictal discharges within the hamartoma triggered those which seemed to originate in the cortex. Last but not least, data from various centres show that resection of HH, when fully achieved, can control all seizure types.

Secondary epileptogenesis in HH have also been suggested by others [32]. This phenomenon could occur as a consequence of repetitive intra-hamartoma ictal discharges, affecting neighbouring structures involved in the neuromodulation of cortical activity. In that respect, we

propose a speculative pathophysiology in which the mamillo-thalamo-cingulate tract would serve as a relay of HH discharges towards the cortex, the excitability of which would then progressively increase, first leading to interictal epileptiform abnormalities and then to seizures (*figure 13*). This view is supported by the following observations: i) cortical discharges do not seem to occur randomly in the cortex, as showed by the lateralization of scalp EEG abnormalities and intracranially recorded seizures, which proved always ipsilateral to the lesion in those of our patients in whom the hamartoma demonstrated a side predominance; a similar concordance in lateralization was also found between interictal hypometabolism on ^{18}F FDG-PET and HH (Ryvlin *et al.*, this issue); ii) hypothalamic hamartomas which give rise to epileptic seizures are located within the hypothalamus with tight connections with the mamillary bodies [4, 33, 34]; iii) ictal SPECT findings during gelastic seizures have showed that thalamic hyperperfusion could coexist with that observed in the HH [5], whereas thalamic hypometabolism, ipsilateral to HH, was demonstrated by interictal ^{18}F FDG-PET [Ryvlin *et al.*, this issue]; iv) the cingulate gyrus was consistently involved during non-gelastic seizures in this series.

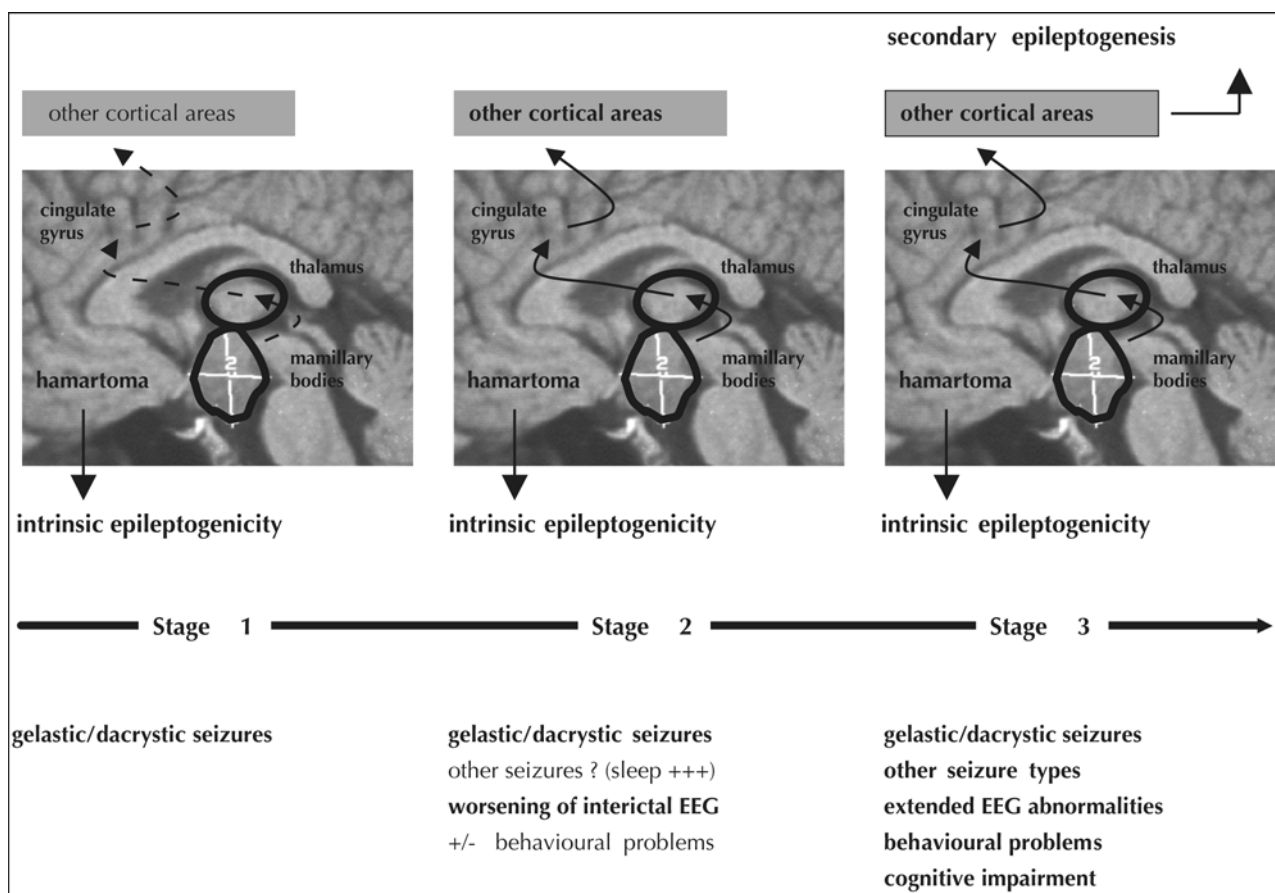


Figure 13. Proposal for the pathophysiology of the epileptic syndrome associated with hypothalamic hamartoma (see text for explanation).

Whether this proposal is valid or not remains a very important issue, since it could provide arguments on the moment to discuss surgery (e.g., worsening of interictal EEG abnormalities, appearance of seizures other than gelastic/dacrystic, behavioral problems) in order to prevent the development of a definite secondary epileptogenesis. It seems likely that this latter, once established, makes more aleatory the effectiveness of the lesion elimination on both kind of seizures. □

References

1. Berkovic SF, Andermann F, Melanson D, Ethier RE, Feindel W, Gloor P. Hypothalamic hamartomas and ictal laughter. Evolution of a characteristic epileptic syndrome and diagnostic value of magnetic resonance imaging. *Ann Neurol* 1988; 23: 429-39.
2. Machado HR, Hoffmann HJ, Hwang PA. Gelastic seizures treated by resection of a hypothalamic hamartoma. *Childs Nerv Syst* 1991; 7: 462-5.
3. Nishio S, Morioka T, Fukui M, Goto Y. Surgical treatment of intractable seizures due to hypothalamic hamartomas. *Epilepsia* 1994; 35: 514-9.
4. Valdez JM, Cristante L, Dammann O, et al. Hypothalamic hamartomas: with special reference to gelastic epilepsy and surgery. *Neurosurgery* 1994; 34: 949-58.
5. Kuzniecky R, Guthrie B, Mountz J, Bebin M, Faught E, Gilliam F, Liu HG. Intrinsic epileptogenesis of hypothalamic hamartomas in gelastic epilepsy. *Ann Neurol* 1997; 42: 60-7.
6. Arita K, Kurisu K, Iida K, et al. Subsidence of seizure induced by stereotactic radiation in a patient with hypothalamic hamartoma. *J Neurosurg* 1998; 89: 645-8.
7. Parrent AG. Stereotactic radiofrequency ablation for the treatment of gelastic seizures associated with hypothalamic hamartoma: case report. *J Neurosurg* 1999; 91: 881-4.
8. Régis J, Bartolomei F, Hayashi M, Roberts D, Chauvel P, Peragut JC. The role of gamma knife surgery in the treatment of severe epilepsies. *Epileptic Disord* 2000; 2: 113-22.
9. Régis J, Bartolomei F, de Toffol B, et al. Gamma knife surgery for epilepsy related to hypothalamic hamartomas. *Neurosurgery* 2000; 47: 1343-51.
10. Unger F, Schrottner O, Haselsberger K, Korner E, Ploier R, Pendl G. Gamma knife radiosurgery for hypothalamic hamartomas in patients with medically intractable epilepsy and precocious puberty: report of two cases. *J Neurosurg* 2000; 92: 726-31.
11. Delalande O, Rodriguez D, Chiron C, Fohlen M. Successful surgical relief of seizures associated with hamartoma of the floor of the fourth ventricle in children: report of two cases. *Neurosurgery* 2001; 49: 726-30.
12. Kramer U, Spector S, Nasser W, Siomin V, Fried I, Constantini S. Surgical treatment of hypothalamic hamartomas and refractory seizures. *Pediatr Neurosurg* 2001; 34: 40-2.
13. Rosenfeld JV, Harvey AS, Wrennall J, et al. Transcallosal resection of hypothalamic hamartomas, with control of seizures, in children with gelastic epilepsy. *Neurosurgery* 2001; 48: 108-18.
14. Dunoyer C, Ragheb J, Resnick T, Alvarez L, Jayakar P, Altman N, Wolf A, Duchowny M. The use of stereotactic radiosurgery to treat intractable childhood partial epilepsy. *Epilepsia* 2002; 43: 292-300.
15. Tassinari CA, Riguzzi P, Rizzi R, Passarelli D, Volpi L. Gelastic seizures. In: *Paediatric epilepsy syndromes and their surgical treatment*. Tuxhorn I, Holthausen H, Boenigk H, eds. London: John Libbey, 1997: 429-46.
16. Plouin P, Ponsot G, Dulac O, Diebler C, Arthuis M. Hypothalamic Hamartomas and laughing seizures. *Rev Electroencephalogr Neurophysiol Clin* 1983; 13: 312-6.
17. Cascino GD, Andermann F, Berkovic SF, Kuzniecky R, Shalhough FW, Keene DL, Bladin PF, Kelly PJ, Olivier A, Feindel W. Gelastic seizures and hypothalamic hamartomas: evaluation of patients undergoing chronic intracranial EEG monitoring and outcome of surgical treatment. *Neurology* 1993; 43: 747-50.
18. Munari C, Kahane P, Francione S, Hoffmann D, Tassi L, Cusmai R, Vigevano F, Pasquier B, Betti O.O. Role of the hypothalamic hamartoma in the genesis of gelastic fits (a video-stereo-EEG study). *Electroenceph clin Neurophysiol* 1995; 95: 154-60.
19. Kahane P, Tassi L, Hoffmann D, Francione S, Grataud-Juery G, Pasquier B, Munari C. Crises dacrystiques et hamartome hypothalamique: à propos d'une observation vidéo-stéréo-EEG. *Epilepsies* 1994; 6: 259-79.
20. Kahane P, Munari C, Minotti L, Hoffmann D, Tassi L, Pasquier B, Grand S, Benabid AL. The role of hypothalamic hamartoma in the genesis of gelastic and dacrystic seizures. In: *Paediatric epilepsy syndromes and their surgical treatment*. Tuxhorn I, Holthausen H, Boenigk H, eds. London: John Libbey, 1997: 447-61.
21. Arroyo S, Santamaria J, Sanmarti F, Lomena F, Catafau A, Casamitjana R, Setoain J, Tolosa E. Ictal laughter associated with paroxysmal hypothalamopituitary dysfunction. *Epilepsia* 1997; 38: 114-7.
22. Di Fazio MP, Davis RG. Utility of early single-photon emission computed tomography (SPECT) in neonatal gelastic epilepsy associated with hypothalamic hamartomas. *J Child Neurol* 2000; 15: 414-7.
23. Tasch E, Cendes F, Li LM, Dubeau F, Montes J, Rosenblatt B, Andermann F, Arnold D. Hypothalamic hamartomas and gelastic epilepsy: a spectroscopic study. *Neurology* 1998; 51: 1046-50.
24. Kahane P, Di Leo M, Hoffmann D, Munari C. Ictal bradycardia in a patient presenting a hypothalamic hamartoma: a stereo-EEG study. *Epilepsia* 1999; 40: 522-9.
25. Kremer S, Minotti L, Thiriaux A, Grand S, Satre V, Le Bas JF, Kahane P. Epilepsy and hypothalamic hamartoma: look at the hand. *Epileptic Disord* 2003; 5: 27-30.
26. Kahane P, Tassi L, Francione S, Hoffmann D, Lo Russo G, Munari C. Manifestations électro-cliniques induites par la stimulation électrique intra-cérébrale par « chocs » dans les épilepsies temporales. *Neurophysiol Clin* 1993; 22: 305-26.
27. Gordon B, Lesser RP, Rance NE, et al. Parameters for direct cortical electrical stimulation in the human: histopathological confirmation. *Electroencephalogr clin Neurophysiol* 1990; 75: 371-7.
28. Harvey AS, Jayakar P, Duchowny M, Resnick T, Prats A, Altman N, Renfro JB. Hemifacial seizures and cerebellar gangliogliomas: an epilepsy syndrome of infancy with seizures of cerebellar origin. *Ann Neurol* 1996; 40: 91-8.

29. McLone DG, Stieg PE, Scott RM, *et al.* Cerebellar epilepsy. *Neurosurgery* 1998; 42: 1106-11.
30. Chae H, Kim SK, Wang KJ, Kim KJ, Hwang YS, Cho BK. Hemifacial seizure of cerebellar ganglioglioma origin: seizure control by tumor resection. *Epilepsia* 2001; Vol: 1204-7.
31. Berkovic SF, Arzimanoglou A, Kuzniecky R, Harvey S, Palmini A, Andermann F. Hypothalamic hamartoma and seizures: a treatable epileptic encephalopathy. *Epilepsia* 2003; 44: 969-73.
32. Freeman JL, Harvey AS, Rosenfeld JV, *et al.* Generalized epilepsy in hypothalamic hamartomas: evolution and postoperative resolution. *Neurology* 2003; 60: 762-7.
33. Arita K, *et al.* Relationship between magnetic resonance imaging findings and clinical manifestations of hypothalamic hamartoma. *J Neurosurg* 1999; 91: 212-20.
34. Debeneix C, Bourgeois M, Trivin C, Sainte-Rose C, Brauner R. Hypothalamic hamartoma: comparison of clinical presentation and magnetic resonance images. *Horm Res* 2001; 56: 12-8.